

Case report

VASOSPASTIC ANGINA AND SCOMBROID SYNDROME: A CASE REPORT

Coppola G, Caccamo G, Bacarella D, Corrado E, Caruso M, Cannavò MG¹, Assennato P, Novo S

U.O.C. di Cardiologia, Scuola di Specializzazione in Malattie dell'Apparato Cardiovascolare, Dipartimento di Medicina Interna, Malattie Cardiovascolari e Nefrourologiche, Policlinico Universitario "Paolo Giaccone", Palermo, Italia. ¹U.O. di Pronto Soccorso e Medicina d'Urgenza, Policlinico Universitario "Paolo Giaccone", Palermo, Italia

Correspondence and offprint requests to: Giuseppa Caccamo, E-mail: capiuc@libero.it

ABSTRACT

Scombroid syndrome is a fish poisoning characterised by the onset of symptoms compatible with a pseudoallergic reaction; it is rarely also responsible of signs and symptoms of acute coronary syndromes, as demonstrated in this case report.

Key words: scombroid syndrome, chest pain, vasospasm, hypotension, arrhythmias

INTRODUCTION

Scombroid syndrome, or histamine fish poisoning (HFP), is a poisoning related to the accumulation of a heat stable toxin in the flesh of red meat fish such as tuna, mackerel, skipjack and dolphin that has been stored at insufficiently low temperatures. Muscle tissue undergoes bacteria-induced degradation (Morganella, Klebsiella, Proteus, Enterobacter, Vibrio) that facilitates in 3-5 hours the decarboxylation of histidine to histamine (1). HFP is responsible of symptoms associated with pseudoallergy such as flushing, rash, swelling of the face or tongue, sweating, palpitations, nausea, vomiting, diarrhea, headache and in severe cases, bronchospasm, hypotension up to shock, chest pain from coronary vasospasm.

CASE REPORT

We report the case of a 56-year-old man admitted to the emergency department of our hospital for the onset of a syndrome characterized by facial rash, paraesthesia, headache,

severe hypotension, sweating, developing immediately after eating cooked tuna. Smoking habits was the unique risk factor for cardiovascular disease. After administration of clorfenamine 10 mg i.v. and methylprednisolone 250 mg i.v., he underwent a cardiologic evaluation with electrocardiograms (ECG) because of the persistence of hypotension (SBP 80 mmHg) and sinus tachycardia interrupted by ventricular ectopy (Figure 1A). Few minutes later the patient suffered from a retrosternal constrictive pain which justified the execution of new ECG in which we observed a gradual ST segment depression in lateral leads and then, after few minutes, a sudden bradycardia characterised by an heart rate of 40 bpm and a single episode of advanced atrioventricular block requiring atropine i.v. For the persistence of angina, a new ECG was performed and it showed a subepicardial lesion in inferior and right leads (Figure 1B), which justified the administration of unfractionated heparin and lysine acetylsalicylate. We started also an infusion of dopamine because of persistent hypotension. The patient was immediately transferred to the Intensive Coronary Care Unit, where we observed a significant improvement of haemodynamic conditions with normal systolic blood pressure values (130/60 mmHg), and the administration of the inotropic agent was interrupted.

The following ECG showed total regression of the subepicardial lesion in the inferior and right leads and ST segment depression in anterior leads (Figure 1C); considering the abnormal behaviour of this suspected acute coronary syndrome, we decided to perform immediately a coronary and left ventricular angiography (CVG) after administration of abciximab (an i.v. bolus followed by infusion) and clopidogrel 300 mg per os. CVG showed a left ventricle with a normal size and function (ejection fraction 55%), characterised by a hypokinetic anterior wall; dominant right coronary artery without any significant stenosis, left anterior descending artery with a critical stenosis in the middle segment,

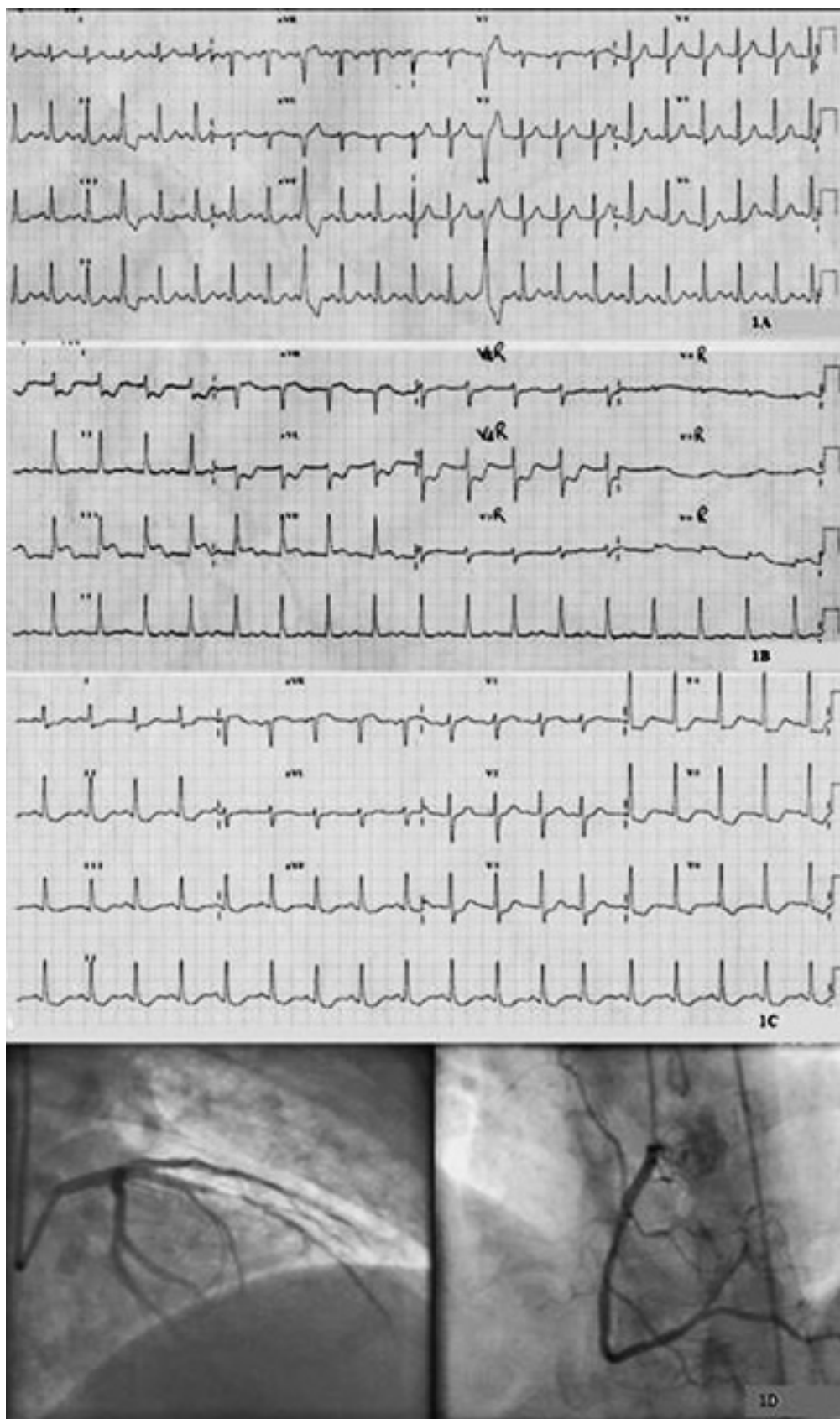


Figure 1: **A)** sinus tachycardia interrupted by ventricular ectopy; **B)** subepicardial lesion in inferior and right leads; **C)** total regression of the subepicardial lesion in inferior and right leads and ST segment depression in anterior leads; **D)** on the left side left anterior descending artery with critical stenosis involved the middle trait, on the right side dominant right coronary artery without any significant stenosis.

involving the ostio-proximal segment of the first diagonal branch (Figure 1D). During CVG, both arteries showed enhanced vasomotility with evidence of episodes of spasm, behaviour confirmed by intra-arterial infusion of nitrates. In the light of the presence of a critical stenosis, and the partial response to nitrates, we performed percutaneous coronary intervention (PCI) on the anterior descending artery through a bare metal stent implant. Anti-ischaemic and anti-thrombotic therapy was performed. After PCI, we observed a low increase of Troponin I levels, with a maximum of 1.09 ng/ml (normal value: 0.00-0.15 ng/ml). After 4 days, as usual before discharge, the patient underwent echocardiographic evaluation which showed normal left ventricle ejection fraction with no kinesis alteration.

DISCUSSION

The fishes most commonly involved in the pathogenesis of HFP belong to the "Scombridae species" (tuna, mackerel), although unusual cases seem to be related to the consumption of fish belonging to the "Clupeidae species" or non scombroid fish, such as sardines, anchovies, herrings. According to most of the published literature, the ingestion of histamine, a biogenic amine normally present at levels less than 0.1 mg/100 g of fish, is the main cause of the onset of symptoms. The Food and Drug Administration maximum allowable histamine level is 5 mg /100 g of fish. The maintenance of inadequate refrigeration at temperatures above 4°-10°C, both after catching and during handling, storage and canning, can facilitate the activity of histidine decarboxylase produced by certain bacteria (*Proteus*, *Klebsiella*, *Aerobacter*, *E. coli*), which represent normal constituents of surface flora of the fishes: in this way histamine and other decomposition products are generated by bacterial enzymatic conversion of free histidine and they rapidly reach toxic levels (20-50 mg/100 g of fish) (2). The onset of the typical symptoms usually occurs within a few hours after the ingestion of the implicated fish, which often is characterised by a peppery bitter taste.

Since scombroid poisoning is related to histamine toxicity, severity of symptoms is associated not only to the concentration of the amine but also to the variations between individuals in their susceptibility to the ingestion of itself. Moreover, histamine toxicity is potentiated through inhibition of metabolising enzymes that detoxify itself (isoniazid, Monoamine oxidase inhibitors-MAOIs) (3), and presence of putrescine and cadaverine, which are formed post-mortem in the muscular tissue of the fish.

Histamine is an important chemical mediator of inflammation, whose activities (airway smooth muscle contraction, gastric acid secretion, induction of pain and itching through sensory nerve stimulation) depend on the interaction with H1 and H2 receptors which we can find in the target tissues. In particular histamine induces the vascular endothelium to release nitric oxide, leading to vasodilatation and erythema, increased vascular permeability and oedema; moreover decreasing peripheral resistance due to vasodilatation may provoke a significant fall in blood pressure or shock in more severe cases. During an allergic episode, systemic vasodilatation, reduced venous return, leakage of plasma and volume

loss due to increased vascular permeability and the ensuing depression of cardiac output contribute to coronary hypoperfusion with subsequent myocardial damage. Indeed, during severe acute allergic episodes the circulating blood volume may decrease by as much as 35% within 10 min due to transfer of intravascular fluid to the extravascular space and severe vasodilation resistant to epinephrine and responding only to other potent vasoconstrictors has been reported. This shift of fluid volume is countered by compensatory vasopressor mechanisms involving the release of epinephrine and norepinephrine as well as the activation of the angiotensin system. However, according to experimental and clinical evidence, the human heart represents the primary target of anaphylaxis, which, after a transient cardiac reaction, early leads to pump failure, with consequent hypotension and myocardial ischaemia.

Finally it is known that histamine in coronary artery has a vasoconstrictive action mediated by H1-histamine receptors in smooth muscle cells. Therefore, during an anaphylactic episode, it could induce coronary vasospasm (4-5). Apart from being a powerful coronary vasoconstrictor, histamine can 1) activate platelets and it potentiates the aggregatory response of other agonists including adrenaline, 5-hydroxytryptamine and thrombin; 2) it can induce pro-inflammatory cytokine production from endothelial cells, 3) it upregulates P-selectin on the endothelial cell surface. Moreover, a novel action of histamine is the induction of the expression of tissue factor, a key enzyme in the activation of coagulation.

CONCLUSIONS

HFP is often misunderstood because of the similarity from a clinical point of view to conditions such as anaphylaxis, septic shock, angioedema; the presence of coronary events is rare but already documented (6). However, the recent recruitment of fish belonging to the incriminated species is an essential element to confirm the diagnosis. The element which aroused particular interest was the involvement of two other members of the same household. The appearance of face and chest rash associated with paraesthesia motivated the hospitalisation at another Intensive Unit Care. In all three cases histamine levels were detected five times higher than normal.

In our case, the poisoning, probably, elicited a vasospastic reaction on a coronary without significant stenosis (i.e. right coronary artery) and, on the other hand, a destabilisation of a pre-existing coronary plaques by plaque erosion, endothelial and platelet activation and vasolability on left anterior descending artery; as acute coronary syndrome without immunological reactions and anaphylaxis, we believed that the best treatment could be PCI and antiplatelet therapy. In fact, according to the literature about Kounis syndrome, it seems to be essential to perform coronary angiography in order to discern its three different variants: coronary vasospasm versus coronary thrombosis versus drug-eluting stent thrombosis (7). In the last two cases percutaneous transluminal coronary angioplasty with implantation of a stent clearly represents a decisive treatment (8), as described in our case report.

CONFLICT OF INTEREST: None.

REFERENCES

1. Kerr GW, Parke TRJ. Scombroid poisoning – a pseudoallergic syndrome. *J R Soc Med* 1998; 91: 83-84.
2. Iannuzzi M, N D'Ignazio, Bressy L, De Sio A. Severe scombroid fish poisoning syndrome requiring aggressive fluid resuscitation in the emergency department: two case reports. *Minerva Anestesiol* 2007; 73: 481-483.
3. Sechi A, Pollet C, Bertolo O, Risucci P. Sindrome sgombroide in D.E.A. FCE news. it II Medical Network.
4. Lionte C. An unusual cause of hypotension and abnormal electrocardiogram ECG. – scombroid poisoning. *Eur J Med* 2010; 53: 292-297.
5. Tadashi W, Mitsuru A, Nobuhito Y, et al. Coronary vasospasm secondary to allergic reaction following food ingestion: a case of type I variant Kounis syndrome. *Heart Vessels* 2010; 25: 263-266.
6. Lavon O, Lurie Y, Bentur Y. Scombroid Fish Poisoning in Israel, 2005-2007. *IMAJ* 2008; 10: 789-792.
7. Biteker M. A new classification of Kounis syndrome. *Int J Cardiol.* 2010; 1453: 553.
8. Patanè S, Marte F, Bella GDI, et al. Acute myocardial infarction and Kounis syndrome. *Int J Cardiol* 2009; 134: e45-e46.