

ANNALI ITALIANI DI CHIRURGIA

Fondati da Giovanni Pascale nel 1922

DIRETTORE: NICOLA PICARDI

Giornale Ufficiale delle

- *Società Italiana dei Chirurghi Universitari (S.I.C.U.)*
- *Società Italiana di Chirurgia d'Urgenza e del Trauma (S.I.C.U.T.)*
- *Società Triveneta di Chirurgia*



«La rivista è presente in Pubmed, Medlars, Medline, ISI Master Journal List, Science Citation Index Expanded, ICMJE»

Gli abstracts sono raggiungibili su INTERNET agli indirizzi:

*www.annaliitalianidichirurgia.com; www.annitalchir.com;
oppure su: www.pubmed.com; www.medlars.com;
www.medline.cos.com*

Gennaio - Febbraio 2013

EDIZIONI LUIGI POZZI

Carcinoma showing thymus-like differentiation (CASTLE)

A case report



Ann. Ital. Chir., 2013 84: 77-80
pii: S0003469X13018782

Girolamo Geraci, Chiara Lo Nigro, Antonio Sciuto, Roberta Modica, Cupido Francesco, Carmelo Sciumè, Andrea Attard, Giuseppe Modica

University of Palermo, Palermo, Italy
Section of General and Thoracic Surgery (Chief: Modica G, MD, PhD)
Sezione di Chirurgia Generale ad Indirizzo Toracico (Direttore: Prof. G. Modica)

Carcinoma showing thymus-like differentiation (CASTLE). A case report

INTRODUCTION: Carcinoma showing thymus-like differentiation (CASTLE) is a rare malignant thyroid cancer. We report a case of CASTLE treated with surgery and adjuvant external neck radiation therapy.

MATERIALS AND METHODS: We experienced a case of CASTLE in a 63-year-old man, who presented with a neck mass due to enlarged and hard thyroid gland, most notably in the right lobe, without palpable cervical nodes.

RESULTS: Total thyroidectomy was performed for both diagnostic and therapeutic purposes. Histologic examination of the specimen showed a "thymus like" thyroid cancer; the tumor, partially circumscribed, lobulated, involved both lobes, and in more points reached the capsule of the organ and infiltrated perithyroid muscle tissue. After immunohistochemical assay (CK19 +, CK20 -, thyroglobulin -, calcitonin -, CD5 +, CD117 +), a diagnosis of CASTLE was made.

DISCUSSION: CASTLE is a rare, malignant tumour of the thyroid gland, with histopathological features similar to squamous cell carcinoma, but with a more favourable prognosis. Preoperative diagnosis is difficult. CASTLE is usually cured surgically with total thyroidectomy and selective neck dissection, followed by radiotherapy.

CONCLUSIONS: Surgery and radiotherapy are effective to manage thyroid CASTLE tumors.

KEY WORDS: Carcinoma showing thymic-like differentiation, CASTLE, Surgery, thyroid cancer

Introduction

Carcinoma showing thymus-like differentiation (CASTLE) is a rare intrathyroidal neoplasm, probably arising from ectopic thymus or branchial pouch remnants.

CASTLE has histopathologic features similar to those of squamous cell carcinoma (SCC) of the thyroid and other organs, but a more favorable prognosis.

We report the case of a CASTLE in a 63-year-old man who underwent curative surgery and adjuvant therapy.

Case report

A 63-year-old Caucasian man with not significant medical history referred to our hospital because of recent slow enlargement of the thyroid and dysphagia.

Physical examination revealed a slight asymmetry of the neck, with an enlarged and hard thyroid gland, most notably in the right lobe. There were no discrete palpable lymph nodes.

Pervenuto in Redazione Febbraio 2012. Accettato per la pubblicazione Marzo 2012

Correspondence to: Girolamo Geraci, MD, Aggregate Professor, University of Palermo, Section of General and Thoracic Surgery, 90100 Palermo, Italy (e-mail: girolamo.geraci@unipa.it)

Systemic investigations did not yield significant findings. Thyroid tests (TSH 2.19 IU/ml [NV 0.49-4.67]; FT4 1.30 ng/dl [NV 0.71-1.85]; FT3 2.08 pg/ml [NV 1.45-3.48]; anti-tireoglobulin antibodies 19.3 IU/ml [NV 0-100]; anti-thyroperoxibase antibodies 1.00 UI/ml [NV 0-80]) and calcitonin (1.7 pg/ml [NV < 18.9]) were within normal limits.

Thyroid ultrasound showed large confluent lobulated nodules in the lower part of the left and right lobes, with perilesional power-doppler signal.

Needle aspiration cytology showed proliferative thyroid cells without follicular pattern ("dyscohesive population of tumor cells forming occasional loose clusters on a background of abundant blood").

The patient underwent surgery. After cervicotomy, neck exploration revealed hard left and right thyroid lobes, adherent to the sternothyroid muscle and to the soft tissue in the anterior-superior mediastinum (Fig. 1a). There was no evidence of vascular invasion or nodal metastases on either side of the neck and total thyroidectomy was carried out (Fig. 1b) without intraoperative complications.

The postoperative course was uneventful and the patient was discharged on the 2nd post-operative day.

At histologic examination, the two lobes were respectively 5x3x1.5 cm and 7x3.5x2 cm large, and exhibited focal whitish areas with soft margins in the lower part of both lobes. Microscopically, the tumor was partially circumscribed, with vague lobulation and cords separated by fibrous bands (Fig. 1c-d) in more points it reached the capsule and infiltrated perithyroid muscle tissue. Immunohistochemistry was positive for CK19, CD5 (Fig. 1e), CEA, CD117 and negative for CK20, thyroglobulin and

calcitonin. Thus a diagnosis of CASTLE was made.

The patient underwent postoperative neck radiation therapy one month after surgery.

Neither recurrence nor relapse have been observed after one-year follow-up.

Discussion

CASTLE is a rare (less than 30 cases in the literature), indolent and slow-growing malignant neoplasm of the thyroid resembling lymphoepithelioma-like and (SCC) of the thymus¹. It was first described by Miyauchi in 1981, named "carcinoma showing thymic-like elements" (CASTLE) by Chan and Rosai ten years later and, finally, in 2004, the disease was categorized as independent type of thyroid tumor in the WHO classification².

CASTLE usually occurs in adults in the fifth decade of life, with a slight female prevalence (1:1.3). Distant metastases (brain, liver, lung) have been described².

The tumor is postulated to originate from ectopic thymic tissue or branchial pouch remnants in or adjacent to the thyroid, because it usually occurs in the lower part of the thyroid. Moreover, it shows several features of thymic differentiation, such as the following: 1 lobulation on cut surfaces; 2 expansive growth pattern; 3 thick, fibrous bands dividing the tumor cell nests; 4 presence of many lymphocytes; 5 perivascular spaces with lymphocytes; 6 rare or infrequent mitoses; and 7 oval, vesicular nuclei, sharply defined nucleoli, and pale cytoplasm.

Furthermore, lack of foci of papillary, follicular, medullary or anaplastic carcinoma is also an important characteristic¹.

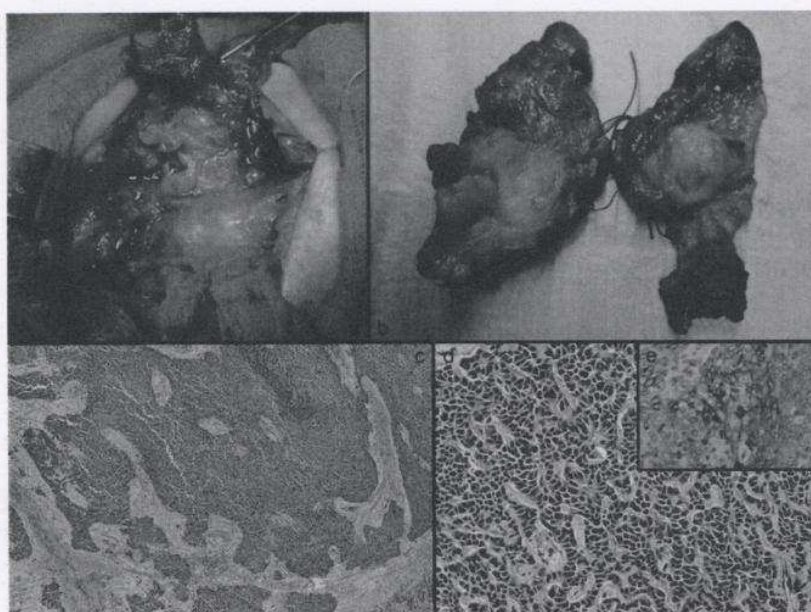


Fig. 1: A) surgical dissection of right lobe strictly adherent to the trachea antero-superior mediastinum; B) surgical specimen; C-D) lobulation and cords separated by fibrous bands; E) CD5 immunostaining.

Although CASTLE histologically resembles SCC, clinical outcomes for in patients with CASTLE are much better than in those with SCC. Therefore, accurate diagnosis with careful morphologic examination of H&E-stained sections is required. CASTLE shares typical morphologic features with some types of thymomas, such as: ¹ pleomorphic or spindle-shaped cells with oval nuclei having well-defined nucleoli; ² well-bounded cell nests; ³ peritumoral and intratumoral infiltration of lymphocytes and plasma cells ³.

Preoperative diagnosis of CASTLE is difficult. Clinical findings, such as hard consistency of the tumor with poor mobility, and frequent involvement of adjacent structures, are common to other advanced thyroid carcinomas (lymphoepithelioma, SCC). FNAB does not play a pivotal role in preoperative diagnosis. In the experience of Ito reported that only one case of twenty was correctly diagnosed by FNAB, but the remaining cases showed cytologic features not typical of other thyroid carcinomas ¹. Unusual cytologic aspects, associated with typical but aspecific features of CASTLE, such as location in the lower part of the thyroid, lobulated pattern at ultrasonography, lack of calcification and lack of rapid tumor enlargement, can be a clue to consider the diagnosis of CASTLE ⁴.

Many studies have indicated that CD5 is useful for diagnosing CASTLE because it is a marker for carcinoma of thymic origin. However not all thymic carcinomas express CD5, as reported by Dorfman (20% CD5 negative, specificity about 100%) ³, Berezowsky (55% CD5 negative) ⁵ and Ito (18% CD5 negative) ¹, probably because the antibody for CD5 requires delicate immunohistochemical staining, and the staining results are not reliable for specimens with poor fixation. Finally, Youens et al., affirmed that "the immunohistochemical profile of CASTLE is identical to that of thymic carcinoma" ⁶. However, the lack of CD5 expression does not completely rule out CASTLE and the final diagnosis should be based on the H&E findings ¹.

In a systematic literature review, Roka showed that node-negative CASTLE had a low risk of recurrence and curative surgery with resection of involved adjacent organs, and systematic lymph node dissection, followed by radiation therapy can prevent locoregional recurrence ⁷.

Moreover, although the number of metastatic nodes is usually small, about 30% of patients have nodal metastases in the lateral compartment, and from this evidence, it may be better to perform modified radical neck dissection not only therapeutically, but also prophylactically ¹.

Ito et al. reported 90% and 82% 5- and 10-year cause-specific survival rates, respectively in their series of 25 cases of CASTLE ¹.

Due to the rarity of the disease and its indolent behaviour, data on adjuvant or palliative chemotherapy are

anecdotal and, to date, effective drugs have not been found ². Many authors have ^{1,4,7} described the usefulness of post-operative radiation therapy. Patients with tumor extension to adjacent organs underwent postoperative radiation more frequently, possibly because surgeons have considered such tumors biologically aggressive and likely to recur. This can explain why the recurrence rate of patients who underwent radiation therapy (40%) was higher than in patients treated only with surgery (27%).

Conclusions

CASTLE is a rare malignant thyroid tumor. Preoperative diagnosis is difficult because neither cytology nor immunohistochemical markers may be sufficient to confirm diagnosis. In thyroid tumors with malignant cytomorphological features but lacking the identifying characteristics of other more common neoplasms, CASTLE should be considered in differential diagnosis.

CD5 immunoreactivity in a primary malignant epithelial thyroid tumor (particularly one arising in the lower pole and with lobulated ultrasonographic appearance) is highly suggestive of CASTLE.

In our case, complete surgical resection followed by radiation therapy was performed, and according to the literature, the patient had a favourable outcome.

Riassunto

INTRODUZIONE: I carcinomi a differenziazione "thymus-like" (CASTLE) della tiroide sono rari. Riportiamo di seguito il caso di un CASTLE della tiroide trattata con successo mediante chirurgia radicale e radioterapia.

MATERIALI E METODI: Riportiamo il caso di un CASTLE della tiroide in un maschio caucasico 63enne, presentato alla nostra osservazione con una massa tiroidea dura a carico del lobo destro, in assenza di linfonopatie laterocervicali clinicamente apprezzabili.

RISULTATI: È stata eseguita una tiroidectomia totale. L'esame istologico della tiroide ha mostrato una neoplasia tiroidea "thymus like"; la neoplasia, parzialmente circoscritta, lobulata, coinvolgeva entrambi i lobi, ed in più punti raggiungeva la capsula infiltrava il tessuto muscolare peritiroideo (IHC: CK19 +, CK20-, tiroglobulina -, calcitonina -, CD5 +, CD117 +).

DISCUSSIONE: Il CASTLE è una rara neoplasia a comportamento biologico maligno della tiroide, con quadro istopatologico simile al carcinoma a cellule squamose, ma con una prognosi più favorevole. La diagnosi preoperatoria è difficoltosa. CASTLE è solitamente trattato con chirurgia radicale, linfonodectomia selettiva dei linfonodi del collo e radioterapia postoperatoria.

CONCLUSIONS: Il trattamento combinato con chirurgia radicale seguita da radioterapia si è dimostrato efficace nella gestione dei CASTLE della tiroide.

References

1. Ito Y, Miyaguchi A, Nakamura Y, Miya A, Kobayashi K, Kakudo K: *Clinicopathologic significance of intrathyroidal epithelial thymoma/carcinoma showing thymus-like differentiation*. Am J Clin Pathol, 2007; 127:230-36.

2. Cappelli C, Tironi A, Marchetti GP, Pirola I, De Martino E, Delbarba A, Castellano M, Agabiti Rosei E.: *Aggressive thyroid carcinoma showing thymic-like differentiation (CASTLE): Case report and review of the literature*. Endocrine Journal, 2008; 55:685-90.

3. Dorfman DM, Shahsafaei A, Miyauchi A: *Intrathyroidal epithelial thymoma (ITET)/carcinoma showing thymus-like differentiation (CASTLE) exhibits CD5 immunoreactivity: New evidence for thymic differentiation*. Histopathology. 1998; 32:104-09.

4. Miyauchi A, Kuma K, Matsuzuka F, et al.: *Intrathyroidal epithelial thymoma: a report of 6 cases with immunohistochemical and ultrastructural studies [in Japanese, with English abstract]*. Endocr Surg, 1989; 6:289-95.

5. Berezowski K, Grimes MM, Gal A, et al.: *CD5 immunoreactivity of epithelial cells in thymic carcinoma and CASTLE using paraffin-embedded tissue*. Am J Clin Pathol, 1996; 106:483-86.

6. Youens KE, Bean SM, Dodd LG, Jones CK: *Thyroid carcinoma showing thymus-like differentiation (CASTLE): Case report with cytomorphology and review of the literature*. Diagn Cytopathol, 2011; 39:204-09.

7. Roka S, Kornek G, Schuller J, Ortmann E, Feichtinger J, Ambruster C: *Carcinoma showing thymic-like elements: a rare malignancy of the thyroid gland*. Br J Surg, 2004; 91:142-45.