

# Therapeutic Efficacy of Magnesium Valproate in Succinic Semialdehyde Dehydrogenase Deficiency

Elena Vanadia • K. Michael Gibson • Phillip L. Pearl •  
Emanuele Trapolino • Salvatore Mangano •  
Francesca Vanadia

Received: 26 February 2012 / Revised: 18 July 2012 / Accepted: 24 July 2012 / Published online: 22 August 2012  
© SSIEM and Springer-Verlag Berlin Heidelberg 2013

**Abstract** Succinic semialdehyde dehydrogenase deficiency (SSADHD), a disorder of  $\gamma$ -aminobutyric acid (GABA) metabolism, manifests typically as a nonprogressive neurodevelopmental disorder with cognitive deficiency, neuropsychiatric morbidity and epilepsy. Therapy targets symptomatic seizures and neurobehavioral disturbances. We report an adolescent female with SSADHD whose unresponsiveness to a broad spectrum of antiepileptics was circumvented with magnesium valproate (MgVPA). Epilepsy remains well controlled in our patient, with concomitant improvements in behavioral symptoms and an absence of adverse symptoms. MgVPA intervention may have utility in SSADHD.

## Introduction

The clinical, metabolic, and molecular phenotypes of SSADHD have been reviewed (Pearl et al. 2003a, b). The metabolic lesion leads to accumulation of two

neuromodulators, gamma-hydroxybutyric acid (GHB) and GABA (Wong et al. 2004). The phenotype of SSADHD is primarily neuropsychiatric, with onset in childhood with hypotonia and developmental delay. Expressive language impairment and sleep anomalies are also encountered. Atypical absence, myoclonic and generalized tonic-clonic seizures may be observed, as well as photosensitivity, electrical status epilepticus of sleep and partial seizures (Pearl et al. 2011). Chronic high endogenous levels of GABA likely elicit down-regulation of GABA receptors, a hypothesis supported by data derived from the corresponding murine model (Cortez et al. 2004; Buzzi et al. 2006; Wu et al. 2006) and clinical PET and transcranial magnetic stimulation studies (Pearl et al. 2009, 2011).

Neuropsychiatric morbidity represents an ongoing challenge in adolescents and adults with SSADHD (Knerr et al. 2008). Behavioral abnormalities include hyperactivity, aggression, inattention, obsessive-compulsive symptoms and sleep disturbances, and present treatment challenges especially when compounded with seizures. Vigabatrin (VGB), an irreversible inhibitor of GABA transaminase, is predicted to decrease GHB production (Ergezinger et al. 2003; Gropman 2003; Gibson et al. 1995). Clinical outcomes with VGB, however, have been inconsistent, and progressive retinopathy with consequent peripheral vision loss represents an undesirable long-term adverse effect (Chiron and Dulac 2011). Moreover, additional augmentation of GABA levels during VGB intervention may also be undesirable. Other antiepileptics, including carbamazepine, lamotrigine and ethosuximide have been variably effective, and benzodiazepines may be efficacious for moderating agitation and aggression, but adversely exacerbate ataxia and hypotonia. Additional pharmaceuticals (e.g., methylphenidate, risperidone, fluoxetine and fluvoxamine) have been employed in selected cases to treat behavioral symptoms (Pearl et al. 2003a, b).

---

Communicated by: Gajja Salomons

---

Competing interests: None declared

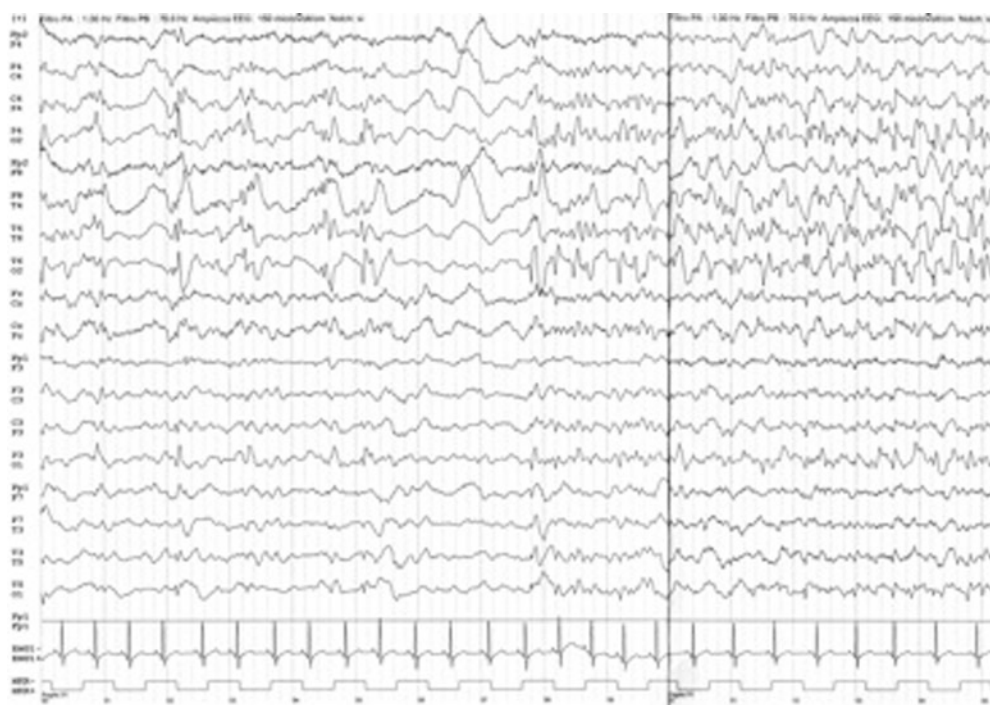
---

E. Vanadia (✉) • S. Mangano  
Department of Child and Adolescent Neuropsychiatry, University  
of Palermo, Palermo, Italy  
e-mail: elena.vanadia@libero.it

K.M. Gibson  
Section of Clinical Pharmacology, Washington State University,  
Spokane, WA, USA

P.L. Pearl  
Department of Neurology, Children's National Medical Center, George  
Washington University School of Medicine, Washington, DC, USA

E. Trapolino • F. Vanadia  
Department of Child and Adolescent Neuropsychiatry, "G. Di Cristina"  
Hospital, Palermo, Italy



**Fig. 1** EEG (age 14) showing right periodic lateralized epileptiform discharges (PLEDS) evolving into rhythmic sharp and slow wave ictal activity maximally from the right posterior temporal region

Valproic acid has not been broadly employed in SSADHD, primarily due to its ability to inhibit any residual SSADH activity (Simler et al. 1981; Shinka et al 2003). Anecdotal reports, however, have reported improved seizure control, without improvements in neurobehavioral symptoms. We present an adolescent with SSADHD in whom MgVPA showed both efficacy in seizure control and an improved behavioral phenotype.

## Case Report

The second of two sibs, our patient was born following a full-term pregnancy with a normal birth and perinatal course. She presented in infancy with developmental delay and diffuse hypotonia. Associated manifestations included hyporeflexia, delayed speech, ataxia, hyperkinesia, short attention span, stereotyped movements, and EEG abnormalities at 3 years of age.

Diagnostic studies at 1 year of age (basic metabolic panel, cranial magnetic resonance imaging) were normal. Until 7 years of age no pharmacological interventions were employed. MgVPA therapy (20 mg/kg/day) was introduced at 7 years based upon behavioral difficulties and EEG alterations, without observable adverse effects. At age 13, MgVPA was stopped because a reasonable level of performance had been achieved and the parents requested treatment termination.

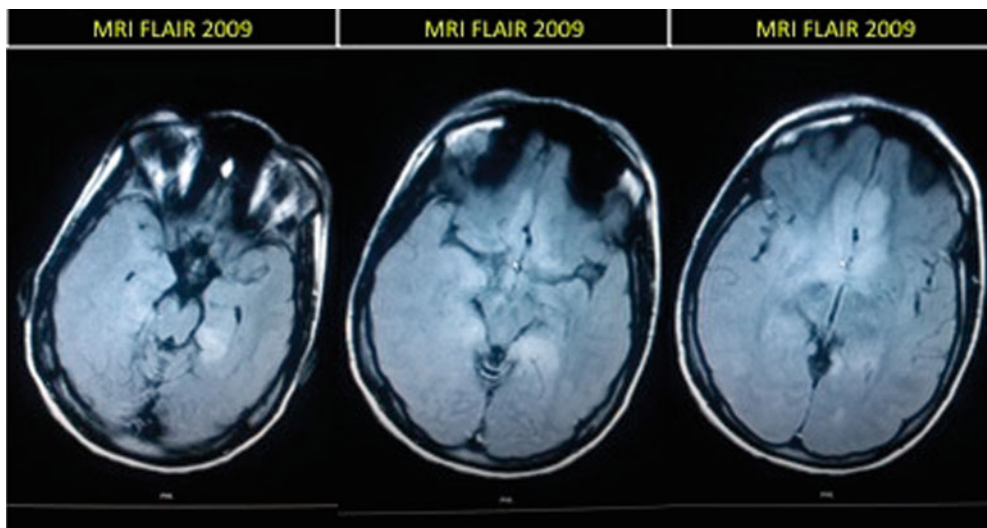
One year following cessation of MgVPA administration, the patient displayed a febrile episode with gradual decay of her state of vigilance and new onset of complex partial seizures. The latter were characterized by altered interpersonal interactions, fluctuating vigilance, disorientation, bewildered appearance, expression of fear, dysarthria and clonus involving primarily the left arm.

At this time (age 14 years), EEG recordings revealed disorganization of the basic background rhythm with slow waves of high voltage predominantly in the right hemisphere associated with a pseudo-periodic sharp-wave discharges mainly localized on the right hemisphere. In addition, the EEG showed intermixed sharp-wave discharges maximally emanating from the right posterior temporal regions and rhythmic sequences of theta/delta activity localized on the same regions (Fig. 1).

Magnetic resonance imaging at this time showed signal alterations characterized by T2/FLAIR hyperintense signal, marked T1 hypointensity, and restricted diffusion of the bilateral parasagittal frontal lobes and right insula and temporal lobe (Fig. 2).

There were no changes following gadolinium administration, and there was a normal appearance of the circle of Willis with magnetic resonance angiography.

Additional laboratory evaluations were normal for ammonia, lactate, hematological panels, and hormonal assays, as were virological studies other than the evidence of prior EBV infection. Cerebrospinal fluid showed



**Fig. 2** T2/FLAIR MRI showing extensive abnormalities of the bilateral parasagittal frontal lobes and right insula and temporal lobe

normal parameters and no detection of oligoclonal bands, CMV, EBV, HHV6, HSV1,2, VZV, or Mycoplasma DNA.

Urine organic acid analysis revealed moderate elevation of GHB with subtle elevations of 4,5 dihydroxyhexanoic acid lactone and threo 4,5 hydroxy hexanoic acid. Confirmation of SSADHD was established via molecular analysis that identified a homozygous deletion of two nucleotides in exon 1 (c.160-161delCT) (as previously described by Akaboshi et al. 2003). This allele was confirmed as heterozygous in both parents.

The patient was treated with acyclovir, ceftriaxone, dexamethasone and barbiturates intravenously, in addition to a number of enteral antiepileptics (carbamazepine, oxcarbazepine, levetiracetam, phenobarbital). Intervention with antiepileptics was subsequently stopped due to adverse effects. Olanzapine was prescribed for ensuing psychiatric symptoms, without evidence of clinical benefit.

At age 15 years, MgVPA (15 mg/kg/day) was reintroduced due to ongoing seizure activity and deteriorating behavior resulting in a gradual improvement in behavior performances and seizure control. Blood parameters (liver functions, ammonia, erythrocyte, white cell, and platelet counts) were cautiously monitored with normal results. One year following MgVPA reintroduction, our patient remained seizure-free with marked behavioral improvements. Significantly, there was an improvement in disinhibited behavior including nonrecognition of danger, aggression and coprolalia. The EEG demonstrated improved background organization (Fig. 3).

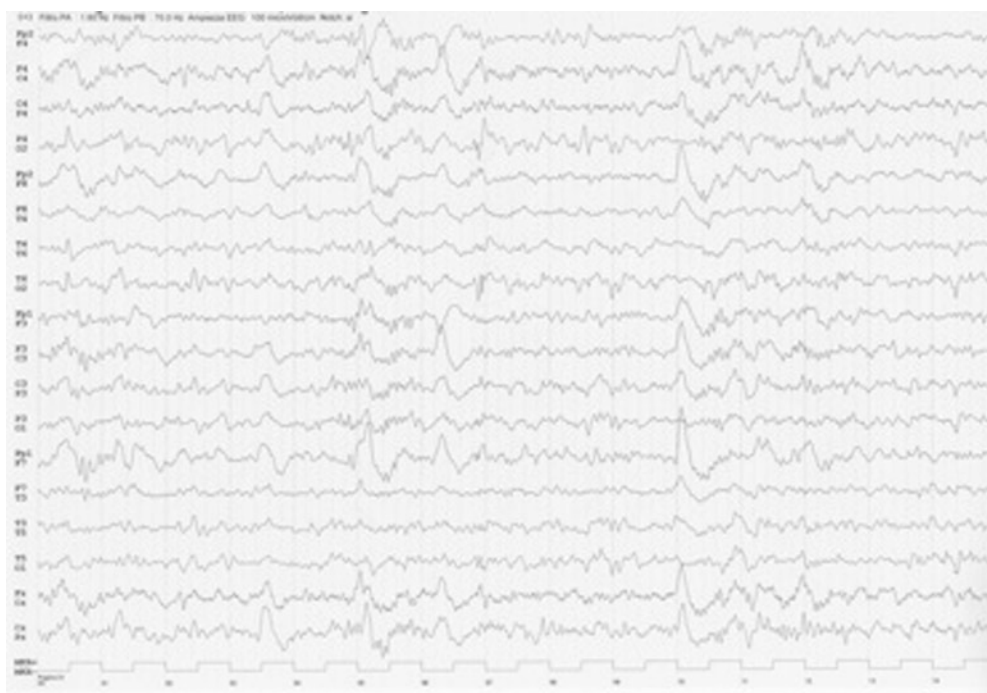MRI, repeated at 16 years of age, revealed evolution of the previously documented acute changes (Fig. 4).

## Discussion

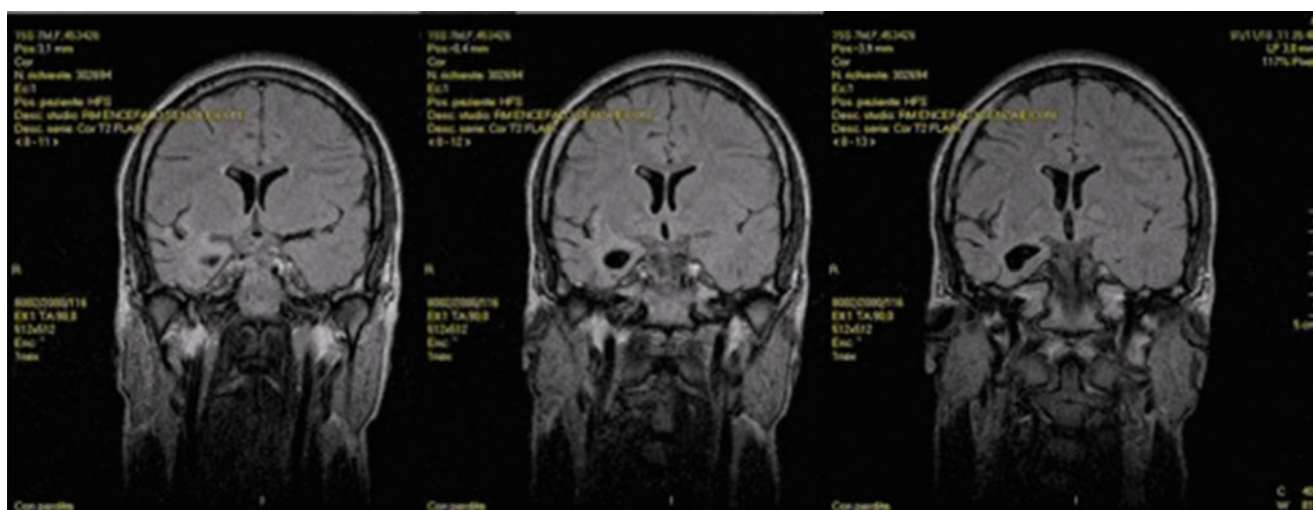
Our patient with confirmed SSADH deficiency presented with neurological deterioration characterized by complex partial seizures and possible limbic encephalitis at 14 years of age. Although there are concerns about a relative contraindication to using valproate in this patient population, our patient had no adverse effects during its use (MgVPA 20 mg/kg/day) in childhood when selected to treat a combination of neuropsychiatric deficits and then appeared to benefit from this agent after presenting with the encephalitic illness.

Magnesium and MgVPA have been successfully employed in other epileptic and learning disorders (Dósa et al. 2010; Zou et al. 2010; Porras-Kattz et al. 2011). For example, Mg has been used to mitigate refractory status epilepticus in patients with POLG-1 mutations (Pandey et al. 2010; Visser et al. 2011). With the recent clinical emphasis on avoiding valproate in children with POLG-1 mutations because of potential precipitation of epilepsy partialis continuans (Saneto et al. 2010), it is possible that magnesium had an important therapeutic role in our patient despite the general clinical tendency to avoid valproate in SSADH deficiency due to potential inhibition of residual enzymatic activity (Shinka et al. 2003). Overall, it appears that valproate was beneficial toward seizure amelioration and improved behavioral features for our patient's condition, and there may have been a therapeutic role for magnesium, which will require further characterization.

*In conclusion*, we present therapeutic efficacy of MgVPA in the behavioral and epileptic phenotype in a patient with SSADH deficiency. Valproate is not necessarily contraindicated in SSADH deficiency, and magnesium may have an important role.



**Fig. 3** Follow-up EEG (age 16 years) showing improvement with more background symmetry and reduction in the right hemispheric epileptiform activity



**Fig. 4** Follow-up MRI after 2 year interval. FLAIR sequences show evolution of the lesion with loss of parenchyma in the right temporal and insular areas

**Acknowledgements** The SSADH deficiency diagnosis was obtained from the valuable collaboration of Dr. Cinzia Castana, Pediatric Unit, “G. Di Cristina” Hospital, Palermo, Italy

## References

- Akaboshi S, Hogema BM, Novelletto A, Malaspina P, Salomons GS, Maropoulos GD, Jakobs C, Grompe M, Gibson KM (2003) Mutational spectrum of the succinate semialdehyde dehydrogenase (ALDH5A1) gene and functional analysis of 27 novel disease-causing mutations in patients with SSADH deficiency. *Hum Mutat* 22(6):442–450
- Buzzi A, Wu Y, Frantseva MV, Perez Velazquez JL, Cortez MA, Liu CC, Shen LQ, Gibson KM, Snead OC 3rd (2006) Succinic semialdehyde dehydrogenase deficiency: GABAB receptor-mediated function. *Brain Res* 1090(1):15–22
- Chiron C, Dulac O (2011) Epilepsy: vigabatrin treatment and visual field loss. *Nat Rev Neurol* 7(4):189–190
- Cortez MA, Wu Y, Gibson KM, Snead OC 3rd (2004) Absence seizures in succinic semialdehyde dehydrogenase deficient mice: a model of juvenile absence epilepsy. *Pharmacol Biochem Behav* 79(3):547–553
- Dósa Z, Nieto-Gonzalez JL, Korshoej AR, Gibson KM, Jensen K (2010) Effect of gene dosage on single-cell hippocampal electrophysiology in a murine model of SSADH deficiency (gamma-hydroxybutyric aciduria). *Epilepsy Res* 90(1–2):39–46



- Ergezinger K, Jeschke R, Frauendienst-Egger G, Korall H, Gibson KM, Schuster VH (2003) Monitoring of 4-hydroxybutyric acid levels in body fluids during vigabatrin treatment in succinic semialdehyde dehydrogenase deficiency. *Ann Neurol* 54(5):686–689
- Gibson KM, Jakobs C, Ogier H, Hagenfeldt L, Eeg-Olofsson KE, Eeg-Olofsson O, Aksu F, Weber HP, Rossier E, Vollmer B et al (1995) Vigabatrin therapy in six patients with succinic semialdehyde dehydrogenase deficiency. *J Inher Metab Dis* 18(2):143–146
- Gropman A (2003) Vigabatrin and newer interventions in succinic semialdehyde dehydrogenase deficiency. *Ann Neurol* 54 (Suppl 6):S66–S72
- Knerr I, Gibson KM, Jakobs C, Pearl PL (2008) Neuropsychiatric morbidity in adolescent and adult succinic semialdehyde dehydrogenase deficiency patients. *CNS Spectr* 13(7):598–605
- Pandey M, Gupta A, Baduni N, Vijfdar H, Sinha S, Jain A (2010) Refractory status epilepticus—magnesium as rescue therapy. *Anaesth Intensive Care* 38(5):962
- Pearl PL, Gibson KM, Acosta MT, Vezina LG, Theodore WH, Rogawski MA, Novotny EJ, Gropman A, Conry JA, Berry GT, Tuchman M (2003a) Clinical spectrum of succinic semialdehyde dehydrogenase deficiency. *Neurology* 60(9):1413–1417
- Pearl PL, Novotny EJ, Acosta MT, Jakobs C, Gibson KM (2003b) Succinic semialdehyde dehydrogenase deficiency in children and adults. *Ann Neurol* 54(Suppl 6):S73–S80
- Pearl PL, Gibson KM, Quezado Z, Dustin I, Taylor J, Trzcinski S, Schreiber J, Forester K, Reeves-Tyer P, Liew C, Shamim S, Herscovitch P, Carson RE, Butman JA, Jakobs C, Theodore WH (2009) Decreased GABA-A binding on FMZ-PET in succinic semialdehyde dehydrogenase (SSADH) deficiency. *Neurology* 73:423–429
- Pearl PL, Shukla L, Theodore WH, Jakobs C, Michael Gibson K (2011) Epilepsy in succinic semialdehyde dehydrogenase deficiency, a disorder of GABA metabolism. *Brain Dev* 33(9):796–805
- Porras-Kattz E, Harmony T, Ricardo-Garcell J, Gal n L, Fern ndez T, Prado-Alcal  R, Avecilla-Ram rez G, S nchez-Moreno L, Barrera-Res ndiz J, Corsi-Cabrera M, Valencia-Solis E (2011) Magnesium valproate in learning disabled children with interictal paroxysmal EEG patterns: preliminary report. *Neurosci Lett* 492 (2):99–104
- Saneto RP, Lee IC, Koenig MK, Bao X, Weng SW, Naviaux RK, Wong LJ (2010) POLG DNA testing as an emerging standard of care before instituting valproic acid therapy for pediatric seizure disorders. *Seizure* 19(3):140–146
- Shinka T, Ohfu M, Hirose S, Kuhara T (2003) Effect of valproic acid on the urinary metabolic profile of a patient with succinic semialdehyde dehydrogenase deficiency. *J Chromatogr B Analyt Technol Biomed Life Sci* 792(1):99–106
- Simler S, Ciesielski L, Klein M, Gobaille S, Mandel P (1981) Mechanism of action of an anticonvulsant, sodium dipropylacetate. *C R Seances Soc Biol Fil* 175(1):114–119
- Visser NA, Braun KP, Leijten FS, van Nieuwenhuizen O, Wokke JH, van den Bergh WM (2011) Magnesium treatment for patients with refractory status epilepticus due to POLG1-mutations. *J Neurol* 258(2):218–222
- Wong CG, Chan KF, Gibson KM, Snead OC (2004) Gamma-hydroxybutyric acid: neurobiology and toxicology of a recreational drug. *Toxicol Rev* 23(1):3–20
- Wu Y, Buzzi A, Frantseva M, Velazquez JP, Cortez M, Liu C, Shen L, Gibson KM, Snead OC 3rd (2006) Status epilepticus in mice deficient for succinate semialdehyde dehydrogenase: GABAA receptor-mediated mechanisms. *Ann Neurol* 59(1):42–52
- Zou LP, Wang X, Dong CH, Chen CH, Zhao W, Zhao RY (2010) Three-week combination treatment with ACTH + magnesium sulfate versus ACTH monotherapy for infantile spasms: a 24-week, randomized, open-label, follow-up study in China. *Clin Ther* 32(4):692–700