

## A simple technique to improve residual skin plasticity for scrotal reconstruction in Fournier's Gangrene

V.D. Palumbo<sup>1,2,3</sup>, G. Damiano<sup>2</sup>, G. Spinelli<sup>2</sup>, G. Tomasello<sup>2,3</sup>, G. Cocchiara<sup>2</sup>, S. De Luca<sup>2</sup>, S. Randazzo<sup>1</sup>, S. Ficarella<sup>2</sup>, A. Bruno<sup>2</sup>, A.I. Lo Monte<sup>2,3</sup>

<sup>1</sup>PhD course on Surgical Biotechnologies and Regenerative Medicine, and <sup>3</sup>Department of Surgical and Oncological Sciences, University of Palermo, Palermo, Italy; <sup>2</sup>AOUP "P. Giaccone" Department of General Surgery, Urgency and Organ Transplantation, Palermo, Italy

### Abstract

A 50 years-old man developed 24 hours after hemorrhoidectomy a severe Fournier's gangrene of the scrotum necessitating surgical excision of more than 2/3 of scrotal skin followed by hyperbaric oxygen therapy. After the resolution of the septic phase, scrotum reconstruction was obtained by tissue expansion to avoid more invasive advanced reconstructive techniques. The procedure consisted of an enzymatic and mechanical debridement and progressive skin expansion by package of gauzes of increasing volume covered with a collagenase-cloramphenicol ointment (Iruxo1®- Smith and Nephew, Italy), then closing the wound edges by temporary stitches to put under tension the skin. The reestablishment of the natural elasticity of the scrotal skin was obtained in ten days and at the final closure of the wound edges an acceptable optimal aesthetic result was achieved. *Clin Ter* 2012; 163(5):e315-318

**Key-words:** enzymatic debridement, Fournier's gangrene, tissue expansion

### Introduction

Fournier's gangrene is a fulminant necrotizing fasciitis of genitalia and perineum, which occurs in patients with diabetes, alcoholism, obesity, and other predisposing diseases (1, 2). Despite modern antibiotic therapy, extensive early surgery and improved intensive care, morbidity and mortality still reach 67% (3-7). Death risk is classified by the Fournier's Gangrene Severity Index (FGSI) (8).

Primary healing of the wound is usually impossible due to the relevant skin loss and the reconstruction of the scrotum might represent a technical challenge. Several experiences using skin grafting (9-11) and tissue expansion techniques (12, 13) have been reported.

A simple technique to increase the elasticity for tissue expansion of residual scrotal skin is hereafter described in a case report.

### Case report

A 50-year-old man with diabetes mellitus type 2 submitted to hemorrhoidectomy, presented 24 hours later, anal pain, massive oedema of the scrotum (Fig. 1a), bilaterally inguinal subcutaneous crepitus, fetid odour, and a rapid evolution towards septic shock with tachycardia (heart rate. 130 bpm.), hypotension (blood pressure: 64/30 mmHg) and hyperpyrexia (39.7 °C). Increased white blood cell count (14,680 mm<sup>3</sup>), platelet consumption (platelet count 31,000 mm<sup>3</sup>), elevated C-reactive protein (20.8 mg/dL), creatine phosphokinase (20.338 IU/L), creatinine (2.03 mg/dL), aspartate aminotransferase (831 IU/L) and alanine aminotransferase (192 IU/L) were detected. FGSI was ten (Table 1).

CT scan confirmed the diagnosis of Fournier's gangrene (Fig. 2a-c). The patient underwent bilateral large incision from scrotum to Malgaigne line with excision of all necrotic tissues (Fig. 1b) and was admitted for two days to intensive care unit. Intravenous antibiotics (Ertapenem sodium 1 g/day iv and Linezolid 600 mg x 2/day iv) were administered. Thereafter, the patient underwent hyperbaric oxygen treatment (14) (one hour a day for ten days) and every other day curettage of the granulation tissue on the inner side of the scrotal wall and of the residual sclerotic dartos. The natural plication of the scrotal skin was stretched by gauzes covered with a collagenase-cloramphenicol ointment (Iruxo1®- Smith and Nephew, Italy) to obtain an improved and faster enzymatic debridement and, once possible, the cutaneous margins were approached by temporary separated stitches. (Fig. 1c).

The manoeuvre was repeated three times in a day with an increasingly volume of sterile gauzes, gaining fast skin expansion.

Ten days after, the surgical bed was entirely clean and the scrotum was easily reconstructed with the skin obtained by tissue expansion (Fig. 1d, Fig. 2e-f).

*Correspondence:* Prof. Attilio Ignazio Lo Monte, Associate Professor of Surgery, Director of PhD course on Surgical Biotechnologies and Regenerative Medicine, Department of Surgical and Oncological Sciences (DI.CHIR.ON), School of Medicine, University of Palermo, Via del Vespro 129, 90127, Palermo, Italy. Phone: +39.091.655.37.43; Fax: +39.091.655.26.34. E-mail: attilioignazio.lomonte@unipa.it

Table 1. Fournier's gangrene severity index (FGSI) in our patient.

Physiological Variable	Values	Point assigned
Temperature (°C)	38.5	+1
Heart rate (beats per minute)	120	+2
Respiration rate (breaths per minute)	34	+1
Serum sodium (mmol/l)	133	0
Serum potassium (mmol/l)	3.16	+1
Serum creatinine (mg/100 ml, x 2 for acute renal failure)	2.03, 2.1	3
Hematocrit (%)	31.4	0
White blood count (cells/mm <sup>3</sup> x 1,000)	14.68	0
Serum bicarbonate (venous, mmol/l)	18	+2
Total		10

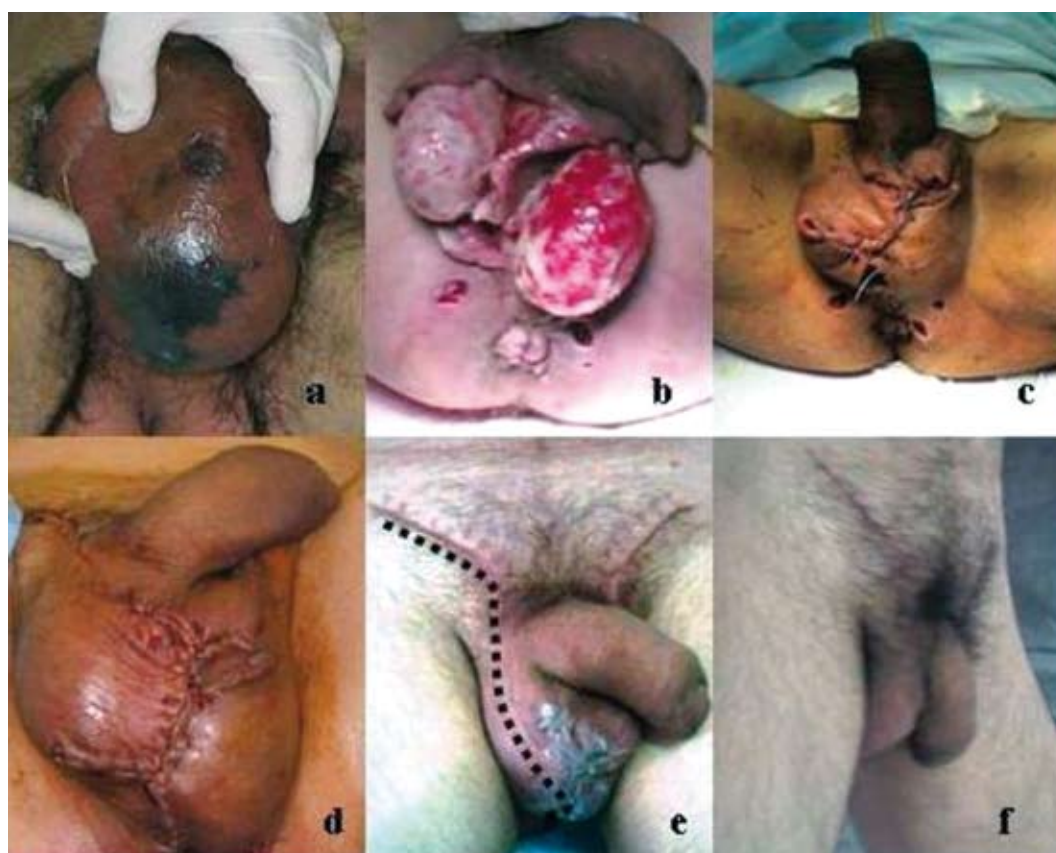

Fig. 1. Pre-surgical testes (a) and residual margins of scrotal skin (b). Enzymatic and mechanical debridement, package with soaked gauzes and skin margins temporarily grossly approached (c). Final scrotal suture after ten days. The skin is evidently stretched with disappearance of scrotal plications (d). Reconstructed scrotal bag two (e) and six months (f) from surgical treatment.

An acceptable cosmetic result was confirmed at two (Fig. 1e) and six months (Fig. 1f).

## Discussion

Metabolic status at presentation is an important prognostic factor in Fournier's gangrene, requiring an immediate multidisciplinary treatment. In Laor's study (7) the mean FGSI value for survivors was 6.9 and 13.5 for non-survivors and the difference was statistically significant. They found

that patients with a FGSI score >9 had a 75% probability of death, and patients with a score of ≤9 presented the 78% of probability of survival.

The key of survival, however, is a prompt and aggressive surgical intervention removing the devitalized tissue in order to reduce the anaerobiosis state eliminating the progress of infection and the systemic effects of necrosis. The spread of infection still causes a high mortality (5). The surgical debridement of necrotic tissue must be repeated until the wound bed is clean and healthy (15). Unfortunately the chronic inflammation with abnormal deposit of fibrin and

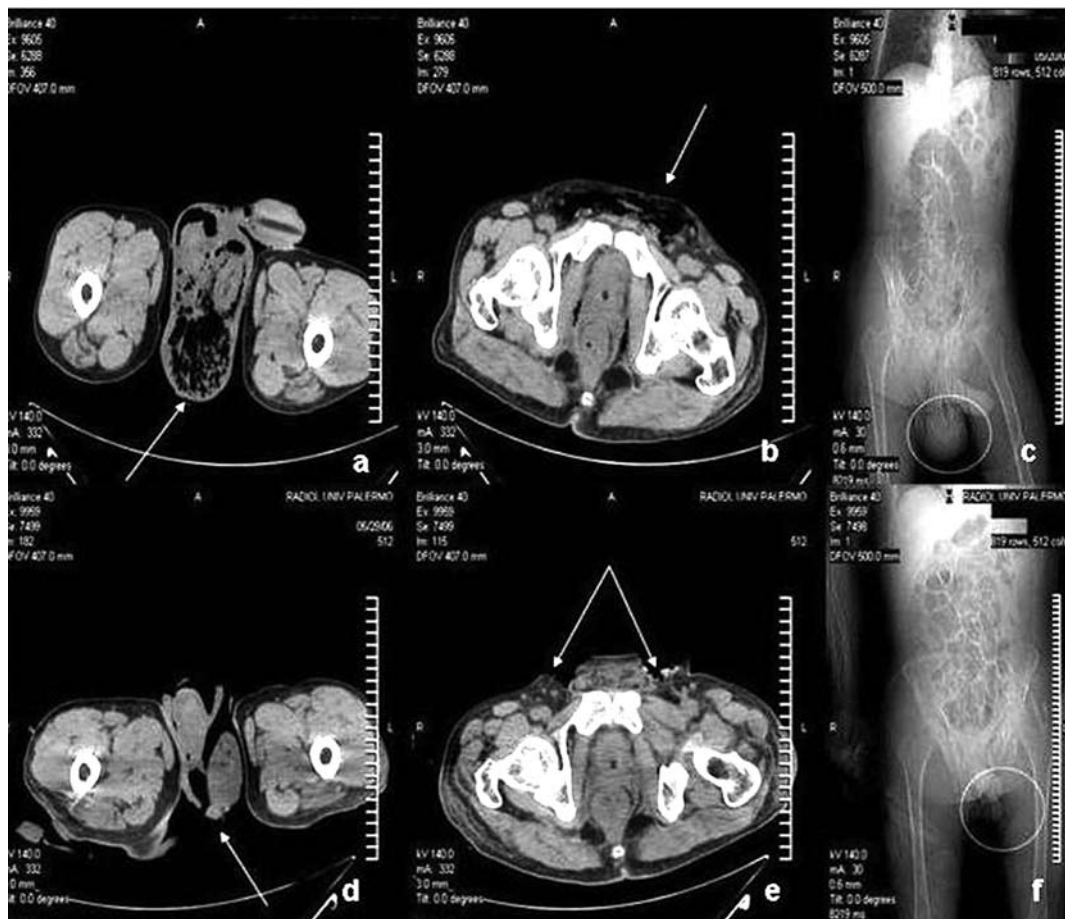


Fig. 2. CT scan before (a,b,c) and after (d,e,f) surgery.

the hyaline degeneration of residual dartos, inevitably reduce the possibility of approaching the wound edges, above all after an extensive skin resection. The biomechanical benefits provided by mechanical creep-of acute tissue expansion depend on the structural and morphological characteristics of collagen and elastin fibres of the skin that may vary due to the reparative sclerosis subsequent to the resolution of the severe septic inflammation. The residual skin flaps are usually inelastic and retracted, adhering to the residual dartos. In our experience, we achieved a great improvement of skin elasticity by enzymatic debridement with IruXol<sup>®</sup> ointment in synergy with the gradual excision synechia between the dermis and the residual sclerotic dartos gaining space for further gauze packing. With this method we reached the total reconstruction of the scrotum in ten days.

## References

1. Clayton MD, Fowler JE Jr, Sharifi R, et al. Causes, presentation and survival of fifty-seven patients with necrotizing fasciitis of the male genitalia. *Surg Gynecol Obstet* 1990;170:49
2. Nisbet AA, Thompson IM. Impact of diabetes mellitus on the presentation and outcomes of Fournier's gangrene. *Urol* 2002; 60:775-9
3. Hejase MJ, Simonin JE, Bihle R, et al. Genital Fournier's gangrene: experience with 38 patients. *Urology* 1996; 47:734-9
4. Başoğlu M, Gül O, Yıldırım I, et al. Fournier's gangrene: review of fifteen cases. *Am Surg* 1997; 63:1019-21
5. Eke N. Fournier's gangrene: a review of 1726 cases. *Br J Surg* 2000; 87:718-28
6. Fillo J, Cervenakov I, Labas P, et al. Fournier's gangrene: can aggressive treatment save life? *Int Urol Nephrol* 2001; 33:533-6
7. Laor E, Palmer LS, Tolia BM, et al. Outcome prediction in patients with Fournier's gangrene. *J Urol* 1995; 154:89-92
8. Tuncel A, Aydin O, Tekdogan U, et al. Fournier's gangrene: three years of experience with 20 patients and validity of the Fournier's Gangrene Severity Index Score. *Eur Urol* 2006; 50:838-43
9. Maguiña P, Palmieri TL, Greenhalgh DG. Split thickness skin grafting for recreation of the scrotum following Fournier's gangrene. *Burns* 2003; 29:857-62
10. Karaçal N, Livaoglu M, Kutlu N, et al. Scrotum reconstruction with neurovascular pedicled pudendal thigh flaps. *Urol* 2007; 70:170-2
11. Spyriounis PK. Scrotum reconstruction with the anterolateral (ALT) thigh flap. *Eur J Plast Surg* 2009; 32:123-6

12. Rapp DE, Cohn AB, Gottlieb LJ, et al. Use of tissue expansion for scrotal sac reconstruction after scrotal skin loss. *Urology* 2005; 65:1216-8
13. Kwon EO, Pareek G, Fracchia JA, et al. Scrotal reconstruction using rapid intraoperative tissue expansion: a preliminary report. *J Urol* 2008; 179:207-9
14. Mindrup SR, Kealey GP, Fallon B. Hyperbaric oxygen for the treatment of Fournier's gangrene. *J Urol* 2005; 173:1975-7
15. Chawla SN, Gallop C, Mydlo JH. Fournier's gangrene: an analysis of repeated surgical debridement. *Eur Urol* 2003; 43:572-5