



Oral temozolomide in heavily pre-treated brain metastases from non-small cell lung cancer: Phase II study

Carmelo Giannitto Giorgio^a, Dario Giuffrida^b, Alessandro Pappalardo^c, Antonio Russo^d, Daniele Santini^{e,*}, Placida Salice^f, Giusy Blanco^b, Sergio Castorina^f, Giuseppe Failla^c, Roberto Bordonaro^g

^a Gravina Hospital, Oncology Unit, Caltagirone, Italy

^b Mediterranean Institute of Oncology, Oncology Unit, Catania, Italy

^c C.C.D.G.B.Morgagni, Oncology Unit, Catania, Italy

^d University of Palermo, Department of Oncology, Palermo, Italy

^e Medical Oncology, University Campus Bio-Medico, Rome, Italy

^f University of Catania, Ingrassia Department, Catania, Italy

^g S. Luigi Hospital, Division of Medical Oncology, Catania, Italy

Received 14 March 2005; received in revised form 20 May 2005; accepted 25 May 2005

KEYWORDS

Brain metastases;
Lung cancer;
Pre-treated;
Temozolomide

Summary

Introduction: The primary tumour type most likely to metastasize to the brain is lung cancer. In heavily pre-treated patients, limited therapeutic option is available and the results of availability therapies reported in literature are disappointing. The present phase II study was designed to assess the efficacy and safety of temozolomide (TMZ) as palliative treatment for brain metastases (BrM) in NSCLC patients pre-treated with WBRT and at least one line of chemotherapy for metastatic brain disease.

Material and methods: Temozolomide was administered orally at 150 mg/mq/day for five consecutive days for the first cycle, doses were increased to 200 mg/mq/day for 5 days every 28 days for subsequent cycles if no grade 3/4 haematological toxicity was observed. Eligibility criteria included cytological or histological confirmed NSCLC; BrM, recurrent or progressing after WBRT and at least one line of chemotherapy. A total of 30 consecutive patients entered the study and received the allocated treatment.

Results: Three patients (10%) achieved an objective response (OR) of BrM with two complete remission. Stable disease and progressive disease were achieved in 3 (10%) and 24 patients (80%), respectively. A correlation between response to TMZ

* Corresponding author. Tel.: +39 06 22541737; fax: +39 06 22541520.
E-mail address: d.santini@unicampus.it (D. Santini).

and sensitivity to the previous first line chemotherapy was reported. Time to progression and overall survival were examined both for responder patients and for all included patients. For long-term survivors, we considered the patients who survived >12 months after the start of TMZ. According to this definition, three patients resulted long-term survivors: 2 with OR and 1 with stable brain disease. No grades 3 or 4 toxicity occurred. The total of treatment-related adverse events were mild or moderate (G1-2) in intensity. No patients discontinued TMZ as a result of treatment-related toxicity.

Discussion: The results of the present trial clearly demonstrates that TMZ is active and safe in BrM NSCLC patients previously treated with WBRT and at least one line of chemotherapy.

© 2005 Elsevier Ireland Ltd. All rights reserved.

1. Introduction

Among intra-cranial tumours, brain metastases (BrM) are more common than primary brain tumours. The primary tumour type most likely to metastasize to the brain is lung cancer. Among patients affected by advanced NSCLC up to 40% have BrM identifiable at autopsy [1]. Whole brain radiotherapy (WBRT) improves neurological symptoms in about 50% of patients and lengthens the median survival from 3 to 6 months [2]. Recent trials suggest that epipodophillotoxins alone or combined with cisplatin are very effective in treating NSCLC-related BrM and ifosfamide–mitomycin–cisplatin or gemcitabine–cisplatin combinations have been evaluated with similar good responses [3–9]. Temozolomide (TMZ) is a novel, oral, alkylating agent with virtually 100% bioavailability [10–12]. It is a new class of second generation imidazotetrazine pro-drugs that undergoes spontaneous conversion under physiological conditions to the active alkylating agent-MTIC, thus not requiring hepatic metabolism to become active. It crosses the blood–brain barrier and has showed activity in heavily pre-treated patients affected by BrM from NSCLC [10–12]. Concentrations of the drug in the central nervous system reach approximately 30–40% of plasma concentrations and clearance of TMZ is unaffected by co-administration with anticonvulsivants, antiemetics or dexamethasone. TMZ also has a good toxicity profile. The dose-limiting toxicity is not cumulative myelosuppression that rarely requires treatment delay or dose reduction.

The present phase II study was designed to assess the efficacy and safety of TMZ as palliative treatment for recurrent or progressing BrM in NSCLC patients pre-treated with WBRT and at least one line of chemotherapy for metastatic brain disease.

2. Patients and methods

2.1. Patients eligibility

Eligibility criteria included cytological or histological confirmed NSCLC; BrM, in progression after WBRT and at least one previous line of chemotherapy for metastatic brain disease. Patients were also required to have evaluable or measurable brain disease assessed by CT or MRI scans, age between 18 and 80 years, an Eastern Cooperative Oncology Group (ECOG) performance status ≤ 2 and a life expectancy >3 months. Bone marrow function requirements included an absolute neutrophil count $\geq 1500 \text{ mm}^{-3}$, a platelet count $\geq 100,000 \text{ mm}^{-3}$ and hemoglobin $\geq 10.0 \text{ g/100 mL}$. Preserved renal function (serum creatinine $\leq 1.5 \text{ mg/dL}$, normal creatinine clearance), hepatic function (total bilirubin $\leq 1.5 \text{ mg/dL}$, AST and ALT ≤ 2.5 times normal without hepatic metastasis and ≤ 4 times normal with hepatic metastasis) and cardiac function were required. Patients could have no other synchronous tumors except for non-melanoma skin cancer or in situ cervical carcinoma, if appropriately treated.

Exclusions criteria included: uncontrolled life-threatening systemic disease, pregnant or lactating women and patients not willing to use effective methods of contraception. Written informed consent from each patient had to be obtained before patient entry. Patients were excluded if adequate follow-up was not possible (environmental or geographic difficulties, no compliance to undergo necessary clinical–instrumental investigations, etc.).

2.2. Study schedule and evaluations

Screening assessments including medical history, physical examination (including vital signs, height, weight and KPS), neurological functional status (Table 1), electrocardiogram (ECG), chest X-ray and tumor measurements, based on the appropriate

Table 1 Neurological functional status

| | |
|---------|--------------------------------------|
| Level 1 | Fully functional |
| Level 2 | Fully functional not able to work |
| Level 3 | Stays in bed-need help half the time |
| Level 4 | Need help full time |

imaging techniques (i.e. CT and/or MRI scan of the brain, CT scan of the chest and upper abdomen, radionuclide bone scan) were conducted within 14 days before treatment initiation. Laboratory data including complete blood count, blood chemistry and urinalysis were also obtained. Monthly evaluations included a complete history, neurological examination, assessment of performance status and toxicity.

All pre-treatment imaging procedures, with exclusion of radionuclide bone scan, were repeated every two cycles. All tumor measurements were reviewed and confirmed by an independent panel of radiologists and oncologists. The primary study end point was radiological response of BrM. Responses for measurable lesions were reported according WHO criteria. Responses for evaluable lesions were scored by a four-point grade system: no evidence of tumour, better, unchanged, worse. Secondary end points were, safety, tolerability and overall survival.

Overall survival was calculated from inclusion date to record of death for any cause.

2.3. Treatment plan and toxicity and dose modifications

Temozolomide was administered orally at 150 mg/mq/day for five consecutive days for the first cycle, doses were increased to 200 mg/mq/day for 5 days every 28 days for subsequent cycles if no grade 3/4 haematological toxicity was observed. Prophylactic antiemetics were administered before the patient ingested TMZ. Steroids were administered at the lowest dose required by neurological status. Anticonvulsivants were given when indicated. Adverse reaction were evaluated according to the National Cancer Institute Bethesda Common Toxicity Criteria, NCI-CTC [13]. Cumulative toxicity was evaluated and noted before each treatment cycle. Blood cell counts and the liver/renal function were assessed 21 days after the first dose of TMZ. The TMZ dose for subsequent cycles was adjusted according to nadir counts with dose levels of 150 or 100 mg/mq/day. In case of grade 2 or greater non-haematological toxicity, patients were to be treated at the lower dose level except for alopecia, nausea, vomiting. In case of grade 2 or

greater hepatic toxicity, elevation of transaminases or alkaline phosphatase had to be resolved to at least a grade 1 prior to repeat dosing. Patients with repeated grades 3 and 4 non-haematological toxicity were taken off study.

Full haematological recovery was required for re-treatment. Patients could remain on treatment until disease progression (evaluated with the best instrumental exams applicable in case of metastatic lesions after at least three cycles and every three cycles) or the development of unacceptable toxicity (according to the National Cancer Institute Bethesda Common Toxicity Criteria, NCI-CTC [13]) or patient's refusal.

2.4. Statistical methods

The efficacy analysis were based on the intent-to-treat population. The primary efficacy end point was objective tumor response, defined as a CR or PR. The 95% CI for response risk was calculated.

According to the method of Fleming, a sample size of 30 patients was required to demonstrate a response rate within $\pm 10\%$ with a power of 90%. Safety and survival were secondary end points. Survival time was defined as the time from initiation of treatment to the date of death. To determine whether objective tumor response was associated with improved survival, a landmark analysis was performed. All analyses were descriptive. Statistical analyses for baseline demographics, response rates and adverse events were descriptive. Safety was analyzed in all patients who received at least one dose of study medication (Table 2).

3. Results

3.1. Patient characteristics

The demographic and baseline disease characteristics of the evaluable patients are listed in Table 3.

A total of 30 consecutive patients entered the study and received the allocated treatment from October 2000 to July 2003. All patients were pre-treated with WBRT (30 Gy in 10 fractions of 300 cGy) and at least one line of chemotherapy for metastatic brain disease (18/30 and 5/30 of patients with second and third line of chemotherapy, respectively, for metastatic disease, regardless of brain disease). The median interval from WBRT to start TMZ was 12 weeks (range 4–48 weeks). The median interval from last chemotherapy to start TMZ was 10 weeks (range 4–16 weeks). A median of six cycles (range 2–36) of TMZ was

Table 2 Patients demographics and baseline disease characteristics

| Characteristics | No. of patients (%) |
|--|---------------------|
| Total number | 30 |
| Male/female | 23/7 |
| Age (years) | |
| Median | 65 |
| Range | 45–79 |
| Performance status | |
| ECOG 0 | 7 (23.3) |
| ECOG 1 | 19 (63.3) |
| ECOG 2 | 4 (13.4) |
| RPA Class II | 20 |
| RPA Class III | 4 |
| Brain metastases | |
| Single | 5 (16.7) |
| Multiple | 25 (83.3) |
| Other metastatic sites | 30 (100) |
| Bone | 5 (16.7) |
| Lymph nodes | 24 (80.0) |
| Liver | 1 (3.3) |
| Lung | 8 (26.6) |
| Other | 14 (46.7) |
| Neurological function evaluation | |
| Level 1 | 25 (83.4) |
| Level 2 | 4 (13.3) |
| Level 3 | 1 (3.3) |
| Previous treatment | |
| WBRT | 30 (100) |
| Stereotactic radiosurgery | 1 (3.3) |
| Chemotherapy (first line for brain metastases) | 30 (100) |
| Cisplatin-based | 17 (56.7) |
| Carboplatin-based | 11 (36.7) |
| Taxane-based | 11 (36.7) |
| Vinorelbine-based | 6 (20.0) |

Values in parenthesis are percentages.

administered to patients for a total of 180 cycles. The median dose for patient was 5550 mg/mq (range 1750–34,750 mg/mq). The median duration of therapy was 6 months (range 2–36 months). All patients were assessable for treatment efficacy and safety.

3.2. Antitumor efficacy

Three patients (10%; 95% CI 7.6–13.4) achieved an objective response (OR) of BrM with two complete remission. Stable disease and progressive disease were achieved in 3 (10%) and 24 patients (80%), respectively (Table 3). When responses were defined according to the criteria of MacDonald et al. [14], all responses were confirmed. Furthermore, in one patient with cytologically confirmed meningitis carcinomatosa, cerebrospinal fluid was cleared after two cycles of TMZ and stable disease for 6 months was obtained. A baseline functional assessment before the start of treatment demonstrated that neurological functional status was level 1 (with ECOG PS 0) in five and two (with ECOG PS 1) in one of the six patients with objective response or stable disease after TMZ administration. The RPA class was two in all responders patients. The neurological status was 1 (2 patients), 2 (18 patients) and 3 (4 patients) in patients with progressive brain disease after TMZ. Moreover, a correlation between response to TMZ and sensitivity to the previous first line chemotherapy was reported. In fact, objective radiological response or stable brain disease was achieved in six patients with chemo-sensitive NSCLC (with partial response-3 patients – or stable disease-3 patients – after first line chemotherapy for metastatic disease regardless brain disease). Among patients with primary refractory disease, defined as failure of first line chemotherapy in inducing a complete or partial response or in stabilizing the disease, no remission or stabilization of brain disease was achieved with TMZ. In patients with OR of brain disease, the median time to progression was 19 (95% CI 12.1–25.9) and 11 (95% CI 8.4–13.6) months for CR and PR, respectively. Stable extracranial disease (with one minimal response) were reported in 4/6 patients with remission or stabilization of brain disease. Notably, progressive disease outside the brain was reported, during the following follow-up, in all six responders patients with a concomitant persistence of objective radiological response or stable brain disease. Five of these patients received TMZ in association with Docetaxel (TXT)

Table 3 Survival of patients according to brain lesion response to treatment

| Response, No. of patients (%) | Time to progression (months) (95% CI) | Overall survival (months) (95% CI) |
|--------------------------------|---------------------------------------|------------------------------------|
| Complete response, 2 (6.7) | 19 (12.1–25.9) | 24 (12.1–35.9) |
| Partial response, 1 (3.3) | 11 (8.4–13.6) | 14 (10.9–17.1) |
| Stable disease, 3 (10.0) | 4 (2.9–6.4) | 8 (6.7–11.9) |
| Progressive disease, 24 (80.0) | 1.5 (0.8–2.7) | 3 (1.9–4.6) |
| All patients | 3.6 (0.8–25.9) | 6 (1.9–35.9) |

or Gemcitabine chemotherapy after TMZ alone, obtaining three PR of extra-brain measurable disease. Progressive extracranial disease was reported in all patients who brain disease progressed. Time to progression and overall survival were examined both for responder patients and for all included patients at the median follow-up of 22 months

(range 3–31 months) (Table 3). Regarding the two patients with complete remission of BrM, one died 24 months after WBRT for leukoencephalopathy (with absence of BrM and stable extra-cranial disease) and the second (presenting extra-cranial progressive disease 32 months after WBRT) is still alive 42 months after radiotherapy (Fig. 1). For

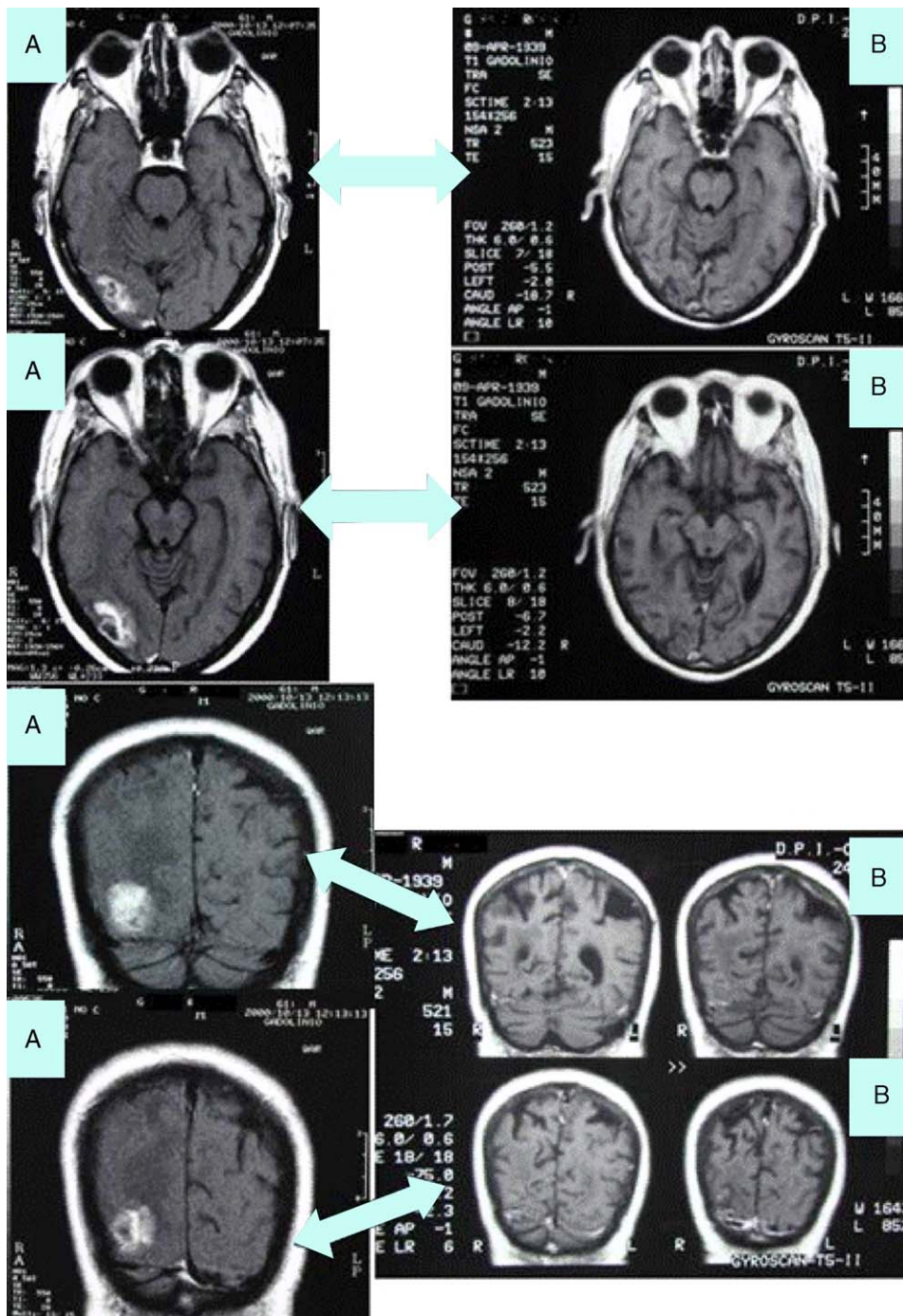


Fig. 1 Magnetic resonance imaging of one metastatic brain lesion in the brain of a 60-year-old man with non-small cell lung cancer at baseline (6 months after end of WBRT) (A) and 40 months after the start of treatment with temozolomide (B). Persistent complete remission of brain disease.

long-term survivors, we considered the patients who survived >12 months after the start of TMZ. According to this definition, three patients resulted long-term survivors: two with OR and one with stable brain disease. Between the long-term survivors patients, two died for cerebral atrophy and leucoencephalopathy with persistent radiological response of BrM and stable extra-cranial disease.

3.3. Safety results

Safety was recorded for all 30 patients enrolled in this study. During the treatment the percentage of patients who required corticosteroid decreased from 100 to 67%. No grades 3 or 4 toxicity occurred. The treatment-related adverse events were mild or moderate (G1-2) in intensity. Myelosuppression was minimal and non-cumulative. Other events included fatigue, constipation, headache (not necessarily related to treatment) and mild to moderate nausea, which was easily controlled with standard antiemetic medications. Dose reductions were required in only eight patients (26.7%): for headache in two patients (6.7%) and for fatigue in six patients (20.0%). Although most patients discontinued TMZ treatment because of disease progression, none of them discontinued it as a result of treatment-related toxicity.

4. Discussion

Brain metastases from NSCLC are associated with poor prognosis despite aggressive treatment. Also, the majority of patients suffer debilitating neurological symptoms. The optimal treatment for patients with BrM continues to evolve. The recursive partitioning analysis (RPA) of prognostic factors in three Radiation Therapy Oncology Group brain metastases trials identified three prognostic classes with median survival of 2.3 months (RPA Class III) to 7.1 months (RPA Class I). [15] Although WBRT remains the mainstay of the treatment for BrM from NSCLC, surgical therapy, possibly followed by WBRT, may be considered the treatment of choice for patient with single resectable BrM, especially for younger patients with a good performance status and satisfactory control of extra-cranial disease [16–19]. Furthermore, a statistically significant improvement in median survival with the addition of radiosurgery to WBRT was seen for patients with single brain metastasis, RPA class I patients [20]. For patients with multiple symptomatic BrM, WBRT is often the treatment of choice. The role of chemotherapy in patients with BrM by NSCLC is

still controversial. However, among patients with NSCLC and BrM, response to different chemotherapy regimens, such as cisplatin–gemcitabine or cisplatin–ifosfamide–irinotecan, was similar to that achieved in other disease sites [3–9]. Instead, for patients with recurrent or persistent BrM after WBRT and at least one line of chemotherapy, the treatment options available are limited. In two phase II trials of TMZ in heavily pre-treated patients the treatment was safe and well tolerated and showed clinical activity in patients with BrMs from NSCLC [21,22]. In 52 patients, with progressive brain metastases after WBRT, three partial responses (two in lung cancer patients and one in patient with melanoma) were reported with TMZ by Friedman et al. [23]. For newly diagnosed brain metastases, a preliminary report by Siena et al. showed an overall response (partial response plus stable disease) of 24% with TMZ monotherapy in patient with NSCLC as primitive tumour [24]. Antonodau et al. in a randomized phase II study and in a confirmatory phase III study comparing TMZ plus WBRT to WBRT alone in population largely consisting of lung cancer patients, reported a significantly greater overall response in the patients receiving TMZ [25,26]. Instead, in a preliminary report of Verger et al., a response of only 16% was noted with WBRT plus TMZ in 85 patients, half of whom had lung cancer [27]. Furthermore, in two phase II studies TMZ was reported to be inactive or marginally active in NSCLC [28,29]. In one review, van de Bent concluded that the available data not justify the use of TMZ in patients with BrMs from NSCLC outside of clinical trials [30]. The present phase II study assessed the activity and safety of TMZ in heavily pre-treated NSCLC patients with BrMs. The results of this trial suggest that treatment with TMZ is safe and quite active: 6/30 patients achieved objective response or stable disease of BrM and the adverse events associated with TMZ are modest, reversible and generally predictable. A correlation between response to TMZ and sensitivity to first line chemotherapy was reported: none of the patients with chemo-refractory NSCLC achieved objective radiological response of BrM or stable brain disease after TMZ. Remarkably 3/30 patients, in the present trial, resulted long-term survivors. Three patients reported neurocognitive deteriorations. Two patients died for severe neurological complications related to WBRT. Long-term sequelae of WBRT comprise neurocognitive deterioration and dementia induced by leucoencephalopathy and cerebral atrophy or necrosis [31] All patients were pre-treated with a short course of large-fraction RT (30 Gy in 10 fractions) and large, daily RT fraction sizes are associated with increase risk of neurocog-

nitive deficits [32]. In the vast majority of patients with metastatic brain disease the survival is short and patients not survive long enough to develop cognitive deficits from RT but the few long-term survivors usually develop cognitive deficits from WBRT with large fraction size [32].

However, the results of the present trial demonstrates that TMZ is quite active, but safe in BrM NSCLC patients previously treated with WBRT and at least one line of chemotherapy. In this particular setting of patients, the results and safety reported in literature are disappointing and limited therapeutic option are available. In conclusion, these results clearly do re-enforce the concept of utility of second and following lines chemotherapy regimens and highlight the need for new trials to verify the real clinical impact of TMZ versus supportive care in patients with NSCLC and metastatic brain disease progressing or recurrent after WBRT and at least one line of chemotherapy.

References

- [1] Loeffler JS, Patchell RA, Sawaja R. Treatment of metastatic cancer. In: De Vita Jr VT, Helmann S, Rosemberg SA, editors. Cancer: principles and practice of oncology. Lippincott Raven: Philadelphia, PA; 1997. p. 2523–36.
- [2] Sundstrom JT, Minn H, Lertola KK, Nordman E. Prognosis of patients treated for intracranial metastases with whole brain irradiation. *Ann Med* 1998;30:296–9.
- [3] Robinet G, Thomas P, Breton JL, Lena H, Gouva S, Dabouis G, et al. Results of a phase III study of early versus delayed whole brain radiotherapy with concurrent cisplatin and vinorelbine combination in inoperable brain metastases of non-small cell lung cancer: groupe francais de pneumocancerologie (GFPC) protocol 95-1. *Ann Oncol* 2001;12:59–67.
- [4] Crinò L, Scagliotti GV, Ricci S, de Marinis F, Rinaldi M, Gridelli C, et al. Gemcitabine and cisplatin versus mitomycin, ifosfamide and cisplatin in advanced non-small cell lung cancer: a randomized phase III study of the Italian lung cancer project. *J Clin Oncol* 1999;17:3522–30.
- [5] Minotti V, Crino L, Meacci ML, Corgna E, Darwish S, Palladino MA, et al. Chemotherapy with cisplatin and teniposide for cerebral metastases in non-small cell lung cancer. *Lung Cancer* 1998;20:93–8.
- [6] Fujita A, Fukuoka S, Takabatake H, Tagaki S, Sekine K, et al. Combination chemotherapy of cisplatin, ifosfamide, and irinotecan with rhG-CSF support in patients with brain metastases from non-small cell lung cancer. *Oncology* 2000;59:291–5.
- [7] Bernardo G, Cuzzoni Q, Strada MR, Bernardo A, Brunetti G, Jedrychowska I, et al. First line chemotherapy with vinorelbine, gemcitabine and carboplatin in the treatment of brain metastases from non-small cell lung cancer: a phase II study. *Cancer Invest* 2002;20:293–302.
- [8] Franciosi V, Cocconi G, Michiara M, Di Costanzo F, Fossler V, Tonalo M, et al. Front-line chemotherapy with cisplatin and etoposide for patients with brain metastases from breast carcinoma, non-small cell lung carcinoma or malignant melanoma. *Cancer* 1999;85:1599–605.
- [9] Quantin X, Khial F, Reme-Saumon M, Michel FR, Pujol JL. Concomitant brain radiotherapy and vinorelbine–ifosfamide–cisplatin chemotherapy in brain metastases of non-small cell lung cancer. *Lung Cancer* 1999;26:25–39.
- [10] O'Reilly SM, Newlands ES, Glaser MG, Brampton M, Rice-Edwards JM, Illingworth RD, et al. Temozolomide: a new oral cytotoxic chemotherapeutic agent with promising activity against primary brain tumours. *Eur J Cancer* 1993;29a:940–2.
- [11] Baker SD, Wirth M, Statkevich P, Reidenberg P, Alton K, Sartorius SE, et al. Absorption, metabolism, and excretion of ¹⁴C-temozolomide following oral administration to patients with advanced cancer. *Clin Cancer Res* 1999;5:309–17.
- [12] Patel M, McCully C, Godwin K, Balis FM, et al. Plasma and cerebrospinal fluid pharmacokinetics of temozolomide. *Proc Am Soc Clin Oncol* 1995;14(461A) (abstract #1485).
- [13] Cancer Therapy Evaluation Program. Common Toxicity Criteria, Version 2.0. <http://webapss.ctep.nci.nih.gov/ctcv2/>; 1999.
- [14] MacDonald DR, Cascino T, Schold SC, Cairncross JG. Response criteria for phase II study of malignant glioma. *J Clin Oncol* 1990;8:1277–80.
- [15] Donahue B, Scott CB, Nelson JS, Rotman M, Murray KJ, Nelson DF, et al. Recursive partitioning analysis (RPA) of prognostic factors in three Radiation Therapy Oncology Group (RTOG) brain metastases trials. *Int J Radiat Oncol Biol Phys* 1997;37:745–51.
- [16] Patchell RA, Tibbs PA, Walsh JW, Dempsey RJ, Maruyama Y, Kryscio RJ, et al. A randomised trial of surgery in the treatment of single metastases to the brain. *N Engl J Med* 1990;322:494–500.
- [17] Noordijk EM, Vecht CJ, Haaxma-Reiche H, Padberg GW, Voormolen JH, Hoekstra PH, et al. The choice of treatment of single brain metastasis should be based on extracranial tumor activity and age. *Int J Radiat Oncol Biol Phys* 1994;29:711–7.
- [18] Gandola L, Navarria P, Lombardi F, et al. Treatment of single brain metastases. *Forum* 2001;1:38–44.
- [19] Kondziolka D, Lunsford LD, Flickinger JC. Controversies in the management of multiple brain metastases: the role of radiosurgery and radiation therapy. *Forum* 2001;1:47–54.
- [20] Sperduto PW, Scott C, Andrew D, et al. Stereotactic radiosurgery with whole brain radiation therapy improve survival in patients with brain metastases Report of Radiation Therapy Oncology Group phase III study 95-08. *Int J Radiat Oncol Biol Phys* 2002;54:3 (abstract).
- [21] Abrey LE, Olson JD, Raizer JJ, Mack M, Rodavitch A, Boutros DY, et al. A phase II trial of temozolomide for patients with recurrent or progressive brain metastases. *J Neuro-Oncol* 2001;53:259–65.
- [22] Christodoulou C, Bafaloukos D, Kosmidis P, Samantas E, Bamias A, Papakostas P, et al. Phase II study of temozolomide in heavily pretreated cancer patients with brain metastases. *Ann Oncol* 2001;12:249–54.
- [23] Quinn JA, Reardon DA, Friedman AH, Rich JN, Sampson JH, Provenzale JM, et al. Phase II trial of temozolomide for patients with progressive brain metastases. *Proc Am Soc Clin Oncol* 2003;22:10 (abstract).
- [24] Siena S, Landonio G, Baietta E, Vitali M, Crino I, Dahova M, et al. Multicenter phase II study of temozolomide therapy for brain metastases in patients with malignant melanoma. Breast cancer, and non-small cell lung cancer. *Proc Am Soc Clin Oncol* 2003;22:102 (abstract).
- [25] Antonodau D, Paraskevaidis M, Sarris G, et al. Phase II randomized trial of temozolomide and concurrent radio-

- therapy in patients with brain metastases. *J Clin Oncol* 2002;20:3644–50.
- [26] Antonaudou D, Coliarakis N, Paraskevaidis M, et al. Whole brain radiotherapy alone or in combination with temozolomide for brain metastases A phase III study. *Int J Radiat Oncol Biol Phys* 2002;54:93–4 (abstract).
- [27] Verger E, Gil M, Yaya R, Vinolas N, Villa S, Pujol I, et al. Concomitant temozolomide and whole brain radiotherapy in patients with brain metastases: randomized multicentric phase II study. *Proc Am Soc Clin Oncol* 2003;22:101 (abstract).
- [28] Dziadziuszko R, Ardizzone A, Postmus PE, Smit EF, Price A, Debruyne C, et al. Temozolomide in patients with advanced non small cell lung cancer with e without brain metastases: a phase II study of EORTC Lung Cancer Group. *Eur J Cancer* 2003;39:1271–6.
- [29] Adonizion CS, Babb JS, Maiale C, Huang C, Donahue J, Millenson MM, et al. Temozolomide in non-small cell lung cancer: preliminary results of a phase II trial in previously treated patients. *Clin Lung Cancer* 2003.
- [30] van den Bent MJ. The role of chemotherapy in brain metastases. *Eur J Cancer* 2003;39:2114–20.
- [31] DeAngelis LM, Delattre JY, Posner JB, et al. Radiation-induced dementia in patients cured of brain metastases. *Neurology* 1989;39:789–96.
- [32] Laack NN, Brown PD. Cognitive sequelae of brain radiation in adults. *Semin Oncol* 2004;31:702–13.

Available online at www.sciencedirect.com

SCIENCE @ DIRECT®