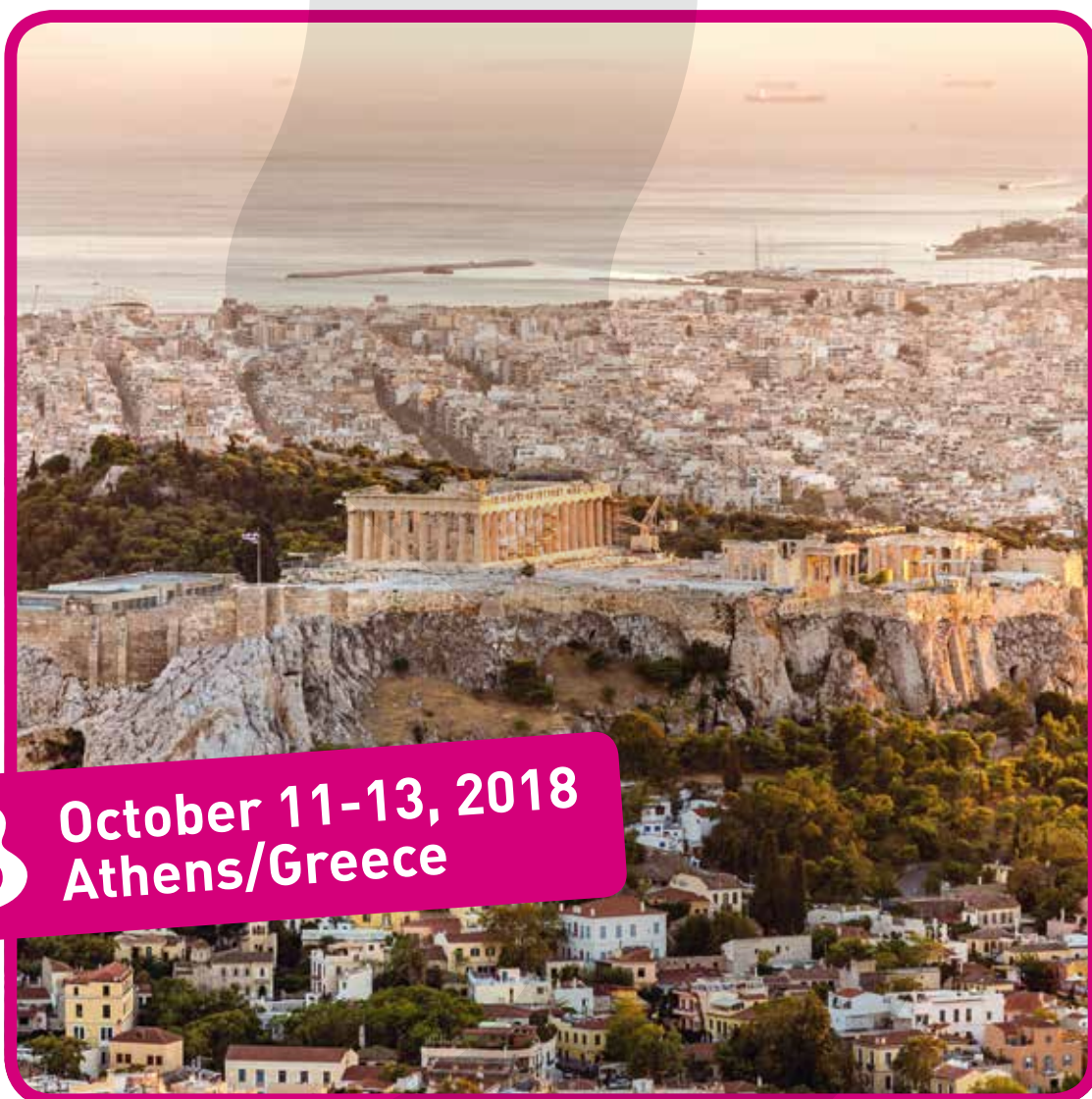

EUSOBI
european society of breast imaging



Annual Scientific Meeting 2018

European Society of Breast Imaging



3 October 11-13, 2018
Athens/Greece

MEETING GUIDE

In cooperation with the
Hellenic Breast Imaging Society



HELLENIC BREAST
IMAGING SOCIETY

DEAR COLLEAGUES AND FRIENDS!

It is our great pleasure to welcome you to our Annual Meeting, at this great new location – Athens – from October 11-13, 2018. This year's meeting is extended to 2,5 days and for the first time it will start with three pre-congress courses, providing a thorough update on case-based BI-RADS® classification, interventional procedures and B3 lesions.

As in the past years, our meeting was preceded by our special Breast MRI course. The Annual Scientific Meeting 2018 is organised in collaboration with the Hellenic Society of Breast Imaging, with active participation of Greek pathologists, breast surgeons, medical oncologists and radiation oncologists, who will participate in a case based MDT session.

We are highly appreciative, all of the positive feedback we received from over 800 participants, complimenting on the professional level and friendly atmosphere of last year's Berlin meeting. We have tried to take into account all of your feedback and recommendations in planning this year's scientific programme.

The highlights of this year's Athens meeting will feature:

- Tomosynthesis in screening/diagnostic settings
- Advanced/ multiparametric ultrasound
- New trending topics in MRI
- The role of breast radiologist as a therapist
- Artificial intelligence and evidence-based imaging

What is more, we hope to attract more young radiologists with an interest to breast diagnostics as an audience and possible future members of the EUSOBI Young Club. Members of the Young Club should not miss the EYC Symposium, which will take place the morning after the Annual Scientific Meeting, on October 14, 2018.

Enjoy this meeting!
Yours sincerely,

Dr. Gábor Forrai
EUSOBI President

Dr. Alexandra Athanasiou
Dr. Athina Vourtsis
Local Congress Organisers

CONTENTS

Programme Overview	2
Detailed Programme	5
Committee & Faculty	10
Abstracts	11
Disclosure Statement	62
Scientific Posters	63
General Information	69
EYC Symposium Info	72
Congress Sponsors	73
Industry Symposia	75
Floor Plan / Industry Exhibition	82
Industry Workshops	84
Session/Workshop Overview	88

EUSOBI 2018 – PROGRAMME OVERVIEW

Thursday, October 11, 2018 | 14:20-18:15

LECTURE HALL

14:20-14:30

Opening remarks

14:30-15:30

BI-RADS® Multimodality Case Session

15:30-16:00

Coffee break

16:00-17:00

Interventional diagnostics and pre-operative management

17:00-18:15

From hyperplasia to DCIS (B3 lesions/DCIS)

EUSOBI 2018 - PROGRAMME OVERVIEW

Friday, October 12, 2018 | 08:15-18:20

LECTURE HALL

08:15-09:45

Tomosynthesis and screening

09:45-10:30

Young Scientists' Session, Carla Boetes Young Investigator Award and awarding of the best submitted abstract

10:30-11:00

Coffee break / Poster viewing

11:00-11:30

EUSOBI meets Saudi Arabia

11:30-13:00

Ultrasound

13:00-14:00

Industry-sponsored lunch symposium

14:00-15:30

MRI trending topics

15:30-15:50

EUSOBI Award for the most quoted breast imaging paper published in European Radiology in 2015

15:50-16:20

Coffee break

16:20-17:20

Industry-sponsored symposia

17:20-18:20

Breast radiologist as therapist

EUSOBI 2018 – PROGRAMME OVERVIEW

Saturday, October 13, 2018 | 08:00-17:00

LECTURE HALL

08:00-08:30

General Assembly

08:30-09:00

EUSOBI Gold Medal

09:00-09:45

Breast Interpretation Competition

09:45-10:15

Coffee break / Poster viewing

10:15-11:15

MDT Session

11:15-11:45

Key note lecture

11:45-12:45

Industry-sponsored lunch symposium

12:45-14:15

Metastatic disease

14:15-14:45

From the US Society of Breast Imaging (SBI)

14:45-15:15

Coffee break

15:15-16:45

AI (Artificial Intelligence) – The rise of the machines

16:45-17:00

Final closing remarks: Looking at Budapest 2019

EUSOBI 2018 - DETAILED PROGRAMME

Thursday, October 11, 2018

14:20	Opening remarks G. Forrai, Budapest/HU; A. Athanasiou, Athens/GR
14:30	BI-RADS® Multimodality Case Session <i>Moderators: P. Clauser, Vienna/AT; M.A. Marino, Messina/IT</i> K. Kinkel, Chêne-Bougeries/CH M. Fuchsjäger, Graz/AT
15:30	Coffee break
16:00	Interventional diagnostics and pre-operative management <i>Moderators: K. Borbely, Budapest/HU; M. Lobbes, Maastricht/NL</i>
16:00	Core needle biopsy B. Brkljacic, Zagreb/HR
16:15	VAB under stx, tomo and UL F. Thibault, Paris/FR
16:30	MR-guided procedures T.H. Helbich, Vienna/AT
16:45	Pre-operative local and regional localisation of breast cancer P. Panizza, Milan/IT
17:00	From hyperplasia to DCIS (B3 lesions/DCIS) <i>Moderators: M. Lesaru, Bucharest/RO; R.M. Trimboli, Milan/IT</i>
17:00	Management of proliferative B3a lesions A. Linda, Udine/IT
17:15	Management of precursor lesions B3b: Lobular neoplasia S. Pérez-Rodrigo, Madrid/ES
17:30	Management of precursor lesions B3b: ADH and FEA N. Sharma, Leeds/UK
17:45	MRI in the management of B3 lesions U. Bick, Berlin/DE
18:00	B3 lesions/correlation with pathology A. Batistatou, Ioannina/GR

EUSOBI 2018 - DETAILED PROGRAMME

Friday, October 12, 2018

08:15	<p>Tomosynthesis and screening Moderators: M. Wallis, Cambridge/UK; S. Zackrisson, Malmö/SE</p>
08:15	<p>Evaluation of screening efficacy S. Duffy, London/UK</p>
08:30	<p>Tomo in clinical practice S. Zackrisson, Malmö/SE</p>
08:45	<p>Tomo in screening D. Bernardi, Trento/IT</p>
09:00	<p>Strategies to optimize the potential of breast tomosynthesis I. Sechopoulos, Nijmegen/NL</p>
09:15	<p>Discussion</p>
09:45	<p>Young Scientists' Session, Carla Boetes Young Investigator Award and awarding of the best submitted abstract Moderators: P. Clauser, Vienna/AT; R.M. Trimboli, Milan/IT</p>
09:45	<p>Summary of the submitted accepted posters and awarding of the best abstract</p>
09:52	<p>Young Physician/Scientist Grant Preoperative staging in women with known breast cancer: Comparison between Digital Breast Tomosynthesis (DBT) and Magnetic Resonance Imaging (MRI) F. Galati, Rome/IT</p>
09:59	<p>Young Physician/Scientist Grant Evaluation of Gd-deposits in healthy women participating in high risk screening program for early breast cancer detection B. Bennani-Baiti, Vienna/AT</p>
10:06	<p>Young Physician/Scientist Grant Prospective comparison of synthetic 2D mammography plus DBT and MRI in breast cancer surveillance of women treated for Hodgkin lymphoma with chest radiation before the age of 30 M. Fasciano, Turin/IT</p>
10:15	<p>Carla Boetes Young Investigator Award Integrating fast diffusion weighted imaging into an abbreviated breast MRI: Increase of accuracy without sacrificing rapidity M. Dietzel, Erlangen/DE</p>
10:30	<p>Coffee break</p>
11:00	<p>EUSOBI meets Saudi Arabia Moderators: M. Fuchsjäger, Graz/AT; L. Martincich, Candiolo/IT Breast screening and diagnostic radiology in Saudi Arabia F.M. Altahan, Riyadh/SA N. Khoumais, Riyadh/SA</p>

10:30-11:00
Poster viewing

EUSOBI 2018 - DETAILED PROGRAMME

Friday, October 12, 2018

11:30	Ultrasound <i>Moderators: C. Colin, Lyon/FR; R.M. Pijnappel, Utrecht/NL</i>
11:30	Multiparametric ultrasound P. Kapetas, Vienna/AT
11:45	A primer on automated breast ultrasound M. Marcon, Zurich/CH
12:00	Novel developments in automated breast ultrasound A. Vourtsis, Athens/GR
12:15	Ultrasound in the axilla F. Kilburn-Toppin, Cambridge/UK
12:30	Applications for CEUS A. Athanasiou, Athens/GR
12:45	Discussion
13:00	Industry-sponsored lunch symposium (see details on page 76)
14:00	MRI trending topics <i>Moderators: P. Baltzer, Vienna/AT; L. Martincich, Candiolo/IT</i>
14:00	Overview on GD controversy V.M. Runge, Bern/CH
14:15	Breast MRI and CESM: Competition or cooperation? F. Sardanelli, Milan/IT
14:30	Current applications of MR-Diffusion S. Vinnicombe, Cheltenham/UK
14:45	Do we need quality control in breast MRI? R.M. Mann, Nijmegen/NL
15:00	Discussion
15:30	EUSOBI Award for the most quoted breast imaging paper published in European Radiology in 2015 <i>Moderators: M. Fuchsjäger, Graz/AT; N. Gourtsoyiannis, Athens/GR</i> Breast MRI: EUSOBI recommendations for women's information R.M. Mann, Nijmegen/NL
15:50	Coffee break
16:20	Industry-sponsored symposia (see details on page 76)
17:20	Breast radiologist as therapist <i>Moderators: E. Giannotti, Nottingham/UK; T. Sella, Jerusalem/IL</i>
17:20	Minimal invasive ablation F. Pediconi, Rome/IT
17:35	Minimal invasive excision N. Abdel Razek, Giza/EG
17:50	Can we avoid surgery after NAC? J. Camps Herrero, Alzira/ES
18:05	Discussion

EUSOBI 2018 - CONGRESS PROGRAMME

Saturday, October 13, 2018

08:00	General Assembly (for society members only)
08:30	EUSOBI Gold Medal <i>Moderators: G. Forrai, Budapest/HU; F. Sardanelli, Milan/IT</i> DCIS in the era of MRI C.K. Kuhl, Aachen/DE
09:00	Breast Interpretation Competition <i>Moderator: M. Fuchsjäger, Graz/AT</i> Greece against the rest of Europe Greek team: T. Kanavou, Larissa/GR; N. Patsinakidis, Ptolemaida/GR European team: N. Healy, Cambridge/UK; P. Kapetas, Vienna/AT
09:45	Coffee break
10:15	MDT Session <i>Moderators: A. Athanasiou, Athens/GR; E. Faliakou, Athens/GR; A. Rousakis, Athens/GR</i> I. Athanasiadis, Athens/GR (Oncologist) A. Batistatou, Ioannina/GR (Pathologist) A. Dimopoulos, Athens/GR (Radiation Oncologist) C. Markopoulos, Athens/GR (Breast Surgeon) E. Panourgias, Athens/GR (Breast Radiologist) A. Vourtsis, Athens/GR (Breast Radiologist)
11:15	Key note lecture <i>Moderators: A. Athanasiou, Athens/GR; G. Forrai, Budapest/HU</i> Ultrafast imaging and super-resolution in biomedical ultrasound M. Tanter, Paris/FR
11:45	Industry-sponsored lunch symposium (see details on page 76)
12:45	Metastatic disease <i>Moderators: E.M. Fallenberg, Berlin, Munich/DE; M. Herranz, Santiago de Compostela/ES</i> Metastatic disease – Which patients need systemic staging I. Athanasiadis, Athens/GR
13:00	Distant staging (CT, PET/CT and PET/MRI) L. Moy, New York/US
13:15	Whole body staging with MRI: DWI and beyond M. Dietzel, Erlangen/DE
13:30	Interventional options in metastatic breast disease D. Nörenberg, Munich/DE
13:45	Discussion

09:45-10:15
Poster viewing

EUSOBI 2018 - CONGRESS PROGRAMME

Saturday, October 13, 2018

14:15	<p>From the US Society of Breast Imaging (SBI) <i>Moderators: J. Camps Herrero, Alzira/ES; G. Forrai, Budapest/HU</i> Breast imaging in the era of value-based care W. DeMartini, Stanford/US</p>
14:45	Coffee break
15:15	<p>AI (Artificial Intelligence) – The rise of the machines <i>Moderators: N. Karssemeijer, Nijmegen/NL; L. Moy, New York/US</i> 15:15 Machine/deep learning/AI – Basics and principles primer G. Langs, Vienna/AT 15:30 'Omics and its integration in breast radiology K. Pinker-Domenig, New York/US 15:45 Creating evidence instead of fake news M. Barta, Truro/UK 16:00 Is AI putting us out of work? F. Gilbert, Cambridge/UK 16:15 Discussion</p>
16:45	<p>Final closing remarks: Looking at Budapest 2019 J. Camps Herrero, Alzira/ES G. Forrai, Budapest/HU</p>

EXECUTIVE COMMITTEE (2015-2018)**President**

G. Forrai, Budapest/HU

Vice President

J. Camps Herrero, Alzira/ES

Past President

F. Sardanelli, Milan/IT

Secretary General

F.J. Gilbert, Cambridge/UK

Treasurer

R.M. Pijnappel, Utrecht/NL

Chairperson of Educational Committee

F. Pediconi, Rome/IT

Chairperson of Scientific Committee

U. Bick, Berlin/DE

Chairperson of International Relations Committee

M. Fuchsjäger, Graz/AT

ORDINARY MEMBERS

T.H. Helbich, Vienna/AT

C.K. Kuhl, Aachen/DE

R.M. Mann, Nijmegen/NL

P. Panizza, Milan/IT

K. Pinker-Domenig, Vienna/AT

S. Zackrisson, Malmö/SE

HONORARY MEMBERS

E. Azavedo, Stockholm/SE

Y. Grumbach, Amiens/FR

R. Salvador, Barcelona/ES

I. Schreer, Kiel/DE

P. Skaane, Oslo/NO

M.G. Wallis, Cambridge/UK

G. Wolf, Vienna/AT

**EUSOBI 2018 PROGRAMME
PLANNING COMMITTEE**

J. Camps Herrero, Alzira/ES

A. Athanasiou, Athens/GR

P.A. Baltzer, Vienna/AT

E.M. Fallenberg, Berlin, Munich/DE

G. Forrai, Budapest/HU

F.J. Gilbert, Cambridge/UK

R.M. Mann, Nijmegen/NL

F. Pediconi, Rome/IT

K. Pinker-Domenig, New York/US

F. Sardanelli, Milan/IT

EUSOBI 2018 FACULTY

N.M. Abdel Razek, Giza/EG

F.M. Altahan, Riyadh/SA

A. Athanasiou, Athens/GR

I. Athanasiadis, Athens/GR

P.A. Baltzer, Vienna/AT

M. Barta, Truro/UK

A. Batistatou, Ioannina/GR

D. Bernardi, Trento/IT

M. Bernathova, Vienna/AT

U. Bick, Berlin/DE

K. Borbely, Budapest/HU

B. Brkljacic, Zagreb/HR

J. Camps Herrero, Alzira/ES

P. Clauser, Vienna/AT

C. Colin, Pierre-Bénite/FR

M. Dietzel, Erlangen/DE

W.B. DeMartini, Stanford/US

A. Dimopoulos, Athens/GR

S. Duffy, London/UK

E.M. Fallenberg, Berlin, Munich/DE

E. Faliakou, Athens/GR

G. Forrai, Budapest/HU

M. Fuchsjäger, Graz/AT

E. Giannotti, Nottingham/UK

F.J. Gilbert, Cambridge/UK

N. Gourtsoyiannis, Athens/GR

N. Healy, Cambridge/UK

T.H. Helbich, Vienna/AT

M. Herranz, Santiago de Compostela/ES

S.H. Heywang-Köbrunner, Munich/DE

T. Kanavou, Larissa/GR

N. Karssemeijer, Nijmegen/NL

P. Kapetas, Vienna/AT

N. Khoumais, Riyadh/SA

F. Kilburn-Toppin, Cambridge/UK

K. Kinkel, Chêne-Bougeries/CH

C.K. Kuhl, Aachen/DE

G. Langs, Vienna/AT

M. Lesaru, Bucharest/RO

A. Linda, Udine/IT

M. Lobbes, Maastricht/NL

R.M. Mann, Nijmegen/NL

M. Marcon, Zurich/CH

M.A. Marino, Messina/IT

C. Markopoulos, Athens/GR

L. Martincich, Candiolo/IT

L. Moy, New York/US

D. Nörenberg, Munich/DE

P. Panizza, Milan/IT

E. Panourgias, Athens/GR

N. Patsinakidis, Ptolemaida/GR

F. Pediconi, Rome/IT

S. Pérez-Rodrigo, Madrid/ES

R.M. Pijnappel, Utrecht/NL

K. Pinker-Domenig, New York/US

A. Rousakis, Athens/GR

V.M. Runge, Bern/CH

F. Sardanelli, Milan/IT

I. Schreer, Kiel/DE

I. Sechopoulos, Nijmegen/NL

T. Sella, Jerusalem/IL

N. Sharma, Leeds/UK

M. Tanter, Paris/FR

F. Thibault, Paris/FR

R.M. Trimboli, Milan/IT

M. Van Goethem, Antwerp/BE

S. Vinnicombe, Cheltenham/UK

A. Vourtsis, Athens/GR

M.G. Wallis, Cambridge/UK

S. Zackrisson, Malmö/SE

Please note that abstracts are printed as initially submitted.

ABSTRACTS

BIRADS MULTIMODALITY CASE SESSION

K. Kinkel, Chêne-Bougeries/CH

BODY

Breast imaging takes into account clinical and imaging information from mammography, ultrasound and MRI. This case session highlights the role, strength and limitation of each imaging technique according to the clinical situation and the patients' age. The role of the radiologist is to choose an efficient way to obtain an answer to the clinical question. The cases cover patients with symptoms as well as screening and staging of breast cancer. A critical analysis of recent technical advances such as tomosynthesis, elastography and diffusion weighted imaging are illustrated and confronted to literature results. The interactive approach leads to a better understanding how to prioritize and synthesize information into a BIRADs number and to guide the radiologist to appropriate management decision.

INTERVENTIONAL DIAGNOSTICS AND PRE-OPERATIVE MANAGEMENT

Vacuum-assisted biopsy (VAB) under stereotactic, tomosynthesis and US guidance

F. Thibault, D. Sebbag-Sfez, C. Dratwa, L. Wallaert, C. Malhaire, A. Tardivon; Paris/FR

INTRODUCTION

A variety of minimally-invasive techniques are routinely used for the diagnosis of impalpable breast lesions. Vacuum-assisted biopsy (VAB) was developed to address the limitations of core needle biopsy (CNB), allowing more extensive sampling of breast tissue. VAB can be performed using mammography (stereotaxis or tomosynthesis guidance), US or MRI guidance. VAB uses a large bore (11 to 7 G) double-lumen vacuum-assisted probe. The probe is only inserted once and rotates over 360°, allowing retrieval of multiple specimens from a single insertion. The volume of tissue retrieved for histological examination is much larger than that obtained from large 14 G CNB. Calcification and architectural distortion sampling in particular has been significantly improved with more accurate diagnosis, and the rates of histologic underestimation of disease have been significantly reduced by using VAB versus core-needle biopsy.

This lecture will focus on VAB indications, on the conditions for achieving a high diagnostic performance and on issues in the management of high-risk disease found at percutaneous image-guided biopsy as new questions are arising about the relationship of atypical ductal hyperplasia (ADH) with ductal carcinoma in situ (DCIS) and invasive carcinoma.

CLINICAL INDICATIONS AND DIAGNOSTIC PERFORMANCE

Microcalcifications and architectural distortions only or mainly visible on mammography are primary indications for VAB performed under stereotactic or, where available, under tomosynthesis guidance. Asymmetric densities without ultrasound (US) correlate are another indication. Tomosynthesis guidance nowadays provides technically easier and more accurate biopsy procedures for such typically low-contrast lesions.

For abnormal findings on US, US-guided VAB may be preferred to CNB for the adequate sampling of large, ill-defined masses or tissue infiltration, or at the opposite of very small suspicious nodules that could result in false negative findings using CNB. US-guided VAB of calcified lesions visible on US is an alternative

to mammographically-guided intervention in the case of a breast too thin on compression to enable a stereotactic approach.

VAB is also used in cases of imaging-histologic discordance of lesions initially sampled with CNB with a risk of false negative result.

More recently the VAB procedure has been used for the therapeutic removal of benign breast lesions, most commonly symptomatic fibroadenomas and papillomas, with high rates of complete excision on follow-up US examination. On the diagnostic side, VAB excision of B3 lesions is recommended in the European guidelines as large tissue sampling minimises the risk of underdiagnosis of both DCIS and invasive tumour. This may apply to B1/B3/B4 result on initial 14G core biopsy and to papillary lesions and radial scars/complex sclerosing lesions previously diagnosed at core biopsy.

VAB procedure out-performs CNB intervention with reported false-negative rates in a large stereotactic series including both calcification and mass lesions (Jackman 2009) of less than 0,5% for 11 G VAB compared with a previously reported 4% for stereotactic 14-gauge CNB (Jackman 1999). False-negative biopsy findings were significantly related to the absence of calcification on specimen radiograph, but not to lesion type, i.e. calcification or mass lesions. The reported underestimation rates in percutaneous needle diagnoses of atypia (with in situ malignancy upgrade on surgical specimen) are consistently in the order of 20%, and those in diagnoses of DCIS (with invasive malignancy upgrade on surgical specimen) of 10%.

Control of all the steps of the procedure, in particular radiologic preparation, documentation of the correct targeting (and calcification retrieval) and radio-pathologic correlation is essential to achieve a high degree of diagnostic accuracy. The role of multidisciplinary discussion is paramount for all discordant results and for deciding on clinical management especially in category B3 findings.

MANAGEMENT OF HIGH-RISK DISEASE FOUND AT PERCUTANEOUS IMAGE-GUIDED BIOPSY

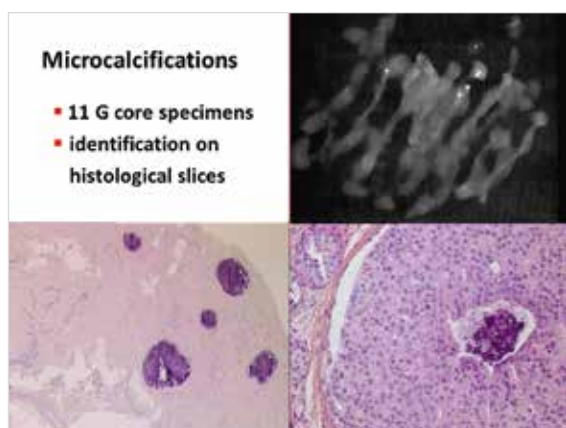
The B1 to B5 classification system guides the pathologic assessment of breast (large-gauge core

Vacuum-assisted biopsy (VAB) under stereotactic, tomosynthesis and US guidance

or VAB) biopsy specimen. B3 lesions are lesions of uncertain malignant potential as they are associated with an increased risk of developing cancer and may be coexisting with malignant lesions. They include a spectrum of heterogeneous lesions: flat epithelial atypia (FEA), ADH, atypical lobular hyperplasia (ALH), lobular carcinoma in situ (LCIS), as well as radial scar/complex sclerosing lesion, papillary lesions, phyllodes tumour, and mucocele like lesions. In particular, the definition of lesions characterized as in situ (or intraepithelial) neoplasia of the ductal or lobular type (WHO classification 2012) is based on their morphologic and molecular features, rather than on their location within glandular ducts and acini. Both type of lesions are frequently coexisting and it is admitted that there is an histopathologic continuum leading from flat epithelial atypia (FEA) to low-grade invasive ductal carcinomas. There is a lack of consensus in their clinical management as no strict clinical, imaging, or histological features are reliable for defining a subset of lesions with an acceptable (< 2%) probability of upgrade to cancer at surgery. ADH is considered a precursor of low-grade ductal carcinoma but may unfrequently precede the occurrence of non-low-grade, as well as ER negative carcinomas (Kader 2018). This is why more clinical and genomic data are presently needed to identify markers of cancer progression that could support management decisions.

TAKE HOME POINTS

- VAB allows large sampling of breast tissue which minimizes the risk of underdiagnosis of both DCIS and invasive carcinoma.
- Primary indications for mammographically-guided VAB are calcification and architectural distortion, whereas large ill-defined or very small solid lesions on ultrasound will be effectively sampled using US guidance. Attention to each step of the procedure is key to representative tissue sampling.
- The role of multidisciplinary team discussion is essential for making decisions following discordant results and B3 findings.
- There is a lack of consensus for the management of lesions with atypia, as different criteria have been used in the literature to select patients at low-risk of underestimation. Surgical excision remains the reference recommendation.



INTERVENTIONAL DIAGNOSTICS AND PRE-OPERATIVE MANAGEMENT

MR-guided procedures

T.H. Helbich; Vienna/AT

BODY

Percutaneous MRI-guided biopsy is increasingly used as an alternative to surgical biopsy for the histologic assessment of breast lesions. Percutaneous MRI-guided biopsy is faster, less invasive, and less expensive than surgical biopsy. Tissue acquisition is performed with directional vacuum-assisted biopsy probes. Imaging guidance depends on lesion type and results of diagnostic imaging studies particular if MRI lesions are seen on second look Ultrasound. Nevertheless, surgical verification in case of B3 to B5 lesions is necessary thus MRI guided localization techniques are important as well.

TAKE HOME POINTS

- Identify the application of different MRI guided interventions in breast lesions.
- Analyze MRI guided techniques and apply the knowledge to protocol development, patient management / safety, and costs.
- Compare the indications, advantages, and controversies of MRI-guided interventions.

INTERVENTIONAL DIAGNOSTICS AND PRE-OPERATIVE MANAGEMENT

Pre-operative local and regional localization of breast cancer

P. Panizza; Milan/IT

BODY

Accurate pre-operative image-guided localization of non-palpable breast lesions is essential to achieve clear surgical margins, minimizing the resection of healthy tissue and cosmetic damage. For this purpose, different techniques are available: black carbon powder, guide-wire localization (GWL) still the most commonly used method, ultrasound intra-operative guidance and Radioguided Occult Lesion Localization (ROLL) or, in alternative Radioactive Seed Localization (RSL). ROLL involves the injection of macroaggregates of human serum albumin labelled with radioactive $^{99\text{m}}\text{Tc}$ directly into the breast lesion, with mammography or ultrasound guidance. After injection of the radiotracer, a gamma radiation detecting probe is used to locate the lesion on the operating table, allowing the surgeon to assess its skin projection and to decide the best approach, with a satisfactory cosmetic outcome. RSL consists in a titanium seed containing ^{125}I placed at the site of the breast lesion under imaging guidance. This method has the advantage of allowing to place and to verify the seed using all the imaging techniques available, MRI included. Both the techniques need a close cooperation between radiologist, nuclear physician, surgeon and pathologist in order to obtain an effective procedure. A very attractive new method of localization of breast lesions is the magnetic seed (Magseed) localization. Magseed is placed under radiological guidance. It consists of a 5×1 mm paramagnetic steel and iron oxide seed. The seed is detectable using the Sentimag probe that generates an alternating magnetic field which transiently magnetizes the iron oxide particles within the Magseed. The magnetic signature of the Magseed is then detected by the probe. This approach presents some advantages respect to ROLL and RSL: first it overcomes limits due to radiation safety requirements and moreover it solves the problems for radiology and surgery scheduling since it has been demonstrated that the seed can be inserted in the lesion up to 30 days before surgical excision. Limitation of the device are its cost in comparison with wire and radioactive localization and the interference with MRI.

For a correct breast cancer regional localization Sentinel lymph Node (SN) biopsy has been established as the standard of care for axillary staging in most patients with breast carcinoma. It is based on the existence of a lymphatic drainage to a regional node, who works as a filter for tumor cells. Sentinel lymph node biopsy has been proposed by Giuliano in 1994 using blue dye, but with the development of isotopes the substance most used in Europe is the $^{99\text{m}}\text{Tc}$ -labeled colloid. This technique consists in a subdermal and peritumoral injection of the tracer. After injection, a lymphoscintigraphy is performed to provide images to the surgeon to locate the SN. The tracer, drained from the lymphatic system, impregnates the first node in the chain, and the surgeon, using a gamma radiation probe, is able to find and to remove. The success rate of radioguidance in localizing the SN in breast cancer surgery is about 94-97%, approaching 99% when combined with the vital blue dye technique. This procedure allows to avoid axillary dissection in case of negative SN. Some authors suggest the use of sentinel lymph node localization (SNL) technique even after neoadjuvant therapy, when clinical and US evaluation are negative, but this use is still controversial. As for breast cancer localization, a new substance has been recently introduced in order to identify the SN: the super paramagnetic iron oxide (SPIO) nanoparticles. Sienna+ is a brown solution containing dextran-coated SPIO nanoparticles. Sienna+ diluted with saline is injected subareolarly shortly before or after induction of anesthesia. The surgeon with a handheld magnetometer (SentiMag) is able to detect the magnetic response from iron oxide particles trapped in SLNs. This new method has none of the disadvantages of the standard technique and is promising as a safe and effective alternative especially in the absence of nuclear medicine facilities.

Pre-operative local and regional localization of breast cancer

TAKE HOME POINTS

- Accurate pre-operative image-guided localization of non-palpable breast lesions is essential to achieve clear surgical margins, minimizing the resection of healthy tissue and cosmetic damage.
- Different techniques are available for breast cancer localization: black carbon powder, guide-wire (GW), ultrasound intra-operative guidance, Radioguided Occult Lesion Localization (ROLL), Radioactive Seed Localization (RSL) and the new one: magnetic seed (Magseed) localization.
- The Sentinel lymph Node (SN) biopsy has been established as the standard of care for axillary staging.
- Different techniques are available for Sentinel Node Localization (SNL): blue dye, 99mTc-labeled colloid and the new Sienna+: a solution containing dextran-coated SPIO (super paramagnetic iron oxide nanoparticles).

References

1. Allen MJ, Thompson WD, Stuart RC, et al: Management of non-palpable breast lesions detected mammographically. *Br J Surg.* 1994 Apr;81(4):543-5.
2. Chan BK, Wiseberg-Firtell JA, Jois RH et al: Localization techniques for guided surgical excision of non-palpable breast lesions. *Cochrane Database Syst Rev.* 2015 Dec 31;(12):CD009206.
3. Rahusen FD, Bremers AJ, Fabry HF et al: Ultrasound-guided lumpectomy of nonpalpable breast cancer versus wire-guided resection: a randomized clinical trial. *Ann Surg Oncol.* 2002 Dec;9(10):994-8.
4. De Cicco C, Pizzamiglio M, Trifiro G, et al.: Radioguided occult lesion localisation (ROLL) and surgical biopsy in breast cancer. Technical aspects. *Q J Nucl Med* 2002;46:145.
5. Monti S, Galimberti V, Trifiro G, et al.: Occult Breast Lesion Localization plus Sentinel Node Biopsy (SNOLL): Experience with 959 Patients at the European Institute of Oncology. *Ann Surg Oncol.* 2007 Oct;14(10):2928-31.
6. Sajid MS, Parampalli U, Haider Z, Bonomi R: Comparison of Radioguided Occult Lesion Localization (ROLL) and Wire Localization for Non-Palpable Breast Cancers: A Meta-Analysis. *J Surg Oncol.* 2012 Jun;105:852-858.
7. Barentsz MW, van den Bosch MA, Veldhuis WB et al.: Radioactive seed localization for non-palpable breast cancer. *Br J Surg.* 2013 Apr;100(5):582-8.
8. Karakatsanis A, Christiansen PM, Fischer L et al: The Nordic SentiMag trial: a comparison of super paramagnetic iron oxide (SPIO) nanoparticles versus Tc99 and patent blue in the detection of sentinel node (SN) in patients with breast cancer and a meta-analysis of earlier studies. *Breast Cancer Res Treat* 2016;157:281-294
9. Price ER, Khoury AL, Esserman LJ, Joe BN, Alvarado MD : Initial Clinical Experience With an Inducible Magnetic Seed System for Preoperative Breast Lesion Localization. *AJR:210, April 2018* 210:913-917
10. Harvey JR, Lim Y, Murphy J et al: Safety and feasibility of breast lesion localization using magnetic seeds (Magseed): a multicentre, openlabel cohort study. *Breast Cancer Research and Treatment* [2018] 169:531-536
11. Giuliano AE, Kirgan DM, Guenther JM, Morton DL: Lymphatic mapping and sentinel lymphadenectomy for breast cancer. *Ann Surg.* 1994 Sep;220(3):391-8
12. Uren RF, Howman-Giles RB, Thompson JF et al.: Lymphoscintigraphy in breast cancer. *J Nucl Med.* 1995 Oct;36(10):1775-80.
13. Veronesi U, Paganelli G, Galimberti V et al: Sentinel-node biopsy to avoid axillary dissection in breast cancer with clinically negative lymph-nodes. *Lancet.* 1997 Jun 28;349(9069):1864-7.
14. Giuliano AE, Hunt KK, Ballman KV et al: Axillary dissection vs no axillary dissection in women with invasive breast cancer and sentinel node metastasis: a randomized clinical trial. *JAMA.* 2011 Feb 9;305(6):569-75.
15. Gentilini O, Veronesi U: Staging the Axilla in Early Breast Cancer. Will Imaging Replace Surgery? *JAMA Oncol.* 2015;1(8):1031-1032.
16. Douek M, Klaase J, Monypenny I et al.: Sentinel node biopsy using a magnetic tracer vs. standard technique: The Sentimag Multicentre Trial. *Ann Surg Oncol* 2014, Vol 21(4): 1237-45
17. Thill et al.: The Central-European Sentimag study: Sentinel lymph node biopsy with superparamagnetic ironoxide (SPIO) vs. radioisotope. *Breast* 2014, Vol 23(2): 175-9
18. Rubio IT, Diaz-Botero S, Esgueva A et al.: The superparamagnetic iron oxide is equivalent to the Tc99 radiotracer method for identifying the sentinel lymph node in breast cancer, *Eur J Surg Oncol.* 2015 Jan;41(1):46-51.

FROM HYPERPLASIA TO DCIS (B3 LESIONS/DCIS)

Management of proliferative B3a lesions

A. Linda¹, R. Girometti², C. Zuiani¹; ¹Udine/IT, ²Tavagnacco, Feletto/IT

BODY

Although the management of the majority of breast lesions diagnosed at imaging-guided core-needle-biopsy (CNB) is straightforward, a small group of lesions – B3 lesions - pose a dilemma when diagnosed at percutaneous biopsy. These lesions - papilloma, radial scar, lobular neoplasia, atypical ductal hyperplasia, and flat epithelial atypia - are benign, but have an increased risk of upgrade to malignancy when the entire lesion is evaluated after surgical excision. However, it is increasingly being recognized that some B3 subtypes are only associated with a very low risk of malignancy, and, therefore, surgical excision for all represents overtreatment. Because B3 lesions essentially fall into two categories with a lesser and greater risk of associated malignancy, some Authors suggest subdividing the category into B3a for benign lesions potentially associated with malignancy (for example radial scars and papillomas) and B3b for more worrisome atypical epithelial proliferations. The purpose of subtyping B3 lesions is to tailor the definitive management, being more aggressive in case of B3b lesions and more conservative for B3a lesions. In particular, according to the literature, conservative management options as radiologic follow-up and second-line vacuum-assisted biopsy should be considered as an alternative to surgical excision.

TAKE HOME POINTS

- Subclassification of B3 category refines the current classification with possible implications in clinical management;
- Conservative management approach is a reasonable option for B3a lesions;
- Extensive sampling (VAB) may be a viable alternative to surgical excision in the investigation of B3a lesions.

FROM HYPERPLASIA TO DCIS (B3 LESIONS/DCIS)

Management of precursor lesions B3b: Lobular neoplasia

S. Pérez-Rodrigo; Madrid/ES

BODY

Lobular neoplasia (LN) is defined as a proliferation of generally small and often loosely cohesive cells originating in the terminal duct-lobular unit. Lobular carcinoma in situ was first described over 60 years ago. Now, the incidence is increasing. Despite the long history, it continues to pose significant difficulties in screening, diagnosis, management, and treatment. This is partly due to the perpetuation of its multifocal and bilateral presentation, an incomplete understanding of its biology and natural perpetuation of misconceptions gathered over the last decades.

There has been some hypothesis, than in a similar manner to DCIS, it may represent an established step along the pathway to the development of invasive cancer. It is a risk indicator (bilateral and multifocal). So mastectomy was recommended as the standard form of treatment for many years until most of the surgeries were benign. Then, the opposite form of treatment, the follow up without any surgery, was considered.

I will review the literature about the different treatment options since the follow up to surgery and the new alternatives. One of them, adopted in many guidelines and hospitals is performing a percutaneous excision of the lesion with vacuum or intact system avoiding surgery without underestimation them.

TAKE HOME POINTS

- LN is a risk indicator and a non-obligate precursor of cancer.
- Its incidence is increasing.
- The standard form of treatment until some years was the surgery.
- Nowadays, the percutaneous excision is the technique of choice with safety avoiding the underestimation and sequelae of the surgery.

FROM HYPERPLASIA TO DCIS (B3 LESIONS/DCIS)

Management of precursor lesions B3b: ADH and FEA

N. Sharma; Leeds/UK

BODY

The management of B3 lesions is complex and controversial. The role of vacuum assisted excision is increasingly being recognised and accepted in the management of B3 lesions with no atypia (radial scars and papillomas), however there has been slow adoption of vacuum assisted excision in managing B3 lesions with atypia, in particular ductal atypia (AIDEP and FEA).

In Europe and USA ductal atypia is still treated with surgical excision. In the UK there is National guidance on managing B3 lesions where B3 lesions with ductal atypia should be treated with vacuum excision rather than surgical excision.

In our unit B3 lesions with ductal atypia are managed with vacuum assisted excision and are only referred for surgery if upgrade to malignancy or there is radiological or pathological concern for malignancy and a surgical diagnostic biopsy is advised.

Data will be presented highlighting the benefits of using vacuum assisted excision to replace surgical diagnostic biopsy and how the new UK guidelines are patient centred and cost effective.

TAKE HOME POINTS

- Vacuum assisted excision is a safe and effective alternative to surgical diagnostic biopsy in patients with ductal atypia
- B3 lesions with atypia are often upgraded to low risk DCIS
- Vacuum assisted excision helps manage overtreatment of ductal atypia

FROM HYPERPLASIA TO DCIS (B3 LESIONS/DCIS)

MRI in the management of B3 lesions

U. Bick; Berlin/DE

BODY

High-risk lesions with uncertain malignant potential classified as B3 at percutaneous biopsy are a heterogeneous group of pathologic entities including e.g. atypical ductal hyperplasia (ADH), lobular neoplasia, flat epithelial atypia (FEA), radial scar and papilloma. The unifying feature between these lesions is the fact, that in a certain portion of these lesions, subsequent surgical excision will reveal malignancy (invasive or in-situ). However, the upgrade rates to malignancy vary significantly between the different lesion entities (and between individual studies) and no common guidelines exist, which lesions should undergo excisional biopsy and which ones can safely be followed. Another problem is, that several lesions (especially e.g. lobular neoplasia) will increase the breast cancer risk not only at the area of the initial biopsy, but also in the remainder of the ipsilateral as well as the contralateral breast. Breast MRI with its high sensitivity and negative predictive value can be used to identify patients, in whom excisional biopsy may not be necessary and who can safely be followed. MRI at the same time addresses the concern of occult malignancies in the ipsilateral breast distant from the biopsy site as well as in the contralateral breast, which would not be found by surgical excision of the biopsy site alone. MRI after diagnosis of a high-risk lesion at percutaneous biopsy will be most useful in lesions with a low upgrade probability such as radial scars and papillomas, as the negative predictive value of the MRI will be higher when the underlying probability of cancer is lower. But presence or absence of enhancement on MRI should only be one factor in deciding which patients should undergo excisional biopsy of high-risk lesions classified as B3, along with the specific histological findings, the size of the initial radiological abnormality as well as the accuracy and completeness of the sampling during the percutaneous biopsy. Ideally, all cases with a high-risk lesion diagnosed at percutaneous biopsy should be discussed at a multidisciplinary conference involving the radiologist, pathologist and surgeon in order to determine the most suitable course of action in each individual case.

TAKE HOME POINTS

MRI of the breast is a very useful piece of the puzzle in determining which patients should undergo surgical excision after diagnosis of a high-risk lesion at percutaneous biopsy.

References

1. Hammersley JA, Partridge SC, Blitzer GC, et al: Management of high-risk breast lesions found on mammogram or ultrasound: the value of contrast-enhanced MRI to exclude malignancy. *Clin Imaging* 49:174-180, 2018.
2. Londero V, Zuiani C, Linda A, et al: High-risk breast lesions at imaging-guided needle biopsy: usefulness of MRI for treatment decision. *AJR* 199:W240-W250, 2012.
3. Linda A, Zuiani C, Furlan A, et al: Nonsurgical management of high-risk lesions diagnosed at core needle biopsy: can malignancy be ruled out safely with breast MRI? *AJR* 198:272-280, 2012.

FROM HYPERPLASIA TO DCIS (B3 LESIONS/DCIS)

B3 lesions/correlation with pathology

A. Batistatou; Ioannina/GR

BODY

In Pathology, as in Radiology and other disciplines of Medicine, a clear-cut clinical picture and/or characteristic imaging findings almost always correlate with pathognomonic histological findings and a certain Pathology diagnosis. The patient treatment follows, based on guidelines, and the prognosis can be predicted. However, there exist abnormalities that are non-typical in any aspect. In breast, for example, a breast lesion categorized as B3 (of uncertain malignant potential) corresponds to a variety of histological appearances, often of a borderline nature. The main mammographic abnormalities are calcifications, mass or architectural deformity. B3 lesions, which represent 3.3-12.6% of core biopsy diagnoses, may prove to be benign, borderline, malignant, associated with malignancy in adjacent issue or with increased risk for future cancer.

THESE LESIONS ARE THE FOLLOWING:

- **Atypical ductal hyperplasia (ADH).** It is a benign group of lesions that involves the terminal duct lobular unit. In classic Pathology textbooks there are cytological, architectural and extent-based criteria for differential diagnosis from usual ductal hyperplasia on one end and low-grade ductal carcinoma in situ (DCIS) on the other. ADH is associated with moderately increased risk for subsequent development of invasive breast carcinoma.
- **Flat epithelial atypia (FEA).** It also involves the terminal duct lobular unit. In the latest WHO classification it has replaced the columnar cell change/hyperplasia with atypia. It is associated with microcalcifications, so it can be detected on screening mammography. FEA often co-exists with lobular neoplasia, ADH, low-grade DCIS and low-grade invasive carcinoma. The risk for subsequent development of invasive breast carcinoma exists, but it is low.
- **Classic (not pleomorphic) lobular neoplasia (LN).** In the latest WHO classification LN includes a spectrum of atypical lesions of the epithelium of the terminal duct lobular unit, from atypical lobular hyperplasia (ALH) to lobular carcinoma in situ (LCIS). The main feature that differentiates these two ends is the extent of involvement of individual lobular units. LN can be multicentric and bilateral and has no specific clinical features, so it is often an incidental finding. On histology the main differential diagnosis is from low-nuclear-grade DCIS, which in many cases can co-exist with LN. LN is a risk factor for subsequent development of invasive breast cancer of lobular or ductal type, in either breast, but in the minority of women and after a long time.
- **Papillary lesions (PL).** The intraductal papillary lesions are the following: intraductal papilloma, intraductal papillary carcinoma, encapsulated papillary carcinoma and solid papillary carcinoma. The intraductal papilloma is a benign lesion; it can be central (solitary) or peripheral (multiple). It may contain areas of ADH or DCIS and if atypical it is associated with increased risk for subsequent development of invasive cancer. The intraductal papillary carcinoma has the same prognosis as DCIS. The encapsulated papillary carcinoma is quite rare; it is circumscribed and surrounded by a fibrous capsule. Thorough sampling is necessary to identify possible areas of invasion. Solid papillary carcinoma is rare (<1% of breast carcinomas) and consists of multiple, closely apposed cellular nodules. On mammography it appears as abnormality or mass. By the definition of this lesion it is difficult to determine if a particular case corresponds to in situ or invasive carcinoma.
- **Radial scar (RS).** Radial scars, in current practice, are most often identified by mammography. A radial scar is a benign lesion that resembles invasive carcinoma. The term "radial scar" is applied to small lesions (typically with stellate configuration) and the term "complex sclerosing lesion" to larger ones that contain a variety of ductal epithelial hyperplasia along with sclerosis. Grossly, it can be undetected (if small), it may appear as an irregular area of firmness or it may be indistinguishable from carcinoma. Radial scars have been associated with benign proliferative breast lesions, but also with atypical ones (ADH) or malignant entities (DCIS and invasive

B3 lesions/correlation with pathology

carcinoma). Association with the latter has been reported in mammography-detected lesions that are >0.6cm in size, in women older than 50 years. There is controversy about the risk for subsequent development of breast cancer, which appears to be low for associated benign lesions and higher if associated with atypical lesions.

- **Other entities such as phylloides tumor, mucocele-like or spindle cell lesions.** Phyllodes tumours are circumscribed biphasic tumours, characterized by a benign epithelial component arranged in clefts surrounded by an overgrowing hypercellular mesenchymal component typically organized in leaf-like structures. Grossly, they are well-circumscribed, firm, bulging masses, occasionally mucoid. Large lesions may have areas of haemorrhage or necrosis. They are classified as benign, borderline or malignant, based on specific histological features such as circumscription, stromal cellularity / atypia / overgrowth, mitoses etc. Mucocele-like lesions are associated with benign cysts, ADH, DCIS or invasive carcinoma.

As it is obvious from the above the marked heterogeneity of B3 lesions corresponds to variable risks for malignancy. Thus, some authors have proposed to sub-classify B3 lesions based on the presence or absence of epithelial atypia (B3a and B3b, respectively). If the lesion is diagnosed in core biopsy, further histological examination is almost always warranted, since the risk of co-existing adjacent malignancy (“risk of upgrade”, defined as synchronous DCIS or invasive carcinoma at the same site) is calculated to: >20% for ADH, 13-21% for FEA, 27% for LN, 36% for PL with atypia, 36% for RS with atypia and <10% for RS without atypia, 21% for mucocele-like lesions with atypia, and <5% for mucocele-like lesions without atypia.

With the continuous great progress in imaging the ability to detect “findings” within the breast should be matched with the ability of a medical multidisciplinary team to determine the meaning of these findings and guide treatment, if needed. In the era of personalized medicine, the discussion in a multidisciplinary

meeting of each individual case/each patient, with all available imaging and histological data, the awareness of possible technical difficulties and patient informed preferences guarantee the optimal therapeutic approach.

Selected References

1. WHO Classification of Tumours of the Breast. 4th Edition. Eds: Lakhani, SR, Ellis IO, Schnitt SJ, Tan PH, van de Vijver MJ. IARC, ISBN 13 9789283224334.
2. Pinder SE, Shaaban A, Desai A, et al. NHS Breast Screening multidisciplinary working group guidelines for the diagnosis and management of breast lesions of uncertain malignant potential on core biopsy (B3 lesions). *Clinical Radiology* (2018) 73: 682-692.
3. Sharma N, Wilkinson LS, Pinder SE. The B3 conundrum—the radiologists’ perspective. *Br J Radiol* (2017) 90: 20160595.
4. Mayer S, Kayser G, Rücker G, et al. Absence of epithelial atypia in B3-lesions of the breast is associated with decreased risk for malignancy. *The Breast* (2017) 31: 144-149.
5. Strachan C, Horgan K, Millican-Slater RA et al. Outcome of a new patient pathway for managing B3 breast lesions by vacuum-assisted biopsy: time to change current UK practice? *J Clin Pathol* (2016) 69:248-254.
6. Raget CJ, O’Flynn EAM, Comstock C, et al. First International Consensus Conference on lesions of uncertain malignant potential in the breast (B3 lesions). *Breast Cancer Res Treat* (2016) 159:203-213.
7. Li Z, Ranade A, Zhao C. Pathologic findings of follow-up surgical excision for radial scar on breast core needle biopsy. *Human Pathology* (2016) 48:76-80.
8. NHS Breast Screening Programme Clinical guidance for breast cancer screening assessment NHSBSP. Publication number 49. Fourth edition. November 2016
9. Rakha EA, Lee AHS, Jenkins JA, et al. Characterization and outcome of breast needle core biopsy diagnoses of lesions of uncertain malignant potential (B3) in abnormalities detected by mammographic screening. *Int. J. Cancer* (2011)129: 1417-1424.
10. Bianchi S, Caini S, Renne G, et al. Positive predictive value for malignancy on surgical excision of breast lesions of uncertain malignant potential (B3) diagnosed by stereotactic vacuum-assisted needle core biopsy (VANCB): A large multi-institutional study in Italy. *The Breast* (2011) 20: 264-270.

TOMOSYNTHESIS AND SCREENING

Evaluation of screening efficacy

S. Duffy; London/UK

BODY

Mammography screening has been shown to reduce breast cancer mortality in randomised trials. There remains a need to quantify the extent to which it does so on the non-experimental setting, in the routine screening services currently provided. We consider some of the challenges in this endeavour and summarise major methods of observational evaluation. New screening modalities, on the other hand, need experimental evaluation. We consider some efficient approaches to such evaluation, with specific reference to studies of digital breast tomosynthesis.

TAKE HOME POINTS

- Observational evaluation of screening services give rise to methodological challenges, and careful application of approaches to deal with these are necessary.
- There are efficient designs and analyses which can experimentally evaluate new screening modalities without the need for very long term follow-up.

TOMOSYNTHESIS AND SCREENING**Strategies to optimize the potential of breast tomosynthesis**

I. Sechopoulos; Nijmegen/NL

BODY

Population screening for breast cancer in Europe is currently performed with digital mammography (DM), involving acquisition of two images per breast: the cranio-caudal and the medio-lateral oblique views. These are acquired, for the most part, to reduce the effect of tissue superposition, but the loss of performance due to this effect, especially in dense breasts, persists. Digital breast tomosynthesis (DBT) has been introduced mostly to reduce the problem of tissue superposition. However, a single DBT image typically consists of one pseudo-3D stack of ~50 slices for a breast of average thickness. The increase in information generated by DBT compared to DM results in a reported doubling in reading time, making its introduction in population screening in its current form challenging. However, several alternative acquisition and reading strategies may be useful in optimizing the interpretation of DBT-based screening. This would allow for the potential of DBT, and its promise of improved outcomes, to finally be introduced in high-volume screening programs without a massive increase in the expenditure of healthcare resources. Strategies that have the potential to allow the acquisition of fewer images, the reconstruction of fewer slices, and the (human) interpretation of fewer cases, will be presented and discussed. It can be expected that all these strategies, or a combination thereof, could result in DBT-based screening requiring the same amount of resources as current DM-based screening, while resulting in improved lesion detection performance.

TAKE HOME POINTS

- Alternative acquisition strategies, such as acquisition of a single view, could reduce the amount of time needed to interpret DBT images.
- Alternative reconstruction methods could help further reduce total reading time.
- Deep-learning based computerized algorithms could further reduce the total reading time for DBT screening.
- A combination of the proposed strategies could reduce the reading time so that population screening with DBT would be feasible.

YOUNG SCIENTISTS' SESSION, CARLA BOETES YOUNG INVESTIGATOR AWARD AND AWARDING OF THE BEST SUBMITTED ABSTRACT – YOUNG PHYSICIAN/SCIENTIST GRANT (2ND)

Preoperative staging in women with known breast cancer: Comparison between Digital Breast Tomosynthesis (DBT) and Magnetic Resonance Imaging (MRI)

F. Galati, F. Marzocca, E. Collalunga, G. Panzironi, C. Caramanico, F. Pediconi; Rome/IT

PURPOSE

To prospectively evaluate the accuracy in tumor extent and size assessment of Digital Breast Tomosynthesis (DBT) and Magnetic Resonance Imaging (MRI) in women with known breast cancers, with pathological size as the gold standard.

METHODS

From May 2014 to April 2016, 50 patients with known breast cancer were enrolled. All patients underwent MRI on a 3T magnet and DBT projections. Two radiologists evaluated in consensus each imaging set unaware of the final histological examination. MRI and DBT sensitivity, positive predictive value (PPV) and accuracy were calculated. McNemar test was used to compare MRI and DBT sensitivity. Correlation and regression analyses were used to evaluate MRI vs Histology, DBT vs Histology and MRI vs DBT lesions tumor size agreement. Separate regression analyses were used to investigate the effect of mass or non-mass enhancement. Finally a logistic model was fitted to the positive cases to evaluate the DBT detection rate with respect to breast density, lesion size and other covariates.

RESULTS

On histological examination 70 lesions were detected. MRI sensitivity was 100%, PPV 96% and accuracy 96%; DBT sensitivity was 81%, PPV 92% and accuracy 77%. McNemar test p-value was 0.0003. Lesions size correlation coefficient was 0.97 for MR vs Histology, 0.92 for DBT vs Histology. The regression coefficient for MR vs DBT was 0.83. A separate regression models fitted to the mass or non-mass enhancement showed MRI smaller error variability into the mass group. Regarding DBT detection rate, we found a lower detection rate and a higher relative error in patients with dense breasts, in particular for small lesions.

CONCLUSION

MRI provided higher diagnostic performance than DBT in pre-operative evaluation of disease, even if DBT showed good accuracy, sensitivity and accurate tumor size assessment.

SUMMARY STATEMENT

DBT could be a valid tool for preoperative staging when MRI could not be performed.

YOUNG SCIENTISTS' SESSION, CARLA BOETES YOUNG INVESTIGATOR AWARD AND AWARDING OF THE BEST SUBMITTED ABSTRACT – YOUNG PHYSICIAN/SCIENTIST GRANT (2ND)

Evaluation of Gd-deposits in healthy women participating in high risk screening program for early breast cancer detection

B. Bennani-Baiti¹, K.B. Krug², M. Hellmich², D. Giese², T.H. Helbich¹, P.A.T. Baltzer¹; ¹Vienna/AT, ²Cologne/DE

PURPOSE

To determine whether patients at high risk to develop breast cancer, that undergo contrast enhanced breast MRI at regular intervals for early breast cancer detection, exhibit brain signal alterations in the dentate nucleus (ND) and globus pallidus (GP).

METHODS

In this IRB-approved, dual-centre randomized, prospective study 73 healthy women with no history of cancer or neurological disease that had received at least 6 doses of macrocyclic Gadolinium-based contrast agents in the course of a national high risk screening program for the early detection of breast cancer were included. At 3T/1.5T MRI, T1 times and T1 signal intensities were measured for ND, pons, GP, and crus posterior of the capsula interna (CP) bilaterally, employing Horos software. Ratios of GP to CP as well as ND to pons were calculated for respective signal intensities and further statistical analyses were performed with SPSS and Medcalc.

RESULTS

There were 73 participants (median age 46+/-9years) with an average of 9 cumulative dosages of Gd-based macrocyclic contrast agents (range 6-23). Spearman's rank analysis revealed a mild correlation between age and number of dosages (R 0.31, p<0.01) but no statistically significant correlations for signal intensity ratios or T1 times in relation to age or number of dosages. ANOVA testing revealed an adjusted R² of -0.026 and -0.004 for the number of cumulative dosages predicting T1 times and signal intensity ratios, respectively, confirming that the number of previous dosages did not affect T1 signal in GP or ND.

CONCLUSION

Neither nucleus dentatus nor globus pallidus display altered T1 signals after high cumulative dosages of macrocyclic Gd-based contrast agents in healthy women.

SUMMARY STATEMENT

These findings show that the currently employed macrocyclic Gd-based contrast agents do not result in Gd-deposits in the brain of healthy women participating in a high risk screening program for early breast cancer detection.

YOUNG SCIENTISTS' SESSION, CARLA BOETES YOUNG INVESTIGATOR AWARD AND AWARDING OF THE BEST SUBMITTED ABSTRACT – YOUNG PHYSICIAN/SCIENTIST GRANT (1ST)

Prospective comparison of synthetic 2D mammography plus DBT and MRI in breast cancer surveillance of women treated for Hodgkin lymphoma with chest radiation before the age of 30

M. Fasciano, G. Mariscotti, M. Durando, C. Casella, G. Negro, I. Castellano, P. Fonio; Turin/IT

PURPOSE

To evaluate the role of synthetic 2D-mammography plus Tomosynthesis (2Dsynth-DBT), Ultrasound (US) and MRI in the identification of breast cancer in women treated for Hodgkin lymphoma (HL) with chest radiation (RT) before the age of 30 years.

METHODS

From January 2015 to March 2018, we prospectively enrolled for breast cancer surveillance 61 Patients previously treated for HL with RT (≥ 20 Gy) before 30 years old. Eligible women, as recommended by international guidelines, were ≥ 25 years and at least 8 years had passed since they received RT. Patients were invited to undergo annual 2Dsynth-DBT, US and MRI. All the findings identified by imaging modalities were classified according to BI-RADS categories and biopsy-proven if suspicious. Diagnostic performances of 2Dsynth-DBT, US and MRI were compared, and imaging features of malignant lesions were also investigated.

RESULTS

Patients' average age at HL diagnosis was 20,9 years (range 12-30) and average RT dose 26,9Gy (range 20-43,2). In the study period, 26/61 women underwent biopsy: out of 41 suspicious lesions, 11 were malignant (8 invasive and 3 in situ carcinomas). Sensitivity for 2Dsynth-DBT, US and MRI was respectively 81%(9/11), 72%(8/11), 81%(9/11). Sensitivity for 2Dsynth-DBT+MRI was 90%(10/11). Specificity for 2Dsynth-DBT, US and MRI was respectively 94%, 81% and 75%. Malignant lesions detected by 2Dsynth-DBT were 5/9 masses, 2/9 microcalcifications, 1/9 asymmetric density and 1/9 architectural distortion. Malignant lesions detected by MRI were 5/9 mass lesions and 4/9 non-mass; MRI didn't identify two cases of microcalcifications (in situ carcinomas).

CONCLUSION

Our study supported the combination of 2Dsynth-DBT and MRI for identifying with high sensitivity breast cancer lesions in women treated with RT for HL before the age of 30 years, mostly represented by masses, but also microcalcifications.

SUMMARY STATEMENT

To assess the role of breast imaging modalities in the surveillance of young women treated for Hodgkin lymphoma with chest radiation for breast cancer detection.

YOUNG SCIENTISTS' SESSION, CARLA BOETES YOUNG INVESTIGATOR AWARD AND AWARDING OF THE BEST SUBMITTED ABSTRACT – CARLA BOETES YOUNG INVESTIGATOR AWARD

Integrating fast diffusion weighted imaging into an abbreviated breast MRI: Increase of accuracy without sacrificing rapidity

M. Dietzel; Erlangen/DE

BACKGROUND

Abbreviated breast MRI (ABM) is a promising approach to both increase accessibility and to decrease costs of breast MRI [1, 2].

Diffusion-weighted imaging (DWI) is a fast and quantitative technique to assess the tissue microstructure. It has been shown that DWI can increase diagnostic accuracy of a standard breast MRI protocol [3, 4].

AIM

To investigate whether an additional fast DWI sequence can increase accuracy of ABM without sacrificing its rapidity.

MATERIAL AND METHODS

In 132 consecutive patients, a standard breast MRI protocol according to international recommendations was performed (10:10 min) [5]. The protocol consisted of the three sections shown in figure 1.

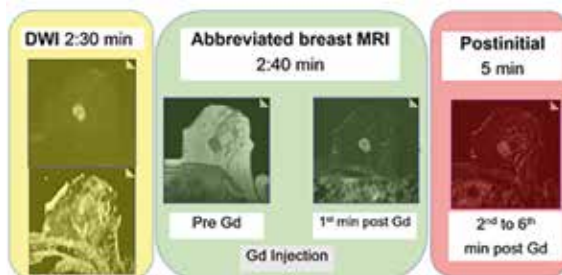


Figure 1: Three sections of the MRI protocol. The centerpiece was the abbreviated breast MRI (ABM), consisting of the pre- and the first scan post Gadolinium (Gd) injection. Considering an average injection time of 10 seconds and a subsequent delay of 30 seconds, this gave an average acquisition time of 2:40 minutes. The ABM was expanded by five additional post-contrast scans (+5 minutes: Postinital) and by a fast DWI sequence (+2:30 minutes).

Histopathological verification served as the referenced standard. Freehand regions of interest (ROI: 10-15 mm²) were drawn around the enhancing parts of the lesion in the first post-contrast scan. ROIs were automatically transferred to the ADC (apparent diffusion coefficient) maps as well as to the pre-contrast, the first and the last post-contrast scan. This gave one semi-/quantitative diagnostic

parameter for every section of the protocol (ABM: wash-in, postinital: wash-out, DWI: ADC).

Applying logistic regression, we investigated whether the following three extensions of the ABM could increase diagnostic accuracy:

Table 1: Extensions of the ABM

EXTENSION OF THE ABM	Sections of the breast MRI protocol (c.f. figure 1) considered for differential diagnosis
I. ABM+	ABM and DWI
II. CURVE	ABM and Postinital
III. CURVE+	Curve and DWI

Finally, diagnostic accuracy of all three sections of the breast MRI protocol (ABM, Postinital, DWI) and all three extensions of the ABM (ABM+, Curve, Curve+) were quantified (area under the curve: AUC) and compared intra-individually (AUC-comparison, alpha=5%, cross-correlation).

RESULTS

145 lesions were included (malignant/benign: 101/44).

Correlation analysis demonstrated substantial redundant diagnostic information between DWI versus Postinital ($\rho=0.61$) and ABM versus Postinital ($\rho=0.59$), but substantially less for ABM versus ADC ($\rho=0.35$; all: $P<0.001$).

Upon univariate analysis, DWI outperformed both ABM and Postinital ($P=0.02$). Integration of DWI into the ABM (ABM+) raised the accuracy by 13.4% ($AUC_{ABM+}=0.88$; $P=0.002$; figure 2). Implementation of Postinital into ABM (Curve) did not raise the accuracy of ABM ($P=0.27$). Similarly ABM+ could not be further optimized, if Postinital was considered as an additional parameter (Curve+ = ABM+; $P=1$).

Integrating fast diffusion weighted imaging into an abbreviated breast MRI: Increase of accuracy without sacrificing rapidity

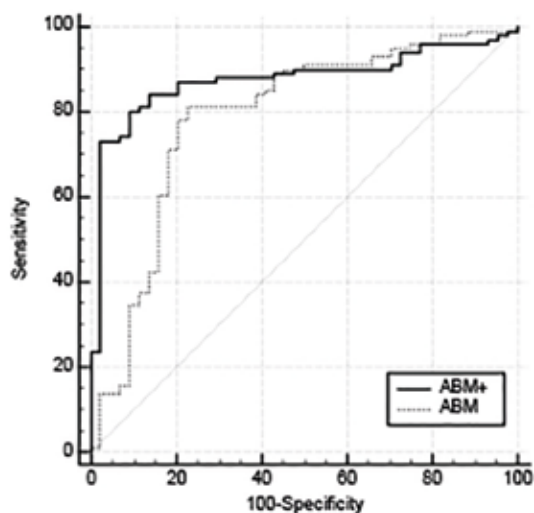


Figure 2: Receiver operation characteristics of ABM and ABM+. Integral assessment of the ADC and the ABM (ABM+: AUC=0.88) significantly increased diagnostic performance compared to ABM alone.

CONCLUSION

An additional fast DWI sequence can increase accuracy of the ABM without sacrificing its rapidity. Combining DWI with one fast pre- and one post-contrast sequence might therefore be an option to further optimized ABM.

References

1. Kuhl CK, Schrading S, Strobel K, et al (2014) Abbreviated breast magnetic resonance imaging (MRI): first postcontrast subtracted images and maximum-intensity projection-a novel approach to breast cancer screening with MRI. *J Clin Oncol* 32:2304–2310. doi: 10.1200/JCO.2013.52.5386
2. Fischer U, Korthauer A, Baum F, et al (2012) Short first-pass MRI of the breast. *Acta Radiol* 53:267–269. doi: 10.1258/ar.2012.110638
3. Pinker K, Bickel H, Helbich TH, et al (2013) Combined contrast-enhanced magnetic resonance and diffusion-weighted imaging reading adapted to the “Breast Imaging Reporting and Data System” for multiparametric 3-T imaging of breast lesions. *Eur Radiol* 23:1791–1802. doi: 10.1007/s00330-013-2771-8
4. Baltzer A, Dietzel M, Kaiser CG, Baltzer PA (2016) Combined reading of Contrast Enhanced and Diffusion Weighted Magnetic Resonance Imaging by using a simple sum score. *Eur Radiol* 26:884–891. doi: 10.1007/s00330-015-3886-x
5. Mann RM, Kuhl CK, Kinkel K, Boetes C (2008) Breast MRI: guidelines from the European Society of Breast Imaging. *Eur Radiol* 18:1307–1318. doi: 10.1007/s00330-008-0863-7

Breast screening and diagnostic radiology in Saudi Arabia

F.M. Altahan; Riyadh/SA

N. Khoumais; Riyadh/SA

BODY (F.M. Altahan)

The Saudi National Breast Cancer Early Detection Program Launched in 2012 under the auspices of the Ministry of Health and with significant support from the private sector and non-governmental organizations to address KSA's growing breast cancer problem and advancing the concept of preventative care in country where prevention is still in its infancy and conservative values are deeply ingrained in daily life.

The objective of the program not only to reduce mortality rate and the economic burden of the disease but also to ensure every woman diagnosed with breast cancer in the kingdom becomes a survivor with good quality of life.

This governmental program was initially established in Riyadh city – the capital of the kingdom - with scaling -up plan to expand across the country with particular emphasis on focusing in engaging more the primary health care sector and investment in the underutilized infrastructure.

Given the numerous leadership changes at the Ministry of Health since 2014 and the huge healthcare transformation plan under 2030 vision on 2016, all initiatives, including the NBCSP, experienced slower than expected progress. However, the NBCSP administrators took advantage of this brief slow down to finalize its expansion plans ensuring that all Saudi women have easy access to screening and treatment. One of the key innovations of the program is the establishment of well women early detection clinics in shopping malls , places are easily accessible to saudi women to relax and enjoy the company of families, relatives and friends ,It is Holistic and cost-effectiveness methodology for setting up an integrated screening service that provides medical services of routine check-up for chronic disease and early detection for most common cancers, counselling, referral and education to women in order to improve outcomes and reduce mortality from disease in country NCDs are estimated to account for 78% of total deaths. The clinics designed and decorated nicely in way to attract casual shoppers visiting the nearby stores, opened 365 days including the weekends from 3:00-10:00 PM to overcome all obstacles facing women to participate in the program.

Many program performance indicators including time line, recall rate, biopsy rate, and cancer detection rate met the criteria according to international guidelines. However, there is need to enhance efforts to raise participation rate working in creative way for Community intervention & set strategies to eliminate structural barriers via collaboration and strategic partnership with all existed communities interested in awareness and prevention to establish organized cancer health education and early detection which will lead to effective public awareness.

TAKE HOME POINTS

Cancer prevention and early detection are the most effective ways to control breast cancer.

Population - based early detection program is the way to go with close involvement of primary health care sectors.

BODY (N. Khoumais)

Diagnostic Breast Imaging has witnessed tremendous development in technology worldwide including Saudi Arabia. In this talk, we will shed light on diagnostic breast imaging in the growing nation of Saudi Arabia including the young generation of subspecialized radiologists through the experience of King Faisal Specialist Hospital and Research Centre, Riyadh. We will also give an idea on the demographics of breast cancer in Saudi Arabia with few case examples highlighting areas for future improvement.

ULTRASOUND

Multiparametric ultrasound

P. Kapetas; Vienna/AT

BODY

Breast ultrasound (US) has a high sensitivity as a screening and diagnostic tool, at the cost of a variable but overall moderate specificity. This is mainly due to the fact that the routinely used B-mode US only provides morphological tissue information. To overcome this limitation, several complementary sonographic modalities, assessing other, functional tissue properties, have been developed and are currently in use, such as elastography (strain or shear-wave), Doppler Imaging and contrast-enhanced US (CEUS).

Elastography provides information regarding tissue stiffness, while Doppler and CEUS assess tissue vascularization. Since breast cancer tends to show different findings from benign lesions in these modalities, the additional pieces of information gained aid in the differentiation of breast lesions. The simultaneous use of ancillary sonographic modalities with B-mode US has given rise to the term "multiparametric US", which has been shown to raise the specificity of breast US through the concomitant assessment of different tissue properties. Thus, a substantial number of unnecessary, false-positive biopsy recommendations may be avoided.

A further important aspect of these modalities lies in the multitude of quantitative indices that they offer, which have the potential to be used as imaging biomarkers for breast cancer and reduce the relatively high interobserver variability of breast US. Finally, multiparametric breast US can be used to assess response to neoadjuvant treatment, as functional tumor changes often occur before significant changes in tumor size.

TAKE HOME POINTS

- Multiparametric ultrasound refers to the simultaneous use of morphologic B-mode with other sonographic techniques, which evaluate different, functional tissue properties (like elastography, Doppler, contrast-enhanced ultrasound).
- A multiparametric approach has the potential to increase the specificity of breast ultrasound, thus avoiding unnecessary, false-positive breast biopsies.

- Multiparametric breast ultrasound offers a series of quantitative indices that may be used as imaging biomarkers and reduce the subjective interpretation bias of qualitative evaluations.
- Monitoring response to neoadjuvant treatment can be facilitated by multiparametric breast ultrasound.

A primer on automated breast ultrasound

M. Marcon; Zurich/CH

BODY

In breast cancer screening ultrasound in addition to mammography is very important in women with mammographically dense breast in order to recognize small cancers possibly masked by the fibroglandular tissue. Ultrasound is radiation free, relatively cheap and does not require intravenous injection of contrast medium. However handheld ultrasound has some main limitations including the operator dependence, the limited reproducibility and the long time required to perform the examination. Automated breast ultrasound has been introduced in the recent years in order to overcome some of these limitations. It consists in a volumetric imaging technique including the whole-breast evaluation, with the possibility to perform multiplanar reconstructions. The access to the entire breast volume acquisition facilitates the comparison of findings in subsequent examinations. Moreover the image acquisition can be performed by technicians with possible remote interpretation of the images by the reporting radiologist. Automated breast ultrasound similarly to handheld ultrasound has been proved to enable the detection of small mammographically negative breast cancer but also to increase the recall-rate. This talk will focus on discussing benefits and harms of automated breast ultrasound and provide the basis for the interpretation of imaging findings.

TAKE HOME POINTS

- ABUS offers automated scanning of the whole breast volume with the possibility to perform multiplanar reconstructions.
- The coronal reconstruction is useful to recognize spiculation and retraction patterns in presence of malignant lesions.
- Use of ABUS supplemented to screening mammography enables the detection of small mammographically negative breast cancer.

ULTRASOUND

Novel developments in automated breast ultrasound

A. Vourtsis; Athens/GR

BODY

It has been established that women with dense breasts are excellent candidates for supplemental screening. Automated breast ultrasound system (ABUS) is an emerging technology that has been developed to overcome the challenges of hand-held ultrasound (HHUS) and thereby to improve the availability of supplemental screening US in women with dense breasts.

Several methods have been developed for the assessment of mammographic breast density, which include visual, semi- or fully automated approaches. Visual, qualitative methods are based on human judgement and are therefore subjective; inter-observer variability can be significant among radiologists, whereas automated approach provides measurement of area-based or volumetric parameters, that is less subjective and more consistent.

ABUS is based on automated scanning of a large portion of the breast and the ability to convert 2D images to high quality multiplanar 3D reconstructed planes. This provides more reliable and reproducible imaging, with global visualization of the entirety of the breast, allowing the radiologist to interpret the data obtained by technologists. Meanwhile, virtual review of data sets enables batch reading, double reading and storage of volumes which allows to compare examinations with priors, that is expected to improve specificity in follow-up examinations and to decrease biopsy rate of benign lesions. In order to improve the utility of ABUS into screening workflow a software upgrade is needed to decrease the time necessary to acquire the acquisitions, to transmit the images and to retrieve prior ones from PACS.

Multiple studies that compared the performance of ABUS technology in breast cancer detection has shown similar results to handheld ultrasound (HHUS) studies and in some instances ABUS appeared to be superior to HHUS, especially in the context of architectural distortion identified in the coronal reconstruction plane.

As more data becomes available on breast density, automated breast ultrasound systems ("ABUS") are seeing wider acceptance in breast screening.

Several research articles have demonstrated it to be a significant contributor in the detection of cancers not visible on mammography or digital breast tomosynthesis (DBT). However, reviewing of ABUS cases is time-consuming. To improve reading time, a computer-aided detection (CAD) software for ABUS ("QVCAD") was developed and has received CE mark approval. A reader study has shown this new technology has the potential to improve the reading time with no loss in diagnostic accuracy. There has been an average of 33% improved reading time among 18 radiologists in this study. These results conclude that the use of the concurrent-read QVCAD system for interpretation of screening ABUS studies of women with dense breast tissue makes interpretation significantly faster and produce non-inferior diagnostic accuracy compared to that of unaided conventional ABUS reading.

Several studies have evaluated the potential role of ABUS for breast density measurement on the basis of its three dimensional prospective, but incorporation of such techniques into clinical practice remains investigational.

Recently we explored the utility of Radiomic ABUS signature in the differentiation of benign from malignant breast lesions. This retrospective study included a total of 77 patients (all females) with biopsy proven lesions. Our results showed that the radiomic signature obtained from ABUS images is a promising tool in differentiating benign from malignant breast lesions, concluding that the automatic classification of these lesions could be successfully implemented using a radiomic signature extracted from ABUS images.

The integration of elastography combined with automated breast volume scanner (ABVS) needs further investigation. A study analyzed the inter-examiner reliability of ABVS and UE, and compared the diagnostic performance among ABVS, UE, and the combination of these two methods. Their results demonstrated substantial inter-examiner reliability with high diagnostic performance for differentiation of benign and malignant lesions in the breast. This implies that the combination of ABVS and UE seems to be a tool in the differentiation between benign from malignant lesions.

Novel developments in automated breast ultrasound

Establishment of an ABUS training program for radiologists and technicians that will provide adequate training in acquiring and interpreting 3D breast volumes data obtained by ABUS will potentially improve the sensitivity, specificity and will reduce the false negative rate.

ABBREVIATIONS

ABUS - Three-dimensional automated breast sonography
HHUS - Hand-held ultrasound
DBT - Digital breast tomosynthesis
ABVS - Automated breast volume scanner
(UE) - Elastography US

TAKE HOME POINTS

ABUS is an efficient, reproducible and comprehensive technique for supplemental breast screening. Novel developments of ABUS will help increase the sensitivity and specificity and will lead to more accurate diagnosis of cancers.

References

1. Alonzo-Proulx O, Mawdsley GE, Patrie JT, Yaffe MJ, Harvey JA (2015) Reliability of automated breast density measurements. *Radiology* 275:366-376.
2. Ekpo EU, McEntee MF (2014) Measurement of breast density with digital breast tomosynthesis—a systematic review. *Br J Radiol* 87:20140460
3. Destounis S, Arieno A, Morgan R, Roberts C, Chan A. (2017) Qualitative Versus Quantitative Mammographic Breast Density Assessment: Applications for the US and Abroad. *Diagnostics (Basel)*
4. Vourtsis A, Kachulis A (2018) The performance of 3D ABUS 815 versus HHUS in the visualisation and BI-RADS characterisation 816 of breast lesions in a large cohort of 1,886 women. *Eur Radiol* 28: 817 592-601.
5. Highnam R, Brady M, Yaffe MJ, Karssemeijer N. Robust breast composition measurements -Volpara. In proceeding of the digital mammography:10thInternational workshop IWDM 2010, Girona, Catalonia, Spain, 16-18 June 2010; Marti J, Oliver A, Freixenet J, Marti R. eds. Springer: Berlin/Heidelberg, Germany 2010; pp. 342-349.
6. Xu et al. (2014) Combined use of the automated breast volume scanner and the US elastography for the differentiation of benign from malignant lesions of the breast. *BMC Cancer*:14:798.
7. Yulei Jiang et al. (2018) Interpretation time using a concurrent read computer-aided detection system for automated breast ultrasound in breast cancer screening of women with dense breast tissue. *AJR*; 211:1-10.
8. Vourtsis A, Berg WA. (2018) Breast density implications and supplemental screening. *European Radiology*. Under Press.
9. Papanikolaou N. et al. (2018) The performance of Radiomic ABUS signature in the differentiation of benign from malignant breast lesions. *EUSOBI annual meeting 2018, Athens Greece*.

ULTRASOUND

Ultrasound in the axilla

F. Kilburn-Toppin; Cambridge/UK

BODY

Evaluation of regional lymph node status is important for staging, treatment planning and prognosis in breast cancer patients. Pre-operative axillary ultrasound and ultrasound-guided biopsy are routinely used to detect nodal metastases, allowing patients to proceed directly to axillary lymph node dissection thereby avoiding sentinel lymph node biopsy. However, following recent clinical trials and with improvement in systemic and radiation therapies, the role of staging sonography has been questioned. In this lecture, the current role of axillary staging will be reviewed, the impact of nodal status on treatment planning discussed, and the future for nodal staging in the advent of evolving surgical management of the axilla and a trend towards less aggressive surgery will be considered.

TAKE HOME POINTS

- There remains an important clinical role in staging of the axilla using US with selective US-guided needle biopsy.
- US can help discriminate between minimal versus advanced nodal metastatic involvement, which is important for axillary surgical planning.
- Contrast enhanced US can improve detection of the sentinel node.

Applications for CEUS

A. Athanasiou; Athens/GR

BODY

Tumor neovascularization is one of the hallmarks of cancer. Based on this statement, Dynamic Contrast Enhanced breast MRI DCE-MRI and, more recently, Contrast Enhanced Spectral Mammography CESM have been of increasing diagnostic value in breast imaging.

Use of contrast agents in breast ultrasound dates back on late 90's, however due to initial inherent technical issues, they were not widely administered in clinical practice. These contrast agents were essentially microbubbles acting as echo-enhancers and technical challenges as stability, strong enhancement and reflectivity on B-mode had to be resolved.

US-contrast agents resonate in specific low frequencies depending on the diameter of the microbubbles. Combining an optimal resonance with a diagnostic quality B-mode imaging is not easy; this issue has been resolved by using the so-called Second Harmonic Imaging. The main resonance frequency is not the only resonance frequency of the bubble itself and multiple frequencies of the fundamental one are emitted. Of those harmonic frequencies, the second one, known as the second harmonic, is strong enough to be used for diagnostic purposes. The theoretical advantage of the harmonic over the fundamental frequency is that only contrast agent microbubbles resonate with harmonic frequencies, while adjacent tissues do not resonate, or else their harmonic resonance is very little. Thus, using this setting, it will be possible to show the contrast agent only, without any artifact from the surrounding anatomical structures and with a markedly improved signal-to-noise ratio.

Once technical issues resolved, clinical applications of CEUS included:

- Differentiation of benign and malignant focal breast lesions
- Predictive information on malignant lesions through correlation of hemodynamics of CEUS and molecular subtypes of breast cancer
- Early prediction of response to Neoadjuvant Treatment

- Preoperative sentinel lymph node identification, localization and biopsy
- Diagnostic aid on detection and characterization of non-mass breast lesions.

Given the wide availability and cost-effectiveness of US, CEUS has a great potential in evaluating tumor neoangiogenesis in every-day clinical practice

TAKE HOME POINTS

- CEUS provides information on tumor neoangiogenesis by taking advantage of specific microbubble contrast agents resonance
- Second Harmonic Frequency allows both Contrast detection and Diagnostic information
- Multiple clinical applications are currently encountered
- CEUS could potentially provide not only diagnostic but also predictive/prognostic information on breast cancer

References

1. Sridharan A, Eisenbrey JR, Dave JK, Forsberg F. Quantitative Nonlinear Contrast-Enhanced Ultrasound of the Breast. *AJR Am J Roentgenol.* 2016 Aug;207(2):274-81
2. Li CY, Gong HY, Ling LJ et al. Diagnostic performance of contrast-enhanced ultrasound and enhanced magnetic resonance for breast nodules. *J Biomed Res.* 2018 Jun 1;32(3):198-207.
3. Zhang W, Xiao X, Xu X et al. Non-Mass Breast Lesions on Ultrasound: Feature Exploration and Multimode Ultrasonic Diagnosis. *Ultrasound Med Biol.* 2018 Aug;44(8):1703-1711
4. Saracco A, Szabó BK, Tánczos E et al. Contrast-enhanced ultrasound (CEUS) in assessing early response among patients with invasive breast cancer undergoing neoadjuvant chemotherapy. *Acta Radiol.* 2017 Apr;58(4):394-402.
5. Du R, Zhang H, Shu W et al. Correlation between Ki-67 Expression and Hemodynamics of Contrast-Enhanced Ultrasound in Patients with Breast Infiltrative Ductal Carcinoma. *Am Surg.* 2018 Jun 1;84(6):856-861.
6. Nielsen Moody A, Bull J et al. Preoperative sentinel lymph node identification, biopsy and localisation using contrast enhanced ultrasound (CEUS) in patients with breast cancer: a systematic review and meta-analysis. *Clin Radiol.* 2017 Nov;72(11):959-971

MRI TRENDING TOPICS

Overview on GD controversy

V.M. Runge; Bern/CH

BODY

The gadolinium chelates (the GBCAs) are critical to disease diagnosis by MR, indeed to clinical medicine worldwide, and have proven to be overall a very safe class of contrast media. This review focuses on the current knowledge regarding accumulation of gadolinium in the brain (dentate nucleus and other structures) and body, with clinical recommendations based on that and other safety data, including discussion of the European Medicines Agency (EMA) ruling.

The established class of intravenous contrast media for magnetic resonance imaging is the gadolinium chelates, often referred to as the gadolinium-based contrast agents (GBCAs). These can be differentiated on the basis of stability in vivo, with safety and tolerability of the GBCAs dependent fundamentally on chemical and biologic inertness. This review discusses first the background in terms of development of these agents and early safety discussions (including hypersensitivity/allergic reactions), and second their relative stability based both on in vitro studies and clinical observations before and including the advent of nephrogenic systemic fibrosis (NSF). This sets the stage for the focus of the review, the current knowledge regarding accumulation of gadolinium in the brain and body, and specifically the dentate nucleus after intravenous administration of the GBCAs and differentiation amongst agents on this basis.

"The gadolinium chelates (the GBCAs) are critical to disease diagnosis by MR, indeed to clinical medicine worldwide, and have proven to be overall a very safe class of contrast media." However, the information available to date, from the initial conception of these agents in 1981 to the latest reports concerning safety, reveals a major difference between the macrocyclic and linear chelates. Specifically, Omniscan, OptiMark, Magnevist, MultiHance and Primovist/Eovist (all being linear gadolinium chelates) are now known to be associated with dentate nucleus hyperintensity, specifically high signal intensity within the dentate nucleus on T1-weighted scans seen pre-contrast after multiple prior contrast injections. Dotarem,

Gadovist and ProHance, the macrocyclic chelates, are not so associated. Dentate nucleus hyperintensity is likely to reflect more general gadolinium deposition throughout the body (and specifically in the skin and bones), in these patients with normal renal function. In patients receiving a very high number of injections of the linear agents, hyperintensity is also observed in many other nuclei and structures within the brain. Initial reports suggest possible clinical symptomatology. The European Commission ruled in November 2017 to suspend the whole body marketing authorizations of the multi-purpose linear GBCAs (Omniscan, OptiMark, Magnevist, MultiHance). The approval for the macrocyclic (Gadovist, ProHance, Dotarem) agents remains unchanged, with continued approval - at this time, for special indications - three linear GBCAs (Primovist and MultiHance specifically for delayed liver imaging only and Magnevist 2 mmol/L for intra-articular use). This followed the March 10, 2017 recommendation of the Pharmacovigilance and Risk Assessment Committee (PRAC) of the European Medicines Agency (the equivalent of the FDA in Europe). Cited in the report was convincing evidence of gadolinium deposition in the brain months after injection of the linear agents. These recommendations were based on an extensive review of the safety of the gadolinium agents that began in March 2016.

TAKE HOME POINTS

- The whole body marketing authorizations of the multi-purpose IV linear MR contrast agents (Omniscan, OptiMark, Magnevist and MultiHance) have been suspended by the European Commission.
- The approval for the macrocyclic agents (Gadovist, ProHance and Dotarem) remains unchanged.
- Primovist and MultiHance remain approved for delayed liver imaging only.

Breast MRI and CESM: Competition or cooperation?

F. Sardanelli; Milan/IT

BODY

Breast MRI gained a screening and diagnostic role all over the world in the last two decades. According a EUSOBI survey [1], common indications included cancer staging, treatment monitoring, high-risk screening and problem-solving, but only one third of the respondents performs MR-guided interventions. Notwithstanding the endless debate on preoperative MRI, breast MRI is surely the third breast imaging technique after mammography and ultrasound and its performance is an option in all highly qualified breast cancer all over the world. This role is supported by a vast research effort, shown by the number of papers retrievable from the PubMed in 2011-2017 for 'breast MRI' (5,835, i.e. 834/year) to be compared with those for 'mammography' (9,503, i.e. 1358/year) and those for 'breast ultrasound' (5,227, i.e. 747/year). Conversely, less than 100 papers can be found overall up to April 29, 2018 for 'contrast-enhanced (spectral or dual-energy) mammography'. Thus, contrast-enhanced mammography (CESM, CEDM, or CEM) is still in its infancy.

To summarize the current evidence in the literature, one can say that it has similar sensitivity and specificity to MRI and has advantages in terms of cost, patient acceptability, and examination time [2]. This general statement has a physiological basis in a similar two-compartment (vascular/interstitial) pharmacokinetics of gadolinium-based contrast agents (GBCAs) and of iodinated contrast agents (ICS), even though a higher contrast power of the former has been shown in past studied comparing CE-MRI with CE-CT in several body parts.

An early meta-analysis [3] reported for CESM a pooled sensitivity of 0.98 (95% CI 0.96-1.00) from 8 studies and a pooled specificity of 0.58 (95% CI 0.38-0.77) from six studies but noted that those studies reported selected case series, i.e. they were prone to selection bias. More recent studies showed higher CESM specificities [4]. A learning curve is most probably acting on CESM interpretation. In addition, we should consider that BI-RADS-like descriptors and diagnostic categories were not still applied to CESM.

When comparing CE-MRI and CESM, we should consider first is a multi-slice three-dimensional (3D) imaging technique while CESM is a two-dimensional (2D) approach, even though performed as a two-view technique. In addition, the following ten considerations should be applied:

1. CE-MRI offers dynamic information, CESM does not (but the implementation of abbreviated CE-MRI protocols showed that dynamics is not relevant, at least for detection);
2. MRI can offer other information (e.g., T2-weighted imaging; diffusion-weighted imaging), not available from CESM;
3. MRI is radiation-free, CESM does not (but the dose is increased by 0.9 mGy and 0.5 mGy compared with 2D mammography and tomosynthesis, respectively, and remains below the dose limit of 3 mGy set by the USA Mammography Quality Standards Act [5];
4. MRI has contraindications such as claustrophobia and those due to magnetic field and radiofrequency pulses that do not contraindicate CESM;
5. CESM has important limitations (image artifacts) in the case of breast implants;
6. Being CESM an option for most mammographic units now commercially available, in the next future its access could become larger and easier than that to breast MRI;
7. CESM examination time (8-10 min) is lower than that of a full CE-MRI protocol (20-25 min), but not than that of abbreviated MRI protocols;
8. Patients acceptance for CESM has been reported to be higher than that for CE-MRI, if sensitivity is equal [6];
9. GBCAs and ICS have the same contraindications in the case of renal failure but accumulation in the brain has been reported only for the latter; however, GBCAs have a rate of acute adverse reactions lower than that of ICS;
10. Cost of CESM is lower than that of MRI, with a ratio approximately ranging from 1:2 to 1:10.

On this basis, in the next future MRI and CESM could cooperate for a better patient care. Contrast-enhanced breast imaging will expand its screening and diagnostic role with a remix of indications and double-option in specific clinical conditions. A possible scenario is the following:

Breast MRI and CEM: Competition or cooperation?

1. Contraindications to breast MRI: CEM;
2. Patients with breast implants: MRI and/or CE-MRI;
3. High-risk screening (BRCA, P53 mutation carriers, strong family history): CE-MRI, avoiding ionizing radiation exposure as much as possible [7];
4. Intermediate risk screening, if additional CE imaging is required: CEM;
5. Preoperative staging: CE-MRI or CEM (CE-MRI should be preferred if the relation between tumor and pectoral muscle/thoracic wall has to be investigated);
6. Monitoring neoadjuvant therapy: CE-MRI or CEM;
7. Search for occult primary breast cancer: CEM or CE-MRI;
8. Unresolved doubts after tomosynthesis and ultrasound, including cases recalled from screening: CEM or CE-MRI;
9. Prognostic breast cancer imaging: CE-MRI;
10. Contraindications to GBCAs: CEM; contraindications to ICS: CE-MRI.

In general, when CEM can be used as a substitute for CE-MRI, the former can be favored by easier access, lower cost, and higher women preference. Finally, the current lack of commercially available CEM guidance systems for intervention should be considered a limitation of CEM (but targeted ultrasound should solve the majority of cases). Conversely, the future availability of CEM guidance for interventions could solve the hot topic of lack of access to facilities able to perform MR-guided interventions. Contrast-enhanced tomosynthesis has the potential to become a 3D contrast-enhanced clinical tool but is still in a preliminary phase [8]: the dose issue has to be fully addressed and the additional value to CEM remains to be investigated.

TAKE HOME POINTS

- CEM and MRI seem to have similar sensitivity and specificity
- In the following indications, MRI should be preferred: patients with breast implants; high-risk screening; preoperative, when relations to

pectoral muscle/thoracic wall has to be studied; contraindications to ICS; prognostic imaging

- In the following indications, CEM should be preferred: contraindications to MRI; contraindications to GBCAs; intermediate risk screening, if additional CE imaging is required
- In the following indications, either CE-MRI or CEM can be performed: preoperative staging; monitoring neoadjuvant therapy; search for occult primary breast cancer; unresolved doubts after tomosynthesis and ultrasound

References

1. Clauser P, Mann R, Athanasiou A, et al. A survey by the European Society of Breast Imaging on the utilisation of breast MRI in clinical practice. *Eur Radiol*. 2018;28:1909-1918.
2. Lewin J. Comparison of contrast-enhanced mammography and contrast-enhanced breast MR imaging. *Magn Reson Imaging Clin N Am* 2018;26:259-263.
3. Tagliafico AS, Bignotti B, Rossi F, et al. Diagnostic performance of contrast-enhanced spectral mammography: Systematic review and meta-analysis. *Breast* 2016;28:13-19.
4. Sardanelli F, Fallenberg EM, Clauser P, et al; European Society of Breast Imaging (EUSOBI), with language review by Europa Donna-The European Breast Cancer Coalition. *Mammography: an update of the EUSOBI recommendations on information for women. Insights Imaging* 2017;8:11-18.
5. James JR, Pavlicek W, Hanson JA, Boltz TF, Patel BK. Breast Radiation Dose With CEM Compared With 2D FFDM and 3D Tomosynthesis Mammography. *AJR Am J Roentgenol* 2017;208:362-372.
6. Phillips J, Miller MM, Mehta TS, et al. Contrast-enhanced spectral mammography (CEM) versus MRI in the high-risk screening setting: patient preferences and attitudes. *Clin Imaging* 2017;42:193-197.
7. Colin C, Foray N, Di Leo G, Sardanelli F. Radiation induced breast cancer risk in BRCA mutation carriers from low-dose radiological exposures: a systematic review. *Radioprotection* 2017; 52: 231-240.
8. Chou CP, Lewin JM, Chiang CL, et al. Clinical evaluation of contrast-enhanced digital mammography and contrast enhanced tomosynthesis--Comparison to contrast-enhanced breast MRI. *Eur J Radiol* 2015;84:2501-2508

Current applications of MR-Diffusion

S. Vinnicombe; Cheltenham/UK

BODY

Diffusion-weighted magnetic resonance imaging (DWI) utilises motion-probing sequences to explore the diffusivity of water molecules within tissues, which can be quantified through measurement of various parameters, most commonly the apparent diffusion coefficient (ADC). Random Brownian motion of water in vivo is restricted by multiple structures such as cell membranes and macromolecules, thus the ADC reflects tissue cellularity, microstructure, and membrane integrity. Broadly, greater cellular density within malignant neoplasms results in a condition of restricted diffusion compared with normal or benign lesions and this feature has resulted in DWI becoming a fundamental technique in oncological imaging. Recent technical advances mean that robust DWI of both breasts can now be obtained in a few minutes, without the need for administration of intravenous contrast.

To date, DWI has mostly been used as a supplemental sequence to increase the specificity of standard dynamic contrast-enhanced MRI (DCE-MRI), with the potential to decrease the number of MRI-guided biopsies. There is evidence to suggest that specificity can be further improved through the use of non-Gaussian models of diffusion such as diffusion kurtosis imaging (DKI). Furthermore, as it reflects features such as cellularity, DWI can be regarded as a biomarker of tumour subtype and aggressivity. There is increasing interest in the role of DWI, in combination with a T2W sequence, as a stand-alone technique not only for lesion characterisation, but also for screening. Finally, DWI can be used to identify early response to neoadjuvant therapy, since the ADC can alter before any change in tumour size, and it may improve the accuracy of MRI in the identification of pathological complete response to therapy, with important implications for patient management.

TAKE HOME POINTS

- DWI reflects the diffusivity of water molecules within normal and abnormal tissues
- It is a quantifiable imaging biomarker of tissue complexity and microstructure that can be quickly and readily obtained without the need for

exogenous intravenous contrast

- DWI can improve breast lesion characterisation and can increase the specificity of DCE-MRI
- DWI can be used as a biomarker of breast tumour chemosensitivity
- Technological advances mean that DWI could potentially be used as a screening modality in the future

MRI TRENDING TOPICS

Do we need quality control in breast MRI?

R.M. Mann; Nijmegen/NL

BODY

Breast MRI has emerged as a key modality in the screening for and evaluation of breast cancer in the last decades. Several practice guidelines, such as the EUSOBI MRI guideline, have been in place for about 10 years, in order to harmonize the quality and use of breast MRI among clinical sites throughout the world. While these guidelines are nowadays, based upon citation indexes and general response, widely accepted by the breast imaging community both the applied imaging techniques and use are still highly variable from site to site. It should also be noted that the existing practice guidelines focus mostly on dynamic contrast enhanced breast MRI and little more than acknowledge the existence of other non-contrast medium based techniques. It appears essential that technical parameters match existing guidelines and are checked on a regular basis. For newer techniques consensus statements on technical performance and evaluation are still required.

While for the performance of breast MRI as a staging examination no clear quality control tools are available, the 2013 breast imaging reporting and data system (BI-RADS) provides benchmark parameters for breast MRI as a screening tool.

These include cancer detection rate, sensitivity, specificity and percentage of small and node negative cancers. The set thresholds are relatively low, and appear manageable, although obviously the parameters are dependent on the screened population, the frequency of screening and the concurrent use of other modalities. While it is important to check once own practice against said standards, it should be noted that this is mainly a numerical exercise that does not require re-evaluation of images.

However, similar to mammography screening, it might be wise to regularly check performance by re-evaluating actual studies. Especially since almost half of screen detected cancers would in retrospect be classified as birads 3 or higher on previous MRI examinations that were actually reported to be negative. Likewise, revision of pre-operative MRI's might lead to improved evaluation, especially for cases

with a clear radiological-pathological discrepancy. It should be noted, however, that pathology can not directly be used as an independent gold standard as the pathological evaluation is also subject to strong interreader variability. Consequently, review needs to be performed in conjunction with pathological review. While there is in the absence of this type of recommendations for breast MRI no direct evidence that this will improve the practice, similar guidelines for mammography have shown to reduce recall rates while boosting cancer detection. Consequently, it appears that a window for improvement is available by simple regular re-evaluation of images that should go beyond checking the image quality and give specific attention to cases with discordant or unfavorable clinical results.

TAKE HOME POINTS

- Technical evaluation of image sequences is mandatory, albeit not for all sequences clear recommendations are available
- Performance measures for pre-operative MRI are lacking, but some benchmark criteria for MRI as a screening tool are available
- Regular re-evaluation of discordant cases, including false negative and false positive screening examinations and cases with a unfavorable clinical outcome may improve clinical practice

EUSOBI AWARD FOR THE MOST QUOTED BREAST IMAGING PAPER PUBLISHED IN EUROPEAN RADIOLOGY IN 2015

Breast MRI: EUSOBI recommendations for women's information

Mann, R.M., Balleyguier, C., Baltzer, P.A. et al. Eur Radiol (2015) 25: 3669.
<https://doi.org/10.1007/s00330-015-3807-z>

BODY

This paper summarizes information about breast MRI to be provided to women and referring physicians. After listing contraindications, procedure details are described, stressing the need for correct scheduling and not moving during the examination. The structured report including BI-RADS® categories and further actions after a breast MRI examination are discussed. Breast MRI is a very sensitive modality, significantly improving screening in high-risk women. It also has a role in clinical diagnosis, problem solving, and staging, impacting on patient management. However, it is not a perfect test, and occasionally breast cancers can be missed. Therefore, clinical and other imaging findings (from mammography/ultrasound) should also be considered. Conversely, MRI may detect lesions not visible on other imaging modalities turning out to be benign (false positives). These risks should be discussed with women before a breast MRI is requested/performed. Because breast MRI drawbacks depend upon the indication for the examination, basic information for the most important breast MRI indications is presented. Seventeen notes and five frequently asked questions formulated for use as direct communication to women are provided. The text was reviewed by Europa Donna–The European Breast Cancer Coalition to ensure that it can be easily understood by women undergoing MRI.

KEY POINTS

- Information on breast MRI concerns advantages/disadvantages and preparation to the examination
- Claustrophobia, implantable devices, allergic predisposition, and renal function should be checked
- Before menopause, scheduling on day 7–14 of the cycle is preferred
- During the examination, it is highly important that the patient keeps still
- Availability of prior examinations improves accuracy of breast MRI interpretation

BREAST RADIOLOGIST AS THERAPIST

Minimal invasive ablation

F. Pediconi; Rome/IT

BODY

Surgical treatment of breast cancer has changed overtime, evolving from radical mastectomy to more conservative approaches. This has been possible thanks to technical advantages in the field of diagnostic imaging that allowed early diagnosis of breast cancers with very small dimensions.

Mini-invasive technologies (radiofrequency ablation, cryoablation, etc.) can preserve the original breast volume avoiding glandular resections and surgical scars and ensuring at the same time complete tumor ablation.

Ablation with high-intensity focused ultrasound (HIFU) is based on the use of an extra-corporeal ultrasound transducer that selectively destroys target tissue avoiding thermal damages to surrounding structures. The technique can be performed under ultrasound or magnetic resonance (MR) guidance.

MR guidance offers several advantages that improve safety and efficacy of the procedure: a visualization of the planned US beam during each phase of the procedure, a real-time monitoring of the progressive temperature increase within the target tissue and surrounding tissues, an accurate treatment planning, an evaluation of the treatment efficacy thanks to the use of intravenous gadolinium-based contrast agent.

TAKE HOME POINTS

Mini-invasive ablation of breast cancer are new and promising techniques that deserve large interest in the field of clinical research in order of its potential application in the clinical practice in the future.

BREAST RADIOLOGIST AS THERAPIST

Minimal invasive excision N.M. Abdel Razek; Giza/EG

BODY

Studies have shown that the combination of a physical examination, radiographic imaging and histopathological confirmation, also referred to as "the triple-test," can produce accuracy levels of over 90% when all three components are concordant for benign or malignant disease (Singhal, 2008). A number of well-designed studies have demonstrated the safety and clinical utility of minimally invasive breast biopsy methods relative to open surgical biopsy. Advantages include less discomfort for the patient, a reduction in scarring and cosmetic defect, less invasive procedure, and quicker patient recovery.

BLES (breast lesion excision system) & VAB (vacuum assisted biopsy) are two advanced automated large needle breast biopsy methods. VAB is done using a percutaneous device developed specifically for breast biopsy. It is a sort of advanced large core needle biopsy. It utilizes vacuum assistance coupled with a high speed rotating cutter to acquire tissue samples.

The BLES is combined Radiofrequency and suction, allows complete excision of the breast tissue under ultrasound or mammography guidance as one piece. Allows excision of the entire breast mass or suspicious area as an intact complete mass may be with safety margin.

Therapeutic Indications of Large needle procedures include Resection of Image evidence of Benign Lesions (if surgery is not preferred) including Fibroadenomas or Lipomas, Complex Cysts, Intraductal Vegetations, Papilloma, Hematomas, Scars

Advantages: No hospitalization, done under local anesthesia, better targeting, small Incision, no sutures, no scar, Short duration of procedure, poor side effects and the patient can resume normal activity immediately after the procedure.

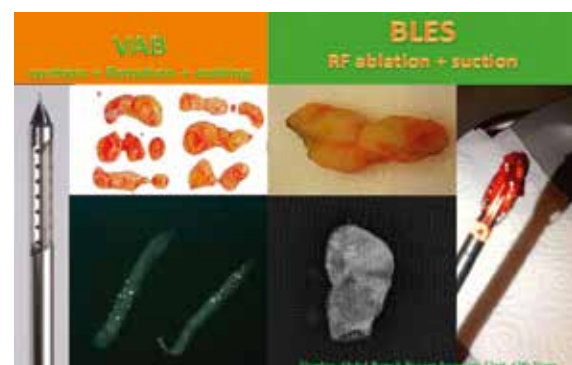
BLES & VAB are used as the primary method for histopathology diagnosis of suspicious small & borderline lesions as well as the unclassified microcalcifications.

There are some limitations to BLES including; lactating females, patients with breast implants and

patients presenting with a lesion close to the skin or in the axillary tail.

BLES is favored in high risk lesions & DCIS considering the relative high underestimation rate associated with VAB and not found with the BLES. Moreover BLES offers complete lesion removal with available margin evaluation.

US guided HIFU in patients with breast fibroadenoma has been previously demonstrated as effective method in reducing the volume and clinical symptoms of FA without serious side effects. US-guided VAB has been proved as an effective minimally invasive method in removing fibroadenomas but it was recommended not to exceed a size of 2.5 cm in order to avoid the complications of bleeding and large haematoma formation. Combined Ultrasound guided HIFU followed by VAB is an efficient well-tolerated non-invasive personalized two steps procedure for non-surgical complete excision of large fibroadenoma. Preliminary results are encouraging and show that the combined HIFU & VAB could be an alternative to surgery for large breast fibroadenoma.



difference between VAB & BLES

TAKE HOME POINTS

BLES (breast lesion excision system) & VAB (vacuum assisted biopsy) are two advanced automated large needle breast biopsy methods. VAB is done using a percutaneous device developed specifically for breast biopsy. It is a sort of advanced large core needle biopsy. It utilizes vacuum assistance coupled with a high speed rotating cutter to acquire tissue samples.

BREAST RADIOLOGIST AS THERAPIST

Can we avoid surgery after NAC?

J. Camps Herrero; Alzira/ES

BODY

Since the implementation of primary or neoadjuvant chemotherapy more than 40 years ago, surgeons and oncologists are wondering if surgery can be spared in those patients that respond well and achieve a pCR. Initially, more than 85-90% of patients treated with neoadjuvant chemotherapy had residual disease, but with the identification of tumor subtypes and development of targeted therapies, rates of pCR have dramatically increased and can be achieved in the 60% range, especially in HER2 positive / hormone receptor negative patients. Houssami showed in a 2012 meta-analysis that different breast cancer subtypes show different pCR rates. Routine surgery in the setting where most patients will obtain no potential benefit is of questionable value. The current proposed omission of surgery is part of the de-escalation strategy that evolved from the halstedian concept of radical surgery to breast conserving surgery, omission of axillary clearance and presently of sentinel lymph-node biopsies.

Of all the breast imaging techniques, breast MRI is the most accurate in response evaluation. Since the meta-analysis of 44 studies by Marinovich et al (2013), we know that breast MRI has a high sensitivity (correct detection of residual tumor) but shows heterogeneity in the estimates of specificity (correct identification of pCR). The highest NPV is achieved in HR negative/HER2 positive and triple negative cancers.

Given the limitations of MRI or conventional imaging techniques to detect pCR, researchers from the United States and Europe started feasibility studies to find out if the addition of accurate sampling of the tumor bed after neoadjuvant chemotherapy can improve the detection of patients that have achieved pCR with a sufficiently low FNR as to avoid surgery.

The present talk will focus on these ongoing trials, their results and the challenges that they pose for the breast radiologists, finally proposing a roadmap that encompasses the imaging techniques, the sampling techniques and the trial designs that will most likely benefit these patients.

TAKE HOME POINTS

- De-escalation of surgery in patients with a pCR after neoadjuvant chemotherapy is a current trend that needs a multidisciplinary approach
- The limitation of breast imaging techniques in the evaluation of response implies that accurate sampling with vacuum-assisted devices is most important
- This is a unique opportunity for radiologists to implicate themselves in the management of breast cancer patients as active stake-holders

EUSOBI 2018 GOLD MEDAL TO CHRISTIANE K. KUHL

Curriculum Vitae (extract)

CURRENT POSITION:

Professor (W3) of Radiology and Chairman of the Department of Diagnostic and Interventional Radiology, University Hospital of Aachen, University of Aachen, RWTH

PROFESSIONAL DEVELOPMENT

2010 – to date

Director and Department Chair, Department of Diagnostic and Interventional Radiology, RWTH Aachen

2012 – 2013

President of the Radiological Society of Northrhine Westphalia

2009

Call to the position of Full Professor and Department Chair, Department of Diagnostic and Interventional Radiology, University of Aachen, RWTH

2009 – 2010

Vice president, University of Bonn Rheinische Friedrich-Wilhelms-Universität Bonn (Prorektorin), International Affairs

2004 – 2010

Vice Chairman, Department of Radiology, University of Bonn

2004

Full Professor of Radiology, Endowed Chair for Diagnostic Imaging in Oncology and Interventional Oncology, University of Bonn, Department of Radiology

1999 – 2004

Assistant professor of Radiology, Department of Radiology, University of Bonn

CLINICAL TRAINING

2010

DEGIR certificate stage 4 (German Society of Interventional Radiology license to conduct and teach the entire range of interventional procedures).

2002

Board certification in Neuroradiology

2001 – 2002

Clinical training in Neuroradiological Interventions at the Department of Neuroradiology, Hospital of Duisburg, Germany

1999

Board certification in Radiology

1996 – 1997

Residency in Neurosurgery, Department of Neurosurgery, University of Bonn

1992 – 1999

Residency in Radiology, Department of Radiology, University of Bonn

01.07.1993

License as physician ("Approbation")

01.01.1992

Temporary license („Vorläufige Approbation")

CLINICAL FOCUS

1. Hepatobiliary imaging, Imaging in Oncology
2. Interventional Oncology: Percutaneous and transarterial treatment of cancer, including Radioembolisation, Chemoembolisation, Chemo-perfusion, Radiofrequency Ablation, Microwave Ablation, Irreversible Electroporation
3. MR imaging of breast and prostate
4. High Field MRI

OTHER QUALIFICATIONS

- Trainer for Interventional Radiology (German Society for Interventional Radiology)
- GCP-Training

UNIVERSITY EDUCATION

1985 – 1991

University degree: State Examination in Medicine, Rheinische Friedrich-Wilhelms-Universität Bonn

SCHOOL EDUCATION

1976 – 1985

High school Liebfrauenschule Bonn (Allgemeine Hochschulreife, Abitur)

1972 – 1976

Elementary School

RESEARCH DEVELOPMENT

2012 – to date

Research focus on prostate MRI

2009 – to date

Research focus on hepatobiliary MRI

Curriculum Vitae (Christiane K. Kuhl)

2006 – to date

Research focus on interventional oncology procedures

1994 – to date

Research focus on MR imaging diagnosis of breast cancer

2000 – 2009

Research focus on high field MRI and neuroradiology

2000

Habilitation and “venia legendi” (professorship and teaching license)

1993

awarded the academic degree of „doctor medicinae“ by the University of Bonn through the thesis „31P-MR-Spectroscopy: Systematic development of the method and clinical evaluation in patients with mitochondrial encephalomyopathies“ („summa cum laude“)

1992 – 1994

Research on 31P MR spectroscopy of neuro-muscular disorders

AWARDS

2018 Impact Award of the National Consortium of Breast Centers (NCoBC), USA

2015 Named „RWTH Fellow“

2015 Gold Medal of the International Society of Magnetic Resonance in Medicine

2008 Wachsmann-Preis (Award for Educational Excellence) of the German Radiological Society)

2007 Outstanding Teacher Award, Intl Society for Magnetic Resonance in Medicine

2004, 2006, 2008 “Best of ASCO”, American Society of Clinical Oncology

2006 Honorary Fellow, Breast Imaging Section, Royal College of Radiologist, UK

2006 European Magnetic Resonance Award

2004 ACRIN (American College of Radiology Imaging Network) Award

2003 Award of the German Radiological Society (Holthusen-Ring)

2000, 2001, 2002, 2011 RADIOLOGY Editor’s Recognition Award

2000 Award of the Ministry of Education and Research (BMBF)

2000 Highlight-Award of the German Radiological Society

EUSOBI 2018 GOLD MEDAL TO CHRISTIANE K. KUHL**DCIS in the era of MRI**

C.K. Kuhl; Aachen/DE

The pathophysiological basis of detectability of cancer on MRI is specifically interesting with regards to classification, and possibly management stratification, of DCIS. As we have shown, more than half of the high-grade DCIS are not associated with calcifications and, as such, will remain mammographically occult, but will indeed be associated with contrast enhancement, and thus be detectable, on MRI. Enhancement is also observed, but to a lesser extent, and less consistently, with intermediate and, even less frequently, with low grade DCIS. The fact that DCIS does produce contrast enhancement at all is actually remarkable, given the concept of DCIS as a disease that is confined to the milk duct epithelium, and shielded from the periductal space by the ductal basal membrane. Detectability on MRI indicates that a DCIS communicates with the world outside the milk duct lumen, and successfully initiates peri-ductal angiogenesis. It also indicates that the Gadolinium contrast agent – a large chelate molecule – is able to diffuse from the interstitium into the milk duct lumen. Such diffusion is not possible through a healthy ductal membrane, but requires a pathologically increased permeability of the ductal basal membrane – and, as such, serves as a biomarker for protease activity of that DCIS. Accordingly, presence or absence, or degree and kinetics of enhancement of a DCIS on MRI, in other words: a DCIS' MR imaging phenotype, will provide important functional information on a given DCIS' genomic toolbox, and on what from this toolbox is locally put to practice. As such, it will be important to investigate whether the MR imaging phenotype of DCIS is a predictor of the natural behavior of a DCIS, and could thus help determine an individual DCIS' need for treatment, in agreement with the aims of the current LORIS trial.

The fact that MRI can remain negative in about 20% of patients with mammography-positive, microcalcification-associated DCIS has been used to justify that MRI can only be used as a supplement to mammography, but not as a stand-alone screening method. With more recent understanding of the variable importance of breast cancer and its precursors, and its implications on overdiagnosis, it is time to realize that it may be prudent to reconsider

this; there is good reason to start trials that prospectively investigate whether use of MRI alone, i.e. without accompanying mammogram, is suitable to avoid overdiagnosis due to calcium-associated, low grade, and possibly more relevant: non-enhancing, DCIS. The superior detectability of DCIS, especially of therapeutically relevant, high grade DCIS or DCIS components also translates into improved treatment planning, i.e. lower positive margin rates.

KEY NOTE LECTURE

Ultrafast imaging and Super-resolution in Biomedical Ultrasound

M. Tanter; Paris/FR

BODY

In the last fifteen years, the introduction of plane or diverging wave transmissions rather than line by line scanning focused beams has broken the conventional barriers of ultrasound imaging. Imaging at several thousands of frames per second permits the advent of completely new ultrasound imaging modes, including shear wave elastography, stress imaging¹, ultrasensitive Doppler, and even neurofunctional ultrasound imaging of brain activity (fUltrasound)^{2,3}.

At ultrafast frame rates, it becomes possible to track in real time the transient vibrations – known as shear waves – propagating through organs. Such “human body seismology” provides quantitative maps of local tissue stiffness whose added value for diagnosis has been recently demonstrated in many fields of radiology (breast, prostate and liver cancer, cardiovascular imaging, ...). For blood flow imaging, ultrafast Doppler permits to detect very subtle blood flow in very small vessels without contrast agents.

Finally, if combined with 3 µm diameter microbubbles injections, ultrafast imaging provides a way to achieve Superresolution and in vivo non-invasive imaging at microscopic scales deep into organs by localizing the position of these millions of microbubbles at ultrafast frame rates. Such ultrasound localization microscopy technique solves for the first time the problem of in vivo imaging at microscopic scale of organs vasculature⁴.

References

1. Fernandez et al., *Nature*, 2015
2. Mace et al., *Nature Methods*, 2011
3. Osmanski et al, *Nature Comm.*, 2014
4. C. Errico et al, *Nature*, Nov. 2015

SHORT BIOGRAPHY OF PROFESSOR MICKAEL TANTER,

Research Professor of the French National Institute for Health and Medical Research, Institut Langevin, ESPCI, Paris France

Mickaël Tanter is the director of the Inserm laboratory “Wave Physics for Medicine” and deputy director of Langevin Institute at ESPCI, Paris, France. He is a world renowned expert in biomedical ultrasound and wave physics. He is the author of more than 300 peer-reviewed papers and book chapters and the recipient of 45 international patents. He co-invented several major innovations in Biomedical Ultrasound: Transient Elastography, Ultrafast Ultrasound and Shear Wave Elastography, functional Ultrasound imaging of brain activity and Super-resolution Ultrasound. He received many national and international distinctions (among them the Honored Lecture of the Radiology Society of North America in 2012, the Grand Prize of Medicine and Medical Research of Paris city in 2011 and the Grand Prize of Fondation de la Recherche Médicale in 2016). He was recently awarded a European Research Council (ERC) Advanced Grant to introduce fUltrasound imaging (functional imaging of brain activity) as a new full-fledged neuroimaging modality. M. Tanter is the co-founder of several MedTech companies in Biomedical Ultrasound (Supersonic Imagine, CardiaWave, Neuroflows). In 2006, he co-founded Supersonic Imagine, an innovative French company positioned in the field of medical ultrasound imaging that launched in 2009 a revolutionary Ultrafast Ultrasound imaging platform called Aixplorer™ with a unique real time shear wave imaging modality for cancer diagnosis (more than 1700 ultrafast scanners already sold worldwide).

Metastatic disease - Which patients need systemic staging I. Athanasiadis; Athens/GR

BODY

Restaging of patients with early breast cancer aiming to identification of latent metastatic disease has been dictated by specific well established guidelines. Patients are followed with regular scheduled office visits and patients are instructed to report new symptoms to their physician. Follow up includes regular office visits and a meticulous history and physical examination is the backbone of surveillance. Imaging restaging for asymptomatic patients is not indicated and unprovoked tests are strongly discouraged. patients should be tutored to appropriately report new symptoms and the physician should be alert to identify persisting minor new symptoms which will not be reported by the patient. Any new symptoms or physical findings will be analyzed and could instigate a diagnostic work up which can be detailed and focused to document latent metastatic disease. Computerized tomography or MRI are included and whenever progressive metastatic disease is demonstrated an image guided biopsy is encouraged to document and inform on the biology of progressive metastatic disease.

Patients with confirmed metastatic disease undergoing systemic therapy undergo scheduled imaging for restaging to confirm response in an objective way. There are no specific guidelines for restaging while on maintained response but clinical judgment and evolution of symptoms will determine the frequency of image restaging. In any case, symptoms should be discussed and analyzed appropriately.

An individualized risk based approach is encouraged and interpretation of imaging could be challenging and inconclusive in asymptomatic patients with metastatic disease, with a low positive predicted value in the specific clinical scenario. FDG-PET is strongly discouraged in patients with breast cancer but could be performed to answer cilinical questions when progression with accelerating disease is suspected. Overall, understanding the biology of the disease and applying clinical judgment and awareness will dictate restaging decisions in metastatic breast cancer.

METASTATIC DISEASE

Distant staging (CT, PET/CT and PET/MRI)

L. Moy; New York/US

INTRODUCTION

New hybrid imaging technology brings together the molecular sensitivity of positron emission tomography (PET), the high contrast anatomic imaging of magnetic resonance (MR), and the functional imaging capabilities of MR, in a single PET/MR exam. PET and MR each already play central roles in breast cancer imaging, MR predominantly as a local exam, screening for and evaluating the extent of disease pre- and post-therapy (1), and PET predominantly as a whole body exam, assessing for distant metastases both during initial staging and later surveillance (2-4). However, whole body MR imaging has also been employed in imaging metastatic spread (5,6). PET and MR images of the breast have been fused (7-10) in efforts to investigate potential benefits of combining these modalities. Now, PET/MR hybrid scanners, depending on the model, simultaneously or sequentially acquire and co-register PET and MR data. The aims of talk is to review the pros and cons of PET/MR whole body imaging compared to PET/CT in the setting of metastatic or suspected metastatic breast cancer.

WHOLE BODY PET/MRI

PET/MRI is particularly interesting as a possible improvement over PET/CT oncologic whole body imaging as MRI provides improves lesion detection in the brain, breast, liver, kidneys and bones as compared with CT. CT detects more pulmonary lesions, especially under 1cm (11, 12), though the clinical importance of pulmonary lesions missed on PET/MRI is still unclear (12).

In whole body imaging for breast cancer, PET/MR provided improved sensitivity over PET/CT (13-15) or PET alone, particularly for breast cancers (14), liver metastases (14) and bone metastases (13-15). PET/MRI also detected brain metastases (14).

When separated out by sequence, DCE-MRI has been shown to be most useful for breast and brain lesions, DWI has been shown to be most useful for liver and bone metastases, and PET has been shown to be most useful for lymph node metastases (14). These variable strengths highlight the advantage of multi-modality imaging. In particular, combining PET and

DWI may be important as PET has been shown to greatly improve the specificity of DWI in whole body imaging (16). In addition, omitting the whole body CT from the PET exam can decrease the radiation dose by half (14). These data suggest a wider role for PET/MRI in breast cancer staging and surveillance, particularly in young patients and in patients undergoing serial examinations.

REVIEW OF LITERATURE ON WHOLE BODY PET/MRI IN BREAST CANCER

PET/MRI, a whole body examination, requires an estimated dose of 9.3mSv on average (range 8.2-9.9mSv) (14) and provides high sensitivity in lymph nodes, bone, liver, and brain via its novel ability to acquire MR data concurrently with metabolic PET data. Early studies specifically in breast cancer patients typically compare PET/MRI with PET/CT and are encouraging, suggesting that replacing CT with MRI does provide some gains in the search for metastatic disease. In general, small studies consistently show that PET/MR detects the same or a few more systemic metastases than PET/CT or PET alone (17, 18). In assessing bone metastases, Catalano et al. (19), showed that PET/MRI found not only more osseous metastases, but also more osseous metastases in more patients as compared with PET/CT. One concern is that PET/MRI may miss lung metastases. Raad et al. demonstrated that while PET/MRI did miss small lung nodules in oncologic patients, 97% of the missed nodules were stable at follow-up, suggesting that the missed nodules may be clinically unimportant (12). Melsaether et al. found that PET/MRI detected liver, lymph node, bone, and brain metastases not seen on PET/CT. While some of these differences in detection were significant at the lesion level, none were reached significance at the patient level, likely because a larger study would be needed (14). Finally, Grueneisen et al. looked at PET/MR another way and, rather than comparing PET/MR to PET/CT, showed that adding PET to whole body MR increases sensitivity and overall accuracy in breast cancer patients (20). In that same vein, Heusner et al. demonstrated that adding PET to DWI greatly improves the specificity of DWI in whole body imaging (21).

Distant staging (CT, PET/CT and PET/MRI)

FUTURE DIRECTIONS PET/MRI

The next step for functional PET imaging is to accurately image the characteristics of breast cancer metastases. Primary breast cancers are heterogeneous, dynamic and have genomic instability (22). In the same way, metastases differ from their index lesion, from one another, and even from themselves over time, especially in response to treatments. Imaging with radio-ligands targeted to molecules that influence therapy would provide a way to non-invasively assess appropriateness of certain therapeutic agents and to reassess when treatment response appears to stall.

TARGETED PET RADIOTRACERS

Breast cancer biopsy and surgical specimens are commonly assessed histologically for estrogen and progesterone receptors and for human epidermal growth factor receptor 2 (HER2) because these receptors determine whether certain treatments can be effective. Tracers targeting steroid receptors are under development and include the estrogen analog 16a-18F-17B-estradiol (23), as well as fluorine labeled progesterone receptor ligands (24). Zirconium labeled human epidermal growth factor receptor 2 (HER2) receptor tracers including 89Zr-trastuzumab have also been developed (25,26). Recently, Ulaner et al showed that 89Zr-trastuzumab PET can detect HER2 positive metastases in patients with HER2 negative primary breast cancers (26). This study underlines how functional imaging of metastases, which typically aren't biopsied, can provide additional information and potentiate personalized treatment options. Further study may be able to establish standardized SUV levels that correlate to histologic levels of receptor expression and therapeutic efficacy. Future PET/MRI directions may ultimately include radiolabeled therapies coupled with dynamic PET imaging, which could enable the radiologist to see in real time whether therapeutic drugs are delivered to and retained within their targets.

TAKE HOME POINTS

- PET/MRI is a flexible hybrid technology which can be customized with any PET tracer or MR sequence. For localized breast PET/MR exams,

18F-FDG-PET and DCE-MRI data sets are typically acquired, often also with DWI.

- For whole body PET/MR exams in the setting of breast cancer, 18F-FDG-PET data is acquired with contrast-enhanced MRI, DWI and additional T2-weighted sequences.
- In whole body imaging, PET/MRI is more sensitive than PET/CT for lesion detection, especially for lesions in the bone, liver, and breast, and requires approximately half of the radiation required for PET/CT.

References

1. Lehman CD, Mahoney M, Newell M et al. for the American College of Radiology. *ACR Practice Parameter for the Performance of contrast-enhanced magnetic resonance imaging (MRI) of the breast*. Reston, VA: American College of Radiology; 2014.
2. Kamel EM, Wyss MT, Fehr MK, von Schulthess GK, Goerres GW. [18F]-Fluorodeoxyglucose positron emission tomography in patients with suspected recurrence of breast cancer. *J Cancer Res Clin Oncol* 2003;129:147-153.
3. Moon DH, Maddahi J, Silverman DH, Glaspy JA, Phelps ME, Hoh CK. Accuracy of whole-body fluorine-18-FDG PET for the detection of recurrent or metastatic breast carcinoma. *J Nucl Med* 1998;39:431-435.
4. Berg WA. *Nuclear Breast Imaging: Clinical Results and Future Directions*. *J Nucl Med*. 2016;57 Suppl 1:46S-52S.
5. Dietzel M, Zoubi R, Burmeister HP, Runnebaum IB, Kaiser WA, Baltzer PA. Combined staging at one stop using MR mammography: evaluation of an extended protocol to screen for distant metastasis in primary breast cancer – initial results and diagnostic accuracy in a prospective study. *Rofo*. 2012;184:618-23.
6. Sawicki LM, Grueneisen J, Schaarschmidt BM et al. Evaluation of ¹⁸F-FDG PET/MRI, ¹⁸F-FDG PET/CT, MRI, and CT in whole-body staging of recurrent breast cancer. *Eur J Radiol*. 2016;85:459-65.
7. Moy L, Noz ME, Maguire GQ Jr et al. Role of fusion of prone FDG-PET and magnetic resonance imaging of the breasts in the evaluation of breast cancer. *Breast J*. 2010;16:369-76.
8. Dmitriev ID, Loo CE, Vogel WV, Pengel KE, Gilhuijs KG. Fully automated deformable registration of breast DCE-MRI and PET/CT. *Phys Med Biol*. 2013;58:1221-33.
9. Atuegwu NC, Li X, Arlinghaus LR et al. Longitudinal, intermodality registration of quantitative breast PET and MRI

Distant staging (CT, PET/CT and PET/MRI)

- data acquired before and during neoadjuvant chemotherapy: preliminary results. *Med Phys.* 2014;41:052302-1-5
10. Bitencourt AG, Lima EN, Chojniak R et al. Can 18F-FDG PET improve the evaluation of suspicious breast lesions on MRI? *Eur J Radiol.* 2014;83:1381-6.
 11. Rauscher I, Eiber M, Fürst S et al. PET/MR imaging in the detection and characterization of pulmonary lesions: technical and diagnostic evaluation in comparison to PET/CT. *J Nucl Med.* 2014;55:724-9.
 12. Raad RA, Friedman KP, Heacock L, Ponzo F, Melsaether A, Chandarana H. Outcome of small lung nodules missed on hybrid PET/MRI in patients with primary malignancy. *J Magn Reson Imaging.* 2016;43:504-11.
 13. Sawicki LM, Grueneisen J, Schaarschmidt BM et al. Evaluation of ¹⁸F-FDG PET/MRI, ¹⁸F-FDG PET/CT, MRI, and CT in whole-body staging of recurrent breast cancer. *Eur J Radiol.* 2016;85:459-65.
 14. Melsaether AN, Raad RA, Pujara AC et al. Comparison of Whole-Body (18)F FDG PET/MR Imaging and Whole-Body (18)F FDG PET/CT in Terms of Lesion Detection and Radiation Dose in Patients with Breast Cancer. *Radiology.* 2016:151155. Epub ahead of print.
 15. Catalano OA, Nicolai E, Rosen BR et al. Comparison of CE-FDG-PET/CT with CE-FDG-PET/MR in the evaluation of osseous metastases in breast cancer patients. *Br J Cancer.* 2015;112:1452-60.
 16. Heusner TA, Kuemmel S, Koeninger A, et al. Diagnostic value of diffusion-weighted magnetic resonance imaging (DWI) compared to FDG PET/CT for whole-body breast cancer staging. *Eur J Nucl Med Mol Imaging.* 2010;37:1077-86.
 17. Pace L, Nicolai E, Luongo A et al. Comparison of whole-body PET/CT and PET/MRI in breast cancer patients: lesion detection and quantitation of 18F-deoxyglucose uptake in lesions and in normal organ tissues. *Eur J Radiol.* 2014;83(2):289-96.
 18. Taneja S, Jena A, Goel R, Sarin R, Kaul S. Simultaneous whole-body (1)(8)F-FDG PET-MRI in primary staging of breast cancer: a pilot study. *Eur J Radiol.* 2014;83(12):2231-9.
 19. Catalano OA, Nicolai E, Rosen BR et al. Comparison of CE-FDG-PET/CT with CE-FDG-PET/MR in the evaluation of osseous metastases in breast cancer patients. *Br J Cancer.* 2015;112:1452-60.
 20. Grueneisen J, Sawicki LM, Wetter A et al. Evaluation of PET and MR datasets in integrated 18F-FDG PET/MRI: A comparison of different MR sequences for whole-body restaging of breast cancer patients. *Eur J Radiol.* 2017;89:14-9.
 21. Heusner TA, Kuemmel S, Koeninger A, et al. Diagnostic value of diffusion-weighted magnetic resonance imaging (DWI) compared to FDG PET/CT for whole-body breast cancer staging. *Eur J Nucl Med Mol Imaging.* 2010;37:1077-86.
 22. Marino N, Woditschka S, Reed LT, Nakayama J, Mayer M, Wetzel M, Steeg PS. Breast cancer metastasis: issues for the personalization of its prevention and treatment. *Am J Pathol.* 2013 Oct;183(4):1084-95.
 23. Katzenellenbogen JA. Designing steroid receptor-based radiotracers to image breast and prostate tumors. *J Nucl Med.* 1995;36:85-135.
 24. Gemignani ML, Patil S, Seshan VE et al. Feasibility and predictability of perioperative PET and estrogen receptor ligand in patients with invasive breast cancer. *J Nucl Med.* 2013;54:1697-702.
 25. Dijkers EC, Oude Munnink TH, Kosterink JG et al. Biodistribution of ⁸⁹Zr-trastuzumab and PET imaging of HER2-positive lesions in patients with metastatic breast cancer. *Clin Pharmacol Ther.* 2010;87:586-92.
 26. Ulaner GA, Hyman DM, Ross DS, et al. Detection of HER2-positive metastases in patients with HER2-negative primary breast cancer using ⁸⁹Zr-trastuzumab PET/CT. *J Nucl Med.* 2016;57(10):1523-1528.

Whole body staging with MRI: DWI and beyond M. Dietzel; Erlangen/DE

BODY

Whole body MRI provides great advantages to breast imaging specialists and clinical oncologists. Different from PET and CT, MRI does not expose patients to ionizing radiation. This is particularly important for the management of breast cancer patients, for whom repeated measurements are anticipated. As a true multiparametric method MRI provides both exact anatomic and functional diagnostic information. This information can be used for initial staging, assessment of treatment response and has a significant impact patient management.

This talk will summarize

- the Technical principles
- Clinical application
- (Potential) future development

of whole body MRI.

TAKE HOME POINTS

- Different from PET and CT, whole body MRI does not expose patients to ionizing radiation.
- State of the art whole body MRI includes functional (DWI) and anatomic sequences.
- Whole body MRI provides exact diagnostic information for staging and assessment of treatment response.
- Future development will focus on standardized clinical workflows and patient outcome.

METASTATIC DISEASE

Interventional options in metastatic breast disease

D. Nörenberg; Munich/DE

BODY

In selected metastatic breast cancer patients image guided tumor therapies („minimal-invasive Oncology“) have evolved as alternative treatment options including their mentioning in international guidelines. The interventional Radiology toolbox includes local ablation techniques such as RFA, Microwave or CT-guided brachytherapy, or locoregional tumor treatments such as Y90-radioembolization (SIRT). Most recommendations and the according evidence point on patients with oligometastatic disease ideally after successful induction chemotherapy. In this lecture, current evidence for the appropriate patient selection as well as the according ablation techniques will be discussed.

FROM THE US SOCIETY OF BREAST IMAGING (SBI)

Breast Imaging in the Era of Value-Based Care

W.B. Demartini; Stanford/US

BODY

Many countries and healthcare systems are navigating transitions to value- over volume-based care practices. In general, value is defined as health outcomes achieved relative to associated costs. Value-based models emphasize and reward activities that measurably contribute to value by improving outcomes or decreasing costs, typically for specific diseases and for episodes-of-care. In radiology, activities that contribute value include using tests that have definitively been shown to improve patient outcomes, interpreting these tests with high accuracy, and generating reports that are clear and actionable. In breast imaging, there is a strong foundation in value-directed activities. These include using screening mammography that improves outcomes by decreasing breast cancer mortality, auditing diagnostic performance to measure and maintain accuracy, and generating reports using the American College of Radiology (ACR) Breast Imaging Reporting and Data System (BI-RADS). This talk will discuss key current and future considerations for breast imaging in leading value-based patient care.

AI (ARTIFICIAL INTELLIGENCE) – THE RISE OF THE MACHINES

Machine learning, deep learning and AI - Basics and principles primer

G. Langs; Vienna/AT

BODY

Artificial intelligence is changing the way imaging data is assessed and used for diagnosis and prognosis. Machine learning, an approach to train models by examples instead of designing rules by hand, is increasingly successful in detecting and quantifying even complex imaging markers with high reliability. Deep learning is a sub field of machine learning inspired by neural architectures and enabled by recent advances in hardware- and algorithm technology. In this primer, the basic building block of the most relevant techniques will be explained. The primer will give examples ranging from detection, to classification, and prediction based on imaging data. Methods will include supervised learning - models are trained based on labeled data - and unsupervised learning - models detect structure in large-scale unlabeled data. After discussing current methods, the primer will outline current limitations and challenges of the field.

TAKE HOME POINTS

- Supervised machine learning models are trained on labeled examples, model the relationship between input (e.g., image) and output (e.g., diagnosis), and can apply this model to new input data.
- Unsupervised machine learning trains models on data without labels, the resulting models capture structure in large populations, and are able to link a new subject to this population model.
- Recent methods, such as deep learning, are particularly effective in learning informative features from imaging data, and reach surprising accuracy and reliability. They can serve as a means to identify new markers.

AI (ARTIFICIAL INTELLIGENCE) – THE RISE OF THE MACHINES

'Omics and its integration in breast radiology K. Pinker-Domenig; Vienna/AT

BODY

Within the field of oncology, “omics” strategies – genomics, transcriptomics, proteomics, metabolomics – have many potential applications and may significantly improve our understanding of the underlying processes of cancer development and progression. “Omics” strategies aim to develop meaningful imaging biomarkers for breast cancer (BC) by rapid assessment of large datasets with different biological information. In BC the paradigm of “omics” technologies has always favored the integration of multiple layers of “omics” data to achieve a complete portrait of BC. Advances in medical imaging technologies, image analysis and the development of high-throughput methods that can extract and correlate multiple imaging parameters with “omics” data have ushered in a new direction in medical research. Radiogenomics is a new “omics” strategy that aims to correlate imaging characteristics (i.e. the imaging phenotype) with underlying gene expression patterns, gene mutations, and other genome-related characteristics. Radiogenomics not only represents the evolution of radiology-pathology correlation from the anatomical-histological level to the molecular level, but it is also a pivotal step in the “omics” paradigm in BC in order to fully characterize BC. Armed with modern analytical software tools, radiogenomics leads to new discoveries of quantitative and qualitative imaging biomarkers that bring hitherto unprecedented insights into the complex tumor biology and facilitate a deeper understanding of cancer development and progression. The field of radiogenomics in breast cancer is rapidly evolving, and results from previous studies are encouraging. It can be expected that radiogenomics will play an important role in the future and has the potential to revolutionize diagnosis, treatment and prognosis of BC patients. This presentation aims to give an overview of breast radiogenomics, its current role, future applications and challenges.

TAKE HOME POINTS

- Understand the principle of radiomics
- Realize the potential application in breast radiology
- Be aware of the challenges and limitations of “omics” strategies

AI (ARTIFICIAL INTELLIGENCE) – THE RISE OF THE MACHINES

Creating evidence instead of fake news

M. Barta; Truro/UK

BODY

Radiology has significantly changed over the last decades resulting in a large number of images to be reported. The literature is ever increasing, textbooks are often out of date and guidelines are struggling to keep up. New technologies are regularly emerging claiming results without clear evidence and patients are already requesting access to them. Practitioners are finding themselves in situations where there are no clear answers to every-day problems combined with financial pressure. The volume-based role of a reporting radiologist needs to change into providing higher quality service and improve patient outcome. We all must understand not just the basic concept of evidence-based medicine but also how to apply it in our own practice. We need to learn how to formulate our question, how to find answers. To be able to do this we have to understand the appropriate level of evidence, we need to critically appraise diagnostic studies, randomized controlled trials and systematic reviews. We then have to incorporate the findings into our practice.

TAKE HOME POINTS

- Understanding the need for EBP
- Formulating questions
- Appraising evidence
- Be critical and look for answers
- Incorporate EBM into your CPD

AI (ARTIFICIAL INTELLIGENCE) – THE RISE OF THE MACHINES

Is AI putting us out of work?

F.J. Gilbert; Cambridge/UK

BODY

Computer aided detection systems in mammography have been used extensively in USA following initial promising results and with reimbursement introduced in 2001. However more recently CAD has been shown to adversely affect some radiologists performance. This has resulted in some scepticism as to whether or not AI tools can really help radiologists in breast cancer screening. An ideal AI tool would be one where an examination can be dismissed with a high degree of certainty as containing no cancer allowing the radiologist to focus their efforts on those cases in which there was a high likelihood of significant disease. The holy grail would be a tool to identify those cancers which are life threatening requiring treatment and those which can be safely ignored, never labelling a woman as having cancer in the first place.

AI tools can also be used to organise workflow with automated decision support to direct a woman to a supplemental examination or additional tests following her mammogram. A more sophisticated approach might take account of lifestyle, family history and genetic information to generate a risk prediction to then have a more tailored imaging approach to offering screening. A review of the literature will be presented to give the current state of play of these big aspirations.

TAKE HOME POINTS

- Computer Aided detection was adopted enthusiastically for many years although is being used in a more thoughtful manner.
- AI tools for mammography are being developed by a number of different organisations and start ups
- Regulatory and governance needs to be adapted to take account of the moving nature of the AI algorithms.
- Radiologists will use the AI tools in different ways depending on their working preference.

POTENTIAL CONFLICT OF INTEREST DISCLOSURES

It is the policy of the European Society of Breast Imaging to ensure balance, independence, objectivity, and scientific rigour in the congress programme. Knowledge of possible relationships with sponsors of any kind is mandatory in order to reinforce the educational and scientific message and to relieve any suspicion of bias. Any potential conflict of interest involving EUSOBI speakers should be made known so that the audience may form their own judgements about the presentation with a full disclosure of the facts. It is for the audience to determine whether the presenter's external interest may reflect a possible bias in either the work carried out or the conclusions presented.

Dr. Julia Camps Herrero, head of the Scientific and Organising Committee, disclosed the following relationships:
Receipt of honoraria or consultation fees: BD Bard

Dr. Alexandra Athanasiou, member of the Scientific and Organising Committee, did not disclose any relationships.

Dr. Pascal A. Baltzer, member of the Scientific and Organising Committee, did not disclose any relationships.

Dr. Eva M. Fallenberg, member of the Scientific and Organising Committee, disclosed the following relationships:
Receipt of grants/research supports: Guerbet, GE Healthcare
Receipt of honoraria or consultation fees: Guerbet, Bayer, Siemens, GE Healthcare
Participation in a company sponsored speaker's bureau: Guerbet, GE Healthcare

Prof. Gabor Forrai, member of the Scientific and Organising Committee, did not disclose any relationships.

Prof. Fiona J. Gilbert, member of the Scientific and Organising Committee, did not disclose any relationships.

Dr. Ritse M. Mann, member of the Scientific and Organising Committee, disclosed the following relationships:
Receipt of grants/research supports: Siemens, Seno Medical Instruments, Bayer, Medtronic, IOS inc., Micrima, Screenpoint
Receipt of honoraria or consultation fees: Transonic Imaging
Spouse/partner: Transonic Imaging

Dr. Federica Pediconi, member of the Scientific and Organising Committee, did not disclose any relationships.

Dr. Katja Pinker-Domenig, member of the Scientific and Organising Committee, did not disclose any relationships.

Prof. Francesco Sardanelli, member of the Scientific and Organising Committee, disclosed the following relationships:

Receipt of grants/research supports: Bracco, Bayer, General Electric
Participation in a company sponsored speaker's bureau: Bracco, General Electric

SCIENTIFIC POSTERS

- P-01 Nipple sparing mastectomy (NSM) for oncologic surgical management: Tumor-to-nipple distance (TND) on preoperative MRI aids patient selection and predicting outcomes**
*J. Lee*¹, K.L. Harris², J. Frey², A. Salibian², M. Choi², N. Karp², D. Axelrod²; ¹Scarsdale/US, ²New York City/US
- P-02 Interpretation of Patterns of Enhancement on Contrast-Enhanced Digital Mammography: An Approach to a Standardized Scheme**
S. Gareer, M.H. Helal, O. Mokhtar, Y. Mounir, A. Abdel Aziz; Cairo/EG
- P-03 Can perilesional edema detected in MRI be considered as a biomarker for breast cancer? Role of FSE T2-weighted IDEAL sequences**
 G. Moffa, F. Galati, F. Marzocca, *G. Panzironi*, F. Pediconi; Rome/IT
- P-04 Tomosynthesis plus digital mammography versus digital mammography for breast cancer screening: the Reggio Emilia tomosynthesis randomized trial**
V. Iotti, C. Campari, P. Giorgi Rossi, A. Nitrosi, R. Vacondio, P. Pattacini; Reggio Emilia/IT
- P-05 Digital Breast Tomosynthesis with Photon-Counting technology: results from a clinical comparison study**
E. Venturini, C. Losio, M.G. Rodighiero, S. Tacchini, E. Schiani, P. Panizza; Milan/IT
- P-06 Visualization and Localization of HydroMARK Axillary Clips in Patients with Node Positive Breast Cancer Treated with Neoadjuvant Chemotherapy – A Retrospective Review**
*K. Adler*¹, N. Samreen¹, A. Bhatt¹, S. Zingula¹, S. Choudhery², K.N. Glazebrook¹; ¹Rochester/US, ²Dallas/US
- P-07 Does a predictive multiparametric [18F]FDG-PET/MRI model including imaging biomarkers of the tumor and contralateral healthy breast tissue aid breast cancer diagnosis?**
*D. Leithner*¹, B. Bernard-Davila², D. Martinez², T.H. Helbich³, G. Karanikas³, M.S. Jochelson², E.A. Morris², P.A.T. Baltzer³, P. Clauser³, K. Pinker-Domenig³; ¹Frankfurt am Main/DE, ²New York/US, ³Vienna/AT
- P-08 Examination of the perceptual behaviour of false negative errors during DBT reading task**
 L. Dong, A.G. Gale, *Y. Chen*; Loughborough/UK
- P-09 Radiomics and deep learning can help mass classification on contrast-enhanced spectral mammograms**
Y. van Wijk, H. Woodruff, A. Jochems, S. Primakov, M.B.I. Lobbes, P. Lambin; Maastricht/NL
- P-10 Breast density proportions differ by race in minority women newly diagnosed with breast cancer: implications for radiology and proactive awareness**
Z. Zhang, O. Ojutiku, R. Rao, S. Vempale, J. Lee; New York/US
- P-11 Associations between Magnetic Resonance Imaging (MRI) Biomarkers and Tumor-Infiltrating Lymphocytes (TILs) in breast cancer: results from a preliminary study**
E. Venturini, M.M. Panzeri, C. Losio, S. Ravelli, F. Gallivanone, P. Panizza; Milan/IT
- P-12 Breast Cancer Biological Subtype Prediction based on Radiomic MR Mammography features**
*N. Papanikolaou*¹, E. Panourgias², J. Santinha¹, M. Lisitskaya¹, A. Uysal¹, L.A. Moulopoulos²; ¹Lisbon/PT, ²Athens/GR
- P-13 A Deep-Learning Approach for Breast Lesions Classification from Tomosynthesis Images**
M. Telegrafo, V. Bevilacqua, E. Ventrella, M. Di Pirchio, C. Tartaglia, M. Moschetta; Bari/IT
- P-14 Difference in tumour characteristics between true interval and screen-detected breast cancers**
 A. Tan¹, S. Eleti², N. Vidyaprakash¹, *A.R. Eleti*¹; ¹Southend/UK, ²London/UK

- P-15 Hidden in plain sight? Contrast-enhanced spectral mammography versus full-field digital mammography; an eye-tracking study**
K.V. van Geel¹, E.M. Kok¹, J. Krol¹, I. Houben², D. Hiller³, F. Thibault⁴, R. Körver-Steeman⁵, R.M. Pijnappel⁶, J.J.G. van Merriënboer¹, **M.B.I. Lobbes**¹; ¹Maastricht/NL, ²Bunde/NL, ³Manchester/UK, ⁴Paris/FR, ⁵Geleen/NL, ⁶Huis Ter Heide/NL
- P-16 US Evaluation Of Axillary Lymph Node Cortical Thickness As A Predictor Of Metastasis, In Early Breast Cancer**
L. Metaxa¹, G. Exarchos², R. Aggarwal¹, L.J. Jones¹, T.D. Suaris¹; ¹London/UK, ²Athens/GR
- P-17 Residual fibroglandular tissue (R-FGT) in BRCA 1/2 germline-mutation carriers with unilateral and bilateral prophylactic mastectomies**
K.B. Krug¹, O. Grinstein¹, F. Siedek¹, R. Schmutzler¹, D. Maintz², K. Rhiem¹, M. Hellmich¹; ¹Cologne/DE, ²Münster/DE
- P-18 Reliability of MRI tumour size measurements for minimal invasive treatment selection in small invasive breast cancers, based on patient and tumour characteristics.**
W. Sanderink, L.J.A. Strobbe, P. Bult, N. Karssemeijer, R.M. Mann; Nijmegen/NL
- P-19 Can biopsy of papillary breast lesions be avoided based on sonographic and clinical features?**
C. Ward¹, H. Marshall¹, I. Ben Nachum¹, A. Kornecki¹, **P. Fani**²; ¹London/CA, ²Burlington/CA
- P-20 Step by Step diagnostic approach of rare breast and axillary lesions**
L. Metaxa¹, S. Dani¹, G. Exarchos², T.D. Suaris¹, R. Patel¹, S.I. Usiskin¹, C.F. Longman¹, D. Evans¹, L.J. Jones¹, P. Dilks¹; ¹London/UK, ²Athens/GR
- P-21 Idiopathic Granulomatous mastitis; a diagnostic challenge**
S. Abayazeed Ahmad¹, M. Hajaj¹, **S. Alshaibani**¹, M. Abu Dakka², A. Anand¹, K. Junejo¹; ¹Doha/QA, ²Amman/JO
- P-22 Additional findings evidenced by MRI in breast implants with intact capsule with potential surgical management: a pictorial review.**
G.D.F. Planard, J. Hiraoka Catani, M. Batina Fernandes Moreira, A. Alves de Queiroz, R. Silva Rabelo, A. Neves Machado; São Paulo/BR
- P-23 Safety and technical issues of stereotactic biopsy of suspicious microcalcifications using the breast lesion excision system (BLES)**
A. Christou¹, V. Koutoulidis², D. Koulocheri², K. Zografos², G. Zografos²; ¹Brighton/UK, ²Athens/GR
- P-24 Tumor MR biomarkers of screen-detected and non-screen detected breast cancers**
E. Panourgias, O. Viskadouraki, K. Zafeiropoulou, O. Preza, L.A. Mouloupoulos; Athens/GR
- P-25 Can radiologists balance their reading time in mammography by using an artificial intelligence computer system for interactive decision support?**
A. Rodriguez-Ruiz¹, E. Krupinski², J.-J. Mordang³, K. Schilling⁴, S.H.H. Heywang-Köbrunner⁵, I. Sechopoulos³, **R.M. Mann**³; ¹Utrecht/NL, ²Atlanta/US, ³Nijmegen/NL, ⁴Boca Raton/US, ⁵Munich/DE
- P-26 Diagnostic Accuracy of Breast MRI compared with conventional imaging, in the evaluation of patients with suspicious nipple discharge.**
G. Panzironi, F. Galati, F. Marzocca, C. Caramanico, E. Collalunga, F. Pediconi; Rome/IT
- P-27 Apparent diffusion coefficient: potential biomarker for complete response after neoadjuvant chemotherapy in breast cancer**
L. Grana Lopez, M. Vázquez Caruncho, Á. Villares Armas; Lugo/ES

- P-28 Correlation between breast background parenchymal enhancement in MRI and standardized uptake value in dbPET. Could these values be associated with breast cancer?**
*L. Grana Lopez*¹, M. Herranz², M. Vázquez Caruncho¹, S. Argibay-Vazquez², I. Dominguez-Prado², Á. Villares Armas¹, A. Ruibal²; ¹Lugo/ES, ²Santiago de Compostela/ES
- P-29 Convolutional Neural Networks: Automatic detection and segmentation of breast cancer using MR Mammography**
N. Papanikolaou, J.M. Moreira, M. Lisitskaya, E.M.G. Batista, J. Santinha, F. Cardoso; Lisbon/PT
- P-32 DCE-MRI radiomics signatures for the differentiation of molecular breast cancer subtypes and receptor status**
*D. Leithner*¹, J.V.M. Horvat², B. Bernard-Davila³, R.E. Ochoa-Albiztegui⁴, M.S. Jochelson³, D. Martinez³, E.A. Morris³, S. Thakur³, K. Pinker-Domenig⁵; ¹Frankfurt am Main/DE, ²Sao Paulo/BR, ³New York/US, ⁴Mexico City/MX, ⁵Vienna/AT
- P-33 Background Parenchymal Enhancement, Mammographic Density and Risk of Breast Cancer**
*A. Orlando*¹, F. Amato¹, L. Spatafora¹, M.L. Di Vittorio¹, M. Safina², S. Busalacchi¹, R. Ienzi¹, T.V. Bartolotta¹; ¹Palermo/IT, ²Castellammare del Golfo/IT
- P-34 A Large Study of Contrast Enhanced Digital Mammography in Clinical Practice.**
E. Gioutlaki, C. Tzimas, E. Feida, A.N. Chalazonitis; Athens/GR
- P-35 Diagnostic accuracy of contrast-enhanced spectral mammography versus MRI - Initial results in the assessment of tumor size in a reference cancer hospital**
M.M. Saito, S. Sabino, M.A. Leão, E.C. Mauad; Barretos/BR
- P-36 The added value of the Contrast Enhanced Spectral Mammography (CESM) in the symptomatic patient**
*R. Alcantara*¹, M.C. Posso Rivera, F. Plancarte, J. Martinez Orfila, E.N. Arenas Rivera, A.M. Rodriguez-Arana; Barcelona/ES
- P-37 Evaluation of breast cancer morphology using diffusion-weighted and dynamic contrast-enhanced MRI: intermethod and interobserver agreement**
N. Radovic, G. Ivanac, E. Divjak, I. Biondic, A. Bulum, B. Brkljacic; Zagreb/HR
- P-38 Potential Of MRI In Characterization Of Breast Cancer Molecular Subtypes**
M. Khadartseva, I. Vassilieva, M. Gorodnova; Moscow/RU
- P-39 Tumour grading prediction based on Radiomic MR Mammography features**
*N. Papanikolaou*¹, E. Panourgias², M. Lisitskaya¹, J. Santinha¹, A. Uysal¹, J.M. Moreira¹, L.A. Mouloupoulos²; ¹Lisbon/PT, ²Athens/GR
- P-40 Diffusion weighted MRI in early assessment of response to neoadjuvant chemotherapy in breast cancer**
*M. Armas Goncalves*¹, A.F. Capelinha¹, M. Fernandes¹, M. Figueiredo Dias², L. Curvo-Semedo²; ¹Funchal/PT, ²Coimbra/P
- P-41 Problem: Dense Breasts. Solution: Contrast Enhanced Digital Mammography.**
E. Gioutlaki, C. Tzimas, E. Feida, A.N. Chalazonitis; Athens/GR
- P-42 Percutaneous ultrasound-guided excision with Vacuum-assisted-breast-biopsy (VABB) system of breast lesions with imaging-histology discordance.**
C. Depretto, F. Balestra, B. Colombo, F. Cartia, C. Ferranti, G. Scaperrotta; Milan/IT
- P-43 Identifying Risk Factors for Coronary Artery Disease and Diabetes in Women with Mammographically Detected Breast Arterial Calcifications**
*B. Li*¹, G. Kim², N. Debruhi²; ¹Santa Monica/US, ²Los Angeles/US

- P-44 Validating high frequency transducers in depicting mammographically suspicious clusters of microcalcifications in order to perform vacuum assisted biopsy**
K. Syrgiannis, S.P. Lazarou, E. Zachari, A. Vrettou, M. Stathoulopoulou, D. Antonopoulos, V. Venizelos; Athens/GR
- P-45 Multimodality imaging correlation of chest wall invasion of breast tumors**
*N. Samreen*¹, C. Lee¹, K. Adler¹, A. Bhatt¹, S. Zingula¹, S. Choudhery², K.N. Glazebrook¹; ¹Rochester/US, ²Dallas/US
- P-46 Radiomics based on baseline DCE-MRI is predictive of tumor pathological complete response to neoadjuvant systemic therapy in breast cancer patients**
R. Granzier, M.D.A. Ibrahim, T. van Nijnatten, M. de Boer, M.D.E. Heuts, M.P.H. Woodruff, P. Lambin, M. Smidt, M.B.I. Lobbes; Maastricht/NL
- P-47 Digital Breast Tomosynthesis-guided Vacuum-Assisted Breast Biopsy: our experience with Patients positioned on a dedicated armchair**
E. Venturini, C. Losio, M.G. Rodighiero, S. Tacchini, M.M. Panzeri, C. Santangelo, P. Panizza; Milan/IT
- P-48 Radiology and pathology concordance in prediction of excision of small clusters of microcalcifications proved malignant using breast lesion excision system (BLES)**
*A. Christou*¹, V. Koutoulidis², D. Koulocheri², K. Zografos², G. Zografos²; ¹Brighton/UK, ²Athens/GR
- P-49 Differentiation between benign and malignant breast lesions based on a Radiomic ABUS signature**
*N. Papanikolaou*¹, A. Uysal¹, J. Santinha¹, J.M. Moreira¹, M. Lisitskaya¹, A. Vourtsis²; ¹Lisbon/PT, ²Athens/GR
- P-50 Abbreviated breast MRI: do we still need contrast media?**
*A. D'Angelo*¹, P. Clauser², J. Al Mohanna², P. Kapetas², P. Rinaldi¹, C. Zuiani³, T.H. Helbich², K. Preidler², P.A.T. Baltzer²; ¹Rome/IT, ²Vienna/AT, ³Udine/IT
- P-51 Breast lesion excision system (B.L.E.S.): Interesting results and demographic correlations from a series of 4120 cases.**
G. Skountzos, I. Sardeli, D. Koulocheri, N. Michalopoulos, M. Alafaki, K. Zografos, G. Zografos; Athens/GR
- P-52 Analysis of the qualitative and quantitative study of Superb Microvascular Imaging (SMI) in breast lesions**
A. Catanese, A.P. Salazar Gomez, B. Navarro Guri, F. Terrel Molina, D.M.A. Pascual, M.S. Garcia Martinez; Barcelona/ES
- P-53 A Computer-aided diagnosis for pretreatment prediction of pathological complete response to neoadjuvant chemotherapy in breast cancer patients using DCE-MRI texture features**
V.M. Doronzio, L. Vassallo, V. Giannini, S. Mazzetti, D. Regge, L. Martincich; Candiolo-Torino/IT
- P-54 Mammographic pattern, background parenchymal enhancement (BPE) and hormonal effect: a comparison between Breast Magnetic Resonance (MRI) and Contrast Enhanced Spectral Mammography (CESM)**
D. La Forgia¹, A. Colaninno¹, R. Dentamaro¹, V. Didonna¹, A. Fanizzi¹, L. Losurdo¹, R. Massafra¹, P. Tamborra¹, *M. Telegrafo*², M. Moschetta¹; ¹Bari/IT, ²Triggiano/IT
- P-55 Investigating Machine Learning Techniques for Identification of Receptor status (ER, PR, HER2) in Invasive Ductal Carcinoma Cases Using BIRADS MRI Features**
U. Aksoy Ozcan, S. Ekemen, S. Ulus, B. Uluc, A. Ozcan; Istanbul/TR
- P-57 Breast Papillary lesions in a uni-centre Malaysian population: Radiopathological features**
F.B. Fadzli, M.T. Ramli, F.I. Rozalli, M.H. See, K.H. Teoh, K. Rahmat, W.L. Ng; Kuala Lumpur/MY

- P-58 Limited liver disease from breast cancer metastasis: a case-series of local control with percutaneous microwave ablation**
M. Correia, C. Alves, F. Gomes, E. Coimbra; Lisbon/PT
- P-59 The role of MRI in the management of High Grade Ductal Carcinoma in Situ**
*M. Hajaj*¹, M. Abu Dhakka², G. Elamin³, S. Pascaline⁴; ¹Doha/QA, ²Amman/JO, ³Mansfield/UK, ⁴Kettering/UK
- P-60 Deep learning for case-wise decision support in breast cancer screening**
*H. Harvey*¹, A. Heindl¹, J. Yearsley¹, G. Khara¹, M. O'neill¹, E. Szabo², K. Keresztes², E. Ambrozay³, Z. Pentek², G. Forrai²; ¹London/UK, ²Budapest/HU, ³Kecskemét/HU
- P-61 Background parenchymal enhancement in patients with invasive lobular carcinoma - comparison with the general population, and analysis of preoperative MRI results in this subgroup**
*Y. Rapson*¹, A. Grubstein², M. Manor², S. Gavrieli², O. Ben Zaquen², E. Atar²; ¹Shoham/IL, ²Petah Tikva/IL
- P-62 Diagnostic accuracy of stereotactic tomosynthesis (DBT) vacuum-assisted breast biopsy (VABB) of non-palpable breast lesions- A single centre experience**
W.L. Ng, K. Rahmat, M.T. Ramli, S. Borhan, S. Kaur, W.Y. Chan, A. Vijayanathan; Kuala Lumpur/MY
- P-63 CEUS in breast imaging**
E. Divjak, N. Radovic, G. Ivanac, B. Brkljacic; Zagreb/HR
- P-64 Identification of axillary lymph node clips on MRI.**
*N. Samreen*¹, K. Adler¹, A. Bhatt¹, S. Zingula¹, S. Choudhery², K.N. Glazebrook¹; ¹Rochester/US, ²Dallas/US
- P-65 Comparison of FOCUS (Field-of-view Optimized and Constrained Undistorted Single-shot)-DWI with standard DWI-MRI and DCE-MRI in the qualitative assessment of breast lesions.**
L. Vassallo, V.M. Doronzio, L. Pusceddu, G.L. Desi, D. Regge, L. Martincich; Candiolo/IT
- P-66 Comparison of the rate of hematoma formation and the size of hematomas between lateral arm and conventional stereotactic biopsy techniques.**
O. Weaver, E. Cohen, R. Perry, H. Tso, K. Phalak, A. Srinivasan, W. Wei; Houston/US
- P-67 Augmented Breast: Is that Aquafilling or not?**
U. Aksoy Ozcan, S. Ulus; Istanbul/TR
- P-68 Diagnostic performance of standard breast MRI compared to dedicated axillary MRI for assessment of axillary lymph node metastases in breast cancer patients**
S. Samiei, T. van Nijnatten, S. Vanwetswinkel, S.M.E. Engelen, M. Smidt, M.B.I. Lobbes; Maastricht/NL
- P-69 Advancements in computer-aided BI-RADS US characterization of focal breast lesions: clinical assessment of a new software release of S-Detect**
*A. Orlando*¹, M.L. Di Vittorio¹, F. Amato¹, M. Safina², S. Busalacchi¹, R. Ienzi¹, T.V. Bartolotta¹; ¹Palermo/IT, ²Castellammare del Golfo/IT
- P-70 Comparison of fat suppression in repeated breast MRI at 1.5T: An evaluation of field shimming strategies**
N. Samreen, W. Zhou, C. Favazza, J.A. Axmacher, C. Lee; Rochester/US
- P-71 Breast pseudoaneurysms: A retrospective analysis of imaging, management and treatment options**
K. Adler, A. Bhatt, N. Samreen, S. Zingula, K.N. Glazebrook; Rochester/US

GENERAL INFORMATION

GENERAL INFORMATION

CONGRESS VENUE

Megaron Athens International Conference Center
Vass. Sofias Ave & Kokkali 1
11521 Athens
Greece

REGISTRATION FEE FOR DELEGATES INCLUDES

- admittance to all scientific sessions
- admittance to the industry exhibition
- congress programme and abstracts
- certificate of attendance
- coffee breaks

CERTIFICATE OF ATTENDANCE

The certificate of attendance/CME accreditation can be viewed and printed after the congress upon entering your EUSOBI MyUserArea at the website (www.eusobi.org). To enter your MyUserArea, please use your username and password.

CME CREDITS

The EUSOBI Annual Scientific Meeting 2018, Athens, Greece, 11/10/2018-13/10/2018 has been accredited by the European Accreditation Council for Continuing Medical Education (EACCME®) with **16 European CME credits (ECMEC®s)**. Each medical specialist should claim only those hours of credit that he/she actually spent in the educational activity.

Breakdown of ECMEC®s per day:

October 11 > 3,00
October 12 > 7,00
October 13 > 6,00

CONFERENCE LANGUAGE

The meeting will be held in English. No simultaneous translation will be offered.

BADGE/TICKETS

You are kindly asked to keep your badge visible on the congress grounds at all time. Pre-ordered evening event tickets will be handed out additionally to the congress badge. (If you have not received your pre-ordered tickets, please contact the registration staff members.)

ONSITE CONGRESS OFFICE

In case of any questions, kindly consult the EUSOBI registration desk. Staff members will be happy to assist you.

Thursday, October 11 12:00-18:30
Friday, October 12 07:15-18:30
Saturday, October 13 07:45-17:00

INDUSTRY EXHIBITION

The industry exhibition area is located in the South and North Hall on floor-2.

Opening Hours

Thursday, October 11 14:00-18:15
Friday, October 12 08:15-18:20
Saturday, October 13 08:30-17:00

ONSITE PAYMENT

Onsite payment can only be made by credit card (Visa or Mastercard) or in cash (Euro). Please understand that no other payment facilities like cheques, etc. will be accepted.

NAME CHANGES

Name changes will be treated like the cancellation of the registration and a new registration of the other participant.

MEDIA CENTER

The media center is located on floor -2 inside the main lecture hall (Banqueting Hall). Trained staff will be available to assist you with the equipment. Speakers are reminded to check in their presentation at least one hour prior to their scheduled session. Please note that the media upload should not be used to prepare your entire presentation and that due to the large number of speakers, the workstation is only available for minor editing.

GUIDELINES FOR SPEAKERS

- You are kindly requested to submit your presentation one hour before your session starts at the latest (USB sticks are recommended).
- All presentations have to be uploaded to the conference IT-system. No personal computer will be accepted for projection.
- Please be at the lecture room at the latest five minutes prior to the start of your session and identify yourself to the moderator(s).
- Kindly observe your presentation time. Exceeding the time limit will not be accepted and the moderators are requested to stop presentations in such cases.

FUTURE MEETING DESK

This area – located next to the registration & information area on floor -2 – offers you an overview of future meetings in the field of radiology and related disciplines, from all over the world. Feel free to contribute flyers and posters to promote your own meetings and courses.

GENERAL INFORMATION

COFFEE BREAKS

Complimentary coffee, tea and refreshments will be served during the official coffee breaks to all congress delegates.

LEAD RETRIEVAL SYSTEM

Your name badge is your business card. EUSOBI and its sponsors are using a lead retrieval system during the congress. In practice that means that when you present your badge for scanning at an exhibition booth or for scanning when entering an industry-sponsored symposium, the following personal data can be retrieved:

- Exhibition booth: first name, last name, address details, email address, profession
- Industry-sponsored symposium: first name, last name, city, country

RECORDING

Video- or audio-recording of any sessions or presentations is not allowed without the speaker's/organiser's prior written permission.

FILMING & PHOTOGRAPHY

We would like to inform you that there will be filming and photography during the Annual Meeting. A photo gallery with all photos taken during the congress will be available to registered participants on the EUSOBI website for one year. In addition, photographs taken during EUSOBI 2018 may be used for the society's social media channels.

MOBILE PHONES

Please do not forget to switch off your mobile phones before entering any of the lecture rooms.

EUSOBI QUIZ

A breast interpretation quiz will be shown in loop on a monitor in the South Hall. Please fill out the answer sheet (available at the monitors) and hand it in at the registration counter before Friday, 16:20 (local time).

SAFETY

The safety of all congress delegates and participants is of utmost importance to the ECR GmbH/EUSOBI. Security measures and precautions at the ECR GmbH/EUSOBI venue have been tightened to ensure maximum security for all attendees. Badges must be worn visibly on the congress grounds at all times. The ECR GmbH/EUSOBI reserves the right for staff to check participants' identification upon admission to and/or inside the congress venue. Participants may at any time be requested to present adequate proof of identity in the form of a passport, driver's license, national or military identification or student ID. Documents for the proof of identity must include a photograph and signature.

DISCLAIMER/LIABILITY

ECR GmbH/EUSOBI cannot accept any liability for the acts of the suppliers to this meeting or the attendees' safety while travelling to or from the congress. All participants and accompanying persons are strongly advised to carry adequate travel and health insurance, as ECR GmbH/EUSOBI cannot accept liability for accidents or injuries that may occur. ECR GmbH/EUSOBI is not liable for personal injury and loss or damage of private property.



Don't miss the latest information

Join us on facebook
<https://www.facebook.com/eusobieuropeansociety/>



EYC SYMPOSIUM INFORMATION

Join the EYC
Symposium on
Sunday!

We are pleased to invite you to the **EUSOBI Young Club Symposium**, which will take place in Athens, Greece, on **Sunday, October 14, 2018**, the morning after the EUSOBI Annual Scientific Meeting 2018.

The topic of our symposium will be **"Being a breast radiologist: Beyond the clinical work"** and is especially addressed to the young club members in order to discuss the role and perspectives of young professionals in our field.

Symposium places are limited and offered upon a first-come, first-served basis. For information about availability, kindly contact the EUSOBI staff at the registration desk.

We are asking for a small handling fee of EUR 20.00.

The EYC Symposium will be held in the same venue of the EUSOBI Annual Scientific Meeting, in room MC 3.2 (floor -1).

EYC SYMPOSIUM PROGRAMME

Being a breast radiologist: Beyond the clinical work

09:30	Introduction by the Committee Chairpersons R.M. Mann, Nijmegen/NL; K. Pinker-Domenig, New York/US; P. Clauser, Vienna/AT
09:45	Being a breast radiologist in 2018: Different experiences in different countries <i>Moderator: K. Pinker-Domenig, New York/US</i> Panel P. Clauser, Vienna/AT; E. Giannotti, Nottingham/UK; M. Marcon, Zurich/CH; M.A. Marino, Messina/IT
10:30	The importance of communication <i>Moderators: R.M. Mann, Nijmegen/NL; K. Pinker-Domenig, New York/US</i>
10:30	Communication with the team M. Fuchsjäger, Graz/AT
10:50	Communication with patients A. Athanasiou, Athens/GR
11:10	Discussion
11:20	Break
11:35	Funding: How to get it C.K. Kuhl, Aachen/DE
11:55	Discussion
12:05	Private, public or academic? <i>Moderator: R.M. Mann, Nijmegen/NL</i> Panel P. Baltzer, Vienna/AT; J. Camps Herrero, Alzira/ES; G. Forrai, Budapest/HU; F. Gilbert, Cambridge/UK
13:15	Closing remarks

CONGRESS SPONSORS

We thank our industry partners for their highly appreciated support of EUSOBI 2018.



MEDIA PARTNER



Stability you can see



Highly stable
macrocyclic structure¹
Low levels
of gadolinium (Gd)
retained in brain
and body tissues
in animal experiments
and human studies²⁻⁶



Bibliography 1. Laurent S, Elst LV, Muller RN. Comparative study of the physicochemical properties of six clinical low molecular weight gadolinium contrast agents. *Contrast Media Mol Imaging*. 2006;1(3):128-37 2. Lohrke J, Frisk AL, Frenzel T, et al. Histology and gadolinium distribution in the rodent brain after the administration of cumulative high doses of linear and macrocyclic gadolinium-based contrast agents. *Invest Radiol*. 2017;52(6):324-33 3. Bussi S, Tedoldi F, Maisano F, et al. Differences in gadolinium retention after repeated injections of macrocyclic contrast agents to rats. *J Magn Res Imaging*. 2017. DOI:10.1002/jmri.25822 4. Study FRCG-03-15. Bracco data on file 5. McDonald RJ, McDonald JS, Dai D, Schroeder D, Jentoft ME, Murray DL, Kadirvel R, Eckel LJ, Kallmes DF. *Radiology*. 2017 Jun 19;161:594. doi: 10.1148/radiol.2017161594. [Epub ahead of print] 6. Murata N, Gonzalez-Cuyar LF, Murata K, et al. Macrocylic and Other Non-Group 1 Gadolinium Contrast Agents Deposit Low Levels of Gadolinium in Brain and Bone Tissue: Preliminary Results From 9 Patients With Normal Renal Function. *Invest Radiol*. 2016;51(7):447-53.

SUMMARY OF PRODUCT CHARACTERISTICS For prescribing information please refer to the approved SPC in your country. **ProHance, 0.5 M solution for injection Composition** 1 ml of solution for injection contains: gadoteridol 279.3 mg/ml (0.5 M) **Excipients** Calteridol Calcium, Tromethamine USP, Hydrochloric Acid Ph Eur, Sodium Hydroxide Ph Eur, Water for Injections Ph Eur **Therapeutic indications** Using Magnetic Resonance Imaging (MRI), ProHance provides contrast enhancement of the brain, spine and surrounding tissues resulting in improved visualization (compared with unenhanced MRI) of lesions with abnormal vascularity or those thought to cause a disruption of the normal blood-brain barrier. ProHance can also be used for whole body MRI including the head, neck, liver, breast, musculoskeletal system and soft tissue pathologies. **Contra-indications** Hypersensitivity to the active substance, or to any of the excipients or to other gadolinium-based contrast. ProHance is contraindicated in children under 66 months of age. **Special warnings and special precaution for use** Patients with a history of allergy, drug reactions, or other hypersensitivity-like disorders should be closely observed during the procedure and the contrast medium administration, as well as for the time the physician deems useful given the patient condition. As with other gadolinium chelates, there have been reports of anaphylactic/anaphylactoid/hypersensitivity reactions with gadoteridol. These reactions manifested with various degrees of severity, including anaphylactic shock or death. They involved one or more body systems, mostly respiratory, cardiovascular and/or mucocutaneous systems. Anaphylactic shock has been very rarely reported with the use of gadoteridol. Appropriate drugs and instruments for emergency measures must be readily available. In patients suffering from epilepsy or brain lesions the likelihood of convulsions during the examination may be increased. Precautions are necessary when examining these patients (e.g. monitoring of the patient) and the equipment and medicinal products needed for the rapid treatment of possible convulsions should be available. Transitory changes in serum iron (within normal range in the majority of cases) have been observed in some patients after administration of ProHance and these changes were shown not to be clinically significant. Since Gadoteridol is renally cleared from the body, caution should be exercised in patients with severely impaired renal function. **Undesirable Effects** The accepted safety considerations and procedures that are required for Magnetic Resonance Imaging are applicable when ProHance is used for contrast enhancement. The following adverse reactions have been reported with ProHance. Adverse reactions from clinical trials have been included with an indication of the frequency. Adverse reactions from spontaneous reporting are included with the frequency "not known". There were no adverse reactions with an incidence greater than 2%. Common ($\geq 1/100$, $< 1/10$): *Gastrointestinal disorders*; Nausea Uncommon ($\geq 1/1,000$, $< 1/100$): *Nervous system disorders*; headache, paraesthesia, dizziness, taste disturbance. *Eye disorders*; increased lacrimation. *Vascular disorders*; flushing, hypotension. *Gastrointestinal disorders*; dry mouth, vomiting. *Skin and subcutaneous tissue disorders*; pruritus, rash, urticaria. *General disorders and administration site conditions*; injection site pain, asthenia. *Investigations*; heart rate increased. Rare ($1/10,000$, $< 1/1,000$): *Immune system disorders*; Anaphylactic/anaphylactoid reactions. *Psychiatric disorders*; anxiety. *Nervous system disorders*; mental impairment, abnormal coordination, convulsion. *Ear and labyrinth disorders*; tinnitus. *Cardiac disorders*; nodal arrhythmia. *Respiratory, thoracic and mediastinal disorders*; laryngospasm, dyspnoea, rhinitis, cough, apnea, wheezing. *Gastrointestinal disorders*; abdominal pain, tongue oedema, oral pruritus, gingivitis, loose stools. *Skin and subcutaneous tissue disorders*; oedema face. *Musculoskeletal and connective tissue disorders*; musculoskeletal stiffness. *General disorders and administration site conditions*; chest pain, pyrexia. Not known (cannot be estimated from the available clinical trial data): *Nervous system disorders*; loss of consciousness, coma, vasovagal reactions. *Cardiac disorders*; cardiac arrest. *Renal and urinary system*; acute renal failure; *Respiratory, thoracic and mediastinal disorders*; respiratory arrest, pulmonary oedema. **Additional Safety Information** Isolated cases of nephrogenic systemic fibrosis (NSF) have been reported with ProHance, most of which were in patients co-administered other gadolinium-containing contrast agents (see below). **Impaired renal function Prior to administration of ProHance, it is recommended that all patients are screened for renal dysfunction by obtaining laboratory tests.** There have been reports of nephrogenic systemic fibrosis (NSF) associated with use of some gadolinium-containing contrast agents in patients with acute or chronic severe renal impairment (GFR < 30 ml/min/1.73 m²). Patients undergoing liver transplantation are at particular risk since the incidence of acute renal failure is high in this group. As there is a possibility that NSF may occur with ProHance, it should therefore only be used in patients with severe renal impairment and in patients in the perioperative liver transplantation period after careful risk/benefit assessment and if the diagnostic information is essential and not available with non-contrast enhanced MRI. Haemodialysis shortly after ProHance administration may be useful at removing ProHance from the body. There is no evidence to support the initiation of haemodialysis for prevention or treatment of NSF in patients not already undergoing haemodialysis. **Infants from 6 months to 1 year of age** Due to immature renal function in infants up to 1 year of age, ProHance should only be used in patients 6 to 12 months of age after careful consideration at a dose not exceeding 0.1 mmol/kg body weight. More than one dose should not be used during a scan. Because of the lack of information on repeated administration, ProHance injections should not be repeated unless the interval between injections is at least 7 days. Use of ProHance is not recommended in children less than 6 months of age. Use for whole body MRI is not recommended in children less than 18 years of age. **Elderly (aged 65 years and above)** As the renal clearance of gadoteridol may be impaired in the elderly, it is particularly important to screen patients aged 65 years and older for renal dysfunction. **Please note** The peel-off tracking label on the vials should be stuck onto the patient records to enable accurate recording of the gadolinium contrast agent used (EU). The dose used should also be recorded (EU). Consult the locally approved package insert. The Marketing Authorisation Holder, the Marketing Authorisation number and the date of approval may be different in different countries. For current prescribing information refer to the package insert and/or contact your local BRACCO organisation. **Date of revision of this text** September 2016.

Your Insight,
Our Solutions



LIFE FROM INSIDE

INDUSTRY SYMPOSIUM

INDUSTRY SYMPOSIA – PROGRAMME OVERVIEW

Friday, October 12, 2018

13:00 Industry-sponsored lunch symposium by Seno Medical Instruments, Inc.
Opto-acoustic imaging: Improving breast diagnosis



Moderators: M. Van Goethem, Antwerp/BE; I. Schreer, Kiel/DE

13:00 **Opto-acoustic overview: Correlation with the Gold Standard - Histopathology**
T. Stavros, San Antonio/US

13:20 **Opto-acoustic clinical results: Findings from the Landmark PIONEER Trial**
G. Menezes, San Antonio/US

13:35 **Opto-acoustic ultrasound: Implications for European breast imagers**
J. Veltman, Hengelo/NL

13:45 **Q&A**

16:20 Industry-sponsored symposium by Kheiron Medical Technologies



Moderators: M. Bernathova, Vienna/AT; S. Heywang-Köbrunner, Munich/DE

From Bench to Bedside: The challenges and opportunities in applying deep learning to breast cancer screening

P. Kecskemethy, London/UK; H. Harvey, London/UK

16:50 Industry-sponsored symposium by BD



Moderators: M. Bernathova, Vienna/AT; S. Heywang-Köbrunner, Munich/DE

The B3 lesions of the breast represent a difficult management dilemma

E. Hughes, London/UK

17:05 Industry-sponsored symposium by Mammotome

Mammotome

Moderators: M. Bernathova, Vienna/AT; S. Heywang-Köbrunner, Munich/DE

The added value of US VABB: From under estimation rate reduction to its role in genetic testing

E. Cassano, Milan/IT

Saturday, October 13, 2018

11:45 Industry-sponsored lunch symposium by Fujifilm

FUJIFILM

Moderators: S. Pérez-Rodrigo, Madrid/ES; R. Pijnappel, Utrecht/NL

New advances in breast tomosynthesis: Personalized acquisition and iterative reconstruction in imaging and biopsy

C. Kurtz, Luzern/CH; A. Russo, Negrar/IT

INDUSTRY-SPONSORED LUNCH SYMPOSIUM BY SENO MEDICAL INSTRUMENTS, INC.

Opto-acoustic imaging: Improving breast diagnosis

Diagnostic specificity remains disappointingly low for breast imaging modalities that are optimized to achieve very high sensitivity. Opto-acoustic (OA) imaging is a fusion of real time, co-registered, interleaved OA and gray-scale information that shows both functional findings (relative de-oxygenation of hemoglobin) and morphologic data (tumor angiogenesis) within and around breast masses using a hand-held duplex OA probe. This hybrid imaging technology may provide additional information that may allow for a more specific diagnosis than conventional, diagnostic ultrasound alone.

The Imagio® breast imaging system (Seno Medical Instruments, Inc.) has obtained a CE Mark and has completed a Post-Market Surveillance and Clinical Follow-up Study at five sites in the Netherlands. In addition, Seno is pursuing Pre-Market Approval (PMA) in the United States to obtain FDA approval. The Imagio system, a fusion technology, shows potential for both structural and functional imaging information about potentially suspicious breast masses without the need for administering contrast agents, radionuclides, or exposing patients to x-irradiation.

OPTO-ACOUSTIC OVERVIEW: CORRELATION WITH THE GOLD STANDARD – HISTOPATHOLOGY

T. Stavros; San Antonio/US

We will discuss the fundamentals of opto-acoustic (OA), a combination of light and sound that shows us both the vascularization (anatomy) and relative oxygen use (function) of breast masses co-registered with ultrasound in real time. The combination of anatomy and function in real time can help us to better distinguish between benign and malignant breast masses and also provide biomarker information. The vascular anatomy of the breast is organized into zones. We will demonstrate some zonal correlations between OA and histologic findings in benign and malignant breast masses.

OPTO-ACOUSTIC CLINICAL RESULTS: FINDINGS FROM THE LANDMARK PIONEER TRIAL

G. Menezes; San Antonio/US

We will recap the landmark, USA-based PIONEER ~2,000 patients (PIVOTAL arm) at 16 centers across the United States to compare the BI-RADS classifications of breast masses assigned by independent readers (IR) using US alone to those assigned using OA/US images. The study is an FDA Pre-Market Approval (PMA) study of the OA/US device whose objective was to determine if OA/US might better reveal non-anatomic differences in benign and malignant tumor biology.

OPTO-ACOUSTIC ULTRASOUND: IMPLICATIONS FOR EUROPEAN BREAST IMAGERS

J. Veltman; Hengelo/NL

Breast diagnostic methodologies are diverse, and each modality offers pros and cons. We will recap highlights from the OA/US European study (MAESTRO) ~250 patients conducted in The Netherlands and discuss benefits of the Imagio breast imaging system and how to incorporate it into a typical clinical setting.

Friday, October 12, 2018, 16:20

INDUSTRY-SPONSORED SYMPOSIUM BY KHEIRON MEDICAL TECHNOLOGIES

From Bench to Bedside: The challenges and opportunities in applying deep learning to breast cancer screening

P. Kecskemethy; London/UK; H. Harvey; London/UK

BODY

Kheiron is focused on developing technology to improve breast cancer screening, and it is the first European company to receive the CE mark for deep learning software as a second reader. We will discuss the challenges in developing, testing and deploying algorithms in clinical practice and the opportunities to support radiologists and improve patient outcomes. From data through to clinical trials and regulations, we will be taking the audience on our journey at the frontier of technology and medicine.

INDUSTRY-SPONSORED SYMPOSIUM BY BD

The B3 lesions of the breast represent a difficult management dilemma

E. Hughes; London/UK

BODY

The B3 lesions of the breast represent a management dilemma. This diverse group of lesions diagnosed on primary core biopsy have risks of malignancy ranging from approximately 2 to up to 40 % in UK literature. However, a majority of these lesions prove benign at secondary diagnostic surgical excision. With the advent of vacuum-assisted excision (VAE), thorough sampling can be achieved in place of surgical excision. Not only is this a less invasive diagnostic technique that provides high positive predictive outcomes, but also offers a significant cost reduction in the management of these lesions. The aim of this lecture is to show based on simple economic model, the cost benefit of the B3 lesions management applying the UK Guidelines and healthcare costs.

INDUSTRY-SPONSORED LUNCH SYMPOSIUM BY FUJIFILM

New advances in breast tomosynthesis: Personalized acquisition and iterative reconstruction in imaging and biopsy

C. Kurtz; Luzern/CH; A. Russo; Negrar/IT

BODY

Digital Breast Tomosynthesis (DBT) acquisition is widely adopted to support both mammography and biopsy procedures, providing advantages in lesions detection and depiction: latest technologies can further boost this technique performance, thanks to improved image quality and advanced processing opportunities. The seminar is meant to provide technical highlights and sample cases on different acquisition protocols to be implemented in routine and diagnostic mammography.




Not yet a member of EUSOBI?

- » Representation of breast imaging on a European level
- » Reduced registration fees for the Annual Scientific Meeting
- » Reduced registration fees for all educational activities of EUSOBI
- » Membership certificate
- » European Diploma in Breast Imaging (EDBI)
- » EUSOBI Young Club (for Junior Members)
- » ESOR exchange programme for fellowships
- » ESOR visiting scholarship programme
- » Reduced subscription fee to the medical journal **Breast Care**
Multidisciplinary Journal for Research,
Diagnosis and Therapy
- » EUSOBI newsletter

Apply online at
www.eusobi.org

Application for 2019
will open in December 2018



European Diploma in Breast Imaging (EDBI)

- » is a common European qualification for breast imagers, helping to standardise training and expertise in breast imaging across Europe.
- » confirms specific competence of radiologists to perform, interpret and report mammography, ultrasound, MRI and breast intervention.
- » will assist breast imagers in the promoting of their skills and experience in breast imaging when dealing with other clinical colleagues and the general public.

Examination date:
ECR, February/March 2019

Application deadline:
December 9, 2018

Apply NOW!
www.eusobi.org

Further details, entry criteria and application form are available on the EUSOBI website www.eusobi.org.

FLOOR PLAN / INDUSTRY EXHIBITION

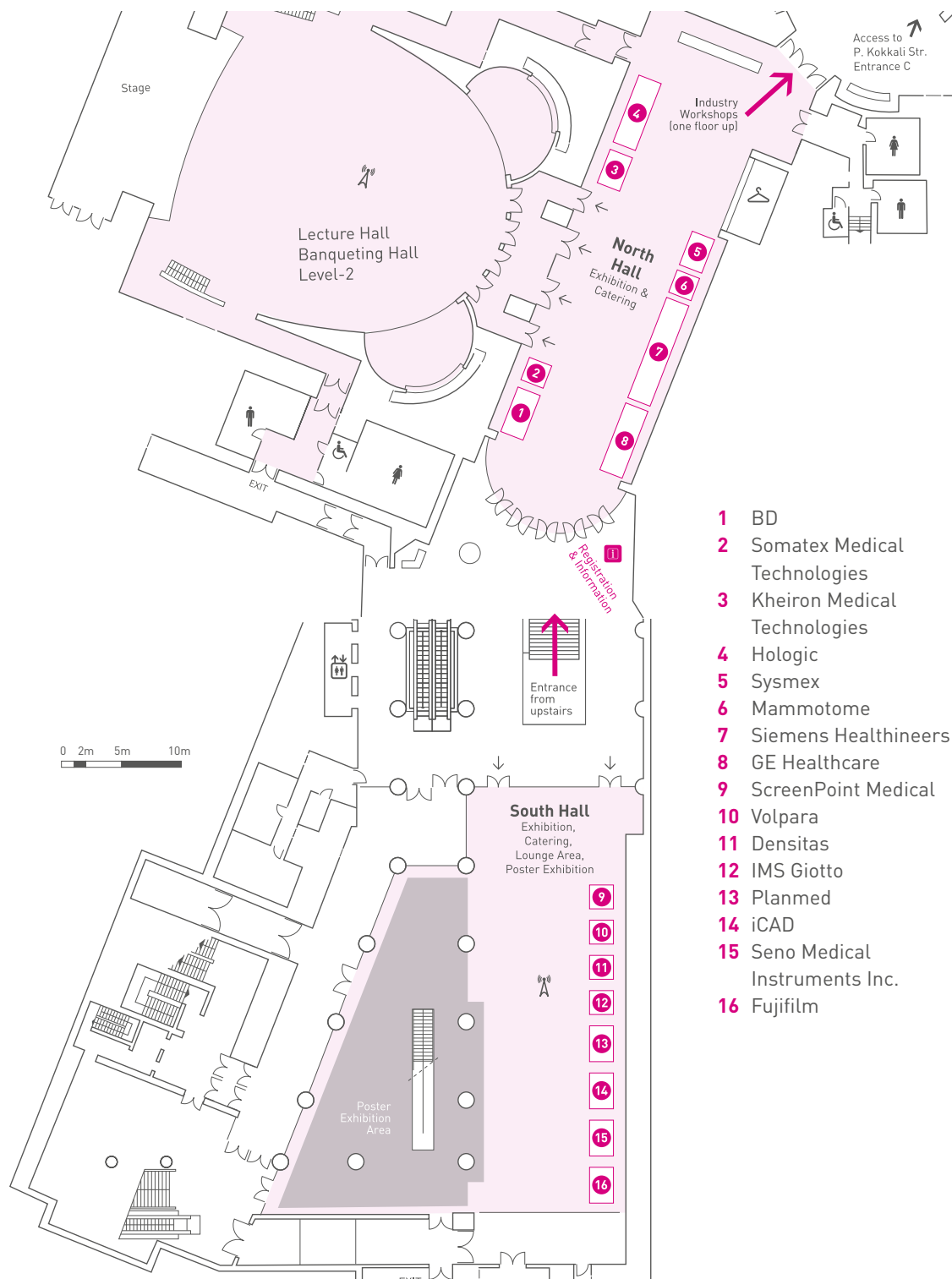
Megaron Athens International Conference Center, Floor -2

Source innovative products, meet new contacts and build networks!

Thursday, October 11 - 14:00-18:15

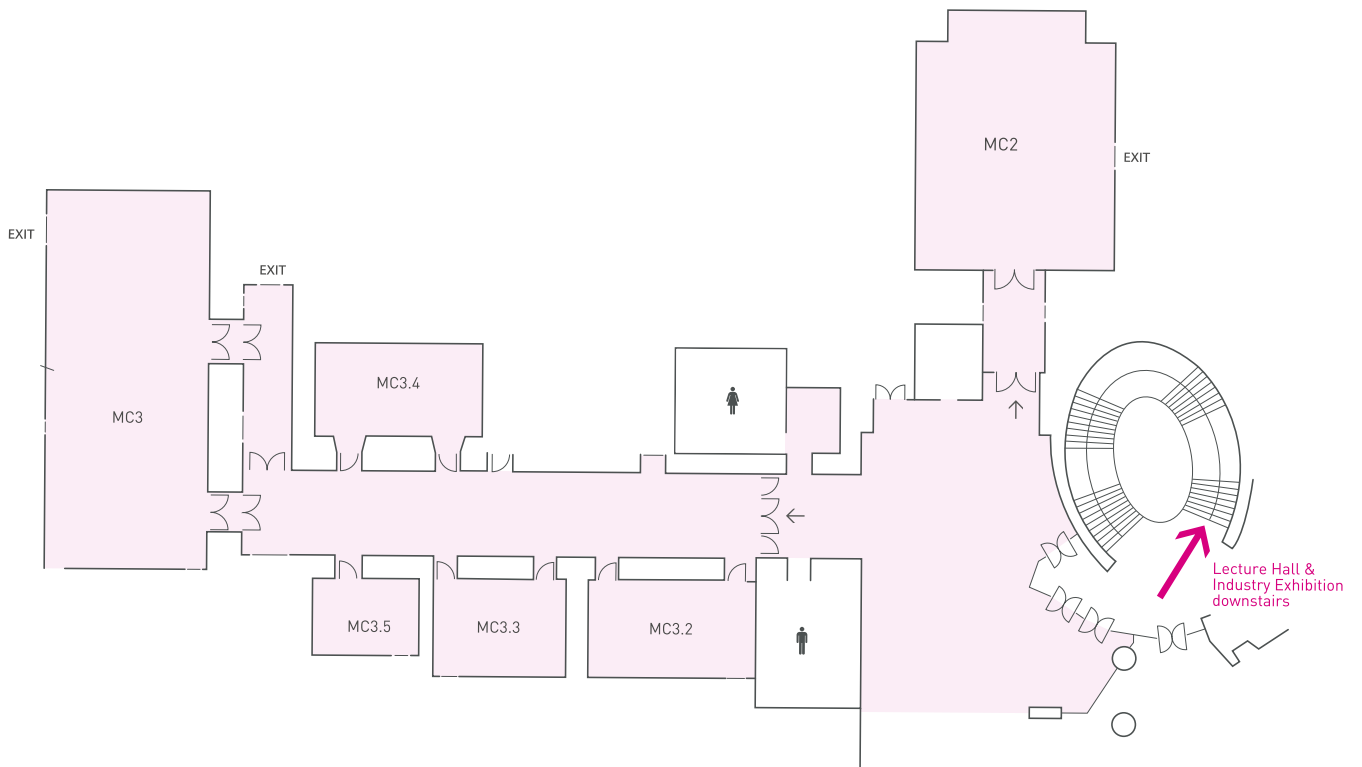Friday, October 12 - 08:15-18:20

Saturday, October 13 - 08:30-17:00



FLOOR PLAN / INDUSTRY WORKSHOPS

Megaron Athens International Conference Center, Floor -1



- MC2** Siemens Healthineers Workshops
- MC3** Hologic Workshops
- MC3.2** GE Healthcare Workshops
- MC3.3** BD
- MC3.4** GE Healthcare Workshops
- MC3.5** Hologic Workshops

INDUSTRY WORKSHOPS OF GE HEALTHCARE



GE HEALTHCARE'S PERSONALIZED BREAST CARE: LOOK DIFFERENTLY AT DENSE BREAST TISSUE – 3D AUTOMATED BREAST ULTRASOUND

Invenia™ ABUS is a non-invasive and FDA approved screening technology, which is proven to increase the invasive cancer detection rate, especially in the challenging dense breasts. The innovative design of Invenia ABUS is based on the latest GE's ultrasound development for an effective workflow integration. The objective of the workshop is to provide an overview of the latest scientific evidence and how to integrate ABUS successfully into the daily breast imaging workflow, followed by hands-on reading of clinical cases using a multimodality approach.

Room MC3.4

Friday, October 12, 16:20-17:50

Speaker: Athina Vourtsis, Athens/GR

GE HEALTHCARE'S PERSONALIZED BREAST CARE: A POSSIBLE ALTERNATIVE TO BREAST MRI – SENOBRIGHT HD

Contrast Enhanced Spectral Mammography has gained interest in the breast care pathway over the last decade. This cost effective alternative to MRI has now proven to be as sensitive and even slightly more specific than MRI. Join and discover how this technique has been integrated in the diagnostic pathway of the Hospital del Mar breast unit through hands on case readings and experience sharing from an expert using it in a daily practice.

Room MC3.2

Friday, October 12, 09:45-10:30

Speaker: Ana Rodriguez, Barcelona/ES

GE HEALTHCARE'S PERSONALIZED BREAST CARE: RESHAPING THE X-RAY GUIDED BIOPSY PROCEDURES

Senographe Pristina™, the latest generation of mammography platform, extended its diagnostic capabilities with Pristina Serena™ Biopsy suite. This workshop will focus on the latest progress in terms of x-ray guided procedures through videos, hands-on case reviews and experience sharing from an expert user, Dr Alcántara.

Room MC3.2

Friday, October 12, 15:30 – 16:15

Speaker: Rodrigo Alcantara, Barcelona/ES

The participation to all industry workshops is free of charge for EUSOBI delegates.

Please note that only a limited number of places are available and will be managed on a first come, first served basis. For registration or information about availability, kindly contact the EUSOBI staff at the registration desk.

INDUSTRY WORKSHOPS OF HOLOGIC



CONTRAST-ENHANCED MAMMOGRAPHY IN CLINICAL PRACTICE: USING I-VIEW SOFTWARE

The objective of this 90 minutes workshop is to provide participants a basic knowledge of contrast mammography and give an introduction to specifics of CEDM images through a selection of cases with training value. After a presentation of the technology and current published evidence the workshop will focus on case review. The participant will be given the opportunity to review selected cases and discuss these as part of the interactive session of the workshop.

Room MC3

Workshop slots: Thursday, October 11, 16:30-18:00
Friday, October 12, 12:00-13:30
Saturday, October 13, 14:30-16:00

Speaker: Jacopo Nori, Florence/IT

CLINICAL WORKFLOW USING REAL-TIME BREAST BIOPSY IMAGING AND TOMOSYNTHESIS GUIDANCE

This one hour workshop focus on the use of Vacuum Assisted Breast Biopsy (VABB) with real-time imaging in conjunction with Tomosynthesis guidance. After an introductory lecture the participant will be given the opportunity for a live hand-on experience with equipment using Tomosynthesis technology for biopsy guidance. The lecture part of the workshop will cover both theoretical and practical aspect of VABB real-time imaging with Tomosynthesis guidance. The trainer will also share personal experience in an interactive environment. The practical interactive hands-on part of the workshop will allow participants to use VABB real-time imaging and Tomosynthesis guidance equipment. The learning environment in small groups will allow the participants to get a good understanding of the technologies, the potential use in their clinical practices and how to address challenges with potential changes to clinical practices.

Room MC3.5

Workshop slots: Friday, October 12, 09:30-10:30
Friday, October 12, 15:30-16:30
Saturday, October 13, 10:30-11:30

Speaker: Gianfranco Scaperrotta, Milan/IT

OPTIMIZING CLINICAL PRACTICE WITH TOMOSYNTHESIS AND SYNTHESIZED 2D: WORKSHOP FOR EXPERIENCED READERS

The objective of this 90 minutes Tomosynthesis with synthesized 2D workshop is to address the clinical challenges faced by experienced Tomosynthesis users and provide a variety of solutions in the form of tips and tricks based on clinical cases selected, to illustrate each of the presented challenges. To ensure optimal conditions for participants the number of people per reading workstation will be limited to two. Participants attending this workshop are expected to have experience in using Tomosynthesis. During this hands-on workshop, using an advanced mammography workstation, the participants will review cases that cover key topics such as reading time, one-view only lesions, localization discrepancy and subtle distortions. The final diagnosis and the teaching value of the cases will be discussed.

Room MC3

Workshop slots: Thursday, October 11, 14:30-16:00
Friday, October 12, 10:00-11:30
Saturday, October 13, 12:00-13:30

Speaker: Aron Belfer, Lisbon/PT

INDUSTRY WORKSHOPS OF HOLOGIC



HIGH RESOLUTION TOMOSYNTHESIS WITH 3DIMENSIONS: GET YOUR OWN EXPERIENCE

This 90 minutes hands-on reading workshop on high-resolution Tomosynthesis with synthesized 2D is intended for radiologists interested in learning more about this breast cancer screening and diagnosis technology. The workshop is composed of a short introductory lecture followed by hands-on reading of selected cases. The workshop will include an interactive discussion of the presented cases in a learning oriented setup with maximum two participants per reading workstation.

Room MC3

Workshop slot: Friday, October 12, 16:00-17:30

Speaker: Lazarou, Athens/GR

The participation to all industry workshops is free of charge for EUSOBI delegates.

Please note that only a limited number of places are available and will be managed on a first come, first served basis. For registration or information about availability kindly contact the representatives at the Hologic Booth (North Hall No. 4).

INDUSTRY WORKSHOPS OF SIEMENS HEALTHINEERS



WIDE-ANGLE DIGITAL BREAST TOMOSYNTHESIS AND CONTRAST ENHANCED MAMMOGRAPHY READING SESSIONS

Learn about the value of wide-angle Digital Breast Tomosynthesis (DBT) and Contrast Enhanced Mammography (CEM) in the daily routine from one of our most experienced clinical experts. The differences and respective advantages of the morphological (DBT) and functional (CEM) breast imaging methods will be discussed. This, all with the flexible assistance of our multi-modality reading solution *syngo.via* and the *syngo*. Breast Care applications.

Room MC2

Workshop slots: Thursday, October 11, 15:30-16:30
Friday, October 12, 12:00-13:00
Friday, October 12, 15:15-16:15
Saturday, October 13, 09:45-10:45

Speaker: Luis Pina, Navarra/ES

AUTOMATED BREAST VOLUME SCANNER (ABVS) PHYSICIAN TRAINING WORKSHOP: AN INTERACTIVE LEARNING EXPERIENCE

Under the guidance of a breast imaging expert you will develop your skills in the interpretation of 3D breast ultrasound acquired with the ACUSON S2000™ Automated Breast Volume Scanner (ABVS), HELX Evolution with Touch Control and displayed on workstations equipped with *syngo*.Ultrasound Breast Analysis (sUSBA) Software. Active participation in real clinical cases will enable you to become familiar with the unique coronal plane while providing practical approaches to the interpretation of 3D automated breast ultrasound.

Room MC2

Workshop slots: Friday, October 12, 09:00-10:00
Friday, October 12, 14:00-15:00
Saturday, October 13, 14:15-15:15

Speaker: Ingolf Karst, Chicago/US

AI-BASED MAMMOGRAPHY READING: HANDS-ON SESSION

In this hands-on session, you will learn about the use of the AI-supported Transpara™ system from Screenpoint in combination with *syngo*.Breast Care to support 2D or 3D mammography reading. Transpara™ provides detection and decision support together with an overall exam based score for prioritization of reading. *syngo*.Breast Care is the advanced mammography reading and reporting solution of *syngo.via* from Siemens Healthineers. You will be guided through example cases and experience a case review session to explore the use of artificial intelligence in mammography reading.

Room MC2

Workshop slots: Thursday, October 11, 17:00-18:00
Friday, October 12, 10:30-11:30
Friday, October 12, 17:20-18:05
Saturday, October 13, 12:45-13:45

Speaker: Nico Karssemeijer, Nijmegen/NL

The participation to all industry workshops is free of charge for EUSOBI delegates.

Please note that only a limited number of places are available and will be managed on a first come, first served basis. For registration or information about availability, kindly contact the EUSOBI staff at the registration desk.

Lecture hall (Banqueting hall)	South Hall	North Hall	MC2 (Siemens Healthineers)
THURSDAY, OCTOBER 11, 2018			
14:20-14:30 Opening remarks			
14:30-15:30 BI-RADS® Multimodality Case Session			
	15:30-16:00 Coffee Break		15:30-16:30 Wide-angle Digital Breast Tomosynthesis and Contrast Enhanced Mammography
16:00-17:00 Interventional diagnostics and pre-operative management			
17:00-18:15 From hyperplasia to DCIS (B3 lesions/DCIS)			17:00-18:00 AI-based mammography reading: Hands-on session
FRIDAY, OCTOBER 12, 2018			
08:15-09:45 Tomosynthesis and screening			09:00-10:00 Automated Breast Volume Scanner (ABVS) Physician Training Workshop
09:45-10:30 Young Scientists' Session, Carla Boetes Young Investigator Award and awarding of the best submitted abstract			
	10:30-11:00 Poster Viewing	10:30-11:00 Coffee Break	10:30-11:30 AI-based mammography reading: Hands-on session
11:00-11:30 EUSOBI meets Saudi Arabia			
11:30-13:00 Ultrasound			12:00-13:00 Wide-angle Digital Breast Tomosynthesis and Contrast Enhanced Mammography
13:00-14:00 Industry-sponsored lunch symposium (Seno Medical Instruments, Inc.)			
14:00-15:30 MRI trending topics			14:00-15:00 Automated Breast Volume Scanner (ABVS) Physician Training Workshop
15:30-15:50 EUSOBI Award for the most quoted breast imaging paper published in European Radiology in 2015			15:15-16:15 Wide-angle Digital Breast Tomosynthesis and Contrast Enhanced Mammography
	15:50-16:20 Coffee Break		
16:20-17:20 Industry-sponsored symposia (Kheiron Medical Technologies / BD / Mammotome)			
17:20-18:20 Breast radiologist as therapist			17:20-18:05 AI-based mammography reading: Hands-on session

14:30-16:00

Optimizing Clinical Practice with Tomosynthesis and Synthesized 2D: Workshop for Experienced Readers

16:30-18:00

Contrast-Enhanced Mammography in Clinical Practice: Using I-View Software

10:00-11:30

Optimizing Clinical Practice with Tomosynthesis and Synthesized 2D: Workshop for Experienced Readers

12:00-13:30

Contrast-Enhanced Mammography in Clinical Practice: Using I-View Software

09:30-10:30

Clinical workflow using real-time breast biopsy imaging and Tomosynthesis guidance

9:45-10:30

GE Healthcare's Personalized Breast Care: A possible alternative to breast MRI – Senobright HD

15:30-16:30

Clinical workflow using real-time breast biopsy imaging and Tomosynthesis guidance

15:30-16:15

GE Healthcare's Personalized Breast Care: Reshaping the X-Ray guided biopsy procedures

16:00-17:30

High Resolution Tomosynthesis with 3Dimensions: Get your own Experience

16:20-17:50

Look differently at dense breast tissue – 3D Automated Breast Ultrasound

Lecture hall (Banqueting hall)	South Hall	North Hall	MC2 (Siemens Healthineers)
--------------------------------	------------	------------	----------------------------

SATURDAY, OCTOBER 13, 2018

08:00-08:30

General Assembly

08:30-09:00

EUSOBI Gold Medal

09:00-09:45

Breast Interpretation Competition

09:45-10:15

Poster
Viewing

9:45-10:15

Coffee
Break

09:45-10:45

Wide-angle Digital Breast
Tomosynthesis and Contrast
Enhanced Mammography

10:15-11:15

MDT Session

11:15-11:45

Key note lecture

11:45-12:45

Industry-sponsored lunch symposium (Fujifilm)

12:45-14:15

Metastatic disease

12:45-13:45

AI-based mammography
reading: Hands-on session

14:15-14:45

From the US Society of Breast Imaging (SBI)

14:15-15:15

Automated Breast Volume
Scanner (ABVS) Physician
Training Workshop

14:45-15:15

Coffee Break

15:15-16:45

AI (Artificial Intelligence) – The rise of the machines

16:45-17:00

Final closing remarks: Looking at Budapest 2019

MC3 (Hologic)

MC3.5 (Hologic)

10:30-11:30

Clinical workflow using
real-time breast biopsy
imaging and Tomosynthesis
guidance

12:00-13:30

Optimizing Clinical Practice
with Tomosynthesis and
Synthesized 2D: Workshop
for Experienced Readers

14:30-16:00

Contrast-Enhanced
Mammography in Clinical
Practice: Using I-View
Software

NOTES

Annual Scientific Meeting 2019

European Society of Breast Imaging




 **October 3-5, 2019**
Budapest/Hungary

BREAST IMAGING

In cooperation with the Breast Diagnostics Section
of the Hungarian Society of Radiologists





EUSOBI

europaan society of breast imaging

www.eusobi.org