



Reversible radiculomyelitis after ChAdOx1 nCoV-19 vaccination

Rossella Spataro ,^{1,2} Giacomo Fisco,² Vincenzo La Bella ¹

¹Department of Biomedicine, Neuroscience and Advanced Diagnostics, ALS Clinical Research Center, University of Palermo, Palermo, Italy
²IRCCS Centro Neurolesi Bonino Pulejo, Palermo, Italy

Correspondence to
Professor Vincenzo La Bella;
vincenzo.labella@unipa.it

Accepted 31 December 2021

SUMMARY

Adverse events occurring after SARS-CoV-2 vaccination have been reported and are the subject of ongoing research. We present the case of a young woman with fully reversible radiculomyelitis, which happened after the first dose of the ChAdOx1 nCOVID-19 vaccine. A previously healthy woman in her 20s presented with a subacute onset of legs' weakness and sensory disturbances, urinary dysfunction and cramping pain after receiving the first dose of the ChAdOx1 nCoV-19 vaccine. A diagnostic workup led to the diagnosis of inflammatory radiculomyelitis. Her clinical status improved, with complete recovery after a few months. The case described a reversible radiculomyelitis associated with the ChAdOx1 nCOVID-19 vaccine. The clinical picture and evolution supported the diagnosis. No other identifiable causes of myelopathy were found. Our patient showed clinically moderate symptoms and signs, showing good recovery. The post-vaccine inflammatory radiculomyelitis is a rare side effect of the anti-COVID-19 vaccination, and it should not discourage the SARS-CoV-2 vaccination programme.

BACKGROUND

The outbreak of the COVID-19 pandemic had caused devastating effects on the health, economic and social systems worldwide. The recent introduction of vaccinations has been a milestone, reversing the infection curve and counteracting the pandemic.

The European Medicines Agency (EMA) authorised four vaccines against COVID-19. One of these, that is, the ChAdOx1 nCOVID-19 vaccine (AstraZeneca), first raised safety concerns due to severe, though rare, side effects, as cerebral venous thrombosis.¹ However, this neurological side effect has now been reported with other vaccines.^{1,2} Furthermore, the safety analysis of data from 4 randomised trials has reported significant side effects in 79 out of 12 021 subjects (ie, 0.6%) receiving at least one dose of the ChAdOx1 nCOVID-19 vaccine.^{3,4}

Among the neurological side effects of the COVID-19 vaccines,^{1,2} several myelitis cases have now been described, primarily occurring days to weeks after vaccination.^{1,5,6}

Here, we report on the case of a young woman with subacute onset of radiculomyelitis after receiving the COVID-19, ChAdOx1 nCoV-19, vaccine with a favourable outcome and a complete recovery.

CASE PRESENTATION

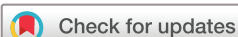A previously healthy woman in her 20s presented with about a subacute onset of legs' weakness,

cramping pain and fever (38°C–39°C) 3–4 days after receiving the first dose of the ChAdOx1 nCoV-19 vaccine. The fever receded with paracetamol in the following days, and the symptoms showed an apparent subjective improvement. However, though the patient still felt muscle tenderness, weakness and pain in the legs, she did not seek medical advice. Ten days to 12 days after presentation, the weakness in the lower limbs worsened, associated with mild urinary retention, increasing paraesthesia and sensory disturbances. The legs' weakness became so severe that she could not walk. She was immediately referred to the emergency unit of our hospital. At the examination, she was afebrile and with normal vital signs.

The neurological examination showed in both lower limb a 2/3 MRC (Medical Research Council) muscle strength proximally (iliopsoas and quadriceps) and distally (ankle dorsiflexion and plantar flexion), mild spasticity, very brisk patellar, abductor and Achilles tendon reflexes with horizontal and vertical extension, and legs paraesthesia. Tactile and pinprick sensation was decreased from T4 dermatome downward. Passive and active leg movements elicited rigidity and tenderness. Babinski sign was equivocal bilaterally. As she had mild retention, a urinary catheter was inserted. All other aspects of the neurological examination, particularly the upper limbs and cranial nerves, were normal.

INVESTIGATIONS

An extensive biochemical workup, including blood cell counts, electrolytes, kidney and liver parameters and urine analysis, gave negative results. Serum antibodies to SARS-CoV-2 were within the normal range. Autoimmune screening (ie, anti-nuclear, anti-extractable nuclear antigen, anti-DNA, anti-gliadin, anti-transglutaminase, anti-endomysial, anti-thyroid peroxidase and anti-thyroglobulin antibodies) was negative. Cerebrospinal fluid (CSF) analysis showed increased proteins, average glucose and 2 cells/ μ L (primarily lymphocytes). Oligoclonal bands were detected in both serum and CSF with a pattern IV. PCR real-time analysis for Herpes Simplex Virus (HSV1, HSV2), Varicella Zoster Virus (VZV), Epstein-Barr Virus (EBV), Cytomegalovirus (CMV), Human Herpesvirus (HHV6, HHV8), *Mycobacterium tuberculosis* and *Enterovirus* in CSF was negative. Main laboratory data are given in table 1.



© BMJ Publishing Group Limited 2022. No commercial re-use. See rights and permissions. Published by BMJ.

To cite: Spataro R, Fisco G, La Bella V. *BMJ Case Rep* 2022;**15**:e247472. doi:10.1136/bcr-2021-247472

Table 1 Laboratory data

Variable	Reference range, adults	On admission
Glucose (mg/dL)	70–100	82
Creatinine (mg/dL)	0.5–0.95	0.61
Urea nitrogen (mg/dL)	10–50	24
Albumin (g/dL)	3.5–5.2	4.2
Alanine aminotransferase (U/L)	0–31	21
Aspartate aminotransferase (U/L)	0–31	12
Alkaline phosphatase (U/L)	35–104	64
Total bilirubin (mg/dL)	0–1.2	1.19
Direct bilirubin (mg/dL)	0–0.30	0.4
Sodium (mmol/L)	136–145	139
Potassium (mmol/L)	3.3–5.1	4.18
Chloride (mmol/L)	93–108	100
C reactive protein (mg/L)	0–5	6.3
Creatine kinase (U/L)	26–192	54
Lactate dehydrogenase (U/L)	50–250	211
Hematocrit (%)	35–48	40
Haemoglobin (g/L)	120–160	120
Red cell count (x10 ¹² /L)	3.8–5.0	4.05
White cell count (x10 ⁹ /L)	4000–11 000	7780
Differential count (μL)		
Neutrophils	2000–8000	4620
Lymphocytes	1000–5000	2230
Monocytes	160–1000	690
Eosinophils	20–800	200
Immature granulocytes	0–100	40
Platelets count (x10 ⁹ /μL)	150–450	304
D-dimer (ng/mL)	<500	486
Erythrocyte sedimentation rate (mm/hour)	0–13	28
Prothrombin time (s)	24–36	31
Prothrombin-time international normalised ratio	0.9–1.1	1.05
CSF analysis		
Colour	Colourless	Colourless
Turbidity	Clear	Clear
Proteins (mg/dL)	0–35	114
Glucose (mg/dL)	40–70	59
Red cell count (μL)	0–5	1
Nucleated-cell count (μL)	0–5	7
Differential count (%)		
Neutrophils	0	0
Lymphocytes	0–100	90
Monocytes	0–100	10
Eosinophils	0	0
Immature granulocytes	0	0
Oligoclonal bands in CSF	No banding seen	Oligoclonal bands seen in both serum and CSF, pattern IV

CSF, cerebrospinal fluid.

MRI of the brain and spinal cord showed no parenchymal hyperintensities, and gadolinium administration did not show enhancement. Electromyography/Electroneurography of the upper and lower limbs and motor/sensory evoked potentials were negative.

A diagnosis of post-vaccine inflammatory radiculomyelitis with no imaging changes, likely linked to the former anti-COVID-19 vaccination, was made.^{7–9}

TREATMENT

The patient was treated with a course of morning high-dose methylprednisolone (ie, 1 g intravenous for 5 days), followed by morning intramuscular 4 mg betamethasone injection for additional 15 days with a noticeable improvement. The urinary catheter was removed, and she was discharged at home, able to walk with a double cane.

OUTCOME AND FOLLOW-UP

At the first follow-up 4 weeks later, she reported a further clinical improvement. The neurological examination showed a mild spastic paraparesis with an uncertain but autonomous gait. Sensory abnormalities and muscle tenderness had disappeared. A novel post-contrast spinal MRI was normal.

A nearly complete recovery was observed at 2-month follow-up, and she could walk almost normally.

DISCUSSION

We have described a case with an inflammatory radiculomyelitis after the ChAdOx1 nCOVID-19 vaccination.^{5,6} Several lines of evidence supported the diagnosis: the patient presented with a subacute onset of leg weakness with brisk reflexes, mild urinary dysfunction and a medullary level of sensory disturbances. Distal nerve conduction studies were negative.

Although MRI studies of the spine showed no signal change, neither in basal conditions nor after gadolinium, the patient significantly improved after intravenous methylprednisolone. This result is not surprising as up to 40% of the acute inflammatory myelopathies do not show post-contrast MRI enhancement.^{8,9}

At present, the EMA has approved for use four vaccines for COVID-19 vaccination, that is, two adenoviruses encoding the SARS-CoV-2 spike (S) glycoprotein (ChAdOx1 nCOVID-19, AstraZeneca; Ad26.CoV2-s, Johnson & Johnson's Janssen), and two mRNA vaccines encoding the viral spike protein of SARS-CoV-2 (Pfizer-BioNTech and Moderna).¹⁰ According to the 'European Commission' COVID-19 dataset, some 76% of Europeans are vaccinated,¹⁰ with Portugal and Spain having the highest vaccination rate.¹¹ The WHO, but not the Food and Drug Administration and EMA, approved virus-inactivated COVID-19 vaccines (ie, BBV152, BBIBP-CoV and CoronaVac). These vaccines are now used mainly in Africa, South America and Asia.¹²

The extensive anti-Covid-19 vaccination campaign has raised concerns about the possible neurological consequences of vaccines. Since early 2021, neurological adverse events have been reported, ranging from mild (eg, myalgia, pain and headache) to severe cerebral venous sinus thrombosis (VST) and peripheral and central nervous system diseases.^{1,2,5} Exacerbation of known autoimmune diseases of the central (eg, multiple sclerosis and neuromyelitis optica) or peripheral (eg, myasthenia gravis and chronic autoimmune demyelinating polyneuropathy) nervous system has also been described.^{13–16}

The most common central and peripheral neurological adverse events after COVID-19 vaccination, besides the VST, are the acute autoimmune disseminated encephalomyelopathy and post-vaccine encephalitis, acute encephalopathy, transverse myelitis, Guillain-Barré polyneuropathy, Bell's palsy (often bilateral, with facial diplegia), Parsonage-Turner syndrome and small fibre neuropathy.¹²

Transverse myelitis and radiculomyelitis have been described after post-COVID-19 infection,^{6,9,17} and now a growing number of cases have been reported after administration of a SARS-CoV-2

vaccine.^{1 2 5 18–22} All EMA-approved COVID-19 vaccines have been associated with transverse myelitis and radiculomyelitis. Reports on central and peripheral neurological adverse events from virus-inactivated vaccines are anecdotal.

Our radiculomyelitis case occurred after a ChAdOx1 nCOVID-19 AstraZeneca vaccination and responded well to methylprednisolone therapy with a complete recovery.

The occurrence of post-vaccine acute myelitis (any type) is exceedingly rare, accounting for only 37 cases spanning 39 years and showing a temporal association from a few days up to 3 months.²³ In addition, from December 2010 through July 2021, there have been only 19 published cases of post-vaccination transverse myelitis.⁵ The post-COVID-19 vaccination myelitis is similarly rare, with 20/10⁶ cases after ChAdOx1 nCovid-19 AstraZeneca vaccination and 6/10⁶ cases after mRNA-based vaccine BNT162b2 Pfizer–Biotech reported in a case series.¹⁴

In summary, neurological complications after COVID-19 vaccination are infrequent. A good outcome, often with a complete recovery, has been documented in most cases after appropriate treatment with plasmapheresis, intravenous immunoglobulin or high-dose methylprednisolone.²⁴ Therefore, the sporadic occurrence of nervous system adverse events should not discourage subjects at risk for COVID-19 infection from vaccination.

The specific pathogenic pathway leading to post-COVID-19-vaccination acute/subacute central and peripheral nervous system complications, including our case of inflammatory radiculomyelitis, is unclear. Immune mechanisms are very likely, possibly through molecular mimicry.^{1 24}

In conclusion, our post-ChAdOx1 nCOVID-19 vaccine radiculomyelitis case remains a very infrequent vaccine complication. It was mild, with an excellent middle-term prognosis and complete recovery.

Learning points

- ▶ Neurological complications have been described after CoV-19 infection.
- ▶ Possible neurological consequences of the SARS-CoV-2 vaccination are the subject of reporting and ongoing research.
- ▶ Inflammatory radiculomyelopathy post-SARS-CoV-2 vaccination is rare. The case presented showed that the diagnosis is mainly based on history, neurological signs and cerebrospinal fluid analysis. The imaging studies can be negative.
- ▶ Outcome can be favourable, and improvement may be fostered by intravenous high-dose methylprednisolone.

Contributors RS and GF described the case and wrote the manuscript. VLB reviewed the case, edited the manuscript and made substantial changes.

Funding The authors have not declared a specific grant for this research from any funding agency in the public, commercial or not-for-profit sectors.

Competing interests None declared.

Patient consent for publication Consent obtained directly from patient(s).

Provenance and peer review Not commissioned; externally peer reviewed.

Case reports provide a valuable learning resource for the scientific community and can indicate areas of interest for future research. They should not be used in isolation to guide treatment choices or public health policy.

ORCID iDs

Rossella Spataro <http://orcid.org/0000-0002-8910-3131>

Vincenzo La Bella <http://orcid.org/0000-0003-2045-1864>

REFERENCES

- 1 Garg KR, Pallavi VK. Spectrum of neurological complications following COVID-19 vaccination. *Neurol Sci* 2021;1–38.
- 2 Finsterer J. Neurological side effects of SARS-CoV-2 vaccinations. *Acta Neurol Scand* 2022;145:5–9.
- 3 Voysey M, Clemens SAC, Madhi SA, et al. Safety and efficacy of the ChAdOx1 nCoV-19 vaccine (AZD1222) against SARS-CoV-2: an interim analysis of four randomised controlled trials in Brazil, South Africa, and the UK. *Lancet* 2021;397:99–111.
- 4 Knoll MD, Wonodi C. Oxford–AstraZeneca COVID-19 vaccine efficacy. *The Lancet* 2021;397:72–4.
- 5 Khan E, Shrestha AK, Colantonio MA. Acute transverse myelitis following SARS-CoV-2 vaccination: a case report and review of the literature. *J Neurol* 2021;1–12.
- 6 Román GC, Gracia F, Torres A, et al. Acute transverse myelitis (ATM): clinical review of 43 patients with COVID-19-associated ATM and 3 post-vaccination ATM serious adverse events with the ChAdOx1 nCoV-19 vaccine (AZD1222). *Front Immunol* 2021;12:653786e1–e11.
- 7 Transverse Myelitis Consortium Working Group. Proposed diagnostic criteria and nosology of acute transverse myelitis. *Neurology* 2002;59:499–505.
- 8 Scotti G, Gerevini S. Diagnosis and differential diagnosis of acute transverse myelopathy. The role of neuroradiological investigations and review of the literature. *Neurol Sci* 2001–569–73.
- 9 Abrams RMC, Safavi F, Tuhim S, et al. MRI negative myelopathy post mild SARS-CoV-2 infection: vasculopathy or inflammatory myelitis? *J Neurovirol* 2021;27:650–5.
- 10 European Commission. Available: <https://ec.europa.eu>
- 11 *Our World in Data*. Available: https://ourworldindata.org/covid-vaccinations?country=OWID_WRL
- 12 WHO. Available: <https://covid19.trackvaccines.org/types-of-vaccines/>
- 13 Khayat-Khoei M, Bhattacharyya S, Katz J. COVID-19 mRNA vaccination leading to CNS inflammation: a case series. *J Neurol* 2021;1–14.
- 14 Kaulen LD, Doubrovinskaia S, Mooshage C, et al. Neurological autoimmune diseases following vaccinations against SARS-CoV-2: a case series. *Eur J Neurol* 2021;1–9.
- 15 Spataro S. Unpublished observations.
- 16 Suri V, Pandey S, Singh J, et al. Acute-onset chronic inflammatory demyelinating polyneuropathy after COVID-19 infection and subsequent ChAdOx1 nCoV-19 vaccination. *BMJ Case Rep* 2021;14:e245816–e4.
- 17 Zachariadis A, Tulbu A, Strambo D, et al. Transverse myelitis related to COVID-19 infection. *J Neurol* 2020;267:3459–61.
- 18 Gao J-J, Tseng H-P, Lin C-L, et al. Acute transverse myelitis following COVID-19 vaccination. *Vaccines* 2021;9:1008–e7.
- 19 Malhotra HS, Gupta P, Prabhu V, et al. COVID-19 vaccination-associated myelitis. *QJM: Intl J Med* 2021;114:591–3.
- 20 Notghi AAA, Atley J, Silva M. Lessons of the month 1: longitudinal extensive transverse myelitis following AstraZeneca COVID-19 vaccination. *Clin Med* 2021;21:e535–8.
- 21 Pagenkopf C, Südmeyer M. A case of longitudinally extensive transverse myelitis following vaccination against Covid-19. *J Neuroimmunol* 2021;358:577606–e5.
- 22 Tahir N, Koorapati G, Prasad S, et al. SARS-CoV-2 vaccination-induced transverse myelitis. *Cureus*;59:e16624e1–5.
- 23 Agmon-Levin N, Kivity S, Szyper-Kravitz M, et al. Transverse myelitis and vaccines: a multi-analysis. *Lupus* 2009;18:1198–204.
- 24 Ismail II, Salama S. A systematic review of cases of CNS demyelination following COVID-19 vaccination. *J Neuroimmunol* 2022;362:577765–e16.

Copyright 2022 BMJ Publishing Group. All rights reserved. For permission to reuse any of this content visit <https://www.bmj.com/company/products-services/rights-and-licensing/permissions/>
BMJ Case Report Fellows may re-use this article for personal use and teaching without any further permission.

Become a Fellow of BMJ Case Reports today and you can:

- ▶ Submit as many cases as you like
- ▶ Enjoy fast sympathetic peer review and rapid publication of accepted articles
- ▶ Access all the published articles
- ▶ Re-use any of the published material for personal use and teaching without further permission

Customer Service

If you have any further queries about your subscription, please contact our customer services team on +44 (0) 207111 1105 or via email at support@bmj.com.

Visit casereports.bmj.com for more articles like this and to become a Fellow