



Contents lists available at ScienceDirect

International Journal of Surgery Case Reports

journal homepage: www.casereports.com

A rare case of infrarenal aortic coarctation in a young female

Ettore Dinoto^{a,*}, Felice Pecoraro^{a,b}, Francesca Ferlito^a, Antonio Peluso^c, Guido Bajardi^{a,b}^a Vascular Surgery Unit – AOUP Policlinico 'P. Giaccone', Palermo, Italy^b Department of Surgical, Oncological and Oral Sciences – University of Palermo, Italy^c Department of Public Health, Vascular Surgery Unit, University Federico II of Naples, Naples, Italy

ARTICLE INFO

Article history:

Received 25 June 2020

Received in revised form 26 July 2020

Accepted 27 July 2020

Available online 24 August 2020

Keywords:

Secondary hypertension

Aortic coarctation

Renal stenting

Endovascular

Percutaneous

Case report

ABSTRACT

INTRODUCTION: Infrarenal abdominal aortic coarctation (AAC) is an extremely rare disease. It can be associated with renal artery stenosis determining secondary renal hypertension.

PRESENTATION OF CASE: We report a case of AAC in young female patient presenting systemic hypertension non-responder to medical treatment. Diagnostics revealed the involvement of the right renal artery as the cause of hypertension. The management consisted of percutaneous renal artery stenting and close surveillance for the aortic segment. The treatment was uneventful with resolution of the hypertensive condition.

DISCUSSION: AAC etiology is unknown. There are no studies comparing the long-term treatment outcome in adult patients. The long-term prognosis depends mainly on blood pressure control and the underlying disease. In the reported case the treatment of the renal lesion was adequate to control the secondary hypertension. This approach does not preclude future intervention in the aortic segment and provides a fast-recovery and less invasive approach to the major clinical manifestation.

CONCLUSION: In this case the treatment of the specific vascular lesion was adequate to address the main clinical hypertensive manifestation. This less-invasive approach did not preclude future intervention in the aortic segment where the evolution of the disease is unknown.

© 2020 The Author(s). Published by Elsevier Ltd on behalf of IJS Publishing Group Ltd. This is an open access article under the CC BY-NC-ND license (<http://creativecommons.org/licenses/by-nc-nd/4.0/>).

1. Introduction

The abdominal aortic coarctation (AAC) represents a rare localization with a reported incidence of 1–2% of all aortic coarctation. AAC is secondary to a stenosis or a hypoplastic aortic segment and usually involves the para or suprarenal renal aortic segment. AAC is associated to renal or mesenteric artery stenosis in 60% and 30% respectively; it is an unusual cause of essential hypertension in adults [1]. A limited number of patients presenting AAC have been described in the literature. Thus we report a single case of AAC in a young female patient. This work has been written in accordance with the SCARE criteria [2].

2. Presentation of case

A 27-year-old woman with uncontrollable hypertension was referred to our hospital. At history she referred progressing pain in

right side flank from a month, she referred to be in treatment with non-steroidal anti-inflammatory drugs. The patient denied any previous family history of similar pathology, but her father was suffering from severe renal failure with polycystic kidney. On physical examination, systemic pressure was 170/100 mmHg with 100 b/m. Auscultation of the abdomen revealed an epigastric systolic bruit. Electrocardiogram showed sinus tachycardia. Abdominal duplex ultrasound (DUS) showed a 90% right renal artery stenosis (Peak systolic velocity 450 cm/s); increased aortic wall thickness (4.7 mm), a reduced aortic lumen in the infrarenal segment Resistive Index (RI) of 0.81; blood flow was preserved in the femoral arteries and decreased in both legs. The subsequent CT-angiography showed any alteration in the thoracic aorta. In the abdominal segment, the CT-angiography confirmed a significant aortic diameter reduction in correspondence of the infrarenal segment with a 5.5 mm patent aortic residual lumen. In addition, the significant right renal artery stenosis (90%) was associated to a reduced right kidney vascularization (Figs. 1–3).

An endovascular approach was chosen in order to address the hypertensive state secondary to the right renal artery approach. In our vascular operating room, under general anesthesia and systemic heparinization (ACT > 250 s), we used a left brachial access with 5F×90 cm (Destination; (Terumo Europe, Leuven,

* Corresponding author at: Vascular Surgery Unit, AOUP Policlinico 'P. Giaccone', Via Liborio Giuffrè, 5, Palermo, Italy.

E-mail addresses: ettoredinoto@gmail.com, ettore.dinoto@policlinico.pa.it (E. Dinoto).

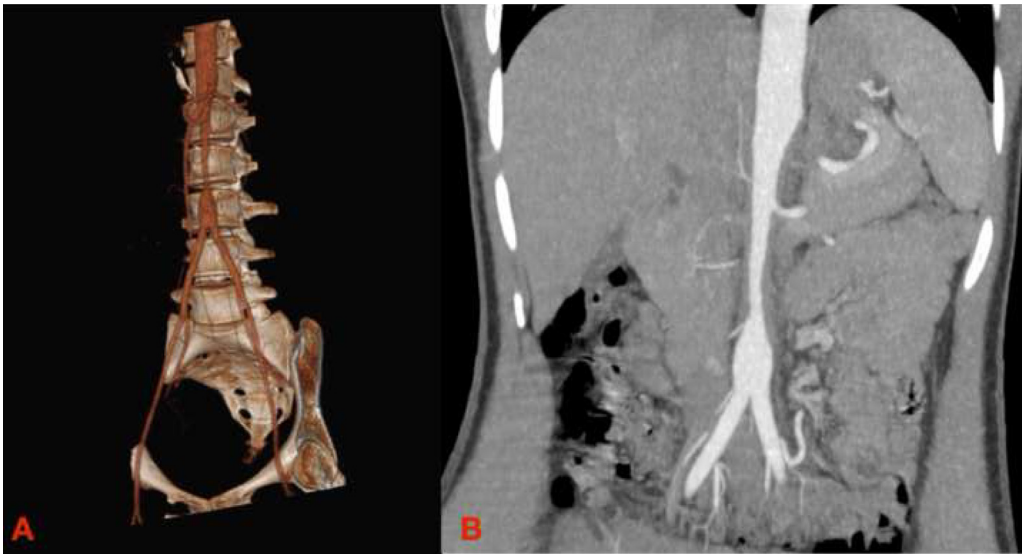


Fig. 1. CT Angiography 3-dimensional volume rendering (A) and MPR (B) preoperative.

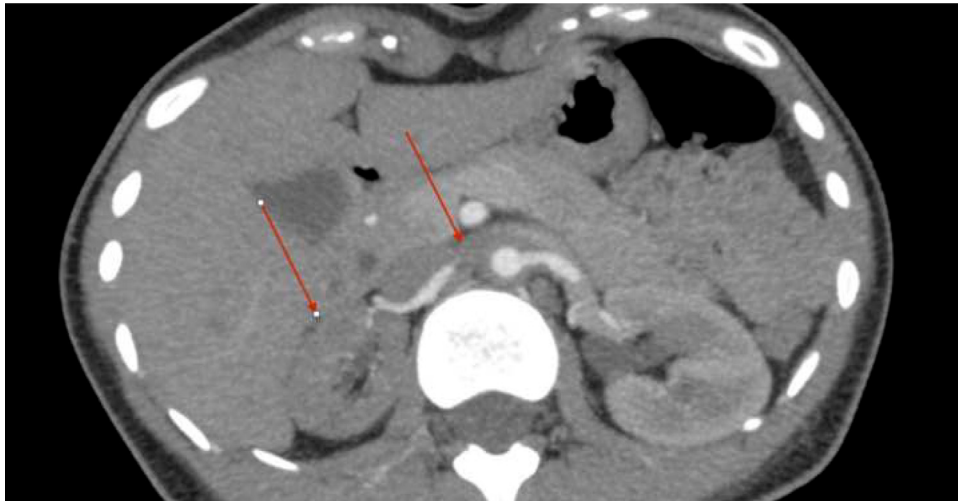


Fig. 2. CT Angiography preoperative with evident decrease of vascularization of right kidney.

Belgium) sheath. A secondary left femoral access was employed for angiographic control using a 5F (Avanti+, Cordis Corporation, Bridgewater, NJ, USA) sheath and to eventually perform a through-and-through body wire [3]. The right renal artery was engaged from the brachial access using a .014 Command wire (Abbott Vascular, Clonmel, Tipperary, Ireland.) using the same technique to address renal artery diseases [4]. A Hippocampus stent 6 × 20 mm (Medtronic, Santa Rosa, Calif) (Fig. 4) was deployed in correspondence of the diseased right renal artery. Multiple inflations were performed using a 5 × 20 Mustang balloon (Boston Scientific, Marlborough, Massachusetts, United State) without achievement of full expansion. Invasive pressure gradient showed no difference between suprarenal aortic pressure and renal artery distal to the deployed stent. (Fig. 5). After three days from the index procedure, systemic pressure was normalized (110/70 mmHg with 70

b/m) without the use antihypertensive therapy and the epigastrium systolic bruit became undetectable. The postoperative CT angiography confirmed proper positioning of the intravascular device and complete revascularization of the right kidney. The DUS at 7 days showed no significant acceleration at the level of the treated right renal artery with an RI of 0.68. Follow-up consisted of DUS (4 weeks and 3 months) and CT (6 months) with visualization of stent patency, without evolution of aortic disease.

3. Discussion

AAC etiology is unknown, proposed mechanisms are anomalous development, infection, obliterative panarteritis and fibromuscular dysplasia. The presence or absence of histological variants play a key role in the arterial wall. It is possible to distinguish an inflamma-

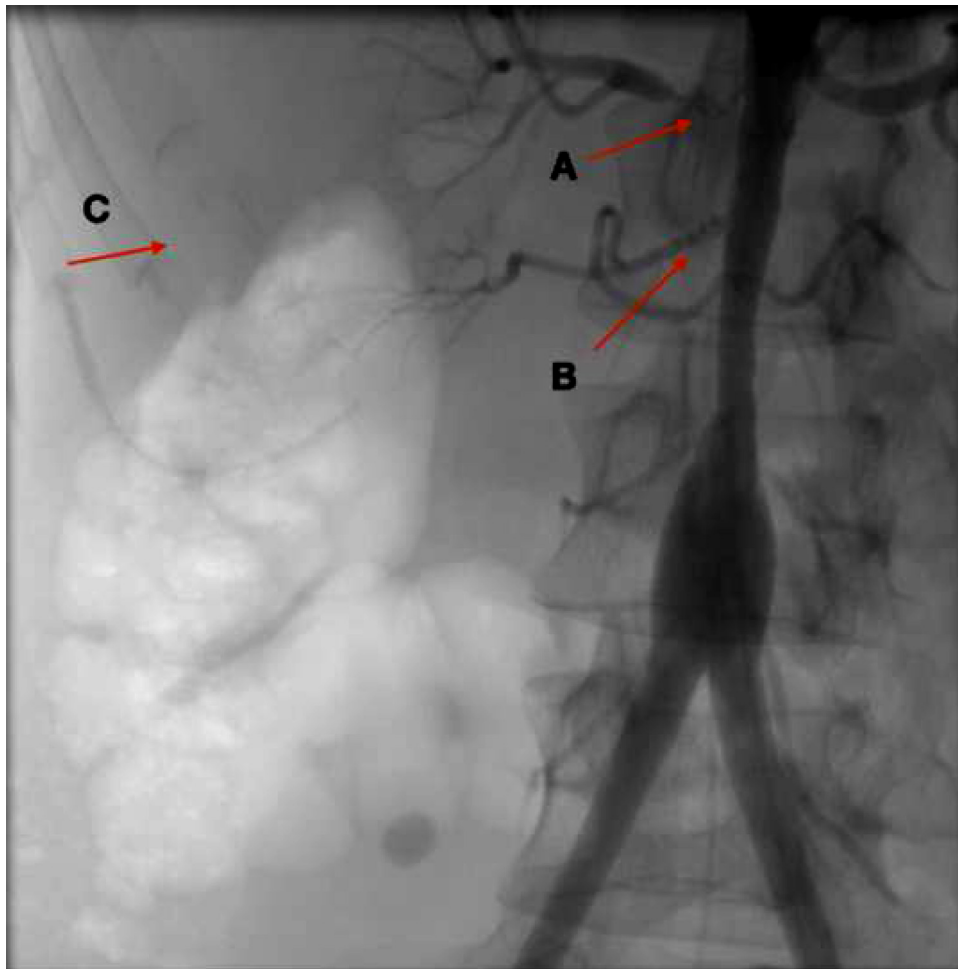


Fig. 3. Initial angiography with severe right renal artery stenosis (A), severe stenosis of polar renal artery (B) determining a poor vascularization of right kidney.

tory variant, where the most common cause is Takayasu arteritis, and a non-inflammatory as in the case of fibromuscular dysplasia [5,6]. In this case the absence of lesions in thoracic aorta and the intraoperative finding of several signs fibromuscular dysplasia allowed us to suppose a non-inflammatory etiology. Takayasu disease has a poorer prognosis [7]. The non-inflammatory AAC variant, as reported in this case, is generally associated with severe hypertension. The choice to address renal artery disease was related to the patient's severe hypertensive state uncontrolled by medical therapy and the absence of peripheral arterial symptoms.

A four types AAC classification has been described according to renal artery involvement and coarctation extension. Type I includes suprarenal coarctation and renal artery stenosis; type II, infrarenal coarctation and renal artery stenosis; type III, suprarenal coarctation and normal renal arteries; and type IV, infrarenal coarctation and normal renal arteries. Patients typically present between the second and third decades of life with uncontrolled hypertension secondary to renal artery stenosis. In the literature cases with claudication and mesenteric ischemia were also reported [8].

Due to AAC rarity, there are no studies comparing the long-term treatment outcome in adult patients. Therefore, the best therapeutic option should consider several aspects, such as the

anatomy of the aorta (tortuous vessels, length of the hypoplastic segment), stenosis in other arteries (renal, mesenteric), and the trans-coarctation gradient. Intravascular ultrasound can be employed to assess such anatomic information [9].

In these circumstances distal embolic protection devices for renal artery were not considered according to intraoperative findings of renal fibromuscular dysplasia [10]. The long-term prognosis depends mainly on blood pressure control and the underlying disease [3]. In our case we preferred to treat the main lesion in right renal artery, trigger of the severe hypertension and its related complications. The lack peripheral arterial symptoms was the basis to not address the aortic coarctation with the potential to postpone the aortic treatment.

4. Conclusions

AAC is a rare cause of hypertension in adult patients. Percutaneous treatments of specific vascular lesions responsible of clinic complications may be an excellent alternative in selected cases to open treatments which are more invasive and present a higher intraoperative risk in the attempt to have a complete resolution on aortic problem. Long follow-up is needed to assess risks and benefits of these procedures.

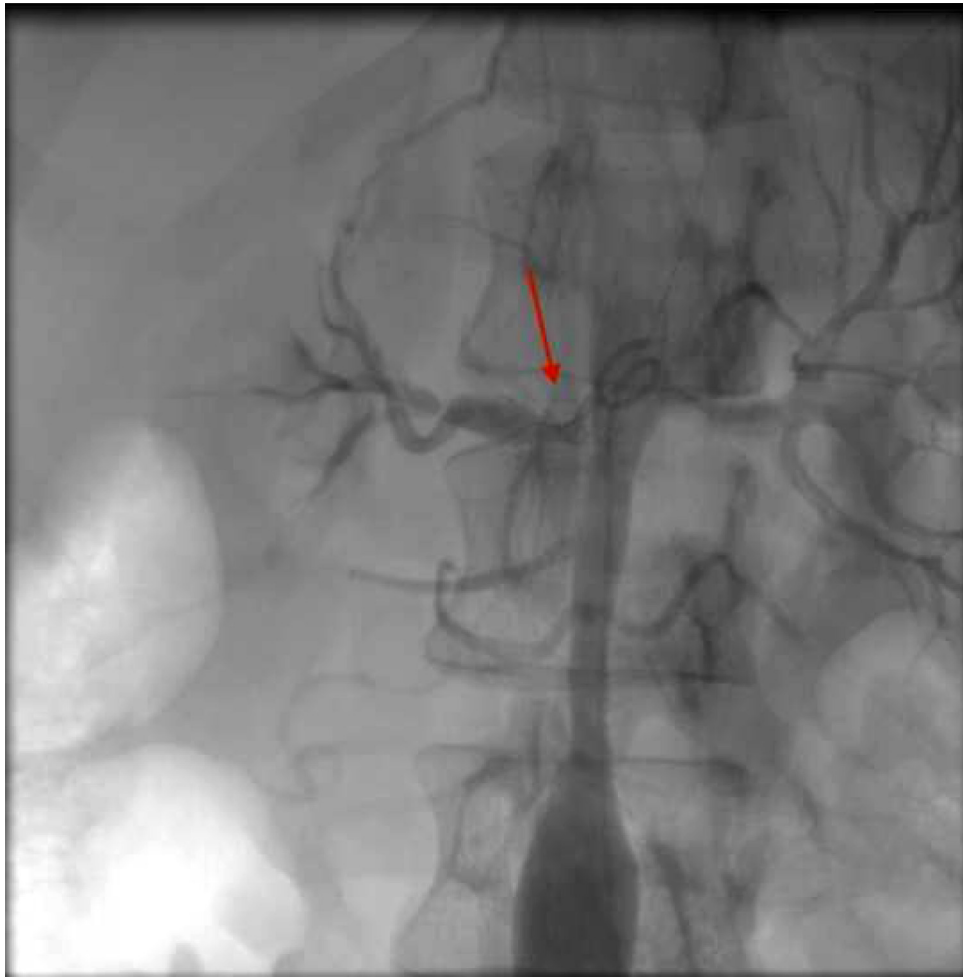

Fig. 4. Angiography after release of stent.

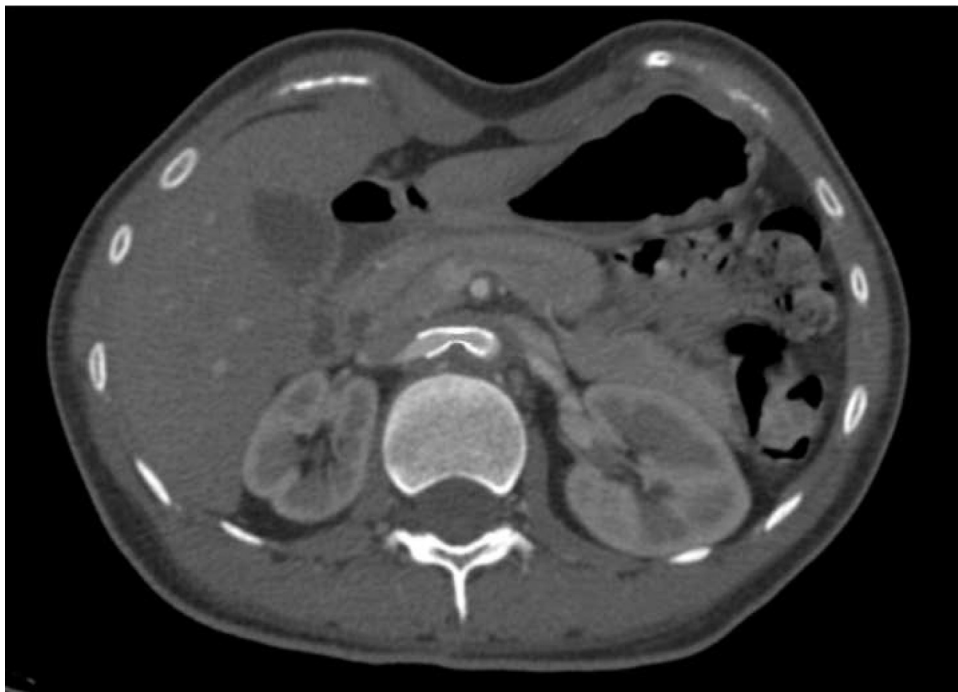

Fig. 5. CT scan postoperative showing an improvement of kidney vascularization after stenting.

Funding

None.

Ethical approval

Exempt from ethical approval.

Consent

Informed Consent was obtained from the patient for presentation of the details of this case, along with the images for the purposes of publication. No personal identification information has been displayed in the images. A copy of the written consent is available for review by the Editor-in-Chief of this journal on request.

Author contribution

Ettore Dinoto: study concept, design, data collection, data analysis, interpretation, writing the paper, final approval of the version to be submitted.

Felice Pecoraro: study concept, design, data collection, data analysis, interpretation, writing the paper, final approval of the version to be submitted.

Francesca Ferlito: study concept, design, data collection, data analysis, interpretation, final approval of the version to be submitted.

Antonio Peluso: study concept, design, data collection, final approval of the version to be submitted.

Guido Bajardi: study concept, design, data collection, data analysis, interpretation, final approval of the version to be submitted.

Registration of research studies

N/A.

Guarantor

Ettore Dinoto.

Provenance and peer review

Not commissioned, externally peer-reviewed.

Declaration of Competing Interest

The authors report no declarations of interest.

Acknowledgements

This article is part of a supplement entitled Case reports from Italian young surgeons, published with support from the Department of Surgical, Oncological and Oral Sciences - University of Palermo.

References

- [1] J.M. Guía, F.J. Castro, M. Gracián, A. Gilabert, E. García, [Coarctation of the abdominal aorta. Treatment by stent placement], *Rev. Esp. Cardiol.* 54 (November (11)) (2001) 1332–1335.
- [2] R.A. Agha, M.R. Borrelli, R. Farwana, K. Koshy, A. Fowler, D.P. Orgill, For the SCARE Group, The SCARE 2018 statement: updating consensus surgical Case REport (SCARE) guidelines, *Int. J. Surg.* 60 (2018) 132–136.
- [3] C.P. van der Zee, M.J. van der Laan, E. Dinoto, I. Tielliu, C.J. Zeebregts, T.A. Vainas, Different angle in through-and-through body wires in difficult aortic arch stent-graft placement, *J. Cardiovasc Surg (Torino)* 60 (February(1)) (2019) 144–146.
- [4] U.M. Bracale, D. Narese, I. Ficarelli, M.D. Laurentis, F. Spalla, E. Dinoto, et al., Stent-assisted detachable coil embolization of wide-necked renal artery aneurysms, *Diagn. Interv. Radiol. Ank. Turk.* 23 (February (1)) (2017) 77–80.
- [5] R. Martín-Reyes, A. Sánchez-Recalde, R. Moreno, M.A. Navas-Lobato, [Atypical aortic coarctation in adult patients undergoing percutaneous stent implantation], *Rev. Esp. Cardiol.* 60 (November (11)) (2007) 1212–1213.
- [6] C. Salmoukas, S. Ruemke, Jh Bräsen, A. Haverich, Oe. Teebken, Renal artery revascularization by using the Riolan anastomosis as feeding vessel in a patient with abdominal aortic coarctation due to fibromuscular dysplasia, *VASA Z. Gefasskrankheiten* 46 (July (4)) (2017) 313–318.
- [7] L.F. Valenzuela García, R. Vázquez García, L. Pastor Morales, R. Calvo Jambrina, M.J. Rodríguez Hernández, I. Font Cabrera, et al., [Aortic coarctation: different anatomo-clinical forms depending on the age of presentation], *Rev. Esp. Cardiol.* 51 (July (7)) (1998) 572–581.
- [8] S. Yuksel, M. Elmali, K. Durna, S.M. Nuro, An interesting case of infrarenal aortic coarctation without any complication, *Int. J. Cardiol.* 128 (August (1)) (2008) e3–5.
- [9] F. Pecoraro, U.M. Bracale, A. Farina, G. Badalamenti, F. Ferlito, M. Lachat, et al., Single-center experience and preliminary results of intravascular ultrasound in endovascular aneurysm repair, *Ann. Vasc. Surg.* 56 (April) (2019) 209–215.
- [10] F. Pecoraro, E. Dinoto, D. Pakeliani, F. Ferlito, D. Mirabella, M. Lachat, et al., Endovascular treatment of spontaneous internal carotid artery dissection with proximal embolic protection device, *Ann. Vasc. Surg.* (January (2)) (2020).

Open Access

This article is published Open Access at [sciencedirect.com](https://www.sciencedirect.com). It is distributed under the [IJSCR Supplemental terms and conditions](#), which permits unrestricted non commercial use, distribution, and reproduction in any medium, provided the original authors and source are credited.