



Article

# Nerve Regeneration after a Nerve Graft in a Rat Model: The Effectiveness of Fibrin Glue

Giovanni Zabbia <sup>1</sup>, Francesca Toia <sup>1</sup> , Federico Coppola <sup>1,\*</sup>, Giovanni Cassata <sup>2</sup>, Luca Cicero <sup>2</sup>, Giuseppe Giglia <sup>3</sup> , Roberto Puleio <sup>4</sup> and Adriana Cordova <sup>1</sup>

<sup>1</sup> Plastic and Reconstructive Surgery, Department of Precision Medicine in Medical, Surgical and Critical Care, University of Palermo, Via del Vespro 129, 90127 Palermo, Italy; giovanni.zabbia@policlinico.pa.it (G.Z.); francesca.toia@unipa.it (F.T.); adriana.cordova@unipa.it (A.C.)

<sup>2</sup> Centro Mediterraneo Ricerca e Training (Ce.Me.Ri.T), Istituto Zooprofilattico Sperimentale della Sicilia "A. Mirri", 90129 Palermo, Italy; giovanni.cassata@izssicilia.it (G.C.); luca.cicero@izssicilia.it (L.C.)

<sup>3</sup> Department of Biomedicine, Neuroscience and Advanced Diagnostics (BiND), Section of Human Physiology, University of Palermo, 90127 Palermo, Italy; giuseppe.giglia@unipa.it

<sup>4</sup> Laboratorio Istopatologia e Immunoistochimica, Dipartimento Ricerca Biotecnologica e Diagnostica Specialistica, Istituto Zooprofilattico Sperimentale della Sicilia "A. Mirri", 90129 Palermo, Italy; roberto.puleo@izssicilia.it

\* Correspondence: federico.coppola@unipa.it

**Abstract:** Background: Simulating the post-traumatic continuity defect of small human peripheral nerves, we compared the effectiveness of fibrin glue with neuroorrhaphy for nerve gap restoration. Methods: In twenty-four male Wistar rats, a fifteen mm defect in one sciatic nerve only was made and immediately repaired with an inverted polarity autograft. According to the used technique, rats were divided into Group A (Control), using traditional neuroorrhaphy, and Group B (Study), using fibrine glue sealing; in total, 50% of rats were sacrificed at 16 weeks and 50% at 21 weeks. Before sacrifice, an assessment of motor function was done through Walking Track Analysis and an electroneurophysiological evaluation. After sacrifice, selected muscle mass indexes and the histology of the regenerated nerves were assessed. All data were evaluated by Student's *t* test for unpaired data. Results: No significant differences were found between the two groups, with only the exception of a relative improvement in the tibialis anterior muscle's number of motor units in the study group. Conclusion: Despite the fact that the use of fibrin glue as a nerve sealant is not superior in terms of functional recovery, its effectiveness is comparable to that of microsurgical repair. Hence, the faster and technically easier glueing technique could deserve broader clinical application.

**Keywords:** nerve injury; nerve regeneration; nerve repair; fibrin glue; peripheral nerve injuries



**Citation:** Zabbia, G.; Toia, F.; Coppola, F.; Cassata, G.; Cicero, L.; Giglia, G.; Puleio, R.; Cordova, A. Nerve Regeneration after a Nerve Graft in a Rat Model: The Effectiveness of Fibrin Glue. *J. Pers. Med.* **2024**, *14*, 445. <https://doi.org/10.3390/jpm14050445>

Academic Editor: Juan J. Salazar Corral

Received: 7 March 2024

Revised: 11 April 2024

Accepted: 22 April 2024

Published: 24 April 2024



**Copyright:** © 2024 by the authors. Licensee MDPI, Basel, Switzerland. This article is an open access article distributed under the terms and conditions of the Creative Commons Attribution (CC BY) license (<https://creativecommons.org/licenses/by/4.0/>).

## 1. Introduction

Peripheral nerve injuries still represent a serious cause of disability; despite the progress made in microsurgical techniques and materials [1,2], it is often difficult to obtain a complete recovery of the axons and, therefore, of the function of the innervated muscles.

In case of injury with a nerve defect, the current gold standard is the grafting of an autologous sensory nerve segment between the two nerve stumps [3–5]. The standard method used to reconnect the stumps is a microsurgical tensionless suture [6–8].

This technique, despite being the current standard treatment, has several limitations; in fact, a microsurgical suture can be a time-consuming and technically intricate process, particularly in challenging situations with small-diameter nerves, requiring appropriate surgical skills [9–11]. Moreover, the use of sutures in nerve repair might not guarantee complete neural regeneration due to tissue responses such as inflammation and scarring at the repair site [12,13], phenomena of Wallerian degeneration [14] and the possible

occurrence of a neuroma at the site of anastomosis due to a granulomatous reaction [15,16]. Finally, the potential disruption of axonal regeneration quality may occur due to the compromise of the intraneural vascular supply resulting from the tension induced by the knot-tying of sutures [17,18].

Fibrin glue is a solution of fibrinogen, thrombin and sealing proteins that could find applications in nerve repair. When these proteins mix during application, they form a clot at the intervention point, simulating the final stage of the coagulation cascade. They are currently used to fix skin grafts (for example, on burn wounds) and to facilitate flap adhesion to the receiving site after extensive surgical dissections. Their composition allows for immediate use without the need for preventive treatments [19,20].

Fibrin glue is widely utilized in peripheral nerve surgery due to its simplicity, reduced tissue manipulation, diminished suture necessity, and shorter procedural durations. However, its application is still considered off label, as the most essential question remains whether fibrin glue also results in similar nerve recovery [21–23].

The aim of this study was to evaluate the effectiveness of the use of fibrin glue (Tisseel®) in securing a nerve graft without the use of sutures and compare the outcomes to those of traditional microsurgical repair. This method could reduce the suture line inflammation, and therefore scarring, improving axonal regeneration and accelerating the time of functional recovery [24–26].

## 2. Materials and Methods

The experimental protocol on the animals was conducted in accordance with the D.L. number 26 of 14 March 2014, authorization number 576/2015-PR, 23 June 2015, on the protection of animals used for experimental purposes or for other scientific purposes. Surgical procedures and animal housing took place at the Experimental Zooprophyllactic Institute of Sicily.

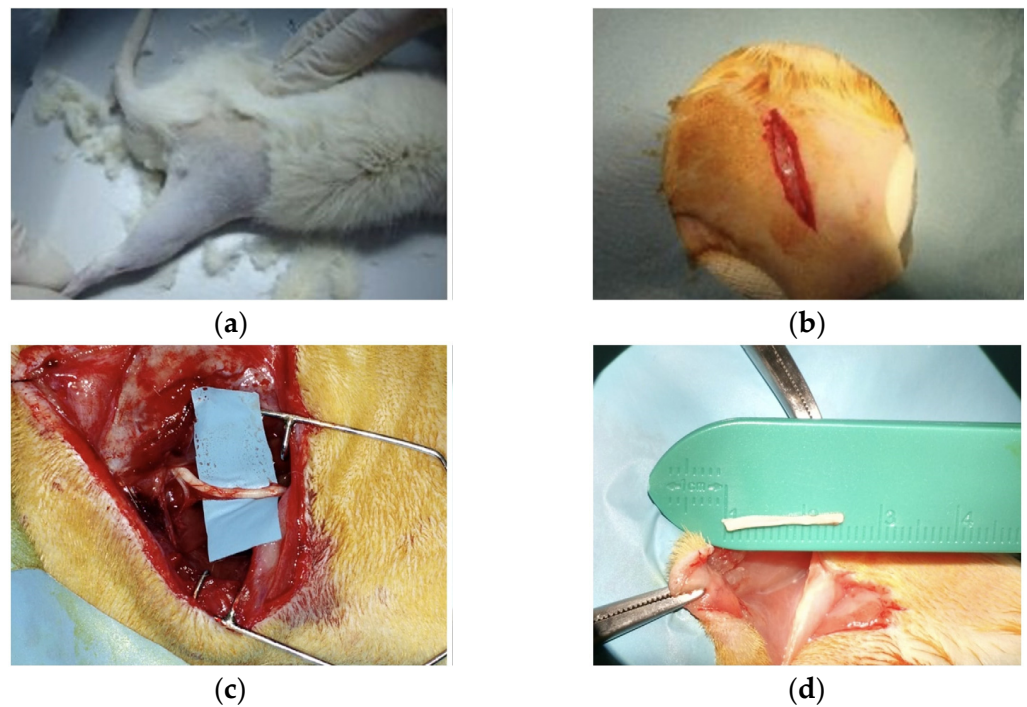
Power analysis determined that 10 animals per group provided 80% statistical power with an alpha of 0.05, based on an expected 20% effect on the Sciatic Functional Index (SFI). Twenty-four adult male Wistar rats weighing between 250 g and 450 g were used to account for eventual animal loss. Rats were housed in a temperature- and humidity-controlled room with 12–12 h light/dark cycles, and fed standard chow and water ad libitum. Measures were taken to minimize pain and discomfort, taking into account human endpoints for animal suffering and distress.

All surgical procedures were performed by the same operator and only on one limb of the animal, to allow for a greater degree of mobility and self-sufficiency. In preparation for surgery, rats were anesthetized first with Isoflurane for induction, followed by the intraperitoneal administration of 1 mL/kg of a Ketamine/xylazine cocktail (91 mg/mL Ketamine + 9.1 mg/mL Xylazine).

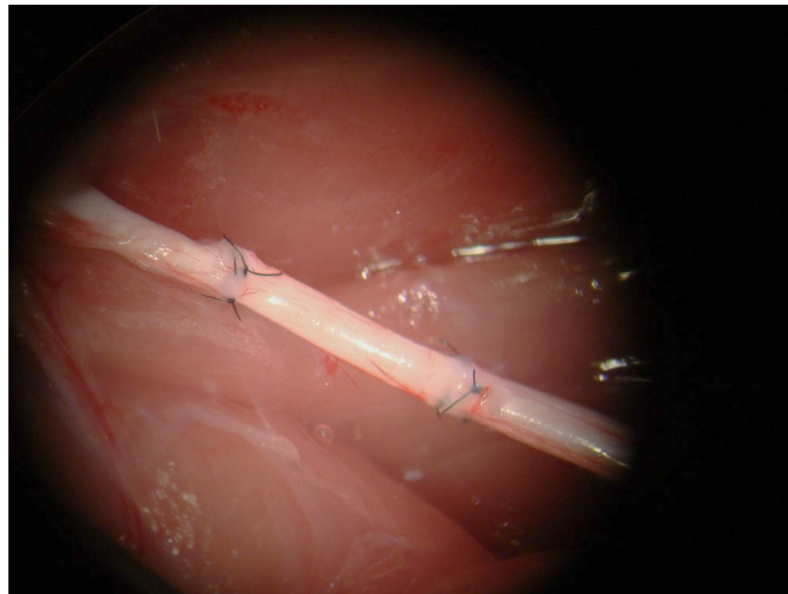
Following anesthesia, right rear limb trichotomy and disinfection were performed (right rear limb) (Figure 1a); the animal was positioned in a prone position with the limbs fixed in abduction. The operation was performed under aseptic conditions and using a PowerFocus surgical microscope. The sciatic nerve was isolated through a skin incision of 40 mm, beginning 0.5 cm lateral to the dorsal midline of the rat and extending by 4 cm along the tibio-femoral articulation; subsequent detachment and retraction of the gluteus and bicep femoris muscles exposed the underlying sciatic nerve (Figure 1b,c).

Each nerve was dissected first proximally (approximately 10 mm from its emergence from the sciatic notch) and then distally, before division into its terminal branches and the creation of a defect of 15 mm. (Figure 1d). The animals were randomly assigned to two groups, A ( $n = 12$ , Control Group) and B ( $n = 12$ , Study Group), according to the repair method. In both groups, the repair was performed by an inverted polarity autograft, using the same segment derived from the nerve section as the graft donor.

In Group A (Control group), the segment was fixed, both proximally and distally, by 3 single-stitch equidistant epi-perineural sutures, (Ethilon 9/0) under microscope magnification (Figure 2).



**Figure 1.** (a) Trichotomy of the right rear limb; (b) skin incision of 40 mm; (c) dissection and exposure of the sciatic nerve; (d) nerve section and autograft obtained.



**Figure 2.** Nerve autograft with inverted polarity fixed with three epi-perineural sutures.

In Group B (Study group), the segment was fixed, both proximally and distally, by Tisseel<sup>®</sup> in the epineurium of the proximal and the distal stumps (Figure 3).

In both groups, the muscular and fascial layers were subsequently closed by resorbable sutures with 4/0 threads, and the skin by a continuous suture with 4/0 thread, after careful hemostasis.

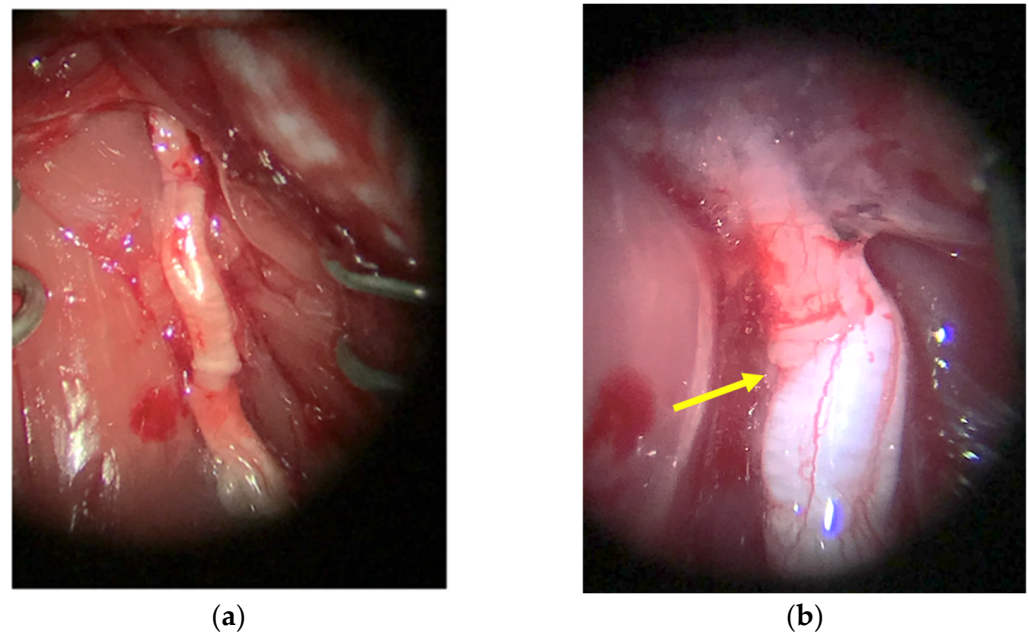
At the end of the surgical procedures, 2 mL of NaCl fluid therapy and Enrofloxacin (10 mg/kg sc) were administered intraperitoneally to prevent the dehydration of the animal and for prophylactic antibiotic purpose.

To awake the animal, Atipamezole Hydrochloride 1 mL/kg was given intramuscularly. Each animal was then transferred to a cage and assigned an identification number.

Rats were sacrificed at the 16th week or 21st week.

For both the control and the study group, 50% of rats were sacrificed at 16 weeks and 50% at 21 weeks. Before sacrifice, all rats underwent Walking Track Analysis (WTA) for the evaluation of motor function, and electrophysiological evaluation. After sacrifice, the calculation of muscle mass indexes was performed, specifically the Gastrocnemius Muscle Weight Ratio (GMWR) and Tibialis Anterior Muscle Weight Ratio (TAMWR); additionally, a histological examination of the regenerated nerve was performed.

All data collected in the Study Group and Control Group populations were evaluated by Student's *t* test for unpaired data, considering significant each value with  $p < 0.05$ .



**Figure 3.** (a) Nerve autograft with inverted polarity fixed with fibrin glue; (b) particular of the suture line with fibrin glue (the yellow arrow pinpoints the specific location of the suture line where fibrin glue was applied).

### 2.1. Walking Track Analysis

For the functional evaluation, the WTA was conducted with the Sciatic Functional Index (SFI) measurement. The rats were tested on a straight path of 75 cm, after coloring the hind legs with black ink to impress the footprints on a strip of white paper placed on the floor of the path. From the print obtained, the following measurements were extrapolated: Print Length (PL), the distance between the heel and the third finger; Toe Spread (TS), the distance between the first and the fifth finger; and Intermediary Toe Spread (ITS), the distance between the second and the fourth finger. The formula used, a reinterpretation made by Bain in 1989, is as follows:

$$SFI = -38.3 \left( \frac{EPL - NPL}{NPL} \right) + 109.5 \left( \frac{ETS - NTS}{NTS} \right) + 13.3 \left( \frac{EIT - NIT}{NIT} \right) - 8.8$$

The letters *E* and *N* stand, respectively, for Experimental (operative limb) and Normal (healthy limb). The index values range from 0 to  $-100$ , 0 indicating a normal situation, and 100 a complete sciatic nerve injury.

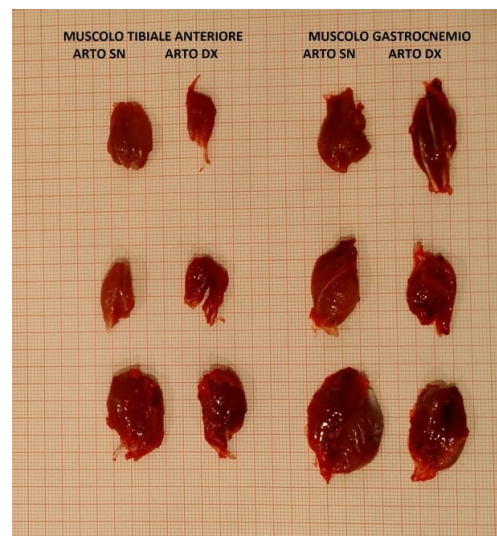### 2.2. Electrophysiological Evaluation

Measurements were detected in the Gastrocnemius and Tibialis Anterior muscles of each operated limb, using the contralateral as a control. Monopolar needle electrodes were placed in each muscle at a fixed distance from each other. The registration of the Compound Muscle Action Potential (CMAP) was made using a pair of monopolar needle electrodes,

applied according to the “belly tendon” assembly. The reference electrode was inserted into the subcutis of a front limb. The stimulation was performed by a single pulse with a duration of 0.1 ms, with a diode-square wave; the amplitude was measured peak-to-peak. Using the Motor Unit Number Estimation (MUNE) technique, an estimate of the number of motor units that make up a muscle was then made, dividing the amplitude of the CMAP by the mean amplitude of the individual motor unit potentials (Single-Motor Unit Action Potential: SMUAP).

### 2.3. Muscle Mass Indexes

After the sacrifice, the Gastrocnemius and Tibialis Anterior muscles of both hind limbs were taken in full (Figure 4) and weighed using an electronic precision balance.



**Figure 4.** Tibialis Anterior Muscle and Gastrocnemius Muscle; example obtained muscle.

The Muscle Weight Ratio (MWR) was then calculated for each muscle, relying on the comparison between the values obtained from the measurement of the muscles of the operated limb (right) and the healthy limb (left); to do this, the following formulas were used:

$$GMWR = \frac{\text{Weight of the reinnervated gastrocnemius}}{\text{Weight of the controlateral gastrocnemius}}$$

$$TAMWR = \frac{\text{Weight of the reinnervated tibialis anterior}}{\text{Weight of the controlateral tibialis anterior}}$$

### 2.4. Histological Analysis

The sciatic nerves of both lower limbs were taken proximally to the proximal suture and distally to the distal suture, fixed in 4% paraformaldehyde in a saline phosphate buffer (PBS) for 2–4 h and then washed and stored in 0.2 g of glycine in 100 mL of PBS before inclusion. After washing in PBS for a few minutes, the nerves were immersed for 4 h in a 2% solution of osmium tetroxide and then dehydrated in a growing series of alcohol.

The samples were then included in paraffin and cross sections were obtained with a thickness of 3–5  $\mu\text{m}$ . By means of an optical microscope connected to a video camera, images at 100 $\times$  magnification were acquired.

An area of 5500  $\mu\text{m}^2$  was then selected (as representative of the entire section of the nerve), distally to the distal suture, for the calculation of the parameters useful for the evaluation of the degree of nerve regeneration of the samples.

The parameters evaluated for morphometric analysis of the nerve were as follows:

- n = Number of myelinated fibers;
- Fiber Area (FA): Area occupied by nerve fibers ( $\mu\text{m}^2$ ) on an assessed sample area of  $5500 \mu\text{m}^2$ ;
- Fiber Density (FD): Number of myelinated fibers (n) over the entire area of the sciatic nerve section ( $\mu\text{m}^2$ ).

### 3. Results

Four rats (two from the Study Group and two from the Control Group) were excluded from the study as they died soon after surgery. Three other rats (2 of the Study Group and 1 of the Control Group) presented self-mutilation phenomena after the 16th week and were excluded from the functional evaluation at 21 weeks.

#### 3.1. Walking Track Analysis

Walking Track Analysis did not show any statistically significant differences between the two groups at both 16 and 21 weeks ( $p = 0.8$  and  $p = 0.9$ , respectively) (Table 1).

Table 1. Average SFI (Sciatic Functional Index).

	16 Weeks Control Group	21 Weeks Control Group	16 Weeks Study Group	21 Weeks Study Group
Average SFI	−47.6 range −35/−60	−38 range −48/−19	−45.8 range −40/−68	−40 range −52/−20

#### 3.2. Electroneurophysiological Evaluation

Intragroup analysis did not show any significant differences for the Gastrocnemius muscle in either group, both at 16 and at 21 weeks. However, at both 16 and at 21 weeks, there was a significant difference in the Tibialis Anterior muscle only in the Control Group ( $p = 0.01$ ), with no significant difference in the Study Group ( $p = 0.1$ ) (Figures 5 and 6).

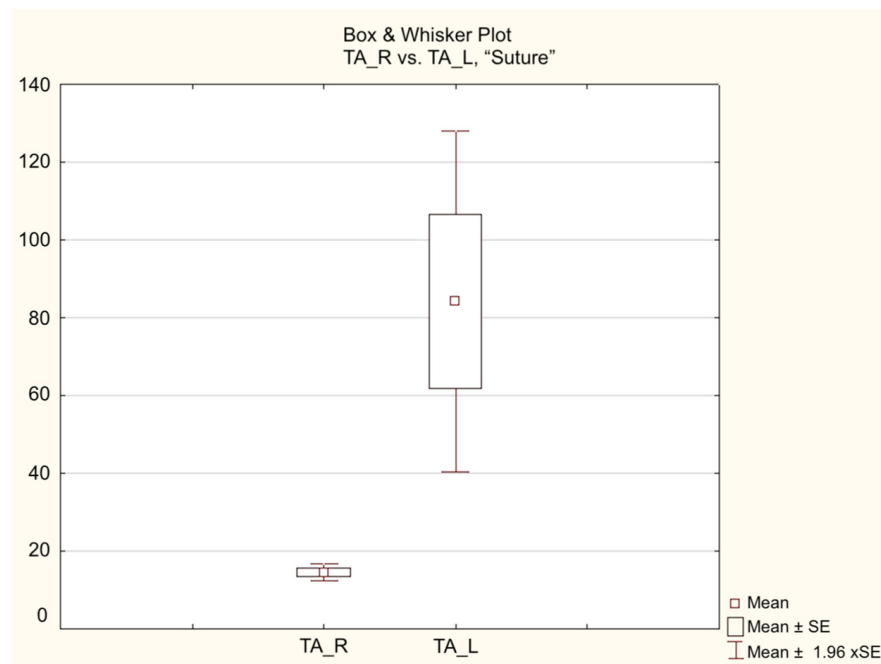
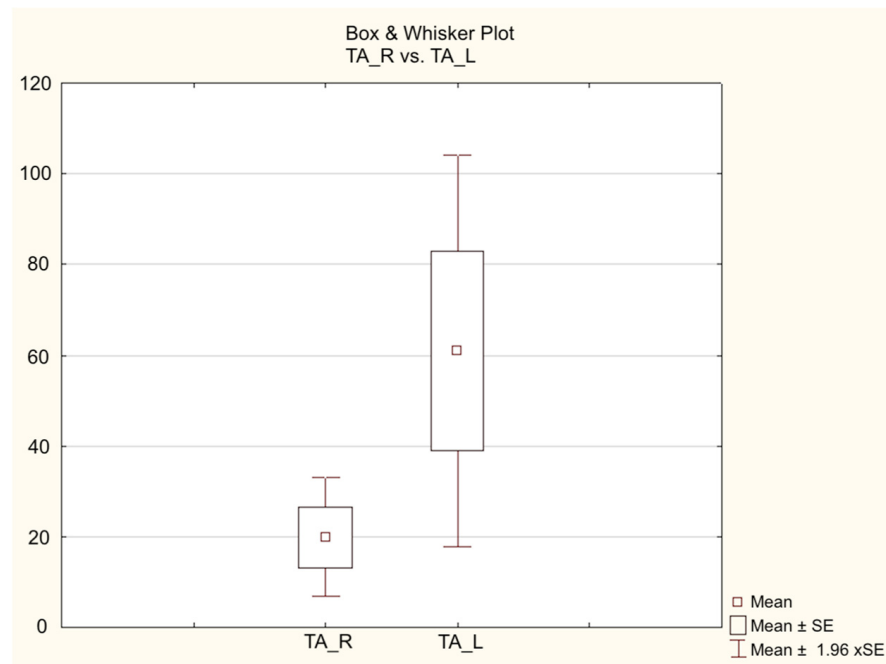


Figure 5. Results of electroneurophysiological evaluation in the 21-week Control Group.



**Figure 6.** Results of electroneurophysiological evaluation in the 21-week Study Group.

### 3.3. Muscle Mass Indexes

#### 3.3.1. GMWR

A detailed summary of the GMWR and Gastrocnemius average weight (of each limb) in both the Control and Study Groups at 16 and 21 weeks after surgery is shown in Table 2.

**Table 2.** Average weight of the Gastrocnemius and Tibialis Anterior muscles. Average GMWR (Gastrocnemius muscle weight ratio) and Average TAMWR (Tibialis Anterior weight ratio).

		16 Weeks Control Group		21 Weeks Control Group		16 Weeks Study Group		21 Weeks Study Group	
		Operated Limb	Healthy Limb	Operated Limb	Healthy Limb	Operated Limb	Healthy Limb	Operated Limb	Healthy Limb
Gastrocnemius muscles	Average weight	1.008 g range: 0.41–1.38 g	1.712 g range: 1.06–2.2 g	0.7620 g range: 0.59–0.86 g	1.266 g range: 1.01–1.43 g	0.93 g range: 0.33–1.32 g	1.768 g range: 1.01–2.5 g	0.6460 g range: 0.31–0.84 g	1.2320 g range: 0.92–1.59 g
	Average GMWR	0.6041 range: 0.262820513–0.90566037		0.6368 range: 0.495798319–0.851485149		0.5027 range: 0.326732673–0.601990049		0.5253 range: 0.336956522–0.762376238	
Tibialis Anterior muscles	Average weight	0.63 g range: 0.35–1.08 g	1.188 g range: 0.67–1.48 g	0.3720 g range: 0.31–0.46 g	0.71 g range: 0.55–0.78 g	0.6160 g range: 0.11–1.11 g	1.2420 g range: 0.55–1.99 g	0.2480 g range: 0.15–0.37 g	0.56 g range: 0.45–0.66 g
	Average TAMWR	0.5519 range: 0.357142857–0.729729729		0.5316 range: 0.397435897–0.63		0.4534 range: 0.2–0.6094674556		0.4458 range: 0.2878787878–0.6086956521	

Statistical analysis did not show any significant differences in GMWR between the Control and Study Groups at either 16 or 21 weeks.

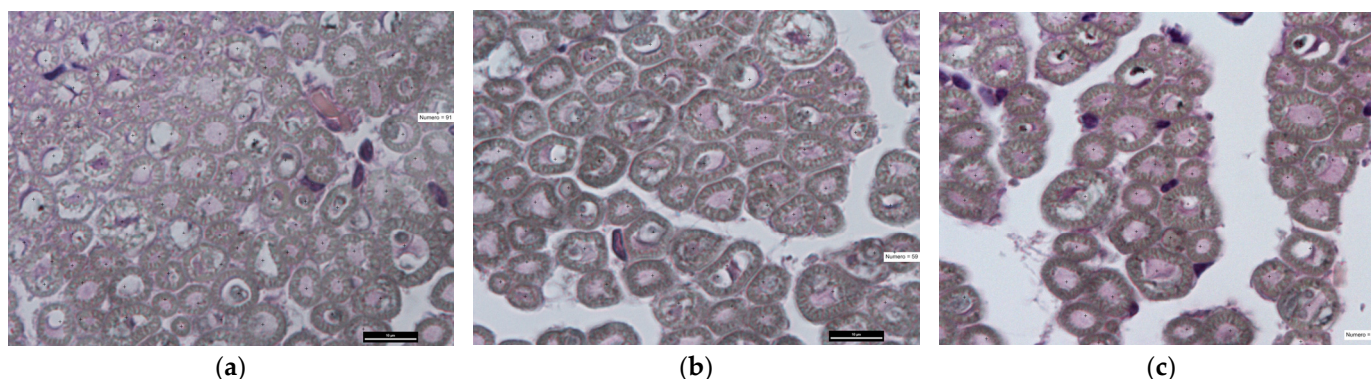
#### 3.3.2. TAMWR

A detailed summary of the TAMWR and tibialis anterior average weight (of each limb) of both the Control and Study Groups at 16 and 21 weeks is shown in Table 2.

Student’s *t* test between the Control Group and Study Group in the population did not show any significant differences in the TAWR at either 16 or 21 weeks post-surgery ( $t = 1.0037$ ;  $df = 8$ ;  $p = 0.3449$  and  $t = 1.1142$ ;  $df = 8$ ;  $p = 0.2975$ , respectively).

### 3.4. Histological Analysis

From the histological evaluation (Figure 7), the following parameters were detected: average number of regenerated nervous fibers, fiber area evaluation and fiber density at 16 and 21 weeks after surgery in both the Control and Study Groups.



**Figure 7.** Section of colored nerve with Osmium tetroxide, 100× magnification. (a) Healthy nerve,  $n = 91$ ; (b) nerve Control Group at 16 weeks,  $n = 59$ ; (c) nerve Study Group at 16 weeks,  $n = 61$ .

Detailed aforementioned values of both the Control and Study Groups at 16 and 21 weeks are shown in Table 3.

**Table 3.** Histological evaluation of regenerated nerves.

	16 Weeks Control Group	21 Weeks Control Group	16 Weeks Study Group	21 Weeks Study Group
Average number of regenerated nervous fibers	$59 \pm 5$	$65 \pm 3.9$	$61 \pm 3$	$67 \pm 2.6$
Fiber area	$4410 \pm 150 \mu\text{m}^2$	$4854 \pm 150 \mu\text{m}^2$	$4586 \pm 148 \mu\text{m}^2$	$5044 \pm 130 \mu\text{m}^2$
Fiber density	$0.0109 \pm 0.0004 \text{ fibers}/\mu\text{m}^2$	$0.012 \pm 0.0004 \text{ fibers}/\mu\text{m}^2$	$0.0112 \pm 0.0005 \text{ fibers}/\mu\text{m}^2$	$0.0123 \pm 0.0005 \text{ fibers}/\mu\text{m}^2$

Statistical analysis did not show any significant difference in regenerated nerve fibers, fiber area or fiber density between the Control and Study Group at either 16 or 21 weeks.

Student’s *t* test between the Control Group and Study Group in the population did not show any significant differences at either 16 and 21 weeks post-surgery in the regenerated nervous fibers ( $t = 0.73$ ;  $df = 8$ ;  $p = 0.486$  and  $t = 0.94$ ;  $df = 8$ ;  $p = 0.3734$ , respectively), in the fiber area ( $t = 1.85$ ;  $df = 8$ ;  $p = 0.1$  and  $t = 2.144$ ;  $df = 8$ ;  $p = 0.0647$ , respectively), nor in the fiber density ( $t = 1.0476$ ;  $df = 8$ ;  $p = 0.3254$  and  $t = 1.04$ ;  $df = 8$ ;  $p = 0.33$ , respectively).

## 4. Discussion

The use of fibrin glue in the repair of peripheral nerves is not a new practice, with the first reports of its use in the literature dating back to the 1940s. Despite these early reports, the use of fibrin glue as a sealant for peripheral nerve injury was quite uncommon, due to low tensile strength and rapid absorption.

During the 1970s, Matras and colleagues created a more concentrated formula that enhanced its longevity [27,28] with the marketing of the first Tisseel® preparation.

Despite Tisseel® being introduced more than four decades ago, there is still limited literature on its application and effectiveness in repairing peripheral nerves, with most studies focusing on its efficacy in rat models [9,10,12,21,29–40]. This could be attributed



to two main factors. Firstly, its approval by the U.S. Food and Drug Administration in 1998 was relatively recent, and secondly, the use of Tisseel® for nerve repair was firstly considered off label. In fact, at the beginning, Tisseel® was only officially approved as an adjunct in maintaining hemostasis during cardio-pulmonary bypass and as a sealant during temporary colostomies [41].

For these two reasons, although lots of animal studies have been carried out to evaluate the effectiveness of fibrin glue in the coaptation and healing of peripheral nerve injuries, the literature still lacks controlled human trials comparing fibrin sealants and suturing techniques [42,43].

Several experimental animal studies conducted in the past years have shown variable outcomes; in some cases, the result of the use of fibrin glue was superimposable to that of the sutures [29–31], if not even better [9,10,32–35], while in other cases it seemed to be worse [12,44,45].

A few systematic reviews were carried out more recently, with the final result of no substantial difference between the two repair methods in terms of nerve regeneration and motor function restorations.

However, most of the assessed studies were carried out on animal models, with the use of different types of glue and different types of evaluated parameters [9,10,12,21,29–40].

Fibrin glue works by simulating the end stage of the coagulation cascade, forming a substance resembling a physiological blood clot. This clot acts as a protective layer that holds the nerve stumps and protect them from the surrounding scar tissue, allowing nerve fibers to heal within the epineurium [27].

Menovsky and Beek's study demonstrated more adhesions, fibrosis, and thickening at the repair site in their suture group [46], while Inalöz et al. demonstrated how nerve coaptation was superior in their fibrin glue group according to the electromyography results, neuroconduction studies, and histopathological examination [47].

In this study, the study group was compared to a population of overlapping characteristics (15 mm sciatic nerve gap) treated with the current gold standard of care for these lesions: a nerve autograft with reverse polarity fixed with sutures.

We evaluated the effectiveness of the fibrin glue repair technique, trying to overcome the well-known limits of injured nerve's repair by suture, such as degenerative nerve bundles, excessive local inflammation, scar and the possibility of neuroma formation (or foreign body granuloma) at the anastomosis site.

Both groups were evaluated at 16 and 21 weeks.

For the evaluation of nerve regeneration, the following parameters were evaluated:

- Walking Track Analysis for the analysis of the locomotor activity;
- Electroneurography;
- Weight of the muscles (and their ratio);
- Histological examination of the regenerated.

The Walking Track Analysis is a useful tool to evaluate the functional restoration in the regeneration of peripheral nerves for the mouse and rat model. The test is based on the assumption that a better regeneration of the reconstructed sciatic nerve corresponds to better running performance [48]. The parameter used in the Walking Track Analysis was the SFI, for the calculation of which we used measurements obtained from the imprint left by the rat on a sheet of white paper placed on a straight path inside a tunnel.

The other evaluated parameters were more objective and bias-from-animal-behavior free.

The analysis of the muscle mass indexes evaluates the tropism of a muscle reinnervated by a reconstructed nerve. A denervated muscle undergoes atrophy, with a speed directly proportional to the muscle mass and denervation time. The reinnervation of the surviving fibers (within certain time limits) causes the degenerative phenomenon to stop and, progressively, the muscle to regain its trophism [49].

On this basis, the weight of the Tibialis Anterior and Gastrocnemius muscles, innervated by the branches of the sciatic nerve, represents a good indirect index for the evaluation of nerve regeneration [29,50,51].

Statistical analysis did not show any significant difference in all the aforementioned evaluated parameters (WTA, electroneurophysiological evaluations, muscle mass index and histological analysis) between the Control and the Study Group at either 16 or 21 weeks. The only significant difference ( $p = 0.01$ ) was found in the electroneurophysiological analysis of the Tibialis Anterior muscles in the Control Group.

At the level of the Tibialis Anterior (at both 16 and 21 weeks), a significant decrease in the number of motor units estimated in the reinnervated muscle was found in the Control Group, compared to the contralateral ( $p = 0.01$ ); in the Study Group, this reduction was not significant ( $p = ns$ ) and there is, therefore, a likely improvement in the number of motor units compared to the group treated with the traditional suture.

This study was aimed at evaluating the effectiveness of the use of fibrin glue compared to the gold standard microsurgical repair technique with a suture. No statistically significant differences between the two analyzed groups emerged. We found an overlap in terms of the results of both the examined techniques which could be interchangeable in terms of post-injury nerve regeneration.

The only statistically significant result of this study is that the electroneurophysiological analysis of the Tibialis Anterior muscles in the Control Group (operated limb compared to healthy limb) pointed at a likely improvement in the number of motor units in the fibrin glue group compared to the current gold standard of care (microsurgical suture).

The fibrin glue technique of nerve repair has, from our perspective, many advantages compared to the microsurgical gold standard of care, the most important of which are the following: reduced surgical time, decreased fibrosis and inflammation, reduced induced trauma and neural scar tissue, better hemostasis and an easier stabilization of small grafts and, above all, technical ease of use.

Microsurgical repair, on the other hand, is a time-consuming and technically demanding procedure in cases with difficult exposure or small caliber nerves, and with many already outlined limitations. Besides, it requires a microsurgery-trained surgeon with experience in this field.

The fact that no statistically significant differences were found in the WTA, in the evaluation of muscle mass indexes and in the histological analysis can be linked to the sample size, or to the fact that the two techniques are interchangeable with overlapping results.

The results obtained encourage new research perspectives aimed at testing the use of fibrin glue on a larger sample to subsequently promote its use in clinical practice, considering that the results are superimposable to the standard technique, and there is an advantage of reduced suture time, and therefore costs.

Given fibrin glue's advantages, particularly its technical ease of use, microsurgical suture limits, and the promising electroneurophysiological results, we think that, despite the unproved superiority of the glueing technique, the similar results can justify a broader use of the fibrin glue technique in clinical practice. This is based on the advantages listed above, primarily its being a less technically and time-demanding procedure compared to microsurgical repair.

Limitations of this study include the following:

- Sciatic Functional Index is a reference parameter used for evaluating the functional restoration in the regeneration of peripheral nerves for the mouse and rat model, but the results of this test can still be influenced by the behavior of the animal;
- Variability in fibrin glue preparation and usage; many fibrin glues exist, so this study's results could be different using different glues commercially available;
- The sample size was relatively small, but due to ethical reasons was kept adherent to the preventive sample size calculation based on statistical power;
- We did not analyze, through histological staining, the potential to reduce the inflammation response when using fibrin glue compared to neuroorrhaphy; we acknowledge that conducting such a study would be beneficial for our future investigations.

## 5. Conclusions

Our study demonstrates that the use of fibrin glue is an effective way to fix nerve autografts to the stumps of the injured peripheral nerve, as effective as microsurgical sutures.

From the evaluation of the number of motor units estimated in the Tibialis Anterior muscle, a statistically significant difference ( $p = 0.01$ ) emerged, indicating a likely improvement in the number of motor units in the fibrin glue group, compared to the group treated with a traditional suture; the limited sample size, however, limits the significance of this superior result.

**Author Contributions:** G.Z.: writing—original draft preparation, Conceptualization, methodology; F.T.: writing—review and editing, supervision; F.C.: writing—original draft, investigation; G.C.: resources, data curation, visualization; L.C.: investigation, data curation, visualization; G.G.: software, validation, investigation; R.P.: resources, data curation, visualization; A.C.: supervision, project administration, funding acquisition. All authors have read and agreed to the published version of the manuscript.

**Funding:** This research received no external funding.

**Institutional Review Board Statement:** The study received prior approval from the Italian Ministry of Health, (n 576/2015-PR del 23 June 2015) and experiments were conducted according to Italian and European legislation.

**Informed Consent Statement:** Not applicable.

**Data Availability Statement:** All data generated or analyzed during this study are included in this published article.

**Conflicts of Interest:** The authors declare no conflicts of interest.

## References

- Khalifeh, J.M.; Dibble, C.F.; Dy, C.J.; Ray, W.Z. Cost-effectiveness analysis of combined dual motor nerve transfers versus alternative surgical and nonsurgical management strategies to restore shoulder function following upper brachial plexus injury. *Neurosurgery* **2019**, *84*, 362–377. [[CrossRef](#)] [[PubMed](#)]
- Gaiovych, I.; Savosko, S.; Labunets, I.; Utko, N.; Makarenko, A.; Chaikovsky, Y. Sciatic nerve regeneration after autografting and application of the bone marrow aspirate concentration. *Georgian Med. News* **2019**, *295*, 145–152.
- Kornfeld, T.; Vogt, P.M.; Radtke, C. Nerve grafting for peripheral nerve injuries with extended defect sizes. *Wien. Med. Wochenschr.* **2019**, *169*, 240–251. [[CrossRef](#)] [[PubMed](#)]
- Wu, R.; Wang, L.; Chen, F.; Huang, Y.; Shi, J.; Zhu, X.; Ding, Y.; Zhang, X. Evaluation of artificial nerve conduit and autografts in peripheral nerve repair in the rat model of sciatic nerve injury. *Neurol. Res.* **2016**, *38*, 461–466. [[CrossRef](#)] [[PubMed](#)]
- Lee, J.I.; Wandling, G.D.; Talukder, M.H.; Govindappa, P.K.; Elfar, J.C. A Novel Standardized Peripheral Nerve Transection Method and a Novel Digital Pressure Sensor Device Construction for Peripheral Nerve Crush Injury. *Bio-Protocol* **2022**, *12*, e4350. [[CrossRef](#)]
- Salomone, R.; Bento, R.F.; Costa, H.J.; Azzi-Nogueira, D.; Ovando, P.C.; Da-Silva, C.F.; Zanatta, D.B.; Strauss, B.E.; Haddad, L.A. Bone marrow stem cells in facial nerve regeneration from isolated stumps. *Muscle Nerve* **2013**, *48*, 423–429. [[CrossRef](#)] [[PubMed](#)]
- Heaton, J.T.; Sheu, S.H.; Hohman, M.H.; Knox, C.J.; Weinberg, J.S.; Kleiss, I.J.; Hadlock, T.A. Rat whisker movement after facial nerve lesion: Evidence for autonomic contraction of skeletal muscle. *Neuroscience* **2014**, *265*, 9–20. [[CrossRef](#)]
- Turner, N.J.; Johnson, S.A.; Foster, L.J.R.; Badylak, S.F. Sutureless nerve repair with ECM bioscaffolds and laser-activated chitosan adhesive. *J. Biomed. Mater. Res. Part B Appl. Biomater.* **2018**, *106*, 1698–1711. [[CrossRef](#)]
- Ornelas, L.; Padilla, L.; Di Silvio, M.; Schalch, P.; Esperante, S.; Infante, P.L.; Bustamante, J.C.; Avalos, P.; Varela, D.; Lopez, M. Fibrin glue: An alternative technique for nerve coaptation—Part I. Wave amplitude, conduction velocity, and plantar-length factors. *J. Reconstr. Microsurg.* **2006**, *22*, 119–122. [[CrossRef](#)]
- Ornelas, L.; Padilla, L.; Di Silvio, M.; Schalch, P.; Esperante, S.; Infante, R.L.; Bustamante, J.C.; Avalos, P.; Varela, D.; Lopez, M. Fibrin glue: An alternative technique for nerve coaptation—part II. Nerve regeneration and his-tomorphometric assessment. *J. Reconstr. Microsurg.* **2006**, *22*, 123–128. [[CrossRef](#)]
- Hong, J.P.; Masoodi, Z.; Tzou, C.J. Attributes of a good microsurgeon—A brief counsel to the up-and-coming prospects. *Arch. Plast. Surg.* **2023**, *50*, 130–140. [[CrossRef](#)] [[PubMed](#)]
- Koulaxouzidis, G.; Reim, G.; Witzel, C. Fibrin glue repair leads to enhanced axonal elongation during early peripheral nerve regeneration in an in vivo mouse model. *Neural Regen. Res.* **2015**, *10*, 1166–1171. [[CrossRef](#)]
- Wang, W.; Degrugillier, L.; Tremp, M.; Prautsch, K.; Sottaz, L.; Schaefer, D.J.; Madduri, S.; Kalbermatten, D. Nerve repair with fibrin nerve conduit and modified suture placement. *Anat. Rec.* **2018**, *301*, 1690–1696. [[CrossRef](#)] [[PubMed](#)]

14. Caillaud, M.; Richard, L.; Vallat, J.M.; Desmouliere, A.; Billet, F. Peripheral nerve regeneration and intraneural revascularization. *Neural Regen. Res.* **2019**, *14*, 24–33. [[PubMed](#)]
15. Barton, M.J.; Morley, J.W.; Stoodley, M.A.; Lauto, A.; Mahns, D.A. Nerve repair: Toward a sutureless approach. *Neurosurg. Rev.* **2014**, *37*, 585–595. [[CrossRef](#)]
16. Rafijah, G.; Bowen, A.J.; Dolores, C.; Vitali, R.; Mozaffar, T.; Gupta, R. The effects of adjuvant fibrin sealant on the surgical repair of segmental nerve defects in an animal model. *J. Hand. Surg.* **2013**, *38*, 847–855. [[CrossRef](#)]
17. Maeda, T.; Hori, S.; Sasaki, S.; Maruo, S. Effects of tension at the site of coaptation on recovery of sciatic nerve function after neurorrhaphy: Evaluation by walking-track measurement, electrophysiology, histomorphometry, and electron probe X-ray microanalysis. *Microsurgery* **1999**, *19*, 200–207. [[CrossRef](#)]
18. Gordon, T. Nerve regeneration: Understanding biology and its influence on return of function after nerve transfers. *Hand Clin.* **2016**, *32*, 103–117. [[CrossRef](#)]
19. Shuchi, A.; Gupta, D.; Sarabahi, S. An Outcome Analysis of Fibrin Sealant versus Staples for Fixation of Split-Thickness Skin Grafts. *Indian J. Plast. Surg.* **2024**, *57*, 60–66. [[CrossRef](#)]
20. Beudert, M.; Gutmann, M.; Lühmann, T.; Meinel, L. Fibrin Sealants: Challenges and Solutions. *ACS Biomater. Sci. Eng.* **2022**, *8*, 2220–2231. [[CrossRef](#)]
21. Koopman, J.E.; Duraku, L.S.; de Jong, T.; de Vries, R.B.M.; Michiel Zuidam, J.; Hundepool, C.A. A Systematic Review and Meta-Analysis on the Use of Fibrin Glue in Peripheral Nerve Repair: Can We Just Glue It? *J. Plast. Reconstr. Aesthet. Surg.* **2022**, *75*, 1018–1033. [[CrossRef](#)] [[PubMed](#)]
22. Biscola, N.P.; Cartarozzi, L.P.; Ulian-Benitez, S.; Barbizan, R.; Castro, M.V.; Spejo, A.B.; Ferreira, R.S., Jr.; Barraviera, B.; Oliveira, A.L.R. Multiple uses of fibrin sealant for nervous system treatment following injury and disease. *J. Venom. Anim. Toxins Incl. Trop. Dis.* **2017**, *23*, 13. [[CrossRef](#)] [[PubMed](#)]
23. Siroya, H.L.; Kumar, V.B.; Bhat, D.I.; Shukla, D.P.; Devi, B.I. Is Popularity of Fibrin Glue a Misrepresentation? A Comparative Study with Fibrin Glue and Suture Anastomosis in Rat Sciatic Nerve Injury Analysing Functional, Histological, Electrophysiological Parameters. *Neurol. India* **2023**, *71*, 55–61. [[PubMed](#)]
24. Akbari, H.; Farokhi, B.; Emami, S.-A.; Akhoondinasab, M.-R.; Akbari, P.; Karimi, H. Comparison of the never repair with fibrin glue and perineural micro-suture in rat model. *World J. Plast. Surg.* **2020**, *9*, 44–47. [[PubMed](#)]
25. Braga Silva, J.; Becker, A.S.; Leal, B.L.M.; Busnello, C.V. Advances of Direct Peripheral Nerve Repair Techniques: Do We Already Have Enough Scientific Evidence? *Indian J. Orthop.* **2022**, *57*, 189–202. [[CrossRef](#)]
26. Potter, B.K. From Bench to Bedside: No Need to be Nervous about Microsuturing? *Clin. Orthop. Relat. Res.* **2017**, *475*, 2165–2167. [[CrossRef](#)] [[PubMed](#)]
27. Isaacs, J.E.; McDaniel, C.O.; Owen, J.R.; Wayne, J.S. Comparative analysis of biomechanical performance of available “nerve glues”. *J. Hand Surg. Am.* **2008**, *33*, 893–899. [[CrossRef](#)] [[PubMed](#)]
28. Matras, H.; Braun, F.; Lassmann, H.; Ammerer, H.P.; Mamoli, B. Plasma clot welding of nerves (experimental report). *J. Max Fac. Surg.* **1973**, *1*, 236–247. [[CrossRef](#)] [[PubMed](#)]
29. Lee, J.I.; Gurjar, A.A.; Talukder MA, H.; Rodenhouse, A.; Manto, K.; O’Brien, M.; Govindappa, P.K.; Elfart, J.C. A novel nerve transection and repair method in mice: Histomorphometric analysis of nerves, blood vessels, and muscles with functional recovery. *Sci. Rep.* **2020**, *10*, 21637. [[CrossRef](#)]
30. Benfield, C.; Isaacs, J.; Mallu, S.; Kurtz, C.; Smith, M. Comparison of nylon suture versus 2 fibrin glue products for delayed nerve coaptation in an animal model. *J. Hand Surg. Am.* **2021**, *46*, 119–125. [[CrossRef](#)]
31. Sallam, A.; Eldeeb, M.; Kamel, N. Autologous fibrin glue versus microsuture in the surgical reconstruction of peripheral nerves: A randomized clinical trial. *J. Hand Surg. Am.* **2022**, *47*, 89.e1–89.e11. [[CrossRef](#)] [[PubMed](#)]
32. Leite, A.P.S.; Pinto, C.G.; Tibúrcio, F.C.; Sartori, A.A.; Rodrigues, A.d.C.; Barraviera, B.; Ferreira, R.S.; Filadelpho, A.L.; Matheus, S.M.M. Heterologous fibrin sealant potentiates axonal regeneration after peripheral nerve injury with reduction in the number of suture points. *Injury* **2019**, *50*, 834–847. [[CrossRef](#)] [[PubMed](#)]
33. Shaikh, S.; Shortland, P.; Lauto, A.; Barton, M.; Morley, J.W.; Mahns, D.A. Sensory perturbations using suture and sutureless repair of transected median nerve in rats. *Somatosen. Mot. Res.* **2016**, *33*, 20–28. [[CrossRef](#)] [[PubMed](#)]
34. Martins, R.S.; Siqueira, M.G.; Silva, C.F.; Godoy, B.O.; Plese, J.P. Electrophysiologic assessment of regeneration in rat sciatic nerve repair using suture, fibrin glue or a combination of both techniques. *Arq. Neuropsiquiatr.* **2005**, *63*, 601–604. [[CrossRef](#)] [[PubMed](#)]
35. Martins, R.S.; Siqueira, M.G.; Da Silva, C.F.; Plese, J.P. Overall assessment of regeneration in peripheral nerve lesion repair using fibrin glue, suture, or a combination of the 2 techniques in a rat model: Which is the ideal choice? *Surg. Neurol.* **2005**, *64* (Suppl. S1), 10–16; discussion 16.
36. Fisher, A.H.; Johnsen, P.H.; Simon, A.; Burns, C.J.; Romiyo, V.; Bodofsky, E.B.; Vega, S.L.; Fuller, D.A. Fibrin Glue Acutely Blocks Distal Muscle Contraction after Confirmed Polyethylene Glycol Nerve Fusion: An Animal Study. *Plast. Reconstr. Surg. Glob. Open* **2024**, *12*, e5535. [[CrossRef](#)]
37. Erdal, A.I.; Findikçioğlu, K.; Karasu, O.; Özkoçer, S.E.; Elmas, Ç. Use of Erythropoietin and Fibrin Glue Mixture for Peripheral Nerve Repair. *Plast. Reconstr. Surg.* **2022**, *149*, 395–403. [[CrossRef](#)] [[PubMed](#)]
38. Suri, A.; Mehta, V.S.; Sarkar, C. Microneural anastomosis with fibrin glue: An experimental study. *Neurol. India* **2002**, *50*, 23–26. [[PubMed](#)]

39. Adel, M.; Abdo Elgamal, D.; Bakry, R.; Abdelkader, M.; Elshazly, M.; Kamel, A. Suture versus fibrin glue microneural anastomosis of the femoral nerve in Sprague dewly rat model. A comparative experimental assessment of the clinical, histological and statistical features. *Acta Chir. Plast.* **2017**, *59*, 65–71.
40. Akhter, E.T.; Rotterman, T.M.; English, A.W.; Alvarez, F.J. Sciatic nerve cut and repair using fibrin glue in adult mice. *Bio Protoc.* **2019**, *9*, e3363. [[CrossRef](#)] [[PubMed](#)]
41. Spotnitz, W.D. Fibrin sealant: Past, present, and future: A brief review. *World J. Surg.* **2010**, *34*, 632–634. [[CrossRef](#)]
42. Becker, C.M.; Gueuning, C.O.; Graff, G.L. Sutures or fibrin glue for divided rat nerves: Schwann cell and muscle metabolism. *Microsurgery* **1985**, *6*, 1–10. [[CrossRef](#)] [[PubMed](#)]
43. Sameem, M.; Wood, T.J.; Bain, J.R. A systematic review on the use of fibrin glue for peripheral nerve repair. *Plast. Reconstr. Surg.* **2011**, *127*, 2381–2390. [[CrossRef](#)] [[PubMed](#)]
44. Mitchell, E.C.; Haddara, M.M.; Wu, K.Y.; Chambers, S.B.; Ferreira, L.M.; Gillis, J.A. Strength comparison of fibrin glue and suture constructs in upper extremity peripheral nerve coaptations: An in vitro study. *J. Hand Surg. Am.* **2022**, *48*, 620.e1–620.e6. [[CrossRef](#)] [[PubMed](#)]
45. Childe, J.R.; Regal, S.; Schimoler, P.; Kharlamov, A.; Miller, M.C.; Tang, P. Fibrin glue increases the tensile strength of conduit-assisted primary digital nerve repair. *Hand* **2018**, *13*, 45–49. [[CrossRef](#)] [[PubMed](#)]
46. Menovsky, T.; Beek, J.F. Laser, fibrin glue, or suture repair of peripheral nerves: A comparative functional, histological, and morphometric study in the rat sciatic nerve. *J. Neurosurg.* **2001**, *95*, 694–699. [[CrossRef](#)] [[PubMed](#)]
47. Inalöz, S.S.; Ak, H.E.; Vayla, V.; Akin, M.; Aslan, A.; Sari, I.; Çelik, Y.; Özkan, Ü. Comparison of microsuturing to the use of tissue adhesives in anastomosing sciatic cuts in rats. *Neurosurg. Rev.* **1997**, *20*, 250–258. [[CrossRef](#)] [[PubMed](#)]
48. Biazar, E.; Heidari Keshel, S.; Pouya, M. Behavioral evaluation of regenerated rat sciatic nerve by a nanofibrous PHBV conduit filled with Schwann cells as artificial nerve graft. *Cell Commun. Adhes.* **2013**, *20*, 93–103. [[CrossRef](#)] [[PubMed](#)]
49. Giusti, G.; Willems, W.F.; Kremer, T.; Friedrich, P.F.; Bishop, A.T.; Shin, A.Y. Return of motor function after segmental nerve loss in a rat model: Comparison of autogenous nerve graft, collagen conduit, and processed allograft (AxoGen). *J. Bone Joint Surg. Am.* **2012**, *94*, 410–417. [[CrossRef](#)] [[PubMed](#)]
50. Summa, P.G.; Kalbermatten, D.F.; Pralong, E.; Raffoul, W.; Kingham, P.J.; Terenghi, G. Long-term in vivo regeneration of peripheral nerves through bioengineered nerve grafts. *Neuroscience* **2011**, *181*, 278–291. [[CrossRef](#)]
51. Saltzman, E.B.; Villa, J.C.; Doty, S.B.; Feinberg, J.H.; Lee, S.K.; Wolfe, S.W. A Comparison Between Two Collagen Nerve Conduits and Nerve Autograft: A Rat Model of Motor Nerve Regeneration. *J. Hand Surg. Am.* **2019**, *44*, 700.e1–700.e9. [[CrossRef](#)]

**Disclaimer/Publisher’s Note:** The statements, opinions and data contained in all publications are solely those of the individual author(s) and contributor(s) and not of MDPI and/or the editor(s). MDPI and/or the editor(s) disclaim responsibility for any injury to people or property resulting from any ideas, methods, instructions or products referred to in the content.