

CASE REPORT

Silent spontaneous uterine rupture in a term pregnancy with extrusion of an intact amniotic sac and without maternal and neonatal morbidity and mortality

Short title: Silent spontaneous uterine rupture

Felice **Sorrentino**^{1,*}, Lorenzo **Vasciaveo**¹, Francesca **Greco**¹, Maria Grazia **Morena**¹,
Guglielmo **Stabile**¹, Francesco **De Seta**^{2,3}, Stefano **Restaino**⁴, Antonio Simone **Laganà**⁵ and
Luigi **Nappi**¹

¹ Department of Medical and Surgical Sciences, Institute of Obstetrics and Gynecology, University of Foggia, Foggia, Italy.

² Institute for Maternal and Child Health IRCCS Burlo Garofolo, Trieste, Italy.

³ Department of Medical, Surgical and Health Sciences, University of Trieste, Trieste, Italy.

⁴ Department of Maternal and Child Health, Obstetrics and Gynecology Clinic, University-Hospital of Udine, Udine, Italy.

⁵ Unit of Gynecologic Oncology, ARNAS "Civico Di Cristina Benfratelli", Department of Health Promotion, Mother and Child-Care, Internal Medicine and Medical Specialties (PROMISE), University of Palermo, Italy.

***Corresponding author:** Felice **Sorrentino**, M.D., Ph.D. Department of Medical and Surgical Sciences, Institute of Obstetrics and Gynecology, University of Foggia, Viale Pinto 1 Foggia, 71121 Italy.

Email: felice.sorrentino.1983@gmail.com.

ORCID: 0000-0003-3993-2895.

Doi: 10.36129/jog.2024.153

ABSTRACT

Background. Uterine rupture in pregnancy is a rare and catastrophic complication with a high incidence of fetal and maternal morbidity and mortality. Silent spontaneous uterine rupture without maternal or neonatal morbidity or mortality is very rare.

Case presentation. We describe a case of silent spontaneous uterine rupture diagnosed during a planned cesarean section in a patient at 38+4 weeks' gestation with two previous cesarean sections. The mother and newborn were discharged three days later in good health and without complications.

Conclusions. Worldwide, the frequency of cesarean deliveries has increased in recent decades and uterine rupture is a very rare catastrophic emergency that can have dramatic consequences. Our case report shows that uterine rupture can occur in pregnancy before labour without any signs

or symptoms. Despite the uterine rupture with extrusion of the intact amniotic sac, there were no complications for the mother or the foetus. Timely diagnosis is crucial and future research should find more reproducible parameters to objectify the risk of silent uterine rupture and define the timing of delivery of previous cesarean sections requiring a new surgical delivery. All patients with previous cesarean sections should be counselled about the possibility of early delivery by cesarean section.

Key words

Spontaneous uterine rupture; cesarean section; trial of labor after cesarean section; cardiotocography; lower uterine segment.

INTRODUCTION

Uterine rupture is a rare but potentially life-threatening peripartum complication that leads to high maternal and perinatal morbidity and mortality. According to current literature, the most common risk factors are: trial of labor following previous cesarean section (TOLAC), augmentation of labor with oxytocin during TOLAC, misoprostol induction, previous uterine rupture, previous vertical uterine incision. Other risk factors with a less strong association have been described: gestational interval of less than 12 months, increasing maternal age, birthweight > 4000 gr, single-layer uterine closure especially if locked, previous cesarean delivery at periviability even after low transverse incision [1-8]. It occurs more frequently in the last weeks of pregnancy [9]. The incidence of uterine rupture in the population with previous cesarean section is around 0.3 %, regardless of whether it is a vaginal or cesarean delivery, although this percentage naturally increases when we talk about the TOLAC population [10-11]. The term "uterine rupture" refers to a complete separation of the endometrium, myometrium and perimetrium, i.e. all three layers of the uterus, which is clinically visible and often leads to an emergency situation for mother and fetus. It can occur during labor or before labor. Uterine dehiscence is the term used to describe an incomplete uterine rupture. This term is often used to describe a silent clinical situation in which the uterus is not completely ruptured and the serosa is intact. It is almost always the result of dehiscence of a previous cesarean delivery scar and is often asymptomatic. It is usually discovered during a repeat cesarean delivery or during manual exploration of the uterus after a successful vaginal delivery following a previous cesarean delivery. The terms rupture and dehiscence are often used interchangeably. The initial symptoms and signs of uterine rupture can typically be non-specific, leading to a difficult diagnosis that sometimes delays definitive surgical therapy. Symptoms of uterine rupture include cardiotocograph (CTG) abnormalities, severe or constant abdominal pain, vaginal bleeding, loss of fetal position, haematuria and hemodynamic deterioration [12]. In a silent uterine rupture, all these signs may be absent or misinterpreted and the rupture may be misdiagnosed or only detected at cesarean section.

CASE PRESENTATION

We describe a case of spontaneous uterine rupture in a 29-year-old woman at 38+4 weeks gestation with a history of two previous cesarean sections. On admission, the woman was healthy, her vital signs were within normal limits and her previous deliveries had both been by cesarean section in the lower segment. Palpation of the abdomen revealed that the baby was cephalic and the size of the uterus corresponded to 39 weeks gestation. A CTG was performed for 20 minutes without detecting any abnormalities or uterine contractions. Routine vaginal examination revealed that the cervix was closed and posterior. A planned cesarean section was performed. The previous deliveries by caesarean section were performed in 2016 and 2019 respectively. The last one was complicated by intra-abdominal adhesions (viscera were directly adhered to the abdominal wall),

so the third cesarean section (CS) was scheduled slightly before the term. In the meantime, after the second cesarean section, the patient was counselled in detail about the next birth timing and various contraceptive options (short-acting reversible contraceptives (SARC), long-acting reversible contraceptives (LARC)...). She expressed her desire to complete the family without using any contraceptive methods. One month before the third cesarean section, the patient requested permanent contraception. The patient was given detailed information about the various contraceptive options, but confirmed her desire for a tubal ligation on admission. The CTG, which was repeated before the operation according to our internal hospital protocols, showed no abnormalities in the fetal heart rate or uterine contractions. The abdominal cavity was opened with a Pfannenstiel incision. On attempted dissection of the bladder flap, uterine rupture was observed and the amniotic sac protruding into the abdominal cavity was visible (Fig. 1). Detachment of the bladder flap was particularly difficult because the bladder was tightly attached. The fetus was delivered in the cephalic position due to the large defect that was already present. The conservative repair (re-suturing after debridement) was performed by our more experienced obstetric surgeon. The APGAR of the newborn was 8 and 9 after 1 and 5 minutes respectively, with a pH of 7.37 and a base excess of -2.2. The birth weight was 5,776 pounds (lb) (2620 g). The uterus was repaired with a double-layer closure using a synthetic absorbable braided suture material made of polyglactin 910.

In detail, double-layer closure was performed with the first layer in a continuous unlocked suture including the endometrial layer and the second layer was also continuous unlocked and imbricated the first. The tubal ligation was performed at the patient's request. The patient had an uncomplicated recovery with normal postpartum bleeding and a postoperative hemoglobin level of 9.80 gr/dl (from a preoperative level of 10.30 gr/dl). The mother and newborn were discharged three days later in good health and without complications. One year later an expert sonographer meticulously conducted the ultrasound assessment of uterine scar utilizing a multifrequency transvaginal probe ranging from 5.0 to 9.0 MHz of GE Voluson E10 ultrasound machine (GE Medical Systems, Zipf, Austria). A small isthmocele and a residual myometrial thickness (RMT) of 2 mm were found. (Fig. 2-3).

DISCUSSION

Uterine rupture can be a catastrophic complication of pregnancy. The higher incidence is associated with a trial of labor following a previous cesarean section (TOLAC) [13]. Abdominal pain, vaginal bleeding, maternal hypovolemic shock and hemorrhage are signs and symptoms of uterine rupture. However, our patient had no symptoms. There may be no symptoms or signs of uterine rupture[14]. Also, no complications have been reported for mother and fetus (very few cases have been described so far) [15-16].

In our case, we decided to anticipate the CS before 39 weeks, as the previous operation was difficult due to adhesions. Early term deliveries are not without fetal risks/complications (respiratory distress syndrome, transient tachypnea of the newborn, ventilator use, pneumonia, respiratory failure, neonatal intensive care unit admission, hypoglycemia, 5-minute APGAR score less than 7, neonatal mortality [17]. However, administration of steroids was not considered as in our institution as well as in other areas of the world, steroids are recommended for late preterm labor at gestational age less than 36w5d [18]. The final diagnosis of uterine rupture is based on evidence of complete disruption of all three layers of the uterus (including the serosa) on imaging or laparotomy. There is no reliable method for predicting this obstetric emergency. As the risk of uterine rupture in patients undergoing TOLAC is 0.5%, far from irrelevant, researchers have conducted sophisticated analyses with the aim of predicting the likelihood of uterine rupture in specific patients based on risk factors. A number of predictive models for uterine rupture using a combination of risk factors have been described, but none have been shown to be reliable or

clinically useful [10,19]. The utility of measuring lower uterine segment thickness was investigated in a multicenter randomized trial [20]. A systematic review (21 studies) found that no threshold for myometrial thickness is appropriate for predicting in clinical practice whether a hysterotomy scar will rupture or not [21]. The quantitative risk of rupture associated with the thickness of the scar has not been determined, a thin lower uterine segment has a low positive predictive value for rupture [22], and uterine rupture occurred during labor in patients with a normal thickness of the lower uterine segment [23-24]. Some authors consider a total thickness of the lower uterine segment < 2 mm to be predictive of an increased risk of rupture or dehiscence [25] and a recent meta-analysis report that a thickness greater than 3.6 mm is associated with a reduced probability of uterine rupture [26]. All authors agree on the importance of including this information in clinical counselling [21,27]. In our case, a completely asymptomatic patient experienced a silent rupture of the uterus. The patient underwent a routine ultrasound scan on admission to hospital. No abnormal findings were observed. However, none of these examinations specifically looked for the lower uterine segment (LUS) as we do not routinely measure the thickness of LUS in patients with a previous cesarean section. CT and MRI are not used because the diagnosis takes longer. In our case, no fetal heart rate abnormalities or uterine contractions were detected on the CTG before delivery. The CTG is not a useful tool for diagnosing uterine rupture. The extrusion of the amniotic sac was complete but there were no maternal-fetal complications. In addition, the silent rupture of the uterus occurred in a patient scheduled for a repeat cesarean section at 38+4 weeks. In addition, a double-layer closure was performed to obtain a thicker myometrial layer at the site of the CS scar (RMT) [28]. However, it should be emphasized that on ultrasound examination one year later, despite the surgical strategy and the type of suture, the residual myometrial thickness was only 2 mm. As the patient underwent tubal sterilization, we will never know whether she may have suffered a new uterine rupture. All international guidelines for low cesarean section deliveries recommend planning a repeat cesarean section starting from 39+0 weeks, regardless of the number of previous cesarean sections, and in case of a previous uterine rupture (or uterine dehiscence) and classic cesarean sections to expect 36 0/7-37 0/7 weeks [29-32].

Due to the increasing number of births by cesarean section [31, 33], all patients with a previous cesarean section should be better counselled about effective contraceptive methods after birth in order to avoid unwanted and short-term pregnancies. They should also be fully informed about the risks of repeat surgery and its rare complications [34] and made aware of the possibility of a silent uterine rupture without signs or symptoms. Our case emphasises that a more individualised approach should be considered. This rare event may become more common due to the significant increase in repeat cesarean sections, particularly in our geographical region. Perhaps it would be right to anticipate the timing of cesarean delivery even in patients with more than one cesarean section and without other risk factors. The other crucial point is to try to find more accurate methods to diagnose silent uterine rupture. As mentioned before, we do not routinely use ultrasound to assess the thickness of the lower uterine segment. However, in these patients with previous cesarean section who have no abnormal symptoms, it would be desirable that ultrasound examination to assess the thickness of the lower uterine segment is performed only by an operator with special expertise in obstetric ultrasound. For silent rupture of the uterus, there are currently no studies, statistical data or trials that allow us to make recommendations [20]. The only objective data obtained in the last 20 years comes from ultrasound examination of the thickness of the LUS. In our case, the patient was not a candidate for TOLAC, but she had a silent rupture of the uterus. This suggests that it may be useful to assess the thickness of the LUS in previous cesarean sections even in patients who have no noticeable symptoms. Although ultrasonography is essentially a real-time examination, assessing the thickness of the myometrium in all previous cesarean sections would not only be useful in patients who are candidates for TOLAC, but could also be very helpful in scheduling previous cesarean sections that require a new surgical delivery. It is therefore desirable that new research can objectify the risks of uterine rupture for obstetricians, which are increasingly objective and in line with current technology, rather than being determined

by assessments, which, although correct, remain subjective and therefore questionable. The incidence of cesarean deliveries has increased globally in recent decades [31,33]. Uterine rupture, a uncommon obstetric complication, has a high rate of fetal and mother morbidity and mortality [35].

CONCLUSIONS

Our case report shows that uterine rupture in pregnancy can occur before labor without any signs or symptoms. Another special feature is that despite uterine rupture with extrusion of the intact amniotic sac, there were no complications for the mother or the fetus. Timely diagnosis is crucial and future research should find more reproducible parameters to objectify the risk of silent uterine rupture and define the timing of delivery of previous cesarean sections requiring a new surgical delivery. All patients with previous cesarean sections should be educated about the possibility of silent uterine rupture without signs or symptoms and made aware of the possibility of anticipating the timing of cesarean delivery.

COMPLIANCE WITH ETHICAL STANDARDS

Authors contribution

F.S., L.V.: Conceptualization; F.S.: Writing – original draft; F.S., L.V., F.G., M. G. M., G.S., F. D.S., S.R., A.S.L., L.N.: Writing – review & editing. All authors: revising and final approval of the manuscript.

Funding: None.

Study registration: Not applicable.

Disclosure of Interests: The authors declare that they have no conflict of interests.

Ethical Approval: Not applicable.

Informed consent: Written informed consent was obtained from the patient for publication of this case report and accompanying images.

Data sharing: The data that support the findings of this study are available from the corresponding author upon reasonable request.

REFERENCES

1. Fitzpatrick KE, Kurinczuk JJ, Alfirevic Z, Spark P, Brocklehurst P, Knight M. Uterine rupture by intended mode of delivery in the UK: a national case-control study. *PLoS Med.* 2012;9. doi: 10.1371/journal.pmed.1001184.
2. Savukyne E, Bykovaite-Stankeviciene R, Machtejeviene E, Nadisauskiene R, Maciuleviciene R. Symptomatic Uterine Rupture: A Fifteen Year Review. *Medicina (Kaunas).* 2020 Oct 29;56(11):574. doi: 10.3390/medicina56110574.
3. Stenson D, Wallstrom T, Sjostrand M, Akerud H, Gemzell-Danielsson K, Wiberg-Itzel E. Induction of labor in women with a uterine scar. *J Matern Fetal Neonatal Med.* 2016. doi: 10.3109/14767058.2015.1123242.

4. Ophir E, Odeh M, Hirsch Y, Bornstein J. Uterine rupture during trial of labor: controversy of induction's methods. *Obstet Gynecol Surv.* 2012 Nov;67(11):734-45. doi: 10.1097/OGX.0b013e318273feeb. PMID: 23151757.
5. Cunningham S, Algeo CE, De Franco EA. Influence of interpregnancy interval on uterine rupture. *J Matern Fetal Neonatal Med.* 2021 Sep;34(17):2848-2853. doi: 10.1080/14767058.2019.1671343.
6. Roberge S, Chaillet N, Boutin A, Moore L, Jastrow N, Brassard N, et al.. "Single- versus Double-Layer Closure of the Hysterotomy Incision during Cesarean Delivery and Risk of Uterine Rupture." *International Journal of Gynecology & Obstetrics* 2011. doi: 10.1016/j.ijgo.2011.04.013.
7. Roberge S, Demers S, Berghella V, Chaillet N, Moore L, Bujold E. Impact of single- vs double-layer closure on adverse outcomes and uterine scar defect: a systematic review and metaanalysis. *Am J Obstet Gynecol.* 2014,. doi: 10.1016/j.ajog.2014.06.014.
8. Lannon SMR, Guthrie KA, Vanderhoeven JP, Gammill HS. Uterine rupture risk after periviable cesarean delivery. *Obstet Gynecol.* 2015 May;125(5):1095-1100. doi: 10.1097/AOG.0000000000000832.
9. Whittington JR., Slaton KB, Rhomberg ME, Ghahremani T, Thomas SL, Magann EF. Uterine Dehiscence and Subsequent Pregnancy Management: A Review of the Literature. *Obstet Gynecol Surv.* 2021, 76(1):48-54. doi: 10.1097/OGX.0000000000000856
10. Guise JM, Eden K, Emeis C, Denman MA, Marshall N, Fu RR, et al. Vaginal birth after cesarean: new insights. *Evid Rep Technol Assess (Full Rep).* 2010, (191):1-397.
11. Zanini A, Inzoli A, Mingozzi S, Zanini U, Miglietta M. The failure rate and related factors of vaginal delivery after caesarean section. *Ital J Gynaecol Obstet.* 2022,34, 1(19-24). doi: 10.36129/jog.34.01.03
12. Langhe R, Shah UF, Alfathil A, et al. Silent uterine rupture in scarred uterus. *Case Reports* 2017, 24 2017: bcr2016218189. doi: 10.1136/bcr-2016-218189.
13. Vilchez G, Gill N, Dai J, Chelliah A, Jaramillo H and Sokol R. "156: rupture in the scarred uterus". *Am J Obstet Gynecol.* 2015 212 (1): S94–S95. <https://doi.org/10.1016/j.ajog.2014.10.202>
14. Xiao J, Zhang C, Zhang Y, Zhao F, Yang J, Li G, Zhou X. Ultrasonic manifestations and clinical analysis of 25 uterine rupture cases. *J Obstet Gynaecol Res.* 2021. doi: 10.1111/jog.14666.
15. Lynch ME, Dakkak M. Case Report: Successful Maternal and Fetal Outcomes After Uterine Rupture. *Am Fam Physician.* 2018 Sep 1;98(5):272.
16. Kok N, Ruiter L, Hof M, Ravelli A, Mol BW, Pajkrt E, et al. Risk of maternal and neonatal complications in subsequent pregnancy after planned cesarean section in a first birth, compared with emergency cesarean section: a nationwide comparative cohort study. *BJOG.* 2014 Jan;121(2):216-23. doi: 10.1111/1471-0528.12483.
17. ACOG Committee Opinion No. 765: Avoidance of Nonmedically Indicated Early-Term Deliveries and Associated Neonatal Morbidities. *Obstet Gynecol.* 2019, 133(2): e156-e163. doi: 10.1097/AOG.0000000000003076.
18. American College of Obstetricians and Gynecologists' Committee on Obstetric Practice, Society for Maternal-Fetal Medicine. Medically Indicated Late-Preterm and Early-Term Deliveries: ACOG Committee Opinion, Number 831. *Obstet Gynecol.* 2021, 138(1): e35-e39. doi: 10.1097/AOG.0000000000004447.

19. Landon MB. Predicting uterine rupture in women undergoing trial of labor after prior cesarean delivery. *Semin Perinatol.* 2010, 34(4):267-71. doi: 10.1053/j.semperi.2010.03.005
20. Rozenberg P, Sénat MV, Deruelle P, et al. Evaluation of the usefulness of ultrasound measurement of the lower uterine segment before delivery of women with a prior cesarean delivery: a randomized trial. *Am J Obstet Gynecol* 2022, doi: 10.1016/j.ajog.2021.08.005
21. Kok N, Wiersma IC, Opmeer BC, de Graaf IM, Mol BW, Pajkrt, E. Sonographic Measurement of Lower Uterine Segment Thickness to Predict Uterine Rupture during a Trial of Labor in Women with Previous Cesarean Section: A Meta-Analysis. *Ultrasound Obstet Gynecol* 2013, 42 (2), 132–139. <https://doi.org/10.1002/uog.12479>.
22. Jastrow N, Demers S, Chaillet N, Girard M, Gauthier RJ, Pasquier JC, et al.. Lower uterine segment thickness to prevent uterine rupture and adverse perinatal outcomes: a multicenter prospective study. *Am J Obstet Gynecol.* 2016. doi: 10.1016/j.ajog.2016.06.018.
23. Bergeron ME, Jastrow N, Brassard N, et al. Sonography of lower uterine segment thickness and prediction of uterine rupture. *Obstet Gynecol* 2009, 113(2 Pt 2):520-522. doi: 10.1097/AOG.0b013e31818c15a7.
24. McLeish SF, Murchison AB, Smith DM, Ghahremani T, Johnson IM, Magann EF. Predicting Uterine Rupture Risk Using Lower Uterine Segment Measurement During Pregnancy with Cesarean History: How Reliable Is It? A Review. *Obstet Gynecol Surv.* 2023 May;78(5):302-308. doi: 10.1097/OGX.0000000000001143.
25. Jastrow N, Demers S, Chaillet N, Girard M, Gauthier RJ, Pasquier JC, et al. Lower Uterine Segment Thickness to Prevent Uterine Rupture and Adverse Perinatal Outcomes: A Multicenter Prospective Study. *Am J Obstet Gynecol* 2016. doi:.1016/j.ajog.2016.06.018.
26. Swift BE, Shah PS, Farine D. Sonographic lower uterine segment thickness after prior cesarean section to predict uterine rupture: A systematic review and meta-analysis. *Acta Obstet Gynecol Scand.* 2019. doi: 10.1111/aogs.13585
27. Jastrow N, Vikhareva O, Gauthier RJ, Irion O, Boulvain M, Bujold E. Can Third-Trimester Assessment of Uterine Scar in Women with Prior Cesarean Section Predict Uterine Rupture? *Ultrasound Obstet Gynecol.* 2016, 47 (4), 410–414. <https://doi.org/10.1002/uog.15786>.
28. Stegwee SI, Jordans IPM, van der Voet LF, Bongers MY, de Groot CJM, Lambalk CB, et al. Single- versus double-layer closure of the caesarean (uterine) scar in the prevention of gynaecological symptoms in relation to niche development - the 2Close study: a multicentre randomised controlled trial. *BMC Pregnancy Childbirth.* 2019 Mar 4;19(1):85. doi: 10.1186/s12884-019-2221-y.
29. RCOG Birth after previous caesarean birth. Green-top Guideline No. 45 October 2015. [available at <https://www.rcog.org.uk/guidance/browse-all-guidance/green-top-guidelines/birth-after-previous-caesarean-birth-green-top-guideline-no-45/>]
30. ACOG Practice Bulletin No. 205: Vaginal Birth After Cesarean Delivery. *Obstet Gynecol.* 2019, 133(2): e110-e127. doi:10.1097/AOG.0000000000003078
31. Linea Guida 22—Sistema Nazionale per le Linee Guida. Taglio Cesareo: Una Scelta Appropriata e Consapevole. Seconda Parte. Edizione 2012, Ultima Revisione Gennaio 2016. Available online: https://www.epicentro.iss.it/itoss/pdf/Taglio%20_Cesareo_seconda.pdf
32. Carlucci S, Stabile G, Sorrentino F, Nappi L, Botta G, Menato G, et al. The singular case of multiple chorangioma syndrome in an IVF pregnancy. Analysis of the case and review of literature. *Placenta.* 2021 Jan. doi: 10.1016/j.placenta.2020.10.025

33. Sorrentino F, Greco F, Palieri T, Vasciaveo L, Stabile G, Carlucci S, et al. Caesarean Section on Maternal Request-Ethical and Juridic Issues: A Narrative Review. *Medicina* 2022, 58, 1255. <https://doi.org/10.3390/medicina58091255>
34. Etrusco A, Fabio M, Cucinella G, de Tommasi O, Guastella E, Buzzaccarini G, et al. Uterocutaneous fistula after caesarean section delivery: diagnosis and management of a rare complication. *Prz Menopauzalny*. 2022 Sep;21(3):214-217. doi: 10.5114/pm.2022.119263.
35. Al Shukri M, Gowri V. Asymptomatic uterine rupture in a term pregnancy following a uterine perforation in a hysteroscopic procedure: a case report. *Ital J Gynaecol Obstet*. 2023. doi: 10.36129/jog.2023.96

Manuscript accepted for publication

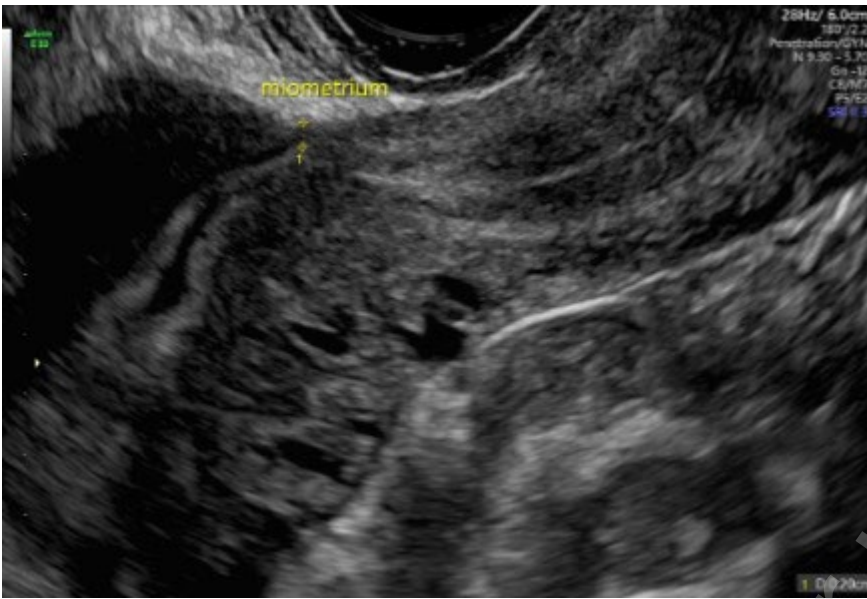
Figure 1. Amniotic sac protruding into the abdominal cavity.

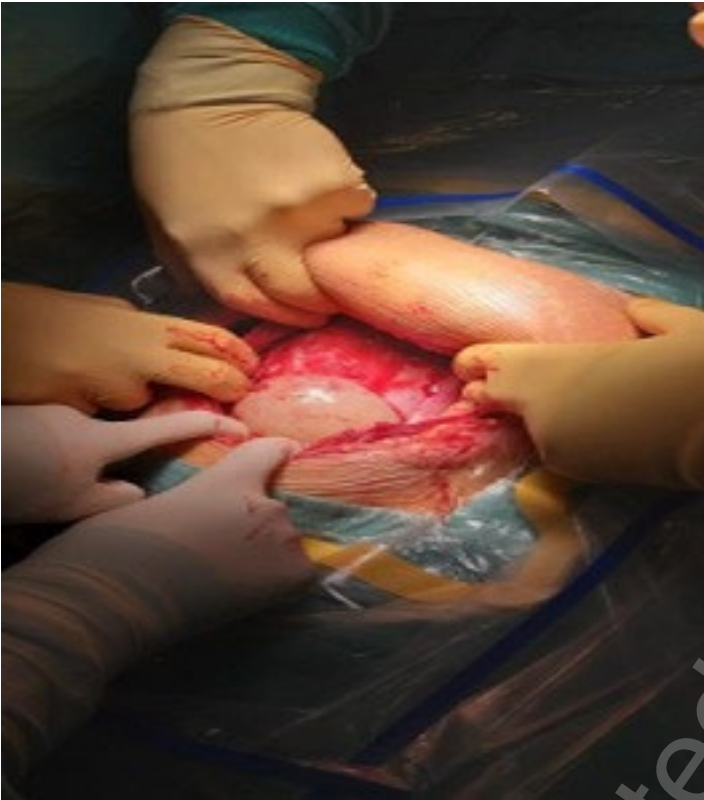

Figure 2. Ultrasound scan one year later: presence of isthmocele

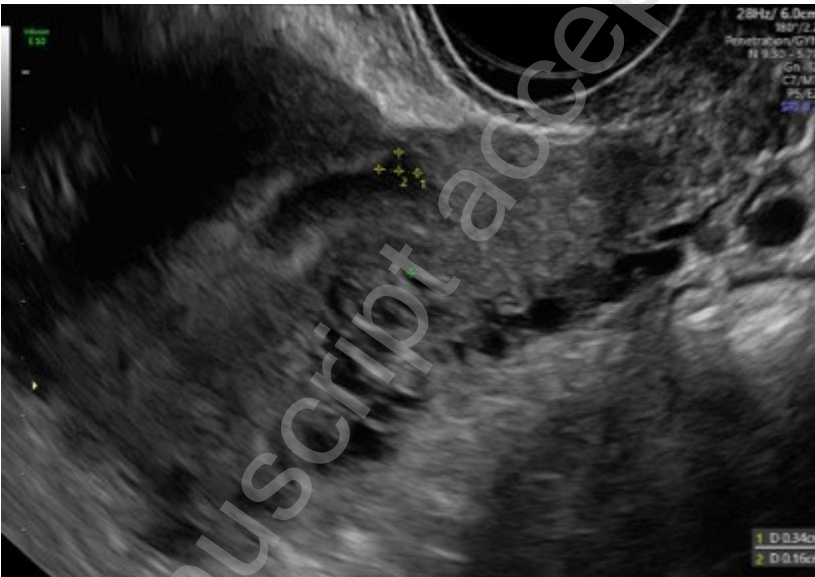

Figure 3. Ultrasound scan one year later: residual myometrial thickness (RMT) of 2 mm.



Manuscript accepted for publication