



Citation: Veronica Papa, Mauro Vaccarezza, Francesco M. Galassi, Elena Varotto (2023) Discover the anatomy of the mummies: how imaging techniques contribute to understanding disease in the past. *Italian Journal of Anatomy and Embryology* 127(1): 23-34. doi: 10.36253/ijae-14549

Copyright: ©2023 Veronica Papa, Mauro Vaccarezza, Francesco M. Galassi, Elena Varotto. This is an open access, peer-reviewed article published by Firenze University Press (<http://www.fupress.com/ijae>) and distributed under the terms of the Creative Commons Attribution License, which permits unrestricted use, distribution, and reproduction in any medium, provided the original author and source are credited.

Data Availability Statement: All relevant data are within the paper and its Supporting Information files.

Competing Interests: The Author(s) declare(s) no conflict of interest.

Mini review

Discover the anatomy of the mummies: how imaging techniques contribute to understanding disease in the past

VERONICA PAPA^{1,2,3,*}, MAURO VACCAREZZA^{4,5}, FRANCESCO M. GALASSI^{6,a}, ELENA VAROTTO^{1,7,a}

¹ Forensic Anthropology, Paleopathology and Bioarchaeology (FAPAB) Research Center, Avola, Italy

² Department of Economics, Law, Cybersecurity, and Sports Sciences, University of Naples "Parthenope", Naples, Italy

³ School of Science, Engineering and Health, University of Naples "Parthenope", Naples, Italy

⁴ Curtin Medical School, Faculty of Health Sciences, Curtin University, Bentley, Perth, 6102 Western Australia, Australia

⁵ Curtin Health Innovation Research Institute (CHIRI), Faculty of Health Sciences, Curtin University, Bentley, Perth, 6102 Western Australia, Australia

⁶ Department of Anthropology, Faculty of Biology and Environmental Protection, University of Lodz, Lodz, Poland

⁷ Archaeology, College of Humanities, Arts and Social Sciences, Flinders University, Adelaide, SA, Australia

*Corresponding author. E-mail: veronica.papa@uniparthenope.it

^aShared last (senior) authorship.

Abstract. Mummies are the well-preserved remains of humans or animals in which non-bony tissue has been maintained naturally or artificially. Their significance lies in their contribution to paleopathological research, which involves understanding the history and evolution of diseases and providing insights into past populations' cultural and social practices. In recent years, mummies studies used nondestructive methods, including modern imaging techniques, to assess the main pathological features of these unique human remains. This mini-review focuses on the role of paleoradiology in mummies' studies and describes the history of mummy radiography and CT scanning over the last fifteen years. The search strategy was conducted between January and April 2023. One thousand one hundred twenty-four records (1124) were initially identified, and 52 studies were assessed for qualitative synthesis. Three main themes and four subthemes were identified, providing a general overview of the role of paleoradiology or offering methodological guidelines. Also, subthemes assessed the role that the use of radiology has in the diagnosis of specific pathologies. Therefore, imaging techniques in ancient human remains might help understand the history and evolution of past and present diseases and their risk factors.

Keywords: computed tomography, magnetic resonance, paleoradiology, radiography, mummies, paleopathology, review.

INTRODUCTION

The word “mummy” has a fascinating history that evolved over time. Initially, it was used to describe a black, tarry substance that was thought to have healing properties. This substance, first reported by Pliny the Elder (AD 23-79), the Roman scholar, was called “múmiyá” by the Persians, likely because it resembled wax, which the Arabs called “mum” (Aufderheide, 2003). Moreover, bitumen and asphalt, inducing dehydration, have been utilized by the ancient Egyptians in their mummification procedures and resulted in the dark or blackened appearance of the mummies’ skin. Therefore, substituting this black, crystalline resin found in mummified Egyptian bodies for bitumen in medicine was made possible due to its chemical similarity in later centuries (Monge and Rühli, 2015). Consequently, the term “mumiya” was extended to include these resins and to describe embalmed bodies. Moreover, in the eighteenth century, its clinical efficacy was demonstrated to be due to the desiccated, light-brown muscle fragments discovered in mummies’ resin (Lynnerup, 2010). This evidence resulted in the word “mummy” being used to refer to any form of mummified human remains, including preserved non-skeletal tissues of the human body. Typically, soft tissue preservation happens when natural circumstances or human interventions, such as mortuary practices that might mimic environmental conditions, hinder taphonomic processes (Lynnerup, 2007). Furthermore, the outcome of soft tissue preservation varies greatly due to the collagen levels in the matrix. Generally, muscles and tendons are the soft tissues most commonly preserved. At the same time, organs of the digestive system are often entirely decomposed, and their description might anyhow be challenging due to their desiccation. Also, funerary rites might involve embalming and evisceration procedures and completely remove internal organs and the brain (Lynnerup, 2010). The study of mummies began in the late 18th century and has been intimately linked to the paleopathology of non-bony tissues. Its evolution has been substantial, and it is currently utilized to investigate the history, change, and patterns of disease in past populations. Although recent concerns have been raised regarding methodological accuracy, reliability (O’Brien et al., 2009; Cox, 2015), and even ethical issues (Kaufmann and Rühli, 2010; Kreissl Lonfat et al., 2015), mummies’ studies have undeniably experienced consistent growth over the past 50 years (Nystrom, 2018). From the beginning of mummy research, unwrapping and opening mummies’ body cavities has been a standard procedure, and autopsies were often performed on

Egyptian mummies. Nevertheless, there is no doubt that being an invasive and destructive procedure, an autopsy undermines the integrity of the mummy as an archaeological and cultural-historical specimen. Moreover, when handling human remains, ethical, moral, and even religious issues arise since mummies, like body donors, are not merely research material (Shin and Bianucci, 2021). They do have to be considered human beings and have to be treated accordingly, including acknowledging and honoring their religious beliefs and burial traditions. (Holm, 2001; Lynnerup, 2009; Papa and Vaccarezza, 2013; Papa et al., 2022). Consequently, in more recent years, the trend in mummies studies has shifted to a clinical and medical approach based on nondestructive methods, including especially modern imaging techniques such as radiography (X-rays), computed tomography (CT scan), and magnetic resonance imaging (MRI) David and Tapp, 1984; Aufderheide, 2003; O’Brien et al., 2009; Cox, 2015) [1, 5].

Standard radiographies are non-invasive techniques commonly used to examine the internal structures of mummies. First discovered by William Röntgen (1845 –1923) in 1895, X-rays were then used by Petrie and Moodie, who, in 1931, published the first systematic analysis of a mummy collection based on radiography (Lynnerup, 2010). Furthermore, these techniques are used for both archaeological and medical purposes, such as studying amulets within mummy wrappings and estimating age and sex based on skeletal features, whenever possible. Other pathological signs eventually diagnosed by X-rays include diseases affecting skeletal or calcified structures, such as arthritis, atheroma, bone fractures, and infection-induced changes such as Pott’s disease. In more recent years, a crucial improvement in the accuracy of mummies studies came from the advent of Computed Tomography (CT) scanners that allow the study of 3D skeletal and soft tissues without overlapping juxtaposed structures as in 2D radiograms. In addition, computed tomography provides paleopathologists with a sectional view of a scanned body, enabling them to non-invasively examine mummies’ complete skeletons and soft tissues without disrupting their wrapping or encasement. Moreover, CT scans might be used to confirm eventual morphological similarities, prompters of family relationships or diseases, and putative causes of death (Habicht et al., 2015). Initially developed for medical imaging, CT imaging was applied to a mummy study two years after its development in 1975 (Cox, 2015). The first CT scanning of mummies was performed in 1977 by Lewin and Harwood-Nash (1977) who CT scanned an Egyptian mummy named Nakht from the Royal Ontario Museum with the purpose to evaluate the mor-

phology of the brain and eventually its pathological features (Lewin and Harwood-Nash, 1977). Since then, CT has been performed on mummies for almost 40 years and has become an increasingly popular method in mummy studies in the 21st century (Harwood-Nash, 1979). Although CT scan still represents the diagnostic gold standard for mummy studies, recent evidence demonstrated successful application of magnetic resonance which allows more effective tissue discrimination on ancient specimens compared to CT (Rühli, 2015). In addition, CT scan imaging allows 3D virtual reconstructions and the analysis on different planes.

Therefore, the aim of this study was to provide a short examination of the literature to evaluate how paleoimaging contributes to studying the history of both past and present diseases.

METHODS

A literature review was performed between January and April 2023. The steps have been assessed in the identification of the research question, the identification of relevant studies, the selection of specific studies, and finally, reporting of the results. The search strategy was designed by V.P. and E.V., validated by the senior author (F.M.G.), and included the terms “Paleoradiology AND human remains OR Mummies”. It was carried out in PubMed (U.S. National Library of Medicine, National Institutes of Health, Bethesda, MD), Biomed Central (BioMed Central Ltd., Springer Nature, London, UK), Scopus (Elsevier B.V., Amsterdam, the Netherlands), and Google Scholar (Google Inc., Mountain View, CA) search engines. Inclusion criteria enclosed any article published in English-language and peer-reviewed journals in the last 15 years (from 2008-2023) that focused on the role of modern imaging techniques in the paleopathology of ancient human remains and mummies. Titles, abstracts, keywords, and full texts were reviewed by two authors (V.P. and M.V.). Eventually, conflicts between reviewers were discussed until a consensus was reached, and the senior author (F.M.G.) was involved if needed. Afterward, the included records were screened, and a thematic analysis was performed. A total of 1124 records were initially identified; after duplicate removal, 332 records were further processed. Afterward, abstracts, keywords, and the complete reference list were analyzed for all articles. Only items whose abstract unequivocally discussed the topic were included. Therefore, 250 records were excluded with reason, and 82 were finally assessed for full-text screening and qualitative analysis.

The Preferred Reporting Items for Systematic Reviews and Meta-Analysis (PRISMA) flowchart was utilized for the reporting of findings (Aromataris and Riitano, 2014; Moher et al., 2015; Tricco et al., 2018) [39–41], and it is available in the Results section (see below). The records included in this study are listed in Table 1. All the authors agreed on the final number of studies included. Finally, the enrolment of records in the qualitative synthesis was made using the online Research Screener machine learning tool for systematic reviews (Chai et al., 2021). The sample in this qualitative analysis was represented by the records assessing the role of radiological techniques in the paleopathology of human remains and mummies.

Initially, the data set imported into the Research Screener machine learning tool was represented by the 82 records assessed for qualitative analysis. Credibility and reliability were ensured by debriefing and triangulation.

After extensive discussion among team members, eight ($n = 8$) seed articles were identified (Lynnerup, 2007, 2009, 2010; O’Brien et al., 2009; Cox, 2015; Monge and Rühli, 2015; Nystrom and Tilley, 2019; Nystrom, 2020). Moreover, 30 missing abstracts were automatically removed by the tool. Therefore, a final set of 52 abstracts was further screened. Two reviewers (V.P. and E.V.) independently flagged the abstract and coded the data into themes and subthemes, which were discussed on a regular basis.

Themes and subthemes were generated using the trial version of NVivo qualitative data analysis software package (QSR International Pty, Ltd., Melbourne, VIC, Australia). Moreover, when available, non-narrative data were extracted, categorized, and imported to Excel (Microsoft Corp., Redmond, WA) for further evaluation.

RESULTS AND DISCUSSION

The authors extensively discussed the foundations of their query. Moreover, they reviewed the pools to ensure they were consistent with the research question. Any further discrepancy was discussed to minimize bias. The authors will address three main themes and four subthemes that were used to analyze the included records. Moreover, non-narrative data were analyzed in terms of type of publication (letter to the editor, original research, review, etc.), and the radiological technique that was utilized. Fifty-two records ($n=52$) were finally included in the qualitative synthesis. Of those, twenty-eight ($n=28$; 53,8%) were categorized as original articles, 18 (34,6%) as reviews, 2 (3,84%) as letters, 1 (1,92%) as an editorial, 1 (1,92%) as a perspective, 1 (1,92%) as a note and 1 (1,92%) as a brief report. With regards to the

radiological technique that was used or discussed, CT scan was most widely exploited (n=28; 53,8%); X-rays were utilized and appraised in 7 studies (n=7; 13,46%); ultrasound and magnetic resonance in 2 studies each (n=2; 3,77%). Only one study (n=1;1,92%) used a combination of CT scans and X-rays, while in 12 (n=12; 23%) studies, this sorting criteria was not applicable. Three main themes were identified: the first related to a general review assessing the role of paleoradiology in mummies studies, the second containing methodological guidelines, and the third related to the ability of paleoradiology to diagnose or review specific pathologies in mummified remains. From the latter, three subthemes were further identified. They were related to specific diseases such as cardiovascular diseases, bone of spine diseases, and infectious, cancer and other diseases.

Themes and subthemes have been included in Table 1. Additionally, a flowchart depicting the 'Reporting items for systematic reviews' adapted from the 'Preferred reporting items for systematic reviews (PRISMA)' statement has been provided. Please refer to Figure 1 below for the flowchart.

Paleoradiography has been widely acknowledged as a crucial non-invasive method for studying ancient human remains (Lynnerup, 2007, 2009, 2010; O'Brien et al., 2009; Beckett, 2014; Cox, 2015; Lynnerup and Rühli, 2015; Moissidou et al., 2015; Rühli, 2015, 2015; Garvin and Stock, 2016; Giovannetti et al., 2016, 2022; Habicht et al., 2016; Licata et al., 2019; Nystrom, 2020), and several guidelines have been issued on its use (Panzer et al., 2015, 2017, 2018, 2019; Tanti et al., 2021). Moreover, Cramer and coworkers (Cramer et al., 2018) performed a systematic review to summarize artificial changes and detectable paleopathologies diagnosed by CT scans. Although the systematic review only included published records in PubMed, the authors demonstrated that CT analyses might be used to confirm previous conventional studies of paleopathologies and eventually identify traumatic injuries. Moreover, consistent with other findings (Jackowski et al., 2008; Panzer et al., 2010; Öhrström et al., 2021), the authors demonstrated the prevalence the typical destruction of the nasal skeleton due to the removal of the brain and identified traumatic fractures as well as chronic degenerative changes of skeletal bones and arteriosclerosis were reported in a subfraction. Finally, general consensus has been expressed in favor of using three-dimensional visualization in mummy studies. It is also worth mentioning that 14 records evaluated the presence of skeletal diseases (Jackowski et al., 2008; Panzer et al., 2010; Dalchow et al., 2012; Schamall et al., 2012; Schmidt et al., 2013; Saleem and Hawass, 2014; Fritsch et al., 2015; Márquez et al., 2015, 2015; Piombino-Mascali et al., 2015; Villa et

al., 2015; Traversari et al., 2016; Beckett et al., 2020; Yatsishina et al., 2020; Öhrström et al., 2021), although some of them were heavily criticized (Beckett et al., 2020, Bianucci et al., 2021a, Bianucci et al., 2021b, Bianucci et al., 2021c). Of note, the majority of the records categorized in this subtheme, described and evaluated common and uncommon bone pathologies while Fritsch and coworkers described severe rotator cuff arthropathy and rotator cuff impingement (Fritsch et al., 2015). The authors conducted a study on 52 ancient Egyptian mummies to determine the occurrence of orthopedic diseases. They systematically reviewed orthopedic diseases observed on CT scans of ancient mummies and demonstrated a higher frequency of osteoarthritic changes in the spine than in the large joints. Moreover, these authors reported for the first time a case of Perthes disease, the juvenile aseptic necrosis of the hip, and diagnosed severe rotator cuff arthropathy and rotator cuff impingement.

Seventeen records evaluated chronic, infectious, or neoplastic diseases. Cardiovascular diseases were demonstrated in 10 studies (Allam et al., 2011; Chandrashekar and Narula, 2011; Thompson et al., 2013, 2014; Clarke et al., 2014; Wann and Thomas, 2014; Wann et al., 2015; Gabrovsky et al., 2016; Panzer et al., 2021; Herrerin et al., 2022), while 7 (Friedrich et al., 2010; Hussein et al., 2013; Lacout et al., 2016a, 2016b; Herrerin et al., 2018; Ventura et al., 2021) assessed the aforementioned pathological conditions. Today, CVD represents the leading cause of death worldwide in both men and women, accounting for at least one-third of all deaths in women and half of deaths in women over 50 years in developing countries (Vacca-rezza et al., 2020). Although atherosclerosis was first identified in the mummy of an elderly Egyptian woman in 1852 and diagnosed in ancient in a calcific aortic atherosclerosis, it is still often wrongly thought to be a disease of the modern era, related to contemporary lifestyles, diet, environmental factors, and chronic inflammatory diseases (Thompson et al., 2013; Wann and Thomas, 2014). Nevertheless, CT scans on ancient mummies clearly demonstrated that atherosclerosis was prevalent even in ancient populations and suggested that this disease was present and commonplace in ancient Egypt. Therefore, challenging questions arise about the nature and extent of human predisposition to the development of atherosclerosis. Furthermore, ancient human populations had a different range of diets and lifestyles; thus, the incidence of atherosclerosis in these populations cannot be explained by traditional and modern risk factors. Instead, inhaling cooking fire smoke and chronic infection or inflammation is likely to have been crucial in developing atherogenic plaques in ancient populations. In 2016, Gabrovsky et al. (Gabrovsky et al., 2016), suggested that the chew-

Table 1. List of the included records: the table details the main features of the included records: authors, type of the study, keywords, country, and eventually, the radiological technique that has been appraised. The indication of theme and subthemes has been provided. Abbreviation: DVI, disaster victim identification; MDCT, multidetector computed tomography; CT scan, computer tomography scan; aDNA, ancient DNA; TIRADS, thyroid imaging reporting and database system; CVD, cardiovascular disease(s).

Study details	Title	Type of study	Key words	Radiological technique	Theme and subtheme
Allam AH et al. JACC: Cardiovascular imaging (2011)	Atherosclerosis in Ancient Egyptian Mummies	Original Article	Not available	CT scan	Specific pathologies-CVD
Beckett RG. Forensic Imaging (2014)	Paleoimaging: a review of applications and challenges	Review	Paleoimaging; bioarchaeology; paleoradiology; endoscopy; mummies	Not available	General review
Beckett RG et al. Forensic Imaging (2020)	A paleoimaging study of human mummies held in the mother church of Gangi, Sicily: Implications for mass casualty methodology	Original Article	Paleoimaging; paleopathology; mass casualty; DVI Sicily	X-Rays	Specific pathologies-skeletal system
Chandrashekhara Y and Narula J. JACC: Cardiovascular Imaging (2011)	Medical Imaging: The New Rosetta Stone	Editorial	Not available	Not available	Specific pathologies-CVD
Clarke EM et al. Journal of Cardiology (2014)	Is atherosclerosis fundamental to human aging? Lessons from ancient mummies	Review	Mummies; atherosclerosis; aging; paleopathology; coronary artery disease	Not available	Specific pathologies-CVD
Cox SL. The Anatomical Records (2015)	Critical Look at Mummy CT Scanning	Review	Mummy; CT scan; paleopathology	CT scan	General review
Cramer L et al. Current Problems in Diagnostic Radiology (2018)	Computed Tomography-Detected Paleopathologies in Ancient Egyptian Mummies	Review	Not available	CT scan	General review
Dalchow CV et al. Eur Arch Otorhinolaryngol (2012)	Imaging of ancient Egyptian mummies' temporal bones with digital volume tomography	Original Article	Temporal bone; computed tomography; radiology; paleoradiology; mummy; digital volume tomography; middle ear	CT scan	Specific pathologies-skeletal system
Friedrich KM et al. European Journal of Radiology (2010)	The story of 12 Chachapoyan mummies through multidetector computed tomography	Original Article	Chachapoyas Peru; mummies; computed tomography; MDCT	CT scan	Specific pathologies-other diseases
Gabrovsky AN et al. International Journal of Cardiology (2016)	Paleopathology of cardiovascular diseases in South American mummies	Original Article	Mummies; South America; atherosclerosis; cardiomegaly; coca leaf	X-Rays	Specific pathologies-CVD
Garvin HM and Stock MK. Academic Forensic Pathology (2016)	The Utility of Advanced Imaging in Forensic Anthropology	Review	Not available	Not available	General review
Giovannetti G et al. Magnetic Resonance Imaging (2016)	Magnetic resonance imaging for the study of mummies	Review	Mummy; paleoradiology; magnetic resonance; imaging; multinuclear spectroscopy	MRI	General review
Giovannetti G et al. Magnetic Resonance Imaging (2022)	Computer tomography and magnetic resonance for multimodal imaging of fossils and mummies	Review	Fossil; mummy; paleoradiology; computer tomography; magnetic resonance; imaging; multinuclear spectroscopy	CT	General review
Habicht ME et al. Yearbook of Physical Anthropology (2016)	Identifications of Ancient Egyptian Royal Mummies from the 18th Dynasty Reconsidered	Review	Pharaoh; ancient; methods; identification; CT-scan; X-ray; aDNA; molecular genetics; mummy; skeleton; Thutmosis I-III; Amenhotep II; Thutmosis IV; Amenhotep III; Akhenaton; Nefertiti; Yuya; Thuya; Tije; Tutankhamun; Ay; DB 320; KV 55; KV 35; KV 62; KV 21	Not available	General review

Study details	Title	Type of study	Key words	Radiological technique	Theme and subtheme
Herrerin J et al. World Neurosurg (2018)	Syrinx in Spinal Cord in Mummified Individual from West Thebes (Egypt)	Original Article	Egypt; mummies; paleopathology; spinal cord; Syringomyelia	X-Rays	Specific pathologies-other diseases
Herrerin J et al. World Neurosurg (2022)	A Possible Stroke Victim from Pharaonic Egypt	Original Article	Not available	X-Rays	Specific pathologies-CVD
Hussein K et al. Virchows Arch (2013)	Paleopathology of the juvenile Pharaoh Tutankhamun—90th anniversary of discovery	Perspective	Paleopathology; Tutankhamun; Akhenaten; ancient Egypt	Not available	Specific pathologies-other diseases
Jackowski C et al. RadioGraphics (2008)	Common and Unexpected Findings in Mummies from Ancient Egypt and South America as Revealed by CT	Original Article	Not available	CT scan	Specific pathologies-skeletal system
Lacout A et al. American Journal of Roentgenology (2016)	Mummified Thyroid Syndrome	Original Article	Cystic-like thyroid nodule; doppler ultrasound; mummy; thyroid cancer; thyroid nodule shrinkage; thyroid nodule; TIRADS	US	Specific pathologies-other diseases
Lacout A et al. American Journal of Roentgenology (2016)	Reverse Mummified Thyroid Syndrome	Letter	Not available	US	Specific pathologies-other diseases
Licata M et al. Semin Ultrasound CT and MRI (2018)	Radiology of Mummies	Review	Not available	Not available	General review
Lynnerup N. Yearbook of Physical Anthropology (2007)	Mummies	Review	Paleopathology; bog bodies; mummified tissue; mortuary practices	Not available	General review
Lynnerup N. Anthropol. Anz (2009)	Methods in mummy research	Review	Bog bodies; mummified tissue; natural sciences in archaeology	Not available	General review
Lynnerup N. Gerontology (2010)	Medical Imaging of Mummies and Bog Bodies – A Mini-Review	Review	Mummy; bog body; paleopathology; CT scan; radiography	Not available	General review
Lynnerup N and Ruhli F. The Anatomical record (2015)	Short Review: The Use of Conventional X-rays in Mummy Studies	Review	X-rays; attenuation; mummies	X-Rays	General review
Marquez S et al. The Anatomical record (2015)	CT Examination of Nose and Paranasal Sinuses of Egyptian Mummies and Three Distinct Human Population Groups: Anthropological and Clinical Implications	Original Article	Nose; paranasal sinuses; frontal sinus; maxillary sinus; nasal complex; Egyptian mummies; CT examination	CT scan	Specific pathologies-skeletal system
Moissidou D et al. BioMed Research International (2015)	Invasive Methods Applied to Mummy Research: Will This Controversy Ever Be Solved?	Review	Not available	Not available	General review
Nystrom KC. International Journal of Paleopathology (2020)	Advances in paleopathology in context: A focus on soft tissue paleopathology	Review	South America; mummies; mummy studies	Not available	General review
O'Brien JJ et al. International Journal of Osteoarchaeology (2009)	CT Imaging of Human Mummies: A Critical Review of the Literature (1979–2005)	Review	Paleoradiology; imaging; human mummies; computerised tomography; critical review	CT scan	General review
O Fritsch K et al. The Anatomical Record (2015)	The Orthopedic Diseases of Ancient Egypt	Original Article	Orthopedic conditions; ancient Egypt mummies; CT scanning	CT scan	Specific pathologies-skeletal system

Study details	Title	Type of study	Key words	Radiological technique	Theme and subtheme
Ohrstrom LM et al. Plos One (2021)	Radiological and histological findings in ancient salt mummies from the salt mine of Douzlākh, Iran	Original Article	Not available	CT scan	Specific pathologies-skeletal system
Panzer S et al. RadioGraphics (2010)	Radiologic Evidence of Anthropogenic Mummification in the Capuchin Catacombs of Palermo, Sicily	Original Article	Not available	X-Rays	Specific pathologies-skeletal system
Panzer S et al. Fortschr Röntgenstr (2017)	Checklist and scoring system for the assessment of soft tissue preservation in CT examinations of human mummies: application to the Tyrolean iceman	Original Article	Mummy, computed tomography, checklist, organ preservation, paleoradiology	CT scan	Guidelines
Panzer S et al. International Journal of Paleopathology (2018)	CT checklist and scoring system for the assessment of soft tissue preservation in human mummies: application to catacomb mummies from Palermo, Sicily	Original Article	Computed tomography; paleoradiology; mummy; soft tissues preservation; checklist	CT scan	Guidelines
Panzer S et al. International Journal of Paleopathology (2019)	How to CT scan human mummies: Theoretical considerations and examples of use	Original Article	Paleoradiology; computed tomography; mummy	CT scan	Guidelines
Panzer S et al. Plos One (2020)	Checklist and scoring system for the assessment of soft tissue preservation in CT examinations of human mummies	Original Article	Not available	CT scan	Guidelines
Panzer S et al. International Journal of Paleopathology (2021)	Correlation of atherosclerosis and osteoarthritis in ancient Egypt: A standardized evaluation of 45 whole-body CT examinations	Original Article	Egyptian mummies; arterial calcifications; cardiovascular disease; degenerative joint disease; paleoradiology; paleopathology	CT scan	Specific pathologies-CVD
Panzer S et al. International Journal of Paleopathology (2022)	Radiological evidence of purulent infections in ancient Egyptian child mummies	Original Article	Multidetector computed tomography; abscess; infectious disease; paleoradiology; paleopathology; ancient Egyptian medicine	CT scan	Specific pathologies-other diseases
Piombino-Mascoli D et al. The Anatomical record (2015)	Paleoradiology of the Savoca Mummies, Sicily, Italy (18th–19th Centuries AD)	Original Article	Mummies; paleoradiology; paleopathology; social status; Italy	X-Rays	Specific pathologies-skeletal system
Ruhli FJ. The Anatomical Records (2015)	Short Review: Magnetic Resonance Imaging of Ancient Mummies	Review	Radiology; computed tomography; mummy; paleopathology; soft tissue	MRI	General review
Saleem SN and Hawass Z. Arthritis & Rheumatology (2014)	Ankylosing Spondylitis or Diffuse Idiopathic Skeletal Hyperostosis in Royal Egyptian Mummies of the 18th–20th Dynasties? Computed Tomography and Archaeology Studies	Brief Report	Not available	CT scan	Specific pathologies-skeletal system

Study details	Title	Type of study	Key words	Radiological technique	Theme and subtheme
Schamall D et al. Wien Med Wochenschr (2012)	Diagnosis of contact injuries in a mediaeval skeleton analysed by μ CT and histology	Original Article	Monteggia fracture; micro-computed tomography; paleopathology; paleoradiology; Bone histology	CT scan	Specific pathologies-skeletal system
Schmidt C et al. Eur Arch Otorhinolaryngol (2013)	Measurement and comparison of labyrinthine structures with the digital volume tomography: ancient Egyptian mummies' versus today's temporal bones	Original Article	Temporal bone; computed tomography; radiology; paleoradiology; mummy; digital volume tomography; semicircular canal; Labyrinth Cochlea Standardized measurement	CT scan	Specific pathologies-skeletal system
Tanti M et al. Plos One (2021)	Automated segmentation of microtomography imaging of Egyptian mummies	Original Article	Not available	CT scan	Guidelines
Thompson RC et al. Lancet (2013)	Atherosclerosis across 4000 years of human history: The Horus study of four ancient populations	Original Article	Not available	CT scan	Specific pathologies-CVD
Thompson RC et al. Global Heart (2014)	Computed Tomographic Evidence of Atherosclerosis in the Mummified Remains of Humans From Around the World	Review	Not available	CT scan	Specific pathologies-CVD
Traversari M et al. BMSAP (2016)	Three cases of developmental dysplasia of the hip on partially mummified human remains (Roccapelago, Modena, 18th Century): a study of paleopathological indicators through direct analysis and 3D virtual models	Note	Paleopathology; DDH; joint pathology; natural mummies; paleoradiology; risk factors	CT scan	Specific pathologies-skeletal system
Ventura L et al. Virchows Archiv (2021)	Giant cell tumor of bone in an eighteenth-century Italian mummy	Original Article	Osteoclastic giant cell-rich tumors; giant cell tumor; non-ossifying fibroma; osteoclastoma; benign fibrous histiocytoma; fibrous cortical defect	CT scan	Specific pathologies-other diseases
Villa C et al. Anthropol. (2015)	The advantage of CT scans and 3D visualizations in the analysis of three child mummies from the Graeco-Roman Period	Original Article	mummies; CT scan; 3D visualization; Graeco-Roman period; hyperdontia.	CT scan	Specific pathologies-skeletal system
Wann S and Thomas GS. Trends in cardiovascular Medicine (2014)	What can ancient mummies teach us about atherosclerosis?	Original Article	Not available	CT scan	Specific pathologies-CVD
Wann S et al. JAMA Network Open (2019)	Atherosclerosis in 16th-Century Greenlandic Inuit Mummies	Letter	Not available	CT scan	Specific pathologies-CVD
Yatsishina EB et al Crystallography Reports (2020)	CT-Scanning Analysis of the Inner Structure of Ancient Egyptian Mummy	Original Article	Not available	CT scan; X-rays	Specific pathologies-skeletal system

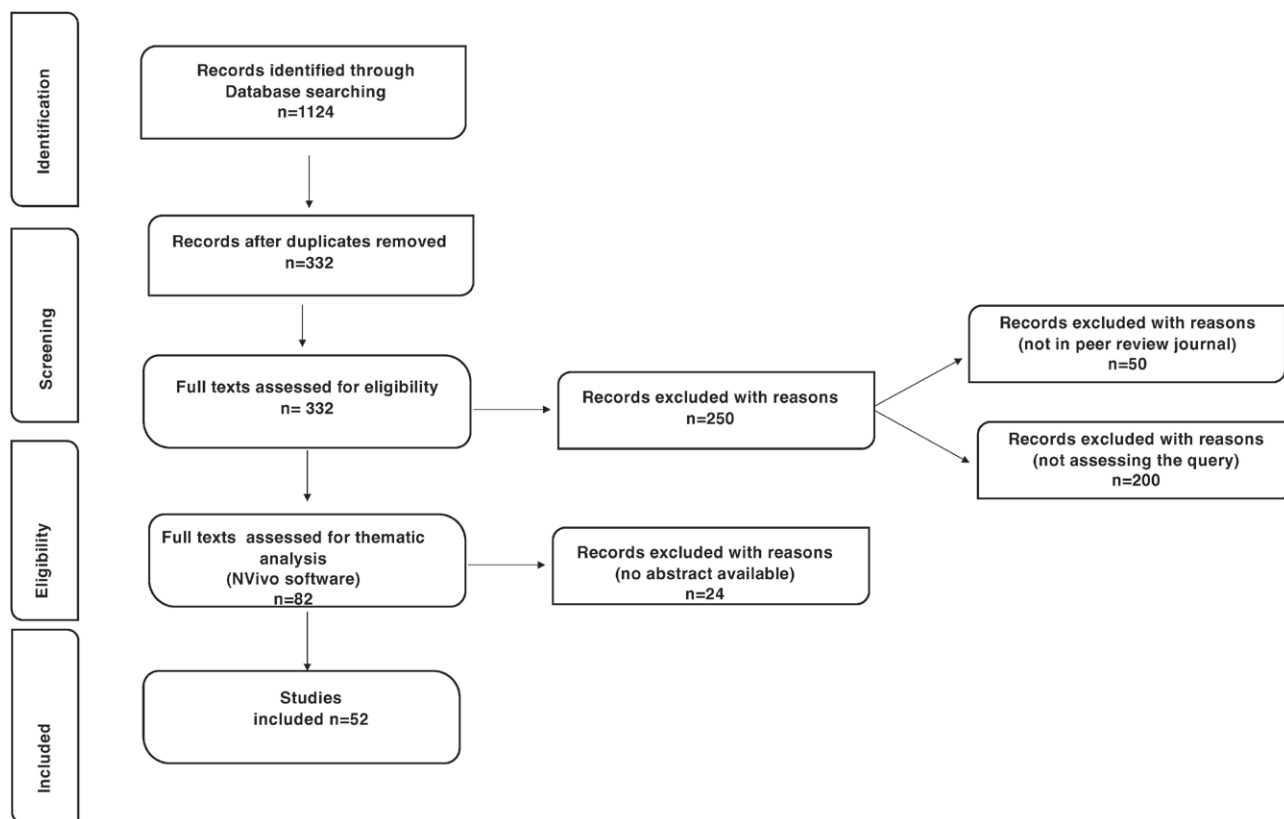


Figure 1.

ing of coca leaves, a habitual cultural practice unique to South American populations might have beneficial effects in decreasing cardiovascular risk among ancient people living in South America. Moreover, Panzer et al. (Panzer et al., 2021), tried to correlate atherosclerosis and osteoarthritis in mummies from ancient Egypt. The authors examined the whole-body CT of 45 mummies and demonstrated for the first time a possible correlation between these diseases with enormous and increasing impacts on public health. The association of atherosclerosis and osteoarthritis was found to be comparable in prevalence to those reported in recent clinical studies, despite the low life expectancy and the different environments and lifestyles of the ancient Egyptians. More recently, studying an ancient female mummy, Herrerin and coworkers (Herrerin et al., 2022) reported the earliest known case of hemiparalysis due to a cerebral stroke, while in previous years the first paleopathological case of stroke was identified by Galassi and colleagues also thanks to CT scan imaging (Galassi et al., 2017, Nerlich et al., 2021). A case of osteoma was reported by Friedrich and coworkers, who assessed the anthropological and paleopathological features of 12 Chachapoyan mummies (Friedrich et al., 2010). More recently, Lacourt and coworkers high-

lighted the sonographic characteristics of thyroid tumors in mummified tissue (Lacourt et al., 2016a, 2016b). Finally, Panzer et al. (Panzer et al., 2022) were the first to describe radiological evidence of purulent infection and skin lesions in ancient Egyptian child mummies.

CONCLUSIONS

According to Monge and coworkers “The *raison d’être* for the scientific study of mummies is to understand the evolution of health and disease in previous or extinct populations of humans” (Monge and Rühli, 2015). From this perspective, paleoradiography represents a valuable and crucial non-invasive method to study a broad range of ancient disease and to review modern-day beliefs.

REFERENCES

- Allam A.H., Thompson R.C., Wann L.S., Miyamoto M.I., Nur el-Din A el-Halim, Maksoud G.A. el- Al-Tohamy Soliman M., Badr I., Amer H.A. el-Rahman,

- Sutherland M.L., Sutherland J.D., Thomas G.S. (2011) Atherosclerosis in Ancient Egyptian Mummies. *JACC: Cardiovascular Imaging* 4:315–327.
- Aromataris E., Riitano D. (2014) Constructing a search strategy and searching for evidence. A guide to the literature search for a systematic review. *Am J Nurs* 114:49–56.
- Aufderheide A.C. (2003) *The Scientific Study of Mummies*. Cambridge, UK ; New York: Cambridge University Press.
- Beckett R.G. (2014) Paleoimaging: a review of applications and challenges. *Forensic Sci Med Pathol* 10:423–436.
- Beckett R.G., Conlogue G.J., Viner M.D., Saleem S.N., Said A.H., Piombino-Mascali D. (2020) A paleoimaging study of human mummies held in the mother church of Gangi, Sicily: Implications for mass casualty methodology. *Forensic Imaging* 23:200416.
- Bianucci R., Sineo L., Micciché R., Mattutino G., Nerlich A.G., Donell S.T., Galassi F.M. (2021a) A paleoimaging study of human mummies held in the Mother Church of Gangi, Sicily: Implications for mass casualty methodology *Forensic Imaging*. 24:200426
- Bianucci R., Sineo L., Micciché R., Mattutino G., Nerlich A.G., Donell S.T., Galassi F.M. (2021b) Correspondence re Piombino-Mascali et al on Mummy Research, Ethics and Editorial Comments, *Forensic Imaging*. 25, 200447.
- Bianucci R., Sineo L., Micciché R., Mattutino G., Nerlich A.G., Donell S.T., Galassi F.M. (2021c) Beckett RG et al. A Paleoimaging study of human mummies held in the mother church of Gangi, Sicily: Implications for mass casualty methodology. *Forensic Imaging*. Volume 24: 200430.
- Chai K.E.K., Lines R.L.J., Gucciardi D.F., Ng L. (2021) Research Screener: a machine learning tool to semi-automate abstract screening for systematic reviews. *Syst Rev* 10:93.
- Chandrashekar Y., Narula J. (2011) Medical Imaging: The New Rosetta Stone. *JACC: Cardiovascular Imaging* 4:440–443.
- Clarke E.M., Thompson R.C., Allam A.H., Wann L.S., Lombardi G.P., Sutherland M.L., Sutherland J.D., Cox S.L., Soliman M.A.-T., Abd el-Maksoud G., Badr I., Miyamoto M.I., Frohlich B., Abdel-Halim Nur el-din, Stewart A.F.R., Narula J., Zink A.R., Finch C.E., Michalik D.E., Thomas G.S. (2014) Is atherosclerosis fundamental to human aging? Lessons from ancient mummies. *J. Cardiol*. 63:329–334.
- Cox S.L. (2015) A Critical Look at Mummy CT Scanning. *Anat Rec* 298:1099–1110.
- Cramer L., Brix A., Matin E., Rühli F., Hussein K. (2018) Computed Tomography–Detected Paleopathologies in Ancient Egyptian Mummies. *Curr Probl Diagn Radiol*. 47:225–232.
- Dalchow C.V., Schmidt C., Harbort J., Knecht R., Grzyska U., Muenscher A. (2012) Imaging of ancient Egyptian mummies’ temporal bones with digital volume tomography. *Eur Arch Otorhinolaryngol*. 269:2277–2284.
- David A.R., Tapp E. (1984) *Evidence Embalmed: Modern Medicine and the Mummies of Ancient Egypt*. Manchester University Press. 198 p.
- Friedrich K.M., Nemeč S., Czerny C., Fischer H., Plischke S., Gahleitner A., Viola T.B., Imhof H., Seidler H., Guillen S. (2010) The story of 12 Chachapoyan mummies through multidetector computed tomography. *Eur J Radiol*. 76:143–150.
- Fritsch K.O., Hamoud H., Allam A.H., Grossmann A., Nur El-Din A-H., Abdel-Maksoud G., Al-Tohamy Soliman M., Badr I., Sutherland J.D., Linda Sutherland M., Akl M., Finch C.E., Thomas G.S., Wann L. S., Thompson R.C. (2015) The Orthopedic Diseases of Ancient Egypt: orthopedic diseases of ancient Egypt. *Anat Rec*. 298:1036–1046.
- Gabrovsky A.N., O’Neill K.D., Gerszten E. (2016) Paleopathology of cardiovascular diseases in South American mummies. *I J Cardiol*. 223:101–107.
- Galassi F.M., Habicht M.E., Rühli F.J., De Carolis S. (2017) A Unique Case of Stroke and Upper Limb Paralysis in a Mid-18th Century Natural Mummy. *Circ Res*. 121(4):338–340.
- Garvin H.M., Stock M.K. (2016) The Utility of Advanced Imaging in Forensic Anthropology. *Acad Forensic Pathol*. 6:499–516.
- Giovanetti G., Guerrini A., Carnieri E., Salvadori P.A. (2016) Magnetic resonance imaging for the study of mummies. *Magnetic Resonance Imaging* 34:785–794.
- Giovanetti G., Guerrini A., Minozzi S., Panetta D., Salvadori P.A. (2022) Computer tomography and magnetic resonance for multimodal imaging of fossils and mummies. *Magn Reson Imaging* 94:7–17.
- Habicht M.E., Bouwman A.S., Rühli F.J. (2016) Identifications of ancient Egyptian royal mummies from the 18th Dynasty reconsidered: Identifications of Ancient Egyptian Royal Mummies. *Am J Phys Anthropol*. 159:216–231.
- Habicht M.E., Henneberg M., Öhrström L.M., Staub K., Rühli F.J. (2015). Body height of mummified pharaohs supports historical suggestions of sibling marriages. *Am J Phys Anthropol*. 157:519–525.
- Harwood-Nash D.C. (1979) Computed tomography of ancient Egyptian mummies. *J Comput Assist Tomogr* 3:768–773.

- Herrerin J., Prats A., Ledesma L., Isidro A. (2018) Syring in Spinal Cord in Mummified Individual from West Thebes (Egypt). *World Neurosurg.* 118:230–234.
- Herrerin J., Sánchez M.A., Ikram S. (2022) A Possible Stroke Victim from Pharaonic Egypt. *World Neurosurg.* 165:e664–e667.
- Holm S. (2001) The Privacy of Tutankhamen – Utilising The Genetic Information In Stored Tissue Samples. *Theor Med Bioeth.* 22:437–449.
- Hussein K., Matin E., Nerlich A.G. (2013) Paleopathology of the juvenile Pharaoh Tutankhamun—90th anniversary of discovery. *Virchows Arch.* 463:475–479.
- Jackowski C., Bolliger S., Thali M.J. (2008) Common and Unexpected Findings in Mummies from Ancient Egypt and South America as Revealed by CT. *RadioGraphics* 28:1477–1492.
- Kaufmann I.M., Rühli F.J. (2010) Without “informed consent”? Ethics and ancient mummy research. *J Med Ethics.* 36:608–613.
- Kreissl Lonfat B.M., Kaufmann I.M., Rühli F. (2015) A Code of Ethics for Evidence-Based Research With Ancient Human Remains. *Anat Rec* 298:1175–1181.
- Lacout A., Chevenet C., Marcy P-Y. (2016a) Reverse Mummified Thyroid Syndrome. *AJR Am J Roentgenol* 207:W23–W23.
- Lacout A., Chevenet C., Marcy P-Y. (2016b) Mummified Thyroid Syndrome. *AJR Am J Roentgenol* 206:837–845.
- Lewin P.K., Harwood-Nash D.C. (1977) Computerized axial tomography in medical archeology. *Paleopathol Newsl* 8–9.
- Licata M., Tosi A., Larentis O., Rossetti C., Lorio S., Pinto A. (2019) Radiology of Mummies. *Semin Ultrasound CT MR.* 40:5–11.
- Lynnerup N. (2007) Mummies. *Am J Phys Anthropol.* 134:162–190.
- Lynnerup N. (2009) Methods in mummy research. *Anthraz.* 67:357–384.
- Lynnerup N. (2010) Medical Imaging of Mummies and Bog Bodies – A Mini-Review. *Gerontology* 56:441–448.
- Lynnerup N., Rühli F. (2015) Short Review: The Use of Conventional X-rays in Mummy Studies: CONVENTIONAL X-RAYS IN MUMMY STUDIES. *Anat Rec.* 298:1085–1087.
- Nerlich A.G., Galassi F.M., Bianucci R. (2021). The Burden of Arteriosclerotic Cardio-vascular Disease in Ancient Populations. In: Shin D., Bianucci R. (Eds). *The Handbook of Mummy Studies*. Singapore, Springer Nature, pp. 147–162.
- Márquez S., Lawson W., Mowbray K., Delman B.N., Laitman J.T. (2015) CT Examination of Nose and Paranasal Sinuses of Egyptian Mummies and Three Distinct Human Population Groups: Anthropological and Clinical Implications. *Anat Rec.* 298:1072–1084.
- Moher D., Shamseer L., Clarke M., Ghersi D., Liberati A., Petticrew M., Shekelle P., Stewart L.A., PRISMA-P Group. (2015) Preferred reporting items for systematic review and meta-analysis protocols (PRISMA-P) 2015 statement. *Syst Rev.* 4:1.
- Moissidou D., Day J., Shin D.H., Bianucci R. (2015) Invasive versus Non-Invasive Methods Applied to Mummy Research: Will This Controversy Ever Be Solved?. *Biomed Res Int.* 1–7.
- Monge J.M., Rühli F. (2015) The Anatomy of the Mummy: Mortui Viventes Docent- When Ancient Mummies Speak to Modern Doctors. *Anat Rec.* 298:935–940.
- Nystrom K.C. (2018) *The Bioarchaeology of Mummies*. New York: Routledge.
- Nystrom K.C. (2020) Advances in paleopathology in context: A focus on soft tissue paleopathology. *Int J of Paleopath* 29:16–23.
- Nystrom K.C., Tilley L. (2019) Mummy studies and the bioarchaeology of care. *Int J Paleopathol.* 25:64–71.
- O’Brien J.J., Battista J.J., Romagnoli C., Chhem R.K. (2009) CT imaging of human mummies: a critical review of the literature (1979–2005). *Int J Osteoarchaeol.* 19:90–98.
- Öhrström L.M., Marquez H., Seiler R., Bode B., Aali A., Stöllner T., Rühli F.J. (2021) Radiological and histological findings in ancient salt mummies from the salt mine of Douzlākh, Iran. *PLoS ONE* 16:e0250745.
- Panzer S., Augat P., Sprenger M., Zesch S., Rosendahl W., Sutherland M.L., Thompson R.C., Paladin A., Zink A.R. (2021) Correlation of atherosclerosis and osteoarthritis in ancient Egypt: A standardized evaluation of 45 whole-body CT examinations. *Int J Paleopathol.* 33:137–145.
- Panzer S., Augat P., Zink A.R., Piombino-Mascalì D. (2018) CT checklist and scoring system for the assessment of soft tissue preservation in human mummies: application to catacomb mummies from Palermo, Sicily. *Int J Paleopathol.* 20:50–59.
- Panzer S., Ketterl S., Bicker R., Schoske S., Nerlich A.G. (2019) How to CT scan human mummies: Theoretical considerations and examples of use. *Int J Paleopathol.* 26:122–134.
- Panzer S., Mc Coy M.R., Hitzl W., Piombino-Mascalì D., Jankauskas R., Zink A.R., Augat P. (2015) Checklist and Scoring System for the Assessment of Soft Tissue Preservation in CT Examinations of Human Mummies. *PLoS ONE* 10:e0133364.
- Panzer S., Pernter P., Piombino-Mascalì D., Jankauskas R., Zesch S., Rosendahl W., Hotz G., Zink A.R. (2017)

- Checklist and Scoring System for the Assessment of Soft Tissue Preservation in CT Examinations of Human Mummies: Application to the Tyrolean Ice-man. *Fortschr Röntgenstr* 189:1152–1160.
- Panzer S., Treitl M., Zesch S., Rosendahl W., Helmbold-Doyé J., Thompson R.C., Zink A.R. (2022) Radiological evidence of purulent infections in ancient Egyptian child mummies. *Int J Paleopathol.* 36:30–35.
- Panzer S., Zink A.R., Piombino-Mascali D. (2010) Scenes from the Past: Radiologic Evidence of Anthropogenic Mummification in the Capuchin Catacombs of Palermo, Sicily. *RadioGraphics* 30:1123–1132.
- Papa V., Vaccarezza M. (2013) Teaching anatomy in the XXI century: New aspects and pitfalls. *The Scientific World Journal*.
- Papa V., Varotto E., Galli M., Vaccarezza M., Galassi F.M. (2022) One year of anatomy teaching and learning in the outbreak: Has the Covid-19 pandemic marked the end of a century-old practice? A systematic review. *Anat Sci Educ.* 15:261–280.
- Piombino-Mascali D., Jankauskas R., Zink A.R., Sergio Todesco M., Aufderheide A.C., Panzer S. (2015) Paleoradiology of the Savoca Mummies, Sicily, Italy (18th-19th Centuries AD). *Anat Rec.* 298:988–1000.
- Rühli F.J. (2015) Short Review: Magnetic Resonance Imaging of Ancient Mummies: MRI of Ancient Mummies. *Anat Rec.* 298:1111–1115.
- Saleem S.N., Hawass Z. (2014) Brief Report: Ankylosing Spondylitis or Diffuse Idiopathic Skeletal Hyperostosis in Royal Egyptian Mummies of the 18th-20th Dynasties? Computed Tomography and Archaeology Studies: AS or Dish in Royals of Ancient Egypt. *Arthritis Rheumatol* 66:3311–3316.
- Schamall D., Pietschmann P., Moser D., Dockner M., Teschler-Nicola M. (2012). Diagnosis of contact injuries in a mediaeval skeleton analysed by μ CT and histology. *Wien Med Wochenschr.* 162:386–393.
- Schmidt C., Harbort J., Knecht R., Grzyska U., Muen-scher A., Dalchow C.V. (2013) Measurement and comparison of labyrinthine structures with the digital volume tomography: ancient Egyptian mummies' versus today's temporal bones. *Eur Arch Otorhinolaryngol.* 270:831–840.
- Shin D.H., Bianucci R. (2021) *The Handbook of Mummy Studies*. Singapore; Springer.
- Tanti M., Berruyer C., Tafforeau P., Muscat A., Farrugia R., Scerri K., Valentino G., Solé V.A., Briffa J.A. (2021) Automated segmentation of microtomography imaging of Egyptian mummies. *PLoS ONE* 16:e0260707.
- Thompson R.C., Allam A.H., Lombardi G.P., Wann L.S., Sutherland M.L., Sutherland J.D., Soliman MA-T., Frohlich B., Mininberg D.T., Monge J.M., Vallodolid C.M., Cox S.L., Abd el-Maksoud G., Badr I., Miyamoto M.I., el-Halim Nur el-din A., Narula J, Finch C.E., Thomas G.S. (2013) Atherosclerosis across 4000 years of human history: the Horus study of four ancient populations. *The Lancet* 381:1211–1222.
- Thompson RC, Allam AH, Zink A, Wann LS, Lombardi GP, Cox SL, Frohlich B, Sutherland ML, Sutherland JD, Frohlich TC, King SI, Miyamoto MI, Mongeyy J.M., Valladolid C.M., Abd el-Halim Nur el-din, Narula J., Thompson A.M., Finch C.E., Thomas G.S. (2014). Computed Tomographic Evidence of Atherosclerosis in the Mummified Remains of Humans From Around the World. *gHERITAGE.* 9:187.
- Traversari M., Feletti F., Vazzana A., Gruppioni G., Frelat M.A. (2016) Three cases of developmental dysplasia of the hip on partially mummified human remains (Roccapelago, Modena, 18th Century): a study of paleopathological indicators through direct analysis and 3D virtual models. *BMSAP* 28:202–212.
- Tricco AC, Lillie E, Zarin W, O'Brien KK, Colquhoun H, Levac D, Moher D, Peters MDJ, Horsley T, Weeks L, Hempel S, Akl EA, Chang C., McGowan J., Stewart L., Hartling L., Aldcroft A., Wilson M.G., Garritty C., Lewin S., Godfrey C.M., Macdonald M.T., Langlois E.V., Soares-Weiser K., Moriarty J., Clifford T., Tuncalp O., Straus S.E. (2018) PRISMA Extension for Scoping Reviews (PRISMA-ScR): Checklist and Explanation. *Ann Intern Med.* 169:467–473.
- Vaccarezza M., Papa V., Milani D., Gonelli A., Secchiero P., Zauli G., Gemmati D., Tisato V. (2020) Sex/gender-specific imbalance in CVD: Could physical activity help to improve clinical outcome targeting CVD molecular mechanisms in women? *Int J Mol Sci.* 21:1–16.
- Ventura L., Petrella E., Piciucchi S., Cilli E., Luiselli D., Feeney R.N.M., Traversari M. (2021) Giant cell tumor of bone in an eighteenth-century Italian mummy. *Virchows Arch.* 479:1255–1261.
- Villa C., Davey J., Craig P.J.G., Drummer O.H., Lynnerup N. (2015). The advantage of CT scans and 3D visualizations in the analysis of three child mummies from the Graeco-Roman Period. *Anthranz.* 72:55–65.
- Wann L.S., Lombardi G., Ojeda B., Benfer R.A., Rivera R., Finch C.E., Thomas G.S., Thompson R.C. (2015) The Tres Ventanas Mummies of Peru: Tres Ventanas Mummies of Peru. *Anat Rec.* 298:1026–1035.
- Wann S, Thomas GS. 2014. What can ancient mummies teach us about atherosclerosis? *Trends Cardiovasc Med* 24:279–284.
- Yatsishina E.B., Vasilyev S.V., Vasilieva O.A., Galeev R.M., Dyuzheva O.P., Kovalchuk M.V. (2020) CT-Scanning Analysis of the Inner Structure of Ancient Egyptian Mummy. *Crystallogr Rep.* 65:1064–1072.