Heart, Lung and Circulation (2024) **33**, 915–931
1443-9506/24/$36.00
https://doi.org/10.1016/j.hlc.2023.11.030

CONSENSUS STATEMENT

Global Consensus Recommendations on Improving the Safety of Chronic Total Occlusion Interventions

Eugene B. Wu, MD [a,1,*], Arun Kalyanasundaram, MD [b,1], Emmanouil S. Brilakis, MD, PhD [c], Kambis Mashayekhi, MD [d], Etsuo Tsuchikane, MD, PhD [e], and the CTO Global Consensus Group[2]

[a]Prince of Wales Hospital, Chinese University Hong Kong, Hong Kong
[b]Promed Hospital, Chennai, India
[c]Minneapolis Heart Institute and Minneapolis Heart Institute Foundation, Minneapolis, MN, USA
[d]Department of Cardiology and Angiology, II University Heart Center, Freiburg Bad Krozingen, Germany
[e]Toyohashi Heart Center, Aichi, Japan

Received 5 January 2023; received in revised form 18 September 2023; accepted 6 November 2023; online published-ahead-of-print 4 June 2024

Safety is of critical importance to chronic total occlusion (CTO) percutaneous coronary intervention (PCI). This global consensus statement provides guidance on how to optimise the safety of CTO) PCI, addressing the following 12 areas: 1. Set-up for safe CTO PCI; 2. Guide catheter-–associated vessel injuries; 3. Hydraulic dissection, extraplaque haematoma expansion, and aortic dissections; 4. Haemodynamic collapse during CTO PCI; 5. Side branch occlusion; 6. Perforations; 7. Equipment entrapment; 8. Vascular access considerations; 9. Contrast-induced acute kidney injury; 10. Radiation injury; 11 When to stop; and, 12. Proctorship. This statement complements the global CTO crossing algorithm; by advising how to prevent and deal with complications, this statement aims to facilitate clinical practice, research, and education relating to CTO PCI.

Keywords Chronic total occlusion • Percutaneous coronary intervention • Consensus document • Global • Safety

Introduction

Chronic total occlusion (CTO) percutaneous coronary intervention (PCI) carries an increased risk of complications compared with non-CTO PCI [1–7]. Complications of CTO PCI can be classified into cardiac (coronary and non-coronary) and non-cardiac (Figure 1). Although a strict delineation between complications in CTO PCI vs non–CTO PCI is artificial, there is an increasing risk of complications from "bread and butter" PCI to complex high-risk indicated percutaneous coronary intervention (CHIPS) PCI to CTO PCI, making this paper relevant to all PCI. Although the indications for CTO PCI is beyond the scope of this paper, a balance—between how "indicated" a CTO PCI is, and the "risks" of complications for a CTO PCI—must be made, soberly and thoughtfully. Through global collaboration, consensus was recently reached on the definitions and terminology [8], guiding principles [9], and crossing algorithm for CTO PCI [10]. In the present manuscript, 147 co-authors from 139 centres in 52 countries developed 12 sets of recommendations for the prevention, early recognition, and treatment of CTO PCI complications.

*Corresponding author at: Dr Eugene Brian WU, 9/F, Division of Cardiology, Department of Medicine & Therapeutics, Clinical Sciences Building, Prince of Wales Hospital, Shatin, N.T., Hong Kong; Email: cto.demon@gmail.com; 𝕏 @ctodemon

[1]Equal First authors.

[2]CTO Global Consensus Group Contributors listed at end of article.

© 2024 The Author(s). Published by Elsevier B.V. on behalf of Australian and New Zealand Society of Cardiac and Thoracic Surgeons (ANZSCTS) and the Cardiac Society of Australia and New Zealand (CSANZ). This is an open access article under the CC BY-NC-ND license (http://creativecommons.org/licenses/by-nc-nd/4.0/).

1. Set-Up for Safe CTO PCI

Cardiac catheterisation laboratories performing CTO PCI should have immediate access to echocardiography, covered stents, coils (ideally compatible with 0.014-inch microcatheters), an Activated Clotting Time (ACT) measurement device, and a pericardiocentesis kit. A trained team of operators, assistants, nurses, technicians, and radiographers with familiarity with CTO equipment, radiation dose minimisation, pericardiocentesis, and cardiopulmonary resuscitation is recommended. Mechanical circulatory support devices such as an intra-aortic balloon pump (IABP), Impella (Abiomed, Danvers, MA, USA) [11], and extracorporeal membrane oxygenation (ECMO) may be useful in selected patients. Modern X-ray machines provide lower radiation dose and should be preferentially used for CTO PCI, if available.

2. Guide Catheter–Associated Vessel Injury

A. Air and Thrombus Embolism

Although air and thrombus embolism can occur during any PCI, the risk is higher with CTO PCI due to routine use of the trapping technique, simultaneous use of multiple devices through the guide catheter, use of guide extension, and long procedure duration. Air embolism in the donor vessel during CTO PCI can be catastrophic, as it can lead to profound ischaemia and haemodynamic collapse. Dampening of the guide catheter pressure tracing may indicate presence of thrombus or air. Air embolism can be prevented by back bleeding and aspirating the guide catheter after every trapping manoeuvre. Prolonged blood stasis inside a guide catheter can lead to thrombus formation, despite adequate anticoagulation. The activated clotting time (ACT) should be checked 5–10 minutes after heparin administration, and then every 30 min, and maintained >300 seconds during antegrade and >350 seconds for retrograde CTO PCI [12]. Moreover, the guide catheters, especially the retrograde guide catheter, should be aspirated and flushed periodically throughout the case, especially if no injection is performed for prolonged periods of time. The retrograde guide catheter should be removed as soon as it is no longer needed.

Thrombosis of the donor vessel can be due to embolisation of catheter thrombus or thrombosis of the vessel itself. Retrograde CTO PCI is more prone to donor vessel thrombosis given the often- prolonged periods of microcatheter or anchoring balloon dwelling in the vessel. Periodic ACT monitoring and having a low threshold to treat donor vessel lesions before retrograde attempts may reduce the risk of donor vessel thrombosis [13].

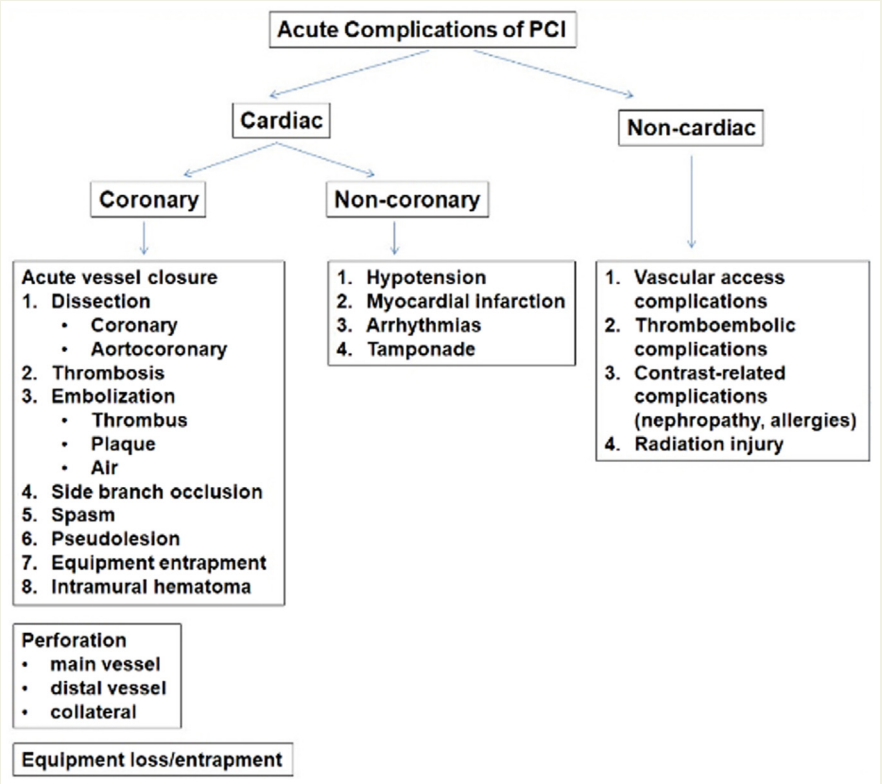

Figure 1 Classification of CTO PCI complications into cardiac (coronary and non-coronary) and non-cardiac.

B. Guide-Induced Dissection

CTO PCI is particularly prone to guide-induced dissections as: i) aggressive guide catheters are often used to maximise support; ii) after CTO crossing, the loss of backward force may lead to deep engagement of the antegrade guide catheter increasing the risk of guide-induced dissection; and, iii) in retrograde CTO PCI, the donor guide catheter can be "sucked in" when the retrograde microcatheter or guidewire is pulled back, potentially leading to donor vessel injury. The donor guide catheter should be pulled back into the ascending aorta after wire externalisation, especially when backing out retrograde devices [13].

Prevention

Avoid oversized guide catheter and aggressive guide catheter manipulations. Pressure dampening can be avoided by slight withdrawal of the guide catheter, by placing a coronary wire in the aortic cusp that prevents deep guide catheter intubation, and in some cases by prophylactic stenting of diseased vessel ostia. Side hole catheters can reduce injection pressure and barotrauma while allowing some perfusion through the side holes, but it increases contrast use and caution must be taken against "false reassurance" of lack of pressure dampening. Inserting a coronary wire as soon as the guide catheter is engaged, before injections, can protect from coronary dissection but may also cause dissection with aggressive wire advancement. Gentle contrast injection, and the avoidance of automated injectors are recommended.

C. Donor Vessel Injury and Treatment

The donor vessel that provides collaterals to the CTO is, in most cases, engaged with a second guide catheter. The donor vessel can be injured during angiography or when instrumented during the retrograde approach. Donor vessel injury can be catastrophic since the donor artery supplies both its own territory and collateralises the CTO. The "ping-pong" (dual-guide catheter) technique [14] is recommended when using an ipsilateral collateral for retrograde CTO PCI. Single-guide catheter approach for ipsilateral retrograde increases the risks of guide-induced dissection during retrograde retrieval, may lead to cardiac strangulation by tension on the retrograde system, and hypotension, and carries risk of equipment entrapment.

In case of donor vessel injury, the haemodynamic status of the patient might quickly deteriorate, often necessitating inotropes, vasopressors, and mechanical circulatory support. Prompt treatment of the donor vessel should, hence, be the highest priority. Prophylactic insertion of a "safety" wire in the donor vessel prior to PCI can greatly facilitate treatment. In case of donor vessel dissection, the retrograde equipment should be removed (if possible) before stenting the donor vessel. CTO treatment attempts should, in most cases, stop unless the procedure is expected to be completed in a short period of time. With donor vessel thrombosis, aspiration thrombectomy and administration of a glycoprotein IIb/IIIa inhibitor might be needed. The ACTs should be monitored to ensure that adequate anticoagulation is achieved.

3. Hydraulic Dissection, Extraplaque Haematoma Expansion, and Aortic Dissection

A. Mechanism

Hydraulic dissection, extraplaque haematoma, and aortic dissection, represent a family of complications of CTO PCI sharing the following common mechanisms:

i). Creation of a connection between the true lumen and the extraplaque (formerly called "subintimal") space—this can be caused by guide-induced dissection (see section 2, ***Guide Catheter–Associated Vessel Injury***, above) [15], by aggressive wiring when the wire has entered the extraplaque space, or by ballooning during the reverse Controlled Antegrade Retrograde Tracking (CART) (Figure 2A).

ii). Hydraulic barotrauma. Pressure from contrast injection or systolic pressure can cause flow from the true lumen into the extraplaque space that can expand the extraplaque haematoma (Figure 2C). Wire advancement may also expand the extraplaque haematoma (Figure 2D).

iii). Exposure of the extraplaque space to arterial pressure, and constant inflow of blood may lead to distal true lumen collapse, aortic root haematoma, aortic dissection [16] and tamponade (Figure 2B).

B. Hydraulic Dissection

Guide-induced dissections are only noticed after contrast injection leading to distal or aortic root haematomas (Figure 2B). When a wire advances from the proximal true lumen into the extraplaque space, a potential pathway for hydraulic dissection is created. Inadvertent or deliberate (balloon-assisted microdissection, BAM) balloon rupture [17] can also lead to hydraulic dissections. Inflation of a balloon when performing reverse CART can also create a connection intraplaque and extraplaque space, possibly leading to hydraulic dissection.

Prevention

The risk of hydraulic dissection may be reduced by gentle injections and avoiding injection when the pressure waveform is dampened. Contrast injections should stop if a hydraulic dissection occurs, to minimise the risk of enlarging the dissection and intravascular ultrasound (IVUS) should be used for guiding PCI. Disconnecting the contrast syringe from the antegrade manifold can help prevent inadvertent contrast injection after proximal cap penetration.

C. Haematoma Expansion

Haematoma expansion is often the result of hydraulic dissection but may also be caused by wire manipulation (Figure 2D). Immediate cessation of contrast injection and inflow control are essential to prevent haematoma expansion. If the entrance site of the dissection can be identified,

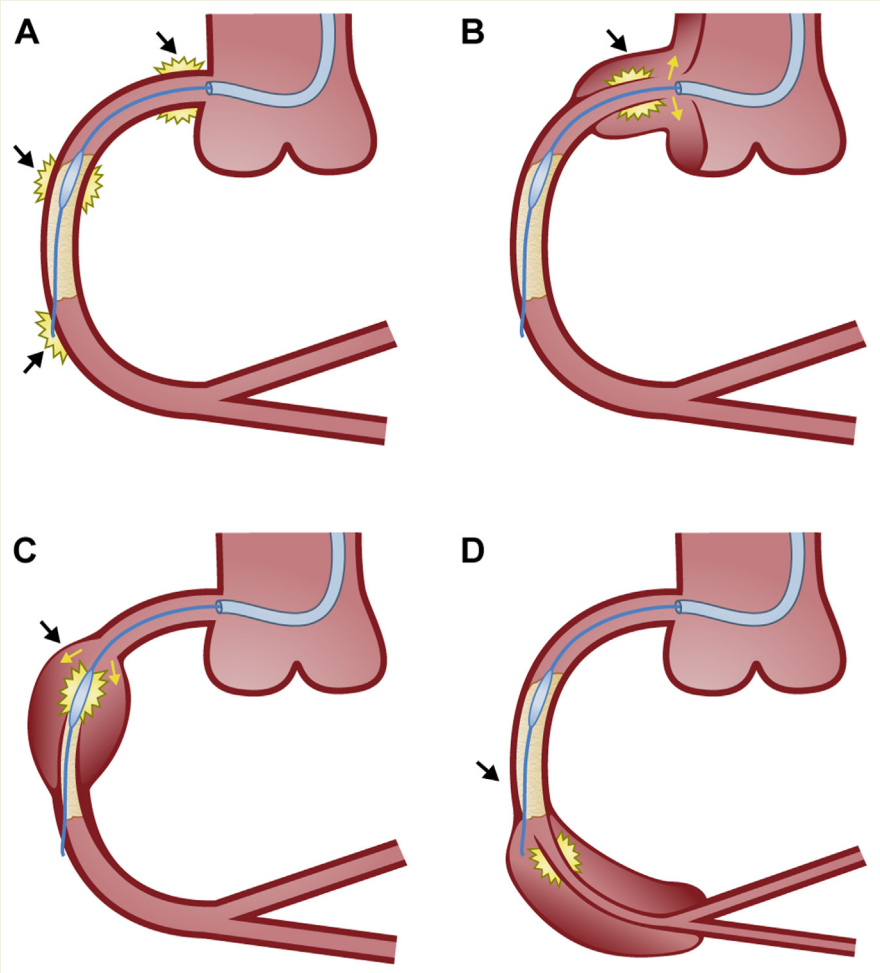

Figure 2 Mechanism of hydraulic dissection, haematoma expansion, and aortic dissection. (A) Mechanism of creation of a connection between the true lumen and the extraplaque space: guide-induced dissection (arrow); ballooning during reverse CART (arrow); CTO wiring in the extraplaque space (arrow). (B) Hydraulic dissection via guide-induced dissection causing haematoma expansion into aortic cusp (yellow arrow) and ascending aortic dissection (yellow arrow). (C) Haematoma expansion around entry site from reverse CART or CTO proximal cap ballooning. (D) Extensive hydraulic dissection and haematoma expansion into distal RCA (yellow arrow) leading to distal vessel narrowing.
Abbreviations: CART, controlled antegrade retrograde tracking; CTO, chronic total occlusion; RCA, right coronary artery.

stenting over it can prevent haematoma expansion. Alternatively, an adequately-sized balloon can be inflated to occlude flow to the vessel, or a guide extension catheter can be advanced into the proximal cap of the CTO to limit blood inflow and prevent haematoma expansion.

Haematoma expansion can cause distal true lumen collapse. IVUS can provide important information about the size and extent of the haematoma. The Subintimal Transcatheter Withdrawal (STRAW) technique can help reduce the size of haematoma via aspiration through a microcatheter [18] or through the Stingray balloon. This is done by delivering the microcatheter tip to the extraplaque space and applying suction with an indeflator or syringe. Treatment options for distal true lumen collapse due to haematoma after successful CTO crossing include: cutting balloon to release the hematoma [19]; low pressure balloon inflation at the distal vessel; or, long stents to cover beyond the distal edge of the haematoma and expand the vessel.

Extraplaque haematomas can also track backwards towards the ostium and into the aortic root leading to an aortocoronary haematoma that can expand towards the ascending aorta, causing a type A aortic dissection (Figure 2B) [20], or towards the pericardium, potentially leading to acute aortic regurgitation and tamponade [21]. Treatment is with stenting, with the stent protruding 1–2 mm into the aorta [22]. A large enough stent should be used to prevent further blood entry into the aortic root. IVUS is often helpful for stent size selection. If there is persistent contrast inflow after stenting, a covered stent can be used. Serial non-invasive imaging (with computed tomography or

transoesophageal echocardiography) could confirm that the dissection is not progressing and should be considered. Emergency surgery is rarely needed [23].

4. Haemodynamic Collapse During CTO PCI

Haemodynamic collapse during CTO PCI may occur for several reasons [13], as outlined below.

A. Access Site Bleeding /Retroperitoneal Haematoma

Femoral access should be obtained using ultrasound- and fluoroscopy-guided techniques. Vascular access complications can cause hypotension during or after CTO PCI. Use of ultrasound can decrease the risk of vascular access complications, primarily driven by a reduction in local haematomas, especially in complex CTO PCI [24]. A high arterial puncture location increases the risk of retroperitoneal bleed [25]. Non–access site-related bleeding complications have a similar prevalence to access site complications, but are associated with a significantly worse prognosis, partly related to the severity of the bleed [25].

B. Aortic Insufficiency

Patients can have a fall in systolic pressure, tachycardia, and a low pulse pressure due to acute aortic insufficiency that is often induced by an Amplatz left (AL-1) guide catheter [26], but can also occur with extra-back up (XB/EBU) type guide catheters. Correcting the guide catheter position (withdrawing it, until it is not pushing against the valve) promptly resolves aortic insufficiency and normalises the blood pressure.

C. Ischaemia

Ischaemia during CTO PCI can lead to hypotension, especially during retrograde CTO PCI. Occlusion of a large dominant collateral might create severe ischaemia in target vessel territory. In patients with low ejection fraction, preferential use of the antegrade approach is recommended as the retrograde approach carries increased risk of haemodynamic compromise. Ventricular support device use, limiting contrast volume and limiting ischaemic time are important in this patient cohort.

D. Donor Vessel Lesions

Donor vessel lesions, even if moderate, can lead to ischaemia and haemodynamic compromise, if crossed during retrograde CTO PCI. Diseased donor vessels should be treated prior to proceeding with retrograde CTO PCI.

E. Donor Vessel Ischaemia

Donor vessel spasm and the accordioning effect could also lead to compromised flow. Intracoronary administration of vasodilators, such as nitroglycerin, often helps resolve the spasm. Meticulous care is needed when utilising the left internal mammary artery for retrograde access; use of highly tortuous internal mammary artery grafts should be avoided.

F. Perforations

Perforations might also lead to tamponade and hypotension.

G. Anaphylaxis

Allergic reaction to contrast or other substances can cause hypotension and should be considered in the differential diagnosis.

5. Side Branch Occlusion

A. Mechanism

Occlusion of side branches that originate within the CTO body is usually inconsequential as they usually fill by collaterals. In contrast, occlusion of a side branch at the distal or proximal cap can lead to periprocedural myocardial infarction (MI) (Figure 3).

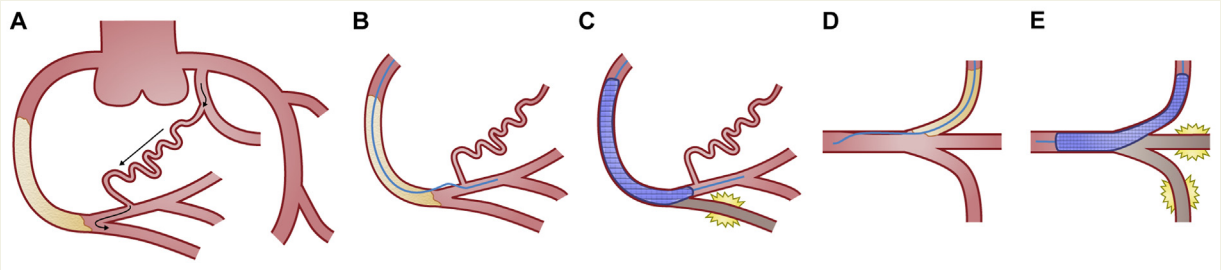

Figure 3 Side branch short cut. (A) The blood supply to the posterior descending artery (PDA) is from the atrioventricular branch (AV) (black arrows). (B) CTO wire is advanced through the extraplaque space in the posterolateral vessel (PLV) distal to the PDA origin. (C) After stenting the PDA ostium is occluded. (D) Ostial LAD CTO with retrograde wire travelling extraplaque in the left main and entering the aorta at the left main ostium. (E) Stenting causes occlusion of the ramus intermedius and the circumflex.
Abbreviations: CTO, chronic total occlusions; LAD, left anterior descending.

Side branches can be occluded by dissection, plaque shift, or subintimal shift, when the wire has gone subintimal beyond the bifurcation at the proximal or distal cap [27]. For example, in a RCA CTO with the distal cap at the posterior left ventricular (PLV) posterior descending artery (PDA) bifurcation, the blood supply to the PDA can be from the circumflex atrioventricular (AV) groove that perfuses the PLV and then, via the bifurcation, the PDA (Figure 3A). If an antegrade CTO wire enters the true lumen in the PLV and not at the bifurcation, the PDA may occlude after stenting into the PLV (Figure 3B). The PDA will lose the original collateral supply from the AV groove resulting in peri-procedural MI (Figure 3C). In a similar manner, in an ostial left anterior descending (LAD) CTO, if one attempts retrograde wire crossing, there is a risk of the retrograde wire travelling extraplaque into the left main and entering the aorta at the left main ostium (Figure 3D and E). Stenting over this wire may lead to circumflex occlusion and MI. This same principle can be applied to any significant size side branch near either cap of the CTO.

B. Prevention

Recanalising a side branch that occluded after stenting can be very challenging, therefore prevention is critical.

Bifurcation at the proximal cap

Major side branches at the proximal cap should be wired prior to CTO crossing attempts. Sometimes placement of an IVUS in a proximal side branch can facilitate antegrade crossing. In cases of retrograde crossing, the extended reverse CART technique (i.e., re-entry proximal to the proximal cap) should be avoided [28]. Instead, antegrade wiring into the CTO body beyond the proximal side branch should be done first, to allow reverse CART within the occluded segment. Using guide extension reverse CART beyond the proximal side branch can minimise the risk of side branch occlusion.

Bifurcation at the distal cap

The global CTO crossing algorithm [10] recommends the use of retrograde approach, if there is a bifurcation at the distal cap. It also recommends use of IVUS before stenting CTOs with bifurcation at the distal cap. Major side branches should be wired (often using a dual lumen microcatheter) before stenting, to reduce the risk of occlusion.

C. Treatment

If despite preventive measures, the side branch becomes occluded, a dual lumen microcatheter is usually used for rewiring (the sidecar technique can be an alternative, if dual lumen not available). IVUS can help identify the origin of the occluded side branch: plaque shifts that cause occlusion can often be stented and wired with a low penetration force wire, followed by kissing balloon inflation, while an extraplaque subintimal shift usually requires a high penetration force wire and a two-stent strategy [29]. If this fails, retrograde crossing or antegrade dissection and re-entry [30] can be used, followed by 2-stent bifurcation PCI. As a last resort, the subintimal tracking and re-entry (STAR) technique [31], with ballooning into the side branch (investment procedure) [10] can restore flow into the side branch, minimise the risk of periprocedural MI, and facilitate a staged procedure.

6. Perforation

CTO PCI carries increased risk of perforation especially in older patients and women, in very calcified vessels, and long occlusions, and with use of rotational atherectomy, antegrade dissection/re-entry and the retrograde approach [32]. Clinically relevant perforations associated with major adverse effects are larger in size, more proximal or at collateral location, and have a high-risk shape ('cloud-like' or 'floating') [33]. Perforations are classified by 2 descriptors: the first descriptor denotes the location of the perforation (large vessel, distal branch, septal collateral and epicardial collateral); and, the second descriptor denotes its severity. Both descriptors have important implications regarding management [8].

A. Large Vessel Perforation

Beware of perforations after stenting in the extraplaque space after knuckle wiring, especially in heavily calcified lesions. In long extraplaque space stenting with large haematoma, the perforation may continue despite covered stent implantation, unless the covered stent covers the entrance to the subintimal space all the way to the distal true lumen.

Large vessel perforations during CTO PCI can occur during CTO crossing attempts or during lesion preparation and stenting. Wire exits from the vessel architecture during CTO crossing are typically benign (except in epicardial collaterals), as long as the wires are not followed by devices. Therefore, microcatheter and balloon advancement should be avoided until the operator is certain that the wire is within the vessel architecture. Knuckle wire advancement is preferred if the course of the vessel is unclear, as it is less likely to cause a perforation compared with stiff tip wires [34]. Care should be taken during knuckle wiring to ensure that the knuckle does not enter a side branch and cause perforation. Dilation of the vessel during reverse CART needs to be done after assessment of the vessel size by fluoroscopy (using the size of the knuckled wire) or by IVUS (preferred).

The first step in every perforation is to inflate a balloon to stop bleeding into the pericardium. Large vessel perforations are usually treated with covered stents [35,36] that could be delivered through the same or through a second guide catheter ("ping-pong" technique [37]) as the blocking balloon [28,38,39]. Another way to seal a large vessel perforation is to create a dissection flap at the site of perforation and stent over the flap [39].

B. Distal Vessel Perforation

Distal vessel perforations are usually caused by too distal advancement of a coronary wire or another device, such as

the CrossBoss catheter (Boston Scientific, Natick, MA, USA). Polymer-jacketed and stiff wires are more likely to cause perforation, hence they should be exchanged for a workhorse wire as soon as possible after CTO crossing.

Distal vessel perforations may lead to slow bleeding and tamponade even several hours after the procedure [32]. Treatment is usually with coil embolisation, using the block and deliver technique; another technique is to deploy a covered stent covering the origin of the perforated branch. Other embolisation materials (such as fat, suture, glue, particles, thrombin, clotted blood, etc.) can be used depending on local availability and operator familiarity and preference.

C. Collateral Perforations

Septal collateral perforations usually do not result in adverse consequences, although septal haematomas may cause outflow obstruction leading to dry tamponade, and ventricular arrhythmias [40,41]. If a large septal haematoma develops, fenestration into the right ventricle (RV) could be performed by directing a high penetration force wire via the haematoma into the RV and passing a microcatheter or balloon [42]. Epicardial collateral perforations can lead to rapid tamponade or loculated collection of fluid especially in post-coronary artery bypass grafting patients, that might lead to cardiac chamber compression [33,43].

Some CTOs have intra-coronary antegrade bridging collaterals. Inadvertent crossing through these channels may cause rupture, especially during microcatheter or balloon crossing [44].

D. Collateral Wire Injury

During retrograde CTO PCI, when force is applied to a bare wire across a retrograde channel or bypass graft, the wire may cut into the channel causing perforation [45]. Therefore, during retrograde CTO PCI, the entire retrograde channel should always be protected by a microcatheter.

E. Persistent Staining

Despite the concerning visual appearance, persistent contrast stain usually suggests bleeding in a contained space. Contrast that disappears is usually into a cardiac chamber, or pericardium.

F. Intact Pericardium

Presence of intact versus non-intact pericardium is a crucial determinant of the consequences of a perforation. Perforations in prior CABG patients are more likely to cause loculated effusions leading to chamber compression that may require surgery or computed-tomography guided drainage.

G. Prevention and Management

Coronary wire manipulation through collaterals should be performed with caution and the position of the wire should always be confirmed prior to microcatheter advancement. 'Back bleeding' through the microcatheter should be confirmed prior to contrast injection. If there is no back bleeding, the microcatheter should be withdrawn. Epicardial collaterals should not be crossed using the surfing technique.

Suction through the microcatheter might occasionally be sufficient to seal a collateral perforation. Coiling [46] from both sides that feed the collateral might be required to seal perforations. Occasionally, additional treatment, such as injection of autologous clots, macerated fat, thrombin, or fibrin glue [47], may be required to achieve haemostasis [48].

The retrograde channel integrity should be checked before removal of the retrograde equipment [13]. The steps for safely removing the retrograde gear must include:

i) Protection of the retrograde channel with microcatheter during pulling back of retrograde wire to avoid a cheese-cutting effect;
ii) Backing out of retrograde guide catheter during retrograde gear pull back to avoid guide catheter sucking in and retrograde vessel injury; and,
iii) Maintaining access to both sides of the retrograde channel until contrast angiography can demonstrate its integrity. Guide catheter injections to check channel integrity are preferable to selective injections, especially in septal channels, as selective injections may cause septal haematoma enlargement. If there is collateral channel perforation but the CTO PCI is unsuccessful, multiple collaterals may have to be coiled, as coiling from CTO side is not possible. Bilateral angiography should always be done to ensure there is no further contrast extravasation.

If there is uncertainty about active pericardial bleeding, echocardiographic contrast administration can help confirm or exclude active bleeding into the pericardial space [49]. Pericardiocentesis should be performed in case of tamponade.

Echocardiography in the recovery area can detect pericardial effusion earlier. Protamine should only be administered after all equipment has been removed from the patient, and the pericardial effusion has been drained, as protamine may cause clotting of the pericardial blood. If surgery may be needed, protamine should not be used [50].

7. Equipment Entrapment

Equipment delivery can be challenging in CTO PCI, given high prevalence of extensive disease, calcification, and tortuosity, and may lead to stent loss and equipment entrapment, such as wire fracture, microcatheter damage and entrapment, and atherectomy burr entrapment [51–53].

Careful lesion preparation minimises the risk of stent loss during delivery attempts. In many cases, stent deployment or crushing is preferable to stent retrieval.

Knuckled coronary wires should be advanced without rotation to reduce the risk of wire fracture and entrapment. Fractured wire tips may be best left in place, but wire unravelling [52] should be ruled out, as it can lead to coronary or aortic thrombosis.

Microcatheter over-torquing can lead to the tip fracture or wire entrapment inside the microcatheter [53]. In case of difficulty advancing a microcatheter or rotating the wire, it is often better to change the microcatheter.

The risk of equipment entrapment is higher during retrograde CTO PCI. Short coronary wires and stiff tip wires should never be snared during retrograde procedures; snaring of dedicated externalisation wires is preferred. If an externalisation wire cannot be passed, snaring of a polymer-jacketed wire on the radiopaque part (e.g., Sion Black, Asahi Intecc) with a releasable snare (e.g., sumi2G snare) is recommended [54,55]. The tips of the antegrade and retrograde equipment should not get in contact over the externalised wire.

Equipment entrapment can be treated percutaneously in most cases; emergency surgery is rarely required. Advancing another wire and performing balloon angioplasty or excimer laser [53] around the entrapped equipment can often facilitate retrieval, as can use of guide catheter extensions. The hub of the trapped equipment has to be cut before inserting a guide extension over it, and often the outer sheath of the device (e.g., rotablator, IVUS, or optimal coherence tomography [OCT] catheter) has to be removed after cutting, in order to deliver a balloon alongside it in the guide catheter. If equipment fragments are left in the coronary circulation, it is best to stent over them to prevent migration, unless they are located distally.

8. Vascular Access Considerations

In most cases, CTO PCI requires two (and sometimes three) arterial access points, usually of large calibre (7 or 8 French), increasing the risk of vascular access complications. The risk could be reduced by the following measures.

i). Use of radial access

Radial access—both proximal and distal [56,57]—is associated with lower risk of bleeding and has been increasingly used for one (for example, femoral–radial) or both (bi-radial) guide catheters during CTO PCI [58–63]. Complex PCI via radial access was associated with similar success compared with femoral access in the Complex Large-bore Radial Percutaneous Coronary Intervention (COLOR) randomised-controlled trial [64].

ii). Optimal technique when obtaining femoral access

Use of fluoroscopy and ultrasound for puncturing the femoral artery, micro-puncture technique [65], performing femoral angiography at the beginning of the case, and possibly using arterial closure devices may minimise the risk of femoral access complications [66]. Use of long sheaths can improve guide catheter support, especially in patients with severe iliac tortuosity and prevent sheath movement [24,67]. iii). Use of two access points. In CTO PCI, two access points are used in most cases, allowing use of the contralateral access to check for vessel integrity and for balloon tamponade if needed.

9. Contrast-Induced Acute Kidney Injury

CTO PCI often requires administration of a large volume of contrast, increasing the risk of contrast-induced acute kidney injury. The risk can be reduced as follows.

i). Reducing contrast toxicity

Contrast induced kidney injury can be reduced by hydration, statin administration, and discontinuation of nephrotoxic medications.

ii). Reducing contrast volume

The global CTO crossing algorithm recommends keeping the contrast volume to less than three times the estimated glomerular filtration rate or even lower if the patient has comorbidities [10,68]. Contrast volume can be reduced by: a) careful analysis of previous angiograms; b) optimal timing of the antegrade contrast injection to coincide with maximal retrograde filling; c) microcatheter tip injections both antegrade (instead of injections through the guide catheter) and retrograde (through the most dominant collateral); d) use of the retrograde approach, especially if selective collateral channel injection is used instead of guide catheter injection to visualise the collateral channel anatomy along with use of the reverse controlled antegrade and retrograde tracking (CART) for proximal true lumen entry; e) use of biplane; and, f) use of IVUS [69].

10. Radiation Injury

A. Radiation Injury in CTO PCI

Radiation injury is especially important in CTO PCI, due to longer procedural time and often high radiation dose [70]. Skin injury from radiation presents late and is often missed [71]. The air kerma radiation dose should be continuously monitored during the procedure, as it correlates well with radiation skin injury. The global CTO crossing algorithm recommends termination of the procedure "if the air kerma radiation dose is >5 Gray, unless the procedure is well advanced" [10].

B. Prevention

i). Reduce total radiation dose

Multiple strategies can reduce the radiation dose [71], such as low magnification and collimation, using ≤7.5 frame per second fluoroscopy, avoiding steep angles, using the fluoroscopy store function instead of cine angiography whenever possible, for example, for documenting the position of balloons and stents, and avoidance of panning.

Further radiation dose reduction can be achieved by using the trapping technique for device exchanges, using a marker torquer on wires (locking the torquer on the wire, when the wire tip is just inside the microcatheter tip before wire removal, and keeping it there when reusing the wire into the microcatheter, to reduce X-ray use to detect when the wire

reaches the tip of the guide catheter) and detailed preprocedural angiogram review, avoiding ad hoc CTO PCI. Some X-ray systems [72] stop imaging when the operator's eyes are not looking at the screen, reducing unnecessary fluoroscopy radiation.

ii) Reduce radiation concentration
Routine preprocedural examination of the patient's skin, if they have undergone a previous long procedure, can help with planning fluoroscopic views to avoid further radiation skin injury. Calculation of the cumulative dose prior to repeat CTO PCI cases can reduce the risk of radiation skin injury. Some angiography machines (Infinix^{TM}-i cardiovascular X-ray, Toshiba Corporation, Tokyo, Japan; Dosemap, General Electric, Boston, MA, USA) have built-in software to display skin dosage information, allowing adjustment of the Xray tube position to scatter radiation dose reducing skin injury risk. Frequent change of views during CTO PCI can also have a similar effect. Disposable radiation shields (such as the Radpad, Kansas City, MO, USA) can be applied to previously injured skin areas. In patients requiring repeat CTO PCI, an adequate period of recovery (at least 6 months) is advised, as dermatitis can occur late [73].

C. Patient Follow-Up

Patient who receives high radiation dose (>5 Gy) should receive patient information sheets, followed by clinical examination and photography after 30 days. This can help avoid unnecessary and potential harmful skin biopsy, that can result in non-healing wounds [74].

11. When to Stop

Four parameters should be constantly evaluated during the procedure to determine the need for stopping: radiation dose, contrast volume, procedure time, and risk of the remaining treatment options. The global CTO crossing algorithm recommends contrast, radiation, and procedural time limits for stopping a procedure [10]. In addition, lack of needed experience in ADR/retrograde, occurrence of a serious complication, and operator or patient fatigue favour stopping CTO PCI [10]. In the event of a complication such as donor vessel injury, the complication should be addressed prior to finishing the procedure. Any complication must be addressed, prior to resuming the CTO PCI. CTO PCI is an elective procedure, and "success" in a procedure should never be at the cost of safety.

Before stopping a CTO crossing attempt, determine if anything can be done to improve the chances of success during the next attempt (investment procedure) [10]. Investment can be considered using subintimal dissection and re-entry (STAR) and subintimal plaque modification (SPM) [75,76]. CTO PCI can be reattempted in 6–8 weeks, unless there is concern for radiation skin injury, in which case a longer delay to reattempt is suggested, as above.

12. Proctorship

The global CTO crossing algorithm recommends proctorship, if advanced crossing techniques such as use of the Stingray system or the retrograde approach are needed but the operator is unfamiliar with these techniques: "Proctoring may not only improve the operator CTO PCI skills but can also improve the safety of the CTO procedure, especially for highly complex lesions and patients" [10]. Therefore, proctorship is an important part of CTO PCI safety [77]. Having well established referral and request systems for proctors for complex CTO cases is part of the setup for a safe CTO program.

Conclusion

In CTO PCI, success should not be achieved at the cost of safety. A thorough understanding of potential complications, continuous monitoring of the patient for early complication detection, and prompt treatment can help prevent complications and/or minimise their adverse impact. Addressing the 12 areas outlined in this document could improve the safety of CTO PCI.

Funding

This paper received no direct external funding.

Disclosures

Dr Wu has received research funding from OrbusNeich, Asahi Intecc, Abiomed; has received consulting honoraria from Boston Scientific and Abbott Vascular; is a member of the board of directors for APCTO Club; and holds stock in Abbott Vascular.

Dr Kalyanasundaram has received fees from Abbott Vascular, Boston Scientific, Asahi Intecc, and Terumo.

Dr Brilakis has received consulting/speaker honoraria from Abbott Vascular, American Heart Association (associate editor Circulation), Amgen, Asahi Intecc, Biotronik, Boston Scientific, Cardiovascular Innovations Foundation (Board of Directors), CSI, Elsevier, GE Healthcare, IMDS, Medtronic, Siemens, and Teleflex; research support: Boston Scientific, GE Healthcare; owner, Hippocrates LLC; shareholder: MHI Ventures, Cleerly Health, Stallion Medical.

Dr Mashayekhi has received consulting, speaker, and proctoring honoraria from Abbott Vascular, Asahi Intecc, AstraZeneca, Biotronik, Boston Scientific, Cardinal Health, Daiichi- Sankyo, Medtronic, Teleflex, and Terumo.

Dr Tsuchikane is a consultant for Boston Scientific, Asahi Intecc, and Kaneka.

For the Disclosures of all the CTO Global Consensus Group contributors (included those listed below), please see Appendix A.

The CTO Global Consensus Group Authors

Writing Committee: Eugene B. Wu, Arun Kalyanasundaram, Emmanouil S. Brilakis, Kambis Mashayekhi, Etsuo Tsuchikane.

Nidal Abi Rafeh (St. George Hospital University Medical Center, Beirut, Lebanon; NorthOaks Health System, Hammond, LA, USA.) Pierfrancesco Agostoni (HartCentrum, Ziekenhuis Netwerk Antwerpen (ZNA), Antwerp, Belgium). Khaldoon Alaswad (Edith and Benson Ford Heart and Vascular Institute, Henry Ford Hospital, Henry Ford Health System, Wayne State University, MI, USA). Mario Araya (Clinica Alemana and Hospital Militar de Santiago, Chile). Alexandre Avran (Centre Hospitalier de Valenciennes, Valenciennes, France). Mohamed Ayoub (University Heartcenter NRW, Bad Oeynhausen, Germany). Lorenzo Azzalini (Division of Cardiology, VCU Health Pauley Heart Center, Virginia Commonwealth University, Richmond, VA, USA). Avtandil M. Babunashvili (Moscow State Medical [Sechenov's] University, Moscow, Russia). Baktash Bayani (Cardiology Department, Mehr Hospital, Mashhad, Iran). Michael Behnes (First Department of Medicine, University Medical Centre Mannheim, Faculty of Medicine Mannheim, University of Heidelberg, Germany). Ravinay Bhindi (Royal North Shore Hospital and University of Sydney, Sydney, NSW, Australia). Nicolas Boudou (Interventional Cardiology Clinique Saint Augustin Bordeaux France). Marouane Boukhris (Cardiology Department, CHU Dupuytren, Limoges, France). Nenad Z. Bozinovic (University Clinical Center of Nis. Serbia). Leszek Bryniarski (Department of Cardiology, Institute of Cardiology, Jagiellonian University Medical College; Department of Cardiology and Cardiovascular Interventions, University Hospital, Kraków, Poland). Alexander Bufe (Heart Center Krefeld, University Witten/Herdecke, Witten, Germany). Christopher E. Buller (Teleflex Inc. and St. Michael's Hospital, Toronto, Canada). M. Nicholas Burke (Minneapolis Heart Institute and Minneapolis Heart Institute Foundation, Minneapolis, MN, USA). Heinz Joachim Buettner (Department of Cardiology and Angiology, II University Heart Center Freiburg Bad Krozingen, Germany). Pedro Cardoso (Cardiology and Vascular Department, Santa Maria University Hospital [CHULN], Lisbon Academic Medical Centre [CAML]; Centro Cardiovascular da Universidade de Lisboa [CCUL], Portugal). Mauro Carlino (Interventional Cardiology Unit, Cardio-Thoracic-Vascular Department IRCCS San Raffaele Scientific Institute, Milan, Italy). Chi-Kin Chan (Premier Medical Centre, Hong Kong). Jiyan Chen (Guangdong Provincial People's Hospital, Guangdong, China). Evald Hoej Christiansen (Department of Cardiology, Aarhus University Hospital, Denmark). Antonio Colombo (Department of Biomedical Sciences, Humanitas University, Pieve Emauele-Milan, Italy; Humanitas Clinical and Research Center, IRCCS, Rozzano-Milan, Italy). Kevin Croce (Cardiovascular Division, Brigham and Women's Hospital, Boston, MA, USA). Felix Damas de los Santos (Instituto Nacional de Cardiologia; Ignacio Chávez and Centro Medico ABC, Mexico City, Mexico). Tony de Martini (Springfield Memorial Hospital, Springfield, IL; Midwest Cardiovascular Institute, Naperville, IL, USA). Joseph Dens (Hospital Oost-Limburg, Genk, Belgium). Carlo di Mario (Department of Clinical & Experimental Medicine, University Hospital Careggi, Florence, Italy). Darshan Doshi (Massachusetts General Hospital, Boston, MA, USA).

Kefei Dou (Research Center for Coronary Heart Disease, State Key Laboratory of Cardiovascular Disease, Fuwai Hospital National Center for Cardiovascular Diseases Chinese Academy of Medical, China). Mohaned Egred (Freeman Hospital & Newcastle University, Newcastle upon Tyne, UK). Basem Elbarouni (St. Boniface Hospital & University of Manitoba, Winnipeg, MB, Canada). Ahmed M. ElGuindy (Department of Cardiology, Aswan Heart Centre - Magdi Yacoub Foundation, Egypt). Javier Escaned (Hospital Clinico San Carlos IDISSC, Complutense University of Madrid, Madrid, Spain). Sergey Furkalo (National Institute of Surgery and Transplantology NAMS, Kiev, Ukraine). Andrea Gagnor (Department of Invasive Cardiology, Maria Vittoria Hospital, Turin, Italy). Alfredo R. Galassi (Department of PROMISE University of Palermo, Italy). Roberto Garbo (Maria Pia Hospital, GVM Care & Research Turin, Italy). Gabriele L.Gasparini (Department of Biomedical Sciences, Humanitas University, Pieve Emauele-Milan, Italy; Humanitas Clinical and Research Center, IRCCS, Rozzano-Milan, Italy). Junbo Ge (Zhongshan Hospital, Fudan University, Shanghai, China). Lei Ge (Zhongshan Hospital, Fudan University, Shanghai, China). Pravin Kumar Goel (Sanjay Gandhi Post Graduate Institute of Medical Sciences, Lucknow, India). Omer Goktekin (Memorial Hospital, Istanbul, Turkey). Nieves Gonzalo (Interventional Cardiology, Hospital Clinico San Carlos, IdISSC, Universidad Complutense, Madrid, Spain). Sevket Gorgulu (Acibadem University Cardiology Department, Istanbul/Turkey). Luca Grancini (Centro Cardiologico Monzino, IRCCS, Milan, Italy). Allison B. Hall (Eastern Health/Memorial University of Newfoundland, St. John's, Newfoundland, Canada). Colm Hanratty (Mater Private Hospital, Dublin, Ireland). Stefan Harb (Medical University of Graz, Department of Cardiology, University Heart Center, Graz, Austria).

Scott A. Harding (Wellington Hospital, Capital and Coast District Health Board, New Zealand). Raja Hatem (Hôpital du Sacré-Coeur de Montréal Université de Montréal, Canada). Farrel Hellig (Sunninghill Hospital, Johannesburg; Division of Cardiology, University of Cape Town, Cape Town, South Africa). Jose P.S. Henriques (Amsterdam UMC location, University of Amsterdam, Department, Amsterdam, The Netherlands). David Hildick-Smith (Sussex Cardiac Centre, Brighton, UK). Jonathan M. Hill (Royal Brompton Hospital, London, UK). Angela Hoye (Centre for Atherothrombosis and Metabolic Disease, Hull York Medical School, University of Hull, UK). Wissam Jaber (Emory University, Atlanta, GA, USA). Farouc A. Jaffer (Massachusetts General Hospital, Boston, MA, USA). Yangsoo Jang (CHA

Bundang Medical Center, CHA University College of Medicine, South Korea). Risto Jussila (Interventional Cardiology, Helsinki Heart Hospital, Finland). Artis Kalnins (Clinic of Cardiovascular Diseases Riga EAST Clinical University Hospital, Riga, Latvia). Sanjog Kalra (Peter Munk Cardiac Centre, Toronto General Hospital, Toronto, Canada). David E. Kandzari (Piedmont Heart Institute and Cardiovascular Services, Atlanta, GA, USA). Hsien-Li Kao (Department of Internal Medicine, Cardiology Division, Cardiovascular Center, National Taiwan University Hospital, Taipei, Taiwan). Dimitri Karmpaliotis (Gagnon Cardiovascular Institute, Morristown Medical Center, Morristown, NJ, USA). Hussien Heshmat Kassem (Kasr Alainy Medical School, Cairo University, Egypt; Fujairah Hospital, Ministry of Health, UAE). Kathleen E. Kearney (University of Washington Medical Centre, Seattle, WA, USA). Jimmy Kerrigan (Ascension Saint Thomas Heart, Nashville, TN, USA). Jaikirshan Khatri (Cleveland Clinic, Cleveland, OH, USA). Dmitri Khelimskii (Natsional'nyy Meditsinskiy Issledovatel'skiy Tsentr Imeni Akademika Ye.n. Meshalkina - Novosibirsk, Russian Federation). Ajay J Kirtane (Columbia University Irving Medical Center, New York, NY, USA). Paul Knaapen (Heart Center of the Amsterdam University Medical Centers, Amsterdam, Netherlands). Ran Kornowski (Department of Cardiology, Rabin Medical Center, Faculty of Medicine, Tel-Aviv University, Tel Aviv, Israel). Oleg Krestyaninov (E.Meshalkin National Medical Research Center of the Ministry of Health of the Russian Federation). V. Ganesh Kumar (Department of Cardiology, Dr LH Hiranandani Hospital, Mumbai, India). Prathap Kumar (Meditrina Hospitals Kerala, India). Pablo Manuel Lamelas (Cardiovascular de Buenos Aires, Argentina; Health Research Methods, Evidence, and Impact, McMaster University, Canada). Seung-Whan Lee (Department of Cardiology Asan Medical Center, University of Ulsan College of Medicine Seoul, Republic of Korea). Thierry Lefevre (Institut Cardiovasculaire Paris Sud, Hôpital Privé Jacques Cartier, Ramsay Santé, Massy, France). Gregor Leibundgut (Department of Cardiology Medizinische Universitätsklinik Kantonsspital Baselland, Liestal, Switzerland). Raymond Leung (CK Hui Heart Centre, Royal Alexandra Hospital, Edmonton, Alberta, Canada). Sum-Kin Leung (Keen Heart, Hong Kong). Yu Li (Beijing Anzhen Hospital, Capital Medical University, China). Yue Li (Department of Cardiology, The First Affiliated Hospital of Harbin Medical University, China). Soo-Teik Lim (National Heart Centre of Singapore, Singapore).

Sidney Lo (Department of Cardiology, Liverpool Hospital; The University of New South Wales, Sydney, Australia). William Lombardi (University of Washington, Seattle, WA, USA). Anbukarasi Maran (Medical University of South Carolina Ralph H Johnson VA Medical Center, Charleston, SC, USA). Margaret McEntegart (Columbia University Irving Medical Center, New York, NY, USA). Jeffrey Moses (Columbia University Irving Medical Center, New York; St Francis Heart Center, Roslyn, New York, NY, USA). Muhammad Munawar (Binawaluya Cardiac Center and Department of Cardiology, Faculty of Medicine, Universitas Indonesia, Jakarta, Indonesia; Department of Cardiology, Faculty of Medicine, Universitas Gadjahmada, Yogyakarta, Indonesia). Wataru Nagamatsu (Hokusetsu General Hospital, Osaka, Japan). Andres Navarro (QRA Medicina Especilizada, Hospital de los Valles, Universidad San Francisco de Quito, Ecuador). Hung M. Ngo (Choray University Hospital, Ho Chi Minh City, Vietnam). William Nicholson (Emory University, Atlanta, GA, USA). Anja Oksnes (Heart Department, Haukeland University Hospital, Norway). Goran K. Olivecrona (Department of Cardiology SUS-Lund, Lund University, Lund, Sweden). Lucio Padilla (Department of Interventional Cardiology and Endovascular Therapeutics, ICBA, Instituto Cardiovascular, Buenos Aires, Argentina). Mitul Patel (Division of Cardiovascular Medicine UC San Diego School of Medicine, San Diego, CA, USA). Ashish Pershad (Chandler Regional Medical Center, Chandler, AZ, USA). Marin Postu (Cardiology Department, University of Medicine and Pharmacy "Carol Davila," Institute of Cardiovascular Diseases "Prof. Dr. C.C. Iliescu," Bucharest, Romania). Stylianos Pyxaras (Medizinische Klinik I, Klinikum Fürth, Fürth, Germany). Jie Qian (Beijing Fuwai Hospital, Beijing, China). Alexandre Quadros (Interventional Cardiology Division and Post Graduate Course of Cardiology, Instituto de Cardiologia do Rio Grande do Sul, Porto Alegre, Brazil).

Franklin Leonardo Hanna Quesada (The "Clinica Comfamiliar" Pereira, Colombia). Truls Råmunddal (Dept of Cardiology Sahlgrenska University Hospital, Gothenburg, Sweden). Vithala Suryaprakasa Rao (Hod Cardiology, Care Hospitals Banjara, Hyderabad, Telangana, India). Sudhir Rathore (Frimley Health NHS Foundation Trust, Frimley, UK). Nicolaus Reifart (Department of Cardiology, Main Taunus Heart Institute, Bad Soden, Germany). Robert F. Riley (Overlake Medical Center & Clinics, Bellevue, WA, USA). Stephane Rinfret (McGill University Health Centre, Montreal, Quebec, Canada). Meruzhan Saghatelyan (Nork Marash MC; Erebouni MC, Yerevan, Armenia). Ricardo Santiago (PCI Cardiology Group, Bayamon Heart and Lung Institute, Puerto Rico). Ashok Seth (Fortis Escorts Heart Institute, New Delhi, India). Georgios Sianos (HEPA University Hospital, Thessaloniki, Greece). Elliot Smith (Department of Cardiology, Barts Heart Centre, St Bartholomew's Hospital, London, UK). Anthony Spaedy (Boone Hospital Center, Columbia, MO, USA). James Spratt (St George's University Hospital NHS Foundation Trust, London, UK). Gregg W. Stone (The Zena and Michael A. Wiener Cardiovascular Institute, Icahn School of Medicine at Mount Sinai, New York, NY, USA). Julian W. Strange (Bristol Royal Infirmary, University Hospital Bristol NHS Trust, Bristol, UK). Khalid O. Tammam (Department at the International Medical Center, Jeddah, Kingdom of Saudi Arabia). Craig A. Thompson (Hartford Healthcare Hartford, CT, USA). Aurel Toma (Department of Internal Medicine II, Division of Cardiology, Medical University of Vienna, Vienna, Austria). Jennifer A. Tremmel (Stanford University Medical Centre, Stanford, CA, USA). Imre Ungi (University of Szeged, Department of Invasive Cardiology, Hungary). Giuseppe

Vadalà (Division of Cardiology, University Hospital, Paolo Giaccone, Palermo, Italy). Minh Vo (Royal Columbian Hospital, Vancouver, BC, Canada). Vu Hoang Vu (University of Medicine and Pharmacy at Ho Chi Minh City, Vietnam). Simon Walsh (Belfast Health and Social Care Trust, Belfast, UK; Boston Scientific, UK). Daniel Weilenmann (Department of Cardiology, Kantonsspital St. Gallen, Sankt Gallen, Switzerland). Gerald S. Werner (Medizinische Klinik I Klinikum, Darmstadt GmbH, Germany). Jaroslaw Wojcik (Hospital of Invasive Cardiology IKARDIA, Nałęczów/Lublin, Poland). Jason Wollmuth (Providence Heart and Vascular Institute, Portland, OR, USA). Chiung-Jen Wu (Chang Chung Memorial Hospital, Taiwan). Bo Xu (Massachusetts General Hospital Boston, MA, USA). Masahisa Yamane (Saitama-Sekishinkai Hospital, Saitama, Japan). Luiz F. Ybarra (London Health Sciences Centre, Schulich School of Medicine & Dentistry, Western University, London, ON, Canada). Robert W. Yeh (Richard A. and Susan F. Smith Center for Outcomes Research in Cardiology, Division of Cardiovascular Medicine, Beth Israel Deaconess Medical Center, Harvard Medical School, Boston MA, USA). Chris Zambakides (Department of Cardiology, Chris-Hani Baragwanath Hospital, Johannesburg, South Africa). Qi Zhang (Shanghai East Hospital, Tongji University, Shanghai, China).

Acknowledgements

We would like to acknowledge Professor Bryan P. Y. Yan and Ms Sushanna Pui Shan Lai for their assistance in preparing the manuscript.

References

[1] Maeremans J, Walsh S, Knaapen P, et al. The Hybrid Algorithm for Treating Chronic Total Occlusions in Europe: The RECHARGE Registry. J Am Coll Cardiol. 2016;68(18):1958–70.

[2] Brilakis ES, Banerjee S, Karmpaliotis D, Lombardi WL, Tsai TT, Shunk KA, et al. Procedural outcomes of chronic total occlusion percutaneous coronary intervention: a report from the NCDR (National Cardiovascular Data Registry). JACC Cardiovasc Interv. 2015;8(2):245–53.

[3] Danek BA, Karatasakis A, Karmpaliotis D, et al. Development and Validation of a Scoring System for Predicting Periprocedural Complications During Percutaneous Coronary Interventions of Chronic Total Occlusions: The Prospective Global Registry for the Study of Chronic Total Occlusion Intervention (PROGRESS CTO) Complications Score. J Am Heart Assoc. 2016;5(10):e004272.

[4] Konstantinidis NV, Werner GS, Deftereos S, et al. Temporal Trends in Chronic Total Occlusion Interventions in Europe. Circ Cardiovasc Interv. 2018;11(10):e006229.

[5] Tanaka H, Morino Y, Abe M, et al. Impact of J-CTO score on procedural outcome and target lesion revascularisation after percutaneous coronary intervention for chronic total occlusion: a substudy of the J-CTO Registry (Multicentre CTO Registry in Japan). EuroIntervention. 2016;11(9):981–8. https://doi.org/10.4244/EIJV11I9A202.

[6] Morino Y, Kimura T, Hayashi Y, et al. In-hospital outcomes of contemporary percutaneous coronary intervention in patients with chronic total occlusion insights from the J-CTO Registry (Multicenter CTO Registry in Japan). JACC Cardiovasc Interv. 2010;3(2):143–51.

[7] Quadros A, Belli KC, de Paula JET, et al. Chronic total occlusion percutaneous coronary intervention in Latin America. Catheter Cardiovasc Interv. 2020;96(5):1046–55.

[8] Ybarra LF, Rinfret S, Brilakis ES, et al. Definitions and Clinical Trial Design Principles for Coronary Artery Chronic Total Occlusion Therapies: CTO-ARC Consensus Recommendations. Circulation. 2021;143(5):479–500.

[9] Brilakis ES, Mashayekhi K, Tsuchikane E, et al. Guiding Principles for Chronic Total Occlusion Percutaneous Coronary Intervention. Circulation. 2019;140(5):420–33.

[10] Wu EB, Brilakis ES, Mashayekhi K, et al. Global Chronic Total Occlusion Crossing Algorithm: JACC State-of-the-Art Review. J Am Coll Cardiol. 2021;78(8):840–53.

[11] Dangas GD, Kini AS, Sharma SK, et al. Impact of hemodynamic support with Impella 2.5 versus intra-aortic balloon pump on prognostically important clinical outcomes in patients undergoing high-risk percutaneous coronary intervention (from the PROTECT II randomized trial). Am J Cardiol. 2014;113(2):222–8.

[12] Lawton JS, Tamis-Holland JE, Bangalore S, et al. 2021 ACC/AHA/SCAI Guideline for Coronary Artery Revascularization: A Report of the American College of Cardiology/American Heart Association Joint Committee on Clinical Practice Guidelines. Circulation. 2022;145(3):e18–114.

[13] Wu EB, Tsuchikane E. The inherent catastrophic traps in retrograde CTO PCI. Catheter Cardiovasc Interv. 2018;91(6):1101–9.

[14] Brilakis ES, Grantham JA, Banerjee S. "Ping-pong" guide catheter technique for retrograde intervention of a chronic total occlusion through an ipsilateral collateral. Catheter Cardiovasc Interv. 2011;78(3):395–9.

[15] Shorrock D, Michael TT, Patel V, et al. Frequency and outcomes of aortocoronary dissection during percutaneous coronary intervention of chronic total occlusions: a case series and systematic review of the literature. Catheter Cardiovasc Interv. 2014;84(4):670–5.

[16] Baumann S, Huseynov A, Behnes M, et al. Treatment optimization of aortocoronary dissection as a complication after heart catheterization using coronary computerized tomographic angiography. Can J Cardiol. 2014;30(6):696.e13–5.

[17] Vo MN, Christopoulos G, Karmpaliotis D, Lombardi WL, Grantham JA, Brilakis ES. Balloon-Assisted Microdissection "BAM" Technique for Balloon-Uncrossable Chronic Total Occlusions. J Invasive Cardiol. 2016;28(4):E37–41.

[18] Smith EJ, Di Mario C, Spratt JC, et al. Subintimal TRAnscatheter Withdrawal (STRAW) of hematomas compressing the distal true lumen: a novel technique to facilitate distal reentry during recanalization of chronic total occlusion (CTO). J Invasive Cardiol. 2015;27(1):E1–4.

[19] Vo MN, Brilakis ES, Grantham JA. Novel use of cutting balloon to treat subintimal hematomas during chronic total occlusion interventions. Catheter Cardiovasc Interv. 2018;91(1):53–6.

[20] Noguchi K, Hori D, Nomura Y, Tanaka H. Iatrogenic Acute Aortic Dissection during Percutaneous Coronary Intervention for Acute Myocardial Infarction. Ann Vasc Dis. 2012;5(1):78–81.

[21] Fiddler M, Avadhani SA, Marmur JD. Guide catheter-induced aortic dissection complicated by pericardial effusion with pulsus paradoxus: a case report of successful medical management. Case Rep Med. 2015;2015:480242.

[22] Shah P, Bajaj S, Shamoon F. Aortic Dissection Caused by Percutaneous Coronary Intervention: 2 New Case Reports and Detailed Analysis of 86 Previous Cases. Tex Heart Inst J. 2016;43(1):52–60.

[23] Núñez-Gil IJ, Bautista D, Cerrato E, et al. Incidence, Management, and Immediate- and Long-Term Outcomes After Iatrogenic Aortic Dissection During Diagnostic or Interventional Coronary Procedures. Circulation. 2015;131(24):2114–9.

[24] Piedimonte G, Bertagnin E, Castellana C, et al. Ultrasound versus fluoroscopy-guided femoral access for percutaneous coronary intervention of chronic total occlusions: Insights from FOUND BLOOD CTO Registry. Cardiovasc Revasc Med. 2022;38:61–7.

[25] Tremmel JA, Tibayan YD, O'Loughlin AJ, et al. Most accurate definition of a high femoral artery puncture: aiming to better predict retroperitoneal hematoma in percutaneous coronary intervention. Catheter Cardiovasc Interv. 2012;80(1):37–42.

[26] Kawasaki T, Azuma A, Tsukamoto M, et al. Echocardiographically documented acute aortic insufficiency induced by Amplatz left guide catheter. Int J Cardiovasc Intervent. 2000;3(4):237–9.

[27] Azzalini L, Moroni F, Santiago R. Subintimal shift at the bifurcation: A cause of side branch occlusion in chronic total occlusion intervention. Cardiovasc Revasc Med. 2022;40S:298–301.

[28] Matsuno S, Tsuchikane E, Harding SA, et al. Overview and proposed terminology for the reverse controlled antegrade and retrograde tracking (reverse CART) techniques. EuroIntervention. 2018;14(1):94–101.

[29] Wu EB, Tsuchikane E, Lo S, et al. Chronic Total Occlusion Wiring: A State-of-the-Art Guide From The Asia Pacific Chronic Total Occlusion Club. Heart Lung Circ. 2019;28(10):1490–500.
[30] Tajti P, Doshi D, Karmpaliotis D, Brilakis ES. The "double stingray technique" for recanalizing chronic total occlusions with bifurcation at the distal cap. Catheter Cardiovasc Interv. 2018;91(6):1079–83.
[31] Galassi AR, Tomasello SD, Costanzo L, et al. Mini-STAR as bail-out strategy for percutaneous coronary intervention of chronic total occlusion. Catheter Cardiovasc Interv. 2012;79(1):30–40.
[32] Azzalini L, Poletti E, Ayoub M, et al. Coronary artery perforation during chronic total occlusion percutaneous coronary intervention: epidemiology, mechanisms, management, and outcomes. EuroIntervention. 2019;15(9):e804–11.
[33] Hirai T, Nicholson WJ, Sapontis J, et al. A Detailed Analysis of Perforations During Chronic Total Occlusion Angioplasty. JACC Cardiovasc Interv. 2019;12(19):1902–12.
[34] Harding SA, Wu EB, Lo S, et al. A New Algorithm for Crossing Chronic Total Occlusions From the Asia Pacific Chronic Total Occlusion Club. JACC Cardiovasc Interv. 2017;10(21):2135–43.
[35] Sandoval Y, Lobo AS, Brilakis ES. Covered stent implantation through a single 8-french guide catheter for the management of a distal coronary perforation. Catheter Cardiovasc Interv. 2017;90(4):584–8.
[36] Song X, Qin Q, Chang S, et al. Clinical Outcomes of Self-Made Polyurethane-Covered Stent Implantation for the Treatment of Coronary Artery Perforations. J Interv Cardiol. 2021;2021:6661763.
[37] Assad-Kottner C, Hakeem A, Uretsky BF. Modified dual guide catheter ("ping-pong") technique to treat left internal mammary artery graft perforation. Catheter Cardiovasc Interv. 2015;86(1):E28–31.
[38] Gupta H, Kaur N, Sharma Y, Lim ST. Modified double guiding catheter 'Ping Pong' technique to treat large coronary perforation: a case report. Eur Heart J Case Rep. 2021;5(5):ytab173.
[39] Xenogiannis I, Tajti P, Nicholas Burke M, Brilakis ES. An alternative treatment strategy for large vessel coronary perforations. Catheter Cardiovasc Interv. 2019;93(4):635–8.
[40] Frisoli TM, Afana M, Mawri S, et al. Respect the Septal Perforator: Septal Artery Perforation During CTO PCI Resulting in Massive Interventricular Septal Hematoma and Biventricular Cardiac Obstructive Shock. JACC Cardiovasc Interv. 2017;10(10):e91–2.
[41] Dautov R, Urena M, Nguyen CM, Gibrat C, Rinfret S. Safety and effectiveness of the surfing technique to cross septal collateral channels during retrograde chronic total occlusion percutaneous coronary intervention. EuroIntervention. 2017;12(15):e1859–67.
[42] Masahisa Y, Kenya N, Masaaki O, et al. The role of imaging in coronary chronic total occlusion intervention. In: Wijns W, Serruys PW, Vahanian A, et al. editors. The PCR-EAPCI Percutaneous Interventional Cardiovascular Medicine Textbook. Toulouse: Europa Digital & Publishing; 2019. https://www.pcronline.com/eurointervention/textbook/pcr-textbook/chapter/?chapter_id=370. [accessed 13.7.22].
[43] Ellis SG. CTO Coronary Perforations: What You Really Need to Know. JACC Cardiovasc Interv. 2019;12(19):1913–4.
[44] Han YL, Wang SL, Jing QM, et al. Percutaneous coronary intervention for chronic total occlusion in 1263 patients: a single-center report. Chin Med J (Engl). 2006;119(14):1165–70.
[45] Gasparini GL, Presbitero P. An extensive cutting effect during retrograde percutaneous coronary intervention of a chronic total occlusion through an old degenerated bypass vein. Cardiovasc Revasc Med. 2015;16(3):192–6.
[46] Hachinohe D, Kashima Y, Okada Y, et al. Coil Embolization for Coronary Artery Perforation: A Retrospective Analysis of 110 Patients. J Interv Cardiol. 2021;2021:9022326.
[47] Störger H, Ruef J. Closure of guide wire-induced coronary artery perforation with a two-component fibrin glue. Catheter Cardiovasc Interv. 2007;70(2):237–40.
[48] Morisawa D, Okamura A, Date M, Nagai H, Iwakura K, Fujii K. Treatment of collateral channel perforation during percutaneous coronary intervention for chronic total occlusion with retrograde approach. Cardiovasc Interv Ther. 2014;29(1):86–92.
[49] Bagur R, Bernier M, Kandzari DE, Karmpaliotis D, Lembo NJ, Rinfret S. A novel application of contrast echocardiography to exclude active coronary perforation bleeding in patients with pericardial effusion. Catheter Cardiovasc Interv. 2013;82(2):221–9.
[50] Barbosa RR, Costa R, Slhessarenko JR, Coelho FM, Feres F. Treatment for Type IV Coronary Perforation during Percutaneous Coronary Intervention. Revista Brasileira de Cardiologia Invasiva (English Edition). 2013;21(1):73–7.
[51] Gasparini GL, Sanz-Sanchez J, Regazzoli D, et al. Device entrapment during percutaneous coronary intervention of chronic total occlusions: incidence and management strategies. EuroIntervention. 2021;17(3):212–9.
[52] Megaly M, Basir MB, Brilakis E, Alaswad K. Wire Entrapment and Unraveling in the Aorta: Snaring Technique for the Nonvisible Filament. JACC Cardiovasc Interv. 2022;15(2):e21–2.
[53] Tajti P, Ayoub M, Loffelhardt N, Mashayekhi K. Management of Microcatheter Fracture in Complex Percutaneous Coronary Intervention With Laser Atherectomy. Cardiovasc Revasc Med. 2021;28S:208–11.
[54] Wu EB, Kao HL, Lo S, et al. From reverse CART to antegrade wire access: a guide to externalisation, tip-in, rendezvous, and snaring from the APCTO club: Reverse CART to antegrade access. AsiaIntervention. 2020;6(1):6–14.
[55] Yokoi K, Sumitsuji S, Kaneda H, et al. A novel homemade snare, safe, economical and size-adjustable. EuroIntervention. 2015;10(11):1307–10.
[56] Gasparini GL, Garbo R, Gagnor A, Oreglia J, Mazzarotto P. First prospective multicentre experience with left distal transradial approach for coronary chronic total occlusion interventions using a 7 Fr Glidesheath Slender. EuroIntervention. 2019;15(1):126–8.
[57] Nikolakopoulos I, Patel T, Jefferson BK, et al. Distal Radial Access in Chronic Total Occlusion Percutaneous Coronary Intervention: Insights From the PROGRESS-CTO Registry. J Invasive Cardiol. 2021;33(9):E717–22.
[58] Poletti E, Azzalini L, Ayoub M, et al. Conventional vascular access site approach versus fully trans-wrist approach for chronic total occlusion percutaneous coronary intervention: a multicenter registry. Catheter Cardiovasc Interv. 2020;96(1):E45–52.
[59] Meah MN, Ding WY, Joseph T, Hasleton J, Shaw M, Palmer ND. Complex Chronic Total Occlusion Revascularization - A Comparison of Biradial Versus Femoral Access. J Invasive Cardiol. 2021;33(1):E52–8.
[60] Bakker EJ, Maeremans J, Zivelonghi C, et al. Fully Transradial Versus Transfemoral Approach for Percutaneous Intervention of Coronary Chronic Total Occlusions Applying the Hybrid Algorithm: Insights From RECHARGE Registry. Circ Cardiovasc Interv. 2017;10(9):e005255.
[61] Tajti P, Alaswad K, Karmpaliotis D, et al. Procedural Outcomes of Percutaneous Coronary Interventions for Chronic Total Occlusions Via the Radial Approach: Insights From an International Chronic Total Occlusion Registry. JACC Cardiovasc Interv. 2019;12(4):346–58.
[62] Wu CJ, Fang HY, Cheng CI, et al. The safety and feasibility of bilateral radial approach in chronic total occlusion percutaneous coronary intervention. Int Heart J. 2011;52(3):131–8.
[63] Rinfret S, Joyal D, Nguyen CM, et al. Retrograde recanalization of chronic total occlusions from the transradial approach; early Canadian experience. Catheter Cardiovasc Interv. 2011;78(3):366–74.
[64] Meijers TA, Aminian A, van Wely M, et al. Randomized Comparison Between Radial and Femoral Large-Bore Access for Complex Percutaneous Coronary Intervention. JACC Cardiovasc Interv. 2021;14(12):1293–303.
[65] Ben-Dor I, Sharma A, Rogers T, et al. Micropuncture technique for femoral access is associated with lower vascular complications compared to standard needle. Catheter Cardiovasc Interv. 2021;97(7):1379–85.
[66] Sandoval Y, Burke MN, Lobo AS, et al. Contemporary Arterial Access in the Cardiac Catheterization Laboratory. JACC Cardiovasc Interv. 2017;10(22):2233–41.
[67] Potluri SP, Hamandi M, Basra SS, et al. Comparison of Frequency of Vascular Complications With Ultrasound-Guided Versus Fluroscopic Roadmap-Guided Femoral Arterial Access in Patients Who Underwent Transcatheter Aortic Valve Implantation. Am J Cardiol. 2020;132:93–9.
[68] Almendarez M, Gurm HS, Mariani J Jr, et al. Procedural Strategies to Reduce the Incidence of Contrast-Induced Acute Kidney Injury During Percutaneous Coronary Intervention. JACC Cardiovasc Interv. 2019;12(19):1877–88.
[69] Sakai K, Ikari Y, Nanasato M, et al. Impact of intravascular ultrasound-guided minimum-contrast coronary intervention on 1-year clinical outcomes in patients with stage 4 or 5 advanced chronic kidney disease. Cardiovasc Interv Ther. 2019;34(3):234–41.
[70] Delewi R, Hoebers LP, Råmunddal T, et al. Clinical and procedural characteristics associated with higher radiation exposure during percutaneous coronary interventions and coronary angiography. Circ Cardiovasc Interv. 2013;6(5):501–6.
[71] Pavlidis AN, Jones DA, Sirker A, Mathur A, Smith EJ. Reducing radiation in chronic total occlusion percutaneous coronary interventions. Curr Cardiol Rev. 2016;12(1):12–7.

[72] Balter S, Simon D, Itkin M, Granada JF, Melman H, Dangas G. Significant radiation reduction in interventional fluoroscopy using a novel eye controlled movable region of interest. Med Phys. 2016;43(3):1531–8.
[73] Kato M, Chida K, Sato T, et al. The necessity of follow-up for radiation skin injuries in patients after percutaneous coronary interventions: radiation skin injuries will often be overlooked clinically. Acta Radiol. 2012;53(9):1040–4.
[74] Yu-An W, Wen-Hwa W, Ping-Chin L, Kai-Che W. Fluoroscopy-induced radiation dermatitis: A pitfall complication of percutaneous cardiac interventions. Med Imaging Interv Radiol. 2016;2:e1415.
[75] Hall AB, Brilakis ES. Hybrid 2.0: Subintimal plaque modification for facilitation of future success in chronic total occlusion percutaneous coronary intervention. Catheter Cardiovasc Interv. 2019;93(2):199–201.
[76] Megaly M, Pershad A. Subintimal Plaque Modification and Subintimal Dissection and Reentry: Strategies to Turn Failure into Success. Interv Cardiol Clin. 2021;10(1):65–73.
[77] Yamamoto M, Tsuchikane E, Kagase A, et al. Novel proctorship effectively teaches interventionists coronary artery chronic total occlusion lesions. Cardiovasc Revasc Med. 2018;19(4):407–12.

Appendix A

Disclosures of the CTO Global Consensus Group

Funding:

This paper received no direct external funding.

Writing committee:

Dr Wu has received research funding from OrbusNeich, Asahi Intecc, Abiomed; has received consulting honoraria from Boston Scientific and Abbott Vascular; is a member of the board of directors for APCTO Club; and holds stock in Abbott Vascular.

Dr Kalyanasundaram has received fees from Abbott Vascular, Boston Scientific, Asahi Intecc, and Terumo.

Dr Brilakis has received consulting/speaker honoraria from Abbott Vascular, American Heart Association (Associate Editor, Circulation), Amgen, Asahi Intecc, Biotronik, Boston Scientific, Cardiovascular Innovations Foundation (Board of Directors), CSI, Elsevier, GE Healthcare, IMDS, Medtronic, Siemens, and Teleflex; research support from Boston Scientific, GE Healthcare; owner of Hippocrates LLC; shareholder in MHI Ventures, Cleerly Health, and Stallion Medical.

Dr Mashayekhi has received consulting, speaker, and proctoring honoraria from Abbott Vascular, Asahi Intecc, AstraZeneca, Biotronik, Boston Scientific, Cardinal Health, Daiichi- Sankyo, Medtronic, Teleflex, and Terumo.

Dr Tsuchikane is a consultant for Boston Scientific, Asahi Intecc, and Kaneka.

Other Contributors:

Dr Abi Rafeh has received speaker fees from Boston Scientific and Shockwave Medical.

Dr Agostoni – none.

Dr Alaswad – none.

Dr Araya has received honoraria from Terumo.

Dr Avran has received proctoring and consulting fees from Boston, Abbott, Terumo, Asahi, Biotronik, Medtronic, Orbus, and Alvimedica.

Dr Ayoub has received proctor, speaker and consultant fees from Boston Scientific, Terumo, Asahi and Biotronik.

Dr. Azzalini has received consulting honoraria from Abiomed, Teleflex, Abbott Vascular, Philips, Asahi Intecc, and Cardiovascular Systems, Inc.

Dr Babunashvili – none.

Dr Bayani – none.

Dr Behnes – none.

Dr Bhindi – none.

Dr Boudou has received proctoring honoraria from Terumo, Asahi Intecc, and Boston Scientific

Dr Boukhris – none.

Dr Bozinovic – none.

Dr Bryniarksi – none.

Dr Buettner – none.

Dr Bufe has received speaker honoraria from Biotronik.

Dr Buller is a Global director of Teleflex.

Dr Burke holds shares in MHI Ventures and Egg Medical.

Dr Cardoso – none.

Dr Carlino – none.

Dr Chan CK – none.

Dr Chen – none.

Dr Christiansen – none.

Dr Colombo – none.

Dr Croce is a consultant for Abbott, BSCI, CSI, Philips, Abiomed, Cordis, Biotronik. Equity Dyad Med, and East End Med.

Dr Damas de los Santos has received proctor, speaker and consultant fees from Boston Scientific, Terumo, Abbott Vascular, and Biotronik.

Dr de Martini has received proctor honoraria from Boston Scientific and Asahi, and Speaker fees for Abiomed, and Boston Scientific.

Dr Dens has received consultancy contracts with Abbott, Boston Scientific, IMDS, Terumo, and Topmedical (a distributor for Asahi), and has received proctoring fees for Boston Scientific, and Topmedical.

Dr Di Mario has received research grants from Abbott, Amgen, Behring, Daiichi-Sankyo, Edwards, Medtronic and Shockwave Medical.

Dr Doshi has received consulting fees from ACIST, Abbott Vascular, Biotronik, Boston Scientific, Cordis, Medtronic, Philips, Penumbra, and Shockwave.

Dr Dou – none.

Dr Egred has received honoraria, proctorship, or speaker's fee from: Abbott Vascular, Boston Scientific, Philips, Spectranetics, Volcano, Vascular Perspective, Merrill, Svelte, EPS Medical, and AstraZeneca.

Dr Elbarouni – none.

Dr ElGuindy has received honoraria from:Medtronic, Boston Scientific, Asahi Intecc, and Abbott; Proctorship fees from: Medtronic, Boston Scientific, Asahi Intecc, and Terumo; Educational grants from: Medtronic.

Dr Escaned – none.

Dr Furkalo – none.

Dr Gagnor – none.

Dr Galassi – none.

Dr Garbo has received proctorship and speaker fee for Abbott, Kardia Asahi, Boston Scientific, iVascular, IMDS, Philips, Teleflex, and Terumo.

Dr Gasparini – none.

Dr Ge J – none.

Dr Ge L – none.

Dr Goel – none.

Dr Goktekin – none.

Dr Gonzalo has received speaker and consultancy fees from Abbott, Boston Scientific, and Philips.

Dr Gorgulu has received consulting, speaker, and proctoring honoraria from Boston Scientific.

Dr Grancini – none.

Dr Hall has received speaker honoraria from Medtronic, OpSens Medical, Teleflex, and the Cardiovascular Innovations Foundation.

Dr Hanratty has received honoraria from Boston Scientific, Abbott, and Medtronic.

Dr Harb has received Consultant and speaker fee from Medtronic, Terumo, Shockwave Medical, Biotronik, Cordis, Cardinal Health, and CSI.

Dr Harding has received Speaking and proctoring honoraria from Boston Scientific, Abbott Vascular, Bio-Excel, Terumo Medical Corporation, and research grant from Asahi Intecc.

Dr Hatem has received speaker fees from Abbott, Boston Scientific, and Teleflex.

Dr Hellig has received proctoring fees from Boston Scientific, Asahi Intec, and Teleflex.

Dr Henriques – none.

Dr Hildick-Smith – none.

Dr Hill has received consulting, speaker, and proctoring honoraria from Abbott Vascular, Abiomed, Boston Scientific, and Shockwave.

Dr Hoye has received speaker fees from AstraZeneca, and Sanofi.

Dr Jaber has received consultation fees and educational institutional grants from Medtronic, and Proctoring fees from Abbott, and has equity in Traverse Medical. Dr Jaffer has received sponsored research support from Canon, Siemens, Teleflex, Shockwave, Amarin, Mercator, and Boston Scientific; and is a consultant/speaker for Boston Scientific, Biotronik, Siemens, Magenta Medical, Asahi Intecc, IMDS, and Philips. FAJ has equity in Intravascular Imaging, Inc. and DurVena, Inc. Massachusetts General Hospital has a patent licensing arrangement with Terumo, Canon, and Spectrawave.

Dr Jang – none.

Dr Jussila – none.

Dr Kalnins – none.

Dr Kalra has received proctor, speaker's fees, and he is an advisory board member for Boston Scientific, Abiomed Inc, Cardiovascular Systems Inc, Philips Healthcare, and Translumina Therapeutics.

Dr Kandzari has received Institutional research/grant support: Boston Scientific, Cardiovascular Systems, Inc., Teleflex, Biotronik, Terumo, and Medtronic. Personal consulting honoraria: Cardiovascular Systems, Inc., Medtronic, Teleflex, and Terumo.

Dr Kao – none.

Dr Karmpaliotis has received honoraria from Abbott Vascular, and Boston Scientific, and holds shares in Saranas, Soundbite, and Traverse Vascular.

Dr Kassem – none.

Dr Kearney has consulting fees from Abiomed, Abbott, Medtronic, Boston Scientific, Teleflex and is on the advisory board: Philips, Teleflex, and Boston Scientific.

Dr Kerrigan has received Consultant fees from Abiomed, Cordis, Boston Scientific, Ischemaview, Osprey Medical, Penumbra, and Philips; and speaker fees: Asahi, Penumbra, and Philips; and serves on Advisory Boards: Biotronik, and Philips.

Dr Khatri has received Proctor and Speakers Bureau from Boston Scientific, Abbott, Terumo, and Medtronic.

Dr Khelimskii – none.

Dr Kirtane has received Institutional funding to Columbia University and/or Cardiovascular Research Foundation from Medtronic, Boston Scientific, Abbott Vascular, Amgen, CSI, Philips, ReCor Medical, Neurotronic, Biotronik, Chiesi, Bolt Medical, Magenta Medical, Canon, and SoniVie. In addition to research grants, institutional funding includes fees paid to Columbia University and/or Cardiovascular Research Foundation for consulting and/or speaking engagements in which Dr Kirtane controlled the content. Personal: Consulting from IMDS; Travel Expenses/Meals from Medtronic, Boston Scientific, Abbott Vascular, CSI, Siemens, Philips, ReCor Medical, Chiesi, OpSens, Zoll, and Regeneron.

Dr Knaapen – none.

Dr Kornowski – none.

Dr Krestyaninov – none.

Dr Kumar G – none.

Dr Kumar P – none.

Dr Lamelas has received proctoring fees from Boston Scientific, Edwards Lifesciences, and Medtronic.

Dr Lee – none.

Dr Lefevre has received honoraria from Terumo, Boston Scientific, and Abbott.

Dr Leigundgut – none declared.

Dr Leung R – none.

Dr Leung SK – none.

Dr Li Yu has received speaker fees from Boston Scientific, Medtronic, Asahi Intec, AstraZeneca, Sanofi, APT Medical and Terumo.

Dr Li Yue – none.

Dr Lim has received educational support and honoraria from Asahi Intecc, Boston Scientific, Abbott Vascular, Kaneka, Biotronik, Alvimedica, Terumo, Medtronic.

Dr Lo has received speaking and proctoring honoraria from Abiomed, Bio-Excel, Boston Scientific, Abbott, Terumo, and member of Medtronic, Abbott, and Edwards advisory board.

Dr Lombardi – none

Dr Maran has received speaker or consultant honoraria from Boston Scientific, Medtronic, Phillips, CSI, Shockwave.

Dr McEntegart has received Honoraria - Abbott Vascular, Boston Scientific, Medtronic, Shockwave Medical, Teleflex

Dr Moses has received funding from Orchestra Biomedical and Ostial Corporation.

Dr Munawar-none.

Dr Nagamatsu has received consultant honoraria from Asahi Intecc, Abbott Vascular Japan.

Dr Navarro – none.

Dr Ngo – none.

Dr Nicholson has received consultant and speaker fees from Abbott, Abiomed, Boston Scientific and Medtronic.

Dr Oksnes has received proctor honoraria from Boston scientific and speaker fee from Shockwave medical.

Dr Olivecrona – none.

Dr Padilla has received proctor and consultant fee from Boston Scientific.

Dr Patel has received consultant fees from Abbott, Terumo, and Chiesi, and is a proctor for Medtronic.

Dr Pershad – none.

Dr Postu has received consultant fees from Medtronic and proctor for Boston Scientific.

Dr Pyxaras – none.

Dr Qian – none.

Dr Quadros has received research grant from Boston Scientific and APT Medical and Speakers honoraria from APT Medical and Teleflex.

Dr Quesada has received proctoring honoraria from Boston Scientific.

Dr Ramunddal has received Consultant and proctoring honoraria received from Boston Scientific, Abbott and EPS Vascular.

Dr Rao – none.

Dr Rathore – none.

Dr Reifart – none.

Dr Riley has received honoraria from Boston Scientific, and Shockwave Medical.

Dr Rinfret – none.

Dr Saghatelyan has received proctoring and Speaker Honoraria from Asahi Intecc, and Terumo.

Dr Santiago has received proctoring/speaker/consultant honoraria from Boston Scientific, Abbott Vascular, Medtronic, and Teleflex.

Dr Seth has received honoraria/Speaker Bureau of Abbott Vascular, Boston Scientific & Medtronic and Advisory Board Member of Meril Lifesciences & SIS Medical.

Dr Sianos – none.

Dr Smith has received honoraria and proctoring fees from Abbott Vascular, Boston Scientific and Teleflex.

Dr Spaedy has received consulting fees from Medtronic and speaking and proctoring fees from Boston Scientific and Abbott Vascular.

Dr Spratt – none.

Dr Stone has received Speaker honoraria from Medtronic, Pulnovo, Infraredx; consultant to Valfix, TherOx, Robocath, HeartFlow, Ablative Solutions, Vectorious, Miracor, Neovasc, Abiomed, Ancora, Elucid Bio, Occlutech, CorFlow, Apollo Therapeutics, Impulse Dynamics, Vascular Dynamics, Shockwave, V-Wave, Cardiomech, Gore, Amgen; equity/options from Ancora, Cagent, Applied Therapeutics, Biostar family of funds, SpectraWave, Orchestra Biomed, Aria, Cardiac Success, Valfix, Xenter. Institutional disclosure: Dr. Stone's employer, Mount Sinai Hospital, receives research support from Abbott, Bioventrix, Cardiovascular Systems Inc, Phillips, Biosense-Webster, Shockwave, Vascular Dynamics, and V-wave. Dr. Stone's daughter is an employee at Medtronic.

Dr Strange – none.

Dr Tammam – none.

Dr Thompson has received Consultant Teleflex, Asahi, Medtronic (Education).

Dr Toma – none.

Dr Tremmel has received honoraria from Abbott Vascular for consulting, speaking, and advisory board participation, and from Boston Scientific for consulting, speaking, advisory board participation, and research funding.

Dr Ungi – none.

Dr Vadalà – none.

Dr Vo – none.

Dr Vu – none.

Dr Walsh is an employee of Boston Scientific.

Dr Weilenmann has received consulting honoraria from Abbott, Biotronik, Boston Scientific, SIS Medical, Terumo, Vascular Medical (Asahi).

Dr Werner has speaker fees: ASAHI Intecc, Biotronik, Bayer, Philips-Volcano, Shockwave, Siemens, Terumo

Dr Wojcik – none.

Dr Wollmuth has received advisory board, consultant, speaker's bureau from Abiomed, advisory board, consultant, speaker's bureau, proctor from Abbott and Boston Scientific, Proctor fees from Asahi, consultant fees from Cardiovascular Systems Inc, and speaker's bureau from Medtronic and Biotronik.

Dr Wu CJ – none.

Dr Xu – none.

Dr Yamane – none.

Dr Ybarra has received consulting and speaker fees from Abbott Vascular Canada.

Dr Yeh has received research grants from Abbott Vascular, AstraZeneca, Cook, BD Bard, Boston Scientific, Medtronic, and Phillips; and is a consultant for Abbott Vascular, AstraZeneca, Boston Scientific, Edwards LifeSciences, Medtronic, Shockwave Medical, and Zoll.

Dr Zambakides – none.

Dr Zhang – none.