



Contents lists available at ScienceDirect

International Journal of Surgery Case Reports

journal homepage: www.casereports.com

Single staged hybrid approach for multilevel aortic-iliac-femoral-popliteal disease

Ettore Dinoto^{a,*}, Felice Pecoraro^{a,b}, Andrea Cutrupi^a, Umberto M. Bracale^c, Marco Panagrosso^c, Guido Bajardi^{a,b}

^a Vascular Surgery Unit - AOUP Policlinico 'P. Giaccone', Palermo, Italy

^b Department of Surgical, Oncological and Oral Sciences, University of Palermo, Italy

^c Department of Public Health, Vascular Surgery Unit, University Federico II of Naples, Naples, Italy

ARTICLE INFO

Article history:

Received 22 June 2020

Received in revised form 3 September 2020

Accepted 3 September 2020

Available online 22 September 2020

Keywords:

Hybrid procedure

Peripheral arterial disease

Revascularization

Endovascular

Case report

ABSTRACT

INTRODUCTION: Multilevel peripheral arterial disease (MPAD) is the main cause of critic limb ischemia (CLI). Vascular interventions are required to increase distal blood flow and reduce the risk of lower limb amputation.

PRESENTATION OF CASE: We report a case of complex hybrid revascularization in a patient presenting a Rutherford V MPAD involving the infrarenal aorta, iliac, femoral and popliteal segments. The simultaneous hybrid intervention consisted of an endovascular aortic stent-graft placement and a surgical above-the-knee prosthetic femoro-popliteal bypass. In the same operation a renal stenting was performed due to a significant renal artery stenosis associated to a systemic hypertension non-responder to medical management.

DISCUSSION: Hybrid interventions can be performed simultaneously or staged with benefit given by the complementary role of endovascular and surgical treatments allowing the correction of eventually inadequate results of both approaches. Reports of simultaneous hybrid treatments are limited but, despite the complexity of such procedures, primary success rate is reported high. Also in the reported case, a complex simultaneous treatment in a patient presenting MPAD in association to a significant and symptomatic renal artery disease was feasible in the same operation.

CONCLUSION: Hybrid procedure are safe with high degree of efficacy in terms of revascularization procedure, reduced morbidity and shorter intensive care and hospital stay. In our experience, the use of hybrid procedure is technically feasible and allowed the treatment of MPAD with a good outcomes.

© 2020 The Author(s). Published by Elsevier Ltd on behalf of IJS Publishing Group Ltd. This is an open access article under the CC BY-NC-ND license (<http://creativecommons.org/licenses/by-nc-nd/4.0/>).

1. Introduction

Multilevel peripheral arterial disease (MPAD) in diabetic patients is a significant cause of amputation. After major lower amputation a significant reduction in the cumulative mortality rate is reported with an incidence of 30.7% at 1 year [1]. Vascular interventions are required to increase blood flow into extremities in order to enhance cutaneous oxygen pressure promoting wound healing [2]. In case of MPAD extensive revascularizations have been advocated as determinant to reduce the risk of amputation. Herein we report a case of diabetic patient affected by critic limb ischemia Rutherford V presenting extensive MPAD addressed by hybrid procedure. In this case we have chosen a hybrid procedure. In fact, the

use of a pure surgical technique or the only endovascular approach not would allow to achieve the best outcome.

This work has been written in accordance with the SCARE criteria [3].

2. Case report

A 71-years-old man with history of hypertension, uncontrolled diabetes mellitus, active smoker (2 pkg per day) was referred to our hospital for right critic limb ischemia Rutherford V (calcaneal and posterior leg ulcers). At history he referred progressing pain in right leg from six months, he referred to be in treatment for diabetes and hypertension. The patient denied any previous family history of similar pathology. On physical examination his systemic blood pressure was 160/90 mmHg with 87 bpm. Abdomen auscultation revealed a mesogastric systolic bruit. Electrocardiogram confirmed signs of previous anterior myocardial infarction.

Laboratory exams showed an eGFR of 62.4. Duplex ultrasound (DUS) showed widespread irregularities of infrarenal aortic wall

* Corresponding author at: Vascular Surgery Unit, AOUP Policlinico 'P. Giaccone', Via Liborio Giuffrè, 5, Palermo, Italy.
E-mail address: ettoredinoto@gmail.com (E. Dinoto).

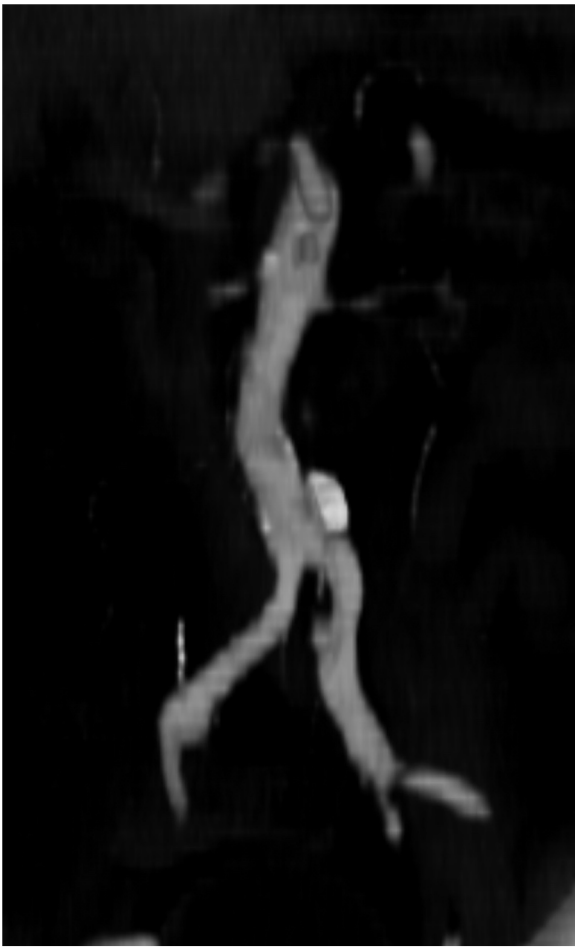

Fig. 1. Preoperative CT-angiography showing significant atherosclerotic disease in correspondence of the infrarenal aortic segment and right renal artery.

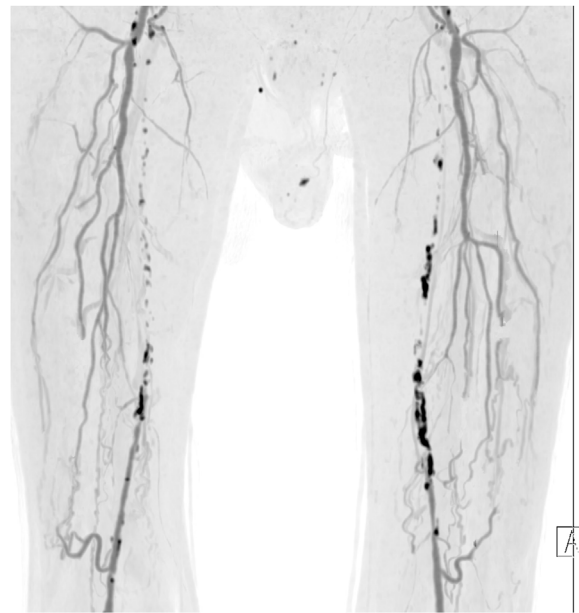


Fig. 2. Preoperative CT maximum intensity projection showing atherosclerotic occlusion of the bilateral femoro-popliteal segments.

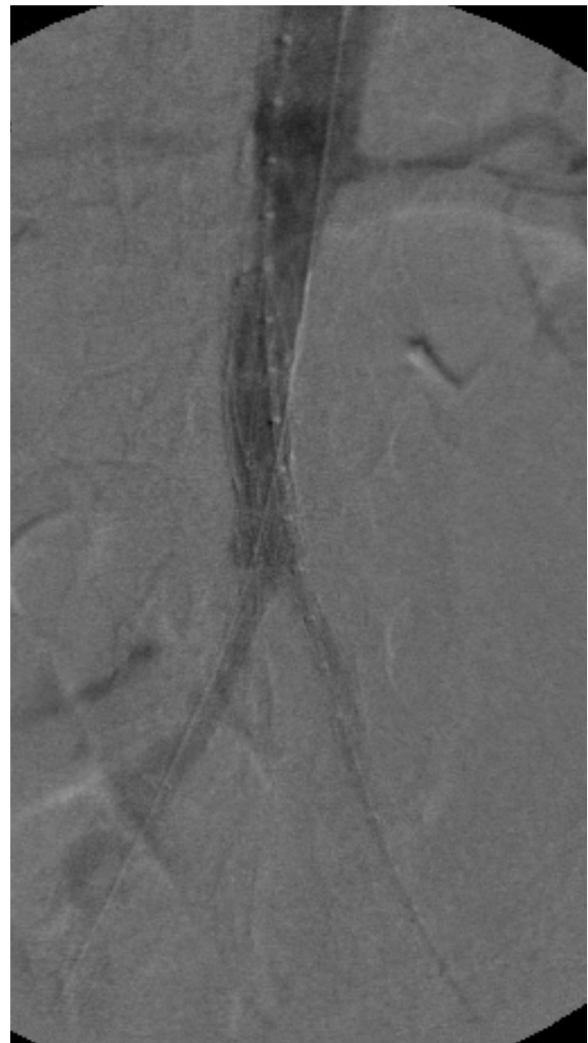

Fig. 3. Completion intraoperative angiography showing the correct positioning and patency of the aortic stent-graft.

with narrowing residual lumen and monophasic wave on both iliac-femoral axes. CT angiography confirmed the atherosclerotic disease in the aortic carrefour with local dissection and significant stenosis on both origins of common iliac arteries (Fig. 1); furthermore, superficial femoral arteries were bilaterally occluded and non-significant stenosis in correspondence of both popliteal arteries (Fig. 2). A significant left renal artery stenosis was also reported.

The reduced blood flow in the right leg and foot was identified as the main cause of patient clinical conditions. A simultaneous multilevel hybrid treatment was proposed to address simultaneously the MPAD.

In our vascular operating room, after spinal anesthesia, the hybrid approach consisted of a first step with implantation of an AFX aortic endograft (Endoogix Inc., Irvine, CA, USA) to address the aorto-iliac disease. The left renal artery stenosis was also addressed by placing a 5 × 15 mm Hippocampus (Medtronic, Dublin, Ireland) renal stent (Fig. 3).

Subsequently a prosthetic right femoro-popliteal above-the-knee bypass using an 8-mm PTFE graft was performed to provide direct flow in the right foot. After intervention a direct blood flow was registered in the right dorsalis pedis on DUS. On second post-operative day the patient was asymptomatic for pain with normalization of blood pressure values, and disappearance of mesogastric systolic bruit. The patient was discharged after a week with double antiplatelet therapy. The 2-months follow-up CT angiography confirmed correct abdominal aortic stent-graft with maintained good patency of renal stent and femoro-popliteal

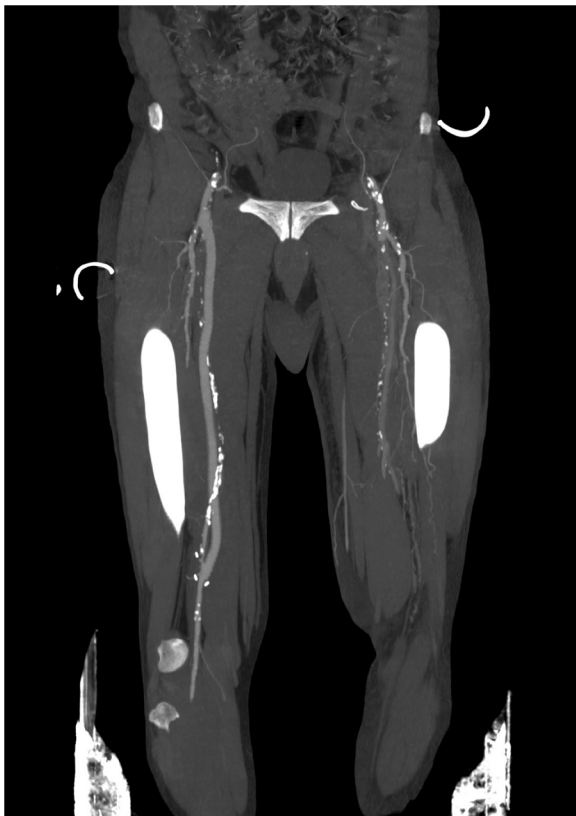

Fig. 4. Postoperative CT maximum intensity projection showing maintained patency of the femoro-popliteal bypass.

bypass (Fig. 4). The clinical examination showed the complete ulcers healing.

3. Discussion

MPAD is a common finding in patients presenting CLI. Addressing multiple atherosclerotic lesions is advocated as determinant to achieve successful clinical improvements [4]. Extensive and complex surgical approach is still indicated in MPAD but endovascular solutions have been reported to reduce the invasiveness of conventional surgery [5]. However, the endovascular approach is often technically inadequate to address simultaneously MPAD. As reported in this case, hybrid treatments represent a valuable option in patients considered at high risk for conventional surgery [6]. In fact, it has been reported that up-to 5–20% of peripheral vascular intervention are performed using a hybrid approach combining an endovascular and an open approach [7].

Hybrid interventions can be performed simultaneously or staged however reported advantages of a simultaneous approach have been identified as a) the absence of delay; b) the complementary role of endovascular and surgical approach allow the correction of eventually inadequate results; c) the endovascular access is gained from a surgical exposed vessel; d) the risk of infection is limited to a single intervention; e) medical therapy does not need adjustment during the interval between the staged interventions; f) hospitalization is reduced to a single intervention; g) intraoperative angiography allows the control of surgical procedures [8,9].

Although reports of simultaneous hybrid treatments are limited [10], in literature primary success rates are high (93–100%). Also long-term results have been shown to be comparable to open surgical procedures, with lower or equal morbidity and mortality rates and with primary patency rates of 60%–91% [11]. Technical aspects regarding target vessel recanalization, wire and catheter place-

ment, stent placement and the timing or order of an endovascular and open procedure usually involve femoral endarterectomy and patching with iliac stenting. Most reports favour pre-arteriotomy guidewire placement, followed by femoral endarterectomy and iliac balloon angioplasty and stenting. The stent materials and brands used vary in all of the reports and reflect the complex and versatile nature of vascular disease [10,12].

Also in our experience the involvement of the common femoral artery impairment represents a determinant for operative strategy.

4. Conclusions

The reduced invasiveness of hybrid procedures determined an increased use in patients presenting multilevel vascular disease and considered at high risk for conventional surgery. Hybrid procedure outcomes seem to be as good as with open revascularization, but with less morbidity and shorter intensive care and hospital stay. Also in our experience, the use of hybrid procedure was safe and technically feasible and allowed the treatment of multilevel peripheral arterial disease with good outcomes.

Declaration of Competing Interest

None.

Funding

None.

Ethical approval

None.

Consent

Not Applicable.

Author contribution

Ettore Dinoto: study concept, design, data collection, data analysis, interpretation, writing the paper, final approval of the version to be submitted.

Felice Pecoraro: study concept, design, data collection, data analysis, interpretation, writing the paper, final approval of the version to be submitted.

Andrea Cutrupi: study concept, design, data collection, final approval of the version to be submitted.

Marco Panagrosso: study concept, design, data collection, final approval of the version to be submitted.

Umberto Marcello Bracale: study concept, design, data collection, final approval of the version to be submitted.

Guido Bajardi: study concept, design, data collection, data analysis, interpretation, final approval of the version to be submitted.

Registration of research studies

Not Applicable.

Guarantor

Ettore Dinoto.

Provenance and peer review

Not commissioned, externally peer-reviewed.

Transparency document

The [Transparency document](#) associated with this article can be found in the online version.

Acknowledgement

This article is part of a supplement entitled Case reports from Italian young surgeons, published with support from the Department of Surgical, Oncological and Oral Sciences – University of Palermo.

References

- [1] E. Dinoto, F. Pecoraro, D. Mirabella, F. Ferlito, A. Farina, N. Lo Biundo, et al., A single-center experience on below-the-knee endovascular treatment in diabetic patients, *Transl. Med. UniSa* 21 (April) (2020) 21–23.
- [2] U.M. Bracale, R.P. Ammollo, E.A. Hussein, J.J. Hoballah, O. Goeau-Brissonniere, M. Taurino, et al., Managing peripheral artery disease in diabetic patients: a questionnaire survey from vascular centers of the Mediterranean Federation for the advancing of vascular surgery (MeFAVS), *Ann. Vasc. Surg.* 64 (April) (2020) 239–245.
- [3] R.A. Agha, M.R. Borrelli, R. Farwana, K. Koshy, A. Fowler, D.P. Orgill, For the SCARE Group, The SCARE 2018 statement: updating consensus surgical CAse REport (SCARE) guidelines, *Int. J. Surg.* 60 (2018) 132–136.
- [4] U.M. Bracale, G. Vitale, G. Bajardi, D. Narese, E. Dinoto, A.M. Giribono, et al., Use of the directional atherectomy for the treatment of femoro-popliteal lesions in patients with critical lower limb ischemia, *Transl. Med. UniSa* 15 (November) (2016) 42–47.
- [5] U.M. Bracale, G. Corte, L. Del Guercio, F. Pecoraro, E. Dinoto, G. La Rosa, et al., Endovascular treatment of abdominal aortic anastomotic pseudoaneurysm. The experience of two centers, *Ann. Ital. Chir.* 83 (December(6)) (2012) 509–513.
- [6] W.S. Jones, X. Mi, L.G. Qualls, S. Vemulapalli, E.D. Peterson, M.R. Patel, et al., Trends in settings for peripheral vascular intervention and the effect of changes in the outpatient prospective payment system, *J. Am. Coll. Cardiol.* 65 (March (9)) (2015) 920–927.
- [7] P.R. Nelson, R.J. Powell, M.L. Schermerhorn, M.F. Fillinger, R.M. Zwolak, D.B. Walsh, et al., Early results of external iliac artery stenting combined with common femoral artery endarterectomy, *J. Vasc. Surg.* 35 (June (6)) (2002) 1107–1113.
- [8] F. Pecoraro, G. Bajardi, E. Dinoto, G. Vitale, M. Bellisi, U.M. Bracale, Endograft connector technique to treat popliteal artery aneurysm in a morbid obese patient, *Vascular* 23 (April (2)) (2015) 165–169.
- [9] P. Balaz, S. Rokosny, J. Bafnec, M. Björck, The role of hybrid procedures in the management of peripheral vascular disease, *Scand J Surg SJS Off Organ Finn Surg Soc Scand Surg Soc.* 101 (4) (2012) 232–237.
- [10] P.-S. Aho, M. Venermo, Hybrid procedures as a novel technique in the treatment of critical limb ischemia, *Scand. J. Surg. SJS Off. Organ Finn Surg. Soc. Scand. Surg. Soc.* 101 (2) (2012) 107–113.
- [11] H.H. Dosluoglu, P. Lall, G.S. Cherr, L.M. Harris, M.L. Dryjski, Role of simple and complex hybrid revascularization procedures for symptomatic lower extremity occlusive disease, *J. Vasc. Surg.* 51 (June(6)) (2010) 1425–1435.e1.
- [12] R.W. Chang, P.P. Goodney, J.H. Baek, B.W. Nolan, E.M. Rzucidlo, R.J. Powell, Long-term results of combined common femoral endarterectomy and iliac stenting/stent grafting for occlusive disease, *J. Vasc. Surg.* 48 (August (2)) (2008) 362–367.

Open Access

This article is published Open Access at [sciencedirect.com](https://www.sciencedirect.com). It is distributed under the [IJSCR Supplemental terms and conditions](#), which permits unrestricted non commercial use, distribution, and reproduction in any medium, provided the original authors and source are credited.