



**Citation:** Cicero Moraes, Michael E. Habicht, Francesco M. Galassi, Elena Varotto, Thiago Beaini (2023) Pharaoh Tutankhamun: a novel 3D digital facial approximation. *Italian Journal of Anatomy and Embryology* 127(1): 13-22. doi: 10.36253/ijae-14514

**Copyright:** © 2023 Cicero Moraes, Michael E. Habicht, Francesco M. Galassi, Elena Varotto, Thiago Beaini. This is an open access, peer-reviewed article published by Firenze University Press (<http://www.fupress.com/ijae>) and distributed under the terms of the Creative Commons Attribution License, which permits unrestricted use, distribution, and reproduction in any medium, provided the original author and source are credited.

**Data Availability Statement:** All relevant data are within the paper and its Supporting Information files.

**Competing Interests:** The Author(s) declare(s) no conflict of interest.

## Pharaoh Tutankhamun: a novel 3D digital facial approximation

CICERO MORAES (BSC PHD H.C.)<sup>1</sup>, MICHAEL E. HABICHT (PHD)<sup>2</sup>, FRANCESCO M. GALASSI (MD PHD)<sup>3,\*</sup>, ELENA VAROTTO (PHD)<sup>3</sup>, THIAGO BEAINI (PHD)<sup>4</sup>

<sup>1</sup> Arc-Team Brazil, Sinop-MT, Brazil

<sup>2</sup> College of Humanities, Art and Social Sciences, Flinders University, Adelaide-SA, Australia

<sup>3</sup> Forensic Anthropology, Paleopathology and Bioarchaeology (FAPAB) Research Center, Avola, Italy

<sup>4</sup> Faculty of Dentistry, Federal University of Uberlândia, Uberlândia-MG, Brazil

\*Corresponding author. E-mail: francescom.galassi@fapab.com

**Abstract.** This article offers a novel and original facial reconstruction of pharaoh Tutankhamun based on data published in the biomedical and Egyptological literature. The reconstruction adopts the Blender 3D software, running the add-on OrtogOnBlender, which allows for a refined presentation of the soft tissues. The present reconstruction is also compared to other approaches produced in the past.

**Keywords:** anatomy, anthropology, facial reconstruction, 3D, endocast, palaeoradiology, pharaoh, Tutankhamun.

### INTRODUCTION

Born Tutankhaten (the living image of Aten) in ca. 1325 BC, in the 11<sup>th</sup> year of the reign of Pharaoh Akhenaten, his probable father, succeeded him under the name “Tutankhamun” at the age of 9, until his death approximately a decade later (Hawass & Saleem, 2016). His reign took place during the 18<sup>th</sup> Dynasty, between the years 1333/1336/1356 BC-1324/1327/1346 BC (Hawass et al., 2010, Hawass & Saleem, 2011, Rühli & Ikram, 2014). Still young he may have married his half-sister Ankhesenamun with whom he supposedly had two stillborn fetuses, one at 5-6 and the other at 9 months of gestation, both mummified and present in his tomb, KV62, found by the British Egyptologist Howard Carter (1874-1939) in 1922 in the Valley of the Kings, Egypt (Hawass et al., 2010, Hawass & Saleem, 2011, Rühli & Ikram, 2014, Hussein et al., 2013).

From the first autopsy, performed in 1925 to the present, the life and death of the young pharaoh have been shrouded in mystery, doubt, and speculation (Derry 1927). A series of hypotheses were raised about the pharaoh's state of health, some with more robust evidence, such as a diagnosis of malaria and Köhler's disease that could have contributed to the death of

the young man (Hawass & Saleem, 2016, Hawass et al., 2010), to others with less to no hard anatomo-pathological evidence such as murder due to brain injury, gyne-comastia, Fröhlich Syndrome, Antley Bixler Syndrome, Marfan Syndrome and even an occasional hippopotamus attack (Rühli & Ikram, 2014, Hussein et al., 2013). More complex familial neurological conditions have also been hypothesised linking, in particular, Akhenaten and Tutankhamun (Ashrafian, 2012).

When he carried out the first analysis on Tutankhamun's body, Howard Carter did not indicate what could be the cause of the pharaoh's death: it was only in 1968 that the first X-ray images were made on that body, revealing more data and along with these, also new speculations, such as the one that attributed the death to a possible blow to the head (Boyer et al., 2003). It was then in 2005 that a computed tomography scan was performed on the body, bringing more internal structural information and, once again, highlighting the debate about the findings, since, if on the one hand the team agreed on the exclusion of the assassination hypothesis, on the other hand there was no consensus about a possible knee fracture that could have been caused in a time near Tutankhamun's death (Guardians, 2005a). In 2010, a new study, this time with the DNA of some pharaohs and family members, brought new information about the health status and potential family ties between these individuals. Thanks to this study, it was known, for example, that Tutankhamun suffered from malaria and Köhler's disease and that he was closely related to Akhenaten (KV55) and to the two fetuses found in his tomb (Hawass et al., 2010).

#### THE FACIAL APPROXIMATIONS OF TUTANKHAMUN (1983-2022)

Because he is a historical figure of great notoriety, Tutankhamun's facial appearance (Fig. 1) has always been a matter of general interest, even more so because of his possible familial relation to Akhenaten, known for breaking with the old religious and artistic tenets of ancient Egypt, which causes fascination and perplexities on the part of scholars and the general public, raising hypotheses ranging from the aforementioned syndromes and conditions linked to endogamy, to sensationalist, unscientific extrapolations.

Precisely because of this popularity, the pharaoh's face has been the target of a series of facial approximations using forensic techniques over the last few decades. In 1983, forensic artist Betty Pat Gatliff (1930-2020) reconstructed Tutankhamun's face from a plaster skull

moulded from radiographs taken of the skull by physical anthropologist Joe Young. The face was revealed during a meeting of the Miami Society of Egyptology and published in *Life magazine* in June of that year (Sandomir, 2020, Taylor, 2001).

In 2005 the then Secretary General of the Supreme Council of Antiquities of Egypt, Dr. Zahi Hawass, presented to the world the result of the work coordinated with three teams that individually developed three facial reconstructions of Tutankhamun, based on the segmented skull from the computed tomography that had been carried out that same year. The Egyptian group was led by biomedical engineer Khaled Elsaïd, who performed the reconstruction digitally with the aid of a 3D editor and was aware of the pharaoh's identity. The French team, on the contrary, was led by forensic specialist Jean-Noel Vignal and the face was modelled analogously by anthropological sculptor Elisabeth Daynes. Both also knew that it was the young pharaoh, while the American team, made up of physical anthropologist Susan Antón and forensic sculptor Michael Anderson, carried out the work completely blindly, without knowing who it was and generating, like the French team, an analogue sculpture of the face. Even though there were slight variations between the faces, the final result was very pleasing to Dr. Hawass, in his own words: "*In my opinion, the shape of the face and skull are remarkably similar to a famous image of Tutankhamun as a child, where he is shown as the sun god at dawn rising from a lotus blossom*" (Guardians, 2005b).

Furthermore, Pausch and colleagues created a bidimensional facial approximation of the profile of Tutankhamun performed from X-ray images, with the aid of the MorphMan 4.0 software (Pausch et al., 2015).

Finally, in the year 2022, Andrew Nelson, segmented and printed the skull of Tutankhamun, based on his computed tomographic scans, passing it on to the sculptor Christian Corbet so that he could proceed with the analogue facial reconstruction. The work was presented in December of that year and served as the basis for a documentary made by the North American broadcaster PBS (Havis & Murray, 2022).

#### MATERIALS AND METHODS

Biological anthropology is the branch of science that aims to study humankind and its biological characteristics. Primarily performed on real anatomical specimens, in recent decades it has been possible to act on volumetric digital records or images. Current technology allows producing three-dimensional material from photographs

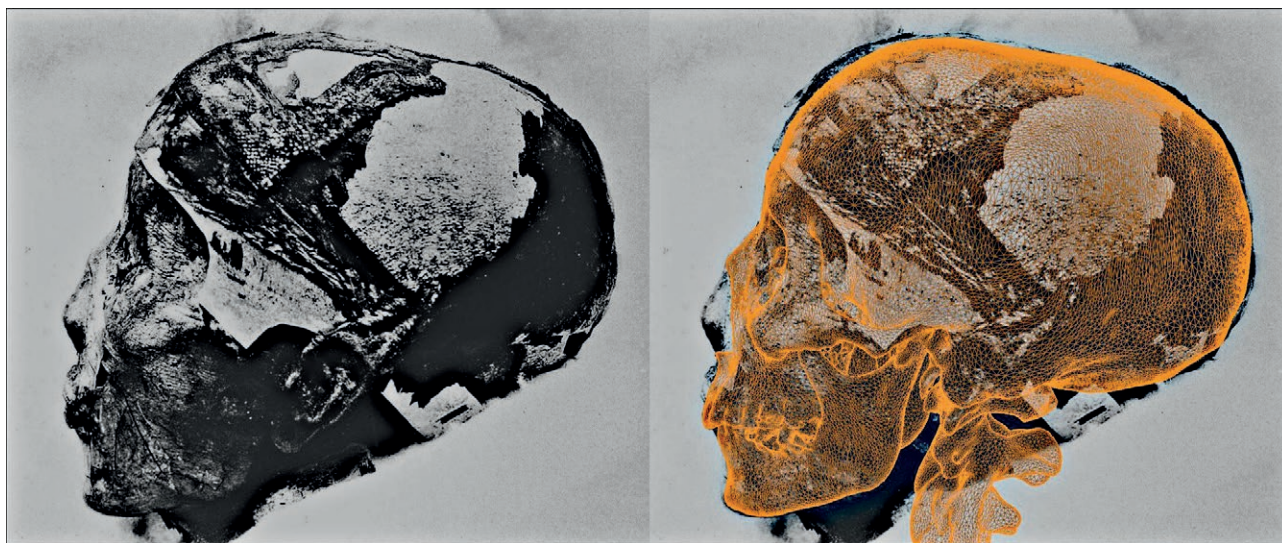
and bidimensional images of CT scans, which significantly increases the possibilities of analysis. Therefore, none of the conclusions of this article are final and are intended only to present the techniques used, as well as to foster new questions about this person of unique historical importance. For this, the analysis by digital deformation of a skull with characteristics similar to those recorded by the Pharaoh are proposed, a facial approximation using forensic techniques was also performed, and analyses of the peculiar characteristics of the shape of this skull, as well as an approach regarding the brain capacity estimated by the volume of the skull were made. Facial approximation is an auxiliary facial recognition technique that uses the skull as a basis to approximate the face of the individual in life. The history of this technique has always been shrouded in controversy (Stephan, 2003) mainly due to the difficulty in defining what is scientific (objective) and what is art (subjective) in its approach. The present work avoids the use of the term reconstruction, replacing it with another one more consistent with its reality, that is, forensic facial approximation (Stephan, 2015), or simply facial approximation (FA). It is not just a question of adapting the name, but of using complementary approaches, based on the analysis of data extracted from living individuals, as will be explained later, in order to obtain a face supported by the maximum of objective references, leaving little room for subjective interventions by the researchers.

### 3D Reconstruction of the Skull

As mentioned above, the FA technique requires a skull to be made, thus the researchers sought spatial references for it so that it could be reconstructed in 3D. The team that composed this work has a broad and long experience in the structural reconstruction of scenarios from a single photo (Moraes, 2013b) and skulls from several photos (Moraes, 2013c) or orthographic images (Moraes, 2013a). Two works carried out by the authors of this publication used skulls modelled from the intersection of two-dimensional data (photos), such as the case of the pseudo-Sophocles in 2020 (Galassi et al., 2020) and Saint Vincent de Paul in 2022 (Moraes et al., 2022a).

Seeking a more robust and reliable base to provide skull structural data, the researchers searched for articles that offered capture data from tomographic slices and skull X-rays, complemented with some anthropometric measurements. Thus, a vast collection of X-ray captures was studied in the work of Boyer et al. (2003), where proportions could be raised from semi-orthographic images, but without available scale parameters. The visual observations and measurements were adjusted by the publication of Hawass and Saleem (2016), which reported the general dimensions of the skull in the X and Y axes. The study by Habicht et al. (2021) reinforced the available measures, complementing with others, providing a general adjustment for the three axes: X, Y and Z.

Two other materials, even though they are not peer-reviewed publications, were shared by the creators who had access to the tomography performed on Tutankha-



**Figure 1.** Photograph of Tutankhamun's head (left) and 3D skull test overlay over it. Base image credit: L0019350 A mummified human skull (Creative Commons): [https://commons.wikimedia.org/wiki/File:Tutankhamun%27s\\_mummified\\_head.jpg](https://commons.wikimedia.org/wiki/File:Tutankhamun%27s_mummified_head.jpg)



mun's skull and offer potential two- and three-dimensional references to the skull. One of them is a video on YouTube ( <https://youtu.be/HKnG5W7fvTc> ) made available by Corbet where, at a given moment, it is possible to see the projection of the eyeball. Knowing that, according to Taylor (2001) the diameter of such a structure is 25 mm, it would be enough to convert the pixels into millimeters and an important measure in the X axis can be found, since the deformation of perspective does not change the measurement in that region drastically. The important measure in this case is the distance between the frontomalar orbital points (fmo-fmo). Another even more precise reference is present in an article on the PHYS.org website ( <https://bit.ly/3Bqv1W0> ) about the same approximation performed by Corbet and Nelson (Havis & Murray, 2022), where there is a screenshot with the visualisation of the pharaoh's skull in the axial, sagittal and coronal planes, accompanied by the measurements in millimeters of the frames, thus a conversion from pixels to millimeters would be enough to know the measurements of such structures.

The presence of all the aforementioned materials, formally published or not, demonstrates the abundance of data available on Tutankhamun. It is thus possible to join the fragmented data, in order to reconstruct three-dimensionally, with a good degree of compatibility with the real anatomical structures, what would be the skull of the young pharaoh.

With all the data of proportions and measurements available, a skull resulting from the CT scan of a virtual donor underwent a process known as anatomical deformation (to be explained below), so that the segmented bone structure adapted to the configurations of the skull of Tutankhamun, generating the model that would be used in the facial approximation (Fig. 1).

### 3D Facial Approximation

Forensic facial reconstruction (FFR) or forensic facial approximation (FFA), or simply facial approximation (FA) (Stephan, 2015) is an auxiliary recognition technique, which reconstructs/approximates the face of an individual from his skull and is used when there is little information for the identification of a subject (Pereira et al., 2017). It should be noted that the technique is not about identification, such as those offered by DNA or comparative analysis of dental arches, but about recognition that can lead to subsequent identification.

The present work uses the same step-by-step approach discussed in Abdullah et al. (2022), starting with the complementation of the missing regions of the skull, followed by the projection of the profile and struc-

tures of the face from statistical data, generating the volume of the face with the aid of the anatomical deformation technique and finishing with the details of the face, configuration of the hair and generation of the final images.

The modeling process was performed in Blender 3D software, running the add-on OrtogOnBlender ( [http://www.ciceromoraes.com.br/doc/pt\\_br/OrtogOnBlender/index.html](http://www.ciceromoraes.com.br/doc/pt_br/OrtogOnBlender/index.html) ) and its submodule ForensicOnBlender. The program and its add-on are free, open source and cross-platform, hence they can run on Windows ( $\geq 10$ ), MacOS ( $\geq$  BigSur) and Linux (=Ubuntu 20.04).

In the case of this work, a desktop computer with the following characteristics was used:

- Intel Core i9 9900K 3.6GHZ/16M processor; 64 GB of RAM memory
- GPU GeForce 8 GB GDDR6 256-bit RTX 2070
- Gigabyte 1151 Z390 motherboard; SSD SATA III 960 GB 2.5"
- SSD SATA III 480 GB 2.5"
- Water Cooler Masterliquid 240V
- Linux 3DCS ( <https://github.com/cogitas3d/Linux3DCS> ), based on Ubuntu 20.04.

OrtogOnBlender has cephalometry tools, for which it is necessary to distribute a series of anatomical points on the surface of the skull (S, N, A, B, t11, t21, t16, t26, Go R, Go L, Gn ans Me) and proceed with the calculation of the angles. The cephalometry chosen was that of the Universidade de São Paulo (USP) ( <https://bit.ly/3pKzP5Q> ).

## RESULTS AND DISCUSSION

The results (Table 1) suggest maxillary prognathism (class II) and mandibular retrognathism, corroborating the findings of Pausch et al. (2015).

Initially, the skull was aligned to the Frankfurt horizontal plane and received a series of projections for the middle limits of regions belonging to the bones (distance between gonions on the X axis, nasospinale point on the Z axis, position of the incisors on the Z axis and position of the chin on the Z axis) and soft tissue (eyeball positioning on the X, Y and Z axes, border of the nasal wings on the X and Z axes, lips on the X axis, eyelids on the X axis and size of the ears on the Z axis) (Moraes & Suharschi, 2022). The projections covering the orbit downwards show a lower region within the expected proportions, with the dimension on the X axis between the gonion slightly larger than the average pro-

**Table 1.** Acronyms based on craniometric points are summarised at this link: <https://bit.ly/3pKzP5Q>.

Angle	Result (°)	Observation
Maxillary occlusion	22.03	10 degrees above normal
SNA	87.91	Maxillary prognathism (Class II)
SNB	79.24	Mandibular retrognathism
ANB	8.67	Skeletal class II
SNGn	70.62	Clockwise rotation of the mandible
Mandibular plane	34.73	
SNGoGn	36.81	Vertical growth trend

portion, but still within normal limits. The positions of the average and proportion of the ns point (nasospinale) coincided with that of the skull, the incisors as well, although, in general, they projected slightly downwards, which may indicate that the teeth are slightly larger than the average and projection. The mental region was positioned a little above the markers, indicating that the mandible may be smaller than the expected average/proportional structure (Fig. 2A), such characteristics corroborate the results of the USP cephalometry. A series of 36 (18 symmetrical) soft tissue thickness markers, based on measurements performed with ultrasound in 204 adult Egyptians, were distributed on the frontal portion of the face, in order to trim the limits of the skin in such regions (Fig. 2B). For the tracing of the nose, statistical data from 110 adult individuals of various ancestries were used. A base template for the projection is available at *OrtogOnBlender/ForensicOnBlender*, based on the work of Moraes and Suharschi (2022). Once the projection of the nose was established, a profile line was drawn using the limits of the pronasal point and the soft tissue thickness markers as a reference (Fig. 2C). To cover the regions not contemplated by the soft tissue thickness markers and to complement the volumetric approximation, the mesh of a virtual donor, composed of the soft tissue, skull and endocranium, was imported and positioned in the same space as the skull of Tutankhamun (Fig. 2D). Structural deformations are performed on the mesh, in order to convert the donor's skull into the skull of the individual to be approximated: as a side effect, the soft tissue mesh also suffers such deformation, resulting in a face with the characteristics of Tutankhamun (Fig. 2E). Although the neck region did not undergo major changes, the most important part of the process generated a profile that was very compatible with the projection made from the soft tissue thickness markers and the nasal projection (Fig. 2F). As discussed in Abdullah et al. (2022), the pre-configured face of another approximated individual is imported into the scene

and deformed to fit the current face (Fig. 2G). Such a face already has hair that are adjusted according to the intended configuration (Fig. 2H) and the same applies to the material and texturing, which receives a complementary pigmentation, according to the historical data gathered and the individual's ancestry (Fig. 2I).

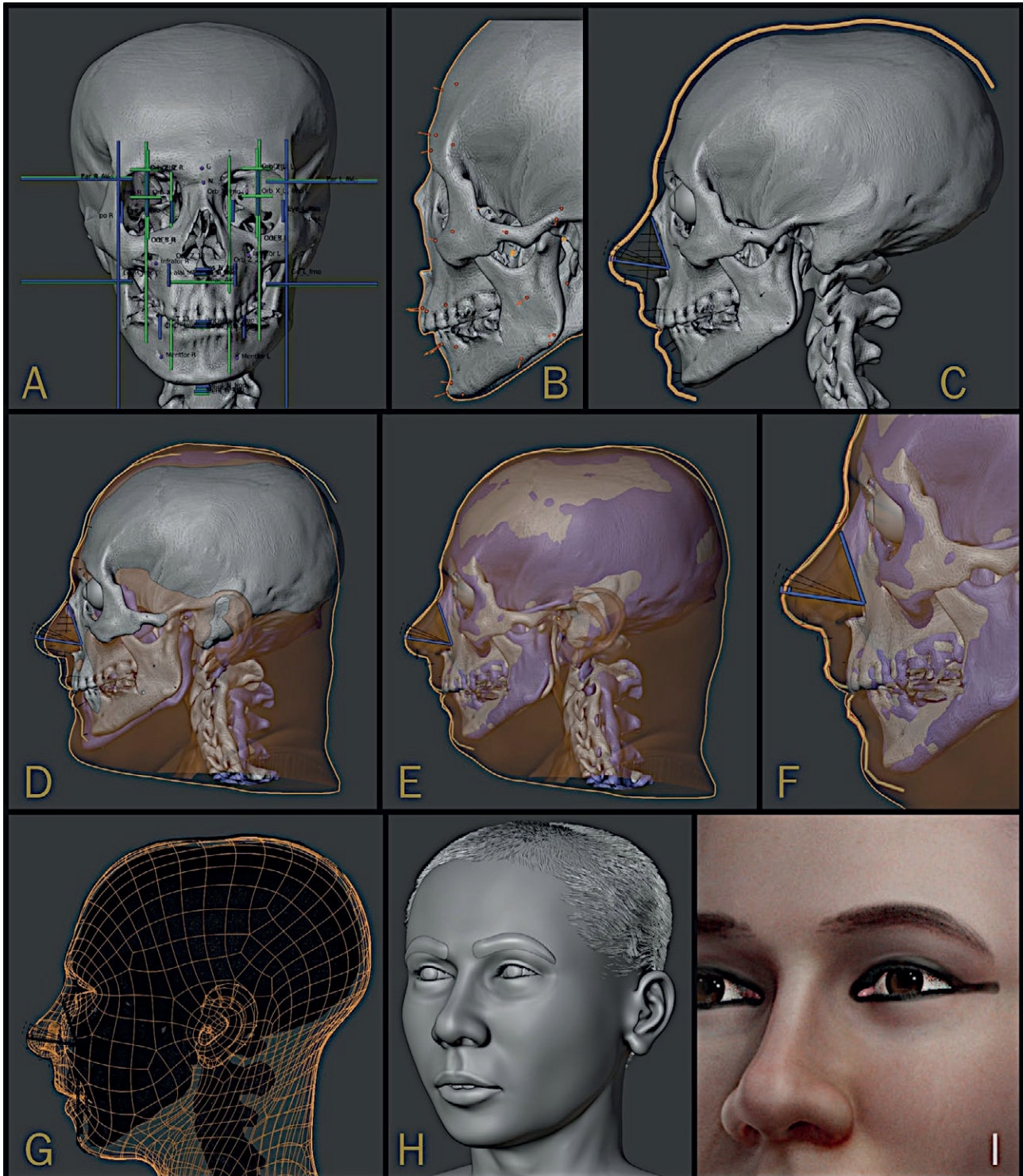
Two approaches related to facial approximation were worked on, one more objective and scientific and the other more subjective and artistic.

The scientific approach consisted of a bust equipped with elements closely linked to the statistical aspects of the approximation and, since the initial stage of the process was composed only of data collected from CT scans and measurements of living individuals and a compatible population, it was possible to generate an anatomically coherent image. In addition, to reduce the incompatibility in the region of the orbit, images were generated with closed eyes, as well as to avoid speculations about skin tone, the color chosen was the gray scale (Figs. 3-5).

The most artistic approach consists of a colour image, with open eyes, eyebrows and face painting (Figs. 6-8), based on data present in the press release of the approximations carried out in 2005 (Guardians, 2005b), where Dr. Hawass cites the JE 60723 sculpture (<https://bit.ly/3W7SaWI>). Although it contains speculative elements about the individual's appearance, as it is one aspect of this work that will be also presented to the general public, it provides the necessary elements for a complete humanisation, very difficult to achieve with just exposing the skull and deficient in the objective image in grayscale with eyes closed.

As mentioned above, when the structure of the virtual donor was deformed, a segmentation corresponding to the endocranium was also adapted to the skull of Tutankhamun (Fig. 9A, B), hence that it was possible to raise its volume to  $\approx 1587 \text{ cm}^3/\text{ml}$ . The measurement of head circumference resulted in 58.45 cm.

Such data were plotted as a graph, containing the volume of endocrania and circumferences of the heads of another 40 facial approximations, resulting in 41 samples (Fig. 10). It is evident that in this sample the endocranium, combined with the circumference of Tutankhamun's head, is positioned among the largest volumes. The work by Neubauer et al. (2018) with the measurement of modern endocrania, presents a general average (men and women,  $n=89$ ) of  $1328 \pm 164 \text{ ml}$ , therefore the endocranium studied in this article is 259 ml above, corresponding to +1.58 SD. The volume of the endocranium is different from the volume of the brain, so that, in order to identify a factor to be used for the conversion, the virtual donor's brain was reconstructed directly from its computed tomography, with the aid of semi-automatic and manual



**Figure 2** A-I Steps of the forensic facial approximation process.

segmentation tools in the free, open source and cross-platform software Slicer 3D (<https://www.slicer.org/>), using as a reference the structure presented in the work

by Ritchie et al. (2018). According to the calculations raised, the volume of the brain is 9.81% smaller than that of the endocranium, so if the endocranium resulted in



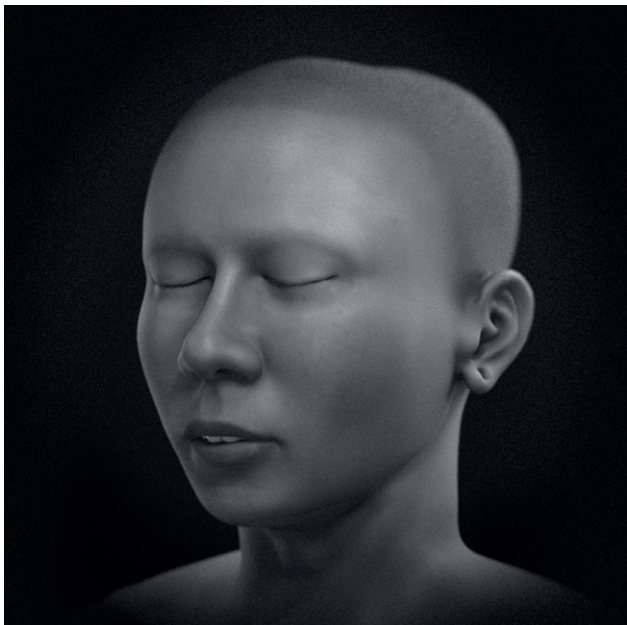

Figure 3. Objective version - 3/4 view face.




Figure 5. Objective version - frontal face.

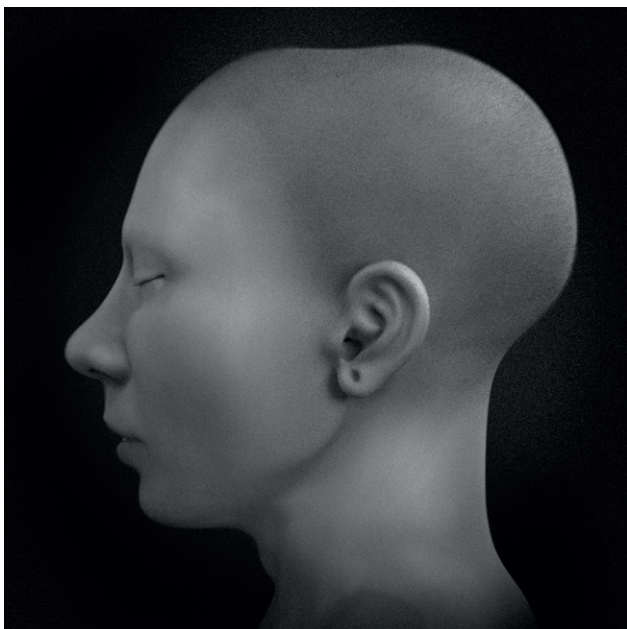


Figure 4. Objective version - face profile.



Figure 6. Coloured version - 3/4 face.

1587 cm<sup>3</sup>, the brain would have a volume of 1431.21 cm<sup>3</sup>. Knowing that the average for men (n=2466) is 1233.58 cm<sup>3</sup>, Tutankhamun's brain is 197.73 cm above it, therefore, at +2.01 SD, a significantly large brain volume.

When observing the population cluster (Moraes et al. 2022b), based on midface measurements (fmo-fmo,

ec, G and N), it can be seen that the skull of Tutankhamun has more affinity with the population of artificially remodeled skulls (Fig. 11), which can be explained by its atypical structure.




Figure 7. Coloured version – face profile (lateral view).




Figure 8. Coloured version – frontal view.

CONCLUSIONS

This new facial reconstruction of Tutankhamun adds to the body of Egyptological and anatomical-anthropological literature on the famous pharaoh and can be of help to both fields of research by highlighting

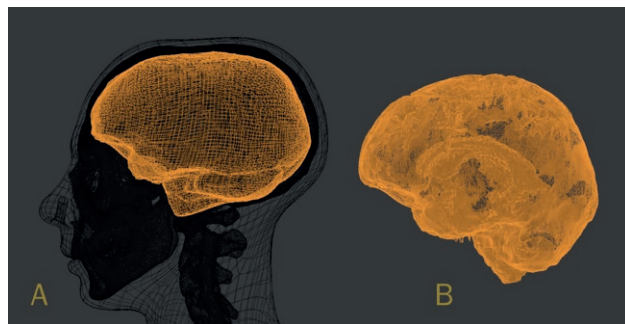


Figure 9. Tutankhamun’s endocranium segmented (left) and virtual donor brain segmented (right).

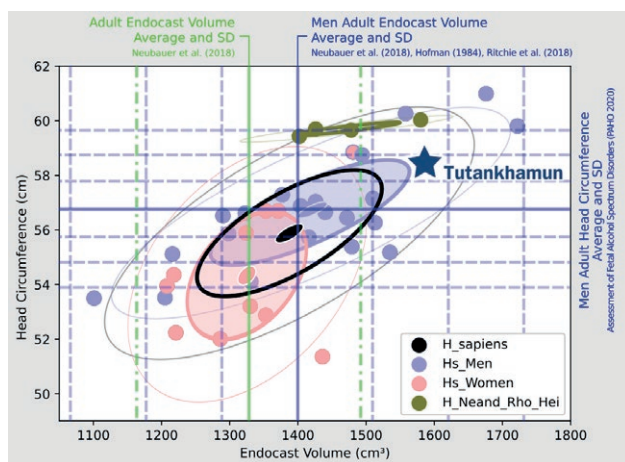


Figure 10. Distribution chart with data on endocranial volume (horizontal) and head circumference (horizontal), with means based on the work of Neubauer et al. (2018), Ritchie et al. (2018), Hofman (1984) and PAHO (2020).

the possibility of a new modelling technique based on the use of digitised graphic information.

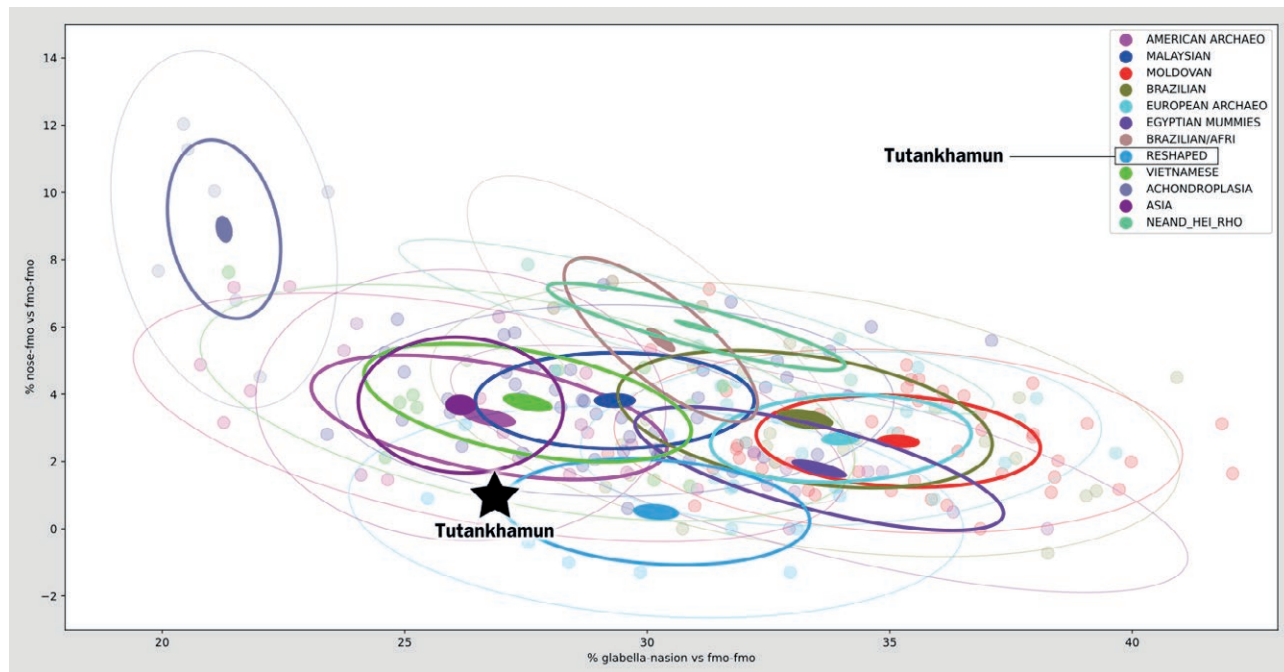
ACKNOWLEDGEMENTS

To Dr. Richard Gravalos for providing the virtual donor CT scan used in this study.

REFERENCES

Abdullah J.Y., Moraes C., Saidin M., Rajion Z.A., Hadi H., Shahidan S., Abdullah J.M. (2022) Forensic Facial Approximation of 5000-Year-Old Female Skull from Shell Midden in Guar Kepah, Malaysia. Appl. Sci. 12 (15): 7871.





**Figure 11.** Population cluster with the placement of Tutankhamun in black.

- Ashrafiyan H. Familial epilepsy in the pharaohs of ancient Egypt's eighteenth dynasty. *Epilepsy Behav.* 2012;25 (1): 23-31.
- Boyer R.S., Rodin E.A., Grey T.C., Connolly R.C. (2003) The Skull and Cervical Spine Radiographs of Tutankhamun: A Critical Appraisal. *Am. J. Neuroradiol.* 24 (6): 1142-1147.
- Derry D.E. (1927) Report upon the Examination of Tutankhamun's Mummy. In: Carter H. *The Tomb of Tutankhamun*. Vol 2. Pp. 143-161.
- Galassi F.M., Habicht M.E., Moraes C., Varotto E. (2020). The Alleged Skull of Sophocles: Anthropological and Paleopathological Confutation of a 19th Century Myth. In: Congiu M., C. Micciché, Modeo S. (Eds.). *Atti del XV Convegno di studi sulla Sicilia antica*. Edizioni Lussografica, Caltanissetta. Pp. 253-268.
- Guardians. (2005). Press release - 8 March 2005 - Tutankhamun CT scan results - Dr. Zahi Hawass - the Plateau - official website of Dr. Zahi Hawass. [http://guardians.net/hawass/press\\_release\\_tutankhamun\\_ct\\_scan\\_results.htm](http://guardians.net/hawass/press_release_tutankhamun_ct_scan_results.htm)
- Guardians. (2005). Press release May 2005 - king tutankhamun facial reconstruction - Dr. Zahi Hawass - the Plateau - official website of Dr. Zahi Hawass.
- Habicht M.E., Galassi F.M., Henneberg M. (2021) Cranial variation in Egyptian Pharaohs: Ancestry or microevolution? : Suggestions of family interrelations. *Acta Palaeomedica* 1: 61-77.
- Havis M., Murray G. (2022, December 8). Face of Tutankhamun seen for the first time in over 3,300 years reconstruction. *mirror*. <https://www.mirror.co.uk/news/world-news/face-tutankhamun-seen-first-time-28684112>
- Hawass Z, Gad YZ, Ismail S, et al. (2010) Ancestry and Pathology in King Tutankhamun's Family. *JAMA* 303 (7): 638-647.
- Hawass Z., Saleem S. (2018) The CT Scan of the Mummy of Tutankhamun: New Evidence on the Life and Death of the King. In: *Scanning the Pharaohs CT Imaging of the New Kingdom Royal Mummies*. The American University in Cairo Press, Cairo.
- Hawass Z., Saleem S.N. (2011) Mummified Daughters of King Tutankhamun: Archeologic and CT Studies. *Am. J. Roentgenol.* 197 (5): W829-W836.
- Hofman M.A. (1984) A Biometric Analysis of Brain Size in Microcephalics. *J. Neurol.* 231: 87-93.
- Hussein K., Matin E., Nerlich A.G. (2013) Paleopathology of the juvenile Pharaoh Tutankhamun—90th anniversary of discovery. *Virchows Arch.* 463 (3): 475-479.
- Moraes C. (2013.) *Homo floresiensis* (parte 1 de 2) – modelagem do crânio. Cicero Moraes. <http://www.cicromoraes.com.br/blog/?p=1025>.
- Moraes C. (2013). Convertendo Uma Pintura em Uma Cena 3D. Cicero Moraes. <http://www.cicromoraes.com.br/blog/?p=840>

- Moraes C. (2013). Triangulação de Pontos em 3D Por Fotografias. Cicero Moraes. <http://www.ciceromoraes.com.br/blog/?p=1461>
- Moraes C., Suharschi I. (2022). Mensuração de Dados Faciais Ortográficos em Moldavos e Comparação com Outras Populações. figshare. <https://doi.org/10.6084/M9.FIGSHARE.20089754>
- Moraes C., Lira J.L., Dias P.E.M., Machado M.P.S., Beaini T.L., Guimarães M.A., Dornelles R., Bueno P.H., da Silva R.H.A., da Rosa E. (2022). The 3D Aproximação Facial 3D de São Vicente de Paulo. <https://doi.org/10.6084/M9.FIGSHARE.18092717>.
- Moraes C., Suharschi I., Abdullah J.Y., Quang D.N., Santos M.E., Machado M.P.S., Beaini T.L. (2022). Agrupamento em Clusters de Populações a partir de Comparações com a Distância Orbital Frontomalar (fmo-fmo). figshare. <https://doi.org/10.6084/M9.FIGSHARE.20161013>
- Neubauer S., Hublin J.-J., Gunz P. (2018). The evolution of modern human brain shape. *Sci. Adv.* 4 (1): eaao5961.
- PAHO. Assessment of Fetal Alcohol Spectrum Disorders. (2020). Pan American Health Organization. <https://doi.org/10.37774/9789275122242>
- Pausch N.C., Naether F., Krey K.F. (2015). Tutankhamun's Dentition: The Pharaoh and his Teeth. *Braz. Dent. J.* 26 (6): 701-704.
- Pereira J.G.D., Magalhães L.V., Costa P.B., da Silva R.H.A. (2017). Three-Dimensional Forensic Facial Reconstruction: Manual Technique vs. Digital Technique. *Rev. Bras. Odontol. Leg.* 4 (2): 46-54.
- Ritchie S.J., Cox S.R., Shen X., Lombardo M.V. Reus L.M. Alloza C. Harris M.A. Alderson H.L. Hunter S. Neilson E. et al. (2018) Sex Differences in the Adult Human Brain: Evidence from 5216 UK Biobank Participants. *Cereb. Cortex* 28 (8): 2959-2975.
- Rühli F.J., Ikram S. (2014) Purported medical diagnoses of Pharaoh Tutankhamun, c. 1325 BC. *HOMO* 65 (1): 51-63.
- Sandomir R. (2020, January 14). Betty Pat Gatliff, 89, whose forensic art solved crimes, dies. *The New York Times*. <https://www.nytimes.com/2020/01/14/science/betty-pat-gatliff-dead.html>
- Stephan C.N. (2003). Anthropological facial 'reconstruction' – recognizing the fallacies, 'unembracing' the errors, and performing method limits. *Sci. Justice.* 43 (4): 193-200.
- Stephan C.N. (2015). Facial Approximation-From Facial Reconstruction Synonym to Face Prediction Paradigm. *J. Forensic Sci.* 60 (3): 566-571.
- Taylor K.T. (2001) Three-Dimensional Facial Reconstruction on the Skull. In: *Forensic art and Illustration*. CRC Press, Boca Raton, Fla. Pp. 466.