

LETTER TO THE EDITOR

EXPRESSION OF GELATINASES (MMP-2, MMP-9)
IN HUMAN ARTICULAR CARTILAGE

L. LIPARI and A. GERBINO

Department of Experimental Biomedicine and Clinical Neurosciences, Section of Histology and Embryology, University of Palermo, Palermo, Italy

Received October 23, 2012 – Accepted July 18, 2013

Osteoarthritis (OA) is a chronic degenerative joint disorder characterized by destruction of the articular cartilage, subchondral bone alterations and synovitis. Matrix metalloproteinases (MMPs) are expressed in joint tissues of patients with osteoarthritis (OA). The objective of this study was to define the steady state levels of two different MMPs to provide more insight into the role of MMPs in cartilage destruction in OA. We investigated the expression of gelatinases through immunohistochemistry. Our results show that high levels of MMP-2 and MMP-9 are present in OA and suggest that once these MMPs are fully activated they may contribute to the cartilage destruction in OA.

Osteoarthritis is one of the most common diseases worldwide, affecting more than 100 million individuals. Risk factors (age, occupation and gender) of OA are closely related to the mechanical loading of the joints and it is assumed that a large part of OA is induced by accumulated mechanical stress (1). The major problem in the treatment of OA is that articular cartilage (AC) has poor potential healing, related to the low regenerative capacity of articular chondrocytes. The pathology of disease process leads to destruction of the articular cartilage by release of deleterious proteinases from articular chondrocytes, inducing excessive degradation of cartilage extracellular matrix (ECM). Articular cartilage has a simple avascular structure composed of a large amount of ECM and a small number of chondrocytes and is the major target tissue for destruction in osteoarthritis (2).

Over a long period, our group has been studying the expression of metalloproteinases (MMP-2; MMP-9) in healthy and pathological samples

(human oral mucosa and salivary gland tumors) by immunohistochemistry and RT-PCR to investigate the entity of the remodelling processes (3-5). The objective of this study is to define the steady levels of two different MMPs to provide more insight into the role of MMPs in cartilage destruction in OA.

MATERIALS AND METHODS

Samples

Twenty articular cartilage specimens were obtained from patients with osteoarthritis (OA) who underwent total knee or hip arthroplasty. OA was diagnosed by clinical and radiological evaluation based on the American College of Rheumatology criteria. Patients who presented with evident joint injury or generalised OA were excluded from the study. Patients were not treated with intra-articular injections of steroid, chondroitin polysulphate or hyaluronic acid for at least one month prior to this study.

Control specimens were collected from 10 patients with no history of joint disease who underwent joint surgery after femoral neck fracture. All samples were

Key words: articular cartilage, metalloproteinases, immunohistochemistry, osteoarthritis

*Mailing address: Dr Lipari Luana,
BioNec, Dipartimento di Biomedicina Sperimentale
e Neuroscienze Cliniche,
Facoltà di Medicina e Chirurgia, Università di Palermo
Via del Vespro 129, 90127 Palermo, Italy
Tel.: +39 091 6553585 Fax: +39 6553586
e-mail: luana.lipari@tiscalinet.it*

0394-6320 (2013)

Copyright © by BJO LIFE, s.a.s.

This publication and/or article is for individual use only and may not be further reproduced without written permission from the copyright holder.

Unauthorized reproduction may result in financial and other penalties
DISCLOSURE: ALL AUTHORS REPORT NO CONFLICTS OF
INTEREST RELEVANT TO THIS ARTICLE.

obtained after informed consent from the patients. The experiments were carried out in accordance with the Declaration of Helsinki.

Immunohistochemistry

Tissue specimens were fixed in 4% buffered formalin. After fixation the tissue was dehydrated in a graded series of alcohols, cleared in xylene and paraffin embedded. Section 7 μ m were obtained with a microtome (Leica RM2145), stored overnight at 37°C and then stored at room temperature until use. On the day of the experiment, slides were dewaxed in xylene and rehydrated in a graded series of alcohols. Slides were then transferred into distilled water for 5 min. Immunohistochemistry was performed using the Dako Cytomation EnVision+ System-HRP (AEC) kit (Dako, Glostrup Denmark) following the manufacturer's instructions. Briefly, sections were covered with the peroxidase block reagent and incubated 5 min at room temperature. The samples were rinsed once in PBS buffer pH 7.2 and the sections were covered with antibody solution and incubated in a humid chamber overnight at 4°C. Mouse anti-human MMP-2 monoclonal antibody (MAB3308, Chemicon Millipore, MA, USA) at 1:800 dilution and rabbit polyclonal antimouse full length MMP-9 antibody (AB19047, Chemicon Millipore, MA, USA) at 1:100 dilution were used. The antibodies were diluted in 0.1% BSA in PBS. The sections were washed twice in PBS pH 7.2, incubated with Peroxidase Labelled Polymer reagent, washed twice in PBS pH 7.2, incubated with the Substrate-Chromogen 2 reagent and immediately placed under a light microscope. The reaction was visually monitored and stopped by distilled water as the staining appeared (2-10 min). Negative controls were obtained by the same immunostaining in which the primary antibody was omitted. The sections were coverslipped using Dako Cytomation Faramount Aqueous Mounting Medium, then were observed under a Leica DM1000 microscope.

Semi-quantitative evaluation of Immunoreactivity

The intensity of immunostaining for MMP-2 and MMP-9 in specimens was evaluated by three independent observers according to the following criteria: (0) no staining, (1) weak staining, (2) moderate staining, (3) strong staining, (4) very strong staining.

RESULTS

The immunodistributions of MMP-2 and MMP-9 were examined in specimens of OA and normal cartilage. The specimens provided examples that were representative of OA grades 1,2,3 for comparison with age-matched normal articular

cartilage, graded as 0. Immunolocalization of the two gelatinases (MMP-2 and MMP-9) was limited to small groups of chondrocytes with rather strong staining (Fig. 1). Control tissue sections from OA grade 3 cartilage gave immunonegative results.

Immunostaining for MMP-2 and MMP-9 was most prominent in the superficial zone of OA grades 2 and 3, especially associated with areas of extracellular matrix depletion, fibrillations, chondrocytes, clusters and loss of metachromasia. By contrast, the MMP immunostaining was reduced or absent within the deep zone of these specimens. From a few cell clusters, this deep zone showed apparently normal hyaline cartilage and chondrocyte morphology (Figs. 2, 3, 4). All the OA specimens showed a greater frequency and distribution of each MMP compared with normal articular cartilage specimens.

DISCUSSION

Cartilage ECM is composed mainly of proteoglycans including the major proteoglycan, aggrecans, and other minor proteoglycans and collagens such as fibrillar type II collagen and other minor collagens (type IX, XI and VI). Depletion of proteoglycans occurs early and the degradation of fibrils follows.

After the initiation of collagen fibrillation, laceration of the articular cartilage begins and is a result of the destruction of the cascade structures of the collagen fibrils in the articular cartilage, which is composed of superficial, transitional, radial and calcified zones.

Destruction of cartilage is a common pathological feature in various joint diseases, and is a major cause of joint dysfunction, which is followed by impairment of the quality of life in those patients. Two pathways are known for the destruction of the cartilage: the former, an intrinsic pathway in which chondrocytes degrade cartilage extracellular matrix (ECM); the latter, an extrinsic pathway in which tissues or cells other than chondrocytes, such as inflamed synovium, pannus tissue, and infiltrated inflammatory cells, cause the extracellular matrix (ECM) breakdown, mostly through synovial fluid. In both pathways, enzyme digestion of ECM is responsible for cartilage destruction (6).

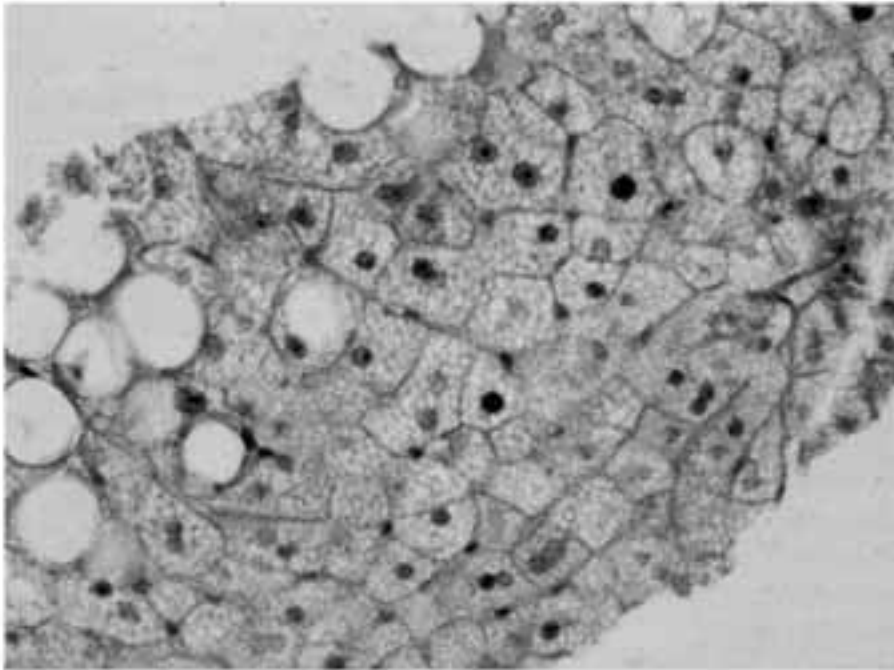


Fig. 1. Articular cartilage sample. MMP-2 immunoreactivity limited in small groups of chondrocytes, 40X.

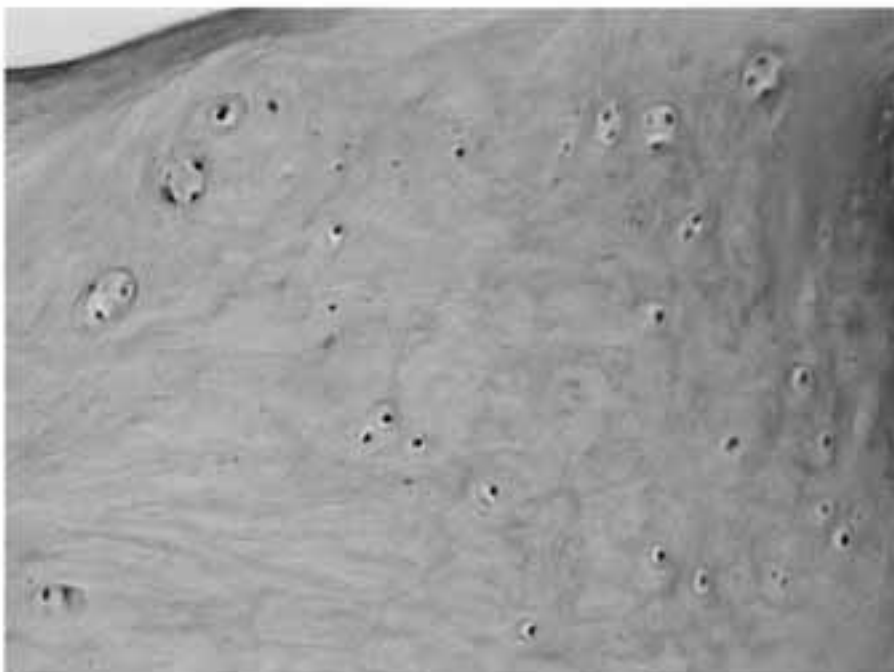


Fig. 2. Articular cartilage sample. MMP-2 immunoreactivity evident in the superficial zone, 40X.

Several proteinases belonging to many classes are expressed in joint tissues of patients with OA. Among them, MMPs are believed to play a key

role in joint destruction. MMPs are zinc-dependent endopeptidases of the a larger family of proteases known as the metzincin superfamily. MMPs are

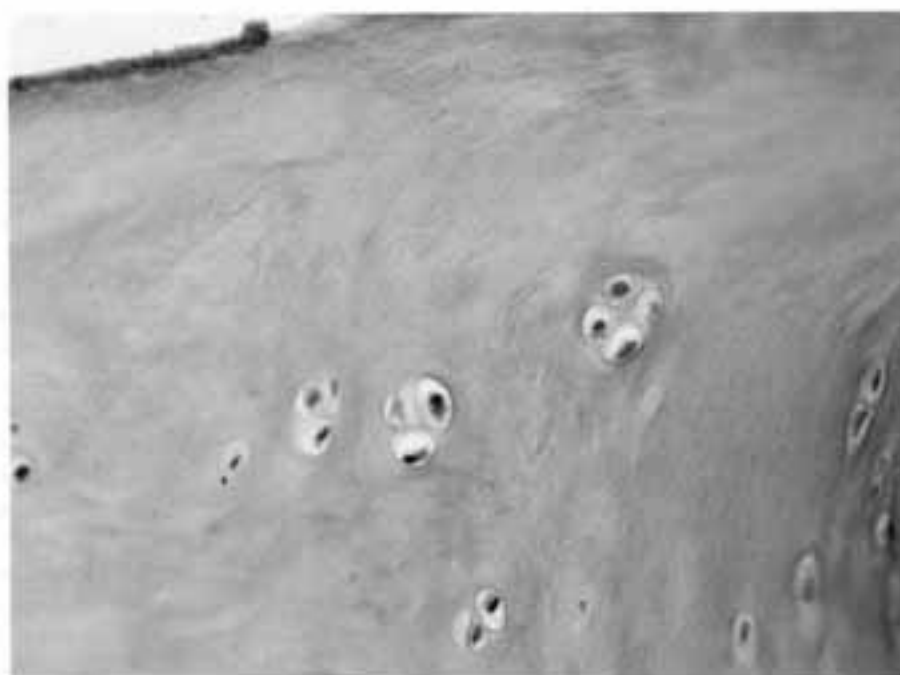

Fig. 3. Articular cartilage sample. MMP-9 immunoreactivity in the superficial zone and in groups of chondrocytes, X40.

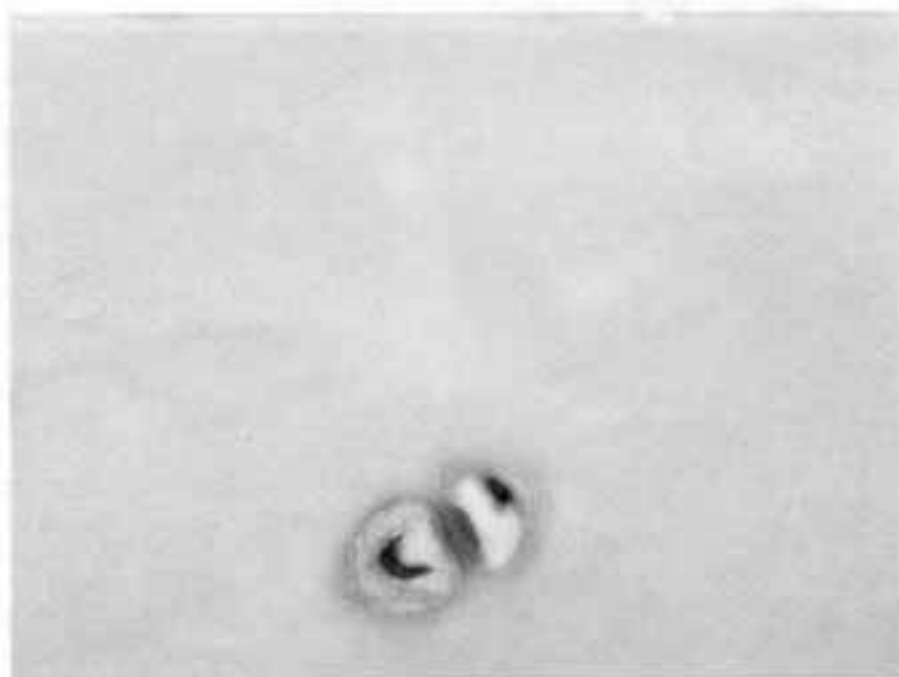

Fig. 4. Articular cartilage sample. MMP-9 immunoreactivity in the isogen chondrocyte group, 100X.

involved in the breakdown of extracellular matrix in physiological processes, such as embryonic development, reproduction, and tissue remodelling, as well as in diseases, such as arthritis and tumor

metastasis. They are capable of degrading all kinds of ECM proteins and of processing a number of bioactive molecules. For example, they are involved in cleavage of cell surface receptors, release of

apoptotic ligands such as the FAS ligand and chemokine inactivation. MMPs are also thought to play a major role on cell proliferation, migration, differentiation, angiogenesis, apoptosis and immunodefence. MMPs are distinguished from other endopeptidases by their dependence on metal ions as cofactors, their ability to degrade extracellular matrix and their specific evolutionary DNA sequence. They are grouped based partly on historical assessment of substrate specificity and partly on cellular localization: collagenases, gelatinases, stromelysins and membrane-type MMPs. The main substrates of gelatinases (MMP-2; MMP-9) are type IV collagen; these enzymes are distinguished by the presence of an additional domain inserted into the catalytic domain and by the presence of cartilage matrix degradation in localized sites (7-9).

It is known that MMP-2 is produced by stromal cells in the sublining synovial layer while MMP-9 is secreted by neutrophils, macrophages and synovial cells. In addition, the expression of these MMPs in chondrocytes has also been reported in literature data. In this study, we determined the levels of MMP-2 and MMP-9 in articular cartilage specimens from patients with OA. MMP-2 and MMP-9 are localized solely in the calcified cartilage and the subchondral bone area.

Studies have shown that, among the seven different MMPs (MMP-1, MMP-2, MMP-3, MMP-7, MMP-8, MMP-9 and MMP-13), the levels of both MMP-2 and MMP-9 are significantly enhanced in patients with OA compared with controls (10). Cartilage degradation and loss are the major features of OA; degenerative changes include fibrillations, chondrocyte proliferation into cell clusters, and matrix disruption. Recent studies have implicated the up-regulation of several matrix-degrading metalloproteinases in OA cartilage. Several reports have proposed that chondrocyte production of MMPs in OA cartilage reflects a local synthesis which is corresponding to the extent of cartilage degeneration. However, the mechanisms which regulate MMP expression, the relative importance of individual MMPs, and their distributions *in situ* remain uncertain (11-13). The major aim of the present study is to examine the MMP expression of chondrocytes in human OA cartilage specimens and to determine whether these are related to the

progressive degenerative changes of OA.

Numerous immunohistochemical studies show the presence of MMPs in OA cartilage of various animal species and humans, many of which have identified MMP distribution in tissue but the results are controversial. One explanation for disagreement may be related to differences in the relatively short-term experimental OA animals models compared with the different cartilage location, joint feature and clinical grading of human OA specimens (14-16). Other studies used isolated chondrocyte culture or cartilage explants to examine the expression of MMPs mRNA and/or protein in normal and OA-derived chondrocytes (17-21).

In the present study, the MMP expression of OA chondrocytes showed variations within specimens of the same grade. Only occasionally was the extent of immunostaining in the deep zone similar to that of the superficial zone. Thus, the results did not always conform to the expected pattern. In general, we showed that both MMPs were more intensely expressed by chondrocytes of the superficial zone, where degenerative changes were more prominent. These findings are largely consistent with the data reported by others Authors (22), who reported the immune reaction and direct correlation for some MMPs of the superficial zones of OA cartilage with more advanced cartilage degradation. The knowledge that OA cartilage specimens show microenvironmental variations in MMPs expression despite similar histologic grading probably reflects the intermittent nature of active and quiescent phases of disease progression in OA.

In conclusion, the present findings further confirm the previous studies on chondrocytes and cartilage explants or on human OA cartilage samples which have emphasized the importance of MMPs in the beginning and progress of cartilage degeneration (23, 24).

REFERENCES

1. Howell DS, Pelletier JP. Etiopathogenesis of osteoarthritis. In: Arthritis and allied conditions: a textbook of rheumatology. McCarty DJ, Koopman WJ, eds, 12th ed. Philadelphia: Lea & Febiger, 1993; p. 1723-34.
2. Murata M, Yudo K, Nakamura H, et al. Hypoxia

- upregulates the expression of angiopoietin-Like-4 in human articular chondrocytes: role of angiopoietin-like-4 in the expression of matrix metalloproteinases and cartilage degradation. *J Orthop Res* 2009; 27(1):50-7.
3. Lipari L, Mauro A, Tortorici S, Burruano F, Leone A, Spatola GF, Gerbino A, Buscemi M, Teté S. Immunohistochemical and transcriptional expression of the matrix metalloproteinases (MMP-2 and MMP-9) in normal and pathological human oral mucosa. *J Biol Regul Homeost Agents* 2009; 23(4):259-67.
 4. Mauro A, Lipari L, Tortorici S, Leone A, Gerbino A, Buscemi M. Expression of MMP-2 and MMP-9 in odontogenic myxoma in a child: report of a clinical case. *Odontology* 2012: Epub ahead of print.
 5. Tortorici S, Mauro A, Burruano F, et al. Matrix metalloproteinase-2, matrix metalloproteinase-9 and inducible nitric oxide synthase in oral leukoplakia: immunohistochemistry and RT-PCR analysis. *J Biol Regul Homeost Agents* 2008; 22(2):125-30.
 6. Yoshihara Y, Nakamura H, Obata K, Yamada H, Hayakawa T, Fujikawa K, Okada Y. Matrix metalloproteinases and tissue inhibitors of metalloproteinases in synovial fluids from patients with rheumatoid or osteoarthritis. *Ann Rheum Dis* 2000; 59(6):455-61.
 7. Bierkedal-Hansen H, Moore WG, Bodden MK, Windsor LJ, Bierkedal-Hansen B, DeCarlo A, Engler JA. Matrix metalloproteinase: a review. *Crit Rev Oral Biol Med* 1993; 4(2):197-250.
 8. Nagase H, Woessner JF Jr. Role of endogenous proteinases in the degradation of cartilage matrix. In: *Joint cartilage degradation*. Woessner JF Jr, Howell DS, eds. New York: Marcel Dekker, Inc 1993; p. 159-85.
 9. Kelly WN, Harris ED Jr, Ruddy S, Sledge CB, Nagase H, Okada Y. Proteinase and matrix degradation. In *Text book of rheumatology* eds Kelly WN, Harris ED Jr, Ruddy S, Sledge CB. Saunders, Philadelphia, 5th ed. 1996; p. 323-41.
 10. Tetlow L, Adlam DJ, Woolley DE. Matrix metalloproteinase and proinflammatory cytokine production by chondrocytes of human osteoarthritic cartilage. *Arthritis Rheum* 2001; 44(3):585-594.
 11. Freemont AJ, Byers RJ, Taiwo YO, Hoyland JA. In situ zymographic localisation of type II collagen degrading activity in osteoarthritic human articular cartilage. *Ann Rheum Dis* 1999; 58(6):357-65.
 12. Billingham RC, Dahlberg L, Ionescu M, et al. Enhanced cleavage of type II collagen by collagenases in osteoarthritic cartilage: *J Clin Invest* 1997; 99(7):1534-45.
 13. Mehraban F, Kuo SY, Riera H, Chang C, Moskowitz RW. Prostromelysin and procollagenase genes are differentially up-regulated in chondrocytes from the knees of rabbits with experimental osteoarthritis. *Arthritis Rheum* 1994; 37(8):1189-97.
 14. Freemont AJ, Hampson V, Tilman R, Goupille P, Taiwo Y, Hoyland JA. Gene expression of matrix metalloproteinase 1, 3, and 9 by chondrocytes in osteoarthritic human knee articular cartilage is zone and grade specific. *Ann Rheum Dis* 1997; 56(9):542-9.
 15. Kammermann JR, Kincaid SA, Rumph PF, Baird DK, Visco DM. Tumor necrosis factor-alpha (TNF-alpha) in canine osteoarthritis: immunolocalization of TNF-alpha, stromelysin and TNF receptors in canine osteoarthritic cartilage. *Osteoarthritis Cartilage* 1996; 4(1):23-34.
 16. van der Sluijs JA, Geesink RG, van der Linden AJ, Bulstra SK, Kuyper R, Drukker J. The reliability of the Mankin score for osteoarthritis. *J Orthop Res* 1992; 10(1):58-61.
 17. Shlopov BV, Lie WR, Mainardi CL, Cole AA, Chubinskaya S, Hasty KA. Osteoarthritic lesions: involvement of three different collagenases. *Arthritis Rheum* 1997; 40(11):2065-74.
 18. Borden P, Solymar D, Suchareczuk A, Lindman B, Cannon P, Heller R. Cytokine control of interstitial collagenase and collagenase-3 gene expression in human chondrocytes. *J Biol Chem* 1996; 271(38):23577-81.
 19. Dahlberg L, Billingham RC, Manner P, et al. Selective enhancement of collagenase-mediated cleavage of resident type II collagen in cultured osteoarthritic cartilage and arrest with a synthetic inhibitor that spares collagenase 1 (matrix metalloproteinase 1). *Arthritis Rheum* 2000; 43(3):673-82.
 20. Bottomley KM, Borkakoti N, Bradshaw D, et al. Inhibition of bovine nasal cartilage degradation by selective matrix metalloproteinase inhibitors. *Biochem J* 1997; 323(Pt2):483-8.
 21. Billingham RC, Wu W, Ionescu M, Reiner

- A, Dahlberg L, Chen J, van Wart H, Poole AR. Comparison of the degradation of type II collagen and proteoglycan in nasal and articular cartilages induced by interleukin-1 and the selective inhibition of type II collagen cleavage by collagenase. *Arthritis Rheum* 2000; 43(3):664-72.
22. Walter H, Kawashima A, Nebelung W, Neumann W, Roessner A. Immunohistochemical analysis of several proteolytic enzymes as parameters of cartilage degradation. *Pathol Res Pract* 1998; 194(2):73-81.
23. Shlopov BV, Gumanovskaya ML, Hasty KA. Autocrine regulation of collagenase 3 (matrix metalloproteinase 13) during osteoarthritis. *Arthritis Rheum* 2000; 43(1):195-205.
24. Ohta S, Imai K, Yamashita K, Matsumoto T, Azumano I, Okada Y. Expression of matrix metalloproteinase 7 (matrylisin) in human osteoarthritic cartilage. *Lab Invest* 1998; 78(1):79-87.