

---

**CONCURRENT SESSION C101: NOVEL APPROACHES TO LONG-TERM GERD MANAGEMENT – October 15, 2012 13:30–15:00**

---

**C101.05 ENDOSCOPIC FULL-THICKNESS-GASTROPLICATION VERSUS LAPAROSCOPIC ANTIREFLUX SURGERY FOR THE TREATMENT OF GASTROESOPHAGEAL REFLUX DISEASE: ONE YEAR RESULTS OF A PROSPECTIVE RANDOMIZED TRIAL**

Adolf Kaindlstorfer<sup>1</sup>, Oliver Owen Koch<sup>1</sup>, Stavros A Antoniou<sup>1</sup>, Kai Uwe Asche<sup>1</sup>, Frank A Granderath<sup>2</sup>, Rudolph Pointner<sup>1</sup>  
<sup>1</sup>General Surgery; Public Hospital Zell Am See, Zell Am See/AUSTRIA,  
<sup>2</sup>Department Of General And Visceral Surgery, Neuwerk Hospital, Mönchengladbach/GERMANY

**Background:** Comparative data of endoscopic full-thickness-gastropliation with well-established surgical therapies are scarce. This prospective randomized controlled study comparatively evaluates the effectiveness of endoscopic plication and laparoscopic antireflux surgery (LARS) one year after the procedures.

**Methods:** Seventy-nine patients with documented GERD were randomly assigned to undergo either endoscopic plication (n = 40) or LARS (n = 39). Patients in the plication group received one or more transmural pledgeted sutures. Patients in the LARS group underwent Nissen or Toupet fundoplication. Esophageal manometry, 24 hrs-impedance-pH-monitoring, Gastrointestinal Quality of Life Index (GIQLI) and standardized symptom questionnaires were evaluated at baseline and twelve months follow-up by appropriate statistical tests for significant (p < 0.05) changes and differences.

**Results:** Mid-respiratory lower esophageal sphincter pressures were increased in the LARS-Group and unchanged in the gastropliation group. All types of reflux events were reduced in both groups (p < 0.05), total numbers as well as acid, proximal and upright reflux events significantly more in the LARS-Group. No significant differences were found for recumbent and non-acid reflux events. Reductions of DeMeester scores were significant in both groups, more intense in the LARS-group. Quality-of-life scores showed a substantial and similar increase for both groups after treatment. Reflux-specific symptom scores were reduced in both groups, significantly more after LARS compared to plicator group. Side effects appeared more often after LARS, but the differences between the procedures did not reach significance level.

**Discussion:** LARS provides stronger reflux-control than endoscopic full-thickness-plication, but one year after the procedures Quality-of-life scores are similar.

**Disclosure:** All authors have declared no conflicts of interest.

---

**CONCURRENT SESSION C102: ACHALASIA – October 15, 2012 15:30–17:00**

---

**C102.05 A PROSPECTIVE EVALUATION OF POEM IN 202 CONSECUTIVE CASES OF ESOPHAGEAL ACHALASIA AT SINGLE INSTITUTE**

Haruhiro Inoue, Hitoshi Satodate, Hitoshi Satodate, Haruo Ikeda, Shin-ei Kudo  
Digestive Disease Center, Showa University Northern Yokohama Hospital, Yokohama/JAPAN

**Background:** Per-oral endoscopic myotomy (POEM) has been developed in our institute over 3 years ago and then continuously performed in 202 consecutive cases. Herein we report a prospective evaluation of POEM in single institute.

**Methods:** All achalasia cases at our hospital were involved in this study except three (one patient received lap-Heller & Dor by patient's request; other two postsurgical cases were easily controlled balloon dilatation.) Age was distributed from 3 to 87 year old. Duration of symptom was 11 years (8 months to 50 years). Thirty-five cases demonstrated sigmoid shape. Eight were surgically failed cases. All technical aspects of POEM were precisely reported in an article (Thorac Surg Clin. 2011; 21:519–25.)

**Results:** In all cases POEM was completed with no major complication. Minor complications were pneumothorax (1 case), local peritonitis (1 case), and intramucosal hemotoma (1 case). Minor troubles were conservatively treated. Mucosal laceration at cardia occurred during procedure in 3 cases, but elongation of post-procedural fasting was effective in all. Myotomy length was 14 cm (3–24). As a single exception 3-cm myotomy was done in 3 year old case. Myotomy toward gastric side was 2.9 cm on average. Resting pressure was dramatically improved from 28.4 to 12.7 mmHg. Eckerdt score was improved from 6.38 to 1.19. Symptomatic GERD after POEM occurred in 15% but easily controlled by regular dose PPI. No recurrent case was observed in maximum 3.5 year follow-up.

**Discussion:** Conclusion: Initial clinical results were excellent. Long-term follow-up data is awaited. Comparative study with other procedure are expected.

**Disclosure:** All authors have declared no conflicts of interest.

---

**CONCURRENT SESSION C103: GERD LONG TERM MANAGEMENT – October 16, 2012 08:00–09:50**

---

**C103.06 PREDICTORS OF POST-FUNDOPLICATION DYSPHAGIA USING HIGH-RESOLUTION MANOMETRY**

Masato Hoshino, Amith Reddy, Kalyana Nandipati, Tommy Lee, Sumeet Mittal

Creighton University Medical Center, Omaha/NE/UNITED STATES OF AMERICA

**Background:** High-resolution manometry (HRM) provides more detailed assessment of esophageal function compared to the conventional manometry. Aim of this study is to identify preoperative HRM parameters, which can be helpful in predicting post-operative dysphagia after fundoplication.

**Methods:** We included 73 (Female: 51, median age: 55) consecutive patients who had pre-operative HRM and underwent primary laparoscopic fundoplication (Nissen: 55, Toupet: 18) for gastro-esophageal reflux disease (GERD) at our institution between Sep.2008 and Oct.2010. All patients followed up at regular intervals with standard symptom questionnaire. Post-operative severity of dysphagia was evaluated using a standardized questionnaire (scale 0–3). Patients with scores of 1, 2, or 3 were defined as having dysphagia.

**Results:** Of the 73 patients included in the study, 54 had at least 1 year postoperative symptom data. After a median follow up of 16 months, 24% reported dysphagia and 76% had no dysphagia. On univariate analysis the preoperative factors; dysphagia before the procedure (41% vs 16%, p = 0.046) and integrated relaxation pressure (IRP) > 15 mmHg (69% vs 34%, p = 0.026) are significantly higher in dysphagia group compared to the no dysphagia group. Distal contractile integral (DCI) <1000 mmHg was noted in higher number of patients in dysphagia group (38% vs 15%, p = 0.063). Multivariate logistic regression analysis indentified IRP > 15 mmHg and distal contractile integral (DCI) <1000 mmHg as predictors of post-operative dysphagia after fundoplication.

**Discussion:** Low DCI and increased IRP in the pre-operative HRM are associated with high incidence of post-fundoplication dysphagia. Patients with these findings should be counseled appropriately and alternative treatment options should be considered.

**Disclosure:** All authors have declared no conflicts of interest.

---

**CONCURRENT SESSION C104: UES (DYS)FUNCTION – October 16, 2012 10:20–11:50**

---

**C104.05 TRANSORAL STAPLING OR TRADITIONAL SURGERY FOR THE TREATMENT OF ZENKER DIVERTICULA?**

Mario Costantini<sup>1</sup>, Nicola Passuello<sup>1</sup>, Raffaele Bottin<sup>2</sup>, Renato Salvador<sup>1</sup>, Michela Di Giunta<sup>1</sup>, Lisa Zanatta<sup>1</sup>, Giorgio Battaglia<sup>1</sup>, Loredana Nicoletti<sup>1</sup>, Giovanni Zaninotto<sup>3</sup>

<sup>1</sup>University Of Padua, Padua/ITALY, <sup>2</sup>University Of Padua, Head And Neck Surgery, Padua/ITALY, <sup>3</sup>Istituto Oncologico Veneto Iov – Irccs, Padua/ITALY, <sup>4</sup>Department Of General Surgery, Ss Giovanni E Paolo Hospital, Uls 12, Venezia/ITALY

**Background:** Since the minimally invasive techniques have been introduced, there is a tendency to treat all Zenker's diverticula (ZD) with this technique, regardless of their dimensions. Our aim was to review our experience with ZD treatment, with particular reference to the size of diverticula.

**Methods:** From 1993 to 2011, 176 ZD patients underwent transoral diverticulostomy (Group A, n = 76) or cricopharyngeal myotomy and diverticulectomy (Group B, n = 100). The choice of treatment was based on the size of the diverticulum, the clinical conditions and the preferred choice of the patients. Long term follow up was available on 70 patients of Group A (92.1%) and in 95 of group B (95%), with a median follow up of 34 (11–68) months.

**Results:** Mortality was nil. Three patients in Group A (4.2%) and 12 in Group B (12.6%) had postoperative complications (p = n.s.). Hospital stay was markedly shorter for patients in Group A. The symptom score decreased significantly in both groups (p < 0.05). Four Group B patients (4.2%) complained of severe dysphagia after surgery (all required endoscopic dilations), whereas 19 Group A patients (27%) required additional endoscopic septal reduction (13) or surgical myotomy (6) (p < 0.01); 13 of these patients (68%)

had a ZD  $\leq$  3 cm. Only after complementary treatment, were long-term satisfactory results achieved in 92.5%.

**Discussion:** Transoral diverticulostomy is safe and may be effective for ZD, but complementary endoscopic treatment is often necessary to achieve long term results comparable to traditional surgery, especially in  $\leq$  3 cm diverticula. Small ZD may represent a formal contraindication to transoral stapling.

**Disclosure:** All authors have declared no conflicts of interest.

---

#### CONCURRENT SESSION C106: PROGRESS IN UNDERSTANDING ESOPHAGEAL MOTILITY – October 16, 2012 15:30–17:00

---

##### C106.05 HYPERTENSIVE POORLY RELAXING LOWER ESOPHAGEAL SPHINCTER IN HIGH RESOLUTION MANOMETRY – A STUDY OF PREVALENCE AND CLINICAL FEATURES

Stefan Niebisch, Thomas Watson, Virginia Litle, Christian Peyre, Carolyn Jones, Jeffrey H Peters

University Of Rochester Medical Center, Rochester/UNITED STATES OF AMERICA

**Background:** The clinical significance, natural history and treatment of hypertensive lower esophageal sphincter (HTLES) remains uncertain. With the introduction of high-resolution manometry (HRM) cases of HTLES have been increasingly recognized. Our aim was to assess clinical features, prevalence and HRM characteristics of patients with HTLES.

**Methods:** From a cohort of 1,686 consecutive patients who underwent HRM between 2004 and 2011, forty patients (2.4%) were identified with HTLES characterized by a resting pressure  $>49.8$  mmHg. Patients with achalasia, hiatal hernia and foregut surgery were excluded. Twenty-six patients with both HTLES and an associated elevated residual pressure (4s-IRP  $>14.7$  mmHg) formed the study population (52.6  $\pm$  14.2 years; BMI 24.6  $\pm$  4.6; F : M 22:4).

**Results:** Dysphagia was present in 46%, heartburn in 42%, regurgitation and atypical GERD symptoms in 35%. Mean LES resting pressure was 60.1  $\pm$  8.6 mmHg and 4s-IRP 19.7  $\pm$  4.7 mmHg. The majority had normal esophageal motility (58%); hypertensive contraction pattern was present in 39% and 1 case met HRM criteria for diffuse esophageal spasm. Treatment included Botox injection in five, dilation in two and myotomy in one patient. Patients with dilation and myotomy had near complete resolution of dysphagia. Response rate after Botox ranged from no symptom improvement to good short-term response. One patient treated with fundoplication had complete GERD-symptom resolution.

**Discussion:** HTLES is an uncommon but not rare manometric finding present in 1.5% of unselected manometric procedures. The clinical presentation and associated studies reveal varied underlying physiology including both predominant GERD and motility disorders. Further clinical trials and follow up are necessary to determine treatment options with best possible response.

**Disclosure:** All authors have declared no conflicts of interest.

---

#### CONCURRENT SESSION C108: ENDOSCOPIC RADIOFREQUENCY ABLATION THERAPY – October 17, 2012 10:20–11:50

---

##### C108.05 HIATAL HERNIA AND THE RESPONSE TO INITIAL CIRCUMFERENTIAL RADIOFREQUENCY ABLATION IN LONG SEGMENT BARRETT'S ESOPHAGUS

Emmanuel Gorospe, Gang Sun, Prasad Iyer, Cadman Leggett, Lori Lutzke, Kenneth Wang

Mayo Clinic, Rochester/UNITED STATES OF AMERICA

**Background:** We assessed the effects of patient and endoscopic factors on the success of initial circumferential radiofrequency ablation (RFA) for patients with long segment Barrett's esophagus (LS-BE).

**Methods:** We reviewed patients with LS-BE, who had HALO 360 per standard protocol. Nodular lesions were resected endoscopically before RFA. We retrieved pertinent patient and endoscopic characteristics: age, gender, BMI, pre-RFA treatment, baseline histology, BE and hiatal hernia (HH) size, alcohol/tobacco and PPI use. Measurement of BE length was performed before HALO 360 application and after 3 months on follow-up. Analysis was performed in a case-control fashion. Success of initial circumferential RFA was arbitrarily defined as  $\geq$  50% reduction in BE length. Univariate analysis was performed to assess significant differences between

the two groups and to identify independent risk factors for successful RFA.

**Results:** A total of 101 patients met our inclusion criteria (52 cases; 49 controls). The mean BE length was 7.4  $\pm$  2.5 cm with 47 patients with high grade dysplasia. The two groups had comparable patient and endoscopic characteristics except for HH size. In our analysis, HH size increases the odds of failing to achieve at least 50% reduction in BE length on initial RFA with HALO 360 (OR 1.74, 95% CI: 1.31–2.46,  $p < 0.0001$ ). At this time, all patients are undergoing ablation and surveillance. None have achieved complete remission of intestinal metaplasia with a follow-up of 9.7  $\pm$  2.9 months.

**Discussion:** Among patients with LS-BE, those with larger HH size are less likely to achieve 50% reduction in BE length at initial RFA.

**Disclosure:** P. Iyer: Dr. Iyer receives research support from Takeda  
K. Wang: Dr. Wang receives research support from the following companies: Abbott Diagnostics, Barrx, Fujinon, NinePoint Medical, Oncoscope and Pinnacle Pharma.  
All other authors have declared no conflicts of interest.

---

#### CONCURRENT SESSION C201: MANAGEMENT OF EARLY ESOPHAGEAL SQUAMOUS CELL CANCER (SCC) – October 15, 2012 13:30–15:00

---

##### C201.05 LONG TERM PROGNOSIS OF ESD FOR SUPERFICIAL ESOPHAGEAL SCC

Akiko Takahashi, Tsuneo Oyama

Department Of Gastroenterology, Saku Central Hospital, Nagano/JAPAN

**Background:** The aim of our study is to investigate the longterm prognosis of SCC treated by ESD.

**Methods:** 286 SCC in 245 patients (222 males and 23females) were treated by ESD from January 2000 to December 2008 were enrolled into this study. The age was 69 (42–91). The follow up period was 64(36–152) months. Additional therapy was recommended for the patient who had lymph duct involvement or SM invasion.

**Results:** 1. en-bloc resection:97% (277/286). R0 resection:95% (273/286). 2.Complications: Mediastinal emphysema: 3% (9/286).Perforation: 0%. Bleeding required blood transfusion: 0%. 3. Prognosis The patients were divided into 3 groups (EP/LPM, MM/SM1 and SM2). SM1 was defined as 200 micrometer or less. 3-1.EP/LPM: No patient died of SCC. 25 of 217 patients died of other disease. 3-2.MM-SM1: 11 of 51 were treated by additional CRT(10) or surgery (1). All patients treated by CRT are alive, and one patient treated by surgery died of distant metastasis. 40 patients were followed up without additional therapy.1 patient died of lymph node metastasis and 8 patients died of other disease. 3-3. SM2: 12 of 18 were treated by additional CRT. One patient died of lymph node metastasis, and the other patients were alive. 6 patients were followed up without additional therapy. 2 patients died of other disease, and 4 patients are alive. 4. Cause specific and overall 3 years survival rate of 3 groups are 100/ 95, 96/ 90 and 94/ 94% , respectively.

**Discussion:** In conclusions, long term prognosis of ESD is excellent not only for EP-LPM but also MM/SM1 and SM2 with an adequate additional therapy.

**Disclosure:** All authors have declared no conflicts of interest.

---

#### CONCURRENT SESSION C202: ESOPHAGEAL ADENOCARCINOMA SCREENING AND PREVENTION – October 15, 2012 15:30–17:00

---

##### C202.05 AUDIT OF COMPLIANCE WITH BRITISH SOCIETY OF GASTROENTEROLGY GUIDANCE ON BARRETT'S OESOPHAGUS SURVEILLANCE

Kristof Nemeth<sup>1</sup>, Varsha Shah<sup>2</sup>, Ashraf Rasheed<sup>3</sup>

<sup>1</sup>Gwent Institute For Minimal Access Surgery, Wales/UNITED KINGDOM, <sup>2</sup>Royal Gwent Hospital, Newport/UNITED KINGDOM, <sup>3</sup>Gwent Institute For Minimal Access Therapy, Newport/UNITED KINGDOM

**Background:** To audit surveillance practice of Barrett's Oesophagus (BO) at our health board against the most up-to-date guidelines issued by the British Society of Gastroenterology (BSG) in 2005.

**Methods:** All cases coded in our histopathology database as BO during the period from 2005 to 2010 were identified. Our team selected a random sample and matched the endoscopy reports with histology reports. The practice was audited against the 2005 BSG guidance.

**Results:** 772 cases coded as BO were detected during the period 2005 to 2010. 389 patients were assessed. 84 were excluded due to inadequate data and incorrect coding. The remaining group of 305 patients consisted of 202/305 males and 103/305 females. The age of the patients ranged from 26 to 97 years. The median age was 64. Intestinal metaplasia was reported in 224/305 cases. The possibility of dysplasia was raised in 30/305 cases. 11/305 cases were diagnosed as indefinite for dysplasia, 5/305 were low grade dysplasia and 6/305 cases were high grade dysplasia. Cancer was detected in 6/305 cases which were all prevalent cases. Only 125/305 (40.9%) cases complied with BSG endoscopy follow up guidelines.

**Discussion:** The audit highlighted lacking compliance with BSG guidance for BO surveillance which is in keeping with published literature on the topic. We have identified a need for compliance and quality improvement in our practice before attempting to answer the question of effectiveness of the surveillance strategy.

**Disclosure:** All authors have declared no conflicts of interest.

---

### CONCURRENT SESSION C203: TREATMENT FOR LOCALLY ADVANCED ESOPHAGEAL ADENOCARCINOMA – October 16, 2012 08:00–09:50

---

#### C203.06 LYMPH NODE INVASION IN GASTROESOPHAGEAL JUNCTION TUMORS AND ITS IMPACT ON PROGNOSIS

**Norman Jael Cervantes, Rocio Santos Ranaño, Ángel Gortázar, Patricia Sáez Carlin, Ester Martín García Almenta, Luis I Diez Valladares, Andrés Sánchez-Pernaute, Antonio José Torres García**  
*Hospital Clínico San Carlos, Madrid/SPAIN*

**Background:** Extent to esophagectomy for cancer is a matter of debate, due to the aggressiveness of the operation and the poor long term survival. Aim. To analyze the lymph node invasion pattern of gastroesophageal junction tumours and its relation to prognosis.

**Methods:** 77 patients with Siewert's type I or II tumours submitted to Ivor Lewis esophagectomy were included. Lymph nodes were isolated and sent separately for histologic analysis.

**Results:** 1918 nodes from 77 patients were harvested. 25% were positive. 13 patients had N1 affection, 16 N2 and 18 N3. Perigastric nodes were affected in 24 patients, celiac trunk or hepatic artery in 12, lower mediastinal nodes in 27 and supracarinal nodes in 5. Long-term survival was 40%. N0 patients had 50% long-term survival, 72% when there were more than 15 negative nodes ( $p = 0,03$ ). N+ patients had a 38% 10 year survival, 70% for N1, 30% for N2 and 22% for N3,  $p = 0,09$ . Supracarinal invasion related to a worse prognosis, 20% at 12 months, while it was 34% for lower mediastinal invasion, 27% for perigastric and 47% for hepatic-celiac lymph node invasion. Number of invaded nodes was higher for distant invasion (16 positive nodes) than for perigastric or lower mediastinal (12 per patient)

**Discussion:** Lymphadenectomy should include 15 negative nodes, Limited lymph node invasion offers a similar survival than no lymph node invasion. Patients with greater or farther lymph node infiltration should be offered initially an oncologic treatment, as survival after surgical resection is poor.

**Disclosure:** All authors have declared no conflicts of interest.

---

### CONCURRENT SESSION C204: MANAGEMENT OF ESOPHAGEAL SQUAMOUS CELL CANCER: EAST VS. WEST – October 16, 2012 10:20–11:50

---

#### C204.05 CLINICOPATHOLOGIC FEATURES OF SUPERFICIAL ESOPHAGEAL SQUAMOUS CELL CARCINOMA WITH SUBMUCOSAL INVASION: ANALYSIS OF 131 SURGICALLY RESECTED CARCINOMA

**Manabu Emi, Jun Hihara, Yoichi Hamai, Yoshiro Aoki, Morihito Okada**  
*Department Of Surgical Oncology, Research Institute For Radiation Biology And Medicine, Hiroshima University, Hiroshima/JAPAN*

**Background:** To determine treatment strategy for superficial esophageal carcinoma (SEC), we retrospectively analyzed recurrence patterns and prognostic factors.

**Methods:** A series of 131 patients with esophageal squamous cell carcinoma with submucosal (sm) invasion of the thoracic esophagus underwent trans-thoracic esophagectomy with systematic extended lymph node dissection in the period between 1990 and 2009 at our institution.

**Results:** Lymph node metastasis was observed in 18% of sm1 cases, in 32% of sm2 cases and in 50% of sm3 cases. The overall recurrence rate of SEC at 5 years was 18.6% that of sm1 was 3.6%, sm2 was 17.5% and sm3 was 30.4%. The recurrent site of sm1 cases were all locoregional recurrence and

distant metastasis occurred in sm2 and sm3 cases. Five-year overall survival (OS) rate was 83% for sm1 cases, 77% for sm2 cases and 59% for sm3 cases. In univariate analysis, LN metastasis, depth of submucosal invasion (sm3 vs sm1/2) and localization of tumor (Ut vs Mt/Lt) were poor prognostic factors for OS, but not angiolymphatic invasion and tumor diameter. Multivariate Cox regression analyses identified depth of submucosal invasion (hazard ratio [HR], 2.55; confidence interval [CI], 1.14– 5.70) and localization of tumor (HR 2.63, CI 1.18–5.85), as the preoperative prognostic factor, but not LN metastasis.

**Discussion:** When the depth of invasion was deeper than sm2, recurrence rates become higher and distant metastasis occurred, but prognosis of sm2 cases was similar to that of sm1 cases. Upper thoracic or sm3 SEC were considered to an indication for neo or adjuvant therapy.

**Disclosure:** All authors have declared no conflicts of interest.

---

### CONCURRENT SESSION C205: PATHOGENESIS OF BARRETT'S ESOPHAGUS – October 16, 2012 13:30–15:00

---

#### C205.05 ANTIOXIDANTS ARE A POTENTIAL THERAPY FOR REVERSING DEOXYCHOLIC ACID INDUCED MITOCHONDRIAL INSTABILITY IN THE PROGRESSION OF BARRETT'S OESOPHAGUS

**Naomih O'Farrell<sup>1</sup>, Ronan Feighery<sup>1</sup>, Sarah Picardo<sup>1</sup>, Niamh Lynam-Lennon<sup>1</sup>, Eddie Fox<sup>2</sup>, Jacintha O'Sullivan<sup>1</sup>, John Reynolds<sup>1</sup>**  
*<sup>1</sup>Department Of Surgery, Institute Of Molecular Medicine, Trinity College Dublin, St. James'S Hospital, Dublin/IRELAND, <sup>2</sup>Department Of Pathology, University Of Washington, Seattle/WA/UNITED STATES OF AMERICA*

**Background:** We have previously shown in-vitro and in-vivo that random mitochondrial mutagenesis is an early event in the Barrett's oesophagus (BO) disease sequence. Mitochondrial dysfunction, characterised by significantly high levels of reactive oxygen species (ROS) and changes in the mitochondrial mass and membrane potential, was driven by deoxycholic acid (DCA). Here, this work focuses on assessing the potential of antioxidants to return the Barrett's-disease model to a redox balanced system.

**Methods:** An in-vitro model of the metaplasia (Qh), dysplasia (GO), adenocarcinoma (OE33) sequence was used. Mutagenesis and mitochondrial dysfunction +/- DCA +/- antioxidants (N-acetylcysteine [NAC] and superoxide dismutase [SOD]), and dimethylxalylglycine (DMOG)) were assessed. A large scale gene array assessing oxidative stress and antioxidant defence was used to determine potential genes these treatments may target.

**Results:** Mutagenesis was decreased following DMOG therapy at all points along the disease sequence. ROS release, significantly increased by DCA exposure ( $p < 0.01$ ) in GO and OE33 cell lines, was decreased ( $p < 0.001$ ) by NAC and DMOG. Mitochondrial mass and membrane potential was rescued with DMOG and SOD ( $p < 0.05$ ). DMOG down-regulated 3 genes, CYGB, FOXM1 and GLRX2 (13, 6 and 4 fold respectively), validations of these are being performed.

**Discussion:** Antioxidants are a potential therapeutic agent that rescue DCA induced mutagenesis and mitochondrial dysfunction, at all points along the Barrett's to oesophageal adenocarcinoma disease sequence.

**Disclosure:** All authors have declared no conflicts of interest.

---

### CONCURRENT SESSION C207: REFRACTORY GERD – October 17, 2012 08:00–09:50

---

#### C207.06 PSYCHOSOCIAL FACTORS ARE ASSOCIATED WITH A POSITIVE SYMPTOM ASSOCIATION DURING 24 HOUR IMPEDANCE-PH MONITORING IN GERD PATIENTS

**Kathleen Blondeau, Ans Pauwels, Veerle Boecxstaens, Clara Caenepeel, Stephanie Depeyter, Lieselot Holvoet, Guy Boecxstaens, Jan Tack, Lukas Van Oudenhove**  
*Translational Research Center For Gastrointestinal Disorders, Leuven/BELGIUM*

**Background:** Symptom association analysis during reflux monitoring is an important diagnostic tool in gastro-esophageal reflux disease (GERD). The contribution of psychosocial factors and somatization to GERD symptoms remains unclear.

**Methods:** Patients with GERD symptoms undergoing MII-pH recordings were prospectively recruited. Patients were instructed to carefully register symptoms. The symptom association probability (SAP) was calculated ( $+if > 95\%$ ). Depression, somatization, different forms of anxiety and body awareness were evaluated using validated questionnaires. Simple and

multiple logistic regression were used to study the association of patient characteristics with positive SAP during MII-pH monitoring.

**Results:** 119 patients were included (mean age  $47.8 \pm 14.7$ , 69 women, 57 'on' PPI). Significant associations were found with somatization, depression, generalized anxiety, post-traumatic stress, illness behaviour and body awareness. (table 1) Factor analysis identified 3 distinct factors: 'affective disorders' (anxiety & depression), 'somatization & illness behaviour' and 'body awareness'. Multiple logistic regression analysis showed that 'Affective disorders' [OR 1.58 (1.07–2.34),  $p = 0.020$ ] and 'body awareness' [OR 1.54 [1.00 – 2.37],  $p = 0.049$ ] were significantly and independently associated with positive SAP, whereas a trend was found for 'somatization & illness behaviour' [OR 1.46 [0.96 – 2.21],  $p = 0.076$ ]. Table 1

Variable	odds ration [95%CI]	p-value
somatization	1.66 [1.11 – 2.49]	.014
depression	1.54 [1.05 – 2.25]	.026
generalized anxiety	1.54 [1.05 – 2.27]	.029
social anxiety	1.08 [0.73 – 1.60]	.70
post-traumatic stress	1.74 [1.14 – 2.65]	.011
GI specific anxiety	1.27 [0.87 – 1.85]	.22
health anxiety	1.30 [0.88 – 1.92]	.19
illness behaviour	1.47 [1.00 – 2.15]	.050
body awareness	1.63 [1.10 – 2.40]	.014

**Discussion:** Our data suggest for the first time an influence of psychosocial factors and somatization on the reflux-symptom association, suggesting their contribution to hypersensitivity in GERD patients.

**Disclosure:** All authors have declared no conflicts of interest.

## CONCURRENT SESSION C208: ESOPHAGEAL PERCEPTION AND SENSITIVITY – October 17, 2012 10:20–11:50

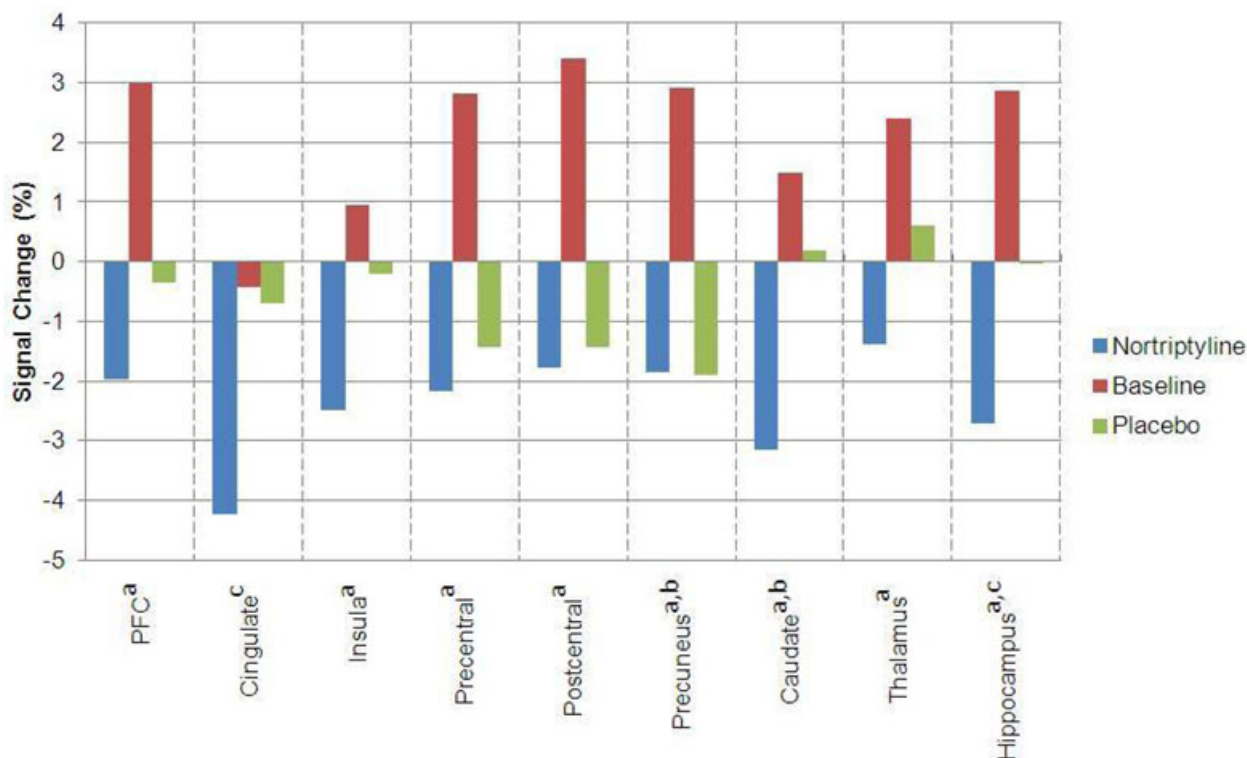
### C208.05 EFFECT OF NORTRIPTYLINE ON HEARTBURN AND BRAIN ACTIVATION IN PATIENTS WITH NON-EROSIVE REFLUX DISEASE: A DOUBLE-BLINDED, PLACEBO CONTROLLED, CROSS-OVER TRIAL

Fernando Fornari<sup>1</sup>, Cassiano Forcelini<sup>1</sup>, José Tomiozzo Jr.<sup>1</sup>, Sidia Callegari-Jacques<sup>2</sup>, Marcelo Ribeiro<sup>3</sup>, Ben Hur Madalosso<sup>3</sup>, Ricard Farre<sup>4</sup>  
<sup>1</sup>Universidade De Passo Fundo, Passo Fundo/BRAZIL, <sup>2</sup>Ufrgs, Porto Alegre/BRAZIL, <sup>3</sup>Clinica Kozma, Passo Fundo/BRAZIL, <sup>4</sup>Targid, Catholic University Leuven, Leuven/BELGIUM

**Background:** A substantial percentage of non-erosive reflux disease (NERD) patients are nonresponsive to proton pump inhibitors (PPIs). Antidepressants such as nortriptyline might be useful to relieve heartburn by acting in the brain-esophagus axis. We aimed to assess the effect of nortriptyline on heartburn and cerebral activation in NERD patients evaluated with functional magnetic resonance imaging (fMRI).

**Methods:** Twenty NERD patients off PPIs ( $36.1 \pm 9.3$  years, 75% women) were randomly assigned to 21 days of nortriptyline (10 mg/day during 7 days and 25 mg/day for 14 days) or placebo followed by a 3-week washout period and then the opposite treatment. Patients were evaluated with a validated heartburn questionnaire (0 - no symptom/30 - worst) and fMRI at the end of each treatment.

**Results:** Both nortriptyline and placebo improved patients' symptoms compared to baseline. The basal heartburn score [median (IQR25-75%)] was 12.5 (9.2–16.0), but decreased to 8.0 (5.5–11.0) with nortriptyline ( $p = 0.001$ ), and to 7.0 (5.0–10.7) with placebo ( $p < 0.001$ ). After adjustments for anxiety and depression scores, the decrease of heartburn remained similar between the treatments. In comparison to baseline fMRI, nortriptyline reduced cerebral activation in eight out of nine areas of interest (Figure 1), while placebo decreased activation in only two areas. Differences between nortriptyline and placebo were observed on cingulate and hippocampus.



<sup>a</sup> $p < 0.05$  Baseline vs. Nortriptyline; <sup>b</sup> $p < 0.05$  Baseline vs. Placebo; <sup>c</sup> $p < 0.05$  Nortriptyline vs. Placebo

**Discussion:** In NERD patients off PPIs, both nortriptyline and placebo reduced heartburn. However, the decrease in brain activation was more pronounced with nortriptyline. These findings suggest that the brain is a modulator of heartburn in NERD patients.

**Disclosure:** All authors have declared no conflicts of interest.

---

**CONCURRENT SESSION C209: GERD: EXTRA-ESOPHAGEAL MANIFESTATIONS – October 17, 2012 13:30–15:00**

---

**C209.05 GASTROESOPHAGEAL REFLUX AND ASPIRATION OF GASTRIC CONTENTS IN PATIENTS WITH IDIOPATHIC PULMONARY FIBROSIS - A STUDY USING HRCT AND PH-IMPEDANCE**

Edoardo Savarino<sup>1</sup>, Patrizia Zentilin<sup>2</sup>, Elisa Marabotto<sup>2</sup>, Manuele Furnari<sup>2</sup>, Luca Sconfienza<sup>2</sup>, Giacomo Carlo Sturmiolo<sup>1</sup>, Vincenzo Savarino<sup>2</sup>

<sup>1</sup>University Of Padova, Padova/ITALY, <sup>2</sup>University Of Genova, Genova/ITALY

**Background:** There is increasing evidence on the potential pathogenetic role of gastro-esophageal reflux (GER) in idiopathic pulmonary fibrosis (IPF), but its prevalence and characteristics are unknown. To characterize GER in biopsy-proven IPF.

**Methods:** Forty consecutive IPF patients underwent pulmonary high-resolution computer tomography (HRCT) scan and impedance-pH monitoring. The presence of pulmonary fibrosis was assessed using validated HRCT-scores. Reflux features included distal esophageal acid exposure, number of acid and weakly-acidic reflux episodes and proximal migration of the refluxate. Forty consecutive patients with interstitial lung disease other than IPF (non-IPF patients) and 50 healthy volunteers (HVs) were enrolled for comparison.

**Results:** IPF patients had significantly higher ( $p < 0.01$ ) esophageal acid exposure (9.25[4.7–15.4] vs. 3.3[1.4–7.4] vs. 0.7[0.2–4.2]), number of acid (45[23–55] vs. 32[19–44] vs. 18[10–31]), weakly-acidic (34[19–43] vs. 21[11–33] vs. 18[15–28]) and proximal reflux events (51[26.5–65.5] vs. 20[9.5–34.5] vs. 9[5–20]) compared to non-IPF patients and HVs. Pulmonary fibrosis HRCT-scores correlated well with reflux episodes in both distal ( $r_2 = 0.567$ ) and proximal ( $r_2 = 0.6323$ ) esophagus. Patients with IPF had more bile acids and pepsin ( $p < 0.03$ ) in BAL (62% and 67%) and saliva (61% and 68%) than non-IPF patients (25% and 25% in BAL, 33% and 36% in saliva) and controls (0% and 0% in both BAL and saliva).

**Discussion:** Increased acid and weakly acidic GER as well as more reflux reaching the proximal esophagus are prevalent in IPF. Patients with IPF have also evidence of gastric aspiration. Outcome studies with intense anti-reflux therapy are needed to confirm the deleterious role of reflux in IPF progression.

**Disclosure:** All authors have declared no conflicts of interest.

---

**ORAL SESSION O01: ESOPHAGEAL CARCINOGENESIS (1) – October 15, 2012 13:30–15:00**

---

**O01.01 COLUMNAR METAPLASIA IN THE ESOPHAGEAL REMNANT FOLLOWING ESOPHAGECTOMY - A COMMON OCCURANCE AND A VALUABLE INSIGHT INTO THE DEVELOPMENT OF BARRETT'S ESOPHAGUS**

Lorna Dunn<sup>1</sup>, Jon Shenfine<sup>2</sup>, Alastair Burt<sup>1</sup>, Janusz Jankowski<sup>3</sup>, S Michael Griffin<sup>2</sup>

<sup>1</sup>Northern Oesophagogastric Cancer Unit, Newcastle Upon Tyne/UNITED KINGDOM, <sup>2</sup>Northern Oesophago-Gastric Cancer Unit, Royal Victoria Infirmary, Newcastle Upon Tyne/UNITED KINGDOM, <sup>3</sup>Queen Mary University Of London, London/UNITED KINGDOM

**Background:** Columnar metaplasia has been described in the remnant esophagus following subtotal esophagectomy. This study assessed the incidence of this phenomenon and the molecular similarity of this 'neo-Barrett's' esophagus to sporadically occurring Barrett's esophagus (BE).

**Methods:** Patients underwent prospective endoscopic evaluation having previously undergone esophagectomy. The presence or absence of metaplastic columnar epithelium above the surgical anastomosis was noted and biopsies taken. Specimens were stained using H&E stains and, where consent was granted, for immunohistochemical stains for cytokeratins 7 and 20 and Chromogranin A (CGA), which have a well described expression pattern in Barrett's esophagus. Samples were also assessed for the presence of trefoil factors (TFFs), peptides postulated to have a role in the maintenance of mucosal integrity and tumorigenesis.

**Results:** Of 126 patients evaluated, 45 (36%) had endoscopic evidence of columnar metaplasia with histological corroboration (neo-Barrett's). Prevalence of neo-Barrett's increased with time from surgery. Non-intestinalised columnar epithelium was observed to occur earlier than neo-Barrett's with specialised intestinal metaplasia. Incidence of neo-Barrett's was similar regardless of indication for surgery. 37 samples underwent molecular analysis. A classical, Barrett's like CK7/20 staining pattern was present in 23 cases (62%), CGA expression was present in all cases. Trefoil peptides were expressed by neo-Barrett's epithelium but not by squamous epithelium from the same patients.

**Discussion:** Columnar metaplasia is common following esophagectomy and increases with time. It expresses CKs, CGA and TFFs with a similar incidence to that seen in sporadic BE suggesting that post-esophagectomy patients are a suitable human model in which to study development of Barrett's esophagus

**Disclosure:** J. Jankowski: Astra Zeneca

All other authors have declared no conflicts of interest.

**O01.02 PREOPERATIVE GASTRIC ACID SECRETION AS A PREDICTOR TO EARLIER DEVELOPMENT OF BARRETT'S ESOPHAGUS IN THE ESOPHAGEAL STUMP AFTER ESOPHAGECTOMY FOR ACHALASIA**

Julio Rocha<sup>1</sup>, Ulysses Ribeiro<sup>2</sup>, Flavio Roberto Takeda<sup>1</sup>, Ary Nasi<sup>1</sup>, Sergio Szachnowicz<sup>1</sup>, Francisco Seguro<sup>1</sup>, Rubens Sallum<sup>1</sup>, Ivan Ceconello<sup>1</sup>

<sup>1</sup>Department Of Gastroenterology – Esophageal Surgical Division, University Of São Paulo School Of Medicine, São Paulo - Brazil, São Paulo/BRAZIL, <sup>2</sup>Department Of Gastroenterology - Esophageal Surgical Division - University Of São Paulo School Of Medicine, São Paulo/BRAZIL

**Background:** Background: Esophagectomy with gastric pull-up and cervical esophago-gastric anastomoses is an option for end stage achalasia. Cervical esophagitis and Barrett's has been associated with this technique. Aim: To determine preoperative conditions, regarding to gastric secretory and hormonal response, associated to the development of Barrett's in the esophageal stump.

**Methods:** Methods: 101 patients submitted to esophagectomy were followed-up prospectively for a mean of  $10.5 \pm 8.8$  years. All patients underwent clinical, endoscopic and histopathologic evaluation every two years. Thirty-six patients (35.6%) had developed columnar metaplasia during follow-up. Gastric acid secretion (GAS) in basal condition and after penta-gastrin stimulation (MAO) and basal gastrin serum levels were measured preoperatively in 14 patients that developed Barrett's esophagus (Group I), and the results were compared to 24 patients who did not have Barrett's esophagus (Group II).

**Results:** Results: In the group I, the mean basal and pentagastrin stimulated gastric acid secretion was significantly higher than in the non Barrett group (basal: 1.52 vs. 1.04,  $p = 0.04$ , stimulated: 19.40 vs. 13.78,  $p = 0.03$ ). There was no difference in serum gastrin between the two groups. Moreover, gastritis was present during endoscopic examination in 64.2% of the Group I, while it was detected in 16.6% of the Group II,  $p = 0.006$ .

**Discussion:** Conclusions: Higher preoperative levels of gastric acid secretion are significantly associated with earlier development of B.E. The higher the preoperative GAS, the sooner the Barrett's manifestation. Lower preoperative GAS levels had delayed Barrett's development.

**Disclosure:** All authors have declared no conflicts of interest.

**O01.03 THE RISING INCIDENCE OF ESOPHAGEAL ADENOCARCINOMA IS NOT ACCOMPANIED WITH AN INCREASE IN MORTALITY: RESULTS OF A POPULATION-BASED COHORT STUDY**

Romy Verbeek, Max Leenders, Fiebo Ten Kate, Frank Vleggaar, Jantine Van Baal, Peter Siersema, Martijn Van Oijen  
University Medical Center Of Utrecht, Utrecht/NETHERLANDS

**Background:** The incidence of esophageal adenocarcinoma (EAC) is rising faster than any other malignancy. The aim was to 1) confirm the rising EAC incidence rate, 2) identify a parallel increasing incidence in the proportion of a prior diagnosis of BE, 3) analyze the absolute 1-year mortality rate, and 4) the adjusted one-year mortality risk over time.

**Methods:** All patients diagnosed with EAC between 1999 and 2009 were identified in the Dutch cancer registry and linked to PALGA, the nationwide histopathology registry. Multivariate Cox regression analysis was performed to calculate adjusted hazard ratios (HR) for 1-year mortalities for each incidence year. HRs were adjusted for age, gender, prior BE diagnosis, tumor differentiation grade and stage, type of hospital and treatment.

**Results:** From 1999–2009, 9,855 patients were diagnosed with EAC. EAC incidence rate increased from 5.2 per 100,000 in 1999 to 10.0 in 2009. The proportion of patients with a BE diagnosis <1 year prior to EAC detection did not change over time. The absolute 1-year mortality rate did not substantially increase over time, whereas the adjusted 1-year mortality risk decreased (e.g. HR 0.67,95%CI0.58-0.78 in 2009 vs. 1999). This was likely to be explained by the treatment strategy, as including this factor in the analysis abolished the association between incidence year and mortality.

**Discussion:** CONCLUSION: The steep increase in EAC incidence was neither accompanied with an increase in the proportion of patients with a

prior BE diagnosis, nor with an increase in absolute one-year mortality. The adjusted one-year mortality risk however decreased.

**Disclosure:** P. Siersema: PD Siersema has received unrestricted research grant support from AstraZeneca B.V., Janssen B.V. and Shire Movetis Ltd.

M. van Oijen: Martijn G.H. van Oijen has received unrestricted research grant support from AstraZeneca BV and Janssen BV, and serves as a consultant for AstraZeneca BV.

All other authors have declared no conflicts of interest.

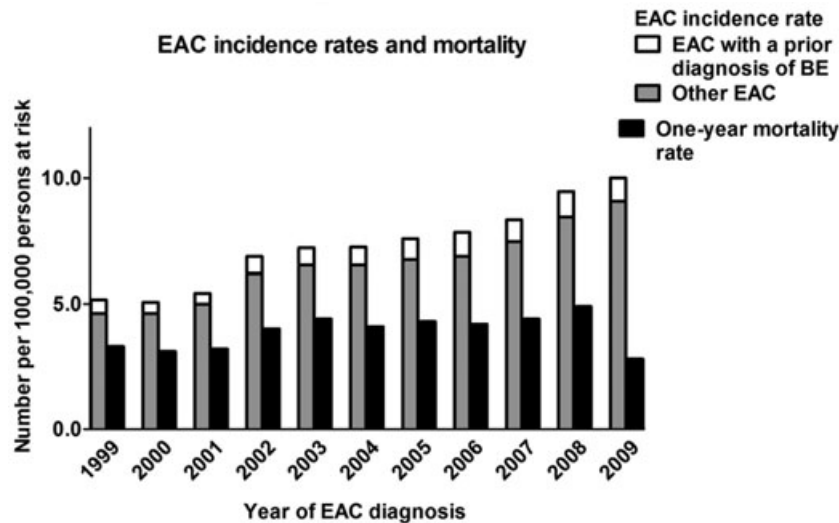


Figure 1 EAC incidence rates and mortality

#### 001.04 FAMILIAL CLUSTERING OF BARRETT'S ESOPHAGUS AND ESOPHAGEAL ADENOCARCINOMA

Romy Verbeek<sup>1</sup>, Lisanne Spittuler<sup>1</sup>, Anique Peute<sup>1</sup>, Martijn Van Oijen<sup>1</sup>, Fiebo Ten Kate<sup>1</sup>, Reinoud Vermeijden<sup>2</sup>, Ardi Oberndorff<sup>3</sup>, Jantine Baal<sup>1</sup>, Peter Siersema<sup>1</sup>

<sup>1</sup>University Medical Center Of Utrecht, Utrecht/NETHERLANDS,

<sup>2</sup>Meander Medisch Centrum, Amersfoort/NETHERLANDS,

<sup>3</sup>Diakonessenhuis, Utrecht/NETHERLANDS

**Background:** We aimed to determine clustering of reflux symptoms, BE and EAC in 1st and 2nd degree relatives of patients with BE or EAC and to identify differences between familial and non-familial cases.

**Methods:** A questionnaire was sent to all patients (n = 838) with BE (≥2 cm) or EAC from 2000–2011 in three hospitals. Information about risk factors, reflux symptoms, and family history was collected. Diagnoses of affected relatives were confirmed in the nationwide histopathology database (PALGA). Familial BE status was defined as 'definitive' with >1 first or second degree relative with BE or EAC, 'possibly' with reported BE or esophageal cancer but not histologically confirmed, 'unlikely' with a negative family history, or 'unknown'.

**Results:** A total of 595 patients responded (response 71%). Familial BE was 'definitive' in 6%, 'possibly' in 6%, 'unlikely' in 49% and 'unknown' in 39%. Definitive familial BE cases reported reflux symptoms in 11% of 1st degree relatives compared to 5% in unlikely familial BE (p < 0.001). For upper endoscopy this was 5% vs. 2% (p < 0.01). Definitive familial BE cases were younger at onset of heartburn compared to unlikely familial BE: 29% vs. 11% <20 years (p < 0.01). No differences in BMI, smoking, alcohol consumption, hiatal hernia, severity of reflux symptoms, age at diagnosis, BE segment length, and highest dysplasia grade were found.

**Discussion:** This study shows that familial BE is present in 6% of patients with BE and EAC. Familial cases reported more often reflux symptoms and a prior upper endoscopy in family members and were younger at onset of reflux symptoms.

**Disclosure:** M. van Oijen: Martijn G.H. van Oijen has received unrestricted research grant support from AstraZeneca BV and Janssen BV, and serves as a consultant for AstraZeneca BV.

P. Siersema: PD Siersema has received unrestricted research grant support from AstraZeneca B.V., Janssen B.V. and Shire Movetis Ltd.

All other authors have declared no conflicts of interest.

#### 001.05 NEXT GENERATION SEQUENCING OF MULTIPLE FAMILIES WITH INHERITED BARRETT'S ESOPHAGUS

Henry To<sup>1</sup>, Cuong Duong<sup>1</sup>, Alison Trainer<sup>2</sup>, Nicholas Clemons<sup>1</sup>, Richard Tohill<sup>3</sup>, Robert Thomas<sup>1</sup>, Wayne Phillips<sup>1</sup>

<sup>1</sup>Division Of Cancer Surgery, Peter MacCallum Cancer Centre, East

Melbourne/VIC/AUSTRALIA, <sup>2</sup>Peter MacCallum Cancer Centre, East

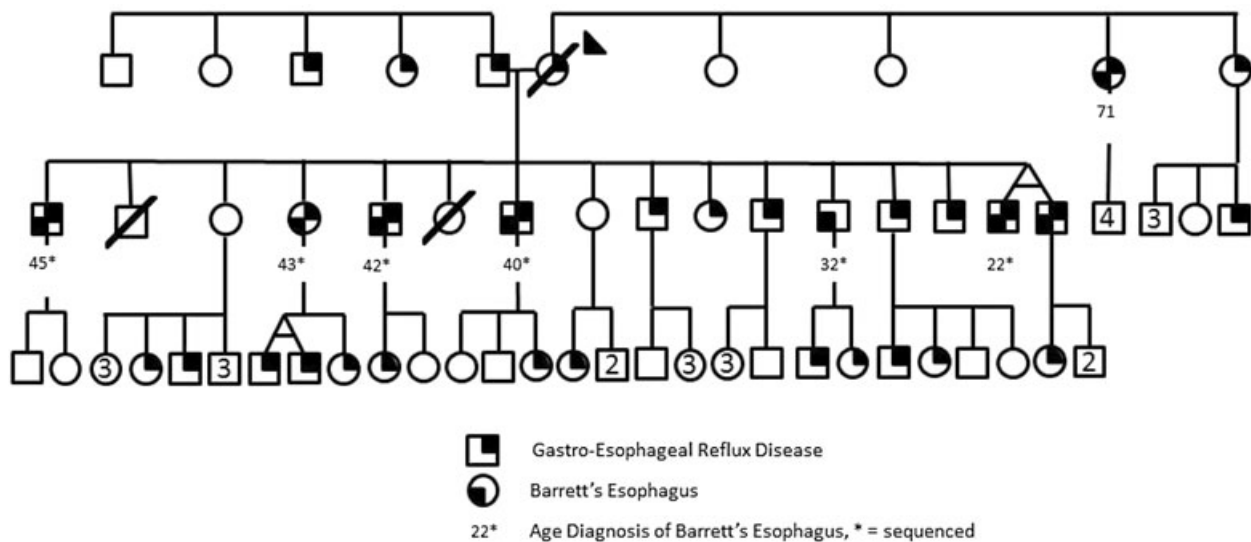
Melbourne/VIC/AUSTRALIA, <sup>3</sup>Ian Potter Centre For Cancer Genomics

And Predictive Medicine, Peter MacCallum Cancer Centre, East Melbourne/VIC/AUSTRALIA

**Background:** Barrett's Esophagus (BE) has previously been reported in familial cohorts implying underlying genetic origin and inheritance. Traditional linkage analysis studies on these groups have failed to identify precise causative genetic variants in familial BE. Therefore, we aimed to determine these by performing complete genetic analysis on affected individuals using Next Generation Sequencing (NGS).

**Methods:** Clinical data, oesophageal biopsies and blood were gathered from 12 families with distinctive inheritance of BE. Initially selecting 12 affected and 1 unaffected individual across 3 highly penetrant families, DNA was isolated with whole exome capture, then NGS was performed. Variants (causing downstream change to protein sequence) were identified by comparison with publically accessible human reference genomes and between samples. Variants were validated via conventional Sanger sequencing to confirm NGS and filtering methods.

**Results:** NGS produced an average of 23187 variants per individual. Combining data sets, quality control filtering, and then applying algorithms to identify genetic variants likely to induce a change in protein function, reduced candidate variants to 893 (4.2%) per family. Of these, 70 (0.3%) were novel and 17 (0.07%) had significant protein functional effects. Validation of variants confirmed our filtering and predictive methods. Segregation analysis (via Sanger sequencing in affected and non-affected individuals in the same family) thus identified variants for further analysis of their role in the development of BE in these families.



**Discussion:** The combination of high penetrant cohorts (in familial BE) and comprehensive genetic analysis (NGS) is a validated, robust method which has clearly refined the candidate genetic pathways in familial BE. This provides stronger direction on possible molecular mechanisms which may then be tested in sporadic cohorts.

**Disclosure:** All authors have declared no conflicts of interest.

**001.06 PREDICTORS OF MORTALITY IN PATIENTS WITH ESOPHAGEAL ADENOCARCINOMA IN A LARGE POPULATION-BASED COHORT**

Romy Verbeek, Max Leenders, Martijn Van Oijen, Fiebo Ten Kate, Frank Vleggaar, Jantine Baal, Peter Siersema  
University Medical Center Of Utrecht, Utrecht/NETHERLANDS

**Background:** The prognosis of esophageal adenocarcinoma (EAC) remains poor. Knowledge of predictors of mortality in EAC may aid in improving its prognosis. We aimed to identify predictors of 2-year mortality in a large nationwide population-based cohort of patients with EAC.

**Methods:** All patients diagnosed with EAC between 1999 and 2009 were identified in the cancer registry. These data were linked to PALGA, a nationwide histopathology registry. Multivariate Cox proportional hazards regression analysis was performed to identify predictors of 2-year mortality. Surveillance participation was defined as  $\geq 1$  additional biopsy sampling episode between the first BE diagnosis and EAC detection.

**Results:** In total, 9,243 patients diagnosed with EAC were identified. Two-year mortality rate was 72% (6,627) during a median follow-up of 0.8 (IQR 0.3–1.6) person-years. Two-year mortality was increased in EAC patients aged between 60–80 years (hazard ratio (HR) 1.13, 95%CI1.07-1.21) and  $>80$  years (HR1.27, 95%CI1.17-1.39) compared to  $<60$  years, and for EACs in the upper third of the esophagus (HR1.24, 95%CI1.01-1.53). Mortality was reduced when participating in a surveillance program prior to EAC (HR0.73, 95%CI0.64-0.82), in well-differentiated (HR0.62, 95%CI0.52-0.74) and moderately differentiated (HR0.76, 95%CI0.71-0.81) EACs, in lower tumor stage (eg. stage 0 vs. IV HR0.16, 95%CI0.09-0.27), when treatment was (partially) performed in a university hospital (HR0.84, 95%CI0.78-0.90), and when surgery was combined with neoadjuvant chemo/radiotherapy (HR0.62, 95%CI0.53-0.72).

**Discussion:** Mortality was decreased when EAC patients were known with prior surveillance, when treatment was (partially) performed in a university hospital, with a lower tumor stage at diagnosis and when surgery was combined with neoadjuvant chemo/radiotherapy.

**Disclosure:** M. van Oijen: Martijn G.H. van Oijen has received unrestricted research grant support from AstraZeneca BV and Janssen BV, and serves as a consultant for AstraZeneca BV.

P. Siersema: PD Siersema has received unrestricted research grant support from AstraZeneca B.V., Janssen B.V. and Shire Movetis Ltd.

All other authors have declared no conflicts of interest.

**001.07 OESOPHGEAL ADENOCARCINOMA INCIDENCE CONTINUES TO RISE IN ENGLAND DESPITE IMPROVED ACCURACY OF DATA; AN ANALYSIS OF TRENDS IN NATIONAL INCIDENCE BETWEEN 1971 TO 2008.**

Nathan Grimes<sup>1</sup>, Nikhil Misra<sup>2</sup>, Mark Hartley<sup>3</sup>, Nathan Howes<sup>3</sup>  
<sup>1</sup>University Of Liverpool, Liverpool/UNITED KINGDOM, <sup>2</sup>Digestive Diseases Unit, Liverpool/UNITED KINGDOM, <sup>3</sup>Department Of Upper Gi Surgery, Liverpool/UNITED KINGDOM

**Background:** Recent reports from some Western units have observed the previously described rising incidence of oesophageal adenocarcinoma (OA) having reached a plateau. We examined national level data to document this change in England.

**Methods:** Oesophageal cancer (OC) registration data between 1971 and 2008, broken down by year, sex, histology and anatomical subsite were obtained from the National Cancer Intelligence Unit, England. Data were age standardized to standard population data and examined for statistical significance by a least squares linear regression model.

**Results:** In males, OC increased in incidence from 7.46 to 14.45/100,000 between 1971 and 2008. A constantly rising incidence of OA contributed significantly, increasing from 0.74 in 1971 to 9.71/100,000 in 2008. Squamous cancers increased from 1.17 to 3.25/100,000 in 2000, but then decreased to 2.85/100,000 in 2008.

In females, OC increased from 4.0/100,000 in 1971 to 5.74/100,000 in 2000, then decreased to 5.26/100,000 in 2008. OA continued to slowly increase from 0.15/100,000 in 1971 to 1.9/100,000 in 2008. Squamous cancers also increased up to 2.89/100,000 then decreased to 2.52/100,000 in 2008.

The proportion of all cancer registrations unspecified for anatomical subsite decreased from 75% in 1971 to 27% in 1994 for both sexes, then at a lower rate to between 13–16% in 2008.

**Discussion:** OC and OA continue to increase in incidence in males, despite improved accuracy in registration data.

**Disclosure:** All authors have declared no conflicts of interest.

**001.08 TOLL-LIKE RECEPTOR 4 ACTIVATION IN BARRETT'S ESOPHAGUS MAY PROMOTE THE DEVELOPMENT OF ESOPHAGEAL ADENOCARCINOMA THROUGH INDUCTION OF COX-2**

Romy Verbeek<sup>1</sup>, Peter Siersema<sup>1</sup>, Fiebo Ten Kate<sup>1</sup>, Rhonda Souza<sup>2</sup>, Frank Vleggaar<sup>1</sup>, Pauline Bus<sup>1</sup>, Jantine Van Baal<sup>1</sup>  
<sup>1</sup>University Medical Center Of Utrecht, Utrecht/NETHERLANDS, <sup>2</sup>University Of Texas Southwestern Medical Center, Va North Texas Health Care System, Texas/UNITED STATES OF AMERICA

**Background:** Barrett's esophagus (BE) progresses to esophageal adenocarcinoma (EAC) in a setting of chronic inflammation. Toll-like receptor (TLR) 4 has been linked to inflammation associated carcinogenesis, however the role of TLR4 in the esophagus remains unknown. We aimed to determine expression and functional activity of TLR4 in the esophagus and if TLR4 could promote carcinogenesis by inducing COX2 expression in BE.

**Methods:** Expression of TLR4 in EAC, BE, duodenum, reflux esophagitis (RE) and normal squamous esophagus (SQ) biopsies was assessed using

real-time PCR and validated by in situ hybridization and immunohistochemistry (IHC). Esophageal cell lines and ex vivo cultures of BE, duodenum and SQ biopsies were stimulated with the TLR4 agonist lipopolysaccharide (LPS). To evaluate functional activity of TLR4, NF- $\kappa$ B activation, IL8 secretion and IL8 and COX2 expression were determined.

**Results:** LPS stimulation resulted in NF- $\kappa$ B activation and a dose dependent increase of IL8 secretion and mRNA expression. Upon LPS stimulation, COX-2 expression increased significantly in ex vivo cultured BE biopsies, however no effect was found in ex vivo cultured duodenum and SQ biopsies. IHC showed a strong increase of COX-2 expression in both epithelium and lamina propria cells following LPS incubation in ex vivo cultured BE biopsies.

**Discussion:** TLR4 activation in BE may contribute to malignant transformation through induction of COX-2.

**Disclosure:** P. Siersema: PD Siersema has received unrestricted research grant support from AstraZeneca B.V., Janssen B.V. and Shire Movetis Ltd.

All other authors have declared no conflicts of interest.

#### 001.09 LOCATION OF HIGH GRADE DYSPLASIA AND ADENOCARCINOMA WITHIN COLUMNAR LINED ESOPHAGUS AND ITS RELATIONSHIP TO EPITHELIAL TYPES.

Parakrama Chandrasoma, Juan Guo, Steven R Demeester, Jeffrey A Hagen, Tom R Demeester  
Keck School Of Medicine, University Of Southern California, Los Angeles  
CAUNITED STATES OF AMERICA

**Background:** The location of high grade dysplasia (HGD) and adenocarcinoma within Barrett esophagus (BE) provides insight into the pathogenesis of esophageal adenocarcinoma.

**Methods:** We identified 36 patients with HGD/adenocarcinoma who had four-quadrant biopsies at 1–2 cm intervals of the segment of BE during 2004–2008. We mapped the epithelial types (oxyntocardiac, cardiac and intestinal) and their relationship to the location of HGD/adenocarcinoma.

**Results:** In 22 patients with a CLE segment greater than 7 cm, the epicenter of HGD/adenocarcinoma was in the distal half of the IM within CLE. In 10 patients, the epithelium proximal to HGD/adenocarcinoma had IM and that distal to it did not. In all 36 patients, intestinal metaplasia (IM) was present between the proximal limit of HGD/adenocarcinoma and the squamocolumnar junction to a length from 1 to 13 cm. In 16 patients, HGD/adenocarcinoma extended to the end of the tubal esophagus. In the other 20 patients the epithelium between the distal limit of the HGD/adenocarcinoma and the end of the tubal esophagus was IM in 10, cardiac in 8 and oxyntocardiac in 2.

**Discussion:** HGD/adenocarcinoma tends to occur in the distal region of IM within CLE. Columnar epithelia without IM are found only distal to the tumor. This indicates that carcinogenesis occurs in the region where carcinogen delivered to the esophagus by reflux interacts with IM within the segment of CLE and not in CLE without IM. This suggests that any increase in the extent of IM into the distal region of CLE increases the risk of HGD/adenocarcinoma in patients with BE.

**Disclosure:** All authors have declared no conflicts of interest.

#### ORAL SESSION O02: SURGICAL TREATMENT OF ESOPHAGEAL CANCER (1) – October 15, 2012 15:30–17:00

##### 002.01 THE MERENDINO PROCEDURE VERSUS GASTRIC PULL-UP FOR EARLY CANCER AND BENIGN DISEASES OF THE ESOPHAGO-GASTRIC JUNCTION.

Ermanno Ancona<sup>1</sup>, Gianpietro Zanchettin<sup>1</sup>, Valentina Belfontali<sup>2</sup>, Renato Salvador<sup>1</sup>, Luca Faccio<sup>1</sup>, Silvia Mantoan<sup>3</sup>, Michele Valmasoni<sup>4</sup>, Tiziana Morbin<sup>1</sup>, Loredana Nicoletti<sup>1</sup>, Matteo Cagol<sup>5</sup>, Mario Costantini<sup>6</sup>, Alberto Ruol<sup>1</sup>

<sup>1</sup>University Of Padua, Department Of Surgical And Gastroenterological Sciences, Clinica Chirurgica 1, Padua/ITALY, <sup>2</sup>University Of Padua, Department Of Surgical And Gastroenterological Sciences, Clinica Chirurgica 1, Padova/ITALY, <sup>3</sup>Clinica Chirurgica 1, Policlinico Padova, Padova/ITALY, <sup>4</sup>University Of Padua, Department Of General Surgery And Organ Transplant - 1st Surgical Clinic, Padova/ITALY, <sup>5</sup>Surgical Oncology, Veneto Oncological Institute, Padova/ITALY, <sup>6</sup>University Of Padua, Padua/ITALY

**Background:** The Merendino procedure (MER) consists in a limited resection of the esophago-gastric junction (EGJ) with jejunal loop interposition as an alternative to more extended esophago-gastric resection for the treatment of early cancer (K) or complicated/recurrent benign diseases (B).

**Methods:** From 2006 to 2011, 16 patients underwent MER, 7 for K and 9 for B. Data regarding postoperative morbidity and mortality, clinical and instrumental follow-up and quality of life (SF-36, GIQLI) were evaluated and compared to 12 patients who underwent esophagectomy and gastric pull-up (EGP), 6 for K and 6 for B.

**Results:** No differences between MER and EGP patients were found in terms of sex, age, postoperative morbidity and mortality. Median follow-up was 17,6 months. Heartburn was referred in 4 (26,7%) MER vs. 6 (50%) EGP patients; acid reflux sensation was present in 50% vs. 100%, respectively; the prevalence of other symptoms was comparable. At 1-year endoscopy, supra-anastomotic esophagitis was found in 0% MER vs. 9 (81,8%) EGP patients,  $p < 0.0001$ ; the interposed jejunal loop was always free of acid-related alterations. pH-metry showed a pathologic DeMeester-Score in 1 (7,1%) MER vs. 10 (90,9%) EGP patients,  $p < 0.0001$ . Five (33,3%) MER patients were actually on PPI vs. 9 (75%) EGP patients,  $p = 0.05$ . There was no difference in impedance results and in quality of life scores between the 2 groups.

**Discussion:** Limited resection of the EGJ with MER, acting as a functional sphincter, seems to be an appropriate procedure as an alternative to esophago-gastric resection for selected patients with early EGJ cancer or complicated/recurrent benign diseases.

**Disclosure:** All authors have declared no conflicts of interest.

##### 002.02 MUCOSAL INJURY IN THE REMNANT ESOPHAGUS AFTER IVOR-LEWIS ESOPHAGECTOMY

Jessica Leers, Moritz Meissner, Hans Fuchs, Wolfgang Schröder, Marc Bludau, Christian Gutschow, Elfriede Bollschweiler, Arnulf Hölscher  
Department Of General, Visceral And Tumorsurgery, University Of Cologne, Cologne/GERMANY

**Background:** The development of mucosal injury namely esophagitis or intestinal metaplasia after Ivor- Lewis esophagectomy and gastric transposition has been described. But little is known about the progress from squamous cell epithelium to esophagitis and intestinal metaplasia in these patients. The aim of this study is to evaluate if the incidence of mucosal injury is more frequent in patients with former adenocarcinoma (AC) compared to patients with squamous cell carcinoma (SCC).

**Methods:** We reviewed our prospectively maintained database of patients with esophagectomy for patients who underwent Ivor Lewis esophagectomy with gastric transposition for carcinoma. All patients who presented in the last 4 months in outpatients clinic for regular tumor follow-up were included. The study population consist of 50 patients (9 women). The median follow-up was 45 months. Thirty-seven patients had AC and 23 patients SCC.

**Results:** All but three patients were treated with proton pump inhibitors disregarding reflux symptoms. Nevertheless, reflux symptoms were evident in 18 patients (36%) with none significant distribution between SCC (17,4%) and ACC (37,8%). In upper endoscopy, mucosal injury was detected in 23 patients with AC (62,1%) and in 2 patients with SCC (8,7%,  $p < 0,0001$ ). Histopathologic verification of mucosal damage was demonstrated in 20 and 5 patients for AC and SCC, respectively ( $p = 0,017$ ).

**Discussion:** We were able to demonstrate that patients with adenocarcinoma had significant more mucosal injury after Ivor Lewis esophagectomy with gastric transposition. Although the reconstruction is equal in both groups, almost exclusively patients with adenocarcinoma developed reflux associated injuries in the remnant esophagus.

**Disclosure:** All authors have declared no conflicts of interest.

##### 002.03 IMPACT OF PERIOPERATIVE FLUID RESTRICTION ON POSTOPERATIVE PULMONARY COMPLICATIONS FOLLOWING ESOPHAGECTOMY FOR CANCER – A PARALLEL-GROUP RANDOMIZED CONTROLLED TRIAL

C S Pramesh, Vijaya Patil, George Karimundackal, Sabita Jiwnani, Jigeeshu Divatia, Atul Kulkarni, Rajesh Mistry  
Tata Memorial Hospital, Mumbai/INDIA

**Background:** Perioperative fluid management is controversial in esophageal surgery. There is no consensus on the superiority of either goal-directed supranormal fluid delivery or restricted fluid administration. Fluid restriction may reduce pulmonary complications by decreasing lung water and interstitial lung edema after extensive mediastinal dissection. We performed a parallel-group randomized trial to test this hypothesis.

**Methods:** We randomized patients undergoing transhiatal or transthoracic esophagectomy in a tertiary referral cancer centre in Mumbai. Patients without cardiac, renal or hepatic dysfunction between 18 and 70 years were randomized to conventional (guided by preoperative deficits, central venous pressure etc) or restricted (targeting urine output of 0.5 ml/kg/hour) perioperative fluid administration. Operative approach and radicality of



lymphadenectomy were stratification factors. Randomization was computer-generated and allocation concealment done by telephonic randomization. Neither patients nor care-givers were blinded. The primary end-point was postoperative pulmonary complications and secondary end-points were other postoperative complications, ICU and hospital stay. The study was prematurely terminated after an interim analysis when 183 of the planned 324 patients were randomized.

**Results:** One hundred and eighty three patients were randomly allocated to conventional(90) or restricted(93) fluid administration. All randomized patients were analysed on intention-to-treat. Postoperative pulmonary complications (22.6% vs 23.3%,  $p = 1$ ) were identical in the two groups. Cardiac and renal complications, need for prolonged ventilation, frequent bronchoscopic suctioning and tracheostomy, ICU and hospital stay, anastomotic leaks and mortality were also similar in the two groups.

**Discussion:** This prematurely terminated randomized trial failed to demonstrate the superiority of perioperative fluid restriction in patients undergoing esophagectomy.

**Disclosure:** All authors have declared no conflicts of interest.

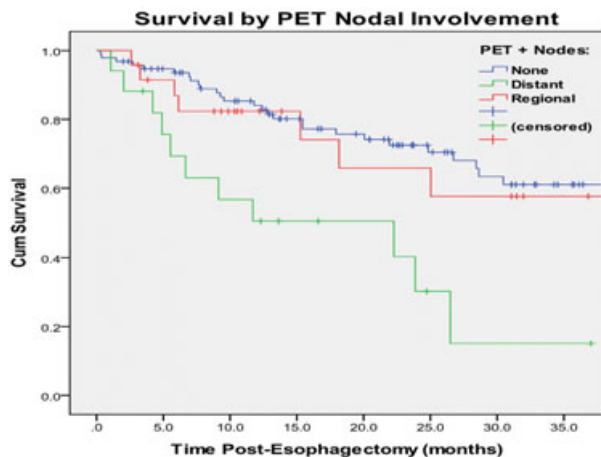
#### 002.04 OUTCOME OF PATIENTS WITH ESOPHAGEAL ADENOCARCINOMA AND OLIGOMETASTATIC NODAL DISEASE ON PRETREATMENT STAGING PET/CT

*Nikita Chapurin, Christian Peyre, Stefan Niebisch, Candice Wilshire, Thomas Watson, Virginia Litle, Carolyn Jones, Jeffrey H Peters University Of Rochester Medical Center, Rochester/NY/UNITED STATES OF AMERICA*

**Background:** The introduction of PET/CT for staging of esophageal cancer has led to increased detection of potentially pathologic lymph nodes outside the field of resection. For distal esophageal adenocarcinoma, this includes nodes above the carina and below the celiac axis. Whether these findings preclude cure is largely unknown. Our aim was to assess the prevalence and outcomes of this clinical scenario.

**Methods:** A retrospective review of 136 patients with esophageal adenocarcinoma undergoing pretreatment PET or PET/CT was performed. Hypermetabolic nodes with SUVmax > 1.5 were considered positive. All patients underwent an esophagectomy, 82/136 received neoadjuvant therapy (45 chemotherapy, 37 chemoradiotherapy). Survival rates for patients with PET-N0, positive regional, and distant nodes were compared.

**Results:** On initial PET, 28% (38/136) of patients had hypermetabolic nodes (median SUVmax = 3.4), having on average 2.1 nodes. Median primary tumor SUVmax was higher in patients with hypermetabolic nodes (9.8 vs. 4.8,  $p = 0.003$ ). Of patients with positive nodes, 45% (17/38) had at least one distant node. All patients with distant and 76% of patients with regional nodes, underwent neoadjuvant therapy. Distant lymphadenopathy resolved in 86% (15/17) of patients, and regional lymphadenopathy resolved in 80% (17/21). Three-year survival post-esophagectomy was 17.8% (mean 17.2 months) for patients with distant nodes, 56.8% (37.3 months) with regional nodes, and 60.0% (42.8 months) with negative nodes ( $p = 0.056$ ).



**Discussion:** Pretreatment detection of hypermetabolic lymphadenopathy in distant nodes for esophageal cancer is common, encompassing nearly half of node positive patients. Although a challenging circumstance, the finding of positive distant nodes on initial PET/CT does not necessarily represent incurable metastatic disease.

**Disclosure:** All authors have declared no conflicts of interest.

#### 002.05 IS PREOPERATIVE CHEMOTHERAPY OR CHEMORADIO THERAPY EFFECTIVE IN ERADICATING NODAL MICROMETASTASIS IN PATIENTS WITH ESOPHAGEAL CANCER?

*Tatsuya Kinjo<sup>1</sup>, Hideaki Shimoji<sup>1</sup>, Masayoshi Nagahama<sup>1</sup>, Hiroyuki Karimata<sup>1</sup>, Naoki Yoshimi<sup>2</sup>, Tadashi Nishimaki<sup>1</sup>  
<sup>1</sup>Department Of Digestive And General Surgery, Graduate School Of Medicine, University Of The Ryukyus, Okinawa/JAPAN, <sup>2</sup>Department Of Pathology And Oncology, Graduate School Of Medicine And Faculty Of Medicine, University Of The Ryukyus, Okinawa/JAPAN*

**Background:** Preoperative chemotherapy or chemoradiotherapy has been increasingly performed in patients with esophageal cancer. However, it is unclear whether radical lymphadenectomy is necessary in patients receiving preoperative chemotherapy or chemoradiotherapy, particularly in patients showing good response to the preoperative treatment. The aim of the study was to evaluate the residual status and the clinical implication of nodal micrometastasis (MM) in patients with esophageal cancer undergoing the preoperative treatment.

**Methods:** 76 patients undergoing esophagectomy for esophageal cancer were included in the study. Of those, 26 and 14 underwent chemotherapy and chemoradiotherapy before surgery due to the advanced stages, respectively. Presence or absence of MM and cyokeratin deposit (CD) which has been reported to be degenerated micro-metastatic cells was immunohistochemically assessed in 2308 lymph nodes retrieved from the patients.

**Results:** MM and CD was found in 46% and 36% of the 76 patients, respectively. The incidence of CD was significantly correlated with pN and MM. However, neither CD nor MM was correlated with the response status of the tumor to the preoperative treatment. Moreover, numerical grade of MM was not correlated with the response status of the tumor. Furthermore, MM was found in 50% of patients showing pathological complete response. Patients with MM showed significantly worse survival than those without MM. However, CD had no impact on the patients' survival.

**Discussion:** Our data suggest the necessity of radical lymphadenectomy in patients with esophageal cancer receiving preoperative treatment even in cases of good response to the treatment.

**Disclosure:** All authors have declared no conflicts of interest.

#### 002.06 ROBOT-ASSISTED THORACOSCOPIC OESOPHAGECTOMY FOR OESOPHAGEAL CANCER.

*Pieter Christiaan Van Der Sluis, Jelle Ruurda, R J J Verhage, S Van Der Horst, Richard Van Hillegersberg University Medical Center Utrecht, Utrecht/NETHERLANDS*

**Background:** Robot-assisted thoracoscopic oesophagectomy was introduced to reduce the morbidity and improve the oncologic outcomes of transthoracic oesophagectomy. The aim of this study was to assess intraoperative data, postoperative complications and oncologic results of robot-assisted thoracoscopic oesophagectomy for oesophageal cancer.

**Methods:** Between May 2007 and September 2011, 108 patients with resectable oesophageal cancer underwent robot-assisted thoracoscopic oesophagectomy in the UMC Utrecht. Clinical data were collected prospectively.

**Results:** Median operating time was 399 min (360–550) and median blood loss 590 (150–5300)ml. Median postoperative ventilation time was 0 days (0–64 days), intensive care stay 1 day (1–73 days) and hospital stay 16 days (9–123 days). Pulmonary complications were most common (35.5%) anastomotic leakage was observed in 18% of all patients. In hospital mortality was 4.5%. A radical resection (R0) was achieved in 94% of all patients with a median number of 29 dissected lymph nodes. Median time to recurrence was 8 months after a median follow-up of 14 months. Out of 108 patients, 40 patients had recurrence, 7 local (6.5%), 22 distant (20.4%) and 11 patients had both (10.2%).

**Discussion:** Conclusion:

Robot-assisted thoracoscopic oesophagectomy was feasible, safe and effective with a high percentage of R0 resections and a lymph node harvest comparable to open surgery. Compared to open surgery, robot-assisted thoracoscopic oesophagectomy shows reduced morbidity with at least comparable oncologic results.

**Disclosure:** All authors have declared no conflicts of interest.

#### 002.07 MINIMALLY INVASIVE ESOPHAGECTOMY: FEASIBILITY OF RADICAL MEDIASTINAL LYMPHADENECTOMY BY STANDARDIZED APPROACH IN PRONE POSITION

*Vaithiswaran V, Palanivelu C, Rajan P.S., Praveenraj P, Rajapandian S Gem Hospital And Research Center, 641045/INDIA*

**Background:** A radical approach to lymphadenectomy has been shown to improve survival in squamous cell carcinoma (SCC) of esophagus in some

series. Critics have questioned such radical procedure mentioning that the benefit is offset by increased post-operative morbidity and mortality. Minimally invasive esophagectomy (MIE) has been shown to have lesser morbidity. The question of increasing the radicality of MIE without increasing morbidity is still being answered. We analyzed our results to show that a standardized radical right thoracoscopic approach in prone position can achieve high lymph node yield without increase in morbidity and mortality.

**Methods:** Though MIE in prone position is being performed in our center for much more than a decade, a standardized radical lymphadenectomy approach has been introduced for last two years. A complete radical mediastinal lymphadenectomy including a thorough superior mediastinal lymphadenectomy with complete clearance of the recurrent laryngeal nerve nodes well into the root of the neck was performed. A radical abdominal lymphadenectomy and infra omohyoid lymphadenectomy were added during the abdominal and cervical phases of the surgery.

**Results:** 48 patients of middle and lower third SCC of esophagus underwent MIE in last two years. The average total lymph nodes and mediastinal lymph nodes harvested was 38(28–46) and 20(15–28) respectively which was significantly higher than that in pre-standardization period (mean total- 19, mediastinal-12). There was no mortality and no significant increase in morbidity.

**Discussion:** A standardized radical right thoracoscopic approach in prone position can achieve high lymph node yield without increase in morbidity and mortality.

**Disclosure:** All authors have declared no conflicts of interest.

#### 002.08 IS THERE A ROLE OF ROUTINE ORAL CONTRAST SWALLOW AFTER OESOPHAGECTOMY?

*Keng Ang, Lilin Hong, Lynda Beggs, David Beggs, John Duffy  
Nottingham City Hospital, Nottingham/UNITED KINGDOM*

**Background:** There is no consensus at present as to whether routine oral contrast swallow (OCS) should be performed after oesophagectomy to detect anastomotic leak. We investigate the value of OCS which is routinely performed in our department 7–14 days after oesophagectomy.

**Methods:** A retrospective notes review was performed on 1024 oesophagectomies performed for oesophageal cancer in our Unit between October 1991 and September 2009.

Age (years)	45	40	60	51	55	33	38
Pre-op CD4 count	354	332	N/A	625	753	N/A	279
Pre-op intervention	Dilation Stenting	None	None	None	Dilation Stenting	None	J-tube
WHO AIDS stage	I	I	III	I	I	I	II
Taking anti-retrovirals	No	No	No	No	Yes	No	Yes
Pathologic stage	T4aN1M0 stage IIIC	T3N0M0 stage IIa	T2N1M0 stage IIb	T2N0M0 Stage IIa	T3N1M0 Stage IIb	benign	benign
Length of stay (days)	17	11	8	14	14	13	21
Complication	Leak	None	ARDS Death	None	None	Stricture	Leak

**Discussion:** Esophagectomy is considered to be one of the most morbid operations, and when combined with AIDS has not been generally considered a reasonable surgical option. Although complications are not insignificant, in carefully selected patients it is a viable option.

**Disclosure:** All authors have declared no conflicts of interest.

#### ORAL SESSION 003: NEW DIAGNOSTIC MODALITIES FOR ESOPHAGEAL CANCER – October 16, 2012 08:00–09:50

##### 003.01 THE ROLE OF MAXIMUM STANDARDIZED UPTAKE VALUE IN POSITRON EMISSION TOMOGRAPHY AS A PROGNOSTIC FACTOR IN THE PATIENTS WITH OPERABLE ESOPHAGEAL SQUAMOUS CELL CARCINOMA

*Hee Chul Yang, In-hag Song, Wonsuk Choi, Jung-moon Lee, Kwhanmien Kim, Sanghoon Jheon, S W Sung, Sukki Cho  
Seoul National University Bundang Hospital, Seongnam-si/KOREA*

**Background:** Fluorodeoxy glucose-positron emission tomography/computed tomography (FDG-PET/CT) plays an important role in preoperative staging, assessment of treatment response and detection of recurrence in esophageal cancer. The aim of this study was to evaluate the role of maximum standardized uptake value (mSUV) of a main mass as a recurrence risk factor for recurrence in patients with completely resected esophageal squamous cell carcinoma.

**Methods:** Between June 2003 and August 2010, 118 patients underwent complete resection for esophageal squamous cell carcinoma at a single institution. Clinicopathologic factors including primary tumor location, number of posi-

**Results:** Ten patients (<1%) developed clinical leaks before their scheduled OCS, 2 of whom subsequently died in hospital from sepsis related multi-organ failure. 5 patients needed immediate re-operation. Less than 1% of the patients with normal swallows unfortunately developed evidence of a clinical leak once oral intake was started. In both situations, the clinical leaks were associated with high in-hospital mortality. Twenty-four (2%) patients had radiologically detected leaks, the majority being managed conservatively, without progression or the need for High Dependency care. There was only one in-hospital mortality, 2 re-operations and 1 patient had delayed stenting. Seven patients with suspected leaks (<1%) had no leaks evident on repeat scans within the next 2 weeks. The sensitivity and specificity of oral contrast swallow for detecting post-oesophagectomy radiological leak was 77% and 99% respectively.

**Discussion:** Our policy of routine post-operative contrast swallow before commencing oral intake appears to detect asymptomatic oesophageal leaks, which can be promptly treated before they develop into clinical leaks. This avoids the need for additional High Dependency care and the higher in-hospital mortality associated with clinical leaks.

**Disclosure:** All authors have declared no conflicts of interest.

##### 002.09 ESOPHAGECTOMY IN AIDS PATIENTS: A VIABLE OPTION?

*Russell White<sup>1</sup>, Michael Mwachiro<sup>1</sup>, Alan Thomay<sup>2</sup>*

*<sup>1</sup>Tenwek Hospital, Bomet/KENYA, <sup>2</sup>Memorial Sloan-Kettering Cancer Center, New York/NY/UNITED STATES OF AMERICA*

**Background:** Esophagectomy for patients meeting the WHO criteria for AIDS (not simply HIV positive), has generally not been considered a wise choice, due to studies showing increased morbidity and mortality for surgery in AIDS patients. Published reports of this major surgical undertaking in the setting of AIDS are nearly non-existent. However, as anti-retroviral therapy continues to become more accessible and the functional immune status and general health of our HIV patient population improves, we are re-evaluating AIDS patients requiring surgical intervention for esophageal disease.

**Methods:** We review the clinical course of 7 consecutive patients with AIDS who underwent esophagectomy at our institution.

**Results:** We present our experience of 7 patients with AIDS that underwent esophagectomy at our institution: **AIDS patients undergoing esophagectomy**

tive LN, existence of vascular or lymphatic invasion, mSUV, TNM staging, and the need for neoadjuvant and adjuvant therapy were analyzed retrospectively as recurrence risk factors. Cut-off value was obtained through the ROC curve. Logistic regression was used for the multivariate analysis.

**Results:** Median follow-up period was 34 months (range, 2–99). The mean mSUV of main mass was  $5.46 \pm 4.22$ . Forty four patients (37.3%) had tumor recurrence. Univariate analysis demonstrated that a tumor size of 3.5 cm or greater ( $p = 0.004$ ), more than T2 classification ( $p < 0.001$ ), need of adjuvant therapy ( $p < 0.001$ ) and mSUV of 5.1 or greater ( $p < 0.001$ ) were statistically associated with the recurrence. However, mSUV (>5.1) was the only recurrence risk factor that showed a significant difference in multivariate analysis ( $p = 0.01$ ).

**Discussion:** Preoperative FDG-PET/CT may attribute in predicting recurrence in the patients with operable esophageal squamous cell carcinoma. The mSUV was an independent predictor for recurrence with cut off value of 5.1.

**Disclosure:** All authors have declared no conflicts of interest.

##### 003.02 PREOPERATIVE ESTIMATION OF CURATIVE RESECTION FOR ADVANCED ESOPHAGEAL CANCER WITH ADJACENT ORGAN INVASION AFTER CHEMORADIATION BY QUALITATIVE RESPONSE EVALUATION USING 3D-VOLUME RENDERED MD-CT

*Shinichi Okazumi<sup>1</sup>, Kiyohiko Shuto<sup>2</sup>, Hisahiro Matsubara<sup>2</sup>, Ryoji Kato<sup>1</sup>*

*<sup>1</sup>Department Of Surgery, Toho University Sakura Medical Center, Chiba/JAPAN, <sup>2</sup>Department Of Frontier Surgery, Chiba University Graduate School Of Medicine, Chiba/JAPAN*

**Background:** By analyzing the change in the enhanced CT value of advanced esophageal cancer after neo-adjuvant chemoradiotherapy (CRT), a new

qualitative diagnostic image which represented the histological responses was developed using 3D-volume rendered MD-CT, and which was applied for the estimation of followed curative resection.

**Methods:** 60 cases of advanced esophageal cancer which underwent neoadjuvant CRT with followed resection were examined. Contrast media (300 mg iodine/ml, 3 ml/kg) was administered intravenously (3 ml/sec). CT scans were performed (slice thickness: 1.3 mm) at 50 seconds delay before and after CRT. The CT value changes of the materials were compared with the histological findings of specimens after surgery. A workstation was used for rendering the diagnostic image which represented histological response with specially selected colors and opacities.

**Results:** The enhanced CT values significantly decreased after CRT according to the tumor regression ; grade 1:  $66.0 \pm 8.46$ (HU), grade2:  $58.5 \pm 6.7$  ( $p < 0.05$ ), grade3:  $52.1 \pm 6.2$  ( $p < 0.001$ ). With the result, the area of below 50 HU was regarded as completely responded and a diagnostic image which represented responded area was rendered with color gradation and opacity. With the diagnostic image, 24 cancers which had adjacent organ invasion were successfully diagnosed as downstaged by CRT and curatively resected.

**Discussion:** The qualitative diagnostic image rendered by 3D-enhanced MD-CT was useful for the response evaluation and necessary to estimate curability of followed resection after CRT for advanced esophageal cancer.

**Disclosure:** All authors have declared no conflicts of interest.

### O03.03 A 3 MOLECULAR TARGET IMMUNOHISTOCHEMISTRY PANEL CAN AID PROGNOSTICATION OF PATIENTS WITH OESOPHAGO-GASTRIC CANCER

Chin-ann Johnny Ong<sup>1</sup>, Joel Shapiro<sup>2</sup>, Katie S Nason<sup>3</sup>, Jon Davison<sup>3</sup>, Xinxue Liu<sup>1</sup>, Caryn Ross-Innes<sup>1</sup>, Nicholas Shannon<sup>4</sup>, Laura K E Schulz<sup>1</sup>, Susannah Worster<sup>1</sup>, Bas Wijnhoven<sup>2</sup>, Richard H Hardwick<sup>5</sup>, Rebecca Fitzgerald<sup>1</sup>

<sup>1</sup>Mrc Cancer Cell Unit, Cambridge/UNITED KINGDOM, <sup>2</sup>Department Of Surgery, Erasmus Mc, Rotterdam/NETHERLANDS, <sup>3</sup>University Of Pittsburgh Medical Center, Pittsburgh/PA/UNITED STATES OF AMERICA, <sup>4</sup>Cambridge Research Institute, Cambridge/UNITED KINGDOM, <sup>5</sup>Cambridge Oesophago-Gastic Centre, Cambridge/UNITED KINGDOM

**Background:** The incidence of esophageal adenocarcinoma (EA) has risen rapidly over the last 3 decades. Current staging modalities remain limited in prognosticating patients and even less so in selecting patients for targeted therapy. Using genomic platforms, we have previously identified 8 molecular targets that can potentially prognosticate patients with oesophago-gastric cancer.

**Methods:** Using Cox regression analysis, we selected 3/8 of the most prognostic molecular targets (TRIM44, SIRT2 and EGFR) to create a clinically applicable IHC panel. This IHC panel was applied to patients from 2 independent centres in Europe and the USA ( $n = 708$ ) for validation.

**Results:** Patients with dysregulation of none or one of these three molecular targets had a significantly better outcome (5 year survival 36.1%) than those with dysregulation of two molecular targets (5 year survival 28.0%) while patients with dysregulation of three molecular targets had a dismal survival outcome (5 year survival 8.3%) ( $p < 0.001$ ). Entering the IHC panel into a multivariable cox regression model with current clinical staging and demographic parameters, the 3 gene signature remained in the final model along with age, TNM stage, differentiation and resection margin status [HR 1.28 (95% CI 1.08 -1.52) for every one more molecular target dysregulated in the panel,  $p = 0.005$ ], demonstrating its independent prognostic ability.

**Discussion:** We have generated and validated a simple clinically applicable IHC panel of 3 molecular targets to prognosticate patients with EA. This IHC panel could potentially be applied preoperatively to aid clinical decisions and offer novel therapeutic strategies.

**Disclosure:** All authors have declared no conflicts of interest.

### O03.04 DETERMINATION OF THE HER-2 STATUS IN ESOPHAGEAL ADENOCARCINOMA: HER-2/NEU IS ASSOCIATED WITH SURVIVAL

Margriet Prins<sup>1</sup>, Jelle Ruurda<sup>2</sup>, Richard Van Hillegersberg<sup>2</sup>, Fiebo Kate, Ten<sup>2</sup>

<sup>1</sup>Utrecht Medical Center Utrecht, Utrecht/NETHERLANDS, <sup>2</sup>Utrecht Medical Center, Utrecht/NETHERLANDS

**Background:** HER-2/neu gene amplification usually is accompanied by HER-2/neu protein overexpression. However its prognostic significance in esophageal adenocarcinoma (EAC) is unclear. Aim was to evaluate the percentage, agreement and prognostic value of HER-2/neu protein and gene amplification in EAC.

**Methods:** A tissue microarray was constructed including 154 patients. HER-2/neu gene amplification was assessed by silver-enhanced-in-situ

hybridization (SISH) and HER-2/neu protein expression by immunohistochemistry (IHC) (0 to 3+).

**Results:** HER-2/neu overexpression was detected in 14.2% (21/148) and HER-2/neu gene amplification in 19.1% (29/152) of patients. All patients with 3+, 33.3% with 2+ and 9.5% with IHC 0/1+ showed gene amplification. Overall concordance between protein and gene amplification was 87%. Five-year overall survival (OS) was 33% for all patients. HER-2/neu overexpression was associated with lymph node metastasis ( $p = .037$ ), recurrence of disease ( $p = .048$ ), cancer specific (CSS) and with OS (HR 1.896; 95% CI 1.096–3.278;  $p = .022$  and HR 1.915; 95% CI 1.143–3.210;  $p = .014$ ). HER-2/neu gene amplification was associated with T-stage ( $p = .012$ ), lymph node metastasis ( $p = .004$ ), recurrence of disease ( $p = .040$ ) and with CSS (HR 1.673; 95% CI 1.027–2.726;  $p = .039$ ). In multivariate analyses T-stage (HR 3.247; 95% CI 1.522–6.928;  $p = .002$ ), grade of tumor differentiation (HR 2.424; 95% CI 1.479–3.973;  $p = .000$ ) and HER-2/neu overexpression (HR 1.929; 95% CI 1.039–3.582;  $p = .038$ ) were independently associated with poor OS.

**Discussion:** HER-2/neu overexpression was seen in 14.2% and HER2/neu gene amplification in 19.1% of patients. Results emphasize the need to examine HER-2/neu gene amplification in all patients, because a proportion with IHC 0/1+ expression showed gene amplification. These patients might also benefit from trastuzumab therapy.

**Disclosure:** All authors have declared no conflicts of interest.

### O03.05 UTILITY OF ULTRASONOGRAPHIC ENDOSCOPY AND LAPAROSCOPY IN PREOPERATIVE STAGING FOR OESOPHAGO-GASTRIC UNION AND DISTAL OESOPHAGUS ADENOCARCINOMA

Rafael Lopez Pardo, Angelica Mira Vazquez, Maria Garcia Avila, Alejandro Repiso, Rufo Rodriguez Merlo, Luis Lopez, Santiago Abad De Castro  
Hospital Virgen De La Salud, Toledo/SPAIN

**Background:** Preoperative staging in oesophagogastric union and distal oesophagus tumours is essential to decide extension of surgery, multimodal therapy or avoid resection. Results of ultrasonographic endoscopy (USE), exploratory laparoscopy (EL) or thoracoscopy (ET) have been recorded .

**Methods:** From January 2005 to December 2011, 35 patients were treated with curative intention. All patients were studied with USE, EL/ ET or both. Multimodal treatment and non resected cases were registered. Preoperative and postoperative TNM was compared. USE and EL/ET sensibility / especificity (S/E) was defined for T, N status, R0-R1 operated patients without neoadjuvant treatment, early cancer and locally advanced tumour patients.

**Results:** R0 resection was achieved in 80% . 27% received neoadjuvant chemotherapy and 11% presented unexpected metastatic disease. Coincidence between preoperative and definitive stage was 30% . USE S/E in T and N status was 63% , 93% / 72% , 72%. USE S/E in early tumours and locally advanced was 80% , 87% / 88%,80%. EL/ ET +USE sensibility for locally advanced reached 100%.

**Discussion:** In our experience USE and EL/ET showed a low correlation between preoperative and definitive staging. Utility of USE, EL/ ET was seen in avoiding resections, indicating multimodal treatment and classifying early or locally advanced tumours. So we recomend using them when possible.

**Disclosure:** All authors have declared no conflicts of interest.

### O03.06 EVALUATION OF CHROMOSAL ABERRATIONS IN THE PRIMARY TUMOR, LYMPH NODE METASTASES AND DISSEMINATED TUMOR CELLS OF PATIENTS WITH ESOPHAGEAL CANCER: IMPLICATIONS FOR ANTI-TUMORAL THERAPY?

Daniel Vallbohmer, Sarah Schumacher, Stephan Baldus, Christian Vay, Andreas Krieg, Jan Schulte Am Esch, Wolfram T Knoefel, Nikolas Stoecklein

Deptment Of Surgery; University Of Dusseldorf, Dusseldorf/GERMANY

**Background:** Recent analyses uncovered genetic variations between primary gastrointestinal tumors, lymph node metastases and disseminated tumor cells (DTCs). These findings might explain variable responses to (neo-) adjuvant therapies and further suggest that multimodality treatment options in gastrointestinal cancer should be guided by individual genetic tumor characteristics. Therefore, we assessed the genetic variations in the primary tumor, lymph node metastases and DTCs of patients with esophageal cancer.

**Methods:** Eighty-six patients with esophageal cancer undergoing multimodality therapy were analyzed. We established a protocol for double immunofluorescence labeling for simultaneous visualization of epithelial cell adhesion molecule (EpCAM) expression on cytokeratin positive cells for the

detection of DTCs in bone marrow and lymph nodes. A comparative genomic hybridization (CGH) for the genome-wide screening of DNA-gains/-losses was applied on paired samples from primary tumors, lymph node metastases and DTCs.

**Results:** DTCs were detected in 25% of the bone marrow and 38% of the lymph node samples. CGH analysis revealed a higher frequency of chromosomal aberrations in DTCs of the bone marrow compared to the lymph node samples. Genomic analysis revealed differences in the nature of chromosomal aberrations between primary tumors and corresponding lymph node metastases. Cluster analysis demonstrated similarities of the aberration spectrum between the DTCs and lymph node metastases while primary tumors showed distinct profiles.

**Discussion:** Chromosomal aberration patterns in lymph node metastases and DTCs of patients with esophageal cancer undergoing multimodality therapy are very similar while primary tumors show a different genomic aberration pattern. These individual genetic tumor characteristics might guide multimodality treatment options in esophageal cancer. .

**Disclosure:** All authors have declared no conflicts of interest.

### 003.07 PROGNOSTIC VALUE OF FDG-UPTAKE EARLY DURING NEOADJUVANT CHEMORADIOTHERAPY FOR POTENTIALLY CURABLE ESOPHAGEAL CANCER

Pieter Van Hagen<sup>1</sup>, Mark Van Heijl<sup>2</sup>, Mark Van Berge Henegouwen<sup>2</sup>, Ronald Boellaard<sup>3</sup>, Patrick Bossuyt<sup>2</sup>, Otto Hoekstra<sup>3</sup>, Gerrit Sloof<sup>4</sup>, Jan Van Lanschot<sup>1</sup>, Also On Behalf Of The Cross- And Neopep-Study Groups<sup>1</sup>

<sup>1</sup>Erasmus Mc – University Medical Center Rotterdam, Rotterdam/ NETHERLANDS, <sup>2</sup>Academic Medical Center, Amsterdam/ NETHERLANDS, <sup>3</sup>Vu Medical Centre, Amsterdam/NETHERLANDS, <sup>4</sup>Academic Medical Centre, Amsterdam/NETHERLANDS

**Background:** FDG-PET has been investigated as a prognostic tool for response to neoadjuvant therapy and for survival in patients with esophageal cancer. The aim of this study was to determine the prognostic value of the change in FDG-uptake measured before and 14 days after the start of neoadjuvant chemoradiotherapy (CRT).

**Methods:** Patients treated with neoadjuvant CRT in a phase-III trial from 2004–2009 were included. The standardized uptake value (SUV) of FDG was measured at baseline and 14 days after commencing with CRT. Patients were followed until recurrence or death. The prognostic value of baseline-SUV as well as the SUV-change after 14 days was determined.

**Results:** One hundred patients were included, of whom 82 had adenocarcinoma. An R0 resection was performed in 94/100 patients. During a median follow-up of 44 months, 37 patients developed recurrent disease. Forty-five patients died, 33 due to recurrent disease and 12 from other causes. Median baseline-SUV was 12.1. The estimated 5-year disease specific survival (DSS) was 69% for patients with baseline-SUV > median vs. 70% for those with baseline-SUV < median (p = 0.826). Median %SUV-change after 14 days was -26.5%. The estimated 5-year DSS was 64% for patients with %SUV-change > median vs. 74% for patients with %SUV-change < median (p = 0.219). Only R0 resection was an independent prognostic factor for DSS in multivariate analysis (HR 3.9, p = 0.010).

**Discussion:** Baseline-SUV and SUV-change 14 days after start of CRT were not associated with DSS in patients with potentially curable esophageal cancer. Therefore, these measurements should not be used for prognostication in these patients.

**Disclosure:** All authors have declared no conflicts of interest.

### 003.08 RESPONSE EVALUATION OF NEOADJUVANT CHEMORADIATION THERAPY BY INTEGRATED POSITRON EMISSION TOMOGRAPHY-COMPUTED TOMOGRAPHY FOR THORACIC ESOPHAGEAL SQUAMOUS CELL CARCINOMA: COMPARISONS IN METABOLIC PARAMETERS

Joon Suk Park, Dohun Kim, Joon Young Choi, Kwahnmin Kim, Young Mog Shim  
Samsung Medical Center, Seoul/KOREA

**Background:** Parameters of <sup>18</sup>F-Fluorodeoxyglucose positron emission tomography-computed tomography (PET-CT) were compared with the results of histopathologic examination to determine which objectively indicates response after neoadjuvant chemoradiation for thoracic esophageal squamous cell carcinoma (SCC)

**Methods:** Between August 2003 and January 2010, data of 25 patients who underwent neoadjuvant chemoradiations and subsequent resection for esophageal SCC retrospectively reviewed. Changes in maximum standardized uptake value ( $\Delta$ SUV<sub>max</sub>), metabolic tumor volume ( $\Delta$ MTV), and total lesion glycolysis ( $\Delta$ TLG) were analyzed by comparison to the histopathologic findings.

**Results:** Pathologic complete remission (CR) was achieved in 11 patients for main tumor. Post-radiation esophagitis was observed in 10 patients.  $\Delta$ SUV<sub>max</sub> of main tumor was significantly greater in the CR group than in the PR group (p = 0.039), while  $\Delta$ MTV and  $\Delta$ TLG of the main tumor were not (p = 0.141 and p = 0.349, respectively). The cut-off  $\Delta$ SUV<sub>max</sub> value for CR was estimated as 72.1% which was significantly better accuracy than visual interpretation (p = 0.045). Of the 48 involved lymph nodes,  $\Delta$ SUV<sub>max</sub> &  $\Delta$ MTV of lymph nodes were significantly greater in the CR group than in the PR group (p = 0.045 and p = 0.014, respectively), while  $\Delta$ TLG was not (p = 0.063). The cut-off  $\Delta$ SUV<sub>max</sub> value for prediction of CR in lymph nodes was calculated as 50.67%.

**Discussion:** PET-CT could be used to predict response of neoadjuvant treatment in thoracic esophageal SCC.  $\Delta$ SUV<sub>max</sub> may be more significant predictor for complete remission after neoadjuvant chemoradiation than  $\Delta$ TLG and  $\Delta$ MTV.

**Disclosure:** All authors have declared no conflicts of interest.

### 003.09 CLINICAL UTILITY OF BRONCHIAL ARTERIES 3D-CT ANGIOGRAPHY AND THORACIC DUCT 3D-MRI DUCTOGRAPHY FUSION IMAGING FOR ESOPHAGEAL CANCER SURGERY

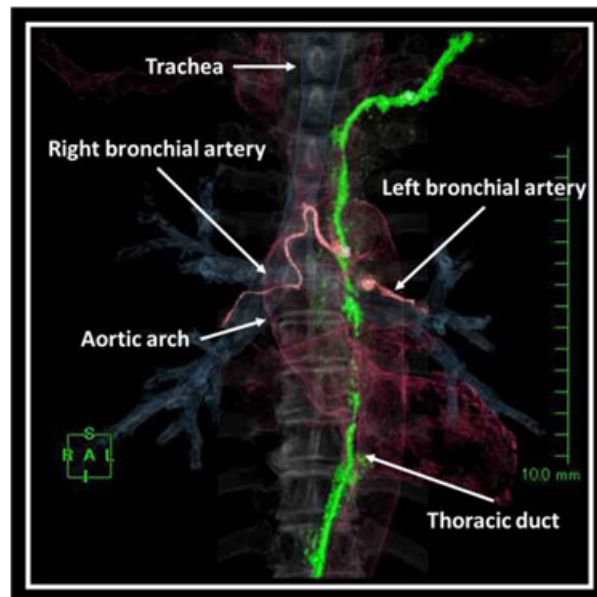
Takeyuki Wada<sup>1</sup>, Hiroya Takeuchi<sup>1</sup>, Hirofumi Kawakubo<sup>1</sup>, Rieko Nakamura<sup>1</sup>, Tsunehiro Takahashi<sup>1</sup>, Norihito Wada<sup>1</sup>, Yoshiro Saikawa<sup>1</sup>, Tai Omori<sup>1</sup>, Masahiro Jinzaki<sup>2</sup>, Sachio Kuribayashi<sup>2</sup>, Yuko Kitagawa<sup>1</sup>  
<sup>1</sup>Department Of Surgery, School Of Medicine, Keio University, Tokyo/ JAPAN, <sup>2</sup>Department Of Radiology, School Of Medicine, Keio University, Tokyo/JAPAN

**Background:** Bronchial arteries (BAs) and thoracic duct (TD) are both important structures in esophagectomy. BAs should be preserved on at least 1 side to avoid tracheobronchial ischemia. Intraoperative injury of TD may cause chylothorax. However, some anomalous BA and TD have been reported. BA 3D-CT angiography and TD 3D-MRI ductography clearly reveal BA and TD anatomies. We investigated clinical utility of BA 3D-CT angiography, TD 3D-MRI ductography, and fusion imaging of these CT/MRI examinations as a preoperative simulation for esophageal cancer surgery.

**Methods:** Sixty six patients who underwent BA 3D-CT angiography and 14 patients who underwent TD 3D-MRI ductography were included in this study. We examined the anatomies of BA and TD and the intraoperative injury rate of these structures, and investigated the contribution to lymphadenectomy of these examinations.

**Results:** The right BA was evaluated in 64 patients (97%) and the left BA in 57 patients (86%). Some anomalies such were observed. In all patients either the right or the left BA was preserved. TD was evaluated in 14 cases (88%). All of visualized TDs were diagnosed as type VI in Adachi's classification. In the group who underwent BA 3D-CTA angiography, significantly more left tracheobronchial lymph nodes could be removed than those in the group who didn't undergo the examination. The fusion imaging clearly revealed both structures with 3D images.

**Discussion:** BA 3D-CT angiography and TD 3D-MRI ductography fusion imaging clearly revealed BA and TD anatomy, contributing to safe and precise lymphadenectomy with esophageal cancer surgery.



**Disclosure:** All authors have declared no conflicts of interest.

**003.10 THE CANCER CELL AMOUNT IN LYMPH NODE METASTASIS OF ESOPHAGEAL CANCER EVALUATED BY CONTRAST ENHANCED MD-CT PATTERN OR FDG-PET UPTAKE AND ITS CLINICAL SIGNIFICANCE.**

Shinichi Okazumi<sup>1</sup>, Kiyohiko Shuto<sup>2</sup>, Hisahiro Matsubara<sup>2</sup>, Ryoji Kato<sup>1</sup>  
<sup>1</sup>Department Of Surgery, Toho University Sakura Medical Center, Chiba JAPAN, <sup>2</sup>Department Of Frontier Surgery, Chiba University Graduate School Of Medicine, Chiba/JAPAN

**Background:** The cancer cell amount in the lymph node metastasis is considered to be important as the prognostic factor currently, however the evaluation is difficult in vivo. In this study, cancer amount in the dissected lymph nodes were compared with pre operatively examined contrast enhanced MD-CT pattern and FDG -PET uptake and investigated the relationship with their prognosis.

**Methods:** 49 cases of esophageal cancer with lymph node metastasis which underwent esophagectomy with 3 field lymph node dissection. Total number of dissected metastatic nodes were 134. Contrast enhanced MD-CT( media: 2 ml/kg body, 3 ml/sec i.v. ,delay time 50 sec) and whole body PET (FDG: 370 MBq ,delay time 60 min) were done before esophagectomy. Enhanced pattern of lymph nodes by MD-CT were classified into three types( Plain, Irregular, Rim) and uptakes of FDG were evaluated quantitatively. The cancer amount in each metastatic node in the pathological specimen was examined after operation, and compared with its MD-CT pattern or FDG uptake, and compared with the prognosis of each case.

**Results:** The cancer amount is  $16.7 \pm 25.2\%$  in Plain type,  $44.0 \pm 32.6$  in Irregular type and  $70.4 \pm 37.8$  in Rim type of MD-CT pattern. The uptakes of FDG significantly correlated with the diameter $\times$ cancer occupying ratios ( $r = 0.47, p < 0.001$ ), and the uptake of the SUV  $> 3.0$  cases showed significantly higher early recurrent ratio( $69.3\%$  in a year) than SUV  $< 3.0$  cases ( $27.1\%$ )( $p < 0.05$ ).

**Discussion:** Contrast enhanced MD-CT pattern or FDG-PET uptake concerned with the amount of metastatic cancer cells in the lymph node and its evaluation had clinical significance as the prognostic factor.

**Disclosure:** All authors have declared no conflicts of interest.

**003.11 HYBRID SPECT-CT SENTINEL NODE IMAGING IN CANCER OF THE ESOPHAGUS AND GE-JUNCTION**

Jon Tsai<sup>1</sup>, Mats Lindblad<sup>1</sup>, Fuat Celebioglu<sup>2</sup>, Magnus Nilsson<sup>1</sup>, Lars Lundell<sup>1</sup>, Rimma Axelsson<sup>3</sup>

<sup>1</sup>Karolinska University Hospital Huddinge, Gastrocentrum K53, Stockholm SWEDEN, <sup>2</sup>Södersjukhuset, Department Of Surgery, Stockholm SWEDEN, <sup>3</sup>Karolinska University Hospital Huddinge, Dept. Of Radiology, Stockholm/SWEDEN

**Background:** Standard of care for cancer in the esophagus or GE-junction consists of neoadjuvant treatment followed by thoracoabdominal resection with 2-field lymphadenectomy. Patients with T1-2/N0 tumors probably do not benefit from such extensive treatment and could instead be treated with transhiatal resection without neoadjuvant treatment. However, there are no methods in use that can exclude lymph node metastases before start of neoadjuvant treatment. Sentinel node biopsy performed during thoracoabdominal esophageal resection has been proven to have a high accuracy in previous studies.

**Methods:** Five patients scheduled for thoracoabdominal esophagectomy received endoscopic injection of Tc-99 radiocolloid close to the tumor the day before surgery. Hybrid SPECT-CT was performed 1 h after this for sentinel node imaging. During surgery, the assumed position of the sentinel node was suture marked before precise localization with a gamma detector.

**Results:** Preoperative SPECT-CT could demonstrate sentinel nodes in 4/5 patients at the following lymph node stations according to the Japanese classification: 1) 106 RecL + 106 RecR, 2) 109 R + 104 L, 3) 1 + 7 + 104 L, 4)108. The gamma detector could confirm the position in all cases and the distance to the assumed suture marked position was 0 to 1.5 cm. In the case where SPECT-CT did not show any sentinel nodes, the gamma detector demonstrated one in station 1.

**Discussion:** Preoperative SPECT-CT is a promising technique that can give a precise localization of sentinel nodes in patients with cancer in the esophagus and GE-junction. This technique could reduce the technical complexity of sentinel biopsy during staging laparo-thoracoscopy.

**Disclosure:** All authors have declared no conflicts of interest.

**ORAL SESSION 004: ESOPHAGEAL FUNCTION TESTING – October 16, 2012 10:20–11:50**

**004.01 MEASURING OESOPHAGEAL WALL DISTENSIBILITY AND COMPLIANCE USING THE ENDOSCOPIC FUNCTIONAL LUMINAL IMAGING PROBE**

Adam Simpson<sup>1</sup>, Michael Samuel James Wilson<sup>1</sup>, Aron Ellefson<sup>2</sup>, Susan Colley<sup>1</sup>, Stephen E Attwood<sup>1</sup>

<sup>1</sup>North Tyneside General Hospital, North Shields/UNITED KINGDOM, <sup>2</sup>Ardmore Healthcare Limited, Amersham/UNITED KINGDOM

**Background:** Identifying the segment of oesophagus causing dysphagia in patients with eosinophilic oesophagitis (EoE) can be difficult in the absence of endoscopic stricture findings. We used the Endoscopic Functional Luminal Imaging Probe (EndoFLIP) to measure oesophageal wall distensibility and compliance and assessed if this helped guide our management.

**Methods:** Under general anaesthetic the EndoFLIP balloon was inflated with varying volumes of water, firstly in the lower and then the upper oesophagus. Oesophageal diameter was recorded at 5 mm intervals and distensibility calculated as changes in cross-sectional area per mmHg.

If the EndoFLIP revealed a segment of oesophagus that was poorly distensible and less than 11 mm across, a through-the-scope balloon dilator was used to dilate the segment.

EndoFLIP testing was then repeated immediately after dilatation to show any improvement in distensibility.

**Results:** 6 patients in total were included, 5 of whom had biopsy proven EoE.

2 of the 5 patients with EoE had poor oesophageal distensibility and underwent dilatation; an immediate improvement in distensibility was seen, correlating with an improvement in symptoms at follow-up.

The remaining 3 patients with EoE had normal distensibility measurements, so did not undergo dilatation.

The single patient without EoE had normal distensibility measurements and therefore did not undergo immediate dilatation.

There was one complication of oesophageal mucosal tear following dilatation, which was not clinically significant.

**Discussion:** Measurements of oesophageal wall distensibility may be of benefit in the clinical assessment of patients with EoE by helping to define the need for oesophageal dilatation as well as assessing the outcome of such intervention.

**Disclosure:** A. Ellefson: Employee of Ardmore Healthcare Limited  
All other authors have declared no conflicts of interest.

**004.02 LAPAROSCOPIC HELLER MYOTOMY FOR IDIOPATHIC ACHALASIA RESULTS IN EXCELLENT OUTCOMES IN ALL SUBTYPES OF THE CHICAGO CLASSIFICATION**

Steven Bharadwaj, Brian E Louie, Alexander S Farivar, Sean P Mchugh, Ralph W Aye

Swedish Medical Center, Seattle/WA/UNITED STATES OF AMERICA

**Background:** Laparoscopic Heller myotomy (LHM) with partial fundoplication and pneumatic dilation are the primary options to palliate idiopathic achalasia. Recently, a new classification of achalasia based on high resolution manometry (HRM) suggested different response rates to the aforementioned therapies in each of the three subtypes of achalasia but only 24% of patients were treated with LHM. We reviewed our surgical outcomes in achalasia patients to determine if this new classification system can predict response to LHM.

**Methods:** We retrospectively reviewed consecutive patients treated with LHM for achalasia from 2005–2012. Patients were placed into one of the three Chicago classification types and symptom resolution, preoperative and postoperative dysphagia scores (Dakkak,etal. 1992) and timed barium swallows (TBS) were compared to determine treatment response.

**Results:** Fifty-five patients were identified with 40 having HRM; 13 Type I, 20 Type II, and 7 Type III. The dominant presenting symptom in Type I and II was dysphagia whereas Type III patients complained of regurgitation, chest pain, and respiratory symptoms as well. The average symptom duration was not significantly different across groups. Postoperative satisfaction rates were 84%, 90% and 80%, with median follow-up times of 13, 13, and 24 months in Types I, II, and III respectively. Comparison of pre- and postoperative dysphagia scores showed improvement in all groups (TypeI:pre-11; post-33( $p = 0.01$ ); TypeII:pre-17;post- 32( $p = 0.02$ ); Type III:pre-15;post- 35( $p = 0.02$ )). Esophageal clearance in 1 to 5 minutes on TBS was also improved in each type.

**Discussion:** LHM results in significantly improved swallowing as evaluated by subjective and objective means in all Chicago classification subtypes.

**Disclosure:** All authors have declared no conflicts of interest.

#### 004.03 INTRAOPERATIVE RESULTS OF LOWER ESOPHAGEAL SPHINCTER MANOMETRY DURING PER-ORAL ENDOSCOPIC MYOTOMY (POEM) FOR ESOPHAGEAL ACHALASIA.

Ahmed Sharata<sup>1</sup>, Ashwin Kurian<sup>2</sup>, Christy Dunst<sup>1</sup>, Neil Bhayani<sup>3</sup>, Kevin Reavis<sup>1</sup>, Lee Swanstrom<sup>1</sup>

<sup>1</sup>The Oregon Clinic, Portland/UNITED STATES OF AMERICA,

<sup>2</sup>Providence Portland Medical Center, Portland/OR/UNITED STATES OF AMERICA, <sup>3</sup>Providence Portland Medical Center, Portland/OR/UNITED STATES OF AMERICA

**Background:** Per-Oral Endoscopic Myotomy (POEM) has been recently described as a surgical therapy for Achalasia of the esophagus. POEM as compared with the conventional Heller myotomy divides only the inner circular muscle layer. The procedure does not include a fundoplication. We present intraoperative manometry results in patients undergoing a POEM procedure.

**Methods:** Water perfusion catheter was used to measure immediate premyotomy and postmyotomy Lower Esophageal Sphincter (LES) length and resting pressure. Paired t-test was used and p-values < 0.05 were considered significant.

**Results:** Twenty-five patients underwent POEM for achalasia between October 2010 to January 2012. Of these patients, six had intraoperative manometry. The mean premyotomy total LES length was 3.2 cm as compared with 3.0 cm postmyotomy (p-value: 0.9). The premyotomy resting pressures ranged from 35 to 40 mm of Hg. The postmyotomy resting pressures ranged from 10 to 20 mm of Hg. The percentage reduction of LES resting pressures ranged from 43% to 73%. The mean LES resting pressure was significantly reduced after the myotomy (37.6 ± 2.5 to 15.6 ± 5.1 mm of Hg, p-value < 0.0001). All patients had marked improvements in postoperative dysphagia at 1 month. One patient complained of rare heart burn. 6 month objective follow up these patients is pending.

**Discussion:** The POEM maintains LES length, while significantly reducing resting pressure. Compared with previously published intraoperative reports of Heller myotomy, the LES is not obliterated postmyotomy. This may provide indirect evidence that a POEM may not need a fundoplication for reflux control.

**Disclosure:** All authors have declared no conflicts of interest.

#### 004.04 THE MEASUREMENT AND CLINICAL IMPORTANCE OF THE OUT-FLOW RESISTANCE OF A NISSEN FUNDOPPLICATION

Shahin Ayazi<sup>1</sup>, Abraham Nisim<sup>1</sup>, Joerg Zehetner<sup>2</sup>, Steven R Demeester<sup>2</sup>, Kimberly S Grant<sup>2</sup>, Arzu Oezcelik<sup>2</sup>, John Lipham<sup>2</sup>, Jeffrey A Hagen<sup>2</sup>, Tom R Demeester<sup>2</sup>

<sup>1</sup>University Of Southern California, Los Angeles/UNITED STATES OF AMERICA, <sup>2</sup>Department Of Surgery, University Of Southern California, Los Angeles/UNITED STATES OF AMERICA

**Background:** There is an attitude of indifference regarding the level of esophageal body contraction amplitude to avoid dysphagia following a 360° fundoplication. This comes from studies showing no difference in the outcome of a fundoplication in patients with esophageal contraction amplitude above or below the 5th percentile level of normal subjects. We hypothesized that, it is more fitting to measure the outflow resistance imposed by a 360° fundoplication. This resistance can be measured by the intra-bolus pressure (iBP) 5 cm above the LES. The aim of this study was to measure the outflow resistance in normal subjects and patients before and after fundoplication to identify the contraction amplitude necessary to overcome the outflow resistance and avoid dysphagia.

**Methods:** The iBP was measured 5 cm above the upper border of the LES in 53 normal subjects and in 37 patients free of dysphagia before and after a Nissen fundoplication.

**Results:** The mean (SD) amplitude of the iBP in normal subjects was 6.8(3.7) mmHg. The iBP in patients before fundoplication was 3.6 (7.0) mmHg. This was significantly lower than that in normal subjects (p = 0.003). After Nissen fundoplication the iBP increased to 12.0 (3.2) mmHg p < 0.0001 vs. normal subjects or pre-operative values). The 95th percentile value for iBP following Nissen fundoplication was 20.0 mmHg.

**Discussion:** In patients with reflux, iBP is less than normal subjects and increases over normal subjects after a 360° fundoplication. To avoid post-operative dysphagia the esophageal contraction amplitude should exceed the 95th percentile of the iBP measured in the dysphagia-free post-surgical patients.

**Disclosure:** T.R. DeMeester: Torax Medical Inc

All other authors have declared no conflicts of interest.

#### 004.05 PH-SYMPTOM INDICES DO NOT PREDICT SYMPTOM IMPROVEMENT AFTER ANTIREFLUX SURGERY

Stefan Niebisch, Candice Wilshire, Carolyn Jones, Virginia Litle, Christian Peyre, Thomas Watson, Jeffrey H Peters

University Of Rochester Medical Center, Rochester/UNITED STATES OF AMERICA

**Background:** One of the key challenges, in the decision to pursue antireflux surgery, is assuring that the patients symptoms are actually caused by GERD. Mathematical calculations of the relationship of reflux events to the occurrence of symptoms have been proposed as a mechanism to support GERD as the underlying cause of both typical and atypical reflux symptoms. The symptom index (SI) and symptom association probability (SAP) are the most commonly calculated measures in clinical use. The clinical utility of these measures is unclear and unexplored with respect to antireflux surgery.

**Methods:** The study population included 66 pH-positive patients (age 52.6 years; 58% female) undergoing fundoplication from November 2006 to October 2011. SI and SAP were calculated for cough, heartburn and/or regurgitation. Symptom outcome after surgery was scaled from 'improvement' to 'worsening'.

**Results:** Heartburn was recorded in 84%, regurgitation in 33% and cough in 32% of patients. Symptom indices were positive in 85% and negative in 15% of the patients. Cough was significantly less associated with positive symptom indices compared to heartburn and regurgitation (SI+ 19% vs. 72.5% and 81.8%; p < 0.0001; SAP+ 33.3% vs. 78.4% and 68.2%; p = 0.0007 and p = 0.0337 respectively). Overall, 93% reported improvement in their symptoms which was independent of the symptom indices. Eighty percent with negative indices improved compared to 87% with positive indices (p = 0.6217). There was no significant difference in improvement between atypical and typical symptoms; patients with heartburn improved in 98%, regurgitation in 95.5% and cough in 85.7% (p = 0.072).

**Discussion:** These data show that symptom improvement following antireflux surgery is independent to symptom indices. Atypical symptoms such as cough are less likely associated with a positive SI, particularly when compared to typical symptoms like heartburn and regurgitation.

**Disclosure:** All authors have declared no conflicts of interest.

#### 004.06 PATIENTS WHO RESPOND TO PPI THERAPY NOT ALWAYS ARE CONFIRMED AS GERD PATIENTS WITH MII-PH STUDY.

Nicola De Bortoli<sup>1</sup>, Irene Martinucci<sup>2</sup>, Edoardo Savarino<sup>3</sup>, Valeria Bolognesi<sup>2</sup>, Valeria Ussia<sup>2</sup>, Lorenzo Bertani<sup>1</sup>, Salvatore Russo<sup>1</sup>, Massimo Bellini<sup>2</sup>, Santino Marchi<sup>2</sup>

<sup>1</sup>University Of Pisa, Gastroenterology Unit, PISA/ITALY, <sup>2</sup>University Of Pisa, PISA/ITALY, <sup>3</sup>University Of Padova, Padova/ITALY

**Background:** Gastroesophageal reflux disease (GERD) is defined by the presence of troublesome heartburn and/or regurgitation, without the need for diagnostic testing. Consistently with this notion, empiric proton pump inhibitor (PPI) therapy is used to diagnose GERD as ex a diuantiibus criteria. Patients with well controlled symptoms under PPI therapy undergo pathophysiological investigations less frequently; thus, the presence of functional heartburn (FH) cannot be excluded. The aim of this study was to evaluate whether patients with reflux symptoms, who well respond to PPI therapy, are always considered within the spectrum of GERD, after undergoing a multichannel intraluminal impedance and pH study (MII-pH).

**Methods:** One hundred and twelve non erosive reflux disease (NERD) patients were treated for 8 weeks with PPIs. The positive therapeutic outcome was recorded through a validated questionnaire (GIS) before stopping such medication. All patients underwent esophageal manometry and MII-pH after a wash-out from PPI before evaluation for laparoscopic anti-reflux surgery (LARS). Patients were grouped on the basis of MII-pH results as follows: True-NERD (increased acid exposure time, AET, or reflux number); Hypersensitive Esophagus (normal AET and reflux number, positive symptom association probability index, SAP); Functional Heartburn (normal AET and reflux number, negative SAP).

**Results:** The male : female ratio was 1.1 (59/53); mean age (± sd) was 52.7 (± 11.6) years; mean BMI was 25.7 (± 3.1). Presenting symptoms were: heartburn 71/112; regurgitation 29/112; chest pain 7/112, belch 5/112. MII-pH analysis results: number of True-NERD 73/112 (65.2%) with mean AET 7.3 ± 4.1; Hypersensitive esophagus 26/112 (23.2%) with mean AET 1.9 ± 1.4 and 100% positive SAP; Functional Heartburn 13/112 (11.6%) with mean AET 1.0 ± 0.7 and 100% negative SAP.

**Discussion:** Our findings show that a MII-pH diagnosis of GERD is not confirmed in over than 11% of PPI responder patients with reflux-like symptoms. The mechanisms through which PPI are able to control symptoms in patients with a reflux-unrelated symptoms need future investigations.

**Disclosure:** All authors have declared no conflicts of interest.

**004.07 HIGH RESOLUTION MANOMETRY CHARACTERISTICS OF THE GASTROESOPHAGEAL JUNCTION IN PATIENTS WITH GERD**

Stefan Niebisch, Candice Wilshire, Nikita Chapurin, Thomas Watson, Virginia Little, Christian Peyre, Carolyn Jones, Jeffrey H Peters  
*University Of Rochester Medical Center, Rochester/NY/UNITED STATES OF AMERICA*

**Background:** While esophageal motility disorders have been extensively described using high resolution manometry (HRM), data assessing the integrity of the gastroesophageal junction (GEJ) in patients with gastroesophageal reflux (GERD) are limited. Our aims were to assess the impact of HRM GEJ parameters on esophageal acid exposure as assessed by ambulatory pH monitoring.

**Methods:** The study population consisted of 505 patients without previous upper GI surgery referred for evaluation of suspected GERD between 2004 and 2011. All patients underwent HRM and pH studies. Positive pH was defined as a DeMeester Score > 14.72. HRM values were referenced against 50 control subjects.

**Results:** Sixty-five percent were pH positive (age 50.1 ± 14 years) and 35% were pH negative (age 49.2 ± 13 years). GERD patients were more commonly overweight (BMI > 25) (77% vs. 53%; p < 0.0001) and tended to be male (OR 1.5; 95%CI: 1.2–2; p = 0.001). A hiatal hernia was present more frequently in pH positive patients (26% vs. 7%; p < 0.0001), as was a hypotensive LES (10% vs. 2%; p < 0.0001). DeMeester score increased significantly with decreasing resting pressure (p < 0.0001), decreasing length (p = 0.019) and increasing number of defective EGJ parameters (p = 0.005). Multivariate analysis revealed presence of a hiatal hernia, overweight BMI and male gender as independent predictors for pH positivity, but failed to identify any of the HRM parameters of the LES as significant.

**Discussion:** Although individual HRM parameters of the LES are associated with the magnitude of esophageal pH score, they do not correlate well with overall pH positivity. These data support the need for improved methods of HRM assessment of LES characteristics.

**Disclosure:** All authors have declared no conflicts of interest.

**004.08 A DISTINCT OESOPHAGEAL MUCOSAL INTEGRITY BEHAVIOR IN PATIENTS WITH NERD COMPARED TO FUNCTIONAL HEARTBURN. A CLINICAL EVALUATION USING BASELINE IMPEDANCE AND ASSESSMENT OF MUCOSAL RECOVERY AFTER ACID CHALLENGE**

Philip Woodland, Mohannad Al-Zinaty, Ivana Bravi, Etsuro Yazaki, Daniel Sifrim  
*Wingate Institute, Barts And The London School Of Medicine And Dentistry, London/UNITED KINGDOM*

**Background:** The relationship between impaired esophageal mucosal integrity and acid perception is unclear and may be key to different reflux-perception between NERD and FH. Esophageal impedance baseline values have been suggested as an in vivo surrogate to assess mucosal integrity. Esophageal mucosal integrity is probably a dynamic process reflecting 1) damage from acid reflux events and 2) the mucosal capacity to recover. We aimed to study the dynamic properties of esophageal mucosal integrity after acid challenge in patients with NERD and FH.

**Methods:** We studied 50 patients with typical reflux symptoms using distal esophageal impedance-pH monitoring. After baseline impedance measurement we performed a 10 min mid-esophageal perfusion of a neutral solution, then a 10 min pH1 perfusion, separated by a 10 min rest period. Impedance recovery was observed for 120 mins post-acid perfusion, then a 24 hr reflux study was completed. NERD was defined by pathological 24 hr esophageal acid exposure and/or positive reflux-symptom association.

**Results:** 20 patients were classified as NERD, 30 as FH. NERD patients had lower baseline impedance than FH patients (1669 ± 182 Ω vs. 2384 ± 211 Ω, P = 0.02). Acid perfusion caused a drop in impedance that was slow to recover. Patients with NERD had a slower rate of impedance recovery compared to patients with FH (6.0 ± 0.9 Ω/min vs. 10.7 ± 1.6 Ω/min, P = 0.03).

**Discussion:** A continuous impaired mucosal integrity might be a consequence of repeated reflux episodes with slow recovery. There is a distinct mucosal phenotype in NERD compared to FH. This behaviour may be important in NERD pathogenesis.

**Disclosure:** D. Sifrim: Daniel Sifrim receives a research grant from Sandhill Scientific, USA.

All other authors have declared no conflicts of interest.

**004.09 RISK OF DYSPHAGIA AFTER FUNDOPLICATION RECOGNISED WITH HIGH-RESOLUTION IMPEDANCE/MANOMETRY**

Jennifer C Myers<sup>1</sup>, Glyn Jamieson<sup>1</sup>, John Dent<sup>2</sup>, Taher Omari<sup>1</sup>  
<sup>1</sup>*University Of Adelaide, Adelaide/SA/AUSTRALIA*, <sup>2</sup>*Royal Adelaide Hospital, Adelaide/SA/AUSTRALIA*

**Background:** Recently we reported low-resolution impedance/manometry revealed pre-operative pressure-flow variables that relate to dysphagia after fundoplication. In this study we will determine if high-resolution impedance/manometry (HRIM) enhances recognition of dysphagia risk in these patients.

**Methods:** HRIM (36 pressure/18 impedance) was undertaken in 15 patients with reflux disease (10 M, 26–69 yrs, xBMI 28) prior to fundoplication, to record 10 x 5 mL liquid (LiqB) & viscous swallows (ViscB). A validated dysphagia questionnaire was utilised pre & post surgery.

**Results:** At 5 months post-op, 8 patients experienced some dysphagia. Several pre-operative HRIM parameters varied significantly in relation to post-operative dysphagia, including: length of 20 mmHg isocontour defect (LiqB 5.3 cm, IQR 3–8 vs 1.0 cm, IQR 0.1–2 p < 0.001; ViscB 4.4 cm, IQR 3–9 vs 0.6 cm, IQR 0.2–3 p < 0.01, dysphagia vs no dysphagia respectively); peak esophageal pressure (PeakP, LiqB 33 ± 5 mmHg vs 74 ± 12 mmHg p < 0.01; ViscB 36 mmHg, IQR 21–43 vs 59 mmHg, IQR 41–112 p < 0.03, dysphagia vs no dysphagia respectively); and complete viscous bolus clearance (ViscB 56 ± 5% vs 88 ± 11% p < 0.05, dysphagia vs no dysphagia respectively). Other parameters of HRIM analysis were consistent with reflux disease, but did not relate to post-operative dysphagia e.g. 4-s integrated relaxation pressure (N15, LiqB 4sIRP 2 ± 0.8 mmHg; ViscB 4sIRP 3 ± 0.8 mmHg).

**Discussion:** This study confirms post-fundoplication dysphagia is related to a pre-existing variation of esophageal function. Conclusion: Analysis of pre-operative high-resolution impedance/manometry identifies distinct characteristics of esophageal function that enhance recognition of patients at risk of dysphagia after fundoplication.

**Disclosure:** J. Dent: Financial relationship with AstraZeneca

All other authors have declared no conflicts of interest.

---

**ORAL SESSION 005: ADVANCES IN ESOPHAGEAL CANCER SURGERY – October 16, 2012 13:30–15:00**

---

**005.01 ANASTOMOTIC LEAKAGE AFTER ESOPHAGECTOMY DID NOT AFFECT 3 YEAR SURVIVAL AND CANCER RECURRENCE AMONG PATIENTS WITH SQUAMOUS ESOPHAGEAL CANCERS**

Philip Chiu, Anthony Teoh, Simon Wong, Shirley Liu, My Yung, Candice Lam, Enders Ng  
*Dept Of Surgery And Cuhk Jockey Club Minimally Invasive Surgical Skills Center, The Chinese University Of Hong Kong, Hong Kong/ HONG KONG*

**Background:** Esophagectomy remained the standard treatment for squamous esophageal cancers. While the rate of anastomotic leakage after esophagectomy varies between 10 to 15%, and 40% of perioperative mortality was related to leakage. Controversies abound upon the effect of anastomotic leakage to cancer recurrence after esophagectomy. This study aimed to investigate the effect of anastomotic leakage after esophagectomy among patients with squamous esophageal cancers on 3 year survival.

**Methods:** A retrospective charts reviewed was conducted among prospectively collected patients with squamous esophageal cancers from 2003 to 2010. Standard esophagectomy with 2 field nodal dissection was performed with either thoracotomy or thoracoscopic approach. The clinical outcomes for patients with anastomotic leakage were compared to those without.

**Results:** A total of 94 patients underwent esophagectomy for treatment of squamous esophageal carcinoma. 12 patients (12.8%) sustained anastomotic leak. There was no difference in tumor staging between the two groups and no patient sustained 30-day mortality. The median hospital stay for those leakage was 44 days and those without leakage was 15 days (p < 0.01). Patients with anastomotic leak had a significantly higher rate of chest infection (58.3% vs 20.7%; p = 0.01) and need of ICU support when compared to those without leakage. The 3-year survival for patients with leakage was 28.6% while those without leakage was 38.4% (p = 0.400). There was also no difference in tumor recurrence between those with leakage (53.7%) and those without (66.7%) (p = 0.67).

**Discussion:** Patients with anastomotic leakage did not sustained a significant difference in tumor recurrence and 3 year survival.

**Disclosure:** All authors have declared no conflicts of interest.

#### 005.02 END-TO-END CERVICAL ESOPHAGOGASTRIC ANASTOMOSES REQUIRE A HIGHER NUMBER OF ENDOSCOPIC STRICTURE DILATIONS COMPARED WITH END-TO-SIDE ANASTOMOSES AFTER ESOPHAGECTOMY.

Leonie Haverkamp, Pieter Christiaan Van Der Sluis, Jelle Ruurda, Richard Van Hillegersberg  
Umc Utrecht, Utrecht/NETHERLANDS

**Background:** Cervical anastomotic leakage and benign stricture formation occur frequently after esophagectomy. Surgical anastomotic techniques might influence outcome. The objective of this study was to analyze the influence of end-to-end (ETE) versus end-to-side (ETS) hand-sewn esophago-gastric anastomoses in patients who underwent an esophageal resection with gastric conduit reconstruction.

**Methods:** A total of 390 consecutive patients were analyzed, with 112 ETE and 278 ETS anastomoses after esophagectomy and gastric tube reconstruction.

**Results:** No significant differences were found in anastomotic leakage rates, which occurred 21 (18%) patients with ETE anastomoses versus 58 (21%) patients with ETS anastomoses ( $p = 0.50$ ). A higher incidence in anastomotic strictures was seen in ETE anastomoses (48 (42%)) compared with ETS anastomoses (89 (32%),  $p = 0.04$ ). In multivariate analysis, these differences were not significant. However, the number of endoscopic dilations required for patients with an ETE anastomosis was significantly higher in multivariate analysis. A median of 11 (7–17) dilations were necessary in patients with a benign anastomotic stricture in the ETE group, compared with a median of 4 (2–8) dilations per patient with a benign anastomotic stricture in the ETS group ( $p < 0.001$ ).

**Discussion:** In conclusion, the technique of anastomosis is not significantly related to anastomotic leakage, and stricture formation. However, patients with ETE anastomoses require significantly more dilations compared with patients with ETS anastomoses.

**Disclosure:** All authors have declared no conflicts of interest.

#### 005.03 HEALTH-RELATED QUALITY OF LIFE AFTER IVOR-LEWIS

Christian Gutschow<sup>1</sup>, Wolfgang Schröder<sup>1</sup>, Jessica Leers<sup>1</sup>, Marc Bludau<sup>1</sup>, Hans Fuchs<sup>1</sup>, Elfriede Bollschweiler<sup>2</sup>, Arnulf Hölscher<sup>1</sup>  
<sup>1</sup>Department Of General-, Visceral- And Cancer Surgery, University Of Cologne, Cologne/GERMANY, <sup>2</sup>Dept. Of General-, Visceral And Cancer Surgery, University Of Cologne, Cologne/GERMANY

**Background:** Transthoracic Ivor Lewis esophagectomy is a surgical standard therapy for esophageal carcinoma. The aim of this study was to assess health-related quality of life (HRQL) in mid- and long-term survivors.

**Methods:** Patients with cancer free survival of at least 12 months after esophageal resection for cancer were identified from a prospectively maintained database. EORTC questionnaires were sent out to assess health related general (QLQ-C30) and esophageal cancer-specific (QLQ-OES18) quality of life. A numeric score was calculated in each conceptual area and compared with reference data.

**Results:** 147 patients completed the self-rated questionnaires. They were 121 men and 26 women with a mean age of years; median FU was 39 (12–139) months. Global health status, functional scales, and symptom scores were significantly reduced compared with healthy reference populations. Also, there was no significant impact of tumor histology, neoadjuvant treatment, minimally invasive approach, or duration of follow-up on HRQL. However, more than half of patients reported a HRQL similar to that of a healthy reference population.

**Discussion:** Despite the major psychosocial and physiological impact of the disease, more than 50% of mid- and long term survivors of the Ivor Lewis procedure for esophageal cancer have a HRQL similar to that of a healthy reference population.

**Disclosure:** All authors have declared no conflicts of interest.

#### 005.04 MINIMALLY INVASIVE IVOR LEWIS ESOPHAGECTOMY: TECHNIQUE AND OUTCOME IN A SERIES OF PATIENTS.

Palanivelu C, Vaithiswaran V, Rajan P.S.  
Gem Hospital And Research Center, 641045/INDIA

**Background:** At our centre we prefer thoraco-laparoscopic esophagectomy with neck anastomosis for squamous cell cancers and minimally invasive Ivor- Lewis esophagectomy for Type I and Type II esophago- gastric junction adenocarcinoma. In this article we summarize our technique and results.

**Methods:** In this retrospective analysis, data of all patients who underwent minimally invasive Ivor Lewis Esophagectomy between Jan 2008 to November 2011 were analysed. During the laparoscopic phase the stomach is mobil-

ised, a radical abdominal lymphadenectomy is performed and the hiatus dissected. With adequate distal margin the stomach is divided and a stomach tube is formed. In the thoracoscopic phase in prone position, Esophagus mobilization is performed with complete mediastinal lymphadenectomy. After division of the esophagus above the level of the azygos vein, an end to end hand sewn or side to side stapled anastomosis is made.

**Results:** Thirty eight patients underwent minimally invasive Ivor Lewis Esophagectomy during the study period. There were no conversions and no mortality. The results are summarised in table. There were two intra thoracic leaks and early intervention salvaged both patients. Longitudinal margins were negative in all patients. Circumferential margin was positive in one patient who had T4 disease. Mean number of lymph nodes 24(18–38) Mean operating time (min) 254 (200–365) Mean blood loss (ml) 125 Median Post Op ICU stay (days) 2 (1.5 -18) Median Post Op hospital stay (days): 7 (5 -28) Overall Morbidity: 9 (23.7%) Pulmonary complications: 2 (5.2%) Leak: 2 (5.2%) Urinary tract infection 1 (2.6 %) Vocal cord paresis 2 (5.2%) Wound infection 1 (2.6 %) Left pleural effusion 1 (2.6 %)

**Discussion:** Minimally Invasive Ivor Lewis esophagectomy can be performed safely with good short term outcome. Long term follow up is essential to prove ultimate efficacy.

**Disclosure:** All authors have declared no conflicts of interest.

#### 005.05 EXTENDED ENTERAL NUTRITION VIA FEEDING JEJUNOSTOMY REDUCES WEIGHT LOSS AND READMISSION FOLLOWING ESOPHAGECTOMY

Fiona M S Macharg, Jeremy R Huddy, Oliver H Priest, Shaun R Preston  
Royal Surrey County Hospital, Guildford/UNITED KINGDOM

**Background:** Despite specialist dietetic support following esophagectomy, recovery is often impaired due to poor nutritional status and weight loss. A standardized clinical pathway for esophagectomy (SCPfE) including routine continued supplementary jejunal feeding after discharge was introduced at our regional Oesophago-Gastric Unit in April 2011. We present our evaluation of the impact on post-operative nutritional status and re-admission.

**Methods:** A retrospective analysis of weight change and readmission, based on intention to treat, was conducted on all esophagectomies performed for cancer between January 2010 and October 2011. Patients discharged on unrestricted dietary intake with supplementary enteral feed when needed (pre-SCPfE) were compared to those discharged with routine supplementary enteral feed and gradual re-introduction of diet (post-SCPfE).

**Results:** Sixty-seven esophagectomies were analysed; twenty-one patients on the SCPfE and 46 prior. Twelve patients were excluded from analysis: 10 where follow-up was carried out away from the regional unit and two peri-operative deaths. Median weight loss and readmission rates for the 2 groups are presented in Table 1.

	Pre-SCPfE 37	Post-SCPfE 18	p
Median weight change (kg) (range)	-6.00 (-14.70 to 2.10)	-3.80 (-10.30 to 4.80)	0.03
% weight change (range)	-8.52 (-19.34 to 3.70)	-4.49 (-16.87 to 6.27)	0.05
Readmission n (%)	9 (24)	3 (17)	

**Discussion:** Patients who had continued supplementary jejunal feeding planned (post-SCPfE) had significantly less weight loss than those supplemented on demand ( $p = 0.03$ ). Readmission rate was also reduced following introduction of the SCPfE.

**Disclosure:** All authors have declared no conflicts of interest.

#### 005.06 QUALITY OF LIFE AFTER OESOPHAGECTOMY – DYNAMICS DURING THE FIRST POSTOPERATIVE YEAR

Jan Johansson<sup>1</sup>, Marlene Malmström<sup>1</sup>, Rosemarie Klefsgård<sup>2</sup>, Bodil Ivarsson<sup>3</sup>, Maria Roman<sup>1</sup>  
<sup>1</sup>Dept Of Surgery, Lund Univ. Hospital, Lund/SWEDEN, <sup>2</sup>Lund Univ. Hospital, Lund/SWEDEN, <sup>3</sup>Lund Univ Hospital, Lund/SWEDEN

**Background:** Oesophagectomy is a major surgical procedure with reduced quality of life (QoL) after surgery. The dynamics of the changes during the first postoperative year of patient assessed QoL is not determined.

**Methods:** Eighty patients operated on for cancer in the oesophagus were included in the study. 79 patients fulfilled the EORTC quality of life questionnaires QLQ-C30 and QLQ-OES18 before, 2, 4, 6, 9 and 12 months after surgery. We transformed the results into function- and symptom scales as recommended by the provider (QLQ C30 function scales, QLQ C30 symptom scales, QLQ-OES18 symptom scales), and performed three separate sets of analyses of the results during the first postoperative year. A general linear model with repeated measurement analysis of variance was used for statistical testing. Adjustments were made for several potential impact factors.



**Results:** There was a significant change of QOL over time ( $p = 0.006$ ,  $p < 0.001$ ,  $p < 0.001$ ), with a significantly lower QOL at 2 months as compared to 12 months after surgery ( $p < 0.001$ ,  $p < 0.001$ ). Treatment with proton pump inhibitors (PPIs) were associated with enhanced QOL ( $p = 0.081$ ,  $p = 0.003$ ,  $p = 0.015$ ) but age ( $p = 0.696$ ,  $p = 0.696$ ,  $p = 0.812$ ), gender ( $p = 0.379$ ,  $p = 0.319$ ,  $p = 0.428$ ) and ASA classification ( $p = 0.338$ ,  $p = 0.338$ ,  $p = 0.9$ ) did not significantly impact the QOL.

**Discussion:** QOL was severely hampered after oesophagectomy for cancer during the first postoperative year, with a nadir at two months after surgery. The results of this study indicate that PPIs improve the results in general, and that focused and timed support to the patients hopefully and additionally would improve their return to normal daily activities.

**Disclosure:** All authors have declared no conflicts of interest.

#### O05.07 ROBOTIC ASSISTED MINIMALLY INVASIVE ESOPHAGECTOMY FOR TREATMENT OF SQUAMOUS ESOPHAGEAL CANCER

Philip Chiu, Anthony Teoh, Simon Wong, Shirley Liu, My Yung, Candice Lam, Enders Ng  
*Dept Of Surgery, The Chinese University Of Hong Kong, Hong Kong/ HONG KONG*

**Background:** Minimally invasive esophagectomy (MIE) aimed to reduce postoperative pain and improve the clinical outcomes after esophagectomy. MIE is technically challenging, especially when performed within the confined thoracic cavity using rigid instruments. Da Vinci Robotic system could theoretically improve the surgical dissection through improved degree of freedom from robotic arms. This study aimed to assess the feasibility and safety of performing MIE using Da Vinci Robotic system among patients with squamous esophageal cancers.

**Methods:** From 2009, patients with T1 or T2 squamous esophageal cancers were recruited. We excluded tumors with suspected invasion to adjacent organs and those received neoadjuvant chemoradiation. Preoperative staging included EUS, CT thorax and abdomen and bronchoscopy. We perform mobilization of thoracic esophagus with 2 field lymphadenectomy using robotic system, with laparoscopic gastric mobilization and hand-sew cervical anastomosis.

**Results:** A total of 10 patients were recruited, with 8 male and 2 female. The mean age was 65.5 years. All the patients were successfully treated with Robotic assisted MIE with mean operative time of 498.5 minutes. The mean blood loss was 533.3 mls with no perioperative mortality. There was no pulmonary complication, while 3 patients sustained anastomotic leakage and were successfully managed conservatively. The mean hospital stay was 18.1 days. Five patients had stage I tumors, 3 had stage II and 2 had stage III disease. The mean number of lymph node dissection was 23.9, and the average involved lymph node was 3.1.

**Discussion:** Our study showed that Robotic MIE is feasible and safe for patients with stages I/II squamous esophageal cancers.

**Disclosure:** All authors have declared no conflicts of interest.

#### O05.08 THE ROLE OF SUBCARINAL LYMPH NODE IN THORACIC ESOPHAGEAL SQUAMOUS CELL CARCINOMA: METASTASIS AND OPERATIVE MORBIDITY

Long-qi Chen, Zhen-jun Miao  
*West China Hospital, Chengdu/CHINA*

**Background:** The removal of subcarinal nodes during esophagectomy for esophageal carcinoma is controversial. Some authors suggested that these nodes were rarely involved and unnecessary to be resected, in order to avoid the additional operative risk. This study investigates the frequency of subcarinal node metastasis in patients with thoracic esophageal squamous cell carcinoma, its association with clinicopathological characteristics and operative morbidity.

**Methods:** The clinical data of 782 consecutive patients with thoracic esophageal squamous cell carcinoma who underwent esophagectomy in our department was retrospectively analyzed. The tumor location and TNM staging were recorded according to the AJCC Cancer Staging Manual, 7th edition (2009).

**Results:** Among them, 604 (77.2%) cases had documented subcarinal node resection (Study group). The remaining 178 patients were set as Control group. Totally 141 complications were documented (18.0%). The most frequently seen was pulmonary complication. However, there was no difference between the two groups for age (59.3 vs. 59.7 yrs.,  $P = 0.508$ ), tumor staging ( $P = 0.154$ ) and morbidity rate (19.0% vs. 14.6%,  $P = 0.176$ ), even for pulmonary complication (10.3% vs. 7.3%,  $P = 0.238$ ).

In Study group, totally 2566 subcarinal nodes were harvested, with a mean of 4.3 per case. The frequency of patients with subcarinal node metastasis was 17.5%, as 0.0%, 4.0%, 22.2% and 34.0% for T1, T2, T3, and T4 tumors,

respectively. This metastasis was correlated with the length of tumor ( $P < 0.001$ ) and depth of invasion ( $P < 0.001$ ).

**Discussion:** The new TNM staging criteria classifies subcarinal node as regional. This study supports the routine resection of subcarinal node during esophagectomy, without increasing operative morbidity, especially for pulmonary complications.

**Disclosure:** All authors have declared no conflicts of interest.

#### O05.09 INTRATHORACIC ANASTOMOTIC LEAKAGE, ENDOSCOPIC STENT INSERTION AND THE RISK OF AORTO-ESOPHAGEAL FISTULA

Michael Schweiger<sup>1</sup>, Attila Dubecz<sup>1</sup>, Rudolf J Stadhuber<sup>1</sup>, Herbert Muschweck<sup>2</sup>, Dietmar Oefner-Velano<sup>3</sup>, Hubert J Stein<sup>1</sup>  
*<sup>1</sup>Department Of General And Thoracic Surgery, Klinikum Nuernberg Nord, Nuernberg/GERMANY, <sup>2</sup>Department Of Gastroenterology, Klinikum Nuernberg Nord, Nuernberg/GERMANY, <sup>3</sup>Department Of Surgery, Paracelsus Medical University Salzburg, Salzburg/AUSTRIA*

**Background:** Intrathoracic anastomotic leakage following esophagectomy is a devastating complication. In recent years endoscopic stent implantation has replaced surgical re-exploration as primary treatment option. While stent insertion helps to avoid hazardous re-thoracotomy, the stent itself can cause trouble. The risk of stent-related vascular erosion is well known from series of esophageal stent insertion in palliative intention. Aim of this retrospective study was to investigate, if endoscopic stent implantation increases the incidence of postoperative aorto-esophageal fistula by reason of stent-related erosion of the thoracic aorta.

**Methods:** Between 01/2004 and 10/2011 275 consecutive patients underwent esophageal resection mainly for esophageal cancer. An intrathoracic esophageal anastomotic leak was endoscopically verified in 30 patients. Endoscopic implantation of a self-expanding stent was accomplished in 21 cases, while re-thoracotomy was mandatory in 9 patients.

**Results:** Successful sealing of the anastomotic leakage was achieved in all 21 cases. Altogether 16 patients recovered well and the stent was subsequently removed. Two patients died from severe sepsis despite sufficient stent placement. In three cases erosion of the thoracic aorta occurred followed by massive hemorrhage. All three patients died of exsanguination with severe hypovolemic shock. Postmortem examination confirmed an aorto-esophageal fistula in each case. None of the 254 patients without stent implantation developed an aorto-esophageal fistula.

**Discussion:** While endoscopic stent insertion is highly effective in dealing with intrathoracic anastomotic leaks following esophagectomy, it puts the well-known risk of stent-related vascular erosion on the spot. Awareness of this life-threatening complication is mandatory. Better prevention seems achievable by improved patient selection.

**Disclosure:** All authors have declared no conflicts of interest.

#### ORAL SESSION O06: GASTRO-ESOPHAGEAL REFLUX DISEASE – October 16, 2012 15:30–17:00

##### O06.01 TRANSCRANIAL DIRECT CURRENT STIMULATION (TDCS) CAN MODULATE ESOPHAGEAL MOTILITY IN GASTROESOPHAGEAL REFLUX DISEASE (GERD) PATIENTS.

Simone Vigneri, Sebastiano Bonventre, Angela Inviati, Giuseppe Cosentino, Giuseppe Giglia, Piera Paladino, Filippo Brighina, Brigida Fierro, Roberto Gullo  
*University Of Palermo, Palermo/ITALY*

**Background:** The interactions between human cortex and esophageal motility are still debated. We evaluated the effects of transcranial direct current stimulation (TDCS) on esophageal manometric parameters in GERD patients.

**Methods:** We studied 40 patients with clinical diagnosis of GERD (“Montreal definition”) who previously underwent endoscopy to differentiate erosive (ERD) from non-erosive reflux disease (NERD). An esophageal manometry was performed before and during cortical stimulation with TDCS (1,5 mA) on the right esophageal motor area [1]. Randomly twenty patients were assigned to anodal stimulation, twenty patients to sham stimulation. Distal waves amplitude and number of pathological waves (distal amplitude  $< 30$  mmHg or not propagated distal peristalsis) were measured 3 cm over the lower esophageal sphincter (LES) after swallowing a water bolus, for ten subsequent times. LES pressure was obtained as well. A 24-hours pH-metry was further performed to rule out functional heartburn. Mean waves amplitude, number of pathological waves and mean basal LES pressure were compared by paired-samples T-test before and during TDCS in both groups of patients.

**Results:** Mean distal waves amplitude increased significantly ( $p = 0.04$ ) and the number of distal pathological waves decreased significantly ( $p = 0.01$ ) during anodal TDCS, while sham stimulation did not influence both parameters. LES mean pressure was not significantly modified during anodal nor sham stimulation in GERD patients. Comparison between groups (NERD vs ERD) showed that significant changes after TDCS occurred only in NERD subgroup.

**Discussion:** Our data suggest TDCS can influence cortical control of esophageal motility and improve pathological motor pattern in NERD patients.

**Disclosure:** All authors have declared no conflicts of interest.

#### O06.02 CORRELATION OF TRANSIENT ESOPHAGEAL RELAXATIONS WITH GASTRIC ACCOMMODATION ASSESSED BY COMBINED HIGH RESOLUTION MANOMETRY AND IMPEDANCE MEASUREMENT WITH A MIXED MEAL CHALLENGE.

Ege Altan<sup>1</sup>, Veerle Boecxstaens<sup>1</sup>, Kathleen Blondeau<sup>1</sup>, Ans Pauwels<sup>1</sup>, Nathalie Rommel<sup>1</sup>, Jan Tack<sup>2</sup>

<sup>1</sup>Translational Research Center For Gastrointestinal Disorders (Targid), Leuven/BELGIUM, <sup>2</sup>University Of Leuven, Targid, Leuven/BELGIUM

**Background:** Reflux events associated with transient lower esophageal sphincter relaxations (TLESRs) increase during the postprandial period. This is thought to be triggered by gastric distension. We have recently shown that the drop in intragastric pressure (IGP), derived from high resolution manometry (HRM) channels below the lower esophageal sphincter (LES) can be used as a surrogate for gastric accommodation (Janssen et al., NMO 2011), providing us with an easy method to study the relationship between TLESRs and accommodation.

**Methods:** Computer records were used to identify patients with proven GERD with 24 hour pH-impedance measurement, who underwent combined esophageal HRM and impedance measurement with a mixed meal challenge. During a time period of 5 minutes before and 30 minutes after a mixed meal, pressure changes in channel(s) situated at 5 cm below LES were taken as a measure of accommodation. Postprandial TLESRs with a liquid reflux were identified in the same tracings.

**Results:** A total of 14 patients (8 males, 6 females; mean age  $39.1 \pm 4.8$ ) were identified. Mean IGP change before and after the meal was  $2.5 \pm 0.8$  mmHg. Mean number of TLESRs with a liquid reflux during the postprandial 30 minutes was  $3.0 \pm 1.0$ . Changes in LES resting pressure between pre and postprandial periods were not correlated with TLESRs (mean change in LES pressure  $6.4 \pm 2.3$  mmHg). A strong negative correlation was observed between the change in IGP and TLESRs (Spearman rank correlation =  $-0.7849$ ;  $p = 0.0009$ ).

**Discussion:** Results suggest accommodation helps to inhibit triggering of TLESRs and incomplete accommodation may contribute to the pathogenesis of GERD.

**Disclosure:** All authors have declared no conflicts of interest.

#### O06.03 ESOPHAGEAL IMPEDANCE-PH MONITORING AND SYMPTOM ANALYSIS IN NON CARDIAC CHEST-PAIN (NCCP) – A MULTICENTER ITALIAN STUDY IN PATIENTS ON AND OFF THERAPY

Edoardo Savarino<sup>1</sup>, Francesca Galeazzi<sup>1</sup>, Patrizia Zentilin<sup>2</sup>, Nicola De Bortoli<sup>3</sup>, Giacomo Carlo Sturniolo<sup>1</sup>, Vincenzo Savarino<sup>2</sup>  
<sup>1</sup>University Of Padova, Padova/ITALY, <sup>2</sup>University Of Genova, Genova/ITALY, <sup>3</sup>University Of Pisa, Gastroenterology Unit, Pisa/ITALY

**Background:** The precise aetiology of NCCP is unknown, but previous studies demonstrated that chemostimulation with acid is frequently involved. However, the role of non-acid reflux (NAR) in provoking NCCP in these patients is poorly known. To assess the role of NAR in NCCP patients.

**Methods:** Consecutive NCCP patients underwent impedance-pH monitoring on or off-PPI therapy. Forty-eight healthy volunteers (HVs) served as controls. We measured distal esophageal acid exposure time (AET), characteristics of reflux episodes (acid/weakly acidic) and symptom-reflux association using both symptom association probability (SAP+  $\geq 95\%$ ) and symptom index (SI+  $\geq 50\%$ ).

**Results:** Out of 307 NCCP patients (167F/140M, mean age 49), 266 (86%) were included in the study. Among the 198 off-PPI, a positive SAP/SI was found in 77(39%) for acid reflux only, 31(16%) for both acid and NAR and 26(13%) for NAR only. Sixty-four patients (32%) patients had no association between reflux and symptoms. In the group of patients on-PPI, 13(19%) had a positive SAP for acid reflux only, 22(32%) for NAR only and 5(7%) for both acid and NAR. Twenty-eight (41%) patients had no association between reflux and symptoms. Identifying patients with symptomatic weakly acidic reflux reduces the number of patients with unexplained chest-pain

from 91(46%) to 64(32%) and from 51(75%) to 28(41%) among patients off-PPI and on-PPI, respectively ( $p < 0.01$ ).

**Discussion:** Monitoring for NAR in NCCP patients increases our ability to identify patients in whom symptoms are associated with reflux, mainly in patients on-PPI therapy. Our data support the use of ambulatory impedance-pH monitoring in a diagnostic algorithm for patients with unexplained chest pain.

**Disclosure:** All authors have declared no conflicts of interest.

#### O06.04 PEPSIN CONCENTRATIONS ARE ELEVATED IN THE BRONCHOALVEOLAR LAVAGE FLUID OF PATIENTS WITH IDIOPATHIC PULMONARY FIBROSIS AFTER LUNG TRANSPLANTATION

Christopher Davis, Diana Flint, Karen Pelletiere, Erin Lowery, Luis Ramirez, Robert Love, Elizabeth Kovacs, P Marco Fisichella  
Loyola University Medical Center, Maywood/IL/UNITED STATES OF AMERICA

**Background:** Aspiration of gastroesophageal refluxate has been implicated in both the pathogenesis of idiopathic pulmonary fibrosis (IPF) and the progression of bronchiolitis obliterans syndrome after lung transplantation. The mechanisms responsible for these phenomena are unknown. Therefore, we aimed to identify those lung transplant patients at greatest risk for aspiration and investigate causative factors.

**Methods:** From September 2009 to November 2011, 252 bronchoalveolar lavage fluid (BALF) samples were collected from 100 lung transplant patients. BALF pepsin concentrations and the results of transbronchial biopsy, esophageal function testing, barium swallow, and gastric emptying scan were compared among the top four indications of lung transplantation:  $\alpha$ 1-anti-trypsin deficiency (AAT), cystic fibrosis (CF), chronic obstructive pulmonary disease (COPD), and IPF.

**Results:** Patients with IPF had higher BALF pepsin concentrations (Figure 1) and a greater frequency of acute rejection compared to those with AAT, CF, or COPD ( $p < 0.05$ ). BALF pepsin concentrations correlated: a) negatively with lower esophageal sphincter pressure and distal esophageal amplitude (DEA) among the entire cohort; b) negatively with DEA and positively with total esophageal acid time, longest reflux episode, and DeMeester score in those with COPD; and c) negatively with upright acid clearance time in those with IPF.

**Discussion:** Our results suggest that lung transplant patients with IPF are at increased risk for aspiration, and that risk factors for aspiration may be different among the most common indications for lung transplantation. These results support the role of evaluating the BALF for markers of aspiration in assessing lung transplant patients as candidates for antireflux surgery.

**Disclosure:** All authors have declared no conflicts of interest.

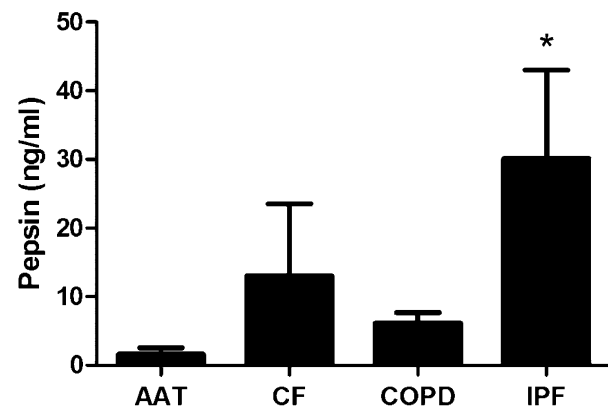


Figure 1. BALA pepsin concentrations after lung transplantation.

\* $p < 0.05$ , vs all groups.

#### O06.05 PATIENTS WITH GERD NOT RESPONDING TO PPIs: AEROPHAGIA DURING MEALS AND POST-PRANDIAL REFLUX

Philip Woodland, Ivana Bravi, Ravinder Gill, Etsuro Yazaki, Daniel Sifrim  
Wingate Institute, Barts And The London School Of Medicine And Dentistry, London/UNITED KINGDOM

**Background:** 30% of patients with GERD are refractory to PPI therapy. Proximal extent of reflux episodes, and presence of gas in the refluxate have

been shown as most important for reflux perception in patients “off” and “on” PPI. Excessive air swallowing (aerophagia) in the fasting state has been observed in patients with heterogeneous GI symptoms. Aerophagia during meals may be more relevant for post-prandial symptoms (e.g. heartburn) but, thus far, has not been studied. We aimed to study the relationship between mealtime air swallowing and postprandial reflux in patients with GERD.

**Methods:** We assessed mealtime air swallow using ambulatory impedance-pH monitoring. We studied 44 consecutive patients with typical reflux symptoms and pathological esophageal 24h acid exposure. 18 patients were fully responsive and 26 were partially or unresponsive to PPI. Prandial air swallows were defined as swallows with antegrade flow and fast impedance increase (>3000  $\Omega$  from baseline) in the distal recording segment. Prandial air swallow frequency (air swallows/10 min meal) was calculated.

**Results:** PPI-refractory patients had a higher frequency ( $10.5 \pm 1.4$  vs  $5.9 \pm 0.8$ ,  $p < 0.05$ ) and absolute number ( $83.1 \pm 12.7$  vs  $47.8 \pm 7.3$ ,  $p < 0.05$ ) of prandial air swallows than PPI-responders. PPI-refractory patients demonstrated a significantly higher number and proportion of post-prandial gas-containing reflux episodes than PPI-responders.

**Discussion:** PPI non-responders displayed significantly more mealtime air swallowing than responders. As a likely consequence, non-responders had more reflux episodes containing gas, a factor very important in reflux perception. The relevance in GERD patients over controls is that they are known to be more sensitive to mechanical esophageal distension.

**Disclosure:** D. Sifrim: Daniel Sifrim receives a research grant from Sandhill Scientific, USA

All other authors have declared no conflicts of interest.

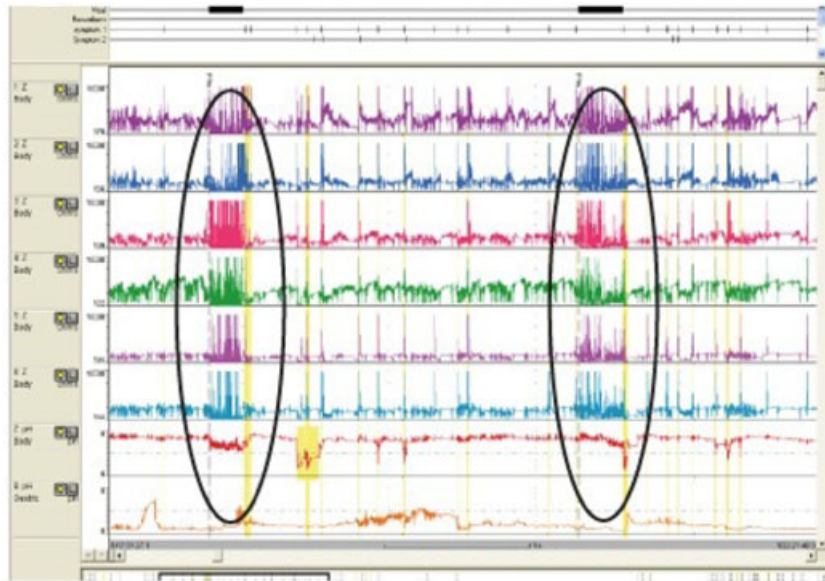


Figure: 24 hr pH-MII study displaying prandial aerophagia

#### 006.06 GASTROESOPHAGEAL REFLUX IN ADULT CYSTIC FIBROSIS: A PRIMARY PHENOMENON OR SECONDARY TO RESPIRATORY DYSFUNCTION?

Ans Pauwels<sup>1</sup>, Kathleen Blondeau<sup>2</sup>, Lieven Dupont<sup>3</sup>, Daniel Sifrim<sup>4</sup>  
<sup>1</sup>Targid, Catholic University Leuven, Leuven/BELGIUM, <sup>2</sup>Translational Research Center For Gastrointestinal Disorders, Leuven/BELGIUM, <sup>3</sup>Dept. Of Pneumology, Catholic University Leuven, Leuven/BELGIUM, <sup>4</sup>Barts And The London School Of Medicine And Dentistry, Queen Mary, University Of London, London/UNITED KINGDOM

**Background:** It has been suggested that gastroesophageal reflux (GER) in cystic fibrosis (CF) is a primary phenomenon, since reflux occurs already at young age. Reflux in CF occurs mostly during transient lower esophageal sphincter relaxations (TLESR). We showed that reflux during TLESR is mostly due to an increased gastroesophageal pressure gradient (GEPG), caused by decreased intra-thoracic pressures (ITP). We aimed to assess the relation between magnitude of respiratory oscillations and GER in CF.

**Methods:** 12 CF adults and 11 age and sex-matched healthy subjects were studied using high resolution manometry-impedance. In the thorax, expiration provokes slightly positive pressures that becomes negative in inspiration, which is opposite in the abdomen. GEPG was calculated by subtracting ITP from intra-abdominal pressure (IAP).

**Results:** GEPG in expiration was similar in CF and healthy. However, GEPG was significantly higher in CF patients compared to healthy subjects during inspiration [ $13.1$  ( $9.9$ – $15.8$ ) vs.  $7.1$  ( $4.5$ – $9.4$ ) mm Hg,  $p = 0.005$ ]. This was due to significantly lower ITP in CF [ $-7.5$  ( $-10.6$ – $-5.6$ ) vs.  $0.07$  ( $-6.1$ – $1.1$ ) mm Hg,  $p = 0.003$ ]. In CF, 77 (67–85)% of the reflux episodes started during inspiration vs. 23 (15–33)% in expiration ( $p < 0.0001$ ). In healthy subjects, reflux occurred in both respiratory phases.

**Discussion:** CF patients have reflux during TLESR due to high GEPG which was caused by decreased thoracic pressures. This is particularly significant during the inspiratory phase of respiratory oscillations. Most TLESR-related reflux in CF starts in inspiration. The increased inspiratory effort in CF can favor reflux suggesting that in CF adults reflux can be a secondary phenomenon to respiratory dysfunction.

**Disclosure:** D. Sifrim: Daniel Sifrim has served as speaker, consultant and advisory board member for Sandhill Scientific, MMS, Xenoport, Shire Movetis, Astrazeneca, Janssen Cilag, Reckitt Benckiser, Pfizer, Novartis and Glaxo Smith Kline.

All other authors have declared no conflicts of interest.

#### 006.07 THE LINX REFLUX MANAGEMENT SYSTEM: SAFETY AND EFFICACY RESULTS AT 4 YEARS.

Greta Saino<sup>1</sup>, Luigi Bonavina<sup>1</sup>, John Lipham<sup>2</sup>, Robert Ganz<sup>3</sup>, Daniel Dunn<sup>3</sup>, Paul Fockens<sup>4</sup>, Willem Bemelman<sup>4</sup>, Tom R Demeester<sup>2</sup>  
<sup>1</sup>Policlinico San Donato University, Milan/ITALY, <sup>2</sup>University Of Southern California, Los Angeles/CA/UNITED STATES OF AMERICA, <sup>3</sup>Abbott-Northwestern Hospital, Minneapolis/MN/UNITED STATES OF AMERICA, <sup>4</sup>Academic Medical Center, University Of Amsterdam, Amsterdam/NETHERLANDS

**Background:** Sphincter augmentation with the LINX® Reflux Management System is intended for patients with chronic reflux who have incomplete symptom relief from acid suppression therapy and confirmed abnormal acid exposure. Short-term safety and effectiveness results have been previously reported. We now report results at 4 years.

**Methods:** In a multicenter, prospective, single-arm study, a total of 44 patients underwent a laparoscopic surgical procedure to place the LINX System around the gastroesophageal junction (GEJ). Each patient's baseline GERD status served as the control for evaluations post-implant: acid exposure, GERD quality-of-life measures and use of proton-pump inhibitors (PPIs).

**Results:** Median follow-up time was 3.7 years or 1343 days (range 119–1827 days). There were no reports of death or long-term complications, such as migrations or erosions. The mean total acid exposure time was reduced from  $11.9\% \pm 8.0$  to  $3.8\% \pm 3.4$  ( $p < 0.001$ ) at 3 years. Normalization of pH was achieved in 77%, 90% and 80% of patients at 1, 2 and 3 years, respectively. The mean total GERD-HRQL score off PPIs at > 4 years was  $3.3 \pm 3.7$  compared to  $25.7 \pm 6.4$  ( $p < 0.001$ ) at baseline. Freedom from daily dependence on PPIs was achieved in 80% of patients 4 years. Three patients had the device laparoscopically removed without complication.

**Discussion:** In the long-term, sphincter augmentation with the LINX System reduced esophageal acid exposure, improved GERD-related quality of life, and ended dependence on PPIs, with minimal side effects and no long-term complications, such as device migration or erosion at 4 years.

**Disclosure:** L. Bonavina: Consultant for Torax  
R. Ganz: Consultant for Torax  
T.R. DeMeester: Consultant for Torax  
All other authors have declared no conflicts of interest.

#### 006.08 PULMONARY IMMUNE CHANGES EARLY AFTER LAPAROSCOPIC ANTIREFLUX SURGERY IN LUNG TRANSPLANT PATIENTS WITH GASTROESOPHAGEAL REFLUX DISEASE

P. Marco Fisichella, Christopher Davis, Erin Lowery, Matthew Pittman, James Gagermeier, Robert Love, Elizabeth Kovacs  
*Loyola University Medical Center, Maywood/ILLINOIS UNITED STATES OF AMERICA*

**Background:** The biological mechanisms by which laparoscopic antireflux surgery (LARS) may influence the inflammatory process leading to bronchiolitis obliterans syndrome (BOS) are unknown. We hypothesized that LARS alters the pulmonary immune profile in lung transplant patients with gastroesophageal reflux disease (GERD).

**Methods:** In eight lung transplant patients with GERD we quantified and compared the pulmonary leukocyte differential and the concentration of inflammatory mediators in the bronchoalveolar lavage fluid (BALF) four weeks before and four weeks after LARS. We also examined freedom from BOS, trends of pulmonary function, and survival.

**Results:** Compared to preoperative values: 1) the percentages of neutrophils and lymphocytes in the BALF were reduced (6.6% to 2.8%;  $p = 0.049$  and 10.4% to 2.4%;  $p = 0.163$ , respectively); 2) the percentage of macrophages increased (74.8% to 94.6%;  $p = 0.077$ ); and 3) the BALF concentration of myeloperoxidase and IL-1 $\beta$  tended to decrease (2109 to 1033 units/mg;  $p = 0.063$  and 4.1 to 0 pg/mg protein;  $p = 0.031$ , respectively), while the concentrations of IL-13, and interferon- $\gamma$  tended to increase (7.6 to 30.4 pg/mg protein;  $p = 0.078$  and 0 to 159.5 pg/mg protein;  $p = 0.031$ , respectively). At a mean follow-up of 19.7 months the survival rate was 75% and the freedom from BOS was 75%. Overall, FEV1 remained stable over a 12-month period.

**Discussion:** Our preliminary study demonstrates that LARS may restore a more physiologic balance of pulmonary leukocyte populations and that the pulmonary concentration of pro-inflammatory mediators is altered early after LARS. These results suggest that LARS could modulate the pulmonary inflammatory milieu in lung transplant patients with GERD.

**Disclosure:** All authors have declared no conflicts of interest.

#### 006.09 LONG-LASTING IMPAIRED MUCOSAL INTEGRITY AFTER ESOPHAGEAL PERFUSION WITH ACIDIC AND WEAKLY ACIDIC SOLUTION

Ricard Farré<sup>1</sup>, Nicolas Pardon<sup>1</sup>, Maria Vicario<sup>2</sup>, Kathleen Blondeau<sup>1</sup>, Hanne Vanheel<sup>3</sup>, Tim Vanuytsel<sup>3</sup>, Christophe Vanormelingen<sup>3</sup>, Marcel Jimenez<sup>4</sup>, Jan Tack<sup>3</sup>

<sup>1</sup>Translational Research Center For Gastrointestinal Disorders, Leuven BELGIUM, <sup>2</sup>Digestive Diseases Research Unit, Hospital Universitari Vall D'Hebron, Barcelona/SPAIN, <sup>3</sup>Translational Research Center For Gastrointestinal Disorders, 3000/BELGIUM, <sup>4</sup>Department Of Cell Biology, Physiology And Immunology, Universitat Autònoma De Barcelona, Bellaterra/SPAIN

**Background:** Impaired esophageal mucosal integrity may be an important contributor to heartburn perception in NERD patients. In animal models, the effect of harmful solutions is mainly evaluated acutely. We assessed in vivo the effect of an acidic and a weakly acidic solution on esophageal mucosa integrity after 24 and 48 h

**Methods:** Esophageal perfusion was performed for 30 min in 46 rabbits with saline solutions at pH 7.2, pH 5.0, pH 1.0 and pH 5.0 + deoxycholic (DCA) 500  $\mu$ M. Thereafter, subgroups of animals were sacrificed immediately at 0 h, 24 h or 48 h. Transepithelial mucosal resistance (TER) and mucosal dilated intercellular spaces (DIS) were determined

**Results:** Acidic solution (pH 1.0) strongly decreased TER around 80% (from  $2209 \pm 98 \Omega/\text{cm}^2$  to  $413 \pm 88 \Omega/\text{cm}^2$ ,  $N = 7$ ). Tissue recovered completely after 48 h ( $2055 \pm 251 \Omega/\text{cm}^2$ ,  $N = 5$ ). Similar results were found when solution containing DCA was used, ( $p < 0.05$ ) but after 48 h TER was not fully recovered (from  $356 \pm 50 \Omega/\text{cm}^2$  to  $1780 \pm 128 \Omega/\text{cm}^2$ ,  $p < 0.01$ ,  $N = 5$ ). No macroscopic alterations were observed. Impaired mucosal integrity and DIS were present after perfusion with pH 1.0 and DCA solution. Ultrastructural abnormalities, including DIS, were present mainly at the basal cell layer at 24 h after. At 48 h DIS were only present after perfusion with DCA solution.

**Discussion:** Acidic and weakly acidic solution containing DCA impair mucosal integrity provoking functional and ultrastructural changes that can last at least 48 h. The presence of similar changes in the esophageal mucosa in NERD patients may be due to a direct effect of luminal contents or to a slow/incomplete repair mechanism.

**Disclosure:** All authors have declared no conflicts of interest.

#### ORAL SESSION O07: ADJUVANT AND NEO-ADJUVANT THERAPIES – October 17, 2012 08:00–09:50

##### 007.01 GENE EXPRESSION PROFILING IDENTIFIES RESPONSE PREDICTIVE GENES FOR NEOADJUVANT THERAPY IN ESOPHAGEAL CANCER: DIFFERENT PREDICTIVE GENE PANELS ARE REQUIRED FOR THE SUBTYPES

ADENOCARCINOMA AND SQUAMOUS CELL CARCINOMA  
Ralf Metzger<sup>1</sup>, Elfriede Bollschweiler<sup>1</sup>, Ute Warnecke-Eberz<sup>1</sup>, U Drebber<sup>2</sup>, Peter Grimminger<sup>3</sup>, Till Herbold<sup>1</sup>, Stefan Paul Mönig<sup>1</sup>, Arnulf Hölscher<sup>1</sup>  
<sup>1</sup>Dept. Of General-, Visceral And Cancer Surgery, University Of Cologne, Cologne/GERMANY, <sup>2</sup>Institute Of Pathology, University Of Cologne, Cologne/GERMANY, <sup>3</sup>Department Of General-, Visceral- And Cancer Surgery, University Of Cologne, Cologne/GERMANY

**Background:** Neoadjuvant treatment strategies have been developed to improve survival of patients with locally advanced esophageal cancer. Since only patients with major histopathological response benefit from multimodality treatment, we profiled the human genome of patients with esophageal cancer for markers indicating response or non-response.

**Methods:** Pretreatment biopsies of responding and non-responding patients with esophageal cancer were analyzed by human genome microarrays. Differential gene expression was associated with histomorphological tumor regression after induction radiochemotherapy. Quantitative real-time RT-PCR was applied for verification of the predictive value of a panel of the identified marker genes including 39 patients: 27 adenocarcinomas (AC), 12 squamous cell carcinomas (SCC).

**Results:** With regard to response (<10% vital residual tumor cells) and non-response to neoadjuvant radiochemotherapy we detected differentially expressed candidate genes. Verification study including patients with AC and SCC showed that according to each histological subtype a different gene panel is required. Establishing a specific gene panel - including 6 genes - prediction of response was possible in 82% of the ACs. The predictive panel for SCC included 6 genes which were different from that for ACs with the exception of gene which contains a zinc-finger DHHC domain. Regarding its predictive value, this gene was expressed contrarily in ACs and SCCs. In SCC the utilized gene panel enabled a response prediction in 90%.

**Discussion:** According to the different histological subtypes AC and SCC, different gene panels are required for response prediction to a given neoadjuvant radiochemotherapy.

**Disclosure:** All authors have declared no conflicts of interest.

##### 007.02 OBESITY AND RADIOSENSITIVITY STATUS INFLUENCE NUCLEAR INSTABILITY EVENTS: ANAPHASE BRIDGE FORMATION AND SPINDLE ASSEMBLY CHECKPOINT GENE EXPRESSION IN OESOPHAGEAL CANCER

Ann Marie Mongan, Niamh Lynam-Lennon, Laure Marignol, Stephen Maher, Graham Pidgeon, Jacintha O'Sullivan, John Reynolds  
*Institute Of Molecular Medicine/Trinity College Dublin, Dublin 8/ IRELAND*

**Background:** Obesity is strongly associated with oesophageal adenocarcinoma (OAC). However, its role in regulating radiosensitivity and genomic instability events is unknown. Using an isogenic radioresistant OAC cell model (OE33R), the aim of this study was to determine if adipose conditioned media (ACM) from obese and nonobese OAC patients caused radioresistance and whether it activated genomic instability events: anaphase bridge formation and spindle assembly checkpoint gene expression

**Methods:** OE33R and the passage matched control OE33P cell lines were cultured with ACM from obese and nonobese patients. We assessed anaphase bridges in both lines and quantified the number of bridges present over the total cell number. Expression of five SAC genes (MAD2L2, BUB1B, CDC20, CENPE, and ESPL1) was assessed using qPCR. Clonogenic survival following radiation was determined in both cell lines following ACM treatment.

**Results:** OE33P and OE33R showed a significant increase in anaphase bridges in response to ACM ( $p < 0.05$ ,  $p < 0.001$  respectively). This increase in anaphase bridge formation was three times greater in the resistant line ( $p < 0.05$ ). Levels of anaphase bridges correlated with obesity status (BMI and VFA,  $p < 0.05$ ). OE33R cells treated with ACM showed significantly

increased expression of the SAC genes MAD2L2 and BUB1B compared to controls ( $p < 0.01$ ). Expression of MAD2L2 and BUB1B correlated with obesity status ( $p < 0.05$ ). OE33P cells treated with ACM showed increased radioresistance ( $p < 0.05$ ). In contrast, in the resistant OE33R cell line, ACM treatment reversed this radioresistance ( $p < 0.001$ ).

**Discussion:** Obesity drives genomic instability and alterations in SAC gene expression in radioresistant OAC and alters radiosensitivity in OAC.

**Disclosure:** All authors have declared no conflicts of interest.

#### 007.03 EPIGENETICS AND DRUG-RESISTANCE: EXPRESSION OF MICRORNAS AND THEIR PUTATIVE TARGETS IN DRUG-RESISTANT ESOPHAGEAL CANCER CELL LINES

Richard Hummel<sup>1</sup>, Corina Sie<sup>2</sup>, D Watson<sup>2</sup>, Tingting Wang<sup>2</sup>, Michael Michael<sup>3</sup>, Mark Van Der Hoek<sup>4</sup>, Joerg Haier<sup>5</sup>, Damian Hussey<sup>2</sup>  
<sup>1</sup>Department Of General And Visceral Surgery, University Of Muenster, Muenster/GERMANY, <sup>2</sup>Department Of Surgery, Flinders University, Adelaide/AUSTRALIA, <sup>3</sup>Department Of Gastroenterology And Hepatology, Flinders University, Adelaide/AUSTRALIA, <sup>4</sup>Adelaide Microarray Centre, Adelaide/AUSTRALIA, <sup>5</sup>Comprehensive Cancer Center Muenster, Muenster/GERMANY

**Background:** Neoadjuvant or definitive radiochemotherapy plays a crucial role in the treatment of esophageal cancer. Unfortunately, resistance to chemotherapy often limits the success of these treatments. MicroRNAs are regulators of global gene expression and impact on drug-resistance in other tumor types. We were interested if drug-resistant esophageal cancer presents distinct microRNA expression profiles, and if levels of putative target genes are affected.

**Methods:** Based on one esophageal adenocarcinoma (EAC) and one squamous-cell-carcinoma (SCC) cell line, cisplatin- or 5-FU-resistant sublines were generated via pulsatile treatment. microRNA expression was compared between resistant and sensitive cells using microarray and qRT-PCR techniques, and expression of putative targets was analyzed on mRNA and protein levels via qRT-PCR/western blots.

**Results:** All generated resistant sublines presented significant resistance towards the applied drug. We identified significant up- or downregulation of 11 microRNAs in cisplatin-resistant EAC cells, 9 microRNAs in 5-FU-resistant EAC cells, 2 microRNAs in cisplatin-resistant SCC cells and 10 microRNAs in 5-FU-resistant SCC cells. MicroRNA signatures differed between cisplatin- and 5-FU-resistant cells from the same histological entity, and differed between EAC and SCC cells with the same acquired drug resistance. Furthermore, a number of putative targets were deregulated in the respective resistant cells on mRNA (KRAS, MAP4K4, Bcl-2, CBL-B, TYMS, ERBB2, MUC1) and protein levels (CBL-B, TYMS, ERBB3).

**Discussion:** This study demonstrates for the first time that drug resistant esophageal cancer cells present unique microRNA signatures. Furthermore, expression of various putative target genes was affected in resistant cells implicating their potential involvement in resistance development.

**Disclosure:** All authors have declared no conflicts of interest.

#### 007.04 NEOADJUVANT THERAPY WITH WEEKLY DOCETAXEL (D) AND CISPLATIN (P), 5-FLUOROURACIL (5FU) CONTINUOUS INFUSION (C.I.) AND CONCURRENT RADIOTHERAPY (RT) IN PATIENTS WITH LOCALLY ADVANCED ESOPHAGEAL CANCER PRODUCED A HIGH PERCENTAGE OF LONG LASTING PATHOLOGICAL COMPLETE RESPONSE. A PHASE II STUDY.

G. de Manzoni<sup>1</sup>, F. Pasini<sup>2</sup>, C. Cordiano<sup>3</sup>, A. Grandinetti<sup>4</sup>, C. Capirci<sup>5</sup>, M. Pavarana<sup>6</sup>, A. Zanoni<sup>1</sup>

<sup>1</sup>Upper G.I. surgery Verona Hospital, Veronal/ITALY, <sup>2</sup>Division of Oncology, Rovigo Hospital, Rovigo/ITALY, <sup>3</sup>I Divisione Clinicizzata di Chirurgia Generale, Veronal/ITALY, <sup>4</sup>UOC Radioterapia, Veronal/ITALY, <sup>5</sup>SOC Radiothrapia, Rovigo/ITALY, <sup>6</sup>UOC Oncologia, Veronal/ITALY

**Background:** This phase II study was aimed at defining pathological response rate of a neoadjuvant schedule including weekly docetaxel and cisplatin, continuous venous infusion (c.i.) of 5-FU and concomitant radiotherapy (RT) in newly diagnosed stage II-III squamous cell carcinoma of mid-distal thoracic esophagus and type I and II adenocarcinoma.

**Methods:** The schedule consisted of a first phase of chemotherapy alone and of a second phase of concurrent chemoradiation. Doses were as follows: docetaxel 35 mg/m<sup>2</sup> and cisplatin 20 mg/m<sup>2</sup> on days 1, 8, 15, 29, 36, 43, 50, 57 plus 5-FU c.i. (180 mg/m<sup>2</sup> days 1-21 and 150 mg/m<sup>2</sup> days 29-63); RT (50 Gy) started at day 29. Surgery was planned 6 to 8 weeks after the completion of chemoradiation.

**Results:** 74 patients were enrolled; pathological complete remission (pCR) was found in 47% (35/74) and near pCR (microfoci of tumor cells on the primary tumor with negative lymph nodes) (pnCR) in 15% of the patients (11/74).

Grade 3-4 neutropenia, Grade 3-4 non hematological toxicity and toxic deaths occurred in 13.5%, 32.4% and 4% of the patients, respectively.

Median follow-up was 55 months (range 3-108). Median survival of all 74 patients was 55 months, while it was not reached in the pCR subset. The 3 and 5 years survival rates were 83%, 73%, 21% and 77%, 44%, 14% ( $p < 0.001$ ) for pCR, pnCR and Residual Tumor subsets, respectively.

**Discussion:** Our study shows that i) this intensive weekly schedule produced a high pathological response rate, ii) responders had high and long-term durable survival rates.

**Disclosure:** All authors have declared no conflicts of interest.

#### 007.05 SURGERY ALONE VERSUS CHEMORADIOTHERAPY FOLLOWED BY SURGERY FOR STAGE I AND II OESOPHAGEAL CANCER: FINAL ANALYSIS OF A RANDOMISED CONTROLLED PHASE III TRIAL - FFCO 9901

Christophe Mariette<sup>1</sup>, Laetitia Dahan<sup>2</sup>, Emilie Maillard<sup>3</sup>, Françoise Mornex<sup>4</sup>, Bernard Meunier<sup>5</sup>, Valerie Boige<sup>6</sup>

<sup>1</sup>University Hospital Of Lille, France, Lille/FRANCE, <sup>2</sup>University Hospital Marseille, Marseille/FRANCE, <sup>3</sup>Federation Francaise De Cancerologie, Dijon/FRANCE, <sup>4</sup>University Hospital Of Lyon, Lyon/FRANCE, <sup>5</sup>University Hospital Of Rennes, Rennes/FRANCE, <sup>6</sup>Gustave Roussy Institute, Villejuif/FRANCE

**Background:** Resection remains the best treatment for local control of oesophageal carcinoma (OC), but local recurrence, distant metastasis and poor survival remain an issue after surgery. Often investigated in locally advanced OC, the impact of neoadjuvant chemoradiotherapy (NCRT) is unknown in patients with stage I or II OC. The aim of this multicentre randomised controlled phase III trial was to assess whether NCRT improves outcomes for patients with stage I or II OC.

**Methods:** 195 patients were randomly assigned to surgery alone (S group, n = 98) or to NCRT group (NCRT group, n = 97; 45 Gy 25 fractions/5 weeks/2 courses of concomitant chemotherapy by 5Fluorouracil 800 mg/m<sup>2</sup> d1-4 and cisplatin 75 mg/m<sup>2</sup> d1). The primary endpoint was overall survival. Secondary endpoints were progression free survival, postoperative morbidity and 30 day-mortality, R0 resection rate and prognostic factor identification. Analysis was done by intention to treat.

**Results:** Patient and tumour characteristics were well-balanced between the two groups. Patients were preoperatively staged I in 18%, IIA in 49.7%, IIB in 31.8%, unknown in 0.5%. Postoperative morbidity and 30 day-mortality rates were 49.5% vs. 43.9% ( $p = 0.17$ ) and 1.1% vs. 7.3% ( $p = 0.054$ ) in the S group and NCRT group, respectively. After a median follow-up of 5.7 years, 106 deaths were observed. Median survivals were 43.8 vs. 31.8 months, respectively (HR 0.92, 95% CI 0.63-1.34,  $p = 0.66$ ). The trial was stopped due to futility.

**Discussion:** Compared with surgery alone, NCRT with cisplatin and 5-Fluorouracil does not improve overall survival but enhances postoperative mortality for patients with stage I or II OC

**Disclosure:** All authors have declared no conflicts of interest.

#### 007.06 A PHASE I/II CLINICAL TRIAL OF PREOPERATIVE SHORT-COURSE CARBON-ION RADIOTHERAPY FOR PATIENTS WITH SQUAMOUS CELL CARCINOMA OF THE ESOPHAGUS

Yasunori Akutsu<sup>1</sup>, Shigeo Yasuda<sup>2</sup>, Matsuo Nagata<sup>3</sup>, Yosuke Izumi<sup>4</sup>, Shinichi Okazumi<sup>5</sup>, Hideaki Shimada<sup>6</sup>, Yukio Nakatani<sup>7</sup>, Hirohiko Tsujii<sup>2</sup>, Tadashi Kamada<sup>2</sup>, Shigeru Yamada<sup>2</sup>, Hisaohiro Matsubara<sup>1</sup>

<sup>1</sup>Department Of Frontier Surgery, Chiba University, Chiba/JAPAN, <sup>2</sup>Research Center Hospital For Charged Particle Therapy, National Institute Of Radiological Sciences (NIRS), Chiba/JAPAN, <sup>3</sup>Department Of Surgery, Chiba Cancer Center, Chiba/JAPAN, <sup>4</sup>Department Of Surgery, Tokyo Metropolitan Cancer And Infectious Disease Center, Komagome Hospital, Tokyo/JAPAN, <sup>5</sup>Department Of Surgery, Toho University Sakura Medical Center, Chiba/JAPAN, <sup>6</sup>Department Of Surgery, Toho University School Of Medicine, Omori Medical Center, Toyo/JAPAN, <sup>7</sup>Department Of Diagnostic Pathology, Graduate School Of Medicine, Chiba University, Chiba/JAPAN

**Background:** Carbon-ion radiotherapy (CIR) has been under development. We report the results of a phase I/II clinical trial of preoperative CIR for esophageal squamous cell carcinoma (ESCC).

**Methods:** Thirty-one thoracic ESCC patients were enrolled. They were first treated with CIR. The radiation dose was escalated from the initial dose of 28.8 GyE up to 36.8. Four to 8 weeks after CIR followed by clinical evaluation of the therapy, surgery was performed. Thereafter, a pathological evaluation was made.

**Results:** Acute toxicity was not seen except in one case (3.2%), and there were no late toxicities. Throughout the study period, there were no cases of withdrawal due to the effects of preoperative CIR. Twelve out of 31 (38.7%)

patients achieved a clinical complete response (CR) and 13 patients (41.9%) achieved a partial response. Twelve out of 31 patients (38.7%) achieved a pathological CR. The overall 1-, 3-, and 5-year survival rates in the stage I cases were 91%, 81%, and 61%, and was 100%, 85%, and 77% for the stage II, and 71%, 43%, and 29% for the stage III cases, respectively.

**Discussion:** CIR showed strong local tumor control and is highly effective as a neoadjuvant therapy without severe adverse events.

**Disclosure:** All authors have declared no conflicts of interest.

#### 007.07 RELEVANCE OF EXTRACAPSULAR LYMPH NODE INVOLVEMENT IN PT2 ADENOCARCINOMA OF THE ESOPHAGUS

Ralf Metzger<sup>1</sup>, Dietmar Lorenz<sup>2</sup>, Ines Gockel<sup>3</sup>, J Origer<sup>2</sup>, T Junginger<sup>3</sup>, U Drebber<sup>1</sup>, T Hansen<sup>3</sup>, K Krümpelmann<sup>3</sup>, Hauke Lang<sup>3</sup>, Arnulf Hölscher<sup>4</sup>, Elfriede Bollschweiler<sup>1</sup>

<sup>1</sup>Dept. Of General-, Visceral And Cancer Surgery, University Of Cologne, Cologne/GERMANY, <sup>2</sup>Dept. Of General- And Visceral Surgery, Horst Schmidt Klinikum, Wiesbaden, Germany, Wiesbaden/GERMANY, <sup>3</sup>(1) Department Of General And Abdominal Surgery, University Of Mainz, Germany, Mainz/GERMANY, <sup>4</sup>Department Of General-, Visceral- And Cancer Surgery, University Of Cologne, Cologne/GERMANY

**Background:** Extracapsular lymph node involvement (ELNI) is accused to be a predictor for poor prognosis. Aim of the study was to assess the relevance of ELNI in patients with pT2 tumors.

**Methods:** Patients with pT2 adenocarcinoma of the esophagus from three expert centers for upper GI surgery were included. There were 159 patients (m:139, f:20) without induction therapy. Median age was 64.5 years. Survival was analyzed according to intra- and extracapsular lymph node involvement (LNI).

**Results:** Median number of examined lymph nodes was 26 (range 3–75). In 37% of the patients (n = 59) no lymph node involvement (pN0) was detected; 100 patients (63%) were positive. ELNI was detectable in 55 of the 100 pN+ patients. 30- and 90-day mortality for all patients was 2.6% and 3.8% respectively. Results were comparable in all participating hospitals. Overall 5 year survival rate (5-YSR) for all patients with pT2 tumors was 37%. Patients without lymph node involvement had a 5-YSR of 62%. Detection of LNI without extracapsular tumor spread resulted in a 5-YSR of 36%. Proof of ELNI decreased the 5-YSR to 14%. Multivariate analysis according to prognosis revealed only the lymph node status as a significant parameter (p < 0.001): pN0: HR = 1 (reference), pN+ without ELNI: HR = 2.2 (95% CI = 1.2–3.8), pN+ with ELNI: HR = 2.5 (95%CI = 1.5–4.5)

**Discussion:** Based on the finding that 63% of the patients with pT2 tumors present with lymph node metastases - more than half of them with extracapsular tumor spread already - treatment strategies should focus on a multimodal approach including neoadjuvant regimens to optimize therapy results.

**Disclosure:** All authors have declared no conflicts of interest.

#### 007.08 NEOADJUVANT CHEMORADIO THERAPY WITH DOCETAXEL, CISPLATIN AND 5-FLUOROURACIL WITH 50 GY OF CONCURRENT RADIO THERAPY: RESULTS OF A PHASE II STUDY.

Giuseppe Verlati<sup>1</sup>, Andrea Zanoni<sup>2</sup>, Simone Giacopuzzi<sup>3</sup>, Felice Pasini<sup>3</sup>, Antonio Grandinetti<sup>4</sup>, Michele Pavarana<sup>5</sup>, Francesco Casella<sup>2</sup>, Giovanni De Manzoni<sup>2</sup>

<sup>1</sup>Epidemiology And Medical Statistics, University Of Verona, Verona ITALY, <sup>2</sup>Upper G.I. Surgery Division University Of Verona, Verona ITALY, <sup>3</sup>Division Of Oncology, Rovigo Hospital, Rovigo ITALY, <sup>4</sup>Division Of Radiotherapy, Azienda Ospedaliera-Universitaria Integrata Verona, Verona ITALY, <sup>5</sup>Division Of Oncology, Azienda Ospedaliera-Universitaria Integrata Verona, Verona ITALY

**Background:** Neoadjuvant chemoradiotherapy (CRT) is now considered the standard of care by many centers in the treatment of both squamous cell carcinoma (SCC) and adenocarcinoma of the esophagus. This study presents the results of a phase II trial, evaluating a new protocol of neoadjuvant concomitant CRT.

**Methods:** From 2003 to 2011, at Upper G.I. Division of Verona Hospital, 155 consecutive patients with locally advanced esophageal cancers (90 SCC and 65 adenocarcinoma) were treated with a single protocol of neoadjuvant CRT (docetaxel, cisplatin and 5-fluorouracil with 50 Gy of concurrent radiotherapy). Response to CRT was evaluated through percentage of pathological complete response (pCR or ypT0N0), and overall (OS) and disease-related (DRS) survival.

**Results:** One hundred thirty-one patients (85%) underwent two-field surgery. Six patients were not operated on because of treatment toxicity and 18 because of disease progression. Radical resection (R0) was achieved in 123 patients (79%), and pCR in 65 (42%). Post-operative mortality was 0.7% (1 case). Five-year OS and DRS were respectively 43% (95% CI 34–52%)

and 49% (39–58%) in the entire cohort, 52% (41–62%) and 59% (48–69%) in R0 cases, 72% (57–82%) and 81% (65–90%) in pCR cases. Survival did not significantly differ between SCC and adenocarcinoma. Forty-three patients (33% of the operated on patients) died from relapse.

**Discussion:** This phase II trial suggests that patients treated with the present protocol achieve good survival with a very high percentage of pCR. The non-negligible toxicity requires anyway to be managed in specialized centers.

**Disclosure:** All authors have declared no conflicts of interest.

#### 007.09 META-ANALYSIS OF LYMPH NODE METASTASIS RATE FOR PATIENTS WITH THORACIC ESOPHAGEAL CANCER AND ITS IMPLICATION IN DELINEATION OF CLINICAL TARGET VOLUME FOR RADIATION THERAPY

Baosheng Li, Jian Zhang

Shandong Cancer Hospital, Jinan/CHINA

**Background:** To pool the lymph node metastasis (LNM) in thoracic esophageal cancer (TEC) patients, to assess the clinical factors affecting LNM, and to determine which node level should be included while radiotherapy.

**Methods:** Series of studies were identified through Medline, Embase, CBM, and the Cochrane Library searches and analyzed by a pooled estimate of LNM using a random effect model. Possible effect modifiers which led to the statistical heterogeneity were identified through the meta-regression model and further subgroup analysis of influencing LNM were performed. Forty-five observational studies with a total of 18,415 patients were included.

**Results:** The pooled estimates of LNM in patients with upper, middle, and lower TEC were: 30.7%, 16.8%, and 11.0% cervical; 42.0%, 21.1%, and 10.5% upper mediastinal; 12.9%, 28.1%, and 19.6% middle mediastinal; 2.6%, 7.8%, and 23.0% lower mediastinal; 9%, 21.4%, 39.9% abdominal; and 16.9%, 28.7%, and 34.8% paraesophageal, respectively. The LNM occurred most frequently at paratracheal, 106 recR, 101 and 105 in the upper thoracic esophageal carcinoma, paraesophageal, perigastric, 108 and 106 recR in the middle, and perigastric, pericardial, Station 7 and paraesophageal to the lower. It was found LNM was significantly affected by the mean number of resected lymph nodes, percentage of male patients, percentage of 3FLD, percentage of middle or low TEC.

**Discussion:** The study provides useful information on how to define CTV of TEC patients, who will undergo radiotherapy.

**Disclosure:** All authors have declared no conflicts of interest.

#### 007.10 COMPLETE CLINICAL RESPONSE AFTER NEOADJUVANT CHEMORADIO THERAPY FOR SQUAMOUS CELL CANCER OF THE THORACIC OESOPHAGUS: IS SURGERY STILL NECESSARY?

Rita Alfieri<sup>1</sup>, Carlo Castoro<sup>1</sup>, Marco Scarpa<sup>1</sup>, Matteo Cagol<sup>1</sup>, Alberto Ruol<sup>2</sup>, Francesco Cavallin<sup>1</sup>, Silvia Michieletto<sup>1</sup>, Vanna Chiarion Sileni<sup>3</sup>, Luigi Corti<sup>4</sup>, Ermanno Ancona<sup>5</sup>

<sup>1</sup>Surgical Oncology, Veneto Oncological Institute, Padova ITALY, <sup>2</sup>Dept. Of Surgical And Gastroenterological Sciences, University Of Padova, Padova ITALY, <sup>3</sup>Clinical Oncology, Istituto Oncologico Veneto, Padova ITALY, <sup>4</sup>Radiotherapy, Veneto Oncological Institute, Padova ITALY, <sup>5</sup>Dept. Of Surgical And Gastroenterological Sciences, University Of Padova, Padova ITALY

**Background:** The aim of this study was to compare, in term of post-operative survival, patients who had clinical complete response (CR) after neoadjuvant CT-RT for squamous cell carcinoma (SCC) of the thoracic oesophagus and those who had CR and also had oesophagectomy.

**Methods:** Data of 1,639 patients with oesophageal SCC who had clinical complete response (CR) after neoadjuvant CT-RT were prospectively collected from 1992 to 2007. All the 77 consecutive patients with CR after neoadjuvant CT-RT were included. Thirty-nine patients underwent oesophagectomy (CT-RT + oesophagectomy), while 38 (CT-RT) were not operated on because unfit for surgery or refused the operation.

**Results:** Overall survival (OS) was similar in both (5-year-survival: 50% in the CT-RT + oesophagectomy-group vs. 57% in the CT-RT-group, p = 0.99). Upon multivariate survival analysis, advanced pulmonary disease was the only independent predictor of OS [RR = 4.21(95%CI:1.85-9.56), p < 0.001]. Among the patients who had CT-RT + oesophagectomy and those who had CT-RT alone, the 5-year disease-free cumulative survival rates were 55.5% and 34.6% (p = 0.15).

**Discussion:** Patients who had clinical CR to neoadjuvant CT-RT for oesophageal-SCC had the same OS, whether or not they underwent surgery. However, clinical CR was accurately diagnosed in only two-thirds of cases. More accurate restaging protocols are warranted to improve decision-making.

**Disclosure:** All authors have declared no conflicts of interest.

**O07.11 VERIFICATION OF THE OPTIMAL PERIOPERATIVE TIMING OF SURGICAL ADJUVANT THERAPY FOR PATIENTS WITH ESOPHAGEAL SQUAMOUS CELL CARCINOMA**

Nobutoshi Ando<sup>1</sup>, Hiroyasu Igaki<sup>2</sup>, Masayuki Shinoda<sup>3</sup>, Haruhiko Fukuda<sup>4</sup>

<sup>1</sup>Tokyo Dental College Ichikawa General Hospital, Ichikawa/JAPAN, <sup>2</sup>National Cancer Center Hospital, Tokyo/JAPAN, <sup>3</sup>Aichi Cancer Center Hospital, Nagoya/JAPAN, <sup>4</sup>Japan Clinical Oncology Group Data Center, Tokyo/JAPAN

**Background:** The Japan Clinical Oncology Group trial (JCOG9204) comparing postoperative adjuvant chemotherapy using cisplatin plus 5-fluorouracil (5-FU) with surgery alone showed superior disease-free survival in postoperative chemotherapy for patients with esophageal squamous cell carcinoma (ESCC) (Ando N, et al, J Clin Oncol 2003). JCOG conducted a randomized controlled trial to evaluate optimal perioperative timing, i.e. before or after surgery, for implementing chemotherapy in patients with locally advanced ESCC.

**Methods:** Eligible patients with clinical stage II or III, excluding T4, ESCC were randomly assigned to undergo surgery followed (Post group) or preceded (Pre group) by chemotherapy consisting of two courses of cisplatin plus 5-FU. The primary endpoint was progression-free survival.

**Results:** Between May 2000 and May 2006, 330 patients (Post /Pre: 166/164, cN0/N1: 114/216) from 24 institutions were randomized. The planned interim analysis was conducted after completion of patient accrual. Since the overall survival in the Pre group was remarkably superior to that of the Post group (p = 0.01), the Data and Safety Monitoring Committee recommended early publication. Updated analyses showed the 5-year overall survival to be 42.7% in the Post group and 55.0% in the Pre group (hazard ratio 0.73, 95% confidence interval 0.54-0.99; p = 0.04), where the median follow-up of censored patients was 61.6 months. Concerning operative morbidity, renal dysfunction after surgery in the Pre group was slightly higher than in the Post group.

**Discussion:** Giving chemotherapy before surgery is optimal timing and preoperative chemotherapy with cisplatin plus 5-FU followed by surgery can be regarded as a standard treatment for stage II/III ESCC.

**Disclosure:** All authors have declared no conflicts of interest.

**ORAL SESSION O08: ESOPHAGEAL MOTILITY DISORDERS – October 17, 2012 10:20–11:50**

**O08.01 MEDIUM AND LONG-TERM OUTCOMES AFTER LAPAROSCOPIC HELLER MYOTOMY OR PNEUMATIC DILATION FOR ACHALASIA: A META-ANALYSIS**

Cynthia Weber, Christopher Davis, P Marco Fisichella  
Loyola University Medical Center, Maywood/IL/UNITED STATES OF AMERICA

**Background:** Although the short-term outcomes for the treatments of achalasia have been reported, the medium and long-term outcomes are less known. The aim of this study was to compare by meta-analysis the medium and long-term outcomes (5 and 10-year) after laparoscopic Heller myotomy (LHM) and pneumatic dilation (PD).

**Methods:** We performed a systematic search of Pubmed to identify cohort studies (retrospective or prospective) published between 2001 and 2011 with at least 5 years of follow-up after treatment for achalasia using LHM or PD.

**Results:** We identified a total of 36 studies (16 included LHM and 20 included PD). Overall, 1526 patients, mean age 46.3 years, were treated with LHM; 82.8% (1264 patients) received a fundoplication (796 Dor, 148 Toupet, 4 Belsey, and 316 Nissen). Using a random effects model, the mean 5-year remission rate was 76.1% (95% CI: 68.5%-83.7%), and the mean 10-year remission rate was 79.6% (95% CI: 54.3%-). Similarly, 3211 patients, mean age 49.8 years, were treated with PD. The most widely used dilator was the Microvasive-Rigiflex, though technique varied. The mean 5-year remission rate was 61.9% (95% CI: 52.2%-71.7%), and the mean 10-year remission rate was 47.9% (95% CI: 35.7%-60.1%). The mean change in LES pressure was 18.6 mmHg (95% CI: 16.1 -21.0 mmHg). The perforation rate was 4.8% for LHM and 2.4% for PD (p < 0.01).

**Discussion:** Although LHM and PD represent viable long term treatments for achalasia, LHM offers higher 5 and 10 year remission rates than PD but suffers from a higher perforation rate.

**Disclosure:** All authors have declared no conflicts of interest.

**O08.02 A COMPARISON OF PER-ORAL ENDOSCOPIC MYOTOMY (POEM) AND HELLER MYOTOMY FOR ACHALASIA**

Neil Bhayani<sup>1</sup>, Ashwin Kurian<sup>1</sup>, Ahmed Sharata<sup>2</sup>, Kevin Reavis<sup>2</sup>, Christy Dunst<sup>2</sup>, Lee Swanstrom<sup>2</sup>

<sup>1</sup>Providence Cancer Center, Portland/UNITED STATES OF AMERICA, <sup>2</sup>The Oregon Clinic, Portland/UNITED STATES OF AMERICA

**Background:** The surgical gold-standard for achalasia is laparoscopic esophageal myotomy (Heller). There is a novel, less-invasive alternative: Per-Oral Endoscopic Myotomy (POEM). We compare their safety and efficacy.

**Methods:** We collected data on our Hellers and POEMs for achalasia from 1993–2011. Primary outcomes: postoperative dysphagia and heartburn, 1 and 6 months after surgery. Secondary outcomes: operative time, morbidities, 6-month manometry & 24-hour pH.

**Results:** There were 140 patients: 116 Hellers (with 75% Toupet & 19% Dor funduplications) & 24 POEMs (no fundoplication). Presenting symptoms were comparable. Median operative time = 149 minutes for Hellers v. 120 minutes for POEMs; mean hospitalization = 2.2 and 1.1 days, respectively. Esophageal perforations occurred for 3 POEMs and 8 Hellers, without clinical consequence. Post-operative bleeding required transfusion for one POEM & re-operation for one Heller. POEMs experienced more pre-operative liquid dysphagia (p = 0.02). At 1 month, POEMs reported more chest pain, (13% v 0%, p = 0.004) but less dysphagia to solids (0% v 21%, p = 0.01). By 6 months, the only difference was more solid dysphagia after Heller (36% v. 0%, p = 0.004). Initially, POEMs recorded higher LES pressures v. Hellers (48 v. 32 mmHg, p = 0.01). At 6 months, POEM LES resting (24.1 v.19.3, p = 0.2) and residual pressures (7.9 v. 5.8, p = 0.2) were similar to Heller. Postoperatively, 33% of POEMs and 26% of Hellers had abnormal DeMeester scores (p = 0.7).

**Discussion:** The POEM is comparable to laparoscopic Heller for safe, effective treatment of achalasia. Symptoms and esophageal physiology are similar between Heller with fundoplication compared to POEM. Prospective comparisons are needed.

**Disclosure:** All authors have declared no conflicts of interest.

**O08.03 INTRAOPERATIVE DISTENSIBILITY MONITORING DURING LAPAROSCOPIC HELLERS MYOTOMY FOR ACHALASIA REVEALS NO DECREASE IN OESOPHAGOGASTRIC JUNCTION DISTENSIBILITY FROM ADDITION OF A FUNDOPPLICATION**

Andrei Ilcyszyn, Joanna Cartwright, Abraham Botha  
Guys And St Thomas' Nhs Trust, London/UNITED KINGDOM

**Background:** Laparoscopic Hellers myotomy (LHM) is associated with better long-term outcomes and symptomatic improvement when compared to endoscopic balloon dilatation (EBD). However, uptake of LHM is limited by the theoretical risk of post-operative reflux. Fundoplication may reduce the incidence of reflux but increases the risk of dysphagia. It has recently been postulated that OGJ distensibility after treatment for achalasia may be a better method of evaluating outcome, correlating well with oesophageal emptying and recurrent symptoms. We therefore measured distensibility intra-operatively to assess whether adding a fundoplication after myotomy increases or decreases the distensibility.

**Methods:** Patients with achalasia underwent LHM and partial anterior fundoplication by standardised technique. A functional luminal imaging system (FLIP) (EndoFLIP EF-325) was used to calculate the 30-second median distensibility by distending a balloon tipped catheter at the OGJ to 30 and 40 mL before myotomy, after myotomy and after fundoplication. Statistical comparison used sequential paired t-tests with P ≤ 0.05 being taken as significant.

**Results:** Eleven patients were studied (average age 46.3 (28–63), 4M7F). Myotomy resulted in a significant increase in the distensibility of the OGJ of up to 2.7x.

	mL	Preop	Pneumoperitoneum	Myotomy	Fundoplication
Distensibility (mm <sup>2</sup> /mmHg)	30	3.56	2.00*	5.40*(x2.7)	5.78
	40	2.41	3.87	7.87*(x2.0)	7.26

P < 0.05

**Discussion:** LHM results in an immediate statistically significant increase in the distensibility of the OGJ of up to 2.7x, fundoplication does not appear to significantly affect this. Further intraoperative studies with the EndoFLIP system may lead to optimisation of the myotomy to relieve dysphagia and as well as the fundoplication to prevent GORD.

**Disclosure:** All authors have declared no conflicts of interest.

**008.04 CHANGES IN INDICATION FOR ESOPHAGECTOMY IN ESOPHAGEAL ACHALASIA. ANALYSIS OF 1,697 CONSECUTIVE PATIENTS**

Rubens Sallum<sup>1</sup>, Ivan Ceconello<sup>2</sup>, Julio Rocha<sup>3</sup>, Sergio Szachnowicz<sup>4</sup>, Angela Falcao<sup>2</sup>, Francisco Seguro<sup>5</sup>, Flavio Takeda<sup>2</sup>

<sup>1</sup>University Of Sao Paulo, Sao Paulo/BRAZIL, <sup>2</sup>Esophageal Surgical Division Univ Of Sao Paulo, Sao Paulo/BRAZIL, <sup>3</sup>Esophageal Surgical Division Univ Of Sao Paulo, Sao Paulo, Brazil, Sao Paulo/BRAZIL, <sup>4</sup>Department Of Gastroenterology – Esophageal Surgical Division, University Of São Paulo School Of Medicine, São Paulo - Brazil, São Paulo/BRAZIL, <sup>5</sup>Hospital Das Clínicas - Fmusp, São Paulo/BRAZIL

**Background:** Esophagectomy is an important indication in end-stage esophageal achalasia (EA), however accompanied by significant morbimortality and late complications such as cervical reflux and Barrett's esophagus in the cervical stump. The conservative surgical treatment (cardiomyotomy), has gained importance in the treatment of borderline forms of end-stage achalasia.

**Aim:** To evaluate the rate of current indication of esophagectomy in relation to other therapeutic procedures and compare it to historical group.

**Methods:** We analyzed from 2000 to 2011 637 patients of EA. Esophagectomy was performed in 30. These data were compared to the previous historical period (1977–1999) when 1060 patients were treated, with 164 esophagectomies performed.

**Results:** From 30 esophagectomies performed, end-stage form was the most frequent indication with 12 patients (40%). Cancer associated was the second indication- 10 patients (33.3%) and was prevalent in 1.5 % of treated cases. In 8 patients (26.6%) indication was failure of the previous conservative surgical treatment. Comparing to the historical period, the annual esophagectomy rate fell from 7.1 esophagectomies / year to 2.7. The indication of esophagectomy when compared to all therapeutic procedures fell from 15.4% (historical) to 4.7% (current period).

**Discussion:** Conclusions: Esophagectomy remains a therapeutic option in esophageal achalasia, however with more restricted indications. The association with cancer has a significant prevalence (1.5%), becoming one of the main indications.

**Disclosure:** All authors have declared no conflicts of interest.

**008.05 ESOPHAGEAL ACHALASIA: WHAT IF MYOTOMY IS NOT ENOUGH?**

Lisa Zanatta<sup>1</sup>, Mario Costantini<sup>1</sup>, Tiziana Morbin<sup>1</sup>, Renato Salvador<sup>1</sup>, Elena Finotti<sup>1</sup>, Loredana Nicoletti<sup>1</sup>, Gianpietro Zanchettin<sup>1</sup>, Luca Faccio<sup>1</sup>, Giovanni Zaninotto<sup>2</sup>, Ermanno Ancona<sup>1</sup>

<sup>1</sup>University Of Padua, Department Of Surgical And Gastroenterological Sciences, Clinica Chirurgica 1, Padua/ITALY, <sup>2</sup>Department Of General Surgery, Ss Giovanni E Paolo Hospital, Ulss 12, Venezia/ITALY

**Background:** Laparoscopic Heller myotomy (LHM) is the currently preferred treatment for esophageal achalasia (EA), allowing good results in about 90% of patients. Less it is known on the fate of patients not responding to surgery, and on their most appropriate treatment.

**Methods:** Patients undergoing LHM for EA were prospectively evaluated. Failure was defined as a postoperative symptom score > 10<sup>th</sup> percentile of the preoperative score in the whole series of patients.

**Results:** 662 patients (54% males) underwent LHM. Symptoms were relieved in 588, whereas 74 patients (11.1%) developed recurrence at a median of 11.5 months (range 1–143). Chest pain, sigmoid esophagus or low LES resting pressure predicted the failure of LHM. All but one of the patients with symptom recurrence underwent a median of 2 complementary pneumatic dilations (range 1–11), with symptom relief in 62 (85%). One patient (with sigmoid esophagus) needed early reoperation for a misshaped fundoplication. No complications of dilations were recorded; however, reflux developed in 3 patients (4%). The overall success rate of this combined treatment (LHM and complementary dilations) was therefore 98% (650/662). Of the 11 not-responder patients, 5 refused further treatment, while 6 underwent revisional surgery: a new myotomy was laparoscopically performed in 5, whereas in one patient with sigmoid esophagus esophagectomy was considered more appropriate. All these 6 patients were finally cured from their symptoms.

**Discussion:** When symptoms recur after LHM, complementary dilations are highly effective and symptom relief is complete in nearly all the patients. Only a minority requires further surgical treatment for the resolution of their symptoms.

**Disclosure:** All authors have declared no conflicts of interest.

**008.06 REMEDIAL LAPAROSCOPIC MYOTOMY FOR RECURRENT ESOPHAGEAL ACHALASIA AFTER FAILED SURGICAL TREATMENT.**

Mario Costantini<sup>1</sup>, Michela Di Giunta<sup>1</sup>, Renato Salvador<sup>1</sup>, Lisa Zanatta<sup>1</sup>, Tiziana Morbin<sup>1</sup>, Laura Polizzi<sup>1</sup>, Giovanni Capovilla<sup>1</sup>, Alberto Ruol<sup>1</sup>, Giovanni Zaninotto<sup>2</sup>, Ermanno Ancona<sup>1</sup>

<sup>1</sup>University Of Padua, Department Of Surgical And Gastroenterological Sciences, Clinica Chirurgica 1, Padua/ITALY, <sup>2</sup>Department Of General Surgery, Ss Giovanni E Paolo Hospital, Ulss 12, Venezia/ITALY

**Background:** Laparoscopic myotomy allows the resolution of symptoms of achalasia in about 90% of patients. Recurrences are usually managed with complementary endoscopic dilations, and only a minimal percentage of patients needs revisional surgery. In this study we review our experience with laparoscopic redo-myotomy in such patients.

**Methods:** From 2002, 26 patients underwent revisional laparoscopic surgery for failed myotomy. Five were from our series, 21 were referrals. Their median age was 44 (11–78), 10 were male. The distance from previous operation was 87 (1–380) months. Nineteen patients had had the first operation laparoscopically, 7 open (1 thoracotomy). They had a median of 3 (1–6) complementary dilations before revisional surgery was planned. Ten patients had grade II, 11 grade III and 5 grade IV achalasia.

**Results:** All operations were performed laparoscopically. One open revision in 2nd POD was necessary for a perforation at the re-myotomy site. The median symptom-score decreased from 17(8–32) to 7(0–28)(p < 0.05). However, 7 patients needed further endoscopic dilations, and 2 eventually required an esophagectomy (both had stage IV disease). Good results were therefore obtained in 17 patients (65%). Post-operative reflux was found in 6 patients (23%).

**Discussion:** Revisional laparoscopic myotomy is seldom necessary, but it is feasible when primary surgery and complementary dilations fail to cure the symptoms of achalasia. One-third of the patients still requires further dilations or even esophagectomy, but the resolution of the symptoms can be offered to 65% of this selected group of patients who are highly refractory to standard treatment.

**Disclosure:** All authors have declared no conflicts of interest.

**008.07 THE EVOLUTION OF SYMPTOMS AND QUALITY OF LIFE IN PATIENTS WITH UNTREATED ACHALASIA**

Wael Hanna<sup>1</sup>, Linda Miller<sup>2</sup>, Christian Finley<sup>2</sup>, Gail Darling<sup>2</sup>

<sup>1</sup>Toronto General Hospital, Toronto/CANADA, <sup>2</sup>Toronto General Hospital, Toronto/ON/CANADA

**Background:** A third of patients with achalasia elect not to receive treatment. The objectives of this study are to define the evolution of symptoms and quality of life in these patients.

**Methods:** Patients with a manometric diagnosis of achalasia who opted for no treatment between 2004–2007 were enrolled. A validated Achalasia Symptom Score questionnaire was completed at initial manometry and at 3-month intervals for one year. Progression of symptoms was measured by the difference in scores at each time period. Significance was determined using the Freeman-Halton extension of Fisher's exact test (p

**Results:** Over a 3-year period, 36/125 patients with achalasia (29%) elected not to undergo treatment. The majority were male (81%). Mean Achalasia Score was 25 at presentation and 29 at end of follow-up (p > 0.05). Median dysphagia score at presentation was 1 (0–4) and 17% of patients worsened over time whereas 72% did not (p = 0.04). Odynophagia worsened in 22% of patients and was stable in 64% (p = 0.06). At diagnosis, 64% of patients found that they are forced to eat slowly, and this did not improve (83%) or worsened (11%) in most of them (p = 0.03). Only 50% of patients thought their disease limited their life-style, and this did not worsen significantly (11%, p > 0.05) over time.

**Discussion:** The majority of patients with untreated achalasia are men. Despite worsening symptoms, these patients do not report worsening limitations to their quality of life, suggesting that they adapt to the disease process rather than seek treatment.

**Disclosure:** All authors have declared no conflicts of interest.

**008.08 NATIONWIDE TREATMENT AND OUTCOMES IN PATIENTS HOSPITALIZED WITH ESOPHAGEAL ACHALASIA IN THE UNITED STATES**

Daniela Molena<sup>1</sup>, Miloslawa Stem<sup>2</sup>, Avedis Meneshian<sup>1</sup>, Anne Lidor<sup>2</sup>

<sup>1</sup>Johns Hopkins University School Of Medicine, Baltimore/MD/UNITED STATES OF AMERICA, <sup>2</sup>Johns Hopkins University Som, Baltimore/MD/UNITED STATES OF AMERICA

**Background:** While the outcomes after Heller myotomy have been extensively reported, little is known about patients with esophageal achalasia who are admitted for other treatments.



**Methods:** This was a retrospective analysis using the Nationwide Inpatient Sample over a 7-year period (2003–2009). Patients admitted with a primary diagnosis of achalasia were divided into 3 groups based on their treatment. Group 1: patients who underwent Heller myotomy during their hospital stay; Group 2: patients who underwent esophagectomy; Group 3: patients not undergoing surgical treatment. Primary outcome was in-hospital mortality. Secondary outcomes included length of stay (LOS), discharge destination and total hospital charges.

**Results:** Among 27,141 patients admitted with achalasia, about half (48.6%) underwent Heller myotomy, 2.4% underwent esophagectomy and 49% had

endoscopic or other treatment. Group 1 were younger, healthier, and had the lowest mortality when compared with the other two groups. Group 2 had the highest LOS and hospital charges among all groups. Interestingly, despite undergoing no surgical procedures, group 3 had the highest mortality (1.15%,  $p < 0.001$ ) and the lowest home discharge rate (79%,  $p < 0.001$ ) when compared to the other groups (Table). The most frequently performed procedures among Group 3 were esophageal dilatation (25.9%) and injection (13.3%). Among patients who died in this group the most common associated morbidities included acute respiratory failure, sepsis and aspiration pneumonia.

**Baseline demographics and outcomes of patients admitted with achalasia, NIS, 2003-2009**

	Total N=27,141	GROUP 1 n <sub>1</sub> =13,177 48.55%	GROUP 2 n <sub>2</sub> =652 2.40%	GROUP 3 n <sub>3</sub> =13,312 49.05%	p
Age, mean (median)	59.0 (59)	51.1 (51)	53.5 (54)	67.2 (72)	<0.001
Gender					<0.001
Male (%)	12,356 (45.53%)	6,739 (51.14%)	298 (45.71%)	5,319 (39.96%)	
Mean Charlson score	0.61	0.33	0.47	0.90	0.041
In-hospital Mortality	163 (0.60%)	< 11*	< 11*	153 (1.15%)	<0.001
Median length of stay (days)	3	2	12	4	<0.001
Disposition					
Home <sup>a</sup>	87.81%	97.07%	82.87%	78.87%	<0.001
Transfer <sup>b</sup>	11.17%	2.80%	16.31%	19.20%	<0.001
Median total hospital charges	\$26,199.59	\$29,931.46	\$127,080.20	\$20,953.47	<0.001

\*HCUP DUA prohibits reporting of fewer than 11 observations. <sup>a</sup> Home is discharge to home with and without home health care. <sup>b</sup> Transfer is discharge to short term hospital, skilled nursing facility, intermediate care and other type of facilities.

**Discussion:** The surgical management of achalasia carries exceedingly low mortality in the modern era, while non-operative treatment is associated with uniformly poorer outcomes.

**Disclosure:** All authors have declared no conflicts of interest.

**O08.09 THE MANOMETRIC PATTERN REPRESENTS A DIFFERENT STAGE OF ESOPHAGEAL ACHALASIA**

Renato Salvador<sup>1</sup>, Mario Costantini<sup>1</sup>, Giovanni Zaninotto<sup>1</sup>, Lisa Zanatta<sup>1</sup>, Elena Finotti<sup>1</sup>, Cristina Longo<sup>1</sup>, Michela Di Giunta<sup>1</sup>, Nicola Passuello<sup>1</sup>, Giulia Pozza<sup>1</sup>, Giorgia Dogá, Gianfranco Da Dalt<sup>1</sup>, Loredana Nicoletti<sup>1</sup>, Francesco Cavallin<sup>2</sup>, Ermanno Ancona<sup>1</sup>

<sup>1</sup>University Of Padua, Department Of Surgical And Gastroenterological Sciences, Clinica Chirurgica 1, PadovaITALY, <sup>2</sup>Surgical Oncology, Istituto Oncologico Veneto, Iov-Ircs, PadovaITALY

**Background:** A new proposed manometric-pattern classification (pattern 1: no-distal esophageal pressurization, pattern 2: rapidly propagated compartmentalized pressurization, pattern 3: rapidly propagated pressurization attributable to spastic contraction) has changed the diagnostic achalasia assessment. The aim was to investigate if these three patterns represent a different stage of the same disease.

**Methods:** We pre-postoperatively evaluated patients who underwent surgery as first treatment between 2001–2011. Patients with sigmoid-shaped-esophagus were excluded. Symptom-score, barium-swallow, endoscopy and manometry were performed, before and 6 months after surgery. Failure was defined as a postoperative symptom-score > 10th-percentile of the preoperative score (i.e.: > 8).

**Results:** 318 consecutive patients (M = 179) were evaluated. Pattern 3 had shorter duration/severity of symptoms, narrower esophageal diameter, longer overall/abdominal LES length than those in the other groups. Median follow-up was 32 months (IRQ:16–56). The % of failure was significantly different ( $p = 0.001$ ): pattern 1 (11.4%), pattern 2 (4.6%), pattern 3 (25.7%). Almost 50% of pattern 3 patients “progressed” to pattern 1&2 after surgery; the opposite was never observed.

	Pattern 1 + 2 n = 283	Pattern 3 n = 35	p-values
Age	42 (31–55)	48 (33–55)	0.61
Symptom-duration (months)	24 (12–48)	12 (7–24)	0.05
Symptom-score	19 (14–20)	16 (9–20)	0.02
Chest pain score	5 (0–8)	7 (3–9)	0.05
LES-resting-pressure (mmHg)	28 (20–40)	29 (19–43)	0.94
LES-residual-pressure (mmHg)	9 (4.3–14)	7 (2.4–11)	0.19
Nº impaired-relaxation	138 (74.2%)	10 (41.6%)	0.01
LES-overall-length (mm)	39 (32–47)	50 (41–55)	0.001
LES-abdominal-length (mm)	25 (18–33)	34 (25–37)	0.001
Esophageal-diameter (mm)	36 (30–45)	30 (25–35)	0.003

**Discussion:** Pattern 3 may represent an earlier stage of the disease. Moreover, this study confirms that pattern 1&2 have a better outcome after surgery.

**Disclosure:** All authors have declared no conflicts of interest.

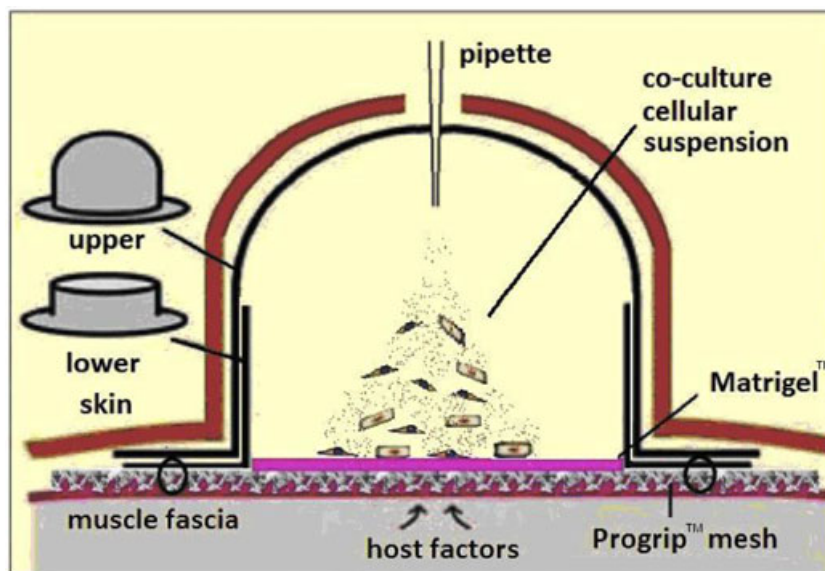
**ORAL SESSION O09: ESOPHAGEAL CARCINOGENESIS (2) – October 17, 2012 13:30–15:00**

**O09.01 DEVELOPING A NOVEL IN VIVO TISSUE RECONSTITUTION SYSTEM FOR THE STUDY OF BARRETT’S OESOPHAGUS.**

Matthew Read, Dan Croagh, Nicholas Clemons, Christina Fennell, Cuong Duong, Wayne Phillips  
Division Of Cancer Surgery, Peter Maccallum Cancer Centre, East MelbourneVIC/AUSTRALIA

**Background:** Studying the pathogenesis of Barrett’s oesophagus (BO) requires a reliable and reproducible model that closely mimics normal processes. A limitation of *in vitro* models is that they fail to incorporate the complex interaction between multiple cell types, including the inflammatory response. This study seeks to evaluate a novel *in vivo* tissue reconstitution model that has the potential to overcome this problem.

**Methods:** A commercially available silicone chamber (hat chamber) is attached to the dorsal fascia of a SCID mouse by means of a polyester mesh. Once attached, a suspension containing both stromal and epithelial cells derived from human tissue is injected into the chamber. Reconstituted tissue is assessed by both histological analysis and immunohistochemistry staining for epithelial and human specific markers.



**Results:** Early results have demonstrated secure chamber fixation, wound healing and mouse tolerance. Initial issues with cell migration have been overcome by incorporating a layer of Matrigel™ into the model. Preliminary results have also indicated that human cells derived from normal oesophagus cultured within the hat chamber can reconstitute a stratified squamous epithelium that closely resembles the original tissue. This epithelium contains three distinct layers, expresses oesophageal specific markers and stains with human specific antibodies.

**Discussion:** This novel *in vivo* system has been shown to be both technically feasible and accessible, making it possible to deliver exogenous factors. It also has the advantage of being genetically manipulable. These features make the model a powerful tool for studying factors implicated in the pathogenesis of BO.

**Disclosure:** All authors have declared no conflicts of interest.

#### 009.02 IDENTIFICATION OF MICRORNAS WHICH REGULATE STEM CELL PROPERTY IN ESOPHAGEAL SQUAMOUS CELL CARCINOMA

Tomoyuki Okumura, Yutaka Shimada, Shinichi Sekine, Makoto Moriyama, Tetsuya Omura, Koki Kamiyama, Ryota Hori, Tomoko Watanabe, Sojo Hojo, Koshi Matsui, Isaku Yoshioka, Shigeaki Sawada, Toru Yoshida, Takuya Nagata, Kazuhiro Tsukada  
*University Of Toyama, Toyama/JAPAN*

**Background:** We have reported that the low affinity neurotrophin receptor (p75NTR) is expressed in undifferentiated cell component of esophageal squamous cell carcinoma (ESCC) and is also expressed in a small number of cells with high colony forming capacity in ESCC cell lines. Our aim of this recent study is to identify molecular targets which regulate stem cell property in ESCC.

**Methods:** We first extracted RNA from formalin fixed paraffin embedded (FFPE) samples of 32 ESCC patients who underwent esophagectomy, to investigate differentially expressed microRNAs in p75NTR positive/negative tumor using microarray. The biological function of target miRNAs was assessed by establishment of stable cell lines by transfection of miRNA expression vector into ESCC cell lines (KYSE790 and KYSE520).

**Results:** Our results demonstrated several miRNAs which are differentially expressed in p75NTR positive tumors, such as Let-7 family members. On the other hand, some miRNAs were expressed in p75NTR negative tumors, such as mir203. Real time PCR experiment revealed that mir-203 was expressed in KYSE 520 and 790. Up regulation of mir-203 expression resulted in morphological change of the cells from small round shape to large flat shape with stratified foci. The expression of p75NTR was reduced and involucrin was up regulated in the cells with strong mir-203 expression. They also showed growth inhibition and reduced colony formation.

**Discussion:** It is suggested that mir-203 regulate stem cell property, such as, cell growth and colonogenicity, and induce squamous differentiation in ESCC.

**Disclosure:** All authors have declared no conflicts of interest.

#### 009.03 SOX9 PROMOTES COLUMNAR DIFFERENTIATION IN THE PATHOGENESIS OF BARRETT'S ESOPHAGUS

Nicholas Clemons<sup>1</sup>, David Wang<sup>2</sup>, Christina Fennell<sup>1</sup>, Anjali Tikoo<sup>1</sup>, Wayne Phillips<sup>1</sup>

<sup>1</sup>Peter MacCallum Cancer Centre, East Melbourne/AUSTRALIA,

<sup>2</sup>Department Of Medicine, Veterans Affairs North Texas Health Care System, University Of Texas Southwestern Medical School, Dallas/UNITED STATES OF AMERICA

**Background:** The molecular mechanism underlying Barrett's metaplasia remains unknown. Our previous work implicated sonic hedgehog (SHH) signaling in the pathogenesis of BE. Here we examined the effect of BMP4 and SOX9, downstream of SHH, and the homeobox gene, CDX2, on the squamous esophageal epithelium. We also assessed expression of Mini-SOX9, a protein coding splice variant of SOX9, in BE and EAC.

**Methods:** The effect of ectopic expression of BMP4, SOX9 and/or CDX2 on the squamous esophageal epithelium was assessed in an *in vivo* tissue reconstitution model. Expression of columnar, gastric and intestinal markers was assessed by immunohistochemistry. Expression of Mini-SOX9 transcript was determined by real time PCR.

**Results:** BMP4 did not alter reconstitution of a squamous epithelium and did not induce expression of columnar/intestinal markers. In contrast, expression of SOX9 abrogated squamous differentiation and induced expression of columnar markers CK8 and CK18, and the intestinal specific transcription factor, A33. Co-expression of CDX2 with SOX9 did not induce any further changes, and CDX2 alone or in combination with BMP4 did not alter development of the squamous epithelium. Expression of Mini-SOX9 was increased in BE and EAC tissue and cell lines, and correlated with SOX9 expression.

**Discussion:** Our results support a role for SHH in the development of BE through induction of SOX9. In contrast, neither BMP4 nor CDX2 are sufficient for columnar differentiation. Up-regulation of Mini-SOX9, shown to antagonize tumor suppressive functions of SOX9 in colon cancer, suggests a further role for this gene in the progression of BE to EAC.

**Disclosure:** All authors have declared no conflicts of interest.

#### 009.04 CHANGES OF FUNCTIONAL SNP IN HUMAN C20ORF54 GENE LEAD TO DIFFERENT SUSCEPTIBILITY TO ESOPHAGEAL SQUAMOUS CELL CARCINOMA

Aifang Ji<sup>1</sup>, Jinsheng Wang<sup>2</sup>, Jianzhou Yang<sup>2</sup>, Liang Ma<sup>1</sup>

<sup>1</sup>Heping Hospital Of Changzhi Medical University, Changzhi, Shanxi/CHINA,

<sup>2</sup>Changzhi Medical University, Changzhi, Shanxi/CHINA

**Background:** The aim of present study was to explore the association of C20orf54 functional SNP with the susceptibility to esophageal squamous cell carcinoma (ESCC) in northern Chinese population.

**Methods:** Two hundred and forty patients with ESCC and one hundred and ninety-eight healthy individuals without overt cancer were chosen as our experimental subjects. Information about smoking and drinking habits and

family history of cancer were collected. The blood samples were taken from all subjects and the tumor tissues were taken freshly from resected specimen. After DNA was extracted and amplified, the C20orf54 SNP was sequenced by ABI 3730XL in BGI China. Their frequencies were then calculated and associated with the collected suspicious risk factors.

**Results:** Drinking status, a family history of ESCC, blood type and BMI have great influence on the risk of developing ESCC. Overall genotype frequencies of the RFT2 SNP 1172 C > A (rs3746803) and 1246A > G (rs3746802) in ESCC patients are significantly different from that in healthy controls ( $\chi^2 = 13.10$ ,  $P = 0.001$  and  $\chi^2 = 7.97$ ,  $P = 0.019$ , respectively). For RFT2 rs3746803, C/T + T/T genotype don't show a relationship with the risk of ESCC (the age and gender adjusted OR = 0.66, 95% CI = 0.41–1.05) by using C/C genotype as reference. For RFT2 rs3746802, A/G + G/G genotype demonstrated a significantly decreased risk to the development of ESCC (the age and sex adjusted OR = 0.53, 95% CI = 0.34–0.84) by using A/A genotype as reference.

**Discussion:** Present study demonstrates that inherited susceptibility is also crucial for esophageal carcinogenesis. The present study suggests that the C20orf54 functional SNP might be associated with a risk of development in ESCC.

**Disclosure:** All authors have declared no conflicts of interest.

#### 009.05 THE BARRETT'S CELL LINE, BAR-T, PRODUCES BOTH SQUAMOUS AND BARRETT'S-LIKE EPITHELIUM IN AN IN VIVO TISSUE RECONSTITUTION MODEL – SUPPORT FOR A COMMON CELL OF ORIGIN THEORY.

Nicholas Clemons<sup>1</sup>, Christina Fennell<sup>1</sup>, David Wang<sup>2</sup>, Stuart Spechler<sup>2</sup>, Rhonda Souza<sup>2</sup>, Wayne Phillips<sup>1</sup>  
<sup>1</sup>Peter MacCallum Cancer Centre, East Melbourne/AUSTRALIA,  
<sup>2</sup>Department Of Medicine, Veterans Affairs North Texas Health Care System, University Of Texas Southwestern Medical School, Dallas/ UNITED STATES OF AMERICA

**Background:** We have developed an in vivo tissue reconstitution model for growth of epithelia from transplanted esophageal cells, which allows the study of molecular pathways underlying development and differentiation of the esophageal epithelium. In the present study we wished to confirm that our model supported the growth of Barrett's epithelium.

**Methods:** Epithelium was reconstituted from the BE cell line, BAR-T, sealed in the lumen of devitalised rat tracheas implanted in SCID mice. Expression of columnar, intestinal and gastric markers was assessed by immunohistochemistry in reconstituted epithelia, and by FACS and immunocytochemistry in in vitro cultures of BAR-T cells.

**Results:** Histopathological analysis of the resultant epithelium revealed glandular columnar epithelium (CK7+ and CK8/18+) with goblet cells (Alcian blue+) and expression of intestinal markers (CDX2, Villin) and gastric mucin (MUC5AC), reminiscent of BE. Surprisingly, we also observed stratified squamous epithelium, and areas of multi-layered epithelium with mixed phenotype. Staining with a human specific antibody confirmed the epithelium was reconstituted by BAR-T cells and not cells from the host mouse. Analysis of 2D cultures of BAR-T cells showed homogeneous co-expression of CK7 and CK14 (squamous marker) in all cells.

**Discussion:** Our findings suggest that BAR-T cells exhibit a level of plasticity that allows differentiation down both squamous and BE-like columnar pathways from the same cell, thus supporting the idea of a common cell of origin for squamous epithelium and BE. What determines whether BAR-T cells differentiate down the squamous or columnar pathway in our model is unclear at this stage.

**Disclosure:** All authors have declared no conflicts of interest.

#### 009.06 UPREGULATION OF LONG NON-CODING RNA HOTAIR PROMOTES CANCER METASTASIS AND PREDICTS POOR PROGNOSIS IN ESOPHAGEAL SQUAMOUS CELL CARCINOMA

Fang-jun Chen, Xiu-feng Cao  
Affiliated Nanjing First Hospital Of Nanjing Medical University And Oncology Center Of Nanjing Medical University, Nanjing/CHINA

**Background:** The functions of individual long noncoding RNAs (lncRNAs) in development and progression of cancer are accumulating in recent two years. Increasing evidence suggests that HOX transcript antisense RNA (HOTAIR) reprogram chromatin organization and promote cancer metastasis. The aim of this study was to ascertain the expression pattern of lncRNA HOTAIR in esophageal squamous cell carcinoma (ESCC) and to assess its biological role in the development and progression of ESCC.

**Methods:** HOTAIR expression in ESCC cancer tissues and matched adjacent noncancerous tissues collected from 78 ESCC samples was measured by real-time reverse transcription-polymerase chain reaction and its correlation with patients' clinicopathological features and prognosis was also ana-

lyzed. Suppression of HOTAIR using siRNA was performed to explore its roles in tumor progression.

**Results:** The expression level of HOTAIR in cancer tissues was higher than that in adjacent noncancerous tissues (96%,  $P < 0.01$ ). High expression level of HOTAIR was strongly associated with cancer metastasis ( $p < 0.01$ ), higher TNM stage of ESCC (2009 classification) ( $P < 0.01$ ) and lower overall survival rates ( $p = 0.005$ ). Multivariate analysis showed that HOTAIR is also an independent prognostic factor when comparing with TNM stage (2009 classification) and lymph node metastasis ( $P = 0.005$  for HOTAIR expression,  $P = 0.009$  for Lymph node metastasis and  $P = 0.005$  for TNM stage). In vitro assays in the ESCC cell line KYSE30 demonstrated that knockdown of HOTAIR reduced cell invasiveness and migration and increased response of cells to the apoptosis.

**Discussion:** Our results highlight HOTAIR is a novel molecule involved in the progression of ESCC and uncover significant associations with prognosis. Elucidating HOTAIR relevant to esophageal carcinogenesis may open avenues for the possible use of lncRNAs in identifying novel drug targets and therapies for ESCC.

**Disclosure:** All authors have declared no conflicts of interest.

#### 009.07 THE ROLE OF SCCA-IGM DETERMINATION IN BARRETT'S ESOPHAGUS AND ESOPHAGEAL CANCER

Gemma Maddalo<sup>1</sup>, Valerio Zorzetto<sup>2</sup>, Massimo Rugge<sup>3</sup>, Matteo Fassan<sup>3</sup>, Giovanni Zaninotto<sup>2</sup>, Alberto Ruol<sup>2</sup>, Massimo Castoro<sup>2</sup>, Alessandra Biasiolo<sup>4</sup>, Fabio Farinati<sup>2</sup>  
<sup>1</sup>Venetian Oncological Institute, Ircs, Padova/ITALY, <sup>2</sup>Department Of Surgical Oncological And Gastroenterological Sciences, University Of Padova, Padova/ITALY, <sup>3</sup>Department Of Medical Diagnostic Sciences, Padova/ITALY, <sup>4</sup>Department Of Clinical And Experimental Medicine, Padova/ITALY

**Background:** Esophageal cancer (EC) is a leading cause of cancer death worldwide. Barrett's esophagus (BE) is the precursor of esophageal adenocarcinoma (EA) and endoscopy is the only approach to secondary prevention; the importance of a biomarker enabling screening of BE and EC in the general population is therefore clear. Squamous cell carcinoma antigen (SCCA), isolated from SCC of the cervix, is elevated in several gastrointestinal cancers. AIM: Since immune-complexed SCCA presents higher sensitivity, we tested SCCA-IgM immunocomplexes in 177 pts: BE (53), EA (51), SCC (31) and controls (CON, 42 blood donors).

**Methods:** SCCA was measured by an ELISA kit (Xeptagen, Marghera-Italy); statistics involved Kolmogorov-Smirnov, non parametric tests and ROC curves.

**Results:** Median SCCA-IgM was significantly higher in all pts than in CON ( $p < 0.0001$ ). EC showed higher SCCA-IgM levels than BE, even though not significantly so (BE SCCA-IgM median value 108,68 AU/mL, EC 129,95 AU/mL;  $p = 0.09$ ). Patients with Barrett "at risk" (Short + dysplasia, long +/- dysplasia), had SCCA-IgM levels significantly higher than short non-dysplastic BE (101,86 AU/ml vs 118,34;  $p = 0.03$ ). Sensitivity and specificity for BE "at risk" were 88% and 55%, respectively, with a R.R. of patients with SCCA-IgM levels above the cut-off of harboring a BE "at risk" of 2.

**Discussion:** Patients with BE present higher SCCA-IgM than CON and those with BE "at risk" even higher levels. When these data will be confirmed in a larger series, SCCA-IgM could be used to select the patients with GERD for endoscopy and to single out "a priori" those with BE that should undergo a stricter surveillance.

**Disclosure:** All authors have declared no conflicts of interest.

#### 009.08 SIGNET RING CELLS CONTAINING CARCINOMA (SRCC) IN ESOPHAGEAL AND GE JUNCTION CARCINOMAS: A STUDY OF BIOLOGICAL BEHAVIOR.

Philippe Naftoux, Toni Lerut, Jeroen Dhaenens, Gert De Hertog, Johnny Moons, Willy Coosemans, Georges Decker, Herbert Decaluwé, Dirk Van Raemdonck, Paul De Leyn  
University Hospital Leuven, Leuven/BELGIUM

**Background:** To study biologic behavior of SRC, clinicopathologic features and prognosis between SRCc and other adenocarcinomas (ADca) of the esophagus and gastroesophageal-junction were compared.

**Methods:** From 1990 till 2009 all adenocarcinoma who underwent primary surgery with R0-resection were retrieved from our prospective database. Sevenhundred-seventy-nine patients were included for analysis. SRCc were classified according to WHO-criteria (SRC > 50% or SRC < 50%).

**Results:** SRCc-fraction was 10.5% (n = 82); with 3.2% SRC > 50% and 7.3% SRC < 50%. Fifty-four % of ADca, 72% of SRC < 50% and 72% SRC > 50% presented with positive lymphnodes. Cancer-specific 5-year survival in ADca was 57% and 30% in all SRC ( $p < 0.001$ ), being 36% in < 50% SRC

( $p = 0.009$ ) and 16% in  $> 50\%$  SRC ( $p < 0.0001$ ). Mean number of positive lymph nodes was not significantly different between ADca and SRC  $< 50\%$  ( $p = 0.46$ ) but significantly different between ADca and SRC  $> 50\%$  ( $p = 0.049$ ). In lymph node-positive patients there was no significant difference in cancer-specific 5-year survival between ADca and SRC  $< 50\%$  ( $p = 0.87$ ) but a significant difference between ADca and SRC  $> 50\%$  ( $p < 0.001$ ). Multivariate analysis withheld SRC  $> 50\%$  and number of positive lymph nodes as independent prognosticators for survival. Furthermore SRC  $> 50\%$  showed a significant higher local recurrence rate (LRR) of 44% compared to 16% in ADca ( $p = 0.002$ ) and 23% in SRC  $< 50\%$  ( $p = 0.053$ ).

**Discussion:** Our results suggest that esophageal carcinomas containing signet-ring cells behave more aggressive as compared to ADca. However in advanced stage (pN+) the subgroup of SRC  $< 50\%$  has a similar survival rate as ADca, while a significantly worse survival was noticed in SRC  $> 50\%$ . Therefore precise preoperative staging with assessment of the proportion of SRC is mandatory to guide adequate therapeutic strategies.

**Disclosure:** All authors have declared no conflicts of interest.

#### 009.09 CORRELATION BETWEEN CLINICAL AND PATHOLOGICAL MANIFESTATIONS WITH GENOMIC DISORDERS IN ESOPHAGEAL SCUAMOUS CELL CARCINOMA

Vladimir Botnarcu<sup>1</sup>, Alina Gheorghe<sup>1</sup>, Marieta Costache<sup>2</sup>, Laura Buburuzan<sup>2</sup>, Catalina Luca<sup>2</sup>, Camelia Vrabie<sup>2</sup>, Irinel Popescu<sup>3</sup>, Simona Dima<sup>3</sup>, Codrut Stanescu<sup>3</sup>, Gabriel Catalin Smarandache<sup>4</sup>, Dan Sabau<sup>5</sup>  
<sup>1</sup>University Ovidius Of Constanta, Constanta ROMANIA, <sup>2</sup>University Of Bucharest, Bucharest ROMANIA, <sup>3</sup>Ic Fundeno, Bucharest ROMANIA, <sup>4</sup>Unifcarol Davila Bucuresti, Bucharest ROMANIA, <sup>5</sup>Universitatea Lucian Blaga Sibiu, Sibiu ROMANIA

**Background:** Results in the surgical management of patients with advanced stage scumous cell carcinoma of the esophagus are poor overall. We studied alterations in BRCA1 and p53 genes with the purpose of constituting a panel of genomic disorders useful in predicting neoplasia for being able to better identifying early stage disease.

**Methods:** Pairs of tumor tissue and blood samples were obtained from 72 patients who underwent surgery for scumous cell oesophageal cancer. Genomic DNA was isolated from normal-, tumor- and blood-samples from patients with ESCC. PCR amplification of two p53 gene fragments was performed using two sets of primers DNA samples were sequenced and then analyzed with BLAST program. Polymerase chain reaction (PCR)-based microsatellite analysis was used to detect LOH occurring in regions mapping for BRCA1 gene.

**Results:** The 72 patients were found with stage III and IV confirmed scumous cell carcinoma. All underwent surgical management procedures. From all the five analyzed microsatellites, presented loss of heterozygosity in the DNA extracted from the tumor tissue of different patients. The p53 gene polymorphisms study showed exons 5, 7 and 8 did not present mutations for the studied patients, but exon 6 featured one modification in different patients.

**Discussion:** 28% of all analyzed patients, presented loss of heterozygosity of at least one microsatellite marker corresponding to BRCA1 gene locus. The mutations of p53 gene can determine the modification of its protein function and the loss of its antioncogene role, which reflects the abnormal proliferation of the cells implicated in this type of cancer.

**Disclosure:** All authors have declared no conflicts of interest.

#### ORAL SESSION O10: SURGICAL TREATMENT OF ESOPHAGEAL CANCER (2) – October 17, 2012 15:30–16:50

##### O10.01 INFLUENCE OF MAJOR POSTOPERATIVE COMPLICATIONS ON HEALTH-RELATED QUALITY OF LIFE AMONG LONG-TERM SURVIVORS OF ESOPHAGEAL CANCER SURGERY

Pernilla Lagergren<sup>1</sup>, Maryam Derogar<sup>2</sup>, Nicola Orsini<sup>3</sup>, Omid Sadr-Azodi<sup>2</sup>  
<sup>1</sup>Karolinska Institutet, Dept Molecular Medicine And Surgery, Stockholm SWEDEN, <sup>2</sup>Karolinska Institutet, Dept. Molecular Medicine And Surgery, Stockholm SWEDEN, <sup>3</sup>Karolinska Institutet, Institute Of Environmental Medicine, Stockholm SWEDEN

**Background:** The influence of postoperative complications on health-related quality of life (HRQL) in long-term survivors of esophageal cancer surgery needs to be clarified.

**Methods:** This study was based on the Swedish Esophageal and Cardia Cancer register with almost complete nationwide coverage and data on esophageal cancer surgery collected prospectively between 2001 and 2005. Patients alive 5 years after surgery were eligible. HRQL was assessed longitudinally until 5 years after surgery using the validated EORTC QLQ-C30

and QLQ-OES18 questionnaires. Linear mixed models were used to assess the mean score difference (MD) with 95% confidence intervals (CI) of each aspect of HRQL in patients with or without major postoperative complications. Adjustment was made for several potential confounders.

**Results:** Of 153 patients surviving 5 years, 141 (92%) answered the 5-year HRQL questionnaires. Of these, 46 (33%) patients sustained a major postoperative complication. Dyspnea (MD 15; 95% CI: 6, 23), fatigue (MD 13; 95% CI: 5, 20), and eating restrictions (MD: 10; 95% CI: 2, 17) remained statistically significantly deteriorated throughout the follow-up in patients with major postoperative complications as compared to those without major complications. While problems with choking declined to levels comparable to patients without major postoperative complications, sleep difficulties and gastroesophageal reflux progressively worsened during follow-up.

**Discussion:** This prospective and population-based cohort study of patients surviving at least 5 years after esophageal cancer surgery indicates that the occurrence of postoperative complications is associated with poor long-term HRQL. These results can be used to guide tailored follow-ups to improve the HRQL of patients with esophageal cancer.

**Disclosure:** All authors have declared no conflicts of interest.

##### O10.02 PROGNOSTIC SIGNIFICANCE OF SIMULTANEOUS PRESENCE OF HISTOLOGIC AND IMMUNOHISTOCHEMICAL METASTASIS TO THE LYMPH NODES IN PATIENTS WITH ESOPHAGEAL CANCER

Tatsuya Kinjo<sup>1</sup>, Hideaki Shimoji<sup>1</sup>, Masayoshi Nagahama<sup>1</sup>, Hiroyuki Karimata<sup>1</sup>, Naoki Yoshimi<sup>2</sup>, Tadashi Nishimaki<sup>1</sup>  
<sup>1</sup>Department Of Digestive And General Surgery, Graduate School Of Medicine, University Of The Ryukyus, Okinawa JAPAN, <sup>2</sup>Department Of Pathology And Oncology, Graduate School Of Medicine And Faculty Of Medicine, University Of The Ryukyus, Okinawa JAPAN

**Background:** Micro-lymph node metastasis (MM) detected by immunohistochemistry has been reported as an indicator of poor prognosis in patients with esophageal cancer undergoing immediate resection. However, the implication of MM remains unclear in patients undergoing preoperative chemotherapy or chemoradiotherapy. The purpose of this study was to evaluate whether the presence of tumor cells histologically or immunohistochemically detected in the lymph nodes is predictive of poor prognosis in patients with esophageal cancer after esophagectomy following the preoperative treatment.

**Methods:** 76 patients undergoing esophagectomy for esophageal cancer were included in this study. Of those, 26 and 14 underwent chemotherapy and chemoradiotherapy before surgery due to the advanced stages, respectively. 2308 lymph nodes retrieved from the 76 patients were histologically and immunohistochemically examined. Influence of MM, pN, and other clinicopathologic factors upon the patients' survival was evaluated using univariate and multivariate analyses.

**Results:** pN and MM were found in 58% and 46% of the patients. Univariate analysis showed cT, pN, pStage, MM, and simultaneous presence of pN and MM ( $p = 0.001$ ) as significant prognostic factors. Multivariate analysis revealed the simultaneous presence of pN and MM to be an only independent prognostic factor ( $p = 0.001$ , HR 3.53). The 5-year overall survival was 53.0% in patients without this factor, whereas it was 26.2% in patients with the factor.

**Discussion:** MM is a significant prognostic factor also in patients with esophageal cancer after esophagectomy following chemotherapy or chemoradiotherapy. Simultaneous presence of pN and MM is an independent strong indicator of poor survival in these patients.

**Disclosure:** All authors have declared no conflicts of interest.

##### O10.03 CAN EXTRACAPSULAR LYMPH NODE INVOLVEMENT BE A TOOL TO FINETUNE pN1 FOR ADENOCARCINOMA IN UICC TNM 7TH EDITION?

Philippe Nafteux, Toni Lerut, Johnny Moons, Willy Coosemans, Georges Decker, Herbert Decaluwe, Hans Van Veer, Dirk Van Raemdonck, Paul De Leyn  
University Hospital Leuven, Leuven BELGIUM

**Background:** The current (7<sup>th</sup>) International Union Against Cancer (UICC) pN staging system is based on the number of positive lymph nodes but does not take into consideration characteristics of the metastatic lymph nodes itself. The aim of the current study was to examine the prognostic value of extracapsular (EC-LNI) and intracapsular (IC-LNI) lymph node involvement in esophageal cancer.

**Methods:** From 1990–2010, 792 adenocarcinoma patients with primary R<sub>0</sub>-resection were retrieved from our prospective database. The number of resected lymph nodes, number of positive lymph nodes and number of EC-LNI / IC-LNI were determined. Extracapsular spread was defined as

infiltration of cancer cells beyond the capsule of the positive lymph node.

**Results:** Four-hundred-and-eight (51.5%) patients had positive lymph nodes. In 227 (55.6%) cases EC-LNI was detected. EC-LNI showed significantly worse cancer-specific 5-year survival compared to IC-LNI, 20.5% versus 40.7% ( $p < 0.0001$ ). In the pN1-category (1 or 2 positive LN's – UICC stages IIB and IIIA) this was 30.2% versus 48.8%;  $p = 0.0035$ ). In higher UICC stages, this effect was no longer noticed.

**Discussion:** EC-LNI is associated with worse survival compared to IC-LNI. In current UICC stages IIB/IIIA, EC-LNI patients show survival rates that are more closely associated with stage IIIB, while IC-LNI patients have a survival more similar to stage IIB. When reclassified as such, homogeneity of the TNM model increases. In future adaptations of the staging system for esophageal cancer, EC-LNI versus IC-LNI should be considered.

**Disclosure:** All authors have declared no conflicts of interest.

#### O10.04 OBESITY AND OUTCOMES FROM TWO-STAGE OESOPHAGECTOMY WITH RADICAL LYMPHADENECTOMY IN PATIENTS WITH OESOPHAGEAL ADENOCARCINOMA

Shajahan Wahed, Helen Jones, Amaran Krishnan, Jon Shenfine, S Michael Griffin

Northern Oesophago-Gastric Cancer Unit, Royal Victoria Infirmary, Newcastle Upon Tyne/UNITED KINGDOM

**Background:** There are concerns that obesity has an impact on the radicality of an oesophagectomy. The aims of this study were to evaluate body mass index (BMI) in patients with oesophageal adenocarcinoma undergoing standardised resection with radical lymphadenectomy.

**Methods:** Patients between January 2000 and December 2010 who underwent 2-stage oesophagectomy with radical lymphadenectomy for adenocarcinoma (all other histological types and operative approaches were excluded) were categorised according to BMI using World Health Organisation criteria: underweight ( $<18.5 \text{ kg/m}^2$ ), normal ( $18.5\text{--}24.99 \text{ kg/m}^2$ ), overweight ( $25\text{--}29.99 \text{ kg/m}^2$ ) and obese ( $\geq 30 \text{ kg/m}^2$ ). Demographics, presence of Barrett's oesophagus or reflux, operative time, R0 resections, complications and lymph node (LN) resection were analysed. Disease-free and overall survivals were calculated using the Kaplan-Meier method.

**Results:** 408 patients were identified. 23 patients without a recorded BMI were excluded leaving 8 underweight, 116 normal, 168 overweight and 93 obese patients. Obese patients (median age 60) were younger than normal or overweight patients (both 66) ( $P < 0.001$ ).

R0 resections (94–97%), LN harvest, LN positivity and LN ratio were similar between BMI groups (all  $P > 0.05$ ). Obese patients had significantly lower pathological disease stages compared to normal ( $P = 0.040$ ) and were more likely to be LN negative ( $P = 0.007$ ). Overall complication rate (61–67%,  $P = 0.585$ ) and in-hospital mortality (overall 2.7%) were similar between groups ( $P = 0.336$ ).

More overweight or obese patients survived 5 years ( $P = 0.004$ ) although disease-free ( $P = 0.162$ ) and stage-matched overall survivals ( $P = 0.158$ ) were not significantly different.

**Discussion:** Increasing BMI did not affect the radicality, complication rate or long-term outcome in this homogeneous group of patients with adenocarcinoma, undergoing 2-stage oesophagectomy with a standardised, radical lymphadenectomy.

**Disclosure:** All authors have declared no conflicts of interest.

#### O10.05 IS LYMPH NODE DISSECTION AT NECK NEEDED AFTER THORACOSCOPIC EXTENDED TWO FIELD LYMPHADENECTOMY FOR SQUAMOUS CELL CARCINOMA OF ESOPHAGUS?

Palanivelu C, Vaithiswaran V, Rajan Ps, Ganesh M.K., Senthilnathan P  
Gem Hospital And Research Center, 641045/INDIA

**Background:** Some series have shown the benefits of a radical approach to esophageal squamous cell carcinoma by a transthoracic approach and three field lymphadenectomy. In minimally invasive radical esophagectomy the thoracoscopic part in prone position can remove nodes along the recurrent laryngeal nerve which are considered to be the most important lymph node group to be removed in the superior mediastinum as well as in the neck. The aim of this study is to assess whether further dissection of nodes at neck is needed.

**Methods:** From Jan 2010 to 2012, 48 patients of squamous cell cancers of lower and mid esophagus underwent minimally invasive esophagectomy with three field lymphadenectomy. In prone position, a complete radical mediastinal lymphadenectomy including a thorough superior mediastinal lymphadenectomy with complete clearance of the recurrent laryngeal nerve nodes well into the neck was performed. A radical abdominal lymphadenectomy and in the neck completion infra homohyoid dissection were per-

formed. The number of nodes removed at the time of neck dissection as well as that during mediastinal phase was analyzed.

**Results:** In all patients, the recurrent Laryngeal node dissection was completed at the thoracoscopic phase only. During neck phase, it was found that recurrent laryngeal nerve nodes groups were already dissected and the mean yield of completion infra- homohyoid dissection was only 6 nodes with none positive. The average total lymph nodes and mediastinal lymph nodes harvested was 38(28–46) and 20(15–28). In 10 of these patients the recurrent laryngeal node group removed during thoracoscopic phase had at least one positive node.

**Discussion:** The recurrent laryngeal group of nodes can be removed under vision well into the neck by thoracoscopy in prone position. For squamous cell cancers of the lower and mid esophagus the need for further neck dissection is questionable. A firm conclusion can be arrived with the results from a larger series of patients especially those with positive recurrent laryngeal nodes.

**Disclosure:** All authors have declared no conflicts of interest.

#### O10.06 PROGRESSION TO INVASIVE CANCER IN PATIENTS WITH HIGH-GRADE DYSPLASIA OR INTRAMUCOSAL CARCINOMA WHO HAVE FAILED ENDOSCOPIC THERAPY AND UNDERGO ESOPHAGECTOMY

Ben M Hunt<sup>1</sup>, Brian E Louie<sup>1</sup>, Christy Dunst<sup>2</sup>, John Lipham<sup>3</sup>, Alexander S Farivar<sup>1</sup>, Ahmed Sharata<sup>2</sup>, Ralph W Aye<sup>1</sup>

<sup>1</sup>Swedish Cancer Institute, Seattle/WA/UNITED STATES OF AMERICA,

<sup>2</sup>The Oregon Clinic, Portland/UNITED STATES OF AMERICA,

<sup>3</sup>University Of Southern California, Los Angeles/CA/UNITED STATES OF AMERICA

**Background:** Endoscopic therapy (ablation +/- endoscopic resection) for high-grade dysplasia (HGD) and/or intramucosal carcinoma (IMC) of the esophagus has demonstrated promising results. However, there is a concern that a curable, local disease may progress to systemic disease with repeated endotherapy. We reviewed our esophagectomies after endotherapy to determine whether patients progress to invasive cancer during endotherapy, and to identify factors that predict failure of endotherapy.

**Methods:** Retrospective review of patients at three tertiary care esophageal centers from 2006–2011.

**Results:** Fourteen patients underwent esophagectomy after a mean of 14 months and 4.3 sessions of endotherapy for progression of disease (50%), failure to clear disease (28%), or recurrence (22%). Initially, all had Barrett's, 71% had  $> 3 \text{ cm}$  segments, 93% had a nodule or ulcer, and 90% had multifocal disease upon presentation. HGD was present at index endoscopy in 57% and IMC in 36%. Final pathology at esophagectomy was T0(14%), T1a(57%), T1b(21%), and T2(7%). An average of 15 lymph nodes were resected with positive lymph nodes in 21%: 1 patient was T2N1 and 2 were T1bN1. Patients with T1b, T2 or N1 disease had more IMC on index endoscopy (75% vs 20%) and more endotherapy sessions (median 6.5 vs 3). There have been no recurrences after a mean of 19 months after esophagectomy.

**Discussion:** Node positive disease was encountered in  $> 20\%$  of patients who required esophagectomy for failed endotherapy of early esophageal cancer. An initial pathology of IMC or failure to clear disease after three treatments should raise concern for loco-regional progression and prompt earlier consideration of esophagectomy.

**Disclosure:** All authors have declared no conflicts of interest.

#### O10.07 COMPARISON OF 6TH AND 7TH UICC-AJCC TNM CLASSIFICATION FOR OESOPHAGEAL CANCER

Koen Talsma<sup>1</sup>, Pieter Van Hagen<sup>2</sup>, Brechtje Grotenhuis<sup>2</sup>, H Tilanus<sup>1</sup>, Ewout Steyerberg<sup>2</sup>, Jan Van Lanschot<sup>1</sup>, Bas Wijnhoven<sup>2</sup>

<sup>1</sup>Erasmus Medical Centre Rotterdam, Rotterdam/NETHERLANDS,

<sup>2</sup>Erasmus Mc - University Medical Center Rotterdam, Rotterdam/NETHERLANDS

**Background:** The new 7th edition of the Union for International Cancer Control-American Joint Committee on Cancer (UICC-AJCC) tumor, node, metastasis (TNM) staging system is the ratification of data-driven recommendations from the Worldwide Esophageal Cancer Collaboration database. Generalizability remains questionable for single institutions. The present study serves as a validation of the 7th edition of the TNM system in a prospective cohort of patients with predominantly adenocarcinomas from a single institution.

**Methods:** Included were patients who underwent transhiatal esophagectomy with curative intent between 1991 and 2008 for invasive carcinoma of the esophagus or gastroesophageal junction. Excluded were patients who had received neoadjuvant chemo(radio)therapy, patients after a noncurative resection and patients who died in the hospital. Tumors were staged according to both the 6th and the 7th editions of the UICC-AJCC staging systems.

Survival was calculated by the Kaplan–Meier method, and multivariate analysis was performed with a Cox regression model. The likelihood ratio chi-square test related to the Cox regression model and the Akaike information criterion were used for measuring goodness of fit.

**Results:** A study population of 358 patients was identified. All patients underwent transhiatal esophagectomy for adenocarcinoma. Overall 5-year survival rate was 38%. Univariate analysis revealed that pT stage, pN stage, and pM stage significantly predicted overall survival. Prediction was best for the 7th edition, stratifying for all substages.

**Discussion:** The application of the 7th UICC-AJCC staging system results in a better prognostic stratification of overall survival compared to the 6th edition. The fact that the 7th edition performs better predominantly in patients with adenocarcinomas who underwent a transhiatal surgical approach, in addition to findings from earlier research in other cohorts, supports its generalizability for different esophageal cancer practices.

**Disclosure:** All authors have declared no conflicts of interest.

#### O10.08 INCREASED RESECTION RATES AND SURVIVAL AMONG PATIENTS WITH ESOPHAGEAL CANCER AGED 75 YEARS AND OLDER: A DUTCH NATIONWIDE POPULATION BASED STUDY

Bas Wijnhoven<sup>1</sup>, Zohra Faiz<sup>1</sup>, Grard Nieuwenhuijzen<sup>2</sup>, Michel Wouters<sup>3</sup>, Tom Rozema<sup>4</sup>, Jan Willem Coebergh<sup>1</sup>, Valery Lemmens<sup>1</sup>

<sup>1</sup>Erasmus Mc - University Medical Center Rotterdam, Rotterdam/  
NETHERLANDS, <sup>2</sup>Catharina Hospital, Eindhoven/NETHERLANDS,  
<sup>3</sup>Antonie Van Leeuwenhoekziekenhuis, Amsterdam/NETHERLANDS,  
<sup>4</sup>Verbeeten Instituut, Tilburg/NETHERLANDS

**Background:** Approximately 30% of esophageal cancer patients are 75 years or older at the time of diagnosis. The aim of the study was to evaluate trends in management and survival of patients aged 75 years or older with esophageal cancer.

**Methods:** All patients  $\geq 75$  diagnosed with esophageal cancer between 1989 and 2008 were identified from the Dutch Cancer Registry. Trends in management and survival were analyzed by time period (1989–2001 vs. 2002–2008), TNM stage, and age (75–79 yrs, 80–84 yrs, and 85+ yrs). Kaplan–Meier analysis and log-rank testing to estimate survival, and Cox regression model to calculate hazard ratios for death.

**Results:** Some 7253 patients were included. The surgical resection rate increased over the 1989–2008 period from 8.9% to 12.6% ( $p = 0.028$ ), especially among patients aged 75–79 years (44.6% vs. 55.4%  $p < 0.001$ ) and patients with TNM stage I disease (12.7% vs. 22.0%  $p < 0.001$ ). The use of definitive chemoradiotherapy (CRT) also increased (0.19% vs. 2.20%  $p < 0.001$ ). Whereas the use of chemotherapy as a single-modality treatment more than doubled (0.64% vs. 1.54%  $p = 0.004$ ), that of radiotherapy alone decreased (38.1% vs. 31.6%  $p < 0.001$ ). Overall 5-year survival rates remained low at 6% and 5% respectively ( $p < 0.001$ ). Five-year survival rate after surgery increased from 16% to 30% ( $p < 0.001$ ).

**Discussion:** In patients of 75 years or older, surgical treatment and use of definitive chemoradiation have increased between 1989 and 2008. Overall 5-year survival for all cancer patients remained stable while survival of patients who underwent esophagectomy improved significantly in the Netherlands since 1989.

**Disclosure:** All authors have declared no conflicts of interest.

### POSTER SESSION P01: BARRETT'S ESOPHAGUS – October 16, 2012 12:30–13:30

#### P01.01 ABDOMINAL OBESITY AND RISK OF BARRETT'S ESOPHAGUS: A PILOT STUDY IN JAPANESE REFERRAL CENTERS

Akio Tamura, Jiro Watari, Ken Hara, Koichi Ikeo, Haruki Asano, Takashi Kondo, Fumihiko Toyoshima, Jun Sakurai, Junji Tanaka, Toshihiko Tomita, Tadayuki Oshima, Hirokazu Fukui, Kazutoshi Hori, Takayuki Matsumoto, Hiroto Miwa  
Hyogo College Of Medicine, NishinomiyalJAPAN

**Background:** Although obesity may be an independent risk factor for gastroesophageal reflux disease in the West, the association between obesity and Barrett's esophagus (BE) remains unclear. We prospectively investigated the prevalence of BE and associated risk factors.

**Methods:** From November 2011, we enrolled 386 consecutive individuals who received upper gastrointestinal endoscopy. The prevalence of visual BE (VBE) based on the Prague C & M criteria and histologically specialized intestinal metaplasia (SIM) was evaluated. VBE was diagnosed when the mucosa was longer more than 5 mm. Obesity was evaluated by several indices: body mass index (BMI,  $\geq 25$  kg/m<sup>2</sup>); waist circumference (WC) (males,  $\geq 85$  cm; females,  $\geq 90$  cm); waist-to-hip ratio (males,  $\geq 0.9$ ; females,  $\geq 0.85$ ).

**Results:** Prevalence of BE was 30.1% for  $\leq 1$  cm, 4.9% for  $> 1$  to  $< 3$  cm, and 0.3% for  $\geq 3$  cm, and that of SIM was 18.9%, 5.6%, and 100% for each BE length. Aging, male gender, BMI, and WC were significantly associated with the prevalence of BE, but reflux symptoms, alcohol drinker, smoker, open type of gastric atrophy, and reflux esophagitis were not. In multivariate logistic regression analysis, aging ( $\geq 65$  yr) was an independent risk factor for BE (Odds ratio = 2.07, 95% CI 1.15–3.72,  $p < 0.05$ ).

**Discussion:** This pilot study found that aging, but not obesity, may have an independent association with the risk of BE, mostly ultra-short segment BE. A further study with a larger sample size will be needed to clarify the association between obesity and BE in a Japanese population.

**Disclosure:** All authors have declared no conflicts of interest.

#### P01.02 SIGNIFICANCE OF ANTIREFLUX SURGERY AFTER HALO RF TREATMENT OF BARRETT'S ESOPHAGUS

Aleksandar P. Simic<sup>1</sup>, Ognjan Skrobic<sup>2</sup>, Mirko Gligorijevic<sup>2</sup>, Nebojsa Radovanovic<sup>2</sup>, Milutin Kotarac<sup>2</sup>, Nenad Ivanovic<sup>2</sup>, Predrag Pesko<sup>2</sup>

<sup>1</sup>Department Of Esophagogastric Surgery, First Surgical University Hospital, Clinical Center Of Serbia, School Of Medicine University Of Belgrade, Belgrade/SERBIA, <sup>2</sup>First Surgical University Hospital, Belgrade/SERBIA

**Background:** Catheter based radiofrequent ablation (RFA) is established as safe and effective procedure in treatment of Barrett esophagus (BE). Nissen fundoplication (NF) is proved successful in long term control of reflux symptoms. Aim of this study is to evaluate the outcome of RFA treatment of BE, and the significance of additional NF.

**Methods:** Prospective one year follow-up of 40 BE patients with intestinal metaplasia (IM) or low grade dysplasia (LGD) treated with HALO RFA. Complete diagnostics were performed prior to and after RFA, or NF. BE was classified according to C&M Prague criteria. NF was performed in 19 patients, 4 to 6 months after RFA treatment, while 21 were treated with 40 mg of PPI's daily for one year. Symptom scores, endoscopic and functional diagnostics data and distal esophageal biopsy specimens were evaluated six months and one year after single RFA or combined with surgery.

**Results:** There were 31 patients with IM and 9 with LGD. Mean values of BE length were C 2.1, M 3.9. Initial HALO 360 was performed in 14, HALO 90 in 26 patients. Mean number of RFA procedure per patient was 1.9. Complete BE eradication was achieved in 33 patients. Mean values of symptom scores were higher in group treated with RFA alone, than in one with additional NF. Histology revealed higher incidence ( $p = 0.003$ ) of inflammatory changes in patients with RFA alone.

**Discussion:** RFA is safe and effective procedure in BE treatment. One year follow-up indicates that NF protects re-epithelialized esophagus from further reflux injuries.

**Disclosure:** All authors have declared no conflicts of interest.

#### P01.03 SHORT-TERM RESULTS AFTER RADIOFREQUENCY ABLATION (RFA) FOR BARRETT'S ESOPHAGUS

Martin Riegler<sup>1</sup>, Sebastian F Schoppmann<sup>1</sup>, Johannes Zacherl<sup>1</sup>, Fritz Wrba<sup>2</sup>, Ildiko Mesteri<sup>2</sup>, Lukas Beller<sup>1</sup>, Stephanie Fischer See<sup>1</sup>

<sup>1</sup>Medical University Of Vienna, Department Of Surgery, Vienna/AUSTRIA, <sup>2</sup>Muv, Wien/AUSTRIA

**Background:** Barrett's esophagus results from gastroesophageal reflux and harbors an increased cancer risk (0.5% per year). Radiofrequency ablation (RFA) represents a novel endoscopic method for the elimination of Barrett's esophagus.

**Methods:** From 4.9.2008 to 28.2.2012, 118 patients [females  $n = 48$ , age 54.15 (18–82) years]; underwent 1 ( $n = 97$ ) or 2 ( $n = 21$ ) RFAs for non-dysplastic Barrett's esophagus (NDBE;  $n = 116$ ) and low-grade dysplasia (LGD;  $n = 2$ ), with fundoplication before ( $n = 22$ ) or after RFA ( $n = 30$ ). RFA was conducted as overnight procedure. In 89 patients follow up endoscopy was conducted 2–12 (mean 6) months after last treatment, i.e. 1st RFA ( $n = 59$ ), 2nd RFA ( $n = 18$ ) or fundoplication ( $n = 28$ ).

**Results:** We conducted 140 RFAs (HALO® 360,  $n = 130$ ; HALO® 90,  $n = 10$ ). Overall, elimination of NDBE was achieved in 66.29% (59/89) and 66.67% (12/18) after 1 and 2 RFAs, respectively. LGD and NDBE was eliminated in 1 case, the second LGD patient awaits follow up. When fundoplication was conducted after RFA, the NDBE-elimination rate was 82.14% (23/28) after 1–2 RFAs. When RFA was conducted after fundoplication the NDBE-elimination rate was 52.9% (9/17) and 60% (3/5) after 1st and 2nd RFA, respectively. After RFA we observed 23 moderate complications (nausea, vomiting), 3 patients required readmission due to pulmonary embolism ( $n = 1$ ), pleuritis ( $n = 1$ ) and esophageal perforation, which was successfully treated by laparoscopic Nissen fundoplication.

**Discussion:** RFA represents an effective treatment tool for the elimination of Barrett's esophagus

**Disclosure:** All authors have declared no conflicts of interest.

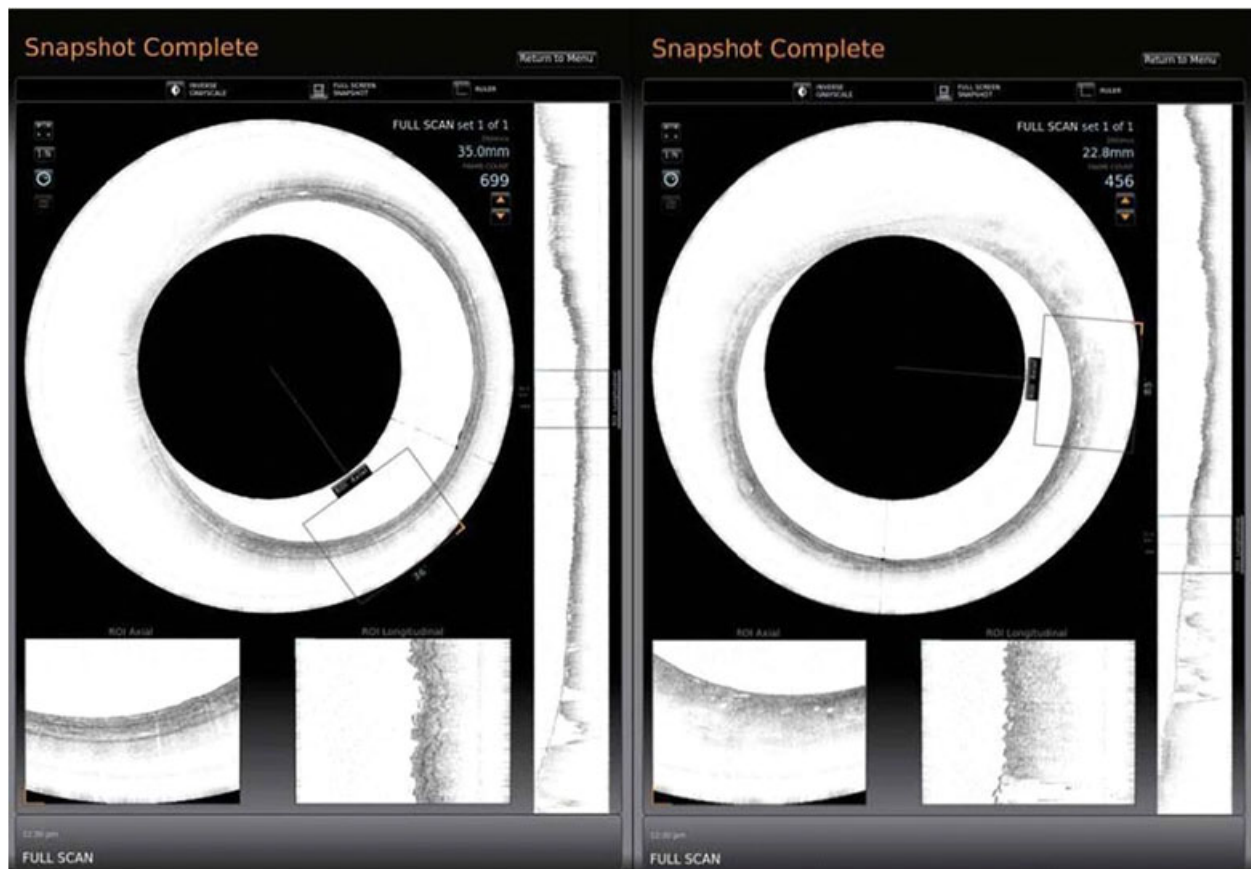**P01.04 REAL-TIME, HIGH-RESOLUTION OPTICAL IMAGING OF BARRETT'S ESOPHAGUS USING VOLUMETRIC LASER ENDOMICROSCOPY: AN OBSERVATIONAL STUDY**

Michael B Wallace<sup>1</sup>, Herbert C Wolfsen<sup>2</sup>, Gary J Tearney<sup>3</sup>  
<sup>1</sup>Mayo Clinic, Jacksonville/UNITED STATES OF AMERICA, <sup>2</sup>Mayo Clinic, Jacksonville/FL/UNITED STATES OF AMERICA, <sup>3</sup>The Wellman Center For Photomedicine, MA/MA/UNITED STATES OF AMERICA

**Background:** Random esophageal biopsy sampling in patients with Barrett's esophagus (BE) can result in missed regions of suspicion due to variability in the distribution of dysplasia and cancer and inability to visualize deep tissue using standard endoscopy. More accurate, real-time methods of identifying areas of dysplasia in endoscopic screening and surveillance of BE are needed.

**Methods:** Volumetric laser endomicroscopy (VLE), recently FDA cleared, generates high-resolution images of the esophageal microstructure, allowing identification of suspicious areas in real time to guide treatment decisions for endoscopic resection and ablation. An ongoing open-label observational study is evaluating VLE performance to visualize subsurface tissue in adults with established/suspected BE undergoing esophagogastroduodenoscopy (EGD) with biopsy. All patients undergo EGD with monitoring per institutional guidelines, followed by VLE imaging and routine endoscopic visualization and biopsy. The primary endpoint is the number of patients completing VLE imaging studies during EGD. Secondary endpoints include the ability to identify suspect areas consistent with BE or carcinoma via esophageal imaging, correlation of suspect areas identified during imaging to diagnosis based on biopsy, quality/speed of image processing, ease of use, and adverse events (AEs).

**Results:** Nine subjects have successfully undergone VLE imaging, with no AEs. Images were obtained and viewed in the axial view of the graphical user interface, including a patient with normal squamous esophageal mucosa (figure, left) and one with BE (right).



**Discussion:** Study enrollment continues, with 100 patients targeted. VLE imaging can provide BE patients streamlined care with significantly shortened time to disease detection, diagnosis, and treatment.

**Disclosure:** M.B. Wallace: Investigator, NinePoint Pharmaceuticals  
H.C. Wolfsen: Investigator, NinePoint Pharmaceuticals  
G.J. Tearney: Investigator, NinePoint Pharmaceuticals

**P01.05 LAPAROSCOPIC NISSEN-ROSSETTI FUNDOPLICATION IN PATIENTS WITH AND WITHOUT BARRETT'S ESOPHAGUS.**

Valentina Mingarelli, Salvatore Marano, Stefano Mattacchione, Barbara Luongo, Filippo Tosato  
Referral Center For The Surgical Treatment Of Gastroesophageal Reflux Diseases, Department Of Surgery "F. Durante", Policlinico "Umberto I", "Sapienza" University Of Rome, Italy, Rome/ITALY

**Background:** Minimal invasive technique is the gold standard in the surgical treatment of GERD. Nowadays the debate focuses on the differences in postoperative results between patients with uncomplicated GERD and patients with Barrett's esophagus. Aim of this study is to compare objective

and subjective outcomes of laparoscopic Nissen-Rossetti fundoplication after 2 years follow-up in patients with and without Barrett's esophagus.

**Methods:** 76 patients with uncomplicated GERD (group A) and 27 patients with Barrett's esophagus (group B) underwent laparoscopic Nissen-Rossetti Fundoplication. Patients were submitted to close follow-up.

**Results:** DeMesteer&Jhonsonn score average decreased from 35.48 (SD ± 40.24) in group A and 38.69 (SD ± 51.44) in group B, to 9.83 (SD ± 6.40) at 6 months in group A and to 11.99 (SD ± 18.08) in group B. At 12 months it was 11.44 (SD ± 10.28) in group A and 12.69 (SD ± 12.91) in group B, at 24 months it was 10.25 (SD ± 5.61) in group A and 11.38 (SD ± 6.43) in group B. No statistically significant differences were found when comparing the two groups. GERD-HRQL improved in both groups and differences were found in the preoperative period, at 6 and 12 months. SF-36 measurement also showed significant improvement in patients with and without Barrett's esophagus.

**Discussion:** Laparoscopic Nissen-Rossetti fundoplication is an effective treatment for GERD regardless of the presence of Barrett's esophagus. Improvement in quality of life is more evident in patients without Barrett's esophagus, and this is due to a different perception of the severity of symptoms.

**Disclosure:** All authors have declared no conflicts of interest.

**P01.06 BARRETT'S ESOPHAGUS AFTER LAPAROSCOPIC NISSEN-ROSSETTI FUNDOPPLICATION: FUNCTIONAL AND QUALITY OF LIFE EVALUATION AFTER 2 YEARS FOLLOW-UP.**

Valentina Mingarelli, Salvatore Marano, Stefano Mattacchione, Barbara Luongo, Filippo Tosato

Referral Center For The Surgical Treatment Of Gastroesophageal Reflux Diseases, Department Of Surgery "F. Durante", Policlinico "Umberto I", "Sapienza" University Of Rome, Italy, Rome/ITALY

**Background:** Barrett's esophagus is a premalignant condition consequence of GERD. Aim of this study is to determine histological, functional outcome and quality of life after fundoplication at 2-years follow-up.

**Methods:** 27 patients with Columnar-lined esophagus (CLE) metaplasia underwent laparoscopic Nissen-Rossetti Fundoplication

**Results:** After 2-years follow-up CLE was still present in 24 patients (88.9%); no patient developed dysplasia or esophageal adenocarcinoma. 2 patients with gastric metaplasia and 1 patient with intestinal metaplasia had regression 12 and 24 months after surgery (11.1%). DeMestee&Jhonsonn score decreased from 38.69 (SD ± 51.44) to 11.99 (SD ± 18.08) at 6 months, 12.69 (SD ± 12.91) at 12 months, to 11.38 (SD ± 6.43) at 24 months. Statistical analysis showed significant differences between preoperative values and follow-up checks, but none in the comparison of postoperative values. Preoperative GERD-HRQL was 19.90 (SD ± 18.54), 9.80 (SD ± 8.77) at 6 months, 9.57 (SD ± 9.14) at 12 months, 11.53 (SD ± 6.48) at 24 months. Differences were significant between preoperative values and 6, 12, 24 months and in the comparison between 6 vs 12 and 24 months and 12 vs 24 months. SF-36 improved and statistic differences were found between preoperative data and those at 6,12 and 24 month and in the comparison between postoperative values

**Discussion:** Successful laparoscopic fundoplication can control acid, biliary-pancreatic reflux, improve quality of life, stop progression and promote regression of esophageal mucosa damage, especially when it is performed in the early stages. Subjective and objective tests are important to identify asymptomatic recurrence of reflux after surgery.

**Disclosure:** All authors have declared no conflicts of interest.

**P01.07 THE EFFECTS OF LAPAROSCOPIC NISSEN FUNDOPPLICATION ON BARRETT'S ESOPHAGUS: LONG-TERM RESULTS**

George Lazar<sup>1</sup>, Attila Paszt<sup>1</sup>, Szabolcs Abraham<sup>1</sup>, Jozsef Pieler<sup>1</sup>, Janos Tajti<sup>1</sup>, Laszlo Tiszlavicz<sup>2</sup>, István Nemeth<sup>2</sup>, Ferenc Izbeki<sup>3</sup>, Andras Rosztoczy<sup>3</sup>, Tibor Wittmann<sup>3</sup>, Ferenc Rarosi<sup>4</sup>, Zsolt Simonka<sup>1</sup>

<sup>1</sup>University Of Szeged Department Of Surgery, Szeged/HUNGARY,

<sup>2</sup>University Of Szeged Department Of Pathology, Szeged/HUNGARY,

<sup>3</sup>University Of Szeged ISI Department Of Internal Medicine, Szeged/HUNGARY, <sup>4</sup>University Of Szeged Department Of Medical Physics And Informatics, Szeged/HUNGARY

**Background:** The aim of our study was a retrospective investigation of the efficacy of laparoscopic Nissen fundoplication in patients with Barrett's esophagus.

**Methods:** A total of 78 patients with Barrett's esophagus underwent surgery. Patients were divided into three groups on the basis of the preoperative endoscopic biopsies: a non-intestinal group (n = 63) with fundic or cardiac metaplasia, an intestinal group (n = 18) with intestinal metaplasia, and a dysplastic group (n = 7) with low-grade dysplasia. Clinical follow-up was available in the case of 64 patients at a mean of 42 ± 16.9 months after surgery.

**Results:** Check-up examination revealed total regression of Barrett's metaplasia in 10 patients. Partial regression was seen in 9 cases, no further progression in 34 patients, and progression into cardiac or intestinal metaplasia in 11 patients. No cases of dysplastic or malignant transformation were registered. Where we observed the regression of BE, among the postoperative functional examinations results of manometry (pressure of lower esophageal sphincter) and pH-metry were significantly better compared with those groups where no changes occurred in BE, or progression of BE was found.

**Discussion:** Our results highlight the importance of the cases of fundic and cardiac metaplasia, which can also transform into intestinal metaplasia. Antireflux surgery can appropriately control the reflux disease in a majority of the patients who had unsuccessful medical treatment, and it may inhibit the progression and induce the regression of Barrett's metaplasia in a significant proportion of these patients.

**Disclosure:** All authors have declared no conflicts of interest.

**P01.08 LATE ENDOSCOPIC SURVEILLANCE IN BARRETT'S ESOPHAGUS SUBMITTED TO FUNDOPPLICATION. IS IT WORTHWHILE?**

Sergio Szachnowicz, Francisco Seguro, Rubens Sallum, Ary Nasi, Eduardo Hornoux Guimarães Moura, Julio Rocha, Ivan Ceconello  
Department Of Gastroenterology – Esophageal Surgical Division. University Of São Paulo School Of Medicine, São Paulo - Brazil, São Paulo/BRAZIL

**Background:** Barrett's esophagus is associated to esophageal adenocarcinoma. Endoscopic surveillance of patients treated surgically or clinically allows early detection of cancer. Some authors concluded that surveillance is not cost-effective and does not reduce mortality from cancer. Aim: We analyze efficacy of endoscopic surveillance in patients with Barrett's esophagus submitted to fundoplication.

**Methods:** From January 1980 to march 2011, 221 patients with Barrett's esophagus were submitted to fundoplication to control reflux. Of those, 112 were followed (mean 71months) . All patients in our service had routine endoscopic examination each 2 years with multiple biopsies.

**Results:** Ten patients (8.9%) showed Barrett's endoscopic regression . Three patients (2.6%) were diagnosed with esophageal adenocarcinoma in this series. Two underwent prolonged pH monitoring that showed no acid reflux. They were asymptomatic and had diagnostic of early adenocarcinoma during routine endoscopy 2 (2) and 6 years after fundoplication. All underwent transhiatal esophagectomy and are alive (12 to 56 months).

**Discussion:** Besides the related low cost-effectiveness of endoscopy surveillance, cancer was detected during follow up of Barrett's patients submitted to a successful antireflux procedure allowing early diagnosis and cure.

**Disclosure:** All authors have declared no conflicts of interest.

**P01.09 LONG-TERM FOLLOW-UP OF MALIGNANCY BIOMARKERS IN PATIENTS WITH BARRETT'S ESOPHAGUS UNDERGOING MEDICAL OR SURGICAL TREATMENT**

Pascual Parrilla<sup>1</sup>, Luisa Martinez De Haro<sup>2</sup>, Angeles Ortiz<sup>2</sup>, Vicente Munitiz<sup>2</sup>, David Ruiz De Angulo<sup>2</sup>

<sup>1</sup>University Of Murcia, Murcia/SPAIN, <sup>2</sup>University Hospital V Arrixaca, Murcia/SPAIN

**Background:** The treatment of choice to prevent the malignant progression of BE remains controversial. Translational studies using biomarkers associated with the metaplasia-tumor pathway could be useful to provide some information in this regard. This study aims to compare some validated biomarkers of malignancy (Ki-67, p53, and apoptosis) between 2 groups of patients with Barrett's esophagus (BE) undergoing randomly medical or surgical treatment.

**Methods:** The study group consisted of 45 patients: 20 under medical treatment with 40 mg/day of proton pump inhibitors (PPIs) and 25 after Nissen fundoplication (NFP). After a median follow-up of 8 years (range, 5–10 years), the values of Ki-67, p53, and apoptosis were analyzed in all patients before treatment (n = 45) and then 1 year (n = 45), 3 years (n = 45), 5 years (n = 45), and 10 years (n = 25) afterwards in both groups of treatment. These values were also analyzed in 2 subgroups of patients with successful medical and surgical treatment.

**Results:** Both Ki-67 and p53 remained stable after NFP, whereas they increased progressively in patients under PPIs with statistically significant differences between the 2 groups. Conversely, the apoptotic index increased progressively after NFP and decreased in the patients under PPIs with significant differences at 3, 5, and 10 years of follow-up. On comparing the subgroups of successful treatment the same differences were found.

**Discussion:** This study supports that antireflux surgery could be the treatment of choice in many patients, especially those at low surgical risk and/or at high risk of malignancy.

**Disclosure:** All authors have declared no conflicts of interest.

**P01.10 EROSIIVE ESOPHAGITIS IS A MAJOR PREDICTOR FOR BARRETT'S ESOPHAGUS RECURRENCE AFTER SUCCESSFUL RADIOFREQUENCY ABLATION**

Junichi Akiyama<sup>1</sup>, Carlene Chun<sup>1</sup>, Jennifer Vassalle<sup>2</sup>, Samuel Marcus<sup>1</sup>, George Triadafilopoulos<sup>1</sup>

<sup>1</sup>Stanford University, Stanford/CA/UNITED STATES OF AMERICA, <sup>2</sup>El Camino Gi Medical Associates, Mountain View/CA/UNITED STATES OF AMERICA

**Background:** Radiofrequency ablation (RFA) is an emerging endoscopic modality to eradicate Barrett's esophagus (BE) and associated dysplasia. Despite the promising results with high initial success rates, there is limited data addressing the long-term outcomes of RFA. We aimed to determine the rates and predictors of intestinal metaplasia (IM) recurrence after successful eradication with RFA.



**Methods:** BE patients previously treated with RFA were retrospectively studied. Only those with complete resolution of IM (CR-IM) after RFA and at least one surveillance endoscopy were included in this analysis. Clinical, demographic, endoscopic, and histologic data were collected.

**Results:** Among 81 patients who had received RFA therapy, 34 (male 77%; age 63; BE length C 3.8, M 4.3; dysplastic BE 41%; large hiatal hernia (HH) 29%) met the study criteria. The median follow-up period after CR-IM was 20.2 months (IQR 13.6–36.5) with a median number of 2 surveillance endoscopies (IQR 1–2). Kaplan-Meier analyses showed a 9% and 21% cumulative recurrence rate of IM at 1 and 2 years, respectively. Despite PPI therapy and/or fundoplication, 8 of 34 patients developed erosive esophagitis (EE) (LA-A 2, C 3, D 3). Univariate analyses revealed EE ( $p = 0.002$ ), large HH ( $p = 0.002$ ), dysplastic BE ( $p = 0.04$ ) were associated with IM recurrence, whereas age, gender, BE length, NSAIDs, PPI dosage, fundoplication were not. Multivariate Cox proportional hazard model showed that EE was an independent predictor for IM recurrence (HR 12.8,  $p = 0.026$ ).

**Discussion:** Erosive esophagitis is a major predictor for Barrett's esophagus recurrence. Continued monitoring and optimization of anti-reflux therapy should be recommended to prevent recurrence after RFA.

**Disclosure:** G. Triadafilopoulos: Consulting Honoraria, BARRX Medical, Inc. All other authors have declared no conflicts of interest.

**P01.11 2 MM MARGINS AFTER A SINGLE ENDOSCOPIC MUCOSAL RESECTION (EMR) FOR SHORT SEGMENT BARRETT'S NEOPLASIA: HOW FAR IS ENOUGH?**

Emmanuel Gorospe, Jason Lewis, Tsung-teh Wu, Lori Lutzke, Gang Sun, Prasad Iyer, Kenneth Wang  
*Mayo Clinic, Rochester/UNITED STATES OF AMERICA*

**Background:** We assessed the significance of a 2 mm dysplasia-free margin in achieving complete remission of Barrett's esophagus and early neoplasia (CR-BE) after a single EMR for a focal, short segment BE (SS-BE).

**Methods:** We reviewed patients who had EMR for unifocal SS-BE with negative margins. Surveillance was done every 3 months. CR-BE was defined as absence of dysplasia after 2 negative surveillance biopsies. Histology and resection margins were evaluated by 2 pathologists. Univariate analysis was performed comparing patients with CR-BE and those without.

**Results:** 19 patients met our inclusion criteria; 11 had high grade dysplasia and 8 with intramucosal adenocarcinoma. Pre-EMR BE length was  $1.7 \pm 1.3$  cm. CR-BE was achieved in 10 patients, equally divided between those with and without  $> 2$  mm margins. Patients with CR-BE had no recurrence of dysplasia after 2 surveillance endoscopies at  $18.5 \pm 4.5$  months follow-up. There was no significant difference in patient characteristics between those with and without CR-BE (Table 1).

**Discussion:** A 2-mm margin is not associated with CR-BE (OR: 0.80; 95% CI 0.13–4.94) after a single EMR for a focal SS-BE. Table 1

VARIABLES	CR-BE Patients	Non CR-BE Patients	p value
N	10	9	n/a
Age	$70.56 \pm 9.75$	$65.10 \pm 9.99$	0.26
Gender (M : F)	9:1	8:1	0.93
BMI	$32.00 \pm 3.88$	$30.66 \pm 5.14$	0.54
Smokers (%)	40	33	0.51
PPI (%)	100	100	n/a
BE length (cm)	$1.50 \pm 1.39$	$2.05 \pm 1.28$	0.12
EMR size (cm)	$1.02 \pm 0.19$	$1.11 \pm 0.21$	0.31
Free margins (mm)	$2.28 \pm 1.58$	$1.93 \pm 0.78$	0.84

**Disclosure:** P. Iyer: Dr. Iyer receives research support from TakedaK. Wang: Dr. Wang receives research support from the following companies: Abbott Diagnostics, Barrx, Fujinon, NinePoint Medical, Oncoscope and Pinnacle Pharma. All other authors have declared no conflicts of interest.

**P01.12 DISTRIBUTION AND EXTENT OF INTESTINAL METAPLASIA IN VISIBLE COLUMNAR LINED ESOPHAGUS**

Juan Guo<sup>1</sup>, Steven R Demeester<sup>2</sup>, Jeffrey A Hagen<sup>2</sup>, Tom R Demeester<sup>2</sup>, Parakrama Chandrasoma<sup>1</sup>

<sup>1</sup>Keck School Of Medicine, University Of Southern California, Los Angeles CA/UNITED STATES OF AMERICA, <sup>2</sup>Department Of Surgery, University Of Southern California, Los Angeles/UNITED STATES OF AMERICA

**Background:** Endoscopically visible columnar lined esophagus (CLE) is composed of three histologic columnar epithelial types. Barrett esophagus (BE) is defined by the presence of intestinal metaplasia (IM). We used mapping biopsies to define variations in the extent of IM in CLE.

**Methods:** 132 patients with a diagnosis of BE encountered between 2004–2008 had mapping four-quadrant biopsies at 1–2 cm intervals of visible CLE

of lengths of 2–18 cm. IM was defined by the presence of goblet cells in any biopsy at a given level.

**Results:** All patients had IM in the most proximal level of the CLE. 92/132 (69.7%) had IM in every level of the visible CLE. Of the 40 patients without IM at all levels, 28 had IM in 50% or more levels; the other 12 patients had a majority of levels composed of cardiac and oxyntocardiac epithelia. 128 patients had IM in a continuous zone from the squamocolumnar junction extending distally; the other 4 patients had discontinuous IM.

**Discussion:** If IM is the target epithelium for carcinogenesis, mapping the extent of IM in CLE has a theoretical predictive value in assessing cancer risk independent of either the presence of IM or the total endoscopic length of CLE. Comparison of historical mapping studies of epithelial types within CLE shows that the prevalence and extent of IM within CLE has increased progressively from 1950 to 2008. We postulate that this increased extent of IM is the most likely explanation for the increased risk of esophageal adenocarcinoma during this period.

**Disclosure:** All authors have declared no conflicts of interest.

**POSTER SESSION P02: GASTRO-ESOPHAGEAL REFLUX DISEASE – October 16, 2012 12:30–13:30**

**P02.01 LONG TERM ACID SUPPRESSION THERAPY: IT'S INFLUENCE ON GASTRIC MUCOSA**

Arunkumar Krishnan, Rajesh Prabu P, Jayanthi V  
*Stanley Medical College, Chennai/INDIA*

**Background:** Dyspepsia describes a symptom complex that arises in the upper gastrointestinal tract. It affects more than one fourth of the general population in industrialized countries. The commonly used acid suppression medications are proton pump inhibitors (PPI) and histamine-2 receptor antagonists (H2RA), the former being potent acid suppressants. The aim of the present study was to determine the histological changes in the antral mucosa in patients on long term acid suppression therapy and also to study the prevalence, pattern and effects of H.pylori among these patients.

**Methods:** 126 patients attending the clinic with symptoms of ulcer type (defined as an epigastric burning sensation or food related pain) or reflux type dyspepsia, for at least a year with a normal upper endoscopy were included for the study. Sixty six patients were on omeprazole at a dose of 40 mg a day (Gp I) and the rest were on ranitidine 150 mg twice a day (Gp II). Based on the duration of therapy, the patients in each group were further sub-classified into those taking the antisecretory drug for less than 2 yrs, 2 to 5 yrs and more than 5 yrs. Patients in both groups had an upper endoscopy and biopsy specimens two each were obtained from the fundus, body and antrum of the stomach for rapid urease test, histopathological staging and for detection of H pylori. Patients with other forms of dyspepsia like dysmotility type or those with combination types smokers, alcohol consumers and NSAID abusers and individuals who were on antibiotics a fortnight were excluded.

**Results:** The demographic features including age, gender distribution, literacy levels, occupation and per capita income were comparable between the two groups ( $P > 0.05$ ). There was no statistical significance in duration of treatment with antisecretory drugs in the three subgroups ( $p > 0.05$ ). Gastric mucosa was normal in 18 (27.3%) and 30 (60%) patients in Gp I and Gp II respectively, which was statistically significant ( $P = 0.01$ ). 10 patients (15.2%) in Group I and none in Group II had intestinal metaplasia ( $p = 0.05$ ). The histological findings when correlated with the duration of treatment did not reveal any significant difference between the two groups except for intestinal metaplasia which showed an increasing trend with prolonged use of proton pump inhibitors. H. pylori colonized predominantly in fundus in Group I whereas it remained localized to the antrum in Group II. When the histological changes were compared between those with and without H pylori infection among both groups, it was evident that H. pylori played a significant role in the histological changes, particularly chronic gastritis and intestinal metaplasia, especially in Gp I.

**Discussion:** The gastric mucosa in patients on H2RA was either normal or showed evidence of chronic gastritis; H.pylori colonization in these patients was confined to antrum. Among the PPI group, gastric mucosal changes included atrophy and intestinal metaplasia. H pylori colonized predominantly in the fundus. Based on these observations it seems H2RA may be safer than PPI in patients requiring long term acid suppressants drugs.

**Disclosure:** All authors have declared no conflicts of interest.

### P02.02 POSSIBLE INVOLVEMENT OF GLUCOSE TRANSPORTER 3 AND 4 IN ESOPHAGEAL LEIOMYOMA WITH UNUSUAL HIGH UPTAKE OF FLUORINE-18-FLUORODEOXYGLUCOSE.

Yutaka Shimada<sup>1</sup>, Tomoyuki Okumura<sup>1</sup>, Ryota Hori<sup>1</sup>, Makoto Moriyama<sup>1</sup>, Shinichi Sekine<sup>1</sup>, Takuya Nagata<sup>1</sup>, Kazuhiro Nomoto<sup>1</sup>, Junya Fukuoka<sup>1</sup>, Kenichi Tazawa<sup>2</sup>, Kazuhiro Tsukada<sup>1</sup>  
<sup>1</sup>University Of Toyama, Toyama/JAPAN, <sup>2</sup>Itoigawa Hospital, Itoigawa/JAPAN

**Background:** Fluorine-18-fluorodeoxyglucose positron emission tomography (FDG-PET) scan is used for detection and diagnosis of malignant tumor. However, there were benign leiomyomas that showed unusual uptake of FDG. Glucose transporter 1 (Glut-1) is thought to be a main role of glucose uptake in several malignant tumors. However, there were several Glut isoforms and the role of them in esophageal leiomyoma had not been examined yet.

**Methods:** Three patients received enucleation or resection of esophageal submucosal tumor and had been confirmed as benign leiomyoma pathologically. All tumors showed positive expression of SMA and desmine, and negative expression of CD117 (c-Kit) and CD34. Glut-1, 2, 3 and 4 expression of these tumors were analyzed by immunohistochemical examination, and were compared to the preoperative FDG-PET findings. Cultured leiomyoma cells (TYLeio-3) from the patient were also examined for the expression of Glut-1, 3, and 4.

**Results:** Preoperative FDG-PET examination of the two patients revealed that a maximum standardized uptake value (SUVmax) of the tumor were 5.83 and 5.57. Both tumors had strong expression of Glut-3 and Glut-4. The other one patient showed low uptake of FDG and weak expression of Glut-3 and Glut-4. Interestingly, all three tumors had no expression of Glut-1 and Glut-2. Furthermore, TYLeio-3 cells had strong expression of Glut-3, weak expression of Glut-4 and no expression of Glut-1.

**Discussion:** The expression of Glut-3 and Glut-4, but not Glut-1, may be one of the reasons for high uptake of FDG in benign esophageal leiomyoma.

**Disclosure:** All authors have declared no conflicts of interest.

### P02.03 OBJECTIVE OUTCOMES 14 YEARS AFTER LAPAROSCOPIC ANTERIOR 180° PARTIAL VERSUS NISSEN FUNDOPLICATION: RESULTS FROM A RANDOMIZED TRIAL

Joris Broeders<sup>1</sup>, E Broeders<sup>1</sup>, D Watson<sup>2</sup>, P Devitt<sup>1</sup>, R Holloway<sup>1</sup>, Glyn Jamieson<sup>1</sup>  
<sup>1</sup>Royal Adelaide Hospital, Adelaide/AUSTRALIA, <sup>2</sup>Flinders Medical Centre, Adelaide/AUSTRALIA

**Background:** We aimed to investigate late objective outcomes 14-years after laparoscopic anterior 180° partial vs. Nissen fundoplication.

**Methods:** A subset of participants from a randomized trial of anterior 180° partial vs. Nissen fundoplication underwent stationary esophageal high-resolution manometry and ambulatory 24-h impedance-pH monitoring at 14 years follow-up. The subset and other patients in the trial also completed a standardized clinical questionnaire to ensure they were representative of the overall trial.

**Results:** 18 patients (8 anterior, 10 Nissen) underwent objective testing and they had a similar symptom profile to those who did not (n = 59). The total number of acid and weakly acidic reflux episodes per 24 h were higher after anterior fundoplication than after Nissen fundoplication (40.4 vs 15.0; P = 0.043). Proximal, mid-esophageal and distal reflux were proportionately increased after anterior 180° partial fundoplication. Both the number of liquid and mixed reflux episodes were higher after anterior fundoplication, which was accompanied by higher heartburn scores (2.5 vs 1.5; P = 0.018). There were no differences in gas reflux (37.8 vs 55.8; P = 0.829), gastric belches (51.4 vs 57.0; P = 0.999) and supragastric belches (21.3 vs 30.3; P = 0.762), which is in line with the observation that gas-related symptoms were similar for both groups. Mean LES resting (16.5 vs 19.2 mmHg; P = 0.274) and relaxation nadir pressure (8.3 vs 10.1 mmHg; P = 0.460) were lower after anterior fundoplication, which was reflected by lower dysphagia scores (5.4 vs 11.3; P = 0.006).

**Discussion:** At 14 years after randomization, this study demonstrated that acid and weakly acidic reflux episodes are more common after anterior 180° partial compared to Nissen fundoplication. On the other hand, gas reflux and gastric belching are similar for both procedures. Mean LES resting and relaxation nadir pressure are lower after anterior fundoplication.

**Disclosure:** All authors have declared no conflicts of interest.

### P02.04 PERIOPERATIVE POSITION FOR DEEP VEIN THROMBOSIS PROPHYLAXIS IN LAPAROSCOPIC ANTI-REFLUX SURGERY

Masanori Ohara  
National Hakodate Hospital, Hakodate/JAPAN

**Background:** The operation for laparoscopic anti-reflux surgery is usually performed with the position that elevation made head to maintain it of the operation field. When we conducted an investigation into postoperative deep vein thrombosis (DVT) in laparoscopic operation 54 cases that were performed, there were three cases in stomach carcinoma, one case in esophageal carcinoma, two cases in gallstone and one case in gastroesophageal regurgitation disease, but as for rectal carcinoma and sigmoid carcinoma, no case was seen. Thus, we supposed that the position that an inferior limb was easy to be congested because elevation did head was risk factor of DVT. It became clear that DVT produced even benign disease such as gallstone or esophageal hiatal hernia when it performed a vein of lower extremity echo after MAY 2007.

**Methods:** After June 2009, we started the trial which elevation could prick us with an inferior limb every one hour and was operation on. In a period until May 2011, we evaluated vein of lower extremity echo check for the case that we did.

**Results:** We did not show DVT outbreak in gallstone 15 cases and esophageal hiatal hernia 4 cases.

**Discussion:** It was thought that a position to let an inferior limb congest might let you induce DVT. We suppose that we might prevent DVT by removing blood stasis.

**Disclosure:** All authors have declared no conflicts of interest.

### P02.05 EFFECTIVENESS OF ANTIREFLUX SURGERY (FUNDOPLICATION) FOR THE CURE OF CHRONIC COUGH WITH OR WITHOUT GERD SYMPTOMS

Marialuisa Lugesesi, Ottorino Perrone, Beatrice Aramini, Alberto Ruffato, Sandro Mattioli  
Division Of Thoracic Surgery, Gvm Care & Research, Maria Cecilia Hospital, Cotignola (Ravenna), Center For The Study And Therapy Of Diseases Of The Esophagus. Alma Mater Studiorum - University Of Bologna, Italy, Bologna/ITALY

**Background:** The outcome of surgical therapy for atypical extra-esophageal symptoms allegedly secondary to GERD is controversial. Aim of this study was to assess the results of antireflux surgery in patients affected by 1) typical, 2) typical + atypical, (chronic cough), in whom a dedicated preoperative work up was performed.

**Methods:** Between 1995 and 2010, 151 patients with GERD-related typical and/or atypical symptoms were submitted to antireflux surgery. One hundred percent preoperatively underwent semi-quantitative evaluation of typical/atypical symptoms, chronic cough and esophagitis, barium swallow, endoscopy and histology and esophageal manometry (24 h pH-recording or intraluminal impedance/pH monitoring system in the absence of gross esophagitis). In addition, patients with chronic cough underwent chest HRCT scan, methacholine challenge test and spirometry. Surgery was performed exclusively on patients positive for GERD and negative for pulmonary diseases. Preoperative tests for GERD were repeated at follow-up.

**Results:** Patients were ordered into two groups: A) 83 patients with typical symptoms only, B) 68 patients with typical symptoms and chronic cough. In both groups, antireflux surgery demonstrated to significantly improve typical symptoms. The global score for outcome showed no significant differences between group A and B. In group B, antireflux surgery significantly improved chronic cough as well.

		Group A	Group B
Mean Age (years-Range)		53 (23–83)	53 (20–83)
Surgical procedures	Standard Nissen	65 (79%)	55 (81%)
	Collis Nissen	18 (21%)	13 (19%)
Followed Up Patients No (%)		81 (98%)	67 (99%)
Mean Follow Up (months) (Range)		59 (3–163)	63 (3–180)
		Preop.	Postop.
Reflux	0 (absent)	1 (1%)	71 (88%)
Symptoms (Typical)	1 (2–4/mth)	5 (6%)	8 (10%)
	2 (2–4/week)	34 (41%)	2 (2%)
No (%)	3 (daily)	43 (52%)	0
<i>p</i> (preop. Vs postop.)		<i>p</i> = 0.001	<i>p</i> = 0.000
Dysphagia	0 (absent)	8 (9%)	69 (85%)
No (%)	1 (2–4/mth)	43 (52%)	10 (12%)
	2 (2–4/week)	28 (34%)	36 (53%)
	3 (daily)	4 (5%)	11 (16%)
<i>p</i> (preop. Vs postop.)		<i>p</i> = 0.000	<i>p</i> = 0.002
Dysphagia	0 (absent)	42 (51%)	63 (78%)
No (%)	1 (2–4/mth)	31 (37%)	10 (12%)
	2 (2–4/week)	9 (11%)	2 (3%)
	3 (daily)	1 (1%)	6 (7%)
<i>p</i> (preop. Vs postop.)		<i>p</i> = 0.012	<i>p</i> > 0.05
Esophagitis	0 (absent)	16 (19%)	77 (95%)
No (%)	1 (edema/hist+)	16 (19%)	3 (4%)
	2 (erosion/s)	39 (47%)	1 (1%)
	3 (ulcers/Barrett)	12 (15%)	25 (37%)
<i>p</i> (preop. Vs postop.)		<i>p</i> = 0.004	<i>p</i> = 0.000
Chronic Cough	0 (absent)	–	–
No (%)	1 (mild)	–	0
	2 (moderate)	–	17 (25%)
	3 (severe)	–	35 (51%)
<i>p</i> (preop. Vs postop.)			<i>p</i> = 0.000
Global Outcome	0 (excellent: RS0, D0, E0)	51 (63%)	38 (57%)
No (%)	1 (good: RS1, D1, E1)	24 (30%)	18 (27%)
	2 (fair: RS1-2, D2, E1)	6 (7%)	4 (6%)
	3 (poor: RS2-3, D2-3, E2-3)	0	7 (10%)
<i>p</i> (group A Vs group B)			<i>p</i> > 0.05

**Discussion:** The preoperative work up was highly effective in selecting patients for antireflux surgery which achieved very satisfactory results in the treatment of GERD and GERD-related chronic cough.

**Disclosure:** All authors have declared no conflicts of interest.

#### P02.06 THE MONTREAL CLASSIFICATION OF GASTROESOPHAGEAL REFLUX DISEASE: IS IT USEFUL IN DAILY PRACTICE?

Sami Karoui, Baha Ben Slimane, Mona Bouamoud, Meriem Serghini, Lilia Zouiten, Jalel Boubaker, Azza Filali  
Department Of Gastroenterology A. La Rabta Hospital, Tunis/TUNISIA

**Background:** To determine the impact of the proposed classification for gastroesophageal reflux disease in 2007 called the Montreal in daily practice.

**Methods:** All 24-hour esophageal pH monitoring exams performed in our department since 1996 and for whom clinical information was available were studied. Indications for pH monitoring were reclassified as “The Montreal Classification” in “esophageal syndromes” (group 1), and “extra-esophageal syndromes” (group 2). Group 2 was subdivided, according to the classification in “established associations with GERD” (group 2a) and “proposed associations with GERD” (group 2b).

**Results:** Our study included 905 24-hour esophageal pH monitoring exams, performed in 414 men and 492 women, mean age 36 years (1–85 years). According to “The Montreal classification”, patients were divided into group 1 (n = 510) and group 2 (n = 396). Pathologic GERD has been found globally in 450 patients (50%), more frequently in group 1 (272/510, 53% vs 178/396, 45%, *p* = 0.02), and, paradoxically, more frequently in patients of group 2b compared to group 2a (51/72, 71% vs. 53/103, 51%).

**Discussion:** “The Montreal classification” of GERD is not correlated with the results of 24-hour esophageal pH monitoring. The clinical impact of this classification needs to be confirmed in further studies.

**Disclosure:** All authors have declared no conflicts of interest.

#### P02.07 SAME-DAY DISCHARGE AFTER LAPAROSCOPIC FUNDOPLICATION COMPARED TO CONVENTIONAL APPROACH: CLINICAL AND ECONOMICAL IMPACTS FROM A PROSPECTIVE MATCHED CASE-CONTROL STUDY

Nicolas Briez<sup>1</sup>, Caroline Gronnier<sup>2</sup>, Aurélien Desbeaux<sup>2</sup>, Julien Boutillier<sup>2</sup>, Jean-pierre Triboulet<sup>2</sup>, Christophe Mariette<sup>2</sup>  
<sup>1</sup>Medical And Surgical Ambulatory Department, Lille/France, <sup>2</sup>University Hospital Of Lille, France, Lille/France

**Background:** Day-case laparoscopic Nissen-Rosetti fundoplication (LNRF) was demonstrated feasible and safe. However postoperative course, func-

tional results, quality of life and impact on healthcare costs of the same-day discharge have never been compared to the conventional approach.

**Methods:** All patients who underwent a primary (LNRF) consecutively for proven symptomatic uncomplicated GERD from January 2003 to October 2011 were entered into a prospective database (n = 250). From 104 same-day discharge patients (day-case group), control conventional approach patients matched by age, sex, body mass index, ASA score and presence of hiatal hernia were randomly selected by computer (control group, n = 133).

**Results:** Postoperative mortality was nil. Postoperative morbidity rates were 6.1% in day-case group vs. 4.3% (ns) with median hospital stays of 1 vs. 4 days (*p* < 0.001) and readmission rates of 4.1% vs. 1.4% (ns). With a median follow-up of 24 months, 89.7% of patients were Visick 1 to 3 (excellent to good results), without any difference between groups. Reflux or dysphagia symptoms were reported in 14.7% and 3.4% vs. 14.7% and 4.4% of patients (ns). Reoperation was required in 9.3% of patients, 5 in the day-case group vs. 6 in the control group (ns). Gastrointestinal Quality of Life Index (GIQLI) was significantly enhanced by surgery (*p* < 0.001), without significant difference between groups. Estimated saving cost per patient was 2626 euros.

**Discussion:** Day-case and conventional approaches of patients after LNRF give similar results in terms of postoperative mortality and morbidity, functional results and quality of life, with a substantial cost saving for the day-case procedure.

**Disclosure:** All authors have declared no conflicts of interest.

#### P02.08 ACID AND DUODENOGASTROESOPHAGEAL REFLUX AFTER ESOPHAGECTOMY WITH GASTRIC TUBE RECONSTRUCTION AND INTRATHORACIC ESOPHAGOGASTROSTOMY

Masahide Fukaya, Keita Itatsu, Akihiro Hirata, Hiroaki Usui, Tomoki Ebata, Yukihiro Yokoyama, Tsuyoshi Igami, Gen Sugawara, Yu Takahashi, Keisuke Uehara, Yuichiro Yoshioka, Masato Nagino  
Division Of Surgical Oncology, Department Of Surgery, Nagoya University Graduate School Of Medicine, Nagoya/JAPAN

**Background:** To investigate the mechanism of acid and duodenogastroesophageal reflux after esophagectomy with gastric tube reconstruction and intrathoracic esophagogastronomy.

**Methods:** 23 patients with previous esophagectomy with gastric tube reconstruction and intrathoracic esophagogastronomy were subjected and divided into two groups depending on the position of the esophagogastronomy: group A (above the top of aortic arch, n = 10); and group B (beyond

the top of aortic arch, n = 13). All patients underwent simultaneous 24 h pH and bilirubin monitoring, and endoscopy in order to grade reflux esophagitis according to the Los Angeles classification. Reflux symptoms also were evaluated.

**Results:** No bile reflux to the esophagus was observed in group A, whereas bile reflux (a bilirubin absorbance exceeding 0.14 for more than 1.8 % of the total monitoring time) was observed in 9 of the 13 group B patients (69%) ( $P < 0.05$ ). Acid reflux to the esophagus (an esophageal pH below 4.0 for more than 4.4% of the total monitoring time) was observed in 2 patients in each group. These 4 patients had severe esophagitis. In 2 patients of group A, esophagitis was soon cured by PPI, whereas, in 2 patients of group B, esophagitis wasn't cured by PPI probably due to bile reflux. None in group A had severe reflux symptoms. One patient in group B whose anastomosis was beyond the bifurcation of the bronchus had severe reflux symptom.

**Discussion:** In reconstruction with gastric tube by intrathoracic anastomosis, esophagogastronomy should be performed above the top of aortic arch.

**Disclosure:** All authors have declared no conflicts of interest.

#### P02.09 DIFFERENCES IN ESOPHAGEAL PERCEPTION BETWEEN PROXIMAL AND DISTAL ESOPHAGUS EVALUATED BY ELECTRICAL STIMULATION

Jun Sakurai, Takashi Kondo, Fumihiko Toyoshima, Junji Tanaka, Toshihiko Tomita, Tadayuki Oshima, Hirokazu Fukui, Kazutoshi Hori, Jiro Watari, Hiroto Miwa  
*Hyogo College Of Medicine, Nishinomiyal JAPAN*

**Background:** Several clinical studies suggest that visceral perception by the esophagus may differ by esophageal location. In this study, we investigated the differences using electrical stimulation of the esophagus.

**Methods:** Nine healthy volunteers underwent electrical stimulation of the esophagus. Electrodes were placed at 20 cm, 15 cm, 10 cm, and 5 cm above the lower esophageal sphincter (LES), and sensory thresholds were determined by electrical stimulus intensity at each esophageal level. Symptoms as reported by participants were simultaneously evaluated during the procedure.

**Results:** Sensory thresholds were  $7.1 \pm 3.2$  mA (20 cm above the LES),  $6.9 \pm 2.3$  mA (15 cm above the LES),  $11.3 \pm 4.8$  mA (10 cm above the LES), and  $12.4 \pm 3.4$  mA (5 cm above the LES). We found that sensory thresholds were significantly decreased at 20 cm and 15 cm above the LES compared with 5 cm above the LES ( $p < 0.05$ ). The symptoms evoked by electrical stimulation were significantly different between proximal and distal esophagus, with stimulation evoking a variety of sensations including heartburn, coldness, warmth, and numbness in the distal esophagus.

**Discussion:** Our study reveals the significant differences between proximal and distal esophagus in sensory thresholds and types of symptoms evoked by stimulation. Mechanisms of esophageal sensation may differ between the proximal and distal esophagus.

**Disclosure:** All authors have declared no conflicts of interest.

#### P02.10 THE PREVALENCE AND EXTENT OF GASTROESOPHAGEAL REFLUX DISEASE CORRELATES TO THE TYPE OF LUNG TRANSPLANTATION

Cynthia Weber, Christopher Davis, James Gagermeier, Daniel Dilling, Charles Alex, Elizabeth Kovacs, Raymond Joehl, Robert Love, P Marco Fisichella  
*Loyola University Medical Center, Maywood/IL/UNITED STATES OF AMERICA*

**Background:** Evidence is increasingly convincing that lung transplantation is a risk factor of gastroesophageal reflux disease (GERD). However, it is still not known if the type of lung transplant (unilateral, bilateral, or re-transplant) plays a role in the pathogenesis of GERD.

**Methods:** The records of 61 lung transplant patients who underwent dual-sensor pH-monitoring between September 2008 and May 2010 were retrospectively reviewed. These patients were divided into 3 groups based on the type of lung transplant they received: Unilateral (n = 25); Bilateral (n = 30), and Re-transplant (n = 6). Among these groups we compared: 1) the demographic characteristics (e.g. gender, age, race, and body mass index); 2) the presence of Barrett's esophagus, delayed gastric emptying, and hiatal hernia; and 3) the esophageal manometric and pH-metric profile.

**Results:** Distal and proximal reflux were more prevalent in young and slender patients undergoing bilateral transplant or re-transplant, and less

prevalent in patients following unilateral transplant, regardless of the type of their lung disease. The prevalence of hiatal hernia, Barrett's esophagus, and the manometric profile were similar in all groups of patients.

**Discussion:** Although our data show a discrepancy in prevalence of GERD in patients with different types of lung transplantation, we cannot determine the exact cause for these findings from this study. We speculate that the extent of dissection during the transplant places the patients at risk for GERD. Based on the results of this study, a higher level of suspicion of GERD should be held in patients after bilateral or re-transplantation.

**Disclosure:** All authors have declared no conflicts of interest.

#### P02.11 PREDICTIVE VALUES OF SYMPTOMS IN THE OBJECTIVE EVALUATION OF ANTIREFLUX SURGERY

Ognjan Skrobic, Aleksandar P. Simic, Nebojsa Radovanovic, Milutin Kotarac, Mirko Gligorijevic, Nenad Ivanovic, Predrag Pesko  
*Department Of Esophagogastric Surgery, First Surgical University Hospital, Clinical Center Of Serbia, School Of Medicine University Of Belgrade, Belgrade/SERBIA*

**Background:** Although majority of patients are satisfied with outcome of Nissen fundoplication (NF), there are some who report recurrent symptoms. The aim of this study was to assess the predictive role of preoperative symptoms in the evaluation of NF success.

**Methods:** Prospective data during 4 years follow-up through the yearly check-ups of patients after NF. Symptoms were evaluated separately and in the term of cumulative symptom score. Role of symptom duration, PPI response and intake duration was also evaluated. Concordance of the timing of symptom recurrence and postoperative 24 h pH-metry data were also subject of our analysis. Surgery failure was considered in case of recurrent symptom presence and need for medications. Statistical methods were univariate and linear regression analysis.

**Results:** A total of 94 pts underwent NF and met inclusion criteria. 70 pts were satisfied with surgery (G1), while 25.5% had recurrent symptoms, or/and consumed antireflux medications postoperatively (G2). Positive postoperative 24 h pH-metry was present in 29.1% patients with recurrent symptoms. Poor response to PPIs was associated with higher postoperative heartburn scores. Longer duration of preoperative symptoms was associated with surgery failure ( $P = 0.032$ ). Presence of atypical symptoms was associated with 88.6% and 45.8% surgery success rates in G1 and G2 respectively ( $P = 0.009$ ). Early onset of recurrent symptoms was associated with negative pH-metry scores ( $P = 0.002$ ).

**Discussion:** Presence of atypical symptoms, longer preoperative symptom duration and poor PPI response were associated with surgery failure. Early onset of symptoms after surgery had poor correlation with objective reflux measurements.

**Disclosure:** All authors have declared no conflicts of interest.

#### P02.12 THE SURGICAL EFFECTS OF LAPAROSCOPIC ANTI-REFLUX SURGERY FOR NON-EROSIVE GASTROESOPHAGEAL REFLUX DISEASE

Fumiaki Yano, Nobuo Omura, Kazuto Tsuboi, Masato Hoshino, Seryon Yamamoto, Shunsuke Akimoto, Katsunori Nishikawa, Yuichiro Tanishima, Akira Matsumoto, Masami Yuda, Norio Mitsumori, Hideyuki Kashiwagi, Katsuhiko Yanaga  
*Jikei University School Of Medicine, Tokyo/JAPAN*

**Background:** Due to the high prevalence of PPI resistance, treatment of non-erosive gastroesophageal reflux disease (NERD) is challenging as compared to gastroesophageal reflux disease with reflux esophagitis (GERD). The aim of this study was to investigate the therapeutic effects of laparoscopic anti-reflux surgery (LARS) for NERD using 24-h combined multi-channel intraluminal impedance-pH monitoring (MII-pH).

**Methods:** Five patients (1 woman; mean age, 48.0 years) who underwent LARS for NERD were studied. MII-pH was performed before and at 3 month after surgery. Reflux events were classified by pH as acid or non-acid reflux. Intraesophageal pH < 4 holding time (pH < 4), longest episode, episodes over 5 min, DeMeester score, and the numbers of acid and non-acid reflux episodes were calculated with the patient in both liquid and gas reflux. The symptom index (SI) was also evaluated.

**Results:** The results are listed below. SI was positive for 3 patients (60%) before surgery and only 1 patient (20%) after surgery.

	pH<4HT (%)	Longest episode (min)	Episodes over 5 min.	DeMeester score
pre → post	3.4 ± 4.1 → 0.2 ± 0.4	4.4 ± 5.3 → 0.9 ± 2.0	1.2 ± 2.7 → 0 ± 0	10.9 ± 12.4 → 1.3 ± 1.2

	LAR	LNAR	GAR	GNAR
pre → post	35.8 ± 34.5 → 0.4 ± 0.5	38.0 ± 35.4 → 13.6 ± 10.9	1.6 ± 2.5 → 0.2 ± 0.4	12.6 ± 11.7 → 10.2 ± 8.2

LAR/LNAR: Liquid acid reflux/non-acid reflux, GAR/GNAR: Gas acid reflux/non-acid reflux

**Discussion:** 1) LARS completely controlled all reflux events. 2) LARS is a reliable procedure for treatment of NERD.

**Disclosure:** All authors have declared no conflicts of interest.

**P02.13 POSTOPERATIVE COMPLICATION OF ESOPHAGOBRONCHIAL FISTULA AFTER LAPAROSCOPIC ANTI-REFLUX SURGERY; REPORT OF A CASE**

Fumiaki Yano, Nobuo Omura, Kazuto Tsuboi, Masato Hoshino, Seryon Yamamoto, Shunsuke Akimoto, Norio Mitsumori, Hideyuki Kashiwagi, Katsuhiko Yanaga  
*Jikei University School Of Medicine, Tokyo/JAPAN*

**Background:** Short esophagus and esophageal stricture are complications of chronic severe gastroesophageal reflux disease (GERD). Laparoscopic anti-reflux surgery (LARS) has become the standard surgical procedure for the treatment of GERD.

**Methods:** We report a case of a patient who developed an esophagobronchial fistula after LARS.

**Results:** A 61-year-old male with GERD visited our department complaining of dysphagia. He had a sliding hiatal hernia and reflux esophagitis with Los Angeles classification Grade D, which was accompanied by a shortened esophagus with stricture. As therapy, acid inhibition by lansoprazole 60 mg was started. Endoscopic balloon dilation was performed for 7 times with minimal improvement of symptoms. He therefore underwent laparoscopic Toupet fundoplication. The duration of surgery was 144 min and the blood loss was minimal. His postoperative course was unremarkable and he was discharged on postoperative day (POD) 7. From 15 days after surgery, he had fever but the chest X-ray and the barium esophagogram were normal. He started to complain of chest pain, cough, and hemoptysis on POD 19. At this time, the barium esophagogram revealed esophagobronchial fistula. White blood cell and C-reactive protein were 24,100/mm<sup>3</sup> and 29.4 mg/dl, respectively. Percutaneous endoscopic gastrostomy (PEG) was placed on

POD 22 and enteral alimentation was started on POD 23. The fistula closed on POD 40 and oral intake was resumed. Finally, he was discharged from the hospital without any complaints on POD 51.

**Discussion:** 1) Enteral alimentation was useful for the treatment of the esophagobronchial fistula. 2) PEG should be placed for such a complications.

**Disclosure:** All authors have declared no conflicts of interest.

**P02.14 THE SURGICAL EFFECT OF LAPAROSCOPIC FUNDOPLICATION FOR GERD AND NERD ASSESSED BY COMBINED MULTICHANNEL INTRALUMINAL IMPEDANCE-PH MONITORING**

Fumiaki Yano, Nobuo Omura, Kazuto Tsuboi, Masato Hoshino, Seryon Yamamoto, Shunsuke Akimoto, Yoshio Ishibashi, Norio Mitsumori, Hideyuki Kashiwagi, Katsuhiko Yanaga  
*Jikei University School Of Medicine, Tokyo/JAPAN*

**Background:** Recent studies documented that up to 70% of reflux patients have typical reflux symptoms in the absence of endoscopically visible esophageal mucosal injuries, making NERD a common form of GERD. The long-term relief of reflux symptoms, heartburn and regurgitation are reported to be successfully controlled by laparoscopic antireflux surgery (LARS) in 84% to 97%. On the other hand, many patients especially ones with NERD complain of indiscrete symptoms after LARS. The aim of this study was to investigate the surgical effect of laparoscopic fundoplication for GERD and NERD assessed by combined multichannel intraluminal impedance-pH monitoring (MII-pH).

**Methods:** Eight GERD patients (Group A, 1 woman and 7 men; mean age, 53.6 years; Nissen : Toupet = 2:6) and 6 NERD patients (Group B, 1 woman and 5 men; mean age, 52.8 years; Nissen : Toupet = 0:6) were evaluated using MII-pH before and at 3 month after LARS. Reflux events were identified by MII-pH and patients recorded symptoms on a data logger.

**Results:** The results are listed below.

	Age	Gender	Surgical method
Group A	53.6 ± 19.8	F:M = 1:7	Nissen:Toupet = 2:6
Group B	52.8 ± 22.3	F:M = 1:5	Nissen:Toupet = 0:6
P-value	n.s.	n.s.	n.s.

	pH<4HT (%)	Longest episode (min)	Reflux events > 5 min.	DeMeester score
Group A (pre→post)	6.9 ± 3.8 → 0.2 ± 0.3	28.7 ± 21.8 → 0.9 ± 1.5	4.5 ± 3.1 → 0.1 ± 0.1	22.6 ± 11.0 → 1.3 ± 0.8
Group B (pre→post)	2.9 ± 3.9 → 0.1 ± 0.4	4.0 ± 4.9 → 0.9 ± 1.8	1.0 ± 2.5 → 0 ± 0	9.3 ± 11.7 → 1.4 ± 1.1
P-value (pre→post)	n.s. → n.s.	p=0.001 → n.s.	p=0.020 → n.s.	n.s. → n.s.

	LAR	LNAR	GAR	GNAR
Group A (pre→post)	38.8 ± 16.7 → 7.0 ± 9.1	27.3 ± 17.2 → 46.1 ± 33.6	5.4 ± 5.1 → 0.6 ± 0.9	18.6 ± 13.1 → 11.1 ± 14.5
Group B (pre→post)	31.5 ± 32.6 → 1.3 ± 2.3	32.2 ± 34.7 → 12.8 ± 9.9	1.7 ± 2.3 → 0.7 ± 1.2	13.2 ± 10.5 → 7.4
P-value (pre→post)	n.s. → n.s.	n.s. → p=0.029	n.s. → n.s.	n.s. → n.s.

LAR/LNAR: Liquid acid reflux/non-acid reflux, GAR/GNAR: Gas acid reflux/non-acid reflux

**Discussion:** 1) Between group A and B, intragastric pH < 4HT was not different. 2) Longest episode and reflux events of more than 5 min (i.e. long acid exposure) may be associated with erosion of gastroesophageal junction. 3) All reflux events were inhibited by LARS in patients with NERD as compared to increased LNAR alone in patients with GERD.

**Disclosure:** All authors have declared no conflicts of interest.

#### P02.15 TOTAL FUNDOPLICATION WITHOUT DIVISION OF SHORT GASTRIC VESSELS. FUNCTIONAL AND QUALITY OF LIFE EVALUATION.

Stefano Mattacchione, Salvatore Marano, Valentina Mingarelli, Barbara Luongo, Filippo Tosato  
*Referral Center For The Surgical Treatment Of Gastroesophageal Reflux Diseases, Department Of Surgery "F. Durante", Policlinico "Umberto I", "Sapienza" University Of Rome, Italy, Rome/ITALY*

**Background:** Gastro-esophageal reflux disease (GERD) has emerged as one of the most common diseases in modern civilization. We investigated endoscopic, functional and quality of life evaluation after total fundoplication without division of short gastric vessels

**Methods:** Between January 2007 and September 2010 76 GERD patients underwent laparoscopic Nissen-Rossetti fundoplication. Patients were submitted to close 2 years follow-up.

**Results:** DeMesteer&Jhonnson score decreased from preoperative 35.48 (SD  $\pm$  40.24) to 9.83 (SD  $\pm$  6.40) at 6 months, to 11.44 (SD  $\pm$  10.28) at 12 months and 10.25 (SD  $\pm$  5.61) at 24 months. Total cid exposure percentage < 4 was 14.04 (SD  $\pm$  19.52) before surgery, 2.33 (SD  $\pm$  2.80) at 6 months, 2.67 (SD  $\pm$  5.05) and 2.12 (SD  $\pm$  3.04) at 12 and 24 months. GERD HRQL decreased from preoperative 23.04 (SD  $\pm$  11.59) to 9.84 (SD  $\pm$  8.98) at 6 months, to 8.34 (SD  $\pm$  8.98) at 12 months and 6.8 (SD  $\pm$  6.46) at 24 months. SF-36 measurement showed significant improvement. 2 patients required reoperation for severe dysphagia.

**Discussion:** Our data are similar to those found in literature. Randomized and non-randomized studies seem to point out that division of short gastric vessels is unnecessary to perform a "short and floppy" plication, indeed, it does not improve clinical and laboratory outcome and is associated with prolongation of operating time and risk of bleeding. Only patient selection and accurate construction of fundoplication are fundamental factors in minimizing postoperative side effects. In conclusion Nissen-Rossetti fundoplication is a safe and effective for treatment of GERD, with minimal post-operative side effects.

**Disclosure:** All authors have declared no conflicts of interest.

#### P02.16 DILLATED INTERCELLULAR SPACES IN THE ESOPHAGEAL EPITHELIUM IS A MARKER OF TRETMENT'S EFFICIENCY OF GERD

Boris Starostin  
*Saint-Petersburg Gbuz City Policlinic 38, Saint-petersburg/RUSSIAN FEDERATION*

**Background:** from 90–100% of patients with gastroesophageal reflux disease (GERD) have dilated intercellular spaces (DIS) in the esophageal epithelium.

VALUE (*)	Radiology	Endoscopy	pH reflux	Manometry	Anatomy (pathology)
1	HIATAL HERNIA $\geq$ 2 CM	Z-I $>$ 2 cms	Postprandrial 1 Daily (Bipe) 2		A Esophagitis
3	HH + RX REFLUX	Z-I $<$ 5 cms	Nocturnal 3	LES hypotonic +3	B Esophagitis
4	HH $>$ 4-5 cms	Z-I $>$ 5 cms	Mixed 4	IES intrathoracic + 4 IES mixed +2	C Esophagitis
5	Paraesophageal or mixed H	Paraesophageal or mixed H	Low +0 Moderate +1 Severe +3	Non especific eosophageal body motor disorder + 5	D Esophagitis
7	Intrathoracic stomach	Intrathoracic stomach			
MAXIMUM SCORE	7	7	7	12	7

We prospectively analyzed 68 consecutive patients undergoing ambulatory LNF. Clinical outcome was compared with REFA score. Patients were clinically reviewed and underwent new objective explorations at 12 months postoperatively. Explorations were repeated yearly at least till the 5<sup>th</sup> year.

**Results:** REFA score in relation to GOERD classification showed statistically differences between NE esophagitis and ER 17.6 (4.1) vs 24.8 (4.1) p = 0.000. Follow up scores were also significant for NE and ER esophagitis 3.6 (6.5) vs 8.2 (8.1).

At follow up only 13 patients were classified as restitution ad integrum in terms of REFA scoring.

**Discussion:** The REFA system allows an accurate objective classification of GOERD correlates with GOERD class in terms of presence and degree of erosive esophagitis, allows accurate follow up analysis of surgical results.

**Disclosure:** All authors have declared no conflicts of interest.

**Methods:** The treatment process was performed in first group to endoscopic remission, and in second group to histological remission, which was confirmed by the elimination of DIS. In group 1 (n = 323) patients with various forms of GERD (erosive and nonerosive reflux disease) and the presence of DIS. In group 2 (n = 131) patients also with various forms of GERD, and confirmed at baseline DIS. Treatment was carried to full normalization of the width of intercellular spaces. Determination of DIS was carried out using light microscopy. In the second phase of the study were followed for patients (n = 151) without maintenance therapy. Other patients (n = 303) were transferred to maintenance therapy (various variants) by proton pump inhibitor.

**Results:** In first group during the first 3 months of follow-up recurrence of symptoms was observed in 90%, included in phase 2 of study. The recurrence does not depend on the form of GERD. In second group, in which treatment was carried out to full normalization of DIS, recurrence of symptoms within the first 3 months was observed in only 20%, included in the second phase of the study, and 6 months in 53%. Differences in recurrence in patients with various forms of GERD was not statistically significant. The findings suggest high significance of DIS as a marker of treatment's effectiveness, elimination of which affect the rate and frequency of recurrence of GERD, regardless of the form of the disease (exception composes grade C and D of the Los-Angeles classification). The most effective variant of maintenance therapy was a permanent treatment.

**Discussion:** The treatment of patients with GERD should be done before the histological remission, which slows down the pace and reduces the incidence of relapse of GERD.

**Disclosure:** All authors have declared no conflicts of interest.

#### P02.17 THE REFA SCORING SYSTEM OR HOW TO MEASURE AND CLASSIFY GASTROESOPHAGEAL REFLUX DISEASE IN PATIENTS UNDERGOING LAPAROSCOPIC NISSEN FUNDOPLICATION

Manuel Planells, Rafael Garcia Espinosa, Maria Cervera, Francisco Navarro, Angel Sanahuja  
*Icad (Instituto De Cirugía Y Aparato Digestivo), Valencia/SPAIN*

**Background:** Surgical and medical approaches to gastroesophageal reflux disease (GOERD) are difficult to compare due to heterogeneity in patient selection and characterization. Severity of GOERD through radiology, endoscopy and functional studies remains poor due to the unidimensional view of these studies. Pre-treatment classification allows appropriate selection and post-treatment objective evaluation.

**Methods:** We have developed a new objective system to measure GOERD severity. The REFA systems includes radiology, endoscopic, functional and anatomy findings scored from 1 to 7 points in relation to the severity of GOERD based on previous publications. Functional score is divided in pH and manometric recordings. All scores are equivalent between explorations so that the final score represents a global calculation of the severity of the disease. The scoring system is showed in Table 1.

#### P02.18 USE OF A NON-INVASIVE PEPSIN DIAGNOSTIC TEST TO DETECT GERD: CORRELATION WITH MII-PH EVALUATION IN A SERIES OF SUSPECTED NERD PATIENTS. A PILOT STUDY.

Nicola De Bortoli<sup>1</sup>, Edoardo Savarino<sup>2</sup>, Manuele Furnari<sup>3</sup>, Irene Martinucci<sup>1</sup>, Salvatore Russo<sup>1</sup>, Patrizia Zentilin<sup>3</sup>, Lorenzo Bertani<sup>1</sup>, Massimo Bellini<sup>1</sup>, Santino Marchi<sup>1</sup>, Vincenzo Savarino<sup>3</sup>  
<sup>1</sup>University Of Pisa, Gastroenterology Unit, Pisa/ITALY, <sup>2</sup>University Of Padova, Padova/ITALY, <sup>3</sup>University Of Genova, Genova/ITALY

**Background:** Presence of pepsin in bronchoalveolar lavage fluid, laryngeal biopsy and sputum may be a consequence of gastroesophageal reflux disease

(GERD). A novel non-invasive test to detect it in saliva/sputum (PEP-Test) has been proposed to diagnose GERD. A correlation between PEP-Test and multichannel impedance pH monitoring (MII-pH) has never been performed. The aim was to evaluate the PEP-Test accuracy for the diagnosis of GERD in patients with reflux symptoms by means of MII-pH.

**Methods:** Twenty patients with GER symptoms were studied. All patients with negative endoscopy underwent pathophysiological examinations, after wash-out from proton pump inhibitors. Samples of saliva/sputum were obtained by requesting the patient to cough up and spit into a tube containing 0.01 M citric acid within 15 minutes from experiencing reflux symptoms. Patients were grouped on the basis of MII-pH results as follows: True-NERD (increased acid exposure time, AET/reflux number); Hypersensitive Esophagus, HE (normal AET/reflux number, positive symptom association probability index, SAP); no-GERD patients (normal AET/reflux number, negative SAP). Roc curve was performed to obtain diagnostic accuracy of test.

**Results:** Male/Female was 8/12, mean age was 50.4 yrs, mean BMI was 24.8. MII-pH results showed: 8 True-NERD patients (median AET 10.7); 7 HE (median AET 1.6); 5 no-GERD (median AET 0.7). PEP-Test was positive in 75% of True-NERD, in 50% of HE, and negative in 100% of no-GERD patients. PEP-Test showed 64.3% sensibility, 100% specificity, 100% positive predictive value, 54.5% negative predictive value, 75% diagnostic accuracy.

**Discussion:** PEP-Test is a simple, economic, reproducible, highly specific test to detect the presence of GERD

**Disclosure:** All authors have declared no conflicts of interest.

#### P02.19 THE STATUS OF THE LOWER ESOPHAGEAL SPHINCTER AT REST AND THE DEGREE OF ESOPHAGEAL ACID EXPOSURE IN PATIENTS WITH GASTROESOPHAGEAL REFLUX DISEASE

Shahin Ayazi<sup>1</sup>, Jeffrey A Hagen<sup>2</sup>, Joerg Zehetner<sup>2</sup>, Steven R Demeester<sup>2</sup>, Daniel S Oh<sup>2</sup>, John Lipham<sup>1</sup>, Kimberly S Grant<sup>2</sup>, Arzu Oezcelik<sup>2</sup>, Tom R Demeester<sup>2</sup>

<sup>1</sup>University Of Southern California, Los Angeles/UNITED STATES OF AMERICA, <sup>2</sup>Department Of Surgery, University Of Southern California, Los Angeles/UNITED STATES OF AMERICA

**Background:** Manometric components of LES competency are resting pressure, overall length, and abdominal length. We hypothesized that the magnitude of the esophageal acid exposure is related to the number of the abnormal LES components measured at rest.

**Methods:** We studied 1,659 patients with reflux symptoms who had a detailed assessment of their LES with slow motorized pull-through manometry and 24-hour pH-monitoring off acid-suppression therapy. The LES was graded on a scale of 0-3. Grade 0 indicated all components were normal; 1, only one component abnormal; 2, two components abnormal; 3, all three components abnormal.

**Results:** The table shows as the number of the abnormal LES components increased, esophageal acid exposure increased. The values for the three LES components, irrespective of the LES grade at rest, inversely correlated to the pH score: total length ( $r = -0.23$ ), abdominal length ( $r = -0.22$ ) and resting pressure ( $r = -0.28$ ), ( $p < 0.0001$  for all 3 analyses). In the 883 patients with a normal LES at rest, 46% had an abnormal pH score.

LES Grade	# of patients	% of patients with positive score	Median pH score
0 all components normal	883	46%	12.5
1 only one component abnormal	284	54%	16.1
2 two components abnormal	394	70%	27.5
3 three components abnormal	98	91%	54.7

**Discussion:** The degree of esophageal acid exposure is related to the number of the abnormal LES components measured at rest. Forty six percent of patients with normal LES components measured at rest had an abnormal pH score and are hypothesized to have a decline in their LES component during the dynamic activities of daily living. This is supported by the observation that the measurements of all three LES component, irrespective of their LES grade, inversely correlated to the pH score.

**Disclosure:** T.R. DeMeester: Torax™ Medical Inc  
All other authors have declared no conflicts of interest.

#### P02.20 ALGINATES TEST AS CRITERION OF GASTROESOPHAGEAL REFLUX DISEASE

Dmitry Bordin, Leonid Lazebnik, Antonina Masharova, Vladimir Drozdov

Central Research Institute Of Gastroenterology, Moscow/RUSSIAN FEDERATION

**Background:** A number of different diagnostic modalities have been used for GERD and currently no golden standard has been described. The diagnosis of GERD is certain if there is evident relationship between symptoms and reflux of stomach contents. We hypothesized a relief of heartburn by algi-

nate, medicine that have an antireflux mechanism, can bet the proof of this association.

**Aim:** to evaluate the diagnostic accuracy of single dose of alginates (the alginates test) in detecting GERD in patients with heartburn.

**Methods:** 123 patients (m 46, f 77, age  $43.6 \pm 15.5$  years) with heartburn were investigated. Symptom response to the alginates compared to traditional diagnostic criteria of GERD (endoscopy, 24-hr pH-monitoring, esophageal manometry, response to treatment with PPIs).

**Results:** Of 91 (78.9%) patients with positive alginates test (rapid heartburn relief), 87 were classified as GERD positive and 4 as GERD negative. Of 32 (26%) patients with negative alginates test, 29 were GERD negative and 3 were GERD positive. The results provide a sensitivity of alginates test of 96.7% (95% CI, 93.8-100%), a specificity of 87.7% (95% CI, 82.8-99.2%), positive predictive value 95.5% (95% CI, 92.4-99.8%), and negative predictive value 90.8% (95% CI, 85.8-100%).

**Discussion:** The alginates test may be used as sensitive and specific criterion of diagnosis GERD in patients with typical symptoms.

**Disclosure:** D. Bordin: Reckitt Benckiser HealthCare  
All other authors have declared no conflicts of interest.

#### P02.21 EFFECT OF PPI (RABEPRAZOLE) ON REFLUX ESOPHAGITIS AFTER TOTAL GASTRECTOMY

Naoki Hashimoto  
Kinki University, Osakasayama/JAPAN

**Background:** Esophagitis after total gastrectomy has been associated with biliary and pancreatic reflux into the esophagus. The purpose of this study is to clarify the effect of PPI(Rabeparazole) (Eisai,Tokyo,Japan) on these factors in the esophagitis.

**Methods:** Sixteen 8-week old male Wistar rats were underwent total gastrectomy and esophagoduodenostomy to induce esophageal reflux of duodenal juice. In 5 rats the sham operation induced a midline laparotomy alone(Sham). One week following surgery, they were treated with control (saline)(n = 8),PPI(Rabepazole)(n = 8)(30 mg/kg/ip. 3 weeks after operation, all rats were killed and the esophagus was evaluated histologically. Esophageal injury was evaluated by macroscopic ,microscopic findings and expression of COX2 and PGE2. Esophageal washing was aspirated for the evaluation of bile acid activity.

**Results:** At 3 weeks after surgery, duodenal reflux induced esophageal erosions and ulcer formation as well as marked thickening of esophageal wall. The macroscopic ulcer score and histological ulcer length were significantly reduced by treatment with Rabepazole. The enhanced expression of COX2 and PGE2 in the control group was also markedly inhibited in the Rabepazole treated group. The bile acid activity in the esophageal lumen was significantly increased in the control group, and this increase was significantly inhibited in the Rabepazole treated group.

**Discussion:** With this model, we have demonstrated that Rabepazole significantly reduces inflammation and hyperplasia in the esophageal mucosa. These results indicate that bile acid, which is inhibited by Rabepazole, plays an important role in the mucosal damage induced by duodenal reflux.

**Disclosure:** All authors have declared no conflicts of interest.

#### P02.22 CHANGES IN QUALITY OF LIFE FOLLOWING DIFFERENT THERAPIES OF GERD

Benjamin Babic, Wolfram Breithaupt, Gabor Varga, Thomas Schulz, Alexander Reinisch, Karl-hermann Fuchs  
Agaplesion Markus Krankenhaus, Frankfurt Am Main/GERMANY

**Background:** The management of Gastroesophageal reflux disease (GERD) includes medical and surgical therapy. Quality of Life (QL) is an important parameter both in selecting patients for surgery as well as assessing the therapeutic results. Few prospective follow-up data is available in patients, in whom different therapeutic plans were administered. Aim of this study is to compare the development of QL, measured with the Gastrointestinal-Quality-of-Life-Index (GILQI), in different groups of patients, in whom 1. laparoscopic antireflux-surgery (LARS) was performed, 2. in whom LARS was suggested, but Protonpumpinhibitor(PPI)-therapy was continued and 3. in whom PPI-therapy was suggested to be continued.

**Methods:** Over a 3-year period patients were investigated history, physical examination, endoscopy, esophageal manometry and 24-h-pH-monitoring. In patients with severe GERD a LARS was suggested. Most patients followed the suggestion and had LARS (group1). Others with severe GERD wanted to continue PPI-therapy (group2). Patients with mild GERD were suggested to continue PPI-therapy, which they did (group 3). After 5 years of follow-up all patients were re-examined.

**Results:** Results: Follow-up: 60 months (36-96); Group1: n = 86 ; QL pre/post 93/118; Group2: n = 27; QL pre/post 96/107; Group3: n = 43; QL pre/

post 106/113. Only after LARS a significant difference and improvement in QL could be reached ( $p < 0.0005$ ).

**Discussion:** The study clearly shows the significant benefit in QL of GERD-patients after LARS. As well, the study demonstrates, that patients, who did not undergo the recommended surgical treatment, were not able to improve their QL significantly. Patients, who were recommended to continue conservative treatment, remained in a similar QL-level.

**Disclosure:** All authors have declared no conflicts of interest.

#### P02.23 RISKS OF PPI TREATMENT IN PATIENTS WITH CYSTIC FIBROSIS: EFFECT OF GASTRIC JUICE OF PATIENTS "ON" PPI ON IL-8 PRODUCTION BY CF PRIMARY BRONCHIAL EPITHELIAL CELLS.

Ans Pauwels<sup>1</sup>, Stijn Verleden<sup>2</sup>, Ricard Farre<sup>1</sup>, Bart Vanaudenaerde<sup>3</sup>, Lieven Dupont<sup>2</sup>, Daniel Sifrim<sup>4</sup>

<sup>1</sup>Targid, Catholic University Leuven, Leuven/BELGIUM, <sup>2</sup>Dept. Of Pneumology, Catholic University Leuven, Leuven/BELGIUM, <sup>3</sup>Dept. Of Pneumology, Catholic University Leuven, Leuven/BELGIUM, <sup>4</sup>Barts And The London School Of Medicine And Dentistry, Queen Mary, University Of London, London/UNITED KINGDOM

**Background:** Patients with cystic fibrosis (CF) are often treated with proton pump inhibitors (PPI) to reduce acid gastroesophageal reflux (GER). Duodeno-gastric aspiration is common in CF. We showed that gastric juice (GJ) from patients "on" PPI can induce high IL-8 by bronchial epithelial cells (BEC), mainly related to increased bacterial sub-products. We aimed to evaluate the effect of GJ "on" PPI on IL-8 production by CF primary BEC (CF-PBEC) and compare this with healthy PBEC (H-PBEC).

**Methods:** PBEC, obtained at lung transplantation were stimulated with GJ "off" PPI (1/1000) and GJ "on" PPI (1/1000). IL-8 was measured in supernatant.

**Results:** GJ "off" PPI provoked lower IL-8 production than GJ "on" PPI, both in H-PBEC [11 (4–28) vs. 462 (200–1468)pg/ml,  $p = 0.0001$ ] as in CF-PBEC [85 (26–131) vs. 1468 (841–2449)pg/ml,  $p < 0.0001$ ]. Exposure to GJ "off" PPI and "on" PPI provoked higher IL-8 production in CF-PBEC compared to H-PBEC ["off" 85 (26–131) vs. 11 (4–28)pg/ml,  $p = 0.02$ ; "on" 1468 (841–2449) vs. 462 (200–1468)pg/ml,  $p = 0.04$ ]. Filtration of the GJ "on" PPI reduced IL-8 production, both in H-PBEC as in CF-PBEC. There was a correlation between IL-8 and the pH of GJ, both in H-PBEC ( $r = 0.66$ ) as in CF-PBEC ( $r = 0.73$ ).

**Discussion:** CF patients, treated with PPI, have non-acidic GJ and bacterial contamination and often do aspirate. The aspirated material has an enhanced inflammatory effect on CF-PBEC. Our data suggest that chronic PPI treatment in CF may result in a paradoxically increased inflammatory effect in the airways. Alternative anti-reflux therapies should be considered in CF with increased GER and demonstrated aspiration.

**Disclosure:** D. Sifrim: Daniel Sifrim has served as speaker, consultant and advisory board member for Sandhill Scientific, MMS, Xenoport, Shire Movetis, Astrazeneca, Janssen Cilag, Reckitt Benckiser, Pfizer, Novartis and Glaxo Smith Kline  
All other authors have declared no conflicts of interest.

#### P02.24 ASSESSMENT OF THE ANTI-REFLUX PROPERTIES OF FARINGEL IN SYMPTOMATIC PATIENTS WITH GERD

Edoardo Savarino<sup>1</sup>, Nicola De Bortoli<sup>2</sup>, Francesca Galeazzi<sup>1</sup>, Patrizia Zentilin<sup>3</sup>, Manuele Furnari<sup>3</sup>, Irene Martinucci<sup>4</sup>, Luca Bruzzone<sup>3</sup>, Elisa Giamb Bruno<sup>3</sup>, Santino Marchi<sup>4</sup>, Giacomo Carlo Sturmiolo<sup>1</sup>, Vincenzo Savarino<sup>3</sup>

<sup>1</sup>University Of Padova, Padova/ITALY, <sup>2</sup>University Of Pisa, Gastroenterology Unit, Pisa/ITALY, <sup>3</sup>University Of Genova, Genova/ITALY, <sup>4</sup>University Of Pisa, Pisa/ITALY

**Background:** Antacids are used as add-on therapy in GERD patients. However, there is limited data regarding the mechanisms by which they act. Recently, a novel compound containing sodium bicarbonate and alginate has been introduced on market. To evaluate the effect of Faringel in modifying reflux characteristics and controlling symptoms.

**Methods:** Forty patients reporting heartburn and regurgitation with proven GERD (i.e. positive impedance-pH/erosive esophagitis) underwent impedance-pH testing after eating a refluxogenic meal (cappuccino, brioches containing chocolate cream and orange juice). They were studied 1-h in basal conditions and 1-h after taking 10 mL of Faringel. In both sessions, measurements were obtained in right lateral and supine decubitus. Patients completed a validated Likert-scale questionnaire (LSQ; range 0–4) and a 10-cm visual analogue scale (VAS) to evaluate symptoms control.

**Results:** Faringel decreased significantly ( $p < 0.05$ ), in both right lateral and supine decubitus, esophageal acid exposure time (median 10[25th–75th perc. 6–16] vs. 6[4–11] and 16[12–20] vs. 8[6–11]), number of acid reflux episodes

(5[3–7] vs. 1[1–2] and 6[4–8] vs. 1[1–2]) and percentage of proximal reflux episodes (60% vs. 33% and 65% vs. 35%) compared with baseline. In contrast, Faringel increased the number of non-acid reflux events compared with baseline (2[1–3] vs. 3[2–5] and 3[2–4] vs. 6[3–8]). Faringel was also significantly effective ( $p < 0.05$ ) in controlling heartburn (LSQ 3.1[range 1–4] vs. 0.9[0–2] and VAS score 7.1[3–9.8] vs. 2[0.1–4.8]), while was less effective with regurgitation (2.6[1–4] vs. 2.2[1–4] and 5.6[2–9.6] vs. 3.9[1–8.8]).

**Discussion:** Our findings demonstrate that Faringel is highly tolerated and effective in controlling, or at least reducing, heartburn in GERD patients.

**Disclosure:** All authors have declared no conflicts of interest.

#### P02.25 LOCAL NECK SYMPTOMS BEFORE AND AFTER THYROIDECTOMY: A POSSIBLE CORRELATION WITH GASTROESOPHAGEAL REFLUX AND REFLUX LARYNGOPHARYNGITIS.

Alessia Cusimano<sup>1</sup>, Achille Mastro Simone<sup>2</sup>, Eugenio Fiorentino<sup>1</sup>  
<sup>1</sup>Policlinico Of Palermo, Palermo/ITALY, <sup>2</sup>Policlinico Of Palermo, Agrigento/ITALY

**Background:** Swallowing, voice disorders and throat discomfort are usually reported by patients with a thyroid nodule. It may frequently occur in patients who have undergone uncomplicated TT complain of symptoms such as swallowing disorders, hoarseness, a sensation of strangling or of a lump in the neck, a cough and sore throat, all usually attributed to orotracheal intubation. Swallowing, voice and throat discomfort should thus be in some way related to the mechanical effects of nodular goiter or to thyroidectomy; it has never been suggested that the same symptoms might refer to a different concomitant medical problem with an overlapping clinical presentation. Reflux laryngopharyngitis is the most frequent caused by the laryngopharyngeal reflux (LPR), a term which refers to the backflow of gastric juice into the laryngopharynx. LPR has been considered one of the atypical clinical presentations of gastroesophageal reflux (GER) affecting the larynx and pharynx; several otolaryngologists maintain that LPR differs from GER and concerns reflux in otolaryngology patients more often in the absence of gastrointestinal symptoms.

**Methods:** in a period of 6 months, 144 patients undergone to TT, interviewed according to the Reflux Symptom Index, investigated through videolaryngoscopy and videofluoroscopic swallowing studies

**Results:** 3 months after surgery, swallowing and voice disorders and throat discomfort symptoms persisted in a large number of patients, associated with the laryngopharyngitis revealed by the findings at VLS and alterations at VFSS.

**Discussion:** this is the first study correlating local neck symptoms in patients with non-toxic nodular goiter to reflux extra-esophageal reflux, a new hypothesis.

**Disclosure:** All authors have declared no conflicts of interest.

#### P02.26 LAPAROSCOPIC ANTIREFLUX REDO SURGERY – CAUSES OF FAILURES OF THE PRIMARY REPAIR

Gabor Varga, Wolfram Breithaupt, Thomas Schulz, Benjamin Babic, Karl-hermann Fuchs  
Agaplesion Markus Krankenhaus, Frankfurt/GERMANY

**Background:** Introduction: A prospective analysis is needed from a population of Antireflux-Redo-surgery to assess the frequency and causes of failure of the primary repair and the role of mesh implantation.

The purpose of this study is the analysis of causes of failures after primary laparoscopic antireflux surgery by assessing these mechanisms by diagnostic work-up and during Redo-surgery.

**Methods:** Methods: During 4 years we have performed and attempted laparoscopic Redo-antireflux surgery in 151 patients. Prior to surgery, all patients underwent upper GI endoscopy, manometry, pH or PH-Impedance monitoring, as well as selectively bar-ium studies and gastric-emptying scintigraphy. Indications for Redo-surgery was re-flux recurrence, hiatal hernia recurrence, obstruction and dysphagia and / or pain. During Redo-surgery all intraoperative details were prospectively documented such as herniation, wrap break-down, wrap migration, extensive scarring, hiatal and cardia scar-bloc-formation, volvulus as well as mesh penetration. Long-term follow was assessed by Quality of Life (GIQLI).

**Results:** Results: Patients: 96 males, 55 females; Age: 56 (23–74); Causes of failures: migration: 61%; paraesophageal hernia: 12%; wrap disruption: 14%; Hiatal disruption: 37%; Volvulus and Scarring: 5%; Scar-bloc-formation: 4%; mesh-penetration: 2; Wrap stenosis: 9%; wrong diagnosis: 3%. Refunduplication: 80%; COLLIS-plasty: 10%; Resection: 7%. Conversion 9%. Morbidity 14%, Mortality none; GIQLI pre/post: 81/115.

**Discussion:** Conclusions: Laparoscopic Redo-antireflux surgery is possible in the majority of patients. Major reasons for failure is migration and hiatal



disruption. Major reason for conversion is scaring and bloc-formation after primary Mesh-insertion, which often requires resection.

**Disclosure:** All authors have declared no conflicts of interest.

**P02.27 GASTROESOPHAGEAL REFLUX DISEASE AND SOMATOFORM DISORDERS**

Karl-hermann Fuchs, F Ulbricht, Alexander Reinisch, Benjamin Babic, Thomas Schulz, Wolfram Breithaupt  
Agaplesion Markus Krankenhaus, Frankfurt/GERMANY

**Background:** Introduction: Gastroesophageal reflux Disease (GERD) is a frequent benign disorders with a multifactorial pathophysiologic background and its clinical presentation shows a large variety of different symptoms. Somatisation describes a situation, where physical complaints are present, which can not be explained by physical and objective findings. Little is known about the association between GERD and somato-form disorders, also presenting with an even larger variety of symptoms.

**Aim:** The purpose of this study is the evaluation of the presence and relationship of somatoform disorders in a large population of patients with foregut symptoms and heartburn suggestive of GERD.

**Methods:** All patients, referred with heartburn and other foregut symptoms over 6 years, were registered in a defined protocol of assessment. All patients received questionnaires to assess quality of life, the presence of a large variety of foregut symptoms and the presence of somatoform disorders. The SOMS-instrument (screening test for somatoform disorders) was used. SOMS consists of a number of 53 items, assessing the presence of somatoform disorders with a Somatoform Symptom Index SSI (normal range: 0–17)

**Results:** Results: 651 patients with heartburn and other foregut symptoms: mean age 49 years (13–89)(397 males; 254 females). Esophagitis positive:208 patients (32 %); positive DeMeester-Score in 388 patients (59,6%). Esophagitis 50,5%. SSI positive in 20% of patients. Patients with Foregut symptoms: SSI < 17: pH negative/positive: 196/284 or 59% ph positive ; patients with somatoform disorder SSI > 17: pH negative/positive: 67/104 or 61%.

**Discussion:** There is 23–25% probability of simultaneous somatoform disorder in GERDindependent acid exposure or not.

**Disclosure:** All authors have declared no conflicts of interest.

**P02.28 IBS OVERLAPS MORE FREQUENTLY WITH FH THAN WITH GERD. A PATHOPHYSIOLOGICAL STUDY.**

Nicola De Bortoli<sup>1</sup>, Irene Martinucci<sup>1</sup>, Edoardo Savarino<sup>2</sup>, Massimo Bellini<sup>1</sup>, Lorenzo Bertani<sup>1</sup>, Riccardo Franchi<sup>1</sup>, Caterina Racale<sup>1</sup>, Salvatore Russo<sup>1</sup>, Vincenzo Savarino<sup>3</sup>, Santino Marchi<sup>4</sup>  
<sup>1</sup>University Of Pisa, Gastroenterology Unit, PitalITALY, <sup>2</sup>University Of Padova, PadovaITALY, <sup>3</sup>University Of Genova, GenovaITALY, <sup>4</sup>University Of Pisa – Gastroenterology Unit, PitalITALY

**Background:** A large number of papers suggest an overlap between irritable bowel syndrome (IBS) and gastroesophageal reflux disease (GERD) but pathophysiological examinations have been performed only in few studies. The aim of this study was to evaluate the prevalence of IBS in different subgroups of patients with reflux symptoms: erosive esophagitis (EE), true- non erosive reflux disease (NERD) (TN), hypersensitive esophagus (HE), and functional heartburn (FH). The second aim was to evaluate the prevalence of anxiety and depression in the same subgroups.

**Methods:** One hundred and ninety-eight consecutive patients with typical and atypical reflux symptoms underwent upper endoscopy and, when negative, esophageal manometry and pH-impedance (MII-pH) after a 16-days wash-out from PPI/H2RA. Clinical history was recorded and IBS diagnosis was assessed (Rome III criteria). Colonoscopy was performed if necessary. Symptom association probability (SAP) was evaluated to relate symptoms and reflux events. On the basis of endoscopy and pH-MII results, patients were sub-classified into: erosive esophagitis (EE), TN (pH+), HE (pH-/SAP+), FH (pH-/SAP-).

**Results:** Age, BMI and voluptuary habits were similar in all groups. IBS was diagnosed in 17% of EE patients, 25.7% of TN, 53.3% of HE and 66.2% of FH (p < 0.05). Anxiety was more prevalent in FH patients (84.6%) as compared to HE (33.3%), TN (14.7%) and EE (7.5%) (p < 0.05).

**Discussion:** Our data suggest that IBS overlaps more frequently with FH than with GERD. Anxiety was more prevalent in FH patients, probably playing a role in symptoms perception.

**Disclosure:** All authors have declared no conflicts of interest.

**P02.29 LONG TERM RESULTS OF THE THORACOSCOPIC COLLIS-LAPAROSCOPIC NISSEN FOR THE TREATMENT OF SEVERE GERD WITH ACQUIRED SHORT ESOPHAGUS**

Ottorino Perrone, Marialuisa Lugaresi, Alberto Ruffato, Beatrice Aramini, Sandro Mattioli  
Division Of Thoracic Surgery, Gvm Care & Research, Maria Cecilia Hospital, Cotignola (Ravenna), Center For The Study And Therapy Of Diseases Of The Esophagus. Alma Mater Studiorum – University Of Bologna, Italy, BolognaITALY

**Background:** Purpose of this study is to present the long term results of the thoracoscopic Collis + laparoscopic Nissen performed for the treatment of severe GERD associated with short esophagus.

**Methods:** GERD patients were assessed before surgery with interview based on semi-quantitative scales for grading of symptoms, esophagitis from 0 (no symptoms and esophagitis) to 3 (severe symptoms and esophagitis), global evaluation (excellent, good, fair, insufficient), endoscopy + hysthology, barium swallow, manometry; after surgery every year, alternating interview and tests (same questionnaires as above) except routine manometry, according to a protocol. Intraoperatively the length of the addominal esophagus after maximal mediastinal mobilization of the esophagus was measured with a validated technique; true short esophagus was diagnosed when the submerged segment was < 1.5 cm. After surgery, result in patients receiving medical therapy or with recurrent hernia, although asymptomatic, was classified as insufficient.

**Results:** From 1996 to 2011, 299 minimally invasive procedures for GERD were performed. In 62/299 (20.7 %) short esophagus was assessed. The left thoracoscopic Collis gastroplasty was associated with 1 Toupet and 1 Dor (motility disorders), with the Nissen floppy fundusduplication in 60 patients (24 women, 36 men, mean age 55.2 ± 13.7 years, range 20 - 77). 5 procedures were converted at the beginning of the experience. Mortality was 1.7% (1/60), morbidity 11.7% (7/60). The mean follow-up was 58.6 ± 32.1 months (range 12–108).

Excellent	Good	Fair	Insufficient *
SR0/S0/D0/E0	SRI/SI/DI/E0	SRI-2/S2/D2/E1	SR2-3/S2-3/D2-3/E2-3
SR = Reflux Symptoms, S = Dysphagia, D = Dyspepsia, E = Esophagitis			
16 (27.2%)	37 (62.8%)	2 (3.4%)	4 (6.6%)

\* 2 for severe esophagitis and 2 for anatomical recurrence.

**Discussion:** With the thoracoscopic Collis-laparoscopic Nissen in patients affected by severe GERD and true short esophagus , satisfactory long-term results were achieved in 93.4% of cases.

**Disclosure:** All authors have declared no conflicts of interest.

**P02.30 GASTRO-OESOPHAGEAL REFLUX AND “EPILEPTIC” ATTACKS: CASUALLY ASSOCIATED OR RELATED? EFFICIENCY OF ANTIREFLUX SURGERY A CASE REPORT**

Achille Mastro Simone<sup>1</sup>, Alessia Cusimano<sup>2</sup>, Silvia Marino<sup>2</sup>, Gianni Pantuso<sup>2</sup>, Eugenio Fiorentino<sup>2</sup>  
<sup>1</sup>Polliclinico Of Palermo, PalermoITALY, <sup>2</sup>University Of Palermo, PalermoITALY

**Background:** Although a possible link between gastro-oesophageal reflux disease (GORD) and obstructive sleeping apnoea has already been reported in the literature, there has never been any suggestion of an association with epilepsy, and epileptic attacks have not so far been included among gastro-oesophageal reflux disease symptoms.

**Methods:** We report the case of a patient with gastro-oesophageal reflux disease associated with a sliding hiatus hernia, a short oesophagus and oesophagitis, who for the last ten years had not only presented the typical symptoms of gastroesophageal reflux, but also symptoms of obstructive sleep apnoea and epileptic- like attacks occurring occasionally and only during sleep.

**Results:** Partial posterior fundoplication was performed and considerably reduced the reflux symptoms, and in addition brought about a drastic decrease in the number of epileptic-like attacks.

**Discussion:** Our case suggests that epileptic-like episodes in patients with obstructive sleeping apnoea may well be linked to the simultaneous presence of GORD associated with hiatus hernia, and surgical treatment of GORD may bring about an improvement of the neurological problems.

**Disclosure:** All authors have declared no conflicts of interest.

**P02.31 GASTRO-OESOPHAGEAL REFLUX IN THE JOINT HYPERMOBILITY SYNDROME**

Asma Fikree, Jafar Jafari, Etsuro Yazaki, Daniel Sifrim  
Barts And The London School Of Medicine And Dentistry, Queen Mary, University Of London, London/UNITED KINGDOM

**Background:** Upper gastrointestinal (GI) symptoms are commonly associated with connective tissue disorders. The Joint Hypermobility Syndrome

(JHS) is a non-inflammatory connective tissue disorder characterised by musculoskeletal symptoms and hyperflexibility of the skin and joints. The prevalence of heartburn and regurgitation is as high as 40%. The mechanism for this is unknown, although previous studies have suggested an association between hypermobility and hiatus hernias. So far, it is unknown whether symptoms are caused by pathological acid reflux or hypersensitivity to physiological reflux.

**Methods:** We performed endoscopy, high resolution manometry and 24 hour reflux testing on symptomatic JHS patients who were referred to our upper GI physiology unit over 3 years.

**Results:** 22 patients with JHS were investigated: 6 males, age range: 12–56. None of them had oesophagitis on endoscopy. Based on reflux monitoring, 18 (81%) had non erosive reflux disease (NERD) and 4 (19%) had functional heartburn. Of those with NERD, 12(67%) had increased acid exposure and 6 (33%) had normal acid exposure with a positive symptom correlation (hypersensitive oesophagus). Of the 18 patients with NERD, 2 had a hiatus hernia, 3 had a hypotensive LOS and 5 had oesophageal hypomotility.

**Discussion:** There is a high prevalence of heartburn and regurgitation in patients with JHS. The majority of patients had increased acid reflux and a small group had oesophageal hypersensitivity to acid. Increased acid reflux is not related to hiatus hernia or oesophageal hypomotility suggesting transient lower oesophageal sphincter relaxation as the main mechanism.

**Disclosure:** All authors have declared no conflicts of interest.

#### P02.32 BARRETT'S OESOPHAGUS INFERS A HIGHER RATE OF REFLUX FOLLOWING FUNDOPLICATION

Amanda Bond, Daniel Wilson, Andrew Hastings, Darmarajah Veeramootoo, Krishna Kumar Singh  
*Worthing Hospital, Worthing/UNITED KINGDOM*

**Background:** Laparoscopic fundoplication is carried out for symptomatic proven Gastro Oesophageal Reflux (GOR) in patients with and without Barrett's oesophagus. It has been suggested that in patients with Barrett's, only those patients with no physiological evidence of reflux post surgery have any reduction in risk of transition to cancer. The aim of this study is to assess any difference in reflux recurrence rates for those with and without Barrett's.

**Methods:** A retrospective study of all patients undergoing laparoscopic fundoplication by a single surgeon between January 2002 and December 2011 were identified and information including prospectively collected data on pre and post operative pH manometry was assessed for evidence of reflux.

**Results:** Of 257 Laparoscopic Nissen Funduplications performed, 150 have post operative studies of pH manometry and 104 have pre and post operative pH manometry studies. 40 were in the presence of Barrett's. There is a significant difference ( $p = 0.0313$ ) in the presence of ongoing reflux on pH manometry between those with ( $n = 40$ ) and those without ( $n = 64$ ) Barrett's oesophagus.

**Discussion:** Barrett's oesophagus is shown to have an increased likelihood of continued reflux and therefore patients undergoing fundoplication in the presence of Barrett's should continue with medical management of reflux to reduce the risk of oesophageal cancer even when asymptomatic post procedure, unless absence of reflux is proven.

**Disclosure:** All authors have declared no conflicts of interest.

#### P02.33 LARYNGEAL AND VOICE DISORDERS IN PATIENTS WITH GASTROESOPHAGEAL SYMPTOMS: CORRELATION WITH THE PHMETRIA.

Maria Aparecida Henry, Anete Branco, Elaine Lara Mendes Tavares, Renata Mizusaki Iyomasa, Regina Helena Garcia Martins  
*Botucatu Medical School, Botucatu/BRAZIL*

**Background:** Purpose: To investigate the larynx, vocal and acoustic characteristics of dysphonic patients with positive gastroesophageal symptoms correlating the findings with normal pH monitoring.

**Methods:** 55 adult patients (44 women and 11 men) with permanent vocal symptoms associated with gastroesophageal symptoms underwent laryngoscopy, auditory perceptual analysis (GRBASI scale) and acoustic analysis. Such patients also performed pH monitoring with dual-channel probe during 24 hours.

**Results:** 17 patients had normal pH but 38 had pH altered. Several laryngeal lesions such as pachydermia in the posterior commissure were found in both groups. Some patients had more than a change during the laryngoscopy. The highest GRBASI scores were recorded in patients with pH monitoring change, corresponding to laryngeal lesions such as Reinke's edema, polyps and posterior pachydermia and associated lesions. Acoustic values were altered in both groups when compared with standard values determined by the voice analysis program used. However, in the comparison between groups, no significant differences of these parameters were found.

**Discussion:** Discussion / conclusion: Changes in laryngeal and vocal qualities were identified mainly in patients with pH monitoring altered, who represented 38% of the population. However, some of these changes were also detected in patients with normal pH monitoring, demonstrating that this exam can not necessarily be altered in acid laryngitis secondary to reflux.

**Disclosure:** All authors have declared no conflicts of interest.

#### P02.34 EVALUATION OF ESOPHAGEAL MOTILITY AND GASTROESOPHAGEAL REFLUX AFTER LUNG TRANSPLANTATION.

Rubens Sallum<sup>1</sup>, Sergio Szachnowicz<sup>2</sup>, Angela Falcao<sup>3</sup>, Rafael Carraro<sup>4</sup>, Paulo Pego Fernandes<sup>4</sup>, Ary Nasi<sup>3</sup>, Ivan Ceconello<sup>3</sup>  
<sup>1</sup>University Of Sao Paulo, Sao Paulo/BRAZIL, <sup>2</sup>Department Of Gastroenterology – Esophageal Surgical Division, University Of São Paulo School Of Medicine, São Paulo - Brazil, São Paulo/BRAZIL, <sup>3</sup>Esophageal Surgical Division Univ Of Sao Paulo, Sao Paulo/BRAZIL, <sup>4</sup>University Of S Paulo Thoracic Surg Dept, Sao Paulo/BRAZIL

**Background:** Lung transplantation is effective treatment for end stage lung disease. dysmotility associated to severe GERD is thought to be a risk factor for development or progression of chronic rejection after lung transplantation. Objective: Assess esophageal motility and GERD after lung transplantation correlating with pulmonary outcomes.

**Methods:** Ten consecutive patients were analyzed, 40% after single and 60% after double lung transplantation. 60% had pyrosis, 80% regurgitation, 60% cough, 70% hoarseness, and only 20% dysphagia (low grade score). Concerning the baseline pulmonary disease, 40% had emphysema, 30% cystic fibrosis and 30% with pulmonary fibrosis. Pulmonary function test, bronchoscopy with biopsies, bronchoalveolar lavage, esophageal manometry, pH-metry and endoscopy were performed. All patients enrolled had suspect of GERD and were tested to access the influence in pulmonary outcome.

**Results:** Three patients (30%) showed erosive esophagitis and one with hiatal hernia. Five patients (50%) had pathologic distal reflux (40% at supine position, 30% at upright position and 20% bipositional) 40% had proximal pathological reflux. Only 20% had mild hypomotility with normal peristalsis. Three patients with several upper reflux episodes were submitted to surgical treatment of GERD. They had started with chronic graft failure, and got a temporary improve of pulmonary function after reflux control. One of them was reoperated due to esophageal stasis.

**Discussion:** Conclusion: After lung transplantation, half of patients had pathological reflux. GERD predisposes to chronic graft failure, being an important issue in this patients. Surgical treatment was helpful in three patients and should be study in a larger and prospective series.

**Disclosure:** All authors have declared no conflicts of interest.

#### P02.35 THE CLINICAL SIGNIFICANCE OF SPONTANEOUS REFLUX DURING VIDEOESOPHAGRAM

Shahin Ayazi<sup>1</sup>, Joerg Zehetner<sup>2</sup>, Florian Augustin<sup>2</sup>, John Lipham<sup>2</sup>, Steven R Demeester<sup>2</sup>, Jeffrey A Hagen<sup>2</sup>, Kimberly S Grant<sup>2</sup>, Daniel S Oh<sup>2</sup>, James Halls<sup>3</sup>, Tom R Demeester<sup>2</sup>  
<sup>1</sup>University Of Southern California, Los Angeles/UNITED STATES OF AMERICA, <sup>2</sup>Department Of Surgery, University Of Southern California, Los Angeles/UNITED STATES OF AMERICA, <sup>3</sup>Radiology, University Of Southern California, Los Angeles/UNITED STATES OF AMERICA

**Background:** The significance of spontaneous reflux during a barium swallow is unclear. The aim of this study is to determine if spontaneous reflux events during a videoesophagram are diagnostic for gastroesophageal reflux disease (GERD).

**Methods:** The records of 92 patients with GERD, who underwent a videoesophagram within 2 weeks of esophageal pH-monitoring, were reviewed. An experienced radiologist looked for evidence of the spontaneous reflux defined as the reflux of barium from the abdominal or herniated stomach into the esophagus. The occurrence and characteristics of the spontaneous reflux episodes were compared to the findings from esophageal pH-monitoring.

**Results:** Spontaneous reflux episodes occurred in 41/92 patients (45%). In 33(80%) the height of the reflux was confined to the distal third of the esophagus and in 8(20%) it extended into the mid esophagus or higher. Of the 41 patients, 39(95%) had a hiatal hernia. Patients with spontaneous reflux were more likely to have an abnormal pH score (78% vs. 53%,  $p = 0.016$ ). All of the 8 patients who had spontaneous reflux to or above the mid esophagus had an abnormal pH score. The finding of a spontaneous reflux episode during a videoesophagram had a 78% positive predictive value and a 73% negative predictive value for an abnormal pH score. The number of spontaneous reflux events per patients did not improve these predictive values.

**Discussion:** Patients with spontaneous reflux episodes on videoesophagram had a 78% risk of an abnormal pH score and 100% if it extended up to the mid or proximal esophagus.

**Disclosure:** T.R. DeMeester: Torax™ Medical Inc

All other authors have declared no conflicts of interest.

#### **P02.36 DOES BILIARY DISEASE SHOULD BE ROUTINELY ACCESSED IN SURGICAL PATIENTS WITH GERD AND ESOPHAGEAL ACHALASIA? ANALYSIS OF 914 CONSECUTIVE CASES.**

Rubens Sallum<sup>1</sup>, Julio Rocha<sup>2</sup>, Francisco Seguro<sup>3</sup>, Sergio Szachnowicz<sup>2</sup>, Andre Duarte<sup>5</sup>, Ivan Ceconello<sup>5</sup>

<sup>1</sup>University Of Sao Paulo, Sao Paulo/BRAZIL, <sup>2</sup>Esophageal Surgical Division Univ Of Sao Paulo, Sao Paulo, Brazil, Sao Paulo/BRAZIL, <sup>3</sup>Hospital Das Clinicas – Fmusp, São Paulo/BRAZIL, <sup>4</sup>Department Of Gastroenterology – Esophageal Surgical Division. University Of São Paulo School Of Medicine, São Paulo – Brazil, São Paulo/BRAZIL, <sup>5</sup>Esophageal Surgical Division Univ Of Sao Paulo, Sao Paulo/BRAZIL

**Background:** Introduction: High association of cholecystolithiasis -CC with GERD and esophageal achalasia – EA is systematically emphasized, in particular in patients due to Chagas' disease, (myenteric plexus destruction causing cholestasis). Objective: To evaluate the prevalence of CC in patients to be submitted to surgery for GERD and EA.

**Methods:** Method: We evaluated 914 consecutive patients submitted to fundoplication due to GERD or cardiomyotomy for EA in the Esophageal Surgery Division Univ. of Sao Paulo from 2000 to 2011, evaluating the global prevalence of CC and among cases of EA those objectively identified as resulting from Chagas Disease-CH (positive serology and / or epidemiology) and idiopathic form -ID. Demographic factors (gender, age) also were analyzed and compared.

**Results:** Of 914 surgical patients: 452 with HiatoPlasty and Fundoplication (GERD) and 462 -cardiomyotomy and Fundoplication (EA): 199 with CHform and 263 IDform. The overall CC prevalence was 114cases (12.5%), higher in GERD: 66 (14.6%) than in AE 48 (10.4%) (p = 0.05). There was no difference between different forms: AE-CH was 20 (10.5%) and AE-ID 28 (10.6%) (p = 0.83). Mean age (54.8 y) was similar. Patients were asymptomatic and concomitantly submitted to cholecystectomy during the esophageal laparoscopic operation. No complications or mortality related to cholecistectomy was observed.

**Discussion:** Conclusions: The prevalence of CC in patients to be operated for benign esophageal disorders (GERD and EA) is high (8.9%) and deserves routine preoperative investigation. The prevalence of CC was higher in GERD patients. The possible higher prevalence of CC in EA-CD compared to EA-ID cases was not observed.

**Disclosure:** All authors have declared no conflicts of interest.

#### **P02.37 GASTROESOPHAGEAL REFLUX DISEASE RECURRENCE – ANALYSIS OF 97 CONSECUTIVE REOPERATED CASES**

Sergio Szachnowicz<sup>1</sup>, Rubens Sallum<sup>2</sup>, Julio Rocha<sup>2</sup>, Francisco Seguro<sup>3</sup>, Ivan Ceconello<sup>4</sup>

<sup>1</sup>Department Of Gastroenterology – Esophageal Surgical Division. University Of São Paulo School Of Medicine, São Paulo – Brazil, São Paulo/BRAZIL, <sup>2</sup>Department Of Gastroenterology – Esophageal Surgical Division. University Of São Paulo School Of Medicine, São Paulo – Brazil, São Paulo, Brazil, Sao Paulo/BRAZIL, <sup>3</sup>Department Of Gastroenterology – Esophageal Surgical Division. University Of São Paulo School Of Medicine, São Paulo – Brazil, São Paulo, Brazil, São Paulo/BRAZIL, <sup>4</sup>Department Of Gastroenterology – Esophageal Surgical Division. University Of São Paulo School Of Medicine, São Paulo – Brazil, Sao Paulo/BRAZIL

**Background:** The indication for surgical re-operation of gastroesophageal reflux disease (GERD) is often individualized Aim: to evaluate the most common causes of reoperation and outcome of the surgical re treatment

**Methods:** From 1995 to 2011, 97 GERD patients submitted to reoperation were followed. Of these, 48 patients were previously treated at our hospital and 49 at other hospitals.

**Results:** Indication was in 76% due to symptoms of recurrent GERD , dysphagia in 21% and 7% in both. Predisposing factors (huge hiatal hernias, Barrett's esophagus, obesity) were identified in 40% of cases. In patients with dysphagia, the main causes were tight hiatoPlasty (38%) or twisted /tight fundoplication (38%). At the recurrent GERD group, 76% had migration and /or disruption of fundoplication. The success rate (improvement or complete remission of symptoms) was observed in 77%. Analyzing two different periods we observed mortality of one case before 2000 and zero after. After 2000, lap redo was done in 90% even with previous open procedure. The conversion rate was 6%.

**Discussion:** Reoperation in GERD in a referral service is safe by lap approach with low morbimortality with good results in 77%.

**Disclosure:** All authors have declared no conflicts of interest.

#### **P02.38 PROTON-PUMP INHIBITOR USE AS A MARKER FOR PATIENT DISSATISFACTION AFTER LAPAROSCOPIC NISSEN FUNDOPLICATION**

Guilherme Tommasi Kappaz<sup>1</sup>, Rubens Sallum<sup>2</sup>, Julio Rocha<sup>2</sup>, Sergio Szachnowicz<sup>1</sup>, Francisco Seguro<sup>3</sup>, Ary Nasi<sup>4</sup>, Ivan Ceconello<sup>4</sup>

<sup>1</sup>Department Of Gastroenterology – Esophageal Surgical Division. University Of São Paulo School Of Medicine, São Paulo – Brazil, São Paulo/BRAZIL, <sup>2</sup>Department Of Gastroenterology – Esophageal Surgical Division. University Of São Paulo School Of Medicine, São Paulo – Brazil, São Paulo, Brazil, Sao Paulo/BRAZIL, <sup>3</sup>Department Of Gastroenterology – Esophageal Surgical Division. University Of São Paulo School Of Medicine, São Paulo – Brazil, São Paulo, Brazil, São Paulo/BRAZIL, <sup>4</sup>Department Of Gastroenterology – Esophageal Surgical Division. University Of São Paulo School Of Medicine, São Paulo – Brazil, Sao Paulo/BRAZIL

**Background:** Laparoscopic Nissen fundoplication is indicated for patients with refractory GERD or PPI-dependent GERD. Routine use of proton-pump inhibitors (PPIs) impact quality-of-life and creates costs for patients and the health care system. We tried to demonstrate if PPI use after surgery could be a marker for patient dissatisfaction.

**Methods:** All 178 patients submitted to Laparoscopic Nissen Fundoplication between 2004 and 2008 were included. Patients were divided according to routine use of omeprazole, intermittent use or no use of medication. The GERD-HRQL questionnaire, validated for Portuguese language, was used to determine patient quality-of-life after surgery. Also, preoperative and postoperative body mass index (BMI) were calculated. T-student test and Pearson's correlation coefficient test were used.

**Results:** A total of 45 patients participated in this study. Twenty-four patients were using omeprazole. Twenty-one patients were not using any medication for GERD. The average GERD-HRQL score for patients not taking omeprazole was 4.04, while patients using the medication scored 8.86 (p = 0.034). When stratified by sex, the results were not statistically significant, probably due to a small number of patients in each group (women: p = 0.099; men: p = 0.138). Preoperative BMI was below 30 kg/m<sup>2</sup> in all patients. The mean preoperative BMI was 26.33 kg/m<sup>2</sup>. Patient satisfaction was high overall, with 93% of patients stating that they would do surgery again if needed.

**Discussion:** PPI use is a marker for lower satisfaction after surgery, although most of these patients had significant improvement in their quality-of-life. Preoperative BMI did not influence patient satisfaction as expected, since all of our patients were non obese.

**Disclosure:** All authors have declared no conflicts of interest.

#### **P02.39 COMPARISON OF THE GERD-HRQL QUALITY-OF-LIFE QUESTIONNAIRE APPLIED IN PERSON AND BY TELEPHONE IN PATIENTS SUBMITTED TO LAPAROSCOPIC NISSEN FUNDOPLICATION IN BRAZIL**

Guilherme Tommasi Kappaz, Rubens Sallum, Sergio Szachnowicz, Flavio Roberto Takeda, Julio Rocha, Ivan Ceconello  
<sup>1</sup>Department Of Gastroenterology – Esophageal Surgical Division. University Of São Paulo School Of Medicine, São Paulo - Brazil, São Paulo/BRAZIL

**Background:** Background: The GERD-HRQL questionnaire was developed as a specific instrument for evaluation of quality-of-life in patients with GERD, and was translated and validated to Portuguese. We compared the use of the GERD-HRQL applied in person and by telephone in a low socioeconomic status population.

**Methods:** 178 patients submitted to Laparoscopic Nissen Fundoplication between 2004 and 2008 were included. Forty-five patients accepted to be interviewed at our offices (group A), and another 45 patients were interviewed by telephone (group B). The GERD-HRQL questionnaire was used, and other two simple questions (1– “If you could choose would you do surgery again?” 2– “Score of improvement of symptoms between 0 and 10”) were also included. The t-Student test and Fisher's test were used for statistical analysis.

**Results:** Group A had an average score of 6.29. Group B had an average score of 14.09. The comparison of the overall scores in GERD-HRQL between groups A and B revealed that group A had a statistically lower score when compared to group B. This was observed among male patients (p = 0.018), females (p = 0.049) and both genders (p = 0.002). With questions one and two there was no statistical difference between both groups.

**Discussion:** GERD-HRQL questionnaire applied by telephone in a low socioeconomic status population in Brazil overestimated the symptoms after

Laparoscopic Nissen Fundoplication. We believe many patients attributed points confusing GERD symptoms with symptoms associated with other medical conditions when talking by telephone. The instrument appeared more reliable when applied in person.

**Disclosure:** All authors have declared no conflicts of interest.

#### P02.40 ASSOCIATED SYMPTOMS PATTERN CAN DISTINGUISH FUNCTIONAL HEARTBURN FROM GASTROESOPHAGEAL REFLUX DISEASE

Francesco De Giorgi<sup>1</sup>, Francesco Paolo Zito<sup>1</sup>, Maria Erminia Bottiglieri<sup>2</sup>, Paolo Andreozzi<sup>1</sup>, Alessandra D'Alessandro<sup>1</sup>, Giovanni Sarnelli<sup>1</sup>, Rosario Cuomo<sup>1</sup>

<sup>1</sup>Univeristy Of Naples "Federico II", Naples/ITALY, <sup>2</sup>Ospedale Civile Marcianise, Marcianise/ITALY

**Background:** Functional heartburn (FH) shares a similar symptoms pattern with gastroesophageal reflux disease (GERD) but is characterized by negative endoscopy/pH-impedance monitoring and a poor response to proton pump inhibitors (PPI). Our aim is to verify the presence of specific symptoms associations that should help to distinguish between these two conditions.

**Methods:** We retrospectively evaluated 107 patients with typical (heartburn, regurgitation), atypical (chest pain) and extraesophageal (cough or asthma) symptoms of GERD, who underwent pH-impedance monitoring on PPI. 45 subjects meet diagnostic criteria for FH according to Rome III, while the remaining 62 patients had a diagnosis of GERD. We assessed the prevalence of GERD symptoms associations both in GERD and FH groups by Rome III standardized questionnaire.

**Results:** We found that the presence of both heartburn +/- regurgitation or heartburn +/- regurgitation +/- chest pain was predominant in the GERD group (FH 16 vs GERD 35,  $p < 0.05$ , OR 0.6; FH 21 vs GERD 43,  $p < 0.05$ , OR 0.5), while heartburn +/- asthma or cough was more common in the FH group (FH 20 vs GERD 15,  $p < 0.05$ , OR 1.4). The association of heartburn and chest pain didn't show any statistical significance in both groups (FH 17 vs GERD 13,  $p = 0.08$ ).

**Discussion:** Heartburn, regurgitation and chest pain are more common in GERD patients, while FH is more frequently associated with extraesophageal symptoms, such as cough or asthma. The finding of different symptoms patterns in FH and GERD opens the way for future studies aimed to identify any differences in the pathophysiology of these two conditions.

**Disclosure:** All authors have declared no conflicts of interest.

#### P02.41 POSTPRANDIAL CHANGES IN AUTONOMIC NERVOUS SYSTEM AND FREQUENCY OF TRANSIENT LOWER OESOPHAGEAL SPHINCTER RELAXATION (TLOSRS)

Paul Kuo<sup>1</sup>, Ivana Bravi<sup>2</sup>, Upendra Marreddy<sup>2</sup>, Qasim Aziz<sup>2</sup>, Daniel Sifrim<sup>1</sup>

<sup>1</sup>Wingate Institute Of Neurogastroenterology, Barts And The London School Of Medicine And Dentistry, Queen Mary University Of London, London/ UNITED KINGDOM, <sup>2</sup>Wingate Institute Of Neurogastroenterology, Barts And The London School Of Medicine And Dentistry, Queen Mary University Of London, London/UNITED KINGDOM

**Background:** Patients with gastroesophageal reflux disease show abnormalities in their autonomic nervous system (ANS), especially decreased vagal activity. Transient lower oesophageal sphincter relaxation (TLOSRS) is a vagally-mediated reflex that occurs most frequently after a meal. The parasympathetic component of heart rate variability decreases after a meal, and correlates with changes in gastric electrical activity (electrogastrography). The ANS monitoring system Neuroscope provides beat-to-beat real time information on parasympathetic activity. We aimed to characterize the time association between postprandial changes in vagal tone and occurrence of TLOSRS.

**Methods:** 8 healthy volunteers (5 females, age  $31.2 \pm 2.8$  yrs) underwent simultaneous ANS and LOS pressure (high-resolution manometry) monitoring for 30 minutes, followed by a standard meal, and a further 4 hours postprandially.

**Results:** The number of TLOSRSs increased after the meal, compared to baseline ( $0.6 \pm 0.3$ ), during the first ( $7.1 \pm 1.1$ ;  $P < 0.001$ ), second ( $4.4 \pm 0.7$ ;  $P < 0.01$ ), and third ( $3.3 \pm 0.5$ ;  $P < 0.05$ ), hour. Cardiac Vagal Tone (CVT), a measure of efferent vagal activity, decreased after the meal, compared to baseline ( $10.3 \pm 1.7$ ), during the first ( $7.6 \pm 1.4$ ;  $P < 0.05$ ) and second ( $7.0 \pm 1.2$ ;  $P < 0.01$ ) hour. Cardiac Sensitivity to Baroreceptor reflex (CSB), a measure of afferent vagal activity, also showed a trend ( $P = 0.07$ ) to decrease. During the first postprandial hour there was an inverse correlation between CVT and the number of TLOSRSs ( $R^2 = 0.56$ ;  $P < 0.05$ ).

**Discussion:** Despite being a vagally-mediated reflex, the highest rate of TLOSRSs after a meal occurs during a period of decreased cardiac vagal tone.

A distinct pattern of postprandial CVT may be identified in our group of reflux patients.

**Disclosure:** All authors have declared no conflicts of interest.

#### P02.42 UPPER DIGESTIVE SYMPTOMS: CLINICAL VARIABLES ASSOCIATED WITH DIAGNOSTIC OR THERAPEUTIC APPROACH

Paolo Andreozzi, Simona Cammarota, Marco Della Coletta, Rosa D'Aniello, Giovanni Sarnelli, Rosario Cuomo  
Univeristy Of Naples "Federico II", Naples/ITALY

**Background:** Guidelines for the management of gastroesophageal disease (GERD) and dyspepsia (DYS) are based on clinical trials, without clearly considering some clinical factors as comorbidities. Few studies exist on adherence to these guidelines in primary care. The aim of our study is to identify the clinical variables influencing the physician approach to upper digestive symptoms in a primary care setting.

**Methods:** 197 general practitioners (GPs)(84% male,  $50 \pm 4$ years) participating to study administered to each patient with GERD and/or DYS, consecutively visited, a specific questionnaire in order to assess anamnestic data, upper digestive symptoms, clinical outcome (naïve, therapeutic response or not) and atypical or alarm symptoms.  $\chi^2$ -testing and binary logistic regression were used to evaluate the association between therapeutic or diagnostic approach and analyzed clinical variables.

**Results:** Data on 2042 patients (47% male;  $53 \pm 16$ years) were collected. Therapeutic approach was generally preferred to diagnostic one (63,7%, 36,3%). GPs chose more frequently diagnostic approach in patients with DYS and overlap (GERD + dyspepsia) than GERD (38%,38%,27%; $p < 0.001$ ). Therapeutic approach was also significantly associated to the presence of GERD symptoms (OR:1,52), with therapeutic relapse (OR:2,00) and with history of cardiopathy(OR:1,335), whereas anemia, anorexia, vomiting, symptoms severity and no therapeutic response were associated with diagnostic approach (OR:0,64; 0,64; 0,65; 0,52; 0,45).

**Discussion:** A general GPs adherence to GERD and DYS guidelines was observed. However, we found that history of cardiopathy is associated to therapeutic approach, while the presence of dyspeptic symptoms to diagnostic one, confirming that there are further specific factors influencing clinical approach.

**Disclosure:** All authors have declared no conflicts of interest.

#### P02.43 GERD AND DYSPEPSIA IN A PRIMARY CARE SETTING: ASSOCIATION WITH RISK FACTORS, ATYPICAL AND ALARM SYMPTOMS

Paolo Andreozzi, Simona Cammarota, Francesco Paolo Zito, Marco Della Coletta, Marcella Pesce, Francesco De Giorgi, Giovanni Sarnelli, Rosario Cuomo  
Univeristy Of Naples "Federico II", Naples/ITALY

**Background:** Gastroesophageal reflux disease (GERD) and dyspepsia (DYS) are common in the western population. Specific marks, symptoms and comorbidities can associate with clinical pattern. We aimed to estimate the association of GERD and DYS with risk factors, atypical and alarm symptoms in a population of patients in a primary care setting.

**Methods:** 2042 patients (1024 males,  $53 \pm 16$  years) with upper digestive symptoms were recruited; a specific questionnaire assessing symptoms and anamnestic data was administered to each patient. Data were analysed by  $\chi^2$ -testing.

**Results:** Overlap (GERD + DYS; OV) was more frequent than DYS and GERD (977-745-320 pts). There were no statistically significant differences among the age, gender, voluptuary habits in the three groups of patients. NSAIDs chronic use was more common in DYS and in OV than in GERD groups (189-230-56;  $p = 0.020$ ). GERD and OV were more associated with hoarseness and cough respect to DYS (40-106-46;  $p = 0.001$ ) (83-229-76;  $p < 0.001$ ). Conversely, more patients with chest pain or asthma were present in OV respect to GERD and DYS (190-32-106;  $p < 0.001$ ) (89-17-37;  $p < 0.01$ ). Anemia and anorexia were more frequent in patients with DYS and OV respect to GERD (76-88-16;  $p < 0.022$ ) (55-91-13;  $p = 0.009$ ). Weight loss, dysphagia, and vomiting were more frequent in OV than in DYS and GERD (152-80-28;  $p = 0.001$ ) (511-253-99;  $p < 0.001$ ) (203-112-40;  $p < 0.001$ ).

**Discussion:** The variegate association among marks, comorbidities and upper digestive symptoms can suggest some pathophysiologic mechanisms and support some diagnostic and therapeutic approach. The finding of an association between overlapping and alarm symptoms should lead the GPs to choose a diagnostic approach in these patients.

**Disclosure:** All authors have declared no conflicts of interest.

**P02.44 COMPUTED TOMOGRAPHY EVALUATION OF FAILURE OF ANTIREFLUX SURGERY.**

Andrés Sánchez-Pernaute, Amaya Herrasti, Elia Pérez-Aguirre, Marta Fernández Nespral, María Conde Rodríguez, Antonio Ruiz De León, Ricardo Rodríguez, Antonio José Torres García  
*Hospital Clínico San Carlos, Madrid/SPAIN*

**Background:** Barium swallow and endoscopy are the basis for the preoperative assessment of anatomic failure of antireflux procedure. Our aim is to analyse the contribution of computed tomography to improve the results of these preoperative evaluation

**Methods:** 12 patients with failure of a previous antireflux operation were submitted to computed tomography and then submitted to revisional surgery. Studies were performed using 64-detector-CT (Philips Brilliance CT 64 channel o GE Lightspeed CT) with patients in the prone-right anterior oblique position after 4 hours fasting 400 ml of "Gastrografin"R diluted to 4% were employed. No intravenous contrast media or additional drugs were administered. Scanner was obtained from 7 cm above diaphragm to mid abdomen, including the esophagogastric junction with a slice thickness of 1–2 mm. Multiplanar and volumetric reconstructions were performed. All operations were performed laparoscopically. Herniated funduplications were submitted to reduction and mesh hernioplasty and disrupted or twisted funduplications were unwrapped and re-build as a new total or partial fundoplication.

**Results:** Defects were divided between crural failure and fundoplication disruption or malposition. In the analysis of the crural defects, there was a 75% correlation between computed tomography and surgery, while in the evaluation of the fundoplication, complete correlation was found in 66% of the cases. However, subjective information obtained by the surgeon was considered useful in all cases in order to indicate and perform the revisional operation.

**Discussion:** In selected cases, computed tomography may offer important information towards a revisional operation after failure of an antireflux procedure.

**Disclosure:** All authors have declared no conflicts of interest.

**P02.45 A POLYMER INJECTION AND THE ENDOLUMINAL PPLICATION FOR THE TREATMENT OF GASTROESOPHAGEAL REFLUX DISEASE AND A LONG TERM EVALUATION.**

Rubens Sallum<sup>1</sup>, Eduardo Guimarães Hourneaux De Moura<sup>1</sup>, Sergio Szachowicz<sup>1</sup>, Ary Nasi<sup>1</sup>, Eudrdo Turiani H De Moura<sup>2</sup>, Diogo Turiani Hourneaux De Moura<sup>3</sup>, Joaquim Prado P Moraes-Filho<sup>1</sup>, Paulo Sakai<sup>1</sup>, Ivan Ceconello<sup>1</sup>  
<sup>1</sup>University Of Sao Paulo Medical School, 065/BRAZIL, <sup>2</sup>Santa Casa De Misericórdia De Bragança Paulista, 000/BRAZIL, <sup>3</sup>Hospital Irmãos Penteado, 000/BRAZIL

**Background:** To investigate the efficacy of the polymer injection and endoscopic plication in the long-term control of GERD (60 months).

**Discussion:** Gender and waist circumference determine esophageal acid exposure. Reflux counts and esophageal acid exposure are significantly higher in males than females. SI and symptom occurrences are not significantly different between genders. These findings implicate a higher sensitivity to reflux in females and partially explain higher complication rates in males.

**Disclosure:** All authors have declared no conflicts of interest.

**P02.47 TELEMETRIC PH MONITORING (BRAVOTM) PROVIDES ACCURATE DIAGNOSIS AND THERAPEUTIC PATHWAYS FOR PATIENTS WITH REFLUX SYMPTOMS.**

James Brewer<sup>1</sup>, T Dutton<sup>2</sup>, Hannah Travers<sup>1</sup>, Jon Whybrow<sup>2</sup>, Rachel Mcghee<sup>2</sup>, Phil Niblett<sup>2</sup>, Saj Wajed<sup>1</sup>  
<sup>1</sup>Royal Devon And Exeter Hospital, Exeter/UNITED KINGDOM, <sup>2</sup>Royal Devon And Exeter, Exeter/UNITED KINGDOM

**Background:** Trans-nasal (TN) catheter pH monitoring is the standard investigation for patients with reflux symptoms. The Bravo™ probe is an endoscopically-placed catheter free device that allows objective measurement of distal esophageal acid exposure over a 48-hour period. We utilised this for selected patients to help establish definitive diagnoses. We report on our 8-year experience of this system and its impact upon establishing tailored management pathways.

**Methods:** 47 patients with GERD, age > 18 y, with heartburn longer than 6 months, LES > 5 mmHg, with a percentage of total time of pH < 4 equal or higher than 4.5% and with good response to PPI therapy, were submitted to endoscopic treatment between feb/03 to jul/05 and were followed until 60 m after treatment. Patients were categorized according to the clinical response: complete response (CR), partial response (PR) or no response (NR).

**Results:** 21 patients were submitted to the inert polymer injection technique (G0) and 27 received the endoluminal plication technique (G1). Over time, there was a trend toward an increased number of patients with no response, requiring reintroduction of PPI, with both techniques (G0 p = 0,006; G1 p < 0,001). Regarding the symptoms, there was a clear improvement until 12 m, with progressive decline until 60 m in both groups (p < 0,001). The GERD-HRQL showed a statistically significant CR in G0, at 1, 3, 6 and 12 months. However, the analysis at 60 m showed a significant raise of patients with NR. In the SF-36 there were benefits only in the G0 group until 3 m. G0 was related to higher complications, as fever (p = 0,03), and moderate pain (p < 0,001). There were no deaths. Esophagitis resolution occurred in 45% of G0 and in 40% of G1 patients. There were no improvements of manometric and pHmetric findings post procedures.

**Discussion:** Endoscopic therapies to control GERD were ineffective at long-term follow-up.

**Disclosure:** All authors have declared no conflicts of interest.

**P02.46 ROLE OF GENDER, WAIST CIRCUMFERENCE AND AGE IN GASTRO-ESOPHAGEAL REFLUX ACTIVITY: ANALYSIS OF 1013 IMPEDANCE-PH-STUDIES.**

Johannes Lenglinger, Margit Eisler, Claudia Ringhofer, Martin Riegler  
*Medical University Of Vienna, Dept. Of Surgery, Wien/AUSTRIA*

**Background:** Symptomatic gastro-esophageal reflux disease (GERD) is equally prevalent in both genders. Complications (esophagitis, Barrett's esophagus, esophageal adenocarcinoma) are more prevalent in males. In this study we investigated the influence of gender, age and biometric data on reflux activity.

**Methods:** Impedance-pH-studies of patients with symptoms suggestive of GERD obtained off proton pump inhibitor medication were included in this retrospective study.

**Results:** 1013 tracings of 580 (57.3%) females and 433 (42.7%) males, age 47.6 ± 14.6 years, were analysed. Gender (p < 0.001), age (p < 0.001) and waist circumference (p < 0.001) predicted the number of refluxes. Acid exposure was determined by gender (p < 0.001) and waist circumference (p < 0.001). No significant gender differences were found for Symptom Index (SI) and number of symptoms during reflux monitoring.

	Males N=433	Females N=580	Bonferroni adj. p-value
% pH<4	5.2 ± 4.6	3.8 ± 4.5	<0.001
N reflux episodes	63.3 ± 34.5	50.9 ± 31.4	<0.001
% acid refluxes	56.5 ± 21.0	50.0 ± 23.5	0.001
Liquid clearance time (s)	14.5 ± 9.5	14.7 ± 8.5	n.s.
Acid clearance time (s)	104.3 ± 100.9	85.9 ± 69.5	0.001

**Methods:** Patients undergoing telemetric pH monitoring for reflux symptoms between 2003–2011 were recorded in a prospective database which was used to perform a retrospective analysis of patient clinico-pathological details. The impact of the Bravo™ findings on creating a definitive diagnosis and offering optimal therapeutic modalities was analysed.

**Results:** All patients (total 91, median age 59.8, range 9–87 years, 45 male) were under investigation for suspected reflux-related disorders. Indications for Bravo™ testing included inability to tolerate standard investigations (58%), equivocal prior results (22%), and patient/clinician preference (20%). Failure occurred in 9 cases (10%); 1 due to intolerance and 8 for premature dislodgement. Pathologically increased distal esophageal acid exposure was confirmed in 58 patients (64%). The Bravo™ system proved discriminatory in 13 of 16 patients who had previous equivocal TN-monitoring measurements. 33 patients progressed to anti-reflux surgery. Reflux disease was definitively excluded in 21 (23%), and in 15 (16%) further investigations were warranted.

**Discussion:** The Bravo™ system is a well tolerated and safe investigation providing effective discriminatory diagnosis in the majority of patients with reflux disease. This enables clinicians to offer the optimal combination of treatment modalities.

**Disclosure:** All authors have declared no conflicts of interest.

**P02.48 PATIENTS WITH ESOPHAGEAL REFLUX DISEASE EXPERIENCE MORE INTENSE EPIGASTRIC SYMPTOMS BUT SIMILAR HEARTBURN AS COMPARED TO HEALTHY CONTROLS AFTER CAPSAICIN INGESTION**

Johann Hammer, Martina Führer

Medizinische Universität Wien, Vienna/AUSTRIA

**Background:** Exposure of the mucosa to capsaicin is characterized by a characteristic sensation of burning and pain.

**AIM:** to investigate esophageal symptoms induced by gastric capsaicin.

**Methods:** N = 20 patients with symptoms of heartburn (NERD, GERD I-2; 6 male/14 female; mean age  $\pm$  SEM:  $47 \pm 3$  years) and n = 17 healthy volunteers (10 male/7 female; age:  $31 \pm 3$  years) ingested a capsule containing 0.75 mg capsaicin after an overnight fast. Participants filled out a 5 scale symptom questionnaire (heartburn, epigastric burning and pain) before capsule intake and 30 minutes thereafter (0 = no symptom; 5 = highly severe symptom). Differences in the symptom scores before vs. after the test were calculated.

**Results:** 29% of controls and 50% of patients experienced heartburn after capsaicin ( $p > 0.05$ ); severity of heartburn was minimal both in the control group ( $0.4 \pm 0.2$ ) and the patient group ( $0.8 \pm 0.2$ ). Epigastric burning was reported by 53% (controls) vs. 70% (patients) ( $p < 0.05$ ), epigastric pain by 23% vs. 55% ( $p < 0.05$ ). Median symptom severity scores were minimal in controls for both epigastric burning ( $0.9 \pm 0.2$ ) and pain ( $0.3 \pm 0.2$ ) but mild to moderate in the patients group (epigastric burning:  $2.3 \pm 0.4$ ; epigastric pain:  $1.6 \pm 0.4$ ). Controls were significantly younger than reflux patients ( $p > 0.01$ ), but age did not seem to have an effect on the results (split half analysis:  $p > 0.05$ ).

**Discussion:** Gastric application of capsaicin via a capsule induced transient mild to moderately severe epigastric burning and pain in patients with ERD. Patients experienced more intense epigastric symptoms (burning and pain) than healthy controls, while symptoms of heartburn were not significantly different in patients and controls after capsaicin ingestion.

**Disclosure:** All authors have declared no conflicts of interest.

**P02.49 THE ENDOSCOPIC GRADING OF THE GASTROESOPHAGEAL FLAP VALVE AFFECTS THE REFLUX ACTIVITY IN PATIENTS WITH GASTROESOPHAGEAL REFLUX DISEASE.**

Oliver Owen Koch<sup>1</sup>, Adolf Kaindlstorfer<sup>2</sup>, Stavros A Antoniou<sup>2</sup>, Kai Uwe Asche<sup>2</sup>, Rudolph Pointner<sup>2</sup>

<sup>1</sup>General Surgery, Public Hospital Zell Am See, Austria, Zell Am See AUSTRIA, <sup>2</sup>General Surgery; Public Hospital Zell Am See, Zell Am See AUSTRIA

**Background:** Endoscopic grading of gastroesophageal flap valve (GEFV) is simple and reproducible, and is suggested to be a good predictor of reflux status. The aim of this study was to investigate the potential correlation between the grading of the GEFV and Quality of life (QoL), gastroesophageal reflux disease (GERD) symptoms, esophageal manometry, multichannel intraluminal impedance monitoring (MII) data and size of the hiatal defect.

**Methods:** Forty-three patients with documented chronic GERD who underwent endoscopy, esophageal manometry, and ambulatory MII monitoring before laparoscopic fundoplication were included. GEFV was graded I through IV using Hill's classification. QoL was evaluated using the Gastrointestinal Quality of Life Index (GIQLI). GERD symptoms were documented using a standardized questionnaire. The size of the esophageal hiatus was measured during surgery by calculating the hiatal surface area (HSA). Correlation analysis between QoL, GERD symptoms, esophageal manometry, MII data, HSA size and GEFV grading was performed. Statistical significance was set at a p value of 0.05.

**Results:** There was a significant positive correlation between increased GEFV grade and DeMeester score, total number of refluxes, acid reflux events, number of refluxes in supine position, and refluxes in upright position. Additionally, a significant positive correlation was found between HSA size and GEFV grading. The GEFV grading showed a tendency ( $p < 0.09$ ) to influence QoL, concerning intensity of GERD symptoms no significant influence was found. Mean LES pressures were reduced with increased GEFV grade, but significantly.

**Discussion:** Increased GEFV grade has significant effects on reflux activity. However, subjectively GERD patients are not significantly affected by the GEFV grade. Furthermore the study shows that the size of the esophageal hiatus correlates with the GEFV grading.

**Disclosure:** All authors have declared no conflicts of interest.

**POSTER SESSION P03: ADJUVANT AND NEO-ADJUVANT THERAPIES FOR ESOPHAGEAL CANCER – October 16, 2012 12:30–13:30**

**P03.01 THE NUMBER OF METASTATIC LNS IS A SIGNIFICANT PROGNOSTIC FACTOR FOR ESOPHAGEAL CANCER PATIENTS TREATED WITH NEOADJUVANT CHEMORADIO THERAPY**

Yasunori Akutsu, Kiyohiko Shuto, Masaya Uesato, Tsuguaki Kono, Isamu Hoshino, Toru Shiratori, Yuka Isozaki, Naoki Akanuma, Hisahiro Matsubara

Department Of Frontier Surgery, Chiba University, Chiba/JAPAN

**Background:** Background: The correlation between the number of pathologic metastatic LNs in patients with esophageal squamous cell carcinoma (ESCC) after neoadjuvant chemoradiotherapy (NACRT) and surgical outcome has rarely been reported. We evaluated the correlation between the number of pathologic metastatic lymph nodes (LNs) and the surgical outcome in ESCC after NACRT.

**Methods:** Methods: Eighty-eight patients with ESCC who underwent NACRT followed by surgery were evaluated. The clinical response of NACRT was evaluated and surgical specimens of the primary tumor and resected LNs and analyzed clinicopathologically.

**Results:** Results: Fewer pathologic metastatic LNs was associated with better survival. According to the number of metastatic LNs, the difference in the median survival was the largest between the groups when patients were divided into those with 2 and 3 metastatic LNs ( $\chi^2$ : 13.694,  $p < 0.001$ ). With regard to clinical factors, the initial N status prior to treatment had the most significant impact on survival by a univariate analysis ( $p = 0.064$ ), and the number of pathologic metastatic LNs was a risk factor for poor survival, with a hazard ratio of 5.128 (95% C.I.: 1.438–18.285,  $p = 0.012$ ) by a multivariate analysis.

**Discussion:** Of the various factors, the number of pathologic metastatic LNs was the strongest indicator to predict the patients' survival.

**Disclosure:** All authors have declared no conflicts of interest.

**P03.02 PERI-OPERATIVE OUTCOMES FROM ESOPHAGECTOMY FOLLOWING CHEMOTHERAPY AND RADIO THERAPY IN THE ELDERLY: RESULTS FROM THE KNIGHT CANCER INSTITUTE EXPERIENCE**

Charles Thomas, Cb Ord, Ew Gilbert, Ma Douthit, Lm Bloker, Jm Holland, Jp Dolan, Jg Hunter

Knight Cancer Institute, Oregon Health And Science University, Portland OR/UNITED STATES OF AMERICA

**Background:** Despite the widespread use of neoadjuvant chemoradiotherapy (NAT) prior to esophagectomy, there is a paucity of data regarding outcomes of this regimen in the elderly. The specific aims of this analysis was to quantitatively describe our experience of treating esophageal carcinoma (EC) in the elderly with NAT followed by open esophagectomy (OE) or minimally-invasive esophagectomy (MIE), emphasizing peri-operative complications and outcomes.

**Methods:** Retrospective review of 40 elderly pts. ( $\geq 70$  yrs) were treated with NAT followed by OE or MIE between 1994–2011. Peri-operative outcomes reported include overall complication rates, discharge disposition, & 30 day mortality.

**Results:** Median follow-up was 19.4 mos (range 0.9–59.8). 17 pts received OE & 23 received MIE. Six salvage resections were performed after prior definitive chemoradiotherapy. 36 pts underwent NAT and 4 pts underwent neoadjuvant chemotherapy alone with a platinum-based doublet. There was one 30 day mortality (MIE converted to OE). Overall complication rates in the MIE and OE groups were 78% and 94%, with the most common being arrhythmia, 52% and 53%. Both the MIE and OE groups had similar incidences of anastomotic leak, n = 2 and n = 3, & superficial wound infections, n = 2 and n = 2, respectively. The majority of pts undergoing surgery were discharged home as opposed to another facility, 61% and 59%, respectively. Median survival was 17.7 mos, with 20 pts (MIE n = 16, OE n = 4) alive at a max. follow-up of 59.8 mos.

**Discussion:** Esophagectomy after NAT in the elderly is feasible and age alone should not preclude the use of multi-disciplinary care in such pts with resectable EC.

**Disclosure:** All authors have declared no conflicts of interest.

**P03.03 PATHOLOGIC RESPONSE TO INDUCTION THERAPY PREDICTS SURVIVAL AFTER RESECTION IN LOCALLY-ADVANCED ESOPHAGEAL CANCER**

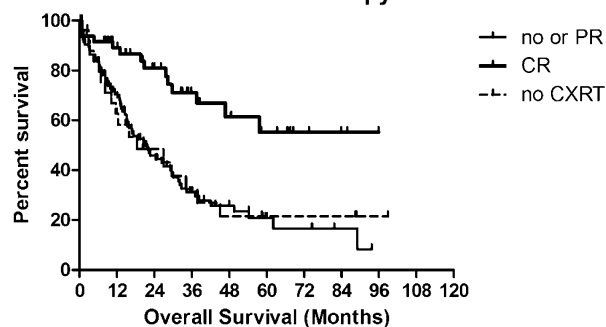
Sabha Ganai, Marie C Ziesat, Mitchell C Posner, Marco G Patti, Vivek N Prachand, Victoria M Villafior, Renuka Malik, Mark K. Ferguson  
The University Of Chicago Medical Center, Chicago/ILL/UNITED STATES OF AMERICA

**Background:** The optimal management of locally-advanced esophageal cancer remains controversial despite an increasing use of multimodal therapy.

**Methods:** A retrospective review was conducted on 282 consecutive esophagectomies performed from 2002–2012, identifying 182 patients with Stage IIB/III esophageal cancer based on preoperative clinical staging. Median follow-up was 15.6 months.

**Results:** Patients were 61 ± 12 years old, 80% male, and had a BMI of 27 ± 6 kg/m<sup>2</sup>. The median time interval from cancer diagnosis until resection was 4 months (IQR 3–5). Histology comprised 75% adenocarcinomas, 22% squamous cell carcinomas, and 3% adenosquamous carcinomas. PET and EUS were used for pretreatment staging in 78% and 93% of patients, respectively. 159 (86%) patients were resected after preoperative chemoradiation therapy, including 7 (4%) patients with disease progression after definitive chemoradiation who were amenable to salvage esophagectomy. Microscopically-negative (R0) resections were obtained in 91% of esophagectomies, although were less frequent without induction therapy (78% vs. 94%, p < 0.001). Pathologic complete responses (pCR) were seen in 29% of adenocarcinomas and 35% of squamous cell carcinomas receiving induction therapy. Median disease-free survival after pCR was 57.7 months, compared to 12.8 months for no/partial responses, and 11.1 months for no induction therapy (p < 0.001). At 5 years, overall survival was 55.3% for pCR, compared to 20.9% for no/partial responses, and 21.6% for no induction therapy (p < 0.001). Complete response to therapy remained an independent predictor of survival when controlled for resection status and key pathologic factors (p < 0.05).

**Overall Survival after Esophagectomy with Induction Therapy**



**Discussion:** Optimizing multimodality therapeutic strategies may provide the greatest benefit in the management of locally-advanced esophageal cancer.

**Disclosure:** All authors have declared no conflicts of interest.

**P03.04 NEO-ADJUVANT CHEMOTHERAPY FOR ESOPHAGEAL SQUAMOUS CELL CARCINOMA**

Ko Onodera<sup>1</sup>, Go Miyata<sup>2</sup>, Susumu Satomi<sup>2</sup>  
<sup>1</sup>Sendai Shakai Hoken Hospital, Sendai/JAPAN, <sup>2</sup>Tohoku University School Of Medicine, Sendai/JAPAN

**Background:** Although surgical treatment for esophageal carcinoma has improved these years, the prognosis of advanced tumors is still poor. To improve the survival rate, neo-adjuvant chemotherapy using cisplatin and 5-fluorouracil has performed and survival rate was compared.

**Methods:** Eligible patients had operable squamous cell carcinoma of the thoracic esophagus (Stage II-III, UICC 6th), treated in our hospital in 2008–2011. T4 tumors were excluded from this study. Patients treated with definitive chemoradiotherapy and primary surgery in 2001–2006 were used as control. Two cycles of chemotherapy using cisplatin 80 mg/m<sup>2</sup> day1 and 5-fluorouracil 800 mg/m<sup>2</sup> day 1–5 were performed and 3 to 5 weeks after secondary chemotherapy, thoracoscopic esophagectomy with regional lymph nodes dissection was performed. Usually, stomach tube was used as esophageal substitute. Cervical lymph nodes dissection was applied in case of upper esophageal tumors.

**Results:** 65 patients were treated with neo-adjuvant chemotherapy. Patients characteristics were as follows: 65 year-old average, male/female: 57/8,

upper/middle/lower/abdominal esophagus: 11/28/23/3, UICC Stage IIA/IIB/III: 13/13/39.No significant difference was observed among these three groups. Chemotherapy was completed in 82.8% patients. Operation was safely performed and occurrence of anastomotic leakage was not higher compared to control. Pathologically, one patients evaluated as complete response. Overall 3-year survival rate was 63.4 % which was slightly higher than definitive chemoradiotherapy and primary surgery groups although the result was statistically insignificant.

**Discussion:** Neo-adjuvant chemotherapy for Stage II-III esophageal squamous cell carcinoma was effective, however, more effective neo-adjuvant therapies were required for better prognosis.

**Disclosure:** All authors have declared no conflicts of interest.

**P03.05 TREATMENT STRATEGY FOR THORACIC ESOPHAGEAL CANCER INVADING TO ADJACENT ORGANS WITHOUT DISTANT METASTASIS (T4M0)**

Keigo Yamamichi<sup>1</sup>, Taku Michiura<sup>2</sup>, Junichi Fukui<sup>2</sup>, Aiko Ueda<sup>1</sup>, Takuya Saito<sup>1</sup>, Koji Nakai<sup>2</sup>, Kentaro Inoue<sup>2</sup>, Takayuki Motohiro<sup>1</sup>, Yasushi Nakane<sup>2</sup>, A-hon Kwon<sup>2</sup>  
<sup>1</sup>Department Of Surgery, Osaka Saiseikai Izuo Hospital, Osaka/JAPAN, <sup>2</sup>Department Of Surgery, Kansai Medical University, Osaka/JAPAN

**Background:** The multimodality treatment is necessary for T4M0 thoracic esophageal cancer. Two therapeutic modalities are currently available for that cancer; neo-adjuvant chemoradiotherapy followed by surgery (NA-CRT) and definitive chemoradiotherapy (D-CRT). However, the optimal choice of the modality remains controversial. In this study, we analyzed retrospectively our experience of the two therapeutic modalities for T4M0 thoracic esophageal cancer.

**Methods:** Between 1997 and 2009, 78 patients with T4M0 thoracic esophageal cancer underwent radical treatments. Nineteen patients underwent NA-CRT and another 59 patients underwent D-CRT. Eleven patients underwent salvage surgery (D-CRT + S) and 12 patients underwent additional chemotherapy (D-CRT + C) after D-CRT. The tumor response of CRT and overall survival rate were compared between the groups.

**Results:** Complete response (CR) was observed in 17 patients of the D-CRT group (28.8%) but in no patient of the NA-CRT group (0%). However, response rates including CR and partial response (PR) were similar between the two groups (D-CRT, 81.4%; NA-CRT, 78.9%). There was no significant difference in overall survival between the D-CRT group and the NA-CRT group. On the other hand, overall survivals of the D-CRT + S group and the D-CRT + C group were significantly improved compared with the D-CRT alone group. Postoperative complications were seen in 6 patients in the D-CRT + S group (54.5%). That was not different from the NA-CRT group (47.3%). No hospital mortality occurred in the D-CRT + S group.

**Discussion:** We seemed that D-CRT should be chosen initially for T4M0 esophageal cancer and the treatment following D-CRT such as a salvage surgery or the adjuvant chemotherapy should be added as needed.

**Disclosure:** All authors have declared no conflicts of interest.

**P03.06 COMPARISONS OF PERIOPERATIVE IMMUNOMODULATORY EFFECTS AND LONG-TERM RESULTS BETWEEN NEOADJUVANT CHEMORADIATION THERAPY AND NEOADJUVANT CHEMOTHERAPY FOR THE ESOPHAGEAL CANCER PATIENTS**

Satoshi Aiko<sup>1</sup>, Isao Kumano<sup>2</sup>, Yasumasa Koyama<sup>1</sup>, Shingo Maeda<sup>1</sup>, Go Ohshima<sup>1</sup>  
<sup>1</sup>Eiju General Hospital, Tokyo/JAPAN, <sup>2</sup>National Defense Medical College, Saitama/JAPAN

**Background:** To investigate the safety and efficacy of neoadjuvant therapy (NAT) for esophageal cancer patients, we compared perioperative immunomodulatory effects and adverse effects as well as beneficial effects between neoadjuvant CRT (NACRT) and neoadjuvant chemotherapy (NAC).

**Methods:** Of 248 patients who underwent curative surgery between 1998 and 2011, patients who had marked lymph node metastasis or T4 tumors received NACRT before 2008 (NACRT-group; n = 62), or NAC after 2009 (NAC-group; n = 30). Remaining 156 patients (S-group) underwent surgery without any NAT. The average irradiation dose was 33 Gy. The chemotherapeutic regimen was a low dose FP in the NACRT group, and was 2 cycles of FP in the NAC-group.

**Results:** The number of lymphocytes was significantly reduced in the NACRT-group during the perioperative period. The both NAT groups showed significantly lower number of T-cells on POD 7, while the NACRT-group showed significantly lower levels of B-cell and CD4(+)T-cell numbers, CD4/CD8 ratio, and PHA-induced lymphocyte transformation test on PODs 1 and 7. Therapeutic effects for Grades 2 or 3 in the primary tumors were achieved in 50% of the NACRT-group and in 6% of the NAC-group.

The incidence of respiratory complications was significantly higher and the survival rate derived from noncancerous death was significantly decreased in the both NAT groups.

**Discussion:** Although NACRT significantly reduced immune competence during the perioperative period when compared to NAC, there were no significant differences in the morbidity and long-term noncancerous mortality between the NAT groups. A strict management is necessary before and after surgery following NAT.

**Disclosure:** All authors have declared no conflicts of interest.

#### P03.07 DCF THERAPY FOR ADVANCED AND RECURRENT ESOPHAGEAL CANCER

Shinichi Asaka, Yoshihiko Naritaka, Noriyuki Isohata, Takeshi Shimakawa, Atsuko Usuda, Akira Miyaki, Minoru Murayama, Kentaro Yamaguchi, Takao Katsube, Shunichi Shiozawa, Kazuhiko Yoshimatsu, Kenji Ogawa  
*Tokyo Women'S Medical University Medical Center East, Tokyo/JAPAN*

**Background:** We have performed DCF therapy, in combination with docetaxel, cisplatin (CDDP) and 5-fluorouracil (5-FU), for unresectable and recurrent esophageal cancer since 2007. Here we report the efficacy of DCF therapy assessed in patients we have treated.

**Methods:** A total of 33 patients with esophageal cancer treated with DCF therapy at our department between 2007 and 2011. Of them, 23 patients received the treatment for unresectable esophageal cancer and 10 patients received for recurrent esophageal cancer. One cycle of DCF therapy comprised docetaxel at 50 mg/m<sup>2</sup> given at day 1, as well as CDDP at 12 mg/m<sup>2</sup> and 5-FU at 500 mg/m<sup>2</sup> given from day 1 to 5, which was performed every 3 to 4 weeks.

**Results:** Ten patients received one cycle of DCF therapy, 13 received 2 cycles, 5 received 3 cycles, 3 received 4 cycles, and 2 received 5 cycles. Therapeutic response was complete remission (CR) in 2 patients, partial remission (PR) in 9 patients, stable disease (SD) in 19 patients, and progressive disease (PD) in 2 patients, with a response rate of 36.4%. Grade 3 to 4 adverse events included hyponatremia in 11 patients (33.3%), neutropenia in 10 patients (30.3%), leukopenia in 9 patients (27.3%), anemia in 4 patients (12.1%), thrombocytopenia in 2 patients (6.1%), cardiac arrest in one patient, and pneumonitis in one patient who died within 30 days after completion of this regimen.

**Discussion:** Two patients reported CR after receiving DCF therapy, but response rate was 36.4%. Grade 3 to 4 hematological toxicity was observed in about 30% patients, and treatment-related deaths occurred in one patient. Therefore, DCF therapy for unresectable and recurrent esophageal cancer should require enough attention for an adverse event.

**Disclosure:** All authors have declared no conflicts of interest.

#### P03.08 SIZE-BASED PATHOLOGICAL RESPONSE (SPR) CLASSIFICATION OF PATHOLOGICAL RESPONSE TO INDUCTION CHEMORADIOTHERAPY: VALIDATION WITH A SERIES OF 172 PATIENTS.

Andrea Zanoni<sup>1</sup>, Simone Giacomuzzi<sup>1</sup>, Francesco Casella<sup>1</sup>, Anna Tomezzoli<sup>2</sup>, Giuseppe Verlato<sup>3</sup>, Jacopo Weindelmayer<sup>1</sup>, Giovanni De Manzoni<sup>1</sup>

<sup>1</sup>Upper G.I. Surgery Verona Hospital, Verona/ITALY, <sup>2</sup>Pathology Verona Hospital, Verona/ITALY, <sup>3</sup>Epidemiology And Medical Statistics, University Of Verona, Verona/ITALY

**Background:** Neoadjuvant chemoradiotherapy (CRT) is increasingly considered a standard approach in the treatment of both squamous cell carcinoma (SCC) and adenocarcinoma of the esophagus. Pathological complete responders (pCR or ypT0N0) are the best possible result, but partial responders still have a survival advantage. We previously published a classification of pathological response. We here re-evaluated an increased dataset of patients with this classification.

**Methods:** From 2000 to 2011, at Upper G.I. Division of Verona Hospital, 172 locally advanced esophageal cancers were treated with neoadjuvant CRT and then radical (R0) surgery (98 SCC and 74 adenocarcinoma). The classification named SizeBased-Pathological-Response (SPR) comprises ypT0N0 (SPR1), minimal residual disease N0 (ypMRDN0 = SPR2), non-responders N0 (huge residual cancer = SPR3) and ypN+ (SPR4). MRD is defined as residual foci on T ≤ 1 cm. The residual foci are carefully measured.

**Results:** pCR represented 46% of the entire population followed by ypN+ (27%), ypMRDN0 (17%) and non-responders N0 (10%). Five-year OS was 71% for SPR1, 57% for SPR2 and 35% for SPR3, while it fell to 14% in SPR4 (p < 0.001).

**Discussion:** SPR classification is a good tool to define response to treatment, being statistically significant, reproducible and objective. Lack of complete

response reduces survival, but SPR2 and less importantly SPR3 have still acceptable survival. N status is a major prognostic determinant, explaining why SPR4 have such dismal results. If SPR1 patients could theoretically avoid surgical procedures, surgery is and will be the mainstay of treatment for patients with residual cancer and no nodal involvement, even without response on T.

**Disclosure:** All authors have declared no conflicts of interest.

#### P03.09 TREATMENT STRATEGY FOR CLINICAL STAGE II/III ESOPHAGEAL CANCER

Yoshiaki Osaka, Sumito Hoshino, Shingo Tachibana, Takeshi Suda, Hironobu Kouji, Akihiko Tsuchida  
*3rd Department Of Surgery Tokyo Medical University, Tokyo/JAPAN*

**Background:** The development of 3-field lymphadenectomy, namely the neck, upper mediastinum and the abdomen, which has increasingly accepted from the mid-1980s, and advances in perioperative management have greatly improved the results of esophageal cancer therapy. Nevertheless, for advanced esophageal cancer, since further advances in surgical technique alone cannot be expected to improve the prognosis, multidisciplinary treatment including chemotherapy and radiation therapy is necessary. We compared treatment modalities for clinical stage II/III esophageal cancer to determine the optimal treatment strategy.

**Methods:** Subjects were a total of 194 patients with clinical stage II/III advanced esophageal cancer who had undergone treatment in our department from 1997 through 2010. For retrospective comparison of treatment modalities, the subjects were categorized according to treatment into two groups: surgery alone group (SA group, N = 92), preoperative chemoradiation group (NAT group, N = 102). Subjects in the NAT group had been treated with chemotherapy of CDDP and 5FU plus radiation of 30–40 Gy, followed by surgery about four weeks later.

**Results:** For subjects in stage II, 5-year survival rates/treatment-related deaths were 53.5%/2.4% in the SA group, 59.4%/0% in the NAT group. There was no significant difference between two groups on prognoses and treatment-related deaths. For subjects in stage III, 5-year survival rates/treatment-related deaths were 22.5%/0% in the SA group, 48.3%/2.6% in the NAT group. Prognoses were significantly more favorable in the NAT group (p < 0.0001), and there was no significant difference on treatment-related deaths.

**Discussion:** Preoperative chemoradiotherapy followed by surgery is recommended as the optimal treatment strategy for stage III advanced esophageal cancer.

**Disclosure:** All authors have declared no conflicts of interest.

#### P03.10 PROGNOSTIC FACTORS IN ESOPHAGEAL SQUAMOUS CELL CARCINOMA PATIENTS TREATED WITH NEOADJUVANT CHEMORADIATION THERAPY AND DETERMINATION OF AN APPROPRIATE STRATEGY FOR THEIR EVALUATION

Hiroshi Okumura<sup>1</sup>, Yasuko Uchikado<sup>1</sup>, Masataka Matsumoto<sup>1</sup>, Tetsuhiko Owaki<sup>1</sup>, Yoshiaki Kita<sup>1</sup>, Itaru Omoto<sup>1</sup>, Ken Sasaki<sup>1</sup>, Toshihide Sakurai<sup>1</sup>, Tetsuro Setoyama<sup>1</sup>, Bunpei Nabeki<sup>1</sup>, Daisuke Matsushita<sup>1</sup>, Sumiya Ishigami<sup>1</sup>, Toyokuni Suenaga<sup>2</sup>, Shoji Natsugoe<sup>2</sup>

<sup>1</sup>Department Of Digestive Surgery, Breast And Thyroid Surgery Graduate School Of Medical Sciences, Kagoshima University, Kagoshima/JAPAN, <sup>2</sup>Department Of Surgery, Nanpoh Hospital Kagoshima-Kyousaikai Corporate Juridical Person, Kagoshima/JAPAN

**Background:** Precise evaluation of surgical specimens obtained after neoadjuvant chemoradiation therapy (CRT) is important for assessing additional treatment or prognosis in patients with esophageal squamous cell carcinoma (ESCC). Therefore, we examined the histological prognostic factors for ESCC patients treated with CRT and determined an appropriate strategy for their evaluation.

**Methods:** The present study involved 38 consecutive ESCC patients who underwent CRT followed by curative operation. CRT consisted of 5-fluorouracil plus cisplatin and 40 Gy of radiation. We examined histological variables as follows: CRT effect on primary tumor (T-effect: T-effective/T-ineffective), tumor depth (pT), lymph node metastases (pN: pN0/N1), number of lymph node metastases (number-pN), lymphatic invasion, and venous invasion. T-effective is defined as disappearance of the tumor is present in more than 2/3 of the whole lesion. Univariate and multivariate analyses were performed to examine the independent prognostic factors. Survivals and mode of recurrence were then evaluated according to the independent prognostic factors.

**Results:** In the univariate analyses, T-effect, pN, number-pN, lymphatic invasion venous invasion and pT were found to be significant prognostic factors. In the multivariate analysis, pN and T-effect were independent prognostic factors. The five-year survival rate of pN0 patients was more than



75%, even though the T-effect was poor. The 5-year survival rate of patients judged as pN1/T-effective was 50%, whereas all of the pN1/T-ineffective patients died within 2 years with relapse disease.

**Discussion:** The evaluation method using both pN status and T-effect is useful for assessing prognosis of ESCC patients treated with neoadjuvant CRT.

**Disclosure:** All authors have declared no conflicts of interest.

### P03.11 IS TNM 7 ED. STILL RELIABLE IN THE DEFINITION OF N STATUS AFTER NEOADJUVANT CHEMORADIOTHERAPY?

Jacopo Weindelmayr, Andrea Zaroni, Simone Giacomuzzi, Francesco Casella, Maria Bencivenga, Giovanni De Manzoni  
*Upper G.I. Surgery Verona Hospital, Verona/ITALY*

**Background:** TNM 7<sup>th</sup> ed. modified, for esophageal cancer, the definition of N status, which is now based on the number of involved nodes. This classification is correct after surgery alone, but it is still debated if it retains its significance after induction therapies. We retrospectively re-classified our patients treated with neoadjuvant chemoradiotherapy (CRT), according to TNM 7<sup>th</sup> ed. to discover if this classification is still valid after neoadjuvant treatments.

**Methods:** From 2000 to 2011, at Upper G.I. Division of Verona Hospital, 172 locally advanced esophageal cancers were treated with neoadjuvant CRT and then radical (R0) surgery (98 SCC of the thoracic esophagus and 74 adenocarcinoma Siewert type 1–2). We re-classified our ypN+ patients treated with CRT in N1 (1–2 involved nodes) and N2-3 (3 or more nodes involved) to evaluate overall survival (OS).

**Results:** The ypN+ rate of the entire population was 28% (48/172), 23/48 SCC and 25/48 adenocarcinoma. Thirty-five patients were defined ypN1, while only 13 were ypN2-3. Moreover 12/13 of the patients with ypN2-3 were adenocarcinomas. Three-year OS was not statistically different for the two groups, being 29% for ypN1 and 25% for ypN2-3 (p = 0.32).

**Discussion:** N status is finely defined by TNM 7<sup>th</sup> ed. after surgery alone, but its value after induction CRT was not confirmed by our data. N status is a major prognostic determinant even after CRT, but the number of involved nodes may have reduced importance.

**Disclosure:** All authors have declared no conflicts of interest.

### P03.12 VENOUS THROMBOEMBOLIC EVENTS AND ESOPHAGECTOMY: IMPLICATIONS FOR DVT PROPHYLAXIS IN THE PERIOPERATIVE MANAGEMENT OF ESOPHAGEAL CANCER

Sabha Ganai, Marie C Ziesat, Mitchell C Posner, Marco G Patti, Vivek N Prachand, Victoria M Villaflor, Renuka Malik, Mark K. Ferguson  
*The University Of Chicago Medical Center, Chicago/ILL/UNITED STATES OF AMERICA*

**Background:** Venous thromboembolic events (VTE) are a major source of morbidity in cancer patients, with increased risk during the administration of chemotherapy. Despite this, little is described on the incidence of VTE with esophagectomy.

**Methods:** A retrospective analysis was performed on 282 esophagectomies from 2002–2012.

**Results:** Patients were 78% male and with median age of 62 years. There were no VTE among 19 esophagectomies performed for benign indications. Among 263 esophagectomies for malignancy, the overall rate of symptomatic VTE was 11.0% (6.8% preoperative and 5.3% postoperative), which comprised deep venous thrombosis (DVT) in 9.1% and pulmonary embolism (PE) in 6.4%. Patients receiving neoadjuvant chemotherapy had VTE in 13.3% (8.9% preoperative and 5.1% postoperative), while those without chemotherapy had VTE in 7.6% (4.8% preoperative and 3.8% postoperative). There were less VTE in the groups undergoing transhiatal esophagectomy (n = 101, 5.0%) compared to open (n = 64, 14.1%), minimally-invasive (n = 71, 15.1%), and hybrid (n = 33, 15.2%) transthoracic approaches (p < 0.05). IVC filters were inserted in 7 (39%) patients with preoperative VTE and in 2 (0.8%) patients without VTE history. BMI did not differ significantly between patients who had a PE compared to without (30 ± 7 vs. 28 ± 6 kg/m<sup>2</sup>). Median hospital length of stay was greater in the group with postoperative PE (23 vs. 9 days; p < 0.05). Morbidity associated with postoperative PE included tracheostomy in 3 (30%) and death in 1 (10%), with a decrease in median survival from 42 to 12 months.

**Discussion:** Opportunity to address VTE risk may be afforded by chemical prophylaxis during chemotherapy in addition to the perioperative period.

**Disclosure:** All authors have declared no conflicts of interest.

### P03.13 HISTOPATHOLOGIC RESPONSE TO PREOPERATIVE CHEMOTHERAPY ECF/ECCAP FOR ADENOCARCINOMA OF THE ESOPHAGUS AND ESOPHAGO-GASTRIC JUNCTION

Tomas Harustiak<sup>1</sup>, Milada Zemanova<sup>2</sup>, Ludmila Hornofova<sup>3</sup>, Eva Salkova<sup>3</sup>, Alexandr Pazdro<sup>1</sup>, Milan Smejkal<sup>1</sup>, Martin Snajdauf<sup>1</sup>, Robert Lischke<sup>1</sup>  
*<sup>1</sup>3rd Department Of Surgery, First Faculty Of Medicine, Charles University Of Prague And The Motol University Hospital, Prague/CZECH REPUBLIC, <sup>2</sup>Department Of Oncology, First Faculty Of Medicine, Charles University Of Prague, General University Hospital In Prague, Prague/CZECH REPUBLIC, <sup>3</sup>Department Of Pathology And Molecular Medicine, 2Nd Faculty Of Medicine, Charles University Of Prague And The Motol University Hospital, Prague/CZECH REPUBLIC*

**Background:** Perioperative chemotherapy ECF/ECCap with surgery is considered a standard of care for locally advanced resectable adenocarcinoma of the esophagus (AE) and esophago-gastric junction (AEGJ). Not all patients though respond well to preoperative chemotherapy (PreCT). The aim of our study was to assess histopathologic response to PreCT.

**Methods:** Seventy-nine patients with AE or AEGJ with initial clinical stage cT ≥ 2 cNany cM0 underwent esophagectomy or extended total gastrectomy after three preoperative cycles of ECF or ECCap according to MAGIC protocol. Tumor regression grade according to Mandar criteria was assessed. Patients with TRG 1,2 or 3 were classified as major responders (MAR) whereas TRG 4 or 5 as minor or no responders (MIR).

**Results:** There were 24 MAR (30%) and 55 MIR (70%). Initial clinical staging was similar in both groups, but there was significantly lower rate of ypNposit. (29% vs. 69%, p = 0.001) and a trend toward lower rate of ypT ≥ 3 (58% vs. 78%, p = 0.069) in MAR than MIR. With median follow-up time of 33 months (range 19–46 months) in 41 patients recurrence occurred in 36% MAR compared to 59% MIR (p = 0.145). In the subgroup with ypN0 the recurrence rate was still lower in MAR (20%) than in MIR (38%) (p = 0.351).

**Discussion:** The major histopathologic response rate to preoperative chemotherapy ECF/ECCap in AE and AEGJ was only 30%. Major responders however profit from significantly reduced rate of nodal metastases and a trend toward lower recurrences rate.

**Disclosure:** T. Harustiak: Supported by grant IGA of Ministry of Health of Czech Republic NT-12331-5  
M. Zemanova: Supported by grant IGA of Ministry of Health of Czech Republic NT-12331-5  
L. Hornofova: Supported by grant IGA of Ministry of Health of Czech Republic NT-12331-5  
A. Pazdro: Supported by grant IGA of Ministry of Health of Czech Republic NT-12331-5  
M. Smejkal: Supported by grant IGA of Ministry of Health of Czech Republic NT-12331-5  
R. Lischke: Supported by grant IGA of Ministry of Health of Czech Republic NT-12331-5  
All other authors have declared no conflicts of interest.

### P03.14 INDUCTION CHEMOTHERAPY USING FAP (5-FU, ADR AND CDDP) FOR PATIENTS WITH LOCALLY ADVANCED ESOPHAGEAL CANCER

Shigeyuki Tamura, Atsushi Takeno, Hirofumi Miki, Takeshi Kanemura, Michiko Hamanaka, Yousuke Mukai, Hiroshi Kawashima, Shin Nakahira, Rei Suzuki, Ken Nakata, Yutaka Takeda, Takeshi Kato  
*Kansairosai Hospital, Hyogo/JAPAN*

**Background:** Patients with locally advanced esophageal carcinoma with lymph node metastasis have a poor prognosis. The aim of this study was to evaluate the feasibility and effectivity of chemotherapy using fluorouracil, adriamycin, and cisplatin (FAP) in these patients excluding obvious T4 cancer.

**Methods:** Chemotherapy consisted of a continuous 5-day infusion of 5-FU (700 mg/m<sup>2</sup>/day), adriamycin (30 mg/m<sup>2</sup>/day1) and cisplatin (70 mg/m<sup>2</sup>: day1). Thirty patients with advanced squamous cell carcinoma of the esophagus were treated with 2 courses of FAP. Following chemotherapy eligible patients underwent esophagectomy. If surgery could not be performed patients received definitive radiation therapy.

**Results:** Twenty-three men and seven were enrolled (mean age 69.2 years). Partial response was achieved in 18 patients (60% including the patients with PR-in), 11 patients had stable disease, and one had progressive disease. Thirteen patients with PR and 6 with SD underwent surgery (resection rate: 63%). Other 11 patients received CRT or chemotherapy for several reasons (refuse operation: 5 patients, poor PS: 4 patients, diagnosis of other cancer and progressive disease: 1 patients). Grade 3 or 4 toxicities developed in 3 patients (10%) with leucopenia, 13 (43%) with neutrophilia, 1 (3%) with thrombocytopenia and 2 (7%) with SIADH during chemotherapy, and last two patients were discontinuation of treatment. The 1, 3 and 5-year survival

rates of these patients were 76%, 51%, 51%, respectively. Patients with good response to chemotherapy had better prognosis than those with poor response with 1 and 3-year survival rate of 89% and 56% vs. 70% and 17% ( $p = 0.018$ ).

**Discussion:** FAP for patients with locally advanced esophageal cancer with lymph node metastasis is effective and feasible and surgery may provide additional benefit for patients with good response to induction chemotherapy.

**Disclosure:** All authors have declared no conflicts of interest.

### P03.15 CHEMORADIO THERAPY FOR RECURRENT ESOPHAGEAL SQUAMOUS CELL CARCINOMA AFTER SURGICAL RESECTION

Sachiko Yamamoto<sup>1</sup>, Ryu Ishihara<sup>1</sup>, Yoshifumi Kawaguchi<sup>1</sup>, Masaaki Motoori<sup>1</sup>, Noboru Hanaoka<sup>2</sup>, Yoji Takeuchi<sup>3</sup>, Koji Higashino<sup>1</sup>, Noriya Uedo<sup>1</sup>, Masahiko Yano<sup>1</sup>, Kinji Nishiyama<sup>1</sup>, Hiroyasu Iishi<sup>1</sup>  
<sup>1</sup>Osaka Medical Center For Cancer And Cardiovascular Diseases, Osaka, Japan., <sup>2</sup>Osaka Medical Center For Cancer And Cardiovascular Diseases, Osaka/JAPAN, <sup>3</sup>Osaka Medical Center For Cancer And Cardiovascular Diseases, Osaka, Osaka/JAPAN

**Background:** Recurrence after initial treatment has large impact on the prognosis of esophageal cancer. Currently there is no standard treatment for recurrence.

**Methods:** We aimed to evaluate the efficacy of chemoradiotherapy for the treatment of recurrent esophageal cancer. A total of 27 patients with recurrence after surgical or endoscopic resection treated by chemoradiotherapy between 1999 and 2011 were included in the analysis. Twenty-three patients had lymph node recurrence, while 4 patients had recurrence around the esophagus or the gastric tube. Twenty-two of 27 patients were treated with cisplatin and fluorouracil-based chemotherapy (cisplatin at a dose of 70 mg/m<sup>2</sup> and fluorouracil at a dose of 700 mg/m<sup>2</sup>). Three patients with poor performance status were treated with low-dose docetaxel (10 mg/m<sup>2</sup> weekly) and 2 patients were treated by S-1. Concurrent radiotherapy using 10-MV X-rays was delivered at a dose of 2 Gy per day, 5 days per week, for a total dose of 60 Gy in 30 fractions.

**Results:** Complete response was achieved in 15 patients after chemoradiotherapy. Eight of 15 patients who achieved complete response are still alive without recurrence, while 2 patients died without recurrence. Five of patients who achieved complete response had another recurrence that were treated by palliative treatment. Grade 3 or 4 hematological adverse effects were seen in 10 (37%) patients. Grade 3 or 4 non-hematological adverse effects were seen in 11 (41%) patients.

**Discussion:** Chemoradiotherapy was effective in 15 of 27 patients. Chemoradiotherapy would be a good treatment option for recurrences after resection of esophageal cancer.

**Disclosure:** All authors have declared no conflicts of interest.

### P03.16 CLINICAL SIGNIFICANCE OF TRIMODALITY THERAPY FOR RESECTABLE ESOPHAGEAL SQUAMOUS CELL CARCINOMA

Yoshinori Fujiwara<sup>1</sup>, Reigetsu Yoshikawa<sup>2</sup>, Kotaro Kitani<sup>1</sup>, Masanori Tsujie<sup>1</sup>, Tsuyoshi Nakayama<sup>1</sup>, Masao Yukawa<sup>1</sup>, Norihiko Kamikonya<sup>3</sup>, Masatoshi Inoue<sup>1</sup>  
<sup>1</sup>Departemnt Of Digestive Surgery, Nara Hospital, Kinki University School Of Medicine, Ikoma-city Nara/JAPAN, <sup>2</sup>Department Of Surgery, Kanzaki Hospital, Amagasaki-city/JAPAN, <sup>3</sup>Department Of Radiology Hyogo College Of Medicine, Nishinomiya-city/JAPAN

**Background:** The prognosis of advanced esophageal cancer is poor even when the radical resection is completed. In this study, we investigated clinicopathological characteristics of the resectable esophageal squamous cell carcinoma (ESCC) patients who received the trimodality therapy of preoperative chemoradiotherapy (CRT) plus surgery, and those with surgery alone.

**Methods:** Fifty three patients who received preoperative CRT followed by surgery (Group A), and thirty two patients with surgery alone (Group B) were retrospectively studied (clinical Stage II-IV). Preoperative CRT was consisted of 40 Gy irradiation and chemotherapy (5-FU: 500 mg/m<sup>2</sup>/day, days 1-5, and cisplatin: 10-20 mg/body, days 1-5). Survivals between two groups were analyzed using Kaplan-Meier methods, with  $p < 0.05$  considered as significant.

**Results:** 1. Toxic effects of CRT: Leukocytopenia > Grade 3 was observed approximately 50% of the patients and nausea > Grade 3 was seen in 30%. 2. Clinical effect of CRT for both primary tumor and metastatic nodes was 79.2%. 3. Postoperative complications: No differences were observed between two groups in anastomotic leakage and recurrent laryngeal nerve palsy. Hospital mortality rates were 3.8% in Group A and 9.4% in Group B

( $p = 0.360$ ). 4. Survival: The 5-year overall survival rates (excluding Stage IV) of Group A and B were 58.6%, and 38.0%, respectively ( $p = 0.045$ ). Univariate analysis showed that the effect of CRT and clinical Stage were independent prognostic factors.

**Discussion:** Our results suggest that multimodality therapy for resectable Stage II/III ESCC is tolerable and contributory in better prognosis compared to surgery alone, although further examinations are necessary for elucidating radiation dose and chemotherapeutic regimen.

**Disclosure:** All authors have declared no conflicts of interest.

### P03.17 COMPARISON OF TWO NEOADJUVANT CHEMORADIO THERAPY REGIMENS IN PATIENTS WITH POTENTIALLY CURABLE ESOPHAGEAL CARCINOMA

Rachel Blom<sup>1</sup>, Meindert Sosef<sup>2</sup>, Marius Nap<sup>2</sup>, Guido Lammering<sup>3</sup>, Franchette Van Den Bermortel<sup>2</sup>, Maarten Hulshof<sup>1</sup>, Sybren Meijer<sup>1</sup>, Hanneke Wilming<sup>1</sup>, Mark Van Berge Henegouwen<sup>1</sup>  
<sup>1</sup>Academic Medical Center, Amsterdam/NETHERLANDS, <sup>2</sup>Atrium Medical Center, Heerlen/NETHERLANDS, <sup>3</sup>Maastrou, Maastricht/NETHERLANDS

**Background:** The implementation of neoadjuvant chemoradiotherapy (CRT) in patients with esophageal carcinoma (EC) has led to improved long term survival rates. Worldwide, different CRT regimens are applied. It is however unknown how these regimens relate to each other regarding toxicity and pathologic response. Therefore, the aim of this study was to determine the preferred regimen regarding toxicity of and pathologic response to CRT, and long-term survival after esophagectomy in EC patients.

**Methods:** EC patients in two different centers who underwent CRT with different CRT regimens prior to surgery were included in this study. CRT consisted of 50.4 Gy combined with two cycles of cisplatin and 5-FU (center A), or 41.4 Gy combined with five cycles of carboplatin and paclitaxel (center B). Toxicity, response to therapy and long-term survival were compared between groups.

**Results:** 165 patients underwent CRT prior to surgery between 2005-2010 (73 and 92 in center A and B respectively). 41% of patients in center A developed at least one toxicity  $\geq$  grade3 vs. 25% in center B ( $p = 0.025$ ). CRT with a cisplatin-based regimen was an independent predictor for development of toxicity  $\geq$  grade3 ( $p = 0.043$ ). There were no differences in pathologic response between both regimens ( $p = 0.904$ ). A pathologic complete remission occurred in 38% and 24% of patients treated according to regimen A and B respectively ( $p = 0.711$ ). Three-year survival was 61% (A) vs. 57% (B) ( $p = 0.725$ ).

**Discussion:** The carboplatin/paclitaxel/41.4 Gy regimen causes less toxicity compared to the cisplatin/5-FU/50.4 Gy regimen with non-significant differences in response rates and long-term survival. Our results support the carboplatin regimen to be the preferred neoadjuvant CRT regimen for EC patients.

**Disclosure:** All authors have declared no conflicts of interest.

### P03.18 NEOADJUVANT CHEMORADIO THERAPY FOLLOWED BY ESOPHAGECTOMY DOES NOT INCREASE MORBIDITY IN THE ELDERLY PATIENT

Rachel Blom, Mark Van Heijl, Jean Klinkenbijn, Jacques Bergman, Hanneke Wilming, Dick Richel, Maarten Hulshof, Hans Reitsma, Olivier Busch, Mark Van Berge Henegouwen  
Academic Medical Center, Amsterdam/NETHERLANDS

**Background:** Esophagectomy in elderly esophageal carcinoma (EC) patients is correlated with a high morbidity and even mortality. Studies on neoadjuvant chemoradiotherapy (NT) in elderly patients are scarce. The aim of this study was to evaluate the effect of advanced age in combination with (NT) in EC patients who underwent an esophagectomy.

**Methods:** Patients who underwent NT prior to esophagectomy between 1993 and 2010 were divided into two groups with the cut-off at 70 years. Toxicity of NT and postoperative morbidity were compared between groups. Primary endpoints were toxicity and complication rate.

**Results:** 213 patients underwent NT during the study period, 43 were aged  $\geq 70$  years. Toxicity of NT was comparable for younger and elderly patients (46% vs. 51%,  $p = 0.854$ ). Overall complications occurred in 62% of younger patients vs. 74% among the elderly ( $p = 0.234$ ). Cardiac complications occurred in 14% of younger patients vs. 33% in elderly patients ( $p = 0.005$ ). Higher age (OR 1.750,  $p < 0.001$ ) was an independent risk factor for development of cardiac complications.

**Discussion:** Toxicity of NT and postoperative complications are comparable for patients aged  $< 70$  and  $\geq 70$  years, with the exception of cardiac complications. Therefore, we consider NT followed by esophagectomy in elderly patients a safe treatment modality.

**Disclosure:** All authors have declared no conflicts of interest.

### P03.19 CLINICAL RELEVANCE OF INDUCTION TRIPLET CHEMOTHERAPY FOR ESOPHAGEAL CANCER INVADING ADJACENT ORGANS

Hiroshi Miyata, Makoto Yamasaki, Tsuyoshi Takahashi, Yukinori Kurokawa, Kiyokazu Nakajima, Shuji Takiguchi, Masaki Mori, Yuichiro Doki  
*Department Of Gastroenterological Surgery, Graduate School Of Medicine, Osaka University, Suita, Osaka/JAPAN*

**Background:** Chemoradiation using cisplatin and 5-fluorouracil (CF) is widely used for T4 esophageal cancer. Enhanced triplet chemotherapy based on CF may be a beneficial induction treatment, especially when surgery is considered as adjuvant treatment.

**Methods:** To investigate the clinical relevance of induction triplet chemotherapy for patients with esophageal cancer invading adjacent organs (T4), we classified 169 patients with T4 esophageal cancer without distant metastasis into those undergoing chemotherapy using CF plus adriamycin or CF plus docetaxel (79 patients) and those undergoing chemoradiotherapy using CF (90 patients). For the former group, chemoradiation was subsequently applied when surgical resection was not indicated.

**Results:** Thirty-four patients in the chemotherapy group (43.0%) received chemoradiotherapy following chemotherapy. Although the response rate tended to be higher in the chemoradiotherapy group, there was no significant difference in the response rate between the groups (63.3% vs. 68.9%). Esophageal perforation during treatment was more frequent among the chemoradiotherapy group than the chemotherapy group (16.7% vs. 6.3%,  $P = 0.0379$ ). The rate of surgical resection was consequently higher for the induction chemotherapy group compared to the chemoradiotherapy group (72.1% vs. 45.6%,  $P = 0.0005$ ). There was no significant difference in overall survival between the groups (5-year survival: 23.1% vs. 16.9%,  $P = 0.259$ ), although the chemotherapy group included more patients with distant lymph node metastasis than the chemoradiotherapy group.

**Discussion:** Induction triplet chemotherapy reduced esophageal perforation and increased the resectability of T4 esophageal cancers by combining second-line chemoradiotherapy. This strategy might increase the chance of curative resection for patients with T4 esophageal cancer.

**Disclosure:** All authors have declared no conflicts of interest.

### P03.20 ROLE OF GLASGOW PROGNOSTIC SCORE AS A PROGNOSTIC ASSESSMENT TOOL FOR ESOPHAGEAL CANCER

Yoshihito Furukita, Akira Tangoku, Masami Morimoto, Masakazu Goto, Takuya Minato, Yota Yamamoto, Yasuhiro Yuasa, Hiromichi Yamai, Hirokazu Takechi, Takahiro Yoshida, Junichi Seike  
*Department Of Thoracic, Endocrine Surgery And Oncology, Tokushima University Hospital, Kuramoto, Tokushima/JAPAN*

**Background:** Glasgow prognostic score (GPS) is known as a prognostic predictor of cancer based on the patient's nutritional status and inflammation. The purpose of this study was to investigate the role of GPS in the treatment of esophageal cancer.

**Methods:** Two hundred thirty seven patients with esophageal squamous cell carcinoma were treated in our ward between January 2004 and July 2011. GPS was evaluated by blood sample at the first visit. Patients were classified as GPS0 (CRP < 1.0 mg/dl and albumin  $\geq 3.5$  g/dl), GPS1 (CRP  $\geq 1.0$  mg/dl or albumin < 3.5 g/dl), and GPS2 (CRP  $\geq 1.0$  mg/dl and albumin < 3.5 g/dl). The relationship between GPS score and clinical course of the patients was examined.

**Results:** One hundred fifty three, 55 and 29 patients had GPS 0, 1 and 2, respectively. Increasing GPS was correlated to cancer progression significantly, and 3-year cancer-specific survivals were 63.1%, 41.1% and 24.8% of GPS0, 1, and 2, respectively ( $P < 0.01$ ). Sixty three patients had undergone primary surgery, and postoperative complications of high GPS occurred more frequently (85.7% vs 46.4%,  $P < 0.05$ ). In multivariate analysis, GPS was an independent prognostic factor (HR 13.3, 95% CI: 1.58–111.1) other than cancer stage. Among 130 patients who had received DFP chemotherapy (weekly DOC + low-dose FP) as an initial treatment, GPS was also an independent risk factor for the adverse effects greater than grade 3 (HR 2.27, 95% CI: 1.01–5.09) other than age.

**Discussion:** GPS was the important predicting factor for prognosis and greater adverse reaction to chemotherapy in the patients with esophageal cancer. Immune boosting foods like Eicosapentaenoic acid-rich ProSuro might improve cachexic state of the patients.

**Disclosure:** All authors have declared no conflicts of interest.

### P03.21 PROGNOSTIC IMPACT OF ERCC1 AND ERCC2 (XPD) POLYMORPHISMS IN ESOPHAGEAL CANCER

Ute Warnecke-Eberz<sup>1</sup>, Markus Boll<sup>1</sup>, Elfriede Bollschweiler<sup>2</sup>, Till Herbold<sup>3</sup>, Peter Grimminger<sup>3</sup>, Hakan Alakus<sup>3</sup>, Uta Drebbler<sup>4</sup>, Arnulf Hölscher<sup>3</sup>, Ralf Metzger<sup>2</sup>

<sup>1</sup>University Hospital Of Cologne, Cologne/GERMANY, <sup>2</sup>Dept. Of General-, Visceral And Cancer Surgery, University Of Cologne, Cologne/GERMANY, <sup>3</sup>Department Of General-, Visceral- And Cancer Surgery, University Of Cologne, Cologne/GERMANY, <sup>4</sup>University Hospital Cologne, Institute Of Pathology, Cologne/GERMANY

**Background:** Genetic variations within genes of nucleotide excision repair pathway (NER) may alter DNA repair capacity and susceptibilities of tumors to radiochemotherapy. We investigated the impact of single nucleotide polymorphisms (SNPs) of ERCC1 (rs3212986) and ERCC2 (rs13181, rs1799793) in esophageal cancer patients.

**Methods:** Polymorphisms were analyzed for 257 patients with locally advanced esophageal cancer, receiving CTx/RTx-treatment before R0-resection. Genotyping of paraffin-embedded tissues was performed by allele-specific real-time PCR (TaqMan 7900HT).

**Results:** Genotype frequencies of ERCC1 SNP rs3212986 were: 3.5%TT, 63.8%GG, 32.7%TG, of ERCC2 rs1799793: 43%CC, 14%TT, 43%CT, of ERCC2 rs13181: 14%GG, 40%TT, 46%GT. Distribution of both ERCC2 SNPs was different for histological type ( $p = 0.02$ ,  $p = 0.03$ ). 5-years survival rate was 48% for major responders, 20% for minor responders ( $p < 0.001$ ) depending on therapy response, ypN-category and genetic variation of SNPs ERCC2 rs13181 and ERCC1 rs3212986. Prognosis of patients carrying the GG-genotype of ERCC2 rs13181 was better (46% 5-years survival) than of GT- or TT-variants (30%),  $p = 0.042$ . Prognosis of GG-homozygote patients of ERCC1 rs3212986 was worse (31% survival rate) than of TG-heterozygotes (49%),  $p = 0.029$ . Distribution of ERCC1 polymorphism rs3212986 was different between responding and non-responding patients. 69% of the minor responders were GG-homozygotes, 28% TG-heterozygotes, ( $p = 0.037$ ). TG-genotype more frequently occurred in patients responding to the neoadjuvant therapy than in non-responders, associated with a better prognosis compared to GG-homozygotes.

**Discussion:** Distribution of gene polymorphisms ERCC1 rs3212986 and ERCC2 rs13181 may have an impact on therapy response and prognosis and might be predictive pharmacological markers to tailor treatment selection and improve outcome of esophageal cancer patients.

**Disclosure:** All authors have declared no conflicts of interest.

### P03.22 ROLE OF R0 ESOPHAGECTOMY FOLLOWING INDUCTION CHEMOTHERAPY WITH OR WITHOUT CONCURRENT RADIOTHERAPY FOR T4 ESOPHAGEAL CANCER

Hideaki Shimoji, Masayoshi Nagahama, Hiroyuki Karimata, Tatsuya Kinjo, Tadashi Nishimaki  
*Department Of Digestive And General Surgery, Graduate School Of Medicine, University Of The Ryukyus, Okinawa/JAPAN*

**Background:** T4 esophageal cancer carries poor prognosis due to its unresectability. We conducted a prospective study to investigate the efficacy of induction chemotherapy (iCT) or chemoradiotherapy (iCRT) followed by esophagectomy for patients with cT4 esophageal cancer. The aim of the study was to evaluate the results of this prospective study.

**Methods:** We classified immediately resectable esophageal cancer without extensive nodal metastases as Category 1 and initially unresectable esophageal cancer due to T4 condition as Category 2. Immediate esophagectomy  $\pm$  NAC and iCT/CRT followed by esophagectomy was assigned to patients with the Category 1 ( $n = 40$ ) and 2 ( $n = 41$ ), respectively. In the Category 1 patients, cStage I, II, III, and IV diseases were found in 12, 28, 0, and 0, respectively, whereas the respective number was 0, 0, 37, and 4, in the Category 2 patients.

**Results:** R0 resection rate (68.3%) of the Category 2 patients was significantly lower than that (97.5%) of the Category 1 patients. The overall 5-year survival (30.1%) of the Category 2 patients was significantly worse than that (64.1%) of the Category 1 patients. However, the survival rates were similar between the two groups undergoing R0 resection (53.3% vs. 65.8%). Multivariate analysis revealed R0 resection was only independent prognostic factor in the Category 2 patients.

**Discussion:** Our data indicate that the prognosis of patients with cT4 esophageal cancer improves if R0 resection can be performed after induction chemotherapy or chemoradiotherapy.

**Disclosure:** All authors have declared no conflicts of interest.

**P03.23 DIFFERENT OUTCOMES OF MULTI-MODALITY TREATMENT FOR PATIENTS WITH ESOPHAGEAL CANCER ASSOCIATED WITH UNFAVORABLE PROGNOSTIC FACTORS**

Hideaki Shimoji, Masayoshi Nagahama, Hiroyuki Karimata, Tatsuya Kinjo, Tadashi Nishimaki

*Department Of Digestive And General Surgery, Graduate School Of Medicine, University Of The Ryukyus, Okinawa/JAPAN*

**Background:** T4 esophageal cancer and esophageal cancer associated with extensive nodal metastasis carries poor prognosis even after en bloc esophagectomy. Although these tumors are treated by multi-modality treatment, efficacy of the treatment is unclear. The aim of the study was to evaluate the outcome of the treatment for such tumors in a prospective cohort study.

**Methods:** Esophageal cancer with extensive nodal metastasis and T4 esophageal cancer was classified as Category 3 (n = 24) and Category 2 (n = 41), respectively. NAC + esophagectomy and induction chemo- or chemoradiotherapy followed by esophagectomy if feasible was assigned to the Category 3 and 2 patients, respectively.

**Results:** R0 resection, mortality, and morbidity rate was 59%, 18%, and 64%; and 83%, 5%, and 71% in the Category 2 and 3 patients, respectively. These figures were significantly different between the two groups. The response rate to the preoperative treatment was 51% and 57% with pCR of 12% and 9% in the Category 2 and 3, respectively. Intention-to-treat analysis of the survival at 5 years showed equally poor in the Category 2 (30%) and 3 (20%). However, the 5-year survival rate of the Category 2 patients undergoing R0 resection was 53% which was equivalent to that (66%) of patients without extensive nodal metastasis or T4 condition after R0 resection, whereas it remained poor (24%) in the Category 3 patients after R0 resection.

**Discussion:** Good survival is expected in patients with T4 esophageal cancer if R0 resection can be performed after induction treatment. However, extensive nodal metastasis is refractory to the multi-modality treatment.

**Disclosure:** All authors have declared no conflicts of interest.

**P03.24 AN EXAMINATION OF PREOPERATIVE CHEMOTHERAPY USING DCF THERAPY FOR ADVANCED ESOPHAGEAL CANCER**

Yuji Akiyama, Yusuke Kimura, Takeshi Iwaya, Masafumi Konosu, Hisataka Fujiwara, Keisuke Koeda, Satoshi Nishizuka, Koki Otsuka, Hiroyuki Nitta, Akira Sasaki, Masaru Mizuno, Go Wakabayashi

*Iwate Medical University, Morioka/JAPAN*

**Background:** Preoperative chemotherapy using CDDP/5-FU (CF therapy) is established as the standard treatment for stage II/III esophageal cancer in Japan. However, the utility of docetaxel / CDDP / 5-FU (DCF therapy) has been anticipated in recent years. Here, we retrospectively examined the treatment outcomes of esophageal cancer patients who underwent preoperative DCF therapy.

**Methods:** Between June 2006 and September 2011, 48 patients with stage II/III esophageal squamous cell carcinoma patients who underwent preoperative chemotherapy (DCF: 13 patients, CF: 35 patients) were enrolled in this study. The regimen for DCF therapy was two courses with each course consisting of four weeks of docetaxel: 60 mg/m<sup>2</sup> (day1), cisplatin: 80 mg/m<sup>2</sup> (day1) and 5-FU: 800 mg/m<sup>2</sup> (day1-5).

**Results:** There was a trend of grade 3 adverse events such as neutropenia (DCF: 38%, CF: 20%) and febrile neutropenia (DCF: 15%, CF: 0%) occurring in the DCF group in comparison to the CF group. The disease control rate was 100% for the DCF group and 89% for the CF group. There was no increase in postoperative complications in the DCF group in comparison to the CF group. The primary tumor histological effect was determined as grade 2/3 in 8% of DCF group and 23% of CF group, however a grade 2/3 result in individual lymph node examination was obtained in 16.6% of DCF group and 8.6% of CF group. No significant difference was observed in DFS and OS between both groups.

**Discussion:** DCF therapy had an extremely high effect compared with CF therapy on lymph node metastasis.

**Disclosure:** All authors have declared no conflicts of interest.

**P03.25 PRECONDITIONING IN PATIENTS UNDERGOING ESOPHAGECTOMY: A RANDOMIZED CONTROLLED PILOT STUDY**

Hanneke Heynen<sup>1</sup>, Charlotte De Jonge<sup>1</sup>, Hans Kerckamp<sup>1</sup>, Jerome Willms<sup>1</sup>, Meindert Sosef<sup>2</sup>

<sup>1</sup>Atrium Medical Centre, Heerlen/NETHERLANDS, <sup>2</sup>Atrium Medical Center, Heerlen/NETHERLANDS

**Background:** Esophagectomy is associated with high morbidity and mortality rates. The hypothesis of preconditioning is that optimizing a patients well-being prior to surgery, with a specifically designed pathway including nutritional, physical and psychological interventions, will result in enhanced

recovery and improvement of quality of life. This pilot study examines the feasibility of such a program in patients undergoing esophagectomy after neoadjuvant chemoradiation therapy.

**Methods:** Patients were randomized either to intervention or control group. The intervention group received daily inspiratory muscle training at home, supervised physical therapy twice a week, nutritional support once a week and psychological support if necessary, in the period between chemoradiation therapy and surgery. The control group received usual care. Main outcome measures are feasibility, progression in general and inspiratory muscle strength, nutritional status and quality of life. Secondary outcome measures are postoperative outcomes.

**Results:** Twenty patients were included, 11 controls and 9 in the intervention group. There was a significant improvement in maximal inspiratory pressure (MIP) in the entire group (p: 0,05), differences between groups were not significant. The intervention group showed a trend towards less postoperative pulmonary complications, shorter duration of hospital stay and improved knee extensor strength. No changes were observed in quality of life in both groups.

**Discussion:** Preconditioning seems feasible and patients were satisfied with the program. Although the results are mostly not significant, probably due to a low number of patients, they seem promising in favour of the intervention group.

**Disclosure:** All authors have declared no conflicts of interest.

**P03.26 MICRORNAS AS PREDICTIVE MARKERS FOR RESPONSE TO CHEMORADIOTHERAPY IN OESOPHAGEAL ADENOCARCINOMA.**

Eelke Toxopeus, Kiran Mahabier, Waqar Farid, Katharina Biermann, H Tilanus, Jan Van Lanschot, Bas Wijnhoven, Luc Van Der Laan

*Erasmus Medical Center, Rotterdam/NETHERLANDS*

**Background:** Chemoradiotherapy (CRT) plus surgery is the treatment of choice for localised oesophageal cancer. Patients with tumours that respond favourably to CRT have improved survival whereas non-responders are exposed to toxicity of CRT and surgery is delayed. MicroRNAs (miRNAs) are thought to be important regulators of CRT sensitivity and represent potential biomarkers for response. The aim of this study is to investigate whether miRNAs in oesophageal adenocarcinoma can be used to distinguish between responders and non-responders to chemoradiotherapy.

**Methods:** 25 patients with oesophageal adenocarcinoma were selected from a prospective database. Response to CRT was assessed in the resection specimens according to Mandard. From 8 responders and 17 non-responders laser capture microdissection was performed on pre-treatment formalin-fixed biopsies in order to obtain tumour specific RNA. MiRNA expression was determined by microarray and quantitative RT-PCR and compared between responders and non-responders.

**Results:** Microarray analysis of tumour specific RNA of pooled samples revealed 38 most up and 40 most down regulated miRNAs (fold change > 2.0). In total, 17 miRNAs were selected for qRT-PCR analysis. MiR-200c, miR-31 and miR-215 showed a 2.8, 6.7 and 11.4 fold higher expression in non-responders while the expression level of miR-134 was 4.2 fold higher in responders.

**Discussion:** MiRNA expression in tumour differs between responders and non-responders prior to CRT. Our findings are in line with earlier reports on miR-200c, which was found to regulate chemosensitivity in other tumours.

**Disclosure:** All authors have declared no conflicts of interest.

**P03.27 EFFICACY AND SAFETY OF PREOPERATIVE DCF THERAPY FOR ADVANCED ESOPHAGEAL SQUAMOUS CELL CARCINOMA**

Yuji Shirai, Kosuke Narumiya, Masaho Ota, Kenji Kudo, Takuya Sato, Shin Yamamoto, Harushi Osugi, Masakazu Yamamoto

*Institute Of Gastroenterology, Tokyo Women'S Medical University, Tokyo/JAPAN*

**Background:** Recently, neo-adjuvant chemotherapy using docetaxel (DOC), cisplatin (CDDP), and 5-fluorouracil (5-FU) (DCF therapy) has been performed for patients with esophageal cancer.

**Methods:** To evaluate the efficacy and safety of preoperative DCF therapy for advanced esophageal squamous cell carcinoma (ESCC). Eighteen patients who received DCF therapy at our department in 2010 - 2011 were compared retrospectively with 22 patients who received CDDP plus 5-FU (FP therapy) from 2000 to 2009. All patients had resectable tumors. Regimens: DCF therapy was DOC (70 mg/ m<sup>2</sup>, Day1), CDDP (70 mg/m<sup>2</sup>, Day1), and 5-FU(700 mg/m<sup>2</sup>, Day1-5), while FP therapy was CDDP (80 mg/ m<sup>2</sup>, Day1) and 5-FU (800 mg/m<sup>2</sup>, Day1-5). Each therapy was performed basically 2 courses.

**Results:** In the DCF group, 10 patients (55.6%) only received 1 course due to toxicity or refusal to continue treatment. Six patients (33.3%) had Grade 4 neutropenia. The clinical response rate was 61.1%. Sixteen patients (88.6%) needed perioperative blood transfusion. Postoperative complications were anastomotic leakage (11.2%), pneumonia (5.5%), ileus (5.5%), and arrhythmia (5.5%). The pathological response rate was 61.1%. In the FP group, 4 patients (18.1%) only received 1 course for the above-mentioned reasons. The clinical response rate was 63.6%, and 12 patients (54.5%) required perioperative blood transfusion. Postoperative complications were leakage (4.5%) and respiratory problems (27.2%). The pathological response rate was 68.1%

**Discussion:** Conclusions: Efficacy and perioperative complications showed no significant differences between DCF therapy and FP therapy. There were no fatal complications in either group. DCF therapy is feasible, but the regimen may need modification.

**Disclosure:** All authors have declared no conflicts of interest.

### P03.28 RECURRENCE AND SURVIVAL BASED ON PATHOLOGIC RESPONSE TO NEOADJUVANT CHEMORADIOTHERAPY FOR LOCALLY ADVANCED ESOPHAGEAL SQUAMOUS CELL CARCINOMA.

Masaki Hiramatsu, Masaru Kawai, Song-woong Lee, Takaya Tokuhara, Tsukasa Nishida, Kazuhisa Uchiyama  
Osaka Medical College, Takatsuki/JAPAN

**Background:** The purpose of our study is to characterize recurrence patterns and survival based on pathologic response in patients who received neoadjuvant chemoradiotherapy (NACRT) for locally advanced esophageal squamous cell carcinoma (ESCC).

**Methods:** We performed a retrospective review of 59 ESCC patients who had received NACRT followed by esophagectomy at Osaka Medical College between 1998 and 2007. All patients were treated with 5-fluorouracil (5-FU) and cisplatin (CDDP) based chemotherapy and fractionated radiotherapy up to a dose of 30 Gy. Pathologic response, recurrence patterns, and recurrence-free survival were analyzed.

**Results:** Eleven (18.6%) showed markedly effective (pCR; Grade 3) to neoadjuvant therapy, with 24 (40.7%) and 23 (39.0%) showing moderately effective (Grade 2) or slightly effective (Grade 1), respectively. Excluding 3 patients who died in the perioperative period, recurrence developed in 30 patients (Grade 1;17/21, 81.0%; Grade 2;8/24, 33.3%; Grade 3;4/11, 36.4%). The incidence of locoregional failure decreased according to pathologic response (Grade 1;33.3%; Grade 2;13.0%; Grade 3;9.1%), though distant recurrence was observed even in responders (Grade 1;57.1%; Grade 2;26.1%; Grade 3;27.3%). Median recurrence-free survival was significantly longer for patients of Grade 2 and Grade 3 vs. Grade 1 (Grade 1;5.8 months, Grade 2;64.7 months, Grade 3;47.3 months, P = .00003), but there was no difference between Grade 2 and Grade 3.

**Discussion:** Patients who achieve good pathologic response after NACRT have reduce the risk of in-field failure, but even in pCR patients, out-of-field failure may occur, which suggests that chemotherapy with 5-FP/CDDP does not have enough power to control distant micro metastasis.

**Disclosure:** All authors have declared no conflicts of interest.

### P03.29 PATHOLOGICALLY COMPLETE RESPONSE AFTER NEOADJUVANT CHEMORADIOTHERAPY AND SURGERY FOR ESOPHAGEAL CANCER IS NO GUARANTEE FOR COMPLETE LOCOREGIONAL CONTROL

Pieter Van Hagen<sup>1</sup>, Bas Wijnhoven<sup>1</sup>, Philippe Naftoux<sup>2</sup>, Johnny Moons<sup>2</sup>, Karin Haustermans<sup>3</sup>, Gert De Hertogh<sup>4</sup>, Jan Van Lanschot<sup>1</sup>, Toni Lerut<sup>2</sup>  
<sup>1</sup>Erasmus Mc - University Medical Center Rotterdam, Rotterdam/  
NETHERLANDS, <sup>2</sup>Department Of Thoracic Surgery University Hospitals Leuven, Leuven/BELGIUM, <sup>3</sup>Department Of Radiation Oncology, University Hospitals Leuven, Leuven/BELGIUM, <sup>4</sup>Department Of Pathology, University Hospitals Leuven, Leuven/BELGIUM

**Background:** Patients with oesophageal cancer are at risk for developing locoregional recurrence after surgery. Neoadjuvant chemoradiotherapy (CRT) is believed to facilitate a radical resection and to improve locoregional control. Approximately one third of the patients have no tumour left in the resection specimen (pathologically complete response = pCR). Little is known about the pattern and timing of recurrence in patients with a pathologically complete or a non-complete response after receiving neoadjuvant chemoradiotherapy followed by resection for oesophageal cancer.

**Methods:** All patients who received neoadjuvant CRT followed by oesophagectomy in our institution between 1993 and 2009 were identified from a prospective database and allocated according to pathological tumour response.

**Results:** One hundred and eighty-eight patients were included. Median potential follow-up was 71.6 months. A pathologically complete response

(pCR) was achieved in 62/188 (33%) patients. Recurrence occurred in 24/62 (39%) patients in the pCR group vs. 70/126 (56%) patients in the non-pCR group (p = 0.03). Locoregional recurrence with or without synchronous distant metastases occurred in 8/62 (13%) patients in the pCR group vs. 31/126 (25%) in the non-pCR group (p = 0.63). Locoregional recurrences without synchronous distant metastases occurred 4/62 (7%) patients in the pCR group vs. 10/126 (8%) patients in the non-pCR group (p = 0.72). Overall 5-year survival was significantly higher in the pCR group (50%) than in the non-pCR group (36%).

**Discussion:** Of the patients with a pCR, 13% still developed a locoregional recurrence. Although a pCR is more favourable for survival, it is not synonymous with complete locoregional disease control.

**Disclosure:** All authors have declared no conflicts of interest.

### P03.30 OVEREXPRESSION AND AMPLIFICATION OF HER2 IN MATCHED PAIRS OF BIOPSIES AND RESECTION SPECIMENS OF ESOPHAGEAL ADENOCARCINOMA

Pieter Van Hagen<sup>1</sup>, Katharina Biermann<sup>1</sup>, James Boers<sup>2</sup>, Oliver Stoss<sup>3</sup>, Hein Sleddens<sup>1</sup>, Jan Van Lanschot<sup>1</sup>, Winand Dinjens<sup>1</sup>, Josef Rüschoff<sup>4</sup>, Bas Wijnhoven<sup>1</sup>

<sup>1</sup>Erasmus Mc - University Medical Center Rotterdam, Rotterdam/  
NETHERLANDS, <sup>2</sup>Isala Clinics, Zwolle/NETHERLANDS, <sup>3</sup>Targos  
Molecular Pathology GmbH, Kassell/GERMANY, <sup>4</sup>Institute Of Pathology,  
Klinikum Kassell, Kassell/GERMANY

**Background:** Human Epidermal growth factor Receptor 2 (HER2) overexpression in oesophageal adenocarcinoma facilitates neoadjuvant treatment with monoclonal antibodies targeted against the HER2 receptor. The concordance of HER2 overexpression between preoperative biopsies and the resection specimen of the primary tumour is however not known. This might lead to under- or over treatment of patients.

**Methods:** Preoperative biopsies and the matched resection specimen were collected from 75 patients who underwent oesophagectomy for oesophageal adenocarcinoma. Immunohistochemistry (IHC) staining on HER2 and dual-colour in-situ hybridisation (ISH) was performed on all biopsies and resection specimens. HER2 status was determined by following a clinical algorithm, first determining HER2 overexpression on IHC, and when doubtful (2+), determining HER2 amplification on ISH. All biopsies and resection specimens were evaluated separately by three individual pathologists.

**Results:** Due to technical failure, 71/75 (95%) cases could be analysed in the biopsies and 68/75 (91%) of the resection specimens. HER2 positivity (overexpression/amplification) was seen in 18/71 (25%) of biopsies and in 15/68 (22%) of resection specimens. One false negative and three false positive biopsies were found. In 94% of cases, HER2 status in the biopsy was concordant with HER2 status in the resection specimen. Interobserver agreement for IHC-scoring for all three observers was 83% in the biopsies and 85% in the resection specimens.

**Discussion:** HER2 positivity is seen in a substantial number of oesophageal adenocarcinomas. Although interobserver agreement is moderate in positive cases, HER2 status of a primary tumour can be reliably determined using preoperative endoscopically obtained biopsies.

**Disclosure:** All authors have declared no conflicts of interest.

### P03.31 EFFICACY OF INDUCTION CHEMORADIOTHERAPY (CRT) FOR PATIENTS WITH LOCALLY ADVANCED ESOPHAGEAL CARCINOMA.

Kazuhiro Nishikawa<sup>1</sup>, Kazuhiro Iwase<sup>1</sup>, Junji Kawada<sup>1</sup>, Tsuyoshi Takahashi<sup>2</sup>, Toyokazu Aono<sup>1</sup>, Shinichi Takeda<sup>1</sup>, Hiroshi Yoshida<sup>1</sup>, Masaya Nomura<sup>1</sup>, Hiroshi Tamagawa<sup>1</sup>, Kenichi Omori<sup>1</sup>, Chu Matsuda<sup>1</sup>, Takashi Deguchi<sup>1</sup>, Hirokazu Sawami<sup>1</sup>, Shigeyoshi Higashi<sup>1</sup>, Satoshi Umeda<sup>1</sup>, Koichi Deguchi<sup>1</sup>, Shigetoshi Shimamoto<sup>1</sup>, Shunji Endo<sup>3</sup>, Yasuhiro Tanaka<sup>1</sup>

<sup>1</sup>Osaka General Medical Center, Osaka/JAPAN, <sup>2</sup>Department Of Gastroenterological Surgery, Graduate School Of Medicine, Osaka University, Suita, Osaka/JAPAN, <sup>3</sup>Higashiosaka City General Hospital, Higashiosaka/JAPAN

**Background:** This study was designed to conduct a retrospective analysis of the efficacy of induction chemoradiotherapy (CRT) for patients with locally advanced esophageal carcinoma.

**Methods:** The 88 first-onset T4-M0-esophageal carcinoma cases were subjects. Induction CRT consisted of two cycles of CDDP / 5-FU with concurrent radiotherapy of 40 Gy. 67 cases were given the additional radiotherapy of over 10 Gy booster (CRT group). 21 cases were done the esophagectomy after induction CRT (SG group). Overall survival curves were constructed using the Kaplan-Meier method, and were compared using log-rank tests.

**Results:** Response rate of induction CRT was 81% in SG group, and CR/PR/NC/PD : 0/17/4/0, respectively. 3/4 NC cases have led to non-curative esophagectomy (R1-2). In SG group, 11/21 cases have led to R1-2, due to T factor in 7 cases and N factor in 4 cases. In R1-2 cases, 9/11 cases have preoperative N(+). Curative esophagectomy cases (R0) (MST: 30.6 M) demonstrated the better survival benefit than R1-2 cases (MST: 11.2 M). There was no difference in survival between SG group (MST: 14.7 M) and CRT group (MST: 9.4 M). But, R0-SG group (30.6 M) demonstrated the better survival benefit than CRT group (9.4 M). In SG group, tracheal injury was seen in 1 case, leakage in 2, pneumonitis in 3, pyothorax in 3 and recurrent nerve paralysis in 4 cases.

**Discussion:** Careful indication for esophagectomy is needed in NC/PD cases after induction CRT and in cases with preoperative N(+). It was suggested that induction CRT is important step in treatments for patients with locally advanced esophageal carcinoma.

**Disclosure:** All authors have declared no conflicts of interest.

### P03.32 NEOADJUVANT CHEMORADIOTHERAPY FOR PRIMARY SMALL CELL CARCINOMA OF THE ESOPHAGUS

Jun Hihara, Yoshie Kobayashi, Manabu Emi, Yoshiro Aoki, Yoichi Hamai, Yoshihiro Miyata, Morihito Okada  
*Department Of Surgical Oncology, Research Institute For Radiation Biology And Medicine, Hiroshima University, Hiroshima/JAPAN*

**Background:** Primary small cell carcinoma of the esophagus is relatively rare and known to be highly aggressive disease, and optimal treatment has not been established. We recently experienced two cases of primary esophageal small cell carcinoma successfully treated with neoadjuvant chemoradiotherapy (CRT) followed by surgery.

**Methods:** Case 1: A 59-year-old woman was diagnosed with primary esophageal small cell carcinoma by endoscopic biopsy. CT and PET-CT showed no local and distant metastasis (clinical-T3N0M0). She received 2 cycles of cisplatin (CDDP) + etoposide (VP-16) and 40 Gy of radiation concomitantly. Four weeks after the completion of CRT, she underwent transthoracic esophagectomy with three-field lymphadenectomy. Case 2: A 69-year-old man was diagnosed with primary esophageal small cell carcinoma coexistent with poorly differentiated squamous cell carcinoma by endoscopic biopsy. CT and PET-CT showed no local and distant metastasis (clinical-T3N0M0). He received 2 cycles of CDDP + VP-16 and 40 Gy of radiation concomitantly. He underwent transthoracic esophagectomy with three-field lymphadenectomy after 4 weeks.

**Results:** In both cases the postoperative courses were unevenful. Histopathological examination of the resected specimen were reported "Squamous cell carcinoma, pT3" in Case 1 and "Basaloid squamous cell carcinoma, pT2" in Case 2. No histopathological lymph node metastasis was reported in both cases.

**Discussion:** It has been reported that esophageal small cell carcinoma sometimes accompanies other types of neoplasm. In our cases, squamous cell carcinoma and basaloid squamous cell carcinoma consequently coexisted with small cell carcinoma, and interestingly the component of small cell carcinoma disappeared by neoadjuvant CRT in both cases.

**Disclosure:** All authors have declared no conflicts of interest.

### P03.33 CONCOMITANT CHEMORADIOTHERAPY USING DOCETAXEL, CISPLATIN AND 5-FU FOR THE PATIENTS WITH CERVICAL ESOPHAGEAL CANCER

Kiyoto Shiga, Katsunori Katagiri  
*Iwate Medical University, Morioka/JAPAN*

**Background:** Chemotherapy using TPF protocol has been showed efficacy in the neo-adjuvant setting for head and neck squamous cell carcinoma (SCC) so far. On the other hand, prognoses of the patients with SCC of the cervical esophagus, especially those of advanced stage patients, were poor. The aim of this study was to determine the safety and efficacy of newly developed concomitant chemoradiotherapy (CCRT) using TPF protocol in patients with SCC of the cervical esophagus.

**Methods:** Patients with previously untreated, histologically proven disease were eligible for the study. Seven patients were enrolled. There were 2 Stage IB, 1 IIA, 2 IIIB and 2 IIC diseases. Treatment consisted of radiotherapy administered once daily to a total dose of 70 Gy, concomitant with 120 hour infusions of 5-FU (600 mg/m<sup>2</sup>/day), Docetaxel (50 mg/m<sup>2</sup>, day 2) and Cisplatin (60 mg/m<sup>2</sup>, day 2) given during first and fifth weeks of radiotherapy. Median follow-up period was 57 months.

**Results:** All patients completed this protocol. Bone marrow suppression was the most common adverse event observed through this study. Grade 4 leukopenia, neutropenia and hemoglobin were observed in 3 (43%), 5 (71%) and 1 (14 %) of the patients. Complete remission of primary tumor was obtained in all patients. However, planned neck dissection was performed

in 2 patients. The disease-specific and over-all survival rates at 60 months of the patients were 83.3% and 83.3%, respectively.

**Discussion:** Our data suggested that CCRT using TPF protocol was feasible and very effective in patients with even advanced stage SCC of the cervical esophagus.

**Disclosure:** All authors have declared no conflicts of interest.

### P03.34 REAL N0 PATIENTS AND DOWNSTAGED N0 PATIENTS AFTER INDUCTION CHEMORADIOTHERAPY: ARE THEY THE SAME CLINICAL ENTITY?

Andrea Zanoni<sup>1</sup>, Giuseppe Verlato<sup>2</sup>, Simone Giacomuzzi<sup>1</sup>, Francesco Casella<sup>1</sup>, Jacopo Weindelmayer<sup>1</sup>, Mariantonietta Di Cosmo<sup>1</sup>, Giovanni De Manzoni<sup>1</sup>

<sup>1</sup>Upper G.I. Surgery Verona Hospital, Verona/ITALY, <sup>2</sup>Epidemiology And Medical Statistics, University Of Verona, Verona/ITALY

**Background:** N status is a major prognostic factor in both immediate surgery and after neoadjuvant treatments, where there could be a downstaging from cN+ to ypN0. We reviewed staging CTs of patients with ypN0 after induction chemoradiotherapy (CRT), to discover if real N0 patients (cN0 and ypN0) have the same prognosis of downstaged N0 (cN+ become ypN0).

**Methods:** A total of 24 CT scans (10 adenocarcinoma and 14 squamous cell carcinoma SCC) were reviewed by a single radiologist. All the patients had been treated in a single institution from 2005 to 2011 with the same CRT protocol and radical (R0) surgery. In this retrospective evaluation of a prospectively collected database, patients were defined as cN0 when no enlarged nodes were detectable in regional areas from cervical to celiac stations (TNM 7<sup>th</sup> ed). They were otherwise named cN+.

**Results:** Eleven patients downstaged from cN+ to ypN0, while 13 were real N0. Eight patients died, 7/8 due to recurrence. Relapse was more frequent in SCC (6/7) and in cN+ (5/7). Three-year overall survival (OS) was 68% for real N0 and 60% for downstaged N0 patients. Real N0 seemed to have better OS, but this didn't reach statistical significance (0.19).

**Discussion:** ypN0 patients have good prognosis, but it is possible that real N0 could have a better prognosis than downstaged patients after CRT. Our results may indicate a difference in prognosis, even though the small sample size didn't allow more precise statistical definition. Larger series are needed to detect possible differences in OS.

**Disclosure:** All authors have declared no conflicts of interest.

### P03.35 RELAPSE IN PATHOLOGICAL COMPLETE RESPONDERS AFTER NEOADJUVANT CHEMORADIOTHERAPY.

Francesco Casella, Andrea Zanoni, Simone Giacomuzzi, Jacopo Weindelmayer, Mariantonietta Di Cosmo, Francesca Guerini, Giovanni De Manzoni

*Upper G.I. Surgery Division University Of Verona, Verona/ITALY*

**Background:** Pathological complete responders (pCR) after neoadjuvant chemoradiotherapy (CRT) are considered long-term survivors, nonetheless a 20% relapse rate is described in this class of patients. We here analyzed our series of pCR patients, describing the characteristics of relapse.

**Methods:** From 2000 to 2011, at Upper G.I. Surgery Division-University of Verona, 213 locally advanced esophageal cancers were treated with neoadjuvant CRT (126 squamous cell carcinoma (SCC) and 87 adenocarcinoma). We analyzed our pCR rate and pCR relapse rate considering rate, pattern and timing of relapse.

**Results:** The pCR rate was 39% of entire population and 43% of operated on patients. The relapse rate of entire population was 19% (23% (12/52) among SCC and 12% (4/32) among adenocarcinoma). All the patients with adenocarcinoma where Siewert type 2 cancers, while SCC patients were 50% upper and 50% mid-lower cancers. Timing of relapse was shorter for SCC (median 14 (9-84) months) than for adenocarcinoma (median 19 (5-50) months). All adenocarcinoma patients had systemic relapse, while the pattern was systemic or mixed in 8 and locoregional in 4 cases of SCC. Liver, lung, bone and brain were interested in case of systemic disease, but only the 3 cases of brain relapse treated with surgery had long-term survival.

**Discussion:** Also pCR can relapse but the reason is still unknown. Systemic or mixed relapse is the most common type of recurrence. SCC relapses more frequently and earlier than adenocarcinoma and Siewert type 2 is at higher risk. Future investigations are needed to discover the reasons of relapse in pCR.

**Disclosure:** All authors have declared no conflicts of interest.

### P03.36 PATTERN OF RECURRENCE AND PROGNOSIS OF PATIENTS AFTER ESOPHAGECTOMY WITH EXTENDED LYMPHADENECTOMY FOR SQUAMOUS CELL CARCINOMA OF THE THORACIC ESOPHAGUS

Yasuaki Nakajima, Naoto Fujiwara, Tairo Ryotokuji, Shunsuke Ota, Swangsri Jirawat, Takuya Okada, Yutaka Miyawaki, Yutaka Tokairin, Kenro Kawada, Tetsuro Nishikage, Kagami Nagai, Tatsuyuki Kawano  
*Tokyo Medical And Dental University, Tokyo/JAPAN*

**Background:** Though, multimodality treatments, such as neo-adjuvant chemoradiotherapy or chemotherapy followed by surgery, are performed for advanced esophageal carcinomas, almost half of the patients still develop recurrence. Herein, we examine the pattern of recurrence after recurrence for the patients after the curative esophagectomy including extended lymphadenectomy without neo-adjuvant therapy. The prognostic factors after the recurrence are also investigated to search the best combination of the treatment modalities.

**Methods:** Since 1998, 659 patients underwent esophagectomy at our institute, and 260 patients were performed pathologically curative esophagectomy with three-field lymphadenectomy for squamous cell carcinoma of the thoracic esophagus without neo-adjuvant therapy. Recurrence was experienced for 115 patients, and herein, we examined the clinicopathological factors, pattern of recurrence, and clinical courses after recurrence. The area of recurrence was divided into 3 groups, that is, intra-surgical field, extra-surgical field lymph node, and distant organ.

**Results:** Among 115 patients, 77 patients showed single recurrent area, and 52 patients developed single recurrent lesion at first. Intra-surgical field recurrence was seen for 50 patients, extra-surgical field lymph node recurrence was for 54 patients, and distant organ recurrence was for 56 patients. Intra-surgical field recurrence had a significant relationship with pathological tumor depth, and extra-surgical field lymph node recurrence related with total numbers of pathological lymph node metastases. The numbers of the abdominal lymph node metastases were also related. Distant organ recurrence had no relationship with clinico-pathological factors. Adjuvant therapy, mainly performed by CDDP + 5FU chemotherapy, had no significant difference among these areas. As for the survival period after recurrence, patients treated for the recurrent tumors achieved significant good prognosis, and single area and single lesion recurrence showed significant long survival period. Recurrence including distant organ metastasis developed significant poor prognosis.

**Discussion:** It is considered difficult to try to pursue the improvement of the surgical technic and as the result, prevent recurrence and achieve long survival moreover in terms of the treatment of advanced esophageal carcinoma. Therefore, to establish the good combination of effective therapeutic modalities available will be necessary. Above all, to establish and perform effective chemotherapeutic agents and regimen that can control systemic spread of the carcinoma cells will be a pressing need.

**Disclosure:** All authors have declared no conflicts of interest.

### P03.37 INTERVAL BETWEEN NEOADJUVANT CHEMORADIATION AND SURGERY IN ESOPHAGEAL SQUAMOUS CELL CARCINOMA : DOSE SURGERY DELAY HAD IMPACT ON OUTCOME?

Yin Kai Chao  
*Chang Gung Memorial Hospital, Taoyuan/TAIWAN*

**Background:** After neoadjuvant chemoradiation(nCRT),surgery has traditionally been recommended to be performed within 8 weeks.However,surgery is often delayed for various reasons.Data from rectal cancer suggested that delaying surgery may enhance RT effect and increasing pCR.In the contrast, there are theoretical concerns that longer waiting interval after sublethal dose radiation may lead to tumor repopulation and metastases. Impact of surgery delay after nCRT in esophageal cancer remained controversial.

**Methods:** We analyzed 280 esophageal SCC patients who were treated with nCRT + surgery from 2002 to 2008.We compared patients who received surgery within 8 weeks of nCRT and those who had surgery after 8 weeks. Perioperative outcome, degree of RT response(assessed by TRG grade & pCR rate) and survival rates were compared.

**Results:** 138 patients were resected within 8 weeks and 142 patients were resected greater than 8 weeks.With similar pre/post nCRT characteristics, longer waiting interval did not result in lower perioperative complication nor higher pCR rate.Overall survival were similar in two groups.In subgroup analysis, delayed surgery had negative impact especially in patients with clinical complete response(cCR) after nCRT.In cCR group, with similar pCR rate, the TRG distribution percentage significantly upgraded following longer waiting time.(P < 0.05) Median survival also differed significantly.

**Discussion:** Surgery should be carried out within 8 weeks after nCRT, especially after cCR.

**Disclosure:** All authors have declared no conflicts of interest.

### P03.38 DETOXIFICATION AND DNA REPAIR GENE POLYMORPHISMS: ASSOCIATION WITH PATHOLOGICAL RESPONSE AND SURVIVAL IN LOCALLY ADVANCED ESOPHAGEAL CANCER (LAEC) PATIENTS RECEIVING NEOADJUVANT CHEMORADIO THERAPY WITH CISPLATIN, DOCETAXEL AND 5-FLUOROURACIL. LONG TERM RESULTS.

Milena Gusella<sup>1</sup>, Giovanni De Manzoni<sup>2</sup>, Laura Bertolaso<sup>1</sup>, Piergiorgio Paganin<sup>1</sup>, Andrea Zanon<sup>2</sup>, Laura Cestari<sup>1</sup>, Antonio Bononi<sup>1</sup>, Yasmina Modena<sup>1</sup>, Daniela Menon<sup>1</sup>, Giorgio Crepaldi<sup>1</sup>, Felice Pasini<sup>1</sup>  
<sup>1</sup>Uls 18- Rovigo, Rovigo/ITALY, <sup>2</sup>Upper G.I. Surgery Verona Hospital, Verona/ITALY

**Background:** Patients with LAEC are generally treated with preoperative chemoradiotherapy; in our series this type of combined treatment produced high long-term survival and pathological response rates. Detoxification systems and DNA repair machineries likely contribute to resistance to radio/chemotherapy; polymorphisms in genes coding for proteins and enzymes involved in these pathways may influence their biological activity and treatment outcome. This study investigated role of polymorphisms as predictive markers for response and survival.

**Methods:** 105 patients were treated with weekly docetaxel (35 mg/mq) and cisplatin (25 mg/mq), protracted venous infusion of fluorouracil (150 mg/mq/die) and concomitant radiotherapy (50 Gy) followed by surgery. Median follow-up was 5.4 years. Genomic DNA was extracted from peripheral blood lymphocytes and XPA, XPD, XRCC1, ERCC1, XRCC3, GSTP1 and MDR1 were genotyped through RFLP analysis. Associations between gene polymorphisms and pathological response and survival were analysed through Chi square test and Log rank test respectively.

**Results:** 45 patients presented complete remission and 17 patients only microfoci of residual disease; the remaining 43 patients were considered as non-responders. Polymorphisms in DNA repair genes XRCC1 and XPA were associated with response and survival with defective variants showing a better outcome. Patients with MDR1 2677GT and GSTP1 114CC genotypes showed a progression-free survival significantly shorter compared with the other genotypes (p = 0.035).

**Discussion:** Polymorphisms in DNA repair and detoxification genes may predict outcome and long-term survival in LAEC patients treated with docetaxel/cisplatin/fluorouracil-based and radiotherapy intensive neoadjuvant schedule

**Disclosure:** All authors have declared no conflicts of interest.

### P03.39 RESPONSE TO NEOADJUVANT RADIOCHEMOTHERAPY AND SUBSEQUENT PROGNOSIS DIFFERS BETWEEN HISTOLOGICAL TYPES OF ESOPHAGEAL CANCER

Elfriede Bollschweiler<sup>1</sup>, Ralf Metzger<sup>1</sup>, U Drebber<sup>2</sup>, Arnulf Höltscher<sup>1</sup>  
<sup>1</sup>Dept. Of General-, Visceral And Cancer Surgery, University Of Cologne, Cologne/GERMANY, <sup>2</sup>Institute Of Pathology, University Of Cologne, Cologne/GERMANY

**Background:** This study investigates response and prognosis after neoadjuvant chemoradiation (CTx/RTx) in patients with advanced esophageal carcinoma, according to histological type.

**Methods:** All patients with cT3 carcinoma of the esophagus receiving preoperative CTx/RTx (5-FU, cis-platin, 40 Gy) (n = 416) treated with curative-intention esophagectomy from 1997 until 2010 were included in this retrospective analysis. Therapy response after CTx/RTx was evaluated using the Cologne Regression Grade (grade I:  $\geq 50\%$  vital residual tumor cells (VRTC), grade II:  $\geq 10$  VRTC, grade III:  $< 10\%$  VRTC, grade IV: pathologic complete response. Prognosis was evaluated for adenocarcinoma (AC) and squamous cell carcinoma (SCC).

**Results:** Of 416 patients, 56% had SCC and 43% AC. Response Grading I, II, III and IV was seen in the SCC group, in 15%, 33%, 29% and 23% and in the AC group, in 25%, 35%, 25% and 15% (p = 0.011). Patients with grade IV regression had no significantly better prognoses, with a 5-year survival rate (5y-SR) of 40%, versus those with grade III, with a 5y-SR of 46% (major response). Grade II and grade I showed 5y-SR of 21% and 18% (minor response). There were significant differences between major and minor responder (p < 0.001).

Examining the prognosis according to type of histology, AC showed a 5y-SR for grade I, II, III and IV of 26%, 21%, 65% and 61% and for SCC of 17%, 20%, 22% and 39% (p < 0.01).

**Discussion:** This retrospective study concludes that in esophageal tumors, response to and prognosis after neoadjuvant CTx/RTx vary according to histological type.

**Disclosure:** All authors have declared no conflicts of interest.

### P03.40 CORRELATION OF TUMOR REGRESSION GRADING AND TUMOR STAGING WITH PROGNOSIS IN NEOADJUVANT TREATED ESOPHAGEAL CANCER

Uta Drebber<sup>1</sup>, Ralf Metzger<sup>2</sup>, Elfriede Bollschweiler<sup>2</sup>, Arnulf Hölscher<sup>3</sup>  
<sup>1</sup>University Hospital Cologne, Institute Of Pathology, Cologne/GERMANY,  
<sup>2</sup>Dept. Of General-, Visceral And Cancer Surgery, University Of Cologne, Cologne/GERMANY, <sup>3</sup>Department Of General-, Visceral- And Cancer Surgery, University Of Cologne, Cologne/GERMANY

**Background:** Neoadjuvant radiochemotherapy is standard of care in advanced esophageal cancer. Histological tumor response is an important parameter to evaluate effectiveness of neoadjuvant therapy. We compare results of tumorstaging (ypT), tumor regression grading and correlation to prognosis.

**Methods:** 416 patients with advanced esophageal cancer (cT3) were treated with neoadjuvant radiochemotherapy prior to transthoracic esophagectomy including lymphadenectomy. Depth of tumor infiltration was documented with ypT classification, histopathological regression with Cologne-regression-grading into 4 grades: I: >50% vital residual tumor cells (VRTC), grade II: 10–50% VRTC, grade III: nearly complete response with < 10% VRTC; grade IV: complete response. Grades 3 and 4 were classified as major, grades 1 and 2 as minor response. Statistical analysis compared correlation between both classification systems with survival.

**Results:** 79% of patients were male, 21% female (median age 61 years). Histopathology revealed 183 (44%) squamous cell carcinomas and 233 (56%) adenocarcinomas. Tumor staging: ypT0 n = 78 (19%), ypT1 n = 34 (8%), ypT2 n = 94 (23%), ypT3 n = 205 (49%), ypT4 n = 5 (1%). Results of regression grading: grade 1 n = 87 (21%), grade 2 n = 145 (35%), grade 3 n = 108 (26%), grade 4 n = 76 (18%). Major response: n = 184 (44%), minor response: n = 232 (56%). Correlation between tumorstage, regression grade and prognosis is shown in the table.

ypT	3 year survival
ypT0	64%
ypT1	71%
ypT2	46%
ypT3	29%
ypT4	0%
Regression grade	
I	28%
II	36%
III	56%
IV	72%

**Discussion:** Prognostic relevance of tumor regression grading is higher than of tumor staging.

**Disclosure:** All authors have declared no conflicts of interest.

### P03.41 PT0N+ AFTER INDUCTION CHEMORADIOTHERAPY: RESPONDERS OR NON-RESPONDERS?

Simone Giacomuzzi<sup>1</sup>, Andrea Zanoni<sup>2</sup>, Francesco Casella<sup>2</sup>, Jacopo Weindelmayr<sup>2</sup>, Mariantonietta Di Cosmo<sup>2</sup>, Alessia Cusimano<sup>3</sup>, Giovanni De Manzoni<sup>2</sup>

<sup>1</sup>Upper G.I. Surgery Division, University Of Verona, Verona/ITALY,

<sup>2</sup>Upper G.I. Surgery Division University Of Verona, Verona/ITALY,

<sup>3</sup>Policlinico Of Palermo, Palermo/ITALY

**Background:** Pathological complete responders (pCR or ypT0N0) are the best possible result of an induction treatment and have good prognosis. Partial responders if N0 still have acceptable survival. Few data exist for complete responders on T but N+. We investigated if ypT0N+ should be considered good responders or not responders.

**Methods:** From 2000 to 2011, at Upper G.I. Surgery Division-University of Verona, 172 locally advanced esophageal cancers were treated with neoadjuvant chemoradiotherapy (CRT) and then radical (R0) two-field surgery (98 SCC and 74 adenocarcinoma). We analyzed our dataset of patients comparing ypT0N0, minimal residual disease N0 (ypMRDN0), non-responders (huge residual cancer or ypN+) and ypT0N+ in terms of overall survival (OS).

**Results:** pCR represented 46% of the entire population followed by non-responders (30%) and ypMRDN0 (17%). ypT0N+ were only 12 cases (7%). Five-year OS was 71% for pCR, 57% for ypMRDN0 and 35% for non-responders N0, while it fell to 8% with non-responders N+. ypT0N+ had 37% 5-year OS, which was closer to non-responder N0 than to the other N+ patients, although this didn't reach statistical significance.

**Discussion:** Lack of complete response reduces survival, but ypMRDN0 and less importantly non-responders N0 have more than 30% five-year OS, compared with less than 10% for non-responders N+. ypT0N+ seems to have a survival rate closer to non-responders N0 than to non-responders N+. N status is a major prognostic determinant after CRT, nonetheless a complete

response on T with residual cancer on N may be regarded as a partial response.

**Disclosure:** All authors have declared no conflicts of interest.

### P03.42 WEIGHT LOSS ASSOCIATED WITH NEOADJUVANT CHEMORADIOTHERAPY AND ITS RELATIONSHIP TO COMPLICATIONS FOLLOWING SURGICAL RESECTION OF ESOPHAGEAL CANCER; SELECTING PATIENTS FOR NUTRITIONAL SUPPLEMENTATION

Sheraz Markar, Donald E Low

Virginia Mason Medical Center, Seattle/UNITED STATES OF AMERICA

**Background:** The aim of this study was to assess the importance of weight loss associated with neoadjuvant chemoradiotherapy, on clinical outcome following esophagectomy.

**Methods:** All patients undergoing esophagectomy following neoadjuvant chemoradiotherapy between 1991 and 2011 were included.

**Results:** 187 patients were included, BMI at the time of surgery was: 1 (0.5%) Underweight (16–18.4 kg/m<sup>2</sup>); 84 (44.9%) Normal (18.5–24.9 kg/m<sup>2</sup>); 66 (35.3%) Overweight (25–29.9 kg/m<sup>2</sup>); 36 (19.3%) Obese (≥30 kg/m<sup>2</sup>). 65.2% of patients presented with weight loss, with an average weight loss of 23 (2–120)lbs. 119 patients had data available comparing weight, before and after neoadjuvant chemoradiotherapy. 77.3% of patients lost weight during neoadjuvant chemoradiotherapy, with an average BMI decrease of 2.1 kg/m<sup>2</sup> (0.1–7.2) and percentage weight loss of 7.5% (0.5–38). Patients with a decrease in BMI of at least 2 kg/m<sup>2</sup> (35.3%) had increased postoperative complications (64.3% vs. 45.5%; P < 0.05), with similar length of ICU and hospital stay. 51.3% of patients had weight loss as a presenting feature and sustained additional weight loss during neoadjuvant therapy, this was not associated with increased complications. 32.8% of patients received nutritional supplementation (jejunostomy or stent placement), this did not affect the proportion of patients who lost weight during neoadjuvant therapy, the degree of weight loss, or surgical outcomes.

**Discussion:** Weight loss during neoadjuvant chemoradiotherapy potentially reflects changes in nutritional status independent of absolute weight, which can significantly increase complications following esophagectomy. BMI decrease of ≥2 kg/m<sup>2</sup> seems to be an important landmark, however the optimal approach to nutritional supplementation is not clear at this point.

**Disclosure:** All authors have declared no conflicts of interest.

### P03.43 NEOADJUVANT CHEMO-RADIOTHERAPY VERSUS NEOADJUVANT CHEMOTHERAPY FOR LOCALLY ADVANCED ADENOCARCINOMA OF THE LOWER THORACIC ESOPHAGUS AND GASTROESOPHAGEAL JUNCTION.

Gianpietro Zanchettin<sup>1</sup>, Angela Pecchiolan<sup>1</sup>, Luca Faccio<sup>1</sup>, Silvia Mantoan<sup>2</sup>, Matteo Cagol<sup>3</sup>, Rita Alfieri<sup>3</sup>, Carlo Castoro<sup>4</sup>, Michele Valmasoni<sup>5</sup>, Vanna Chiarion Sileni<sup>4</sup>, Luigi Corti<sup>6</sup>, Sara Galuppo<sup>4</sup>, Silvia Stragliotto<sup>7</sup>, Ermanno Ancona<sup>1</sup>, Alberto Ruol<sup>1</sup>

<sup>1</sup>University Of Padua, Department Of Surgical And Gastroenterological

Sciences, Clinica Chirurgica 1, Padova/ITALY, <sup>2</sup>Clinica Chirurgica 1,

Policlinico Padova, Padova/ITALY, <sup>3</sup>Surgical Oncology, Veneto

Oncological Institute, Padova/ITALY, <sup>4</sup>Istituto Oncologico Veneto, Padova

ITALY, <sup>5</sup>University Of Padua, Department Of General Surgery And

Organ Transplant – 1St Surgical Clinic, Padova/ITALY, <sup>6</sup>Radiotherapy,

Veneto Oncological Institute, Padova/ITALY

**Background:** The long-term survival after surgery for locally advanced esophageal and cardia adenocarcinoma (LAECA) is limited. Controversy exists about the optimum preoperative treatment for these patients, namely, neoadjuvant chemo-radiotherapy (NCTRT) or neoadjuvant chemotherapy alone (NCT).

**Methods:** The study is based on a retrospective analysis of prospectively collected data of 98 consecutive patients with LAECA, for whom subsequent resection surgery was planned, observed from 1992 to 2007: 59 patients were treated with NCTRT and 39 with NCT.

**Results:** There was no toxicity-related death; WHO grade 3–4 toxicity was similar after NCTRT and NCT. The prevalence of complete-R0 resections was comparable after NCTRT (96.3%) and NCT (93.2%). No deaths occurred after surgery. The incidence of postoperative complications was similar in the two study groups. Pathologic complete responses were significantly more frequent after NCTRT than after NCT (p 0.006). A significantly greater downstaging of the lymph node status was recorded after NCTRT (52.6%) compared to NCT (19.2%) (p 0.009). The overall survival was significantly better after NCTRT: 58% versus 29%, respectively, at 5 years; also, a trend toward better disease-free survival was recorded after NCTRT compared to NCT (p 0.17).

**Discussion:** Patients with LAECA who underwent NCTRT have a significantly better overall survival than patients treated with NCT, without any



worsening of perioperative morbidity and mortality. The better overall survival and disease-free survival of the patients treated with NCTRT can be related to the greater prevalence of pathologic complete responses and downstaging of the lymph node status obtained after NCTRT.

**Disclosure:** All authors have declared no conflicts of interest.

**P03.44 SAFETY OF EPIRUBICIN, CISPLATIN AND CAPECITABIN CHEMOTHERAPY IN RESECTABLE OESOPHAGEAL OR GASTRO-OESOPHAGEAL JUNCTION ADENOCARCINOMA OUTSIDE CLINICAL TRIALS**

Pieter Christiaan Van Der Sluis<sup>1</sup>, I Ubink<sup>1</sup>, S Van Der Horst<sup>1</sup>, J Boonstra<sup>2</sup>, E E Voest<sup>1</sup>, I H M Borel-Rinkes<sup>1</sup>, M J Wiezer<sup>2</sup>, M E I Schipper<sup>1</sup>, Peter Siersema<sup>3</sup>, M Los<sup>2</sup>, Richard Van Hillegersberg<sup>1</sup>, M P Lolkema<sup>3</sup>

<sup>1</sup>University Medical Center Utrecht, Utrecht/NETHERLANDS, <sup>2</sup>Antonius Hospital Nieuwegein, Nieuwegein/NETHERLANDS, <sup>3</sup>University Medical Center Of Utrecht, Utrecht/NETHERLANDS

**Background:** We evaluated safety and feasibility of perioperative epirubicin, cisplatin and capecitabine (ECC) chemotherapy in patients with resectable oesophageal and gastro-oesophageal junction (GOJ) adenocarcinoma in a population-based retrospective cohort study.

**Methods:** We retrospectively analysed the clinical data from 93 consecutive patients treated with perioperative ECC for resectable oesophageal or GOJ adenocarcinoma. Follow-up ranged from 1 month- 47 months since the last ECC dose. Source data verification of grade 3, 4, and 5 adverse events was performed by two independent observers using standardized criteria.

**Results:** ECC chemotherapy resulted in more than expected toxicity; however, the number of surgical procedures with curative (94%) intent, mortality and postoperative complications remained as expected. Grade 3 and 4 non-haematological adverse events in the pre-operative chemotherapy cycles mainly consisted of thromboembolic events (16.2%) and cardiac complications (7.5%). A history of cardiac disease was independently associated with the occurrence of grade 3 or higher adverse events ( $p = 0.049$ ). Binary regression analysis showed that a history of cardiac and vascular disease was independently associated with discontinuation of preoperative chemotherapy.

All 3 planned preoperative cycles were administered in 65 patients (69.9%). Postoperative adjuvant chemotherapy was initiated in 38 patients (41%) and 25 patients (27 %) completed 3 preoperative and 3 postoperative cycles. Despite the difficulties in administering the planned therapy and its toxicity, our preliminary efficacy data suggest that this treatment strategy did not affect outcome.

**Discussion:** Conclusion: The administration of 6 cycles of ECC based perioperative chemotherapy is associated with a relatively high number of adverse events in a standard oesophageal and GOJ adenocarcinoma patient population; however, this toxicity does not seem to affect the ability to surgically remove the tumor.

**Disclosure:** All authors have declared no conflicts of interest.

**P03.45 REDEFINING A RESPONSE TO NEOADJUVANT THERAPY FOR ADENOCARCINOMA OF THE OESOPHAGUS AND GASTRO-OESOPHAGEAL JUNCTION – THE IMPORTANCE OF NODAL DOWNSTAGING.**

T J Underwood<sup>1</sup>, F Noble<sup>2</sup>, Ac Bateman<sup>3</sup>, Jp Byrne<sup>1</sup>, Jj Kelly<sup>1</sup>, Is Bailey<sup>1</sup>, C Rees<sup>2</sup>, T Iveson<sup>2</sup>, Ar Bateman<sup>2</sup>

<sup>1</sup>University Hospital Southampton Nhs Foundation Trust, Department Of Surgery, Southampton/UNITED KINGDOM, <sup>2</sup>Cancer Sciences Unit, University Of Southampton Somers Cancer Research Building Southampton, Southampton/UNITED KINGDOM, <sup>3</sup>University Hospital Southampton Nhs Foundation Trust, Department Of Cellular Pathology, Southampton/UNITED KINGDOM

**Background:** Tumour regression grade (TRG) is used to measure response to induction therapy in adenocarcinoma of the oesophagus. We sought to combine TRG with lymph node downstaging to further define patients who benefit from neoadjuvant chemotherapy (NAC).

**Methods:** 218 patients with adenocarcinoma of the oesophagus or GOJ treated with surgery alone or NAC + surgery between 2005 and 2011 were reviewed. Response to NAC (TRG; Mandard) and lymph node downstaging (cN vs. pN) were assessed for an association with survival and clinic-pathological characteristics.

**Results:** 136 (62.4%) patients received NAC. 44.1% had down-staging of their nodal disease compared to only 15.9% who underwent surgery alone ( $p < 0.0001$ ). Clinical outcomes in pN0 patients after NAC were worse than in those after surgery alone, suggesting that they were truly down-staged by elimination of lymph node metastases. Patients with a significant pathological response in the primary tumour (TRG 1-2 vs. TRG 3-5) were more likely

to undergo R0 resection (97.2% vs. 75%;  $p = 0.004$ ) and to demonstrate nodal down-staging (83.3% vs. 30%;  $p < 0.0001$ ). Response to NAC was associated with significantly increased disease-free survival (TRG1-2: 5.1 years vs. TRG 3-5: 2.8 years;  $p < 0.0001$ ). Nodal downstaging conferred a significant survival advantage for those patients with a poor tumour response to NAC (TRG 3-5 + nodal down-staging: 5.5 years vs. TRG 3-5 + no nodal downstaging: 1.1 years;  $p < 0.0001$ ).

**Discussion:** A previously unidentified group of patients who appear to have a poor tumour response to NAC (TRG 3-5) may benefit substantially from combination therapy by nodal down-staging.

**Disclosure:** All authors have declared no conflicts of interest.

**POSTER SESSION P04: RE-DO SURGERY AND SALVAGE ESOPHAGECTOMY – October 16, 2012 12:30–13:30**

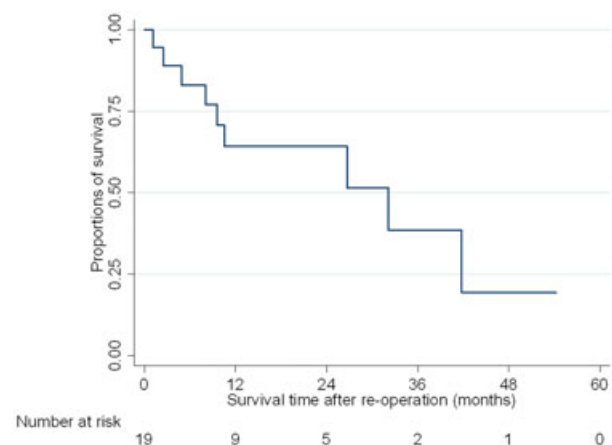
**P04.01 SURGICAL TREATMENTS FOR LOCO-REGIONAL RECURRENCE AFTER ESOPHAGECTOMY FOR ESOPHAGEAL CANCER**

Seong Yong Park, Hyun-sung Lee, Hee-jin Jang, Byungjoon Park, Moon Soo Kim, Jong Mog Lee, Zae Ill Zo  
National Cancer Center, South Korea, Goyang, GyeonggilKOREA

**Background:** After esophagectomy and esophagogastrectomy for esophageal squamous cell carcinoma, loco-regional recurrence occurs frequently. However, the proper treatment for the loco-regional recurrence has not been established.

**Methods:** We retrospectively analyzed 19 patients with loco-regional recurrence after esophagectomy and esophagogastrectomy and underwent re-do operations for loco-regional recurrence from 2001 to 2010.

**Results:** All patients were male and mean age was  $62.1 \pm 8.1$ . The median follow-up periods from initial operation was 39.2 months and from re-do operation was 10.7 months. The sites of recurrences were as follows: cervical lymph nodes only 10, cervical lymph nodes with remnant esophagus invasion 3, mediastinal lymph nodes with gastric conduit invasions 4 and mediastinal lymph nodes with thoracic aorta invasion 1. The median periods from initial operation to recurrence were 17.8 months. Re-do operations for recurrences were as following: cervical lymph node dissections 10, cervical esophagectomy with free jejunal grafts and lymph node dissection 2, partial resection of remnant esophagus with node dissection 1, partial gastrectomy with mediastinal lymph node dissection 4, and thoracic aorta patch angioplasty with mediastinal lymph node dissection 1. There were 2 (10.5%) cases of postoperative morbidities but there was no postoperative mortality. Adjuvant therapy was performed in 5 (26.3%) patients. There were one case of loco-regional recurrence and 12 (63.2%) cases of distant metastasis after re-do operation. The estimated 5-year overall survival after re-do operation was 19.3%.



**Discussion:** Various surgical treatments could be applied for loco-regional recurrence after esophagectomy and showed a good loco-regional control with acceptable operative morbidities.

**Disclosure:** All authors have declared no conflicts of interest.

#### P04.02 ENDOSCOPIC TREATMENT FOR CANCER IN THE RECONSTRUCTED GASTRIC TUBE AFTER RESECTION OF ESOPHAGEAL CANCER: A SINGLE-CENTER EXPERIENCE

Hiroaki Kasashima

*Osaka Kosei Nenkin Hospital, Osaka/JAPAN*

**Background:** Recently, cancer in the reconstructed gastric tube after esophagectomy has been increasingly reported in long-term survivors of esophageal cancer. The aim of this study is to clarify the characteristics and the outcome of 7 patients with gastric tube cancer.

**Methods:** We studied 7 patients with cancer in the reconstructed gastric tube after resection of esophageal cancer, who underwent endoscopic treatment (ESD/Endoscopic submucosal dissection) and intraoperative EMR(Endoscopic mucosal resection) in our hospital.

**Results:** We performed ESD for 11 lesions in 6 patients and intraoperative EMR for 1 lesion in 1 patient. Three of 7 patients were reconstructed via the retromediastinal route and four via the poststernal route. They all were diagnosed by follow-up endoscopy and the mean interval between esophagectomy and gastric tube cancer detection was 104 months (range 36–216 months). In terms of invasion depth of the gastric tube cancer, 9 lesions are mucosal lesions, two lesions are submucosal layer, one is muscularis propria. Histologically, 10 lesions were diagnosed as well differentiated adenocarcinoma and two as poorly differentiated adenocarcinoma. Nine lesions in 6 patients with a completely curative resection have no cancer recurrence during a median follow-up period of 34 months.

**Discussion:** Generally, patients with the gastric tube cancer have a poor prognosis. It is reported that median survival period of them is 45 months. Patients with advanced cancer in the gastric tube have only 8 months of the median survival. For patients after esophagectomy with gastric pull-up, long-term follow-up including periodic endoscopy is necessary to detect a potentially curable gastric tube cancer.

**Disclosure:** All authors have declared no conflicts of interest.

#### P04.03 STUDY OF SALVAGE SURGERY FOR ESOPHAGEAL SQUAMOUS CELL CARCINOMA AFTER DEFINITIVE CHEMORADIOTHERAPY

Masaru Kawai, Masako Hiramatsu, Song-woong Lee, Takaya Tokuhara, Eiji Nomura, Kazuhisa Uchiyama

*Osaka Medical College, Osaka/JAPAN*

**Background:** Salvage surgery is one of the important multimodality therapy for the non-effective cases of definitive chemoradiotherapy (CRT) in esophageal carcinoma. The aim of this study was to determine the efficacy of salvage surgery by investigation of operative procedure, postoperative complications and outcome.

**Methods:** Twenty patients underwent salvage surgery from January 2000 to January 2012 in our department. These cases were included 11 cases of recurrence after CR (complete response) and 9 cases of residual Non-CR. 19 cases. All patients were underwent gastric tube reconstruction under laparotomy or laparoscopy.

**Results:** Hospital mortality rate was 15% and postoperative complications was observed in 3 cases of anastomotic leakage (15%), in 4 cases of pulmonary complications (20%). 3-year survival rate was 41.1% and 5-year survival rate was 26.7%. 3-year survival rate in different tumor depth (T1/T2/T3/T4) was 75%/50%/16%/25% and cT3-cT4 were poor prognosis. In addition, 3-year survival rate of patients who were diagnosed with lymph node metastasis (cN1) before CRT was 25% compared with 63% of cN0. All 5-year survival cases were patients with recurrence after CR, however the cases of residual Non-CR were not observed 5-year survival.

**Discussion:** Salvage surgery has high incidence of complications and poor outcome, however it is possible to be long-term survival, especially in the cases of cN0 or cT1-cT2. Non-CR cases are generally high advanced cancer before CRT and poor outcome after salvage surgery, therefore it is necessary to determine carefully for the surgical procedure. Finally, it is necessary for further improvement of CRT protocols in order to good long-term results.

**Disclosure:** All authors have declared no conflicts of interest.

#### P04.04 SALVAGE ESOPHAGECTOMY AFTER DEFINITIVE CHEMORADIOTHERAPY FOR THORACIC ESOPHAGEAL CANCER

Yasuhiro Tsubosa, Hiroshi Sato, Yoshiko Aikawa, Takuji Kaburagi,

Satoshi Kamiya, Masaki Tanaka, Hiroaki Sawai

*Shizuoka Cancer Center, Shizuoka/JAPAN*

**Background:** Chemoradiotherapy (CRT) is a curative treatment option for esophageal carcinoma. However, local failure after CRT remains major problem that must be overcome to achieve cure. Although salvage surgery is now indicated for such patients, it has a higher morbidity and mortality

compared with primary surgery. The purpose of this study is evaluate salvage surgery after definitive CRT for thoracic esophageal carcinoma.

**Methods:** We examined 22 patients with thoracic esophageal carcinoma who underwent salvage surgery after definitive CRT. All patients received more than 50 Gy of radiation plus concurrent chemotherapy for curative intent. The extent of lymph node dissection in salvage surgery was reduced rather than the standard extent of lymph node dissection for first surgery without CRT.

**Results:** 19 patients underwent right transthoracic esophagectomy and 3 patients did loweresophagectomy and total gastrectomy. There was no patient who underwent standard lymph nodes dissection including both cervix and upper mediastinum. Thirteen patients (59%) were recurred after salvage surgery. Six patients were recurred within the standard extent of lymph node dissection and one patient recurred only to the site which did not undergo lymph node dissection. 3-year postoperative overall survival rate was 45.6% and 3-year postoperative disease free survival rate was 34.5%. Postoperative mortality and morbidity rate was 4.5%, 77.3%, respectively.

**Discussion:** Our salvage surgery which reduced the extent of lymph node dissection following definitive chemoradiotherapy for thoracic esophageal cancer is comparatively safe methods and equivalent in validity as compared with the past report .

**Disclosure:** All authors have declared no conflicts of interest.

#### P04.05 SALVAGE ESOPHAGECTOMY AFTER DEFINITIVE CHEMORADIOTHERAPY FOR ESOPHAGEAL SQUAMOUS CELL CARCINOMA.

Yusuke Kimura, Takeshi Iwaya, Yuji Akiyama, Masafumi Konosu, Fumitaka Endo, Hisataka Fujiwara, Keisuke Koeda, Satoshi Nishizuka, Hiroyuki Nitta, Koki Otsuka, Akira Sasaki, Masaru Mizuno, Go Wakabayashi

*Iwate Medical University, Morioka/JAPAN*

**Background:** Definitive chemoradiotherapy (CRT) is one of the treatment options for esophageal squamous cell carcinomas. CRT typically consists of high-dose (>50 Gy) external beam radiotherapy concurrent with 5-fluorouracil and cisplatin. When definitive CRT fails to achieve local control, salvage esophagectomy is the only treatment available that can offer a chance of long-term survival. However, the clinical benefit and safety of salvage esophagectomy are not clearly defined. This study retrospectively evaluated that complications and outcomes in patients who underwent salvage esophagectomy following definitive CRT at our institution.

**Methods:** We reviewed the records of 545 patients with thoracic esophageal cancer who underwent esophagectomy between 1992 and 2011, salvage esophagectomy was performed on 20 patients at our institution.

**Results:** Patient characteristics were as follows: median age, 58 years; range, 43 to 74 years; male : female, 18:2; T1/T4 = 1/19. Median fraction and total doses of external irradiation given were 2.0 Gy and 60 Gy, respectively. All patients received concurrent chemotherapy, most of the regimens of which included cisplatin and 5-fluorouracil. The median time between the start of CRT and salvage surgery was 134 days (range 37–1488). Curative resection was achieved 17 patients. Complications occurred in eight cases: Anastomotic leakage occurred in one case. MRSA and/or Pseudomonas aeruginosa pneumonia in three patients, open wound of abdominal wall in two cases, pelvic abscess and pancreatic fistula in one patient. There is no patient of died in the hospital. The median hospitalisation was 60 days (range 35–140). With a median follow-up period of 39.5 months (range 3–110) the 5-year survival calculated from the completion of salvage surgery was 61.1%.

**Discussion:** Salvage esophagectomy after definitive chemoradiotherapy is feasible for carefully selected patients.

**Disclosure:** All authors have declared no conflicts of interest.

#### P04.06 SALVAGE CERVICAL LYMPHADENECTOMY FOR PATIENTS WITH THORACIC ESOPHAGEAL SQUAMOUS CELL CARCINOMA FOLLOWING DEFINITIVE CHEMORADIOTHERAPY

Kenji Usui<sup>1</sup>, Kazuhito Yajima<sup>1</sup>, Tatsuo Kanda<sup>1</sup>, Shin-ichi Kosugi<sup>1</sup>, Kaoru Sakamoto<sup>1</sup>, Takashi Ishikawa<sup>1</sup>, Ryuta Sasamoto<sup>2</sup>, Katsuyoshi Hatakeyama<sup>1</sup>

<sup>1</sup>Division Of Digestive And General Surgery, Niigata University Graduate School Of Medical And Dental Sciences, Niigata/JAPAN, <sup>2</sup>Division Of Radiation Oncology, Niigata University Graduate School Of Medical And Dental Sciences, Niigata/JAPAN

**Background:** The aim of this study was to evaluate the surgical outcomes of salvage cervical lymphadenectomy for patients with thoracic esophageal squamous cell carcinoma (SCC) following definitive chemoradiotherapy (D-CRT).

**Methods:** Salvage cervical lymphadenectomy was performed in four patients with residual or recurrent nodes from SCC of the thoracic esophagus following D-CRT. All patients received a total of  $\geq 60$  Gy radiation with concurrent systemic intravenous chemotherapy using 5-fluorouracil and cisplatin. Cervical lymphadenectomy was defined as en bloc dissection including the cervical paraesophageal, supraclavicular, and recurrent nerve lymph nodes.

**Results:** Median intervals between the initiation of D-CRT and salvage cervical lymphadenectomy were 3, 4, 6, and 17 months, respectively. Cervical lymphadenectomy was performed unilaterally in three patients and bilaterally in one. The operating times in the four patients were 124, 150, 176, and 246 min. In two patients, viable cancer nests were identified histologically in the dissected specimens, whereas in the remaining two patients histological evaluation indicated a complete response. Although no cervical lymph node recurrence was found, three patients had lung and local recurrence, and one had abdominal lymph node recurrence. Three patients with lung recurrence died of the disease. The survival periods after cervical lymphadenectomy were 284, 284, 301, and 743 days.

**Discussion:** Salvage cervical lymphadenectomy is a safe and less invasive treatment for residual and recurrent SCC of the thoracic esophagus following D-CRT. Although local tumor control was good, all patients in the present series exhibited secondary recurrence at other sites. More cases are needed to clarify its impact on patient survival.

**Disclosure:** All authors have declared no conflicts of interest.

#### P04.07 MULTIMODALITY THERAPY FOR RECURRENT GASTRIC CARCINOMA WITH OESOPHAGEAL INVASION

*Atom Katayama, Masaru Hirata*

*Jr Tokyo General Hospital, Tokyo/JAPAN*

**Background:** Gastric carcinoma having oesophageal invasion is often aggressive and each mode of recurrence occur frequently even after potentially curative resection. At this moment the median survival of non-resectable or recurrent gastric carcinoma is reported to be around one year.

**Methods:** We report here a case of advanced gastric carcinoma with oesophageal invasion surgically resected, living 7 years and 4 months after the initial operation, or 6 years 3 months after signs of recurrence.

**Results:** The patient was a 45 year-old woman diagnosed as type 4 carcinoma with oesophageal invasion. Total gastrectomy with combined resection of the lower oesophagus, partial resection of diaphragm, splenectomy, D2 dissection, and Roux-en-Y reconstruction via abdominal transhiatal approach was performed in Nov 2004. Adjuvant chemotherapy with S-1 was performed; however, local recurrence around the lower oesophagus was manifested one year and one month after operation. The recurrence was initially treated by S-1/CDDP; however, the patient soon complained of pain and dysphagia. So resection of the lower oesophagus and Roux-en-Y reconstruction was performed in Oct 2007. Chemotherapy was performed for one year postoperatively; S-1/CDDP as first-line, and then Paclitaxel as second-line. In May 2011 the patient complained of abdominal pain and scrutiny revealed malignant colorectal stenosis as a sign of peritoneal carcinomatosis. Ileostomy was performed and chemotherapy was started with S-1/CDDP. The patient is alive under chemotherapy as of March 2012.

**Discussion:** Multimodality therapy may significantly improve survival in selected cases of advanced gastric carcinoma with oesophageal invasion.

**Disclosure:** All authors have declared no conflicts of interest.

#### P04.08 SURGICAL RESECTION FOR THE METASTATIC STERNAL TUMOR AFTER RADICAL ESOPHAGECTOMY FOR THORACIC ESOPHAGEAL CANCER

*Hitoshi Fujiwara, Atsushi Shiozaki, Shuhei Komatsu, Daisuke Ichikawa, Kazuma Okamoto, Yasutoshi Murayama, Yoshiaki Kuriu, Hisashi Ikoma, Masayoshi Nakanishi, Toshiya Ochiai, Yukihito Kokuba, Eigo Otsuji*

*Division Of Digestive Surgery, Department Of Surgery, Kyoto Prefectural University Of Medicine, Kyoto/JAPAN*

**Background:** Bone metastasis is a recurrence type frequently encountered after radical esophagectomy for esophageal cancer, and chemoradiotherapy is generally the first choice of treatment for local control. Here, we present a rare case of a metastatic bone tumor occurred at the sternum after radical esophagectomy for thoracic esophageal cancer, which was successfully treated by surgical resection.

**Methods:** A 43-year-old man with squamous cell carcinoma of the lower thoracic esophagus (cT3N2M0, Stage III) underwent radical esophagectomy with a gastric tube reconstruction through retrosternal route after preoperative chemotherapy, and adjuvant chemotherapy was performed at former institute. Then, he was introduced to our hospital to treat the solitary recurrent tumor found at the upper sternum 6 months after esophagectomy. The tumor

was treated by chemoradiotherapy, and significant tumor regression was observed on CT, but 5 months after chemoradiotherapy, the tumor grew again and deep ulcer due to the tumor invasion to the gastric tube was detected by endoscopy. On the other hand, the tumor stayed localized to the sternum and gastric tube, and no other recurrent tumors were detected on PET.

**Results:** At 7 months after chemoradiotherapy, surgical resection was performed; resection of upper parts of sternum and gastric tube with reconstruction by free jejunal interposition between cervical esophagus and lower part of gastric tube. Postoperative course was good and he was discharged at 27 postoperative days, free from cancer-related signs and symptoms observed preoperatively.

**Discussion:** In conclusion, surgical resection was successfully performed for the metastatic sternal tumor refractory to chemoradiotherapy and favorable local control was obtained.

**Disclosure:** All authors have declared no conflicts of interest.

#### P04.09 SALVAGE ESOPHAGECTOMY FOR LOCOREGIONAL FAILURE AFTER CHEMORADIO THERAPY IN PATIENTS WITH ADVANCED ESOPHAGEAL CANCER

*Changhoon Yoo, Ji-hyun Park, Sung-bae Kim, Dok Hyun Yoon, Seung Il Park, Hyeong Ryul Kim, Jong Hoon Kim, Hwoon-yong Jung, Gi-hyug Lee, Kee Don Choi, Ho June Song, Ho Young Song, Ji Hoon Shin, Kyung-ja Cho, Yong Hee Kim*

*Asan Medical Center, University Of Ulsan College Of Medicine, Seoul/KOREA*

**Background:** Definitive chemoradiotherapy is associated with high local treatment failure rates and surgical resection might be the relevant salvage therapy. However, efficacy and safety of salvage esophagectomy has not been fully elucidated. We assessed the clinical outcomes of salvage esophagectomy for locoregional failure after chemoradiotherapy.

**Methods:** Between January 2003 and November 2010, 12 patients who underwent salvage esophagectomy after chemoradiotherapy were included in this retrospective analysis.

**Results:** Median age was 62.5 years (range, 50–69) and all patients had squamous cell carcinoma. The average radiation dose was 52.7 Gy (range, 41.4–66.0), and median interval between completion of chemoradiation and surgery was 8.0 months (range, 2.0–32.9). With 29.3 months (range, 5.8–73.0) of median follow-up, overall 3-year survival rate was 58%. Patients with early pathologic stage (T1/2 and N0) showed significantly prolonged survival ( $p = 0.03$ ) compared with those with advanced pathologic stage (T3/T4 or N1). There was no in-hospital death and pulmonary complications were most common postoperative morbidity (42%) and anastomotic leakage occurs in one patient (8%).

**Discussion:** We revealed that salvage esophagectomy for locoregional failure after chemoradiotherapy was feasible with great caution, and potent therapeutic option in highly select patients with pathologically early stage, which long-term survival could be achieved.

**Disclosure:** All authors have declared no conflicts of interest.

#### P04.10 SALVAGE ESD FOR THE LOCAL RECURRENCE OF ESOPHAGEAL CANCER AFTER CHEMO RADIO THERAPY

*Akiko Takahashi, Tsuneo Oyama*

*Department Of Gastroenterology, Saku Central Hospital, Nagano/JAPAN*

**Background:** The standard treatment for the local recurrence of esophageal cancer treated by chemo radiotherapy (CRT) is salvage surgery. Endoscopic submucosal dissection (ESD) is an alternative treatment for such cases. The aim of our study is to investigate the outcome of ESD for the local recurrence of esophageal cancer after CRT.

**Methods:** 467 Squamous cell carcinoma (SCC) in 328 patients were treated by ESD from January 2000 to December 2010. Eight local recurrences after CRT (5-FU + CDDP, 60 Gy) of 6 patients were treated by salvage ESD. All patients were male, and the histology was SCC. The patients were divided into T1 and T2 groups due to the invasion depth of the primary cancer. A hook knife and glycerol injection was used for ESD.

**Results:** 1. Complication: There were no perforation and bleeding required blood transfusion. 2. R0 resection rate of T1 group ( $n = 3$ ) 100%. And, local recurrence after ESD wasn't found. They are alive for 59 months (58–151) without recurrence. 3. R0 resection rate of T2 group was 33%. The patient who was treated by R0 ESD is alive for 67 months without recurrence. One patient who had two local recurrences and treated by R1 ESD died of lymph node metastasis. The salvage ESD failed in one patient because of muscle invasion. The patient died of SCC 23 months after ESD. 4. Three-year survival rate of T1 and T2 group was 100% and 33%.

**Discussion:** In conclusions, salvage ESD is a safe and useful treatment for the local recurrence of esophageal SCC after CRT.

**Disclosure:** All authors have declared no conflicts of interest.

#### P04.11 SALVAGE ESOPHAGECTOMY AFTER DEFINITIVE CHEMORADIOTHERAPY FOR ESOPHAGEAL CANCER

Takashi Kamei, Go Miyata, Susumu Satomi  
Tohoku University Hospital, Sendai/JAPAN

**Background:** Recently, definitive chemoradiotherapy (CRT) has become a good therapeutic modality for esophageal cancer. However, the patients with residual tumor after CRT or local relapse after complete response (CR) are not rare and second-line therapy is necessary for these failed cases. Salvage esophagectomy is the only curative intent treatment, but its clinical efficacy and operative indication is unclear.

**Methods:** 78 patients were undergone salvage esophagectomy in our hospital. We divided in two subset groups into 38 residual cases(non-CR) and 40 recurrent cases(CR), and set 238 patients with planned esophagectomy in the same period. We examined clinical outcomes and operative complications in these two groups.

**Results:** 5-year survival rate was 32.1% in salvage group, patients with R0 resection had good survival rate but there is no long survivor in R2 cases. In salvage group, 5-year survival rate was 20.6% in non-CR and 47.2% in CR cases, respectively. Salvage group had many operative complications compared to planned surgery group. In particular, most residual cases had locally advanced disease before CRT and it may develop severe adhesion around primary tumor, therefore, it was difficult to identify the layer to dissection. 15 patients(19.2%) became non-curative R2 resection. Furthermore, non-CR cases had malnutrition and myelosuppression because of short periods from CRT to surgery. As a result, life-threatening complications were occurred and repeated operation was high frequency. In contrast, recurrent cases had relatively good general condition and there a few operative complications.

**Discussion:** Local relapse after CR have a good indication but the strict judgment is necessary for residual diseases.

**Disclosure:** All authors have declared no conflicts of interest.

#### P04.12 SURGICAL PROCEDURE OF SALVAGE ESOPHAGECTOMY AFTER DEFINITIVE CHEMORADIOTHERAPY FOR ESOPHAGEAL SQUAMOUS CELL CARCINOMA

Takamasa Takahashi, Nobukazu Hokamura, Hiroyasu Igaki, Yuji Tachimori

Divisions Of Esophageal Surgery, Departments Of Surgery, National Cancer Research Center Hospital, Tokyo, Japan, Tokyo/JAPAN

**Background:** Salvage esophagectomy is considered as high risk surgery. We have changed surgical procedures from extended esophagectomy to modified one since 2006 in salvage surgery.

**Methods:** Twenty one patients underwent esophagectomy with extended lymph node dissection including cervical lymph node from 2001 to 2005 (extended group) and 24 patients underwent modified esophagectomy from 2006 to 2008 (modified group). All patients underwent salvage esophagectomy through right thoracotomy. Extended lymph node dissection including cervical lymph node was omitted in modified group. Primary reconstruction route was changed from the posterior mediastinal route to the anterior mediastinal one and the gastric tube was made as small as possible to remove the irradiated area in modified group. Postoperative morbidity and mortality rate, recurrence patterns and the overall survival rate were compared between two groups.

**Results:** There was no significant difference in pathological stage (pStage 0/II/III/IV ; 1/2/14/4/0 vs 1/2/13/6/2,  $p = 0.798$ ). Postoperative morbidity and mortality rate were decreased in modified group (morbidity rate; 81.0% vs 41.7%,  $p = 0.014$ , mortality rate; 19.0% vs 4.2%,  $p = 0.083$ ). One patient in extended group died of tracheobronchial necrosis. No fatal air way complications, however, developed in modified group. Anastomotic leakage also decreased (42.9 vs 20.8%,  $p = 0.196$ ) and there was no air way fistula in modified group. There was no significant difference in recurrence patterns and the 3-year overall survival rates between two groups (Local/Distant/Unknown; 3/3/0 vs 2/5/1,  $p = 0.486$ , 3-year overall survival; 42.9% vs 48.3%,  $p = 0.986$ ).

**Discussion:** The overall survival rate remained same with mortality and morbidity decreased in modified esophagectomy.

**Disclosure:** All authors have declared no conflicts of interest.

#### P04.13 ISOLATION OF CD34+ EPITHELIAL STEM CELLS AND DECELLULARIZED OESOPHAGEAL SCAFFOLDS HOLDS POTENTIAL FOR THE PRODUCTION OF A TISSUE-ENGINEERED OESOPHAGUS

Panagiotis Maghsoudlou<sup>1</sup>, Giorgia Totonelli<sup>1</sup>, A. Tyraskis<sup>1</sup>, Fanourios Georgiades<sup>1</sup>, Bertrand Vernay<sup>2</sup>, D. Klepacka<sup>1</sup>, A. Dickinson<sup>1</sup>, Agostino Pierro<sup>1</sup>, Simon Eaton<sup>1</sup>, Paolo De Coppi<sup>1</sup>  
<sup>1</sup>Surgery Unit, Institute of Child Health & Great Ormond Street Hospital, University College London, London/UNITED KINGDOM, <sup>2</sup>Imaging Unit, Institute of Child Health, University College London, London/UNITED KINGDOM

**Background:** The combination of decellularized scaffolds and epithelial stem cells may provide a therapeutic alternative for oesophageal pathologies. The aim of this study was to: (i) compare two techniques of oesophageal decellularization, (ii) isolate oesophageal epithelial stem cells.

**Methods:** Rat oesophagi (n=10) were decellularized using two methods: (a) detergent-enzymatic treatment (DET); (b) sodium dodecyl sulphate (SDS). Samples were analysed by DNA and collagen quantification, Haematoxylin and Eosin (H&E), Masson's Trichrome, Elastin Van Gieson and DAPI. In parallel, epithelial cells and fibroblasts were isolated from mouse oesophagi. Oesophageal epithelial cells were sorted by CD34 using FACS and seeded on 3T3 cells.

**Results:** The oesophagi were decellularized following 1 cycle of DET and 6 hours of SDS respectively. Histology demonstrated loss of microarchitecture and significantly more disrupted elastic fibers in SDS- compared to DET-treated oesophagi. Regarding the epithelial component, CD34low 5.7% and CD34high 0.5% positive cells were isolated and successfully expanded in culture when seeded on feeder layers.

**Discussion:** DET is the preferred method for scaffold production and CD34+ epithelial stem cells can be successfully derived from mouse oesophagus. The combination of decellularized scaffolds and CD34+cells could advance the development of a viable tissue engineered oesophagus.

#### P04.14 GENERATION OF A NATURAL ACELLULAR MATRIX FROM PIG OESOPHAGUS FOR OESOPHAGEAL TISSUE ENGINEERING

Giorgia Totonelli, Panagiotis Maghsoudlou, Fanourios Georgiades, Massimo Garriboli, Kiron Koshy, Agostino Pierro, Simon Eaton, Paolo De Coppi

Surgery Unit, Institute of Child Health & Great Ormond Street Hospital, University College London, London/UNITED KINGDOM

**Background:** Several surgical conditions, both congenital and acquired, require oesophageal tissue replacement. In the last few years, tissue engineering has been proposed as a possible solution for the treatment of these conditions. We previously optimised the production of a natural oesophageal scaffold from rat oesophagus. In this study we aimed to develop a natural acellular matrix from pig oesophagus, as a valid framework for oesophageal replacement.

**Methods:** Pig oesophagi were decellularized with continuous infusion of detergent-enzymatic treatment (MilliQ water, 4% sodium deoxycholate (SD), DNase-I) via the oesophageal lumen. Samples were evaluated at different time points, up to 4 cycles. The efficiency of the decellularization was assessed by histological examination and DNA quantification. Moreover, we performed scanning electron microscopy (SEM) and transmission electron microscopy (TEM), to explore the ultrastructural characteristic of decellularized oesophageal matrices.

**Results:** Decellularization of the native pig oesophagus was achieved after 3 cycles of detergent-enzymatic treatment (DET). This data was confirmed by haematoxylin-eosin staining which revealed the preservation of tissue matrix architecture with absence of cellular elements, verified by the spectrophotometric measurement of DNA. SEM of the oesophageal acellular matrix showed preservation of the ultra- structural characteristics of the native tissue after the DET and confirmed the absence of cells.

**Conclusion:** Oesophageal acellular matrix can be successfully obtained by decellularization of pig oesophagus using a gentle detergent-enzymatic treatment via the oesophageal lumen. This decellularization method guarantees the preservation of the ultrastructural characteristic of the native tissue, yet the almost complete absence of cellular components is obtained. Natural oesophageal matrices obtained using this methodology could represent a valid support for oesophageal tissue regeneration.

**POSTER SESSION P05: SURGICAL TREATMENT OF  
ESOPHAGEAL CANCER – October 16, 2012 12:30–13:30**

**P05.001 IMPACT OF AGEING POPULATION ON OESOPHAGEAL  
SURGERY FOR CANCER: 20 YEAR EXPERIENCE FROM A  
SINGLE CENTRE**

Vinay Rao, Emmanuel Addae-Boateng, Ae Martin-Ucar, John Duffy  
*Nottingham City Hospital, Nottingham/UNITED KINGDOM*

**Background:** The annual incidence of oesophageal carcinoma is increasing with more elderly patients referred for surgical treatment. This study examines the impact this has had on outcomes at a single centre over 20 years.

**Methods:** Data were extracted from a prospectively maintained database of 1092 patients undergoing oesophagectomy for cancer between 1991 and 2010. 77 were 80 years of age or older. Trends in patient profiles and results were analysed in consecutive decades: 1991–2000(Period I) and 2001–2010(Period II).

**Results:** There has been an increase in the median age of patient population from 67.6 y (IQR 58–72) in period I to 69 y (IQR 62–75) in period II ( $p < 0.01$ ) due to an increase in numbers of referrals in the elderly. Patients operated on more recently had a higher incidence of Diabetes ( $p < 0.01$ ), Hypertension ( $p < 0.01$ ), pre-existent AF ( $p = 0.03$ ) and renal impairment ( $p < 0.01$ ).

Independent predictors of mortality (in all patients) were age (OR 1.066,  $p < 0.01$ ), surgery for squamous cell carcinoma (OR 1.98,  $p = 0.018$ ) and radiological anastomotic leak (OR 8.82,  $p < 0.01$ ).

The operative mortality has not changed significantly in either the whole group, (4.9% v 6%,  $p = 0.50$ ) or in the over 80's (15.6% vs. 13.3%)

However 5 year survival was 32.4% in patients <80 and 24.6% in patients over 80.

**Discussion:** The elderly have made up a significant part of our surgical practice in the last 10 years. Despite increasing co-morbidities, there has been no significant change in operative mortality and even patients over the age of 80 have a reasonable chance of 5-year survival.

**Disclosure:** All authors have declared no conflicts of interest.

**P05.002 PRONE POSITION ESOPHAGECTOMY FOR  
ESOPHAGEAL CANCER – A SAFE AND LESS STRESS  
PROCEDURE**

Yutaka Shimada, Tomoyuki Okumura, Ryota Hori, Shigeaki Sawada,  
Koshi Matsui, Isaku Yoshioka, Toru Yoshida, Takuya Nagata,  
Kazuhiro Tsukada  
*University Of Toyama, Toyama/JAPAN*

**Background:** Recent progress of esophagectomy has enabled us to introduce a safe and less stress procedure. From August 2010, we started to perform prone position esophagectomy for thoracic esophageal cancer patients. In this paper, we evaluate preliminary results of prone position esophagectomy.

**Methods:** We performed prone-position esophagectomy for 31 thoracic esophageal cancer patients from August 2010 to December 2011. Twenty five cases were performed in our university and 6 cases were performed in the local hospitals which has less than 5 esophagectomies per year. We compared the clinical outcome of prone-position esophagectomy (PE) to that of 25 thoracoscope assisted esophagectomies (TAE) in left lateral position and 3 hemiprone-position esophagectomies. (HPE) (from 2008 to 2010).

**Results:** There was no significant difference of clinicopathological characteristics of the three groups. Operation time for thoracic procedure of TAE, HPE and PE were 269, 321 and 266 minutes respectively ( $p = 0.1923$ ). Average intrathoracic bleeding volumes of TAE, HPE and PE were 325, 248 and 27 ml respectively ( $p = 0.001$ ). The number of intrathoracic lymph node dissections of TAE, HPE and PE were 19, 24 and 17 respectively. ( $p = 0.1031$ ). There was also no significant difference between the cases of university and local hospital regarding the operation time of thoracic procedure, amount of bleeding and postoperative complications in prone-position esophagectomy.

**Discussion:** Prone-position esophagectomy was performed safely and reduced the intrathoracic bleeding without increasing the complications. The procedure is easy to perform in the local hospitals which have little experience of esophagectomy.

**Disclosure:** All authors have declared no conflicts of interest.

**P05.003 COMPARISON OF THORACOSCOPIC ESOPHAGECTOMY  
PERFORMED IN THE LEFT LATERAL AND PRONE POSITIONS  
FOR ESOPHAGEAL CANCER**

Shirou Kuwabara, Norio Katayanagi, Akiko Tonouchi, Shoichi Manabe,  
Natsuru Sudo, Tomohiro Katada, Yoshinobu Ikeno, Akira Iwaya,  
Naoyuki Yokoyama, Toshiyuki Yamazaki, Tetsuya Otani  
*Niigata City General Hospital Dep.Of Digestive Surgery, Niigata/JAPAN*

**Background:** Thoracoscopic esophagectomy for esophageal cancer is performed in the left lateral position but has often been performed in the prone position recently. However, the differences in the operative field exposure and clinical outcomes of these approaches are unclear.

**Methods:** During May 2002-December 2011, 160 patients underwent thoracoscopic esophagectomy for esophageal cancer. 76 patients (2002–2008), left lateral position; 84 patients (2008–2011), prone position. We retrospectively compared the operative field exposure and clinical outcomes for these positions.

**Results:** In the left lateral position, the operative field showed blood and exudate accumulation and was often obscured by the lung; in the prone position, blood and exudate accumulated outside the operative field, which was not obscured by the lung. Subjective assessment showed that the prone position enabled a better operative field. The prone and left lateral positions did not differ significantly with regard to operative time (208 vs. 210 min). However, blood loss (20 vs. 100 ml), recurrent nerve palsy rates (25% vs. 43%), respiratory tract complication rates (6% vs. 18%), and postoperative hospital stay duration (16 vs. 24 days) were lower in the prone than the left lateral position. The total number of dissected lymph nodes was much greater in the prone than left lateral position (21 vs. 16).

**Discussion:** Thoracoscopic esophagectomy in the prone position appears to be superior to that in the left lateral position in terms of operative field exposure, blood loss, respiratory tract complications, postoperative hospital stay duration, and number of dissected lymph nodes.

**Disclosure:** All authors have declared no conflicts of interest.

**P05.004 FACTORS INFLUENCING THE ONSET OF SEVERE  
POSTOPERATIVE PNEUMONIA IN PATIENTS WITH  
ESOPHAGEAL CANCER WHO UNDERWENT ESOPHAGECTOMY**

Akinobu Furutani, Hitoshi Fujiwara, Masayuki Yoneda, Atsushi Shiozaki, Shuhei Komatsu, Daisuke Ichikawa, Kazuma Okamoto,  
Yasutoshi Murayama, Yoshiaki Kuriu, Hisashi Ikoma, Masayoshi Nakanishi, Toshiya Ochiai, Yukihito Kokuba, Eigo Otsuji  
*Division Of Digestive Surgery, Department Of Surgery, Kyoto Prefectural University Of Medicine, Kyoto/JAPAN*

**Background:** Pneumonia is one of the most common postoperative complications in patients with esophageal cancer who underwent esophagectomy. The purpose of this study was to clarify factors influencing postoperative severe pneumonia.

**Methods:** One hundred thirty-three patients with esophageal cancer who underwent esophagectomy from January 2009 to September 2010 at Kyoto Prefectural University of Medicine Hospital were subjected to this study. Clinicopathological factors were compared between the groups with and without severe pneumonia (Grade IIIb/IVa/IVb) according to Clavien-Dindo classification.

**Results:** Patients consisted of males ( $n = 106$ ) and females ( $n = 27$ ) with mean age of 64.7. Clinical stages were I, IIA, IIB, III, IVA and IVB in 25, 24, 18, 53, 4, and 9 patients. Twenty-two of 133 patients had Grade IIIb-IVa/IVb pneumonia. No significant differences were observed between the two groups in gender, tumor location, smoking history, disease stage, preoperative treatment, the extent of resection, absence/presence of cervical lymph node dissection, operative duration, and transthoracic operative duration. Significant differences were observed in age, Recurrent laryngeal nerve palsy (RLNP), BMI, Brinkman index, FEV1.0%, and the amount of bleeding.

**Discussion:** RLNP and the amount of bleeding were the strongest factors influencing the onset of postoperative severe pneumonia. Careful postoperative management for the prevention of pneumonia should be considered in patients with these factors.

**Disclosure:** All authors have declared no conflicts of interest.

**P05.005 CLINICAL OUTCOMES OF ENDOSCOPIC SUBMUCOSAL  
DISSECTION (ESD) FOR SUPERFICIAL ADENOCARCINOMA OF  
THE ESOPHAGO-GASTRIC JUNCTION (EGJ)**

Tatsuya Toyokawa<sup>1</sup>, Tomoki Inaba<sup>2</sup>, Koichi Izumikawa<sup>2</sup>, Isao Fujita<sup>1</sup>,  
Joichiro Horii<sup>1</sup>, Shigenao Ishikawa<sup>2</sup>, Jun Tomoda<sup>1</sup>  
<sup>1</sup>National Hospital Organization, Fukuyama Medical Center, Fukuyama/JAPAN, <sup>2</sup>Kagawa Prefectural Central Hospital, Takamatsu/JAPAN

**Background:** ESD is an effective procedure for the treatment of superficial gastric and esophageal tumors because it facilitates en bloc resection. This

study aimed to assess the clinical outcomes of ESD for superficial adenocarcinoma of EGJ by comparison with those of early gastric tumors in other areas in a large number of lesions.

**Methods:** This study investigated 1123 lesions treated by ESD at three institutions. The lesions were classified into two groups: EGJ (superficial adenocarcinoma of EGJ) and non-EGJ (early gastric tumors in other areas). The two groups were compared in terms of their backgrounds, underlying diseases, clinical results, complications, and prognosis.

**Results:** The EGJ and non-EGJ groups included 68 and 1055 lesions, respectively. The use of anti-platelet agents in the EGJ group was significantly high. The mean resection size in the EGJ group was significantly large. En bloc and curative resection rates were high in both the groups. However, the mean procedure time in the EGJ group was significantly long. The frequencies of perforation and delayed bleeding were not significantly different. The rates of residual diseases and recurrences in the EGJ group were significantly high (4.4% vs. 0.85%). The death rate because of other diseases in the EGJ group was significantly high (8.8% vs. 2.7%).

**Discussion:** This study demonstrated the characteristics of superficial adenocarcinoma of EGJ. Although en bloc and curative resection rates were high, the procedure time was longer and prognosis was poor in superficial adenocarcinoma of EGJ. These results could conduct more accurate procedure on ESD for superficial adenocarcinoma of EGJ.

**Disclosure:** All authors have declared no conflicts of interest.

#### P05.006 ANALYSIS OF FIVE CASES OF BASALOID CELL CARCINOMA OF THE ESOPHAGUS

Shingo Nakashima<sup>1</sup>, Hitoshi Fujiwara<sup>2</sup>, Atsushi Shiozaki<sup>1</sup>, Shuhei Komatsu<sup>1</sup>, Daisuke Ichikawa<sup>1</sup>, Kazuma Okamoto<sup>2</sup>, Yasutoshi Murayama<sup>2</sup>, Hisashi Ikoma<sup>2</sup>, Yoshiaki Kuriu<sup>2</sup>, Masayoshi Nakanishi<sup>2</sup>, Toshiya Ochiai<sup>2</sup>, Yukihito Kokuba<sup>2</sup>, Eigo Otsuji<sup>2</sup>  
<sup>1</sup>Department Of Digestive Surgery, Kyoto Prefectural University Of Medicine, Kyoto, Japan, <sup>2</sup>Department Of Digestive Surgery, Kyoto Prefectural University Of Medicine, Kyoto/JAPAN

**Background:** Basaloid cell carcinoma is a relatively rare disease and has a poor prognosis. We analyzed five cases with basaloid carcinoma of the esophagus treated with esophagectomy.

**Methods:** Five cases of basaloid carcinoma of the esophagus were treated with surgery from April 1999 to March 2009, and their clinicopathological features were analyzed.

**Results:** The mean age was 66 years old. The tumor was located in the middle thoracic, lower thoracic and abdominal esophagus in 3, 1 and 1 cases, respectively. The depth of tumor invasion was T4, T3, T1b (SM2) in 1, 3, 1 cases, respectively. The type of tumor, was type 3 and 2 in 3 and 1 cases (advanced carcinoma), and type IIC+IIa in 1 case (superficial carcinoma). Metastatic lymph nodes were detected in 2 cases of advanced carcinomas. The positive rate of lymphatic and vessel invasion in advanced carcinoma was 50% (2/4) and 100% (4/4), respectively. In superficial carcinoma, neither lymphatic nor vessel invasion was detected. All four cases of advanced carcinomas recurred and died of metastasis. The median period of disease-free survival and overall survival after the surgery was 12.5 months and 27 months. Initial recurrent lesions were lung (2 cases), liver (1 case), and para-aortic lymph node (1 case). On the other hand, a case of superficial carcinoma has been free from recurrence as of 33 months after the surgery.

**Discussion:** Although basaloid cell carcinoma has a poor prognosis in advanced stages, curative resection may contribute to better prognosis in the early stage.

**Disclosure:** All authors have declared no conflicts of interest.

#### P05.007 CLINICAL OUTCOME OF ENDOSCOPIC SUBMUCOSAL DISSECTION FOR SUPERFICIAL SQUAMOUS CELL CARCINOMA OF THE ESOPHAGUS

Toshiro Iizuka, Daisuke Kikuchi, Shu Hoteya, Mitsuru Kaise  
Toranomon Hospital, Tokyo/JAPAN

**Background:** Endoscopic submucosal dissection (ESD) was recently introduced as a treatment option for superficial squamous cell carcinoma (SCC) of the Esophagus; however, its long-term clinical outcomes have not been fully evaluated in a large number of patients. So the aim of this study is to assess the long-term outcomes of ESD for patients with superficial SCC of the Esophagus.

**Methods:** We studied 385 patients, 327 men and 58 women (mean 66 years), with 388 M1/M2, 94 M3/SM1, and 30 SM2 SCC of the Esophagus undergoing ESD between April 2005 and December 2010. Complications, en bloc resection rate, curative resection rate, local recurrence or distant metastases, and survival after ESD were evaluated.

**Results:** There were no major complications except for 7 patients with ulcer bleeding without the need for blood transfusion, 12 patients with perforation,

and 63 patients with esophageal stenosis. The rates of en bloc resection and R0 resection were 100% and 94%, respectively. The depth of invasion in 119 resections was histologically considered as M3 or deeper; these patients underwent additional Radiotherapy and/or chemotherapy (n = 48) or surgical resection (n = 20). Local and distant recurrences including locoregional lymph nodes were observed in one patient and 10 patients respectively during follow-up (median 37.4 months).

**Discussion:** Long-term outcomes after ESD are favorable. ESD may be adopted as a treatment of choice for superficial SCC of the Esophagus.

**Disclosure:** All authors have declared no conflicts of interest.

#### P05.008 THORACOSCOPIC ESOPHAGECTOMY FOR ESOPHAGEAL CANCER IN PRONE POSITION

Naoshi Kubo

Department Of Surgical Oncology, Graduate School Of Medicine, Osaka City University, Osaka/JAPAN

**Background:** Although thoracoscopic esophagectomy was generally performed in left lateral decubitus position (TEL), recently thoracoscopic esophagectomy in prone position (TEP) has attracted great attention. However there were few reports of comparing about clinical outcome and surgical stress between the two groups. Here we retrospectively compared clinical outcome and surgical stress between TEP and TEL.

**Methods:** Between 2008 and 2011, 49 patients with esophageal cancer consecutively underwent thoracoscopic esophagectomy. Forty nine patients included 28 underwent TEL and 21 underwent TEP. Between the two groups, intraoperative and postoperative parameters were compared.

**Results:** There were no differences between the two groups in patient background (age, gender, tumor stage, tumor location). Mean blood loss during thoracoscopic portion were significantly lower in the prone group than in the left decubitus group (123 ± 83 versus 268 ± 229 ml p = 0.02). The incidence of respiratory complication was significantly lower in the prone group than lateral group (4.7% versus 17.8% p < 0.05). The duration of SIRS condition was significantly shorter in TEP group than that in TEL group (1.6 ± 2.8 days versus 3.6 ± 3.5 days p < 0.05). The levels of serum C reactive protein on postoperative day 1 and 2 were significantly lower in TEP than TEL group (day 1; 5.5 ± 2.5 versus 8.9 ± 3.3 mg/dl, day 2: 8.8 ± 3.6 versus 13.8 ± 3.6 mg/dl (p = 0.01).

**Discussion:** TEP had lower rate of respiratory tract complication and less operative blood loss than those of TEL. Additionally TEP was considered to be potentially less invasive procedure than TEL.

**Disclosure:** All authors have declared no conflicts of interest.

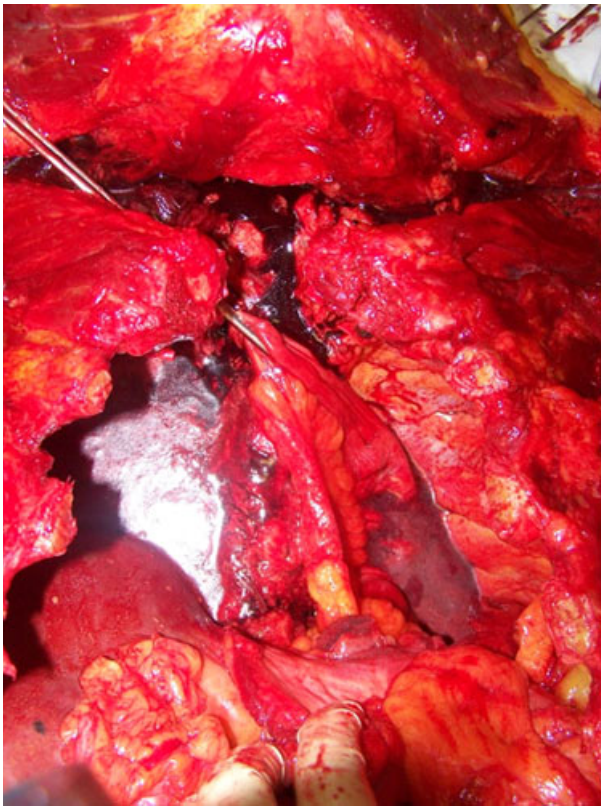
#### P05.009 PROPOSAL OF A NEW TECHNIQUE FOR ESOPHAGEAL REPLACEMENT WITH JEJUNUM.

Massimo Gugliemetti<sup>1</sup>, Michele Colledan<sup>2</sup>, Carla Cattaneo<sup>1</sup>, Antonio Poncino<sup>1</sup>, Massimiliano Casati<sup>1</sup>, Alberto Scaini<sup>1</sup>, Alberto Fontana<sup>1</sup>, Roberto Caterini<sup>1</sup>, Daniela Mattarel<sup>1</sup>, Luigi Serafini<sup>1</sup>, Alessandro Mauri<sup>1</sup>  
<sup>1</sup>Vimercate Hospital, Vimercate/ITALY, <sup>2</sup>Ospedali Riuniti, Bergamo/ITALY

**Background:** The jejunum is potentially a very good substitute of the esophagus. However it is rarely used because of the difficulties to bring it high in the thorax with a good blood supply.

**Methods:** We explored in the autopsy room the feasibility of a new surgical technique to bring the jejunum in the upper chest preserving almost completely its blood supply.

**Results:** The stomach, omentum and esophagus were removed. The right mesocolon and mesentery were mobilized along the avascular plane of Toldt's fascia, exposing the vena cava and abdominal aorta. The duodenum and pancreas were mobilized with the Kocher maneuver. Then the superior mesenteric vessels could be rotated almost 180° with the fulcrum in their origin. A jejunal loop was chosen about one meter below the ligament of Treitz, where the mesentery is usually longer. The superior mesenteric vessels were rotated to bring the root of the mesentery of the selected loop to the esophageal diaphragmatic hiatus. Only one jejunal artery was interrupted and the loop reached the top of the chest.



**Discussion:** This technique allows the jejunum to reach the upper chest without tension and with good blood supply. Moreover it can be added to the other surgical techniques which are available nowadays for esophageal substitution with jejunum, permitting to gain at least 10–15 cm in all cases. The technique could be determinant in some tumours of the esophago-gastric junction. A larger study in the autopsy room is ongoing to amend the procedure, but this preliminary simulation shows that it is valid.

**Disclosure:** All authors have declared no conflicts of interest.

#### P05.010 RISK FACTORS FOR RECURRENCE OF STRICTURE IN PATIENTS TO BE PERFORMED BALLOON DILATION FOR BENIGN ANASTOMOTIC STRICTURES AFTER ESOPHAGECTOMY AND GASTRIC TUBE RECONSTRUCTION

Hyun Jin Cho, Geun Dong Lee, Hyeong Ryul Kim, Dong Kwan Kim, Seung Il Park, Yong Hee Kim  
Asan Medical Center, University Of Ulsan College Of Medicine, Seoul KOREA

**Background:** Benign anastomotic strictures are a significant complication to decline in quality of life of patients to be performed esophagectomy with gastric tube reconstruction because of esophageal cancer. Multiple dilations are needed to resolve the strictures in a lot of case and patients suffer from recurrent dysphagia and interventions. This study was to evaluate risk factors to affect recurrence of stricture at the peri-interventional (balloon dilation) stage as well as the perioperative stage.

**Methods:** Between July 1994 and December 2009, fluoroscopically guided balloon dilation was performed in 151 patients with benign anastomotic strictures among 680 patients to be undertaken esophagectomy and gastric tube reconstruction. Stricture was defined as radiological stenosis requiring dilation of the anastomosis due to dysphagia. Risk factors for recurrence of stricture were evaluated using multivariate logistic regression analysis.

**Results:** A total of 146 patients were included for study. During follow-up after 1st balloon dilation, a recurrent stricture occurred in 80 (54.8%) patients after median time of 2.01 months (0.23 ~ 39.17 months). Earlier development of stricture after surgery ( $p = 0.001$ ) and dysphagia to soft food compared with dysphagia to solid food when 1st dilation ( $p = 0.015$ ) were independent predictor for recurrence of stricture. Antacid medication for 3 months after 1st dilation ( $p = 0.003$ ) reduced recurrence of stricture significantly.

**Discussion:** Prophylactic antacid treatment after balloon dilations help to reduce recurrent strictures. It is conceivable that early dilation of stricture before dysphagia progress will reduce recurrence of stricture.

**Disclosure:** All authors have declared no conflicts of interest.

#### P05.011 CLINICAL OUTCOMES IN PATIENTS WITH PRIMARY ESOPHAGEAL CANCER ASSOCIATED WITH OTHER PRIMARY CANCERS

Geun Dong Lee, Hyun Jin Cho, Hyeong Ryul Kim, Dong Kwan Kim, Seung Il Park, Yong Hee Kim

Asan Medical Center, University Of Ulsan College Of Medicine, Seoul KOREA

**Background:** The occurrence of multiple primary cancers (MPC) in the aerodigestive tract is well-known. The aim of this study was to evaluate the incidence and the surgical implications of MPC in patients with esophageal cancer.

**Methods:** Data were collected retrospectively on 2019 patients with esophageal cancer between 1989 and 2008.

**Results:** Among a total of 2019 patients with esophageal cancer, MPC was identified in 271 (13.4%) patients and a total of 290 non-esophageal primary cancers were identified. The three leading sites of the secondary cancer were stomach (39.7%), head/neck (18.6%) and lung (12.8%). Antecedent, synchronous and subsequent tumors were found in 81 (27.9%), 165 (56.9%) and 44 (15.2%) patients, respectively. There was no difference of survival rate between the MPC and non-MPC patients ( $p = 0.661$ ). Patients with synchronous MPC had a poorer prognosis than those with antecedent MPC or subsequent MPC or the non-MPC group ( $p = 0.025$ ,  $p < 0.001$ ,  $p = 0.031$ , respectively). Among the 622 patients who underwent surgery, mean pack-years of smoking was higher in the MPC group ( $p = 0.014$ ), as was the incidence of early-stage esophageal cancer ( $p = 0.013$ ). Patients with gastric cancer as secondary cancer had a better prognosis than those with lung cancer or head/neck as secondary cancer ( $p = 0.039$ ,  $p = 0.005$ , respectively).

**Discussion:** The incidence of MPC in patients with esophageal cancer was 13.4%. The secondary cancer is often in the stomach, head/neck and lung. Meticulous preoperative evaluation and follow up in patients with esophageal cancer is required to detect the secondary cancer. Surgical treatment of potentially curable esophageal cancer in patients with multiple primary cancers should be encouraged.

**Disclosure:** All authors have declared no conflicts of interest.

#### P05.012 ENDOCRINE CELL CARCINOMA OF THE ESOPHAGUS: 4 CASE REPORTS

Hiroyuki Tada<sup>1</sup>, Hitoshi Fujiwara<sup>2</sup>, Atsushi Shiozaki<sup>1</sup>, Shuhei Komatsu<sup>1</sup>, Daisuke Ichikawa<sup>1</sup>, Kazuma Okamoto<sup>1</sup>, Yasutoshi Murayama<sup>1</sup>, Hisashi Ikoma<sup>1</sup>, Yoshiaki Kuriu<sup>1</sup>, Masayoshi Nakanishi<sup>1</sup>, Toshiya Ochiai<sup>1</sup>, Yukihito Kokuba<sup>1</sup>, Eigo Otsuji<sup>1</sup>

<sup>1</sup>Department Of Digestive Surgery, Kyoto Prefectural University Of Medicine, Kyoto/JAPAN, <sup>2</sup>Kyoto Prefectural University Of Medicine, Kyoto/JAPAN

**Background:** Endocrine cell carcinoma of the esophagus (ECC) is very rare with extremely poor prognosis; however, it is often difficult to diagnose ECC at pretreatment examination.

**Methods:** The purpose of this study was to summarize the clinicopathological features of the patients with ECC who underwent esophagectomy at our institution.

**Results:** The patients were male ( $n = 3$ ) and female ( $n = 1$ ) with median ages of 69 (range:58–74). Preoperative diagnosis of esophageal tumor in each patient was squamous cell carcinoma, adenocarcinoma, sarcoma and unknown, respectively, and clinical stage II( $n = 2$ )and III( $n = 2$ ). All patients underwent esophagectomy with curative intent as initial treatment and post-operative pathological examination revealed that the tumors of these 4 patients were ECC and R0 resection was performed in 3 patients. Postoperatively, 1 node-negative-patient had recurrence-free survival of 4.3 years without adjuvant chemotherapy, and 3 node-positive-patients had early recurrence (multiple lymph node or organ metastases) within 3 months following esophagectomy, resulting in early death (6 months, 6months and 1.8 years) despite multimodal treatment.

**Discussion:** It has been shown that 70% patients with ECC have lymph node metastasis when diagnosed with their 1-year survival rate of 10%, and the median survival period of the patients who underwent curative resection is 6.2 months. On the other hand, accurate diagnosis based on pretreatment biopsy examination is done in 50% patients with ECC. Accordingly, surgery as primary treatment should be avoided when diagnosed with ECC.

**Disclosure:** All authors have declared no conflicts of interest.

**P05.013 SELECTED PATIENTS OVER 80 YEARS WITH ESOPHAGEAL CANCER WILL EXPERIENCE GREATER MORBIDITY BUT SIMILAR MORTALITY, SURVIVAL AND HOSPITAL STAY, WHEN COMPARED TO YOUNGER PATIENTS UNDERGOING ESOPHAGECTOMY**

Sheraz Markar, Donald E Low  
Virginia Mason Medical Center, Seattle/WA/UNITED STATES OF AMERICA

**Background:** The aim of this study is to assess short and long-term outcomes for patients  $\geq 80$  yrs undergoing esophagectomy for malignancy.

**Methods:** All patients undergoing esophagectomy for cancer between 1991 and 2011 had information prospectively entered in an IRB-approved database, patients were divided into elderly ( $\geq 80$ ) and younger ( $< 80$ ) groups.

**Results:** Of the 500 patients included, 32 (6.4%) were  $\geq 80$  years of age and showed a significantly increased presence of preoperative arrhythmia (21.9% vs. 8.1%) and peripheral vascular disease (12.5% vs. 1.5%), and reduced use of neoadjuvant chemoradiotherapy (6.3% vs. 39.7%). Analysis of operative time, estimated blood loss and length of ICU and hospital stay revealed no significant differences between the groups. Patients  $\geq 80$  had significantly increased total morbidity (68.8% vs. 44.9%), particularly arrhythmia (31.3% vs. 16.7%) and pneumonia (18.8% vs. 8.3%). Multivariate analysis showed age  $\geq 80$  to be the only factor significantly associated with increased morbidity. There were no in-hospital mortalities in patients  $\geq 80$  (0 vs. 0.4%), and there was no significant difference in overall survival between the groups ( $53.2 \pm 9.1$  vs.  $77.6 \pm 4.8$  months;  $P = 0.58$ ). Subset analysis demonstrated similar morbidity and length of hospital stay for patients between 70–79 ( $n = 132$ ) and those  $\geq 80$  years.

**Discussion:** Elderly patients undergoing esophagectomy are at greater risk of postoperative complications. However there were no significant differences in other major parameters including length of hospital stay, mortality

and survival, indicating patients  $\geq 80$  can and should be assessed by an experienced surgeon.

**Disclosure:** All authors have declared no conflicts of interest.

**P05.014 TRANSLOCATION OF MULTIDISCIPLINARY STANDARDISED CLINICAL PATHWAYS BETWEEN HOSPITALS AND HEALTH SYSTEMS IS FEASIBLE AND CAN PRODUCE IMMEDIATE IMPROVEMENT IN PERIOPERATIVE OUTCOMES FOLLOWING ESOPHAGECTOMY**

Shaun R Preston<sup>1</sup>, Sheraz Markar<sup>2</sup>, Cara R Baker<sup>1</sup>, Yuen Soon<sup>1</sup>, Sukphal Singh<sup>1</sup>, Donald E Low<sup>2</sup>

<sup>1</sup>Royal Surrey County Hospital, Guildford/UNITED KINGDOM, <sup>2</sup>Virginia Mason Medical Center, Seattle/UNITED STATES OF AMERICA

**Background:** A standardized esophagectomy clinical pathway (SECP) was established at a single institution (VMMC) in 1991. In March 2011 a multi-disciplinary team from another institution (RSC) visited VMMC and instituted a similar pathway in April 2011. The aim of this study is to determine the effect of the translocation and implementation of an established esophagectomy care pathway on postoperative outcomes within a 6-month period.

**Methods:** Four groups were included in this study: 1) 74 patients operated on at VMMC (2009–2011) 2) 12 RSC patients operated on before the introduction of SECP 3) 12 RSC patients operated on after the introduction of SECP but managed according to previous protocols 4) 12 RSC patients managed according to the SECP.

**Results:** Presenting demographics were similar in all groups with respect to BMI, medical co-morbidities, and clinical stage, however age was significantly reduced Group 4 compared to Group 2 ( $P < 0.05$ ) Statistically significant improvements were noted in complications, length of ICU and hospital stay, and first day mobilization in Group 4 (Table). Group 3 also showed a less significant improvement in length of ICU and hospital stay, and first day mobilization.

OUTCOME	VMMC (1)	Prepathway RSC (2)	Nonpathway RSC (3)	Pathway RSC (4)	P value
Pts 1 <sup>st</sup> day mobilization (%)	93	8.3	42	100	$>0.99$ (1vs4) $< 0.05$ (2vs4) 0.16 (2vs3)
Complications (%)	47.3	75	75	33.3	0.53 (1vs4) $< 0.05$ (2vs4)
ICU stay (days)	1 (0–22)	4 (2–20)	3 (2–9)	3 (1–5)	$<0.05$ (1vs4, 2vs4) 0.13 (2vs3)
Hospital stay (days)	8 (6–54)	17 (12–30)	13 (8–22)	7 (6–37)	0.25(1vs4) $< 0.05$ (2vs4) 0.09 (2vs3)

**Discussion:** This study demonstrates the potential for accelerated improvement in esophagectomy outcomes within 6 months following translocation and integration of validated standardized postoperative pathways. This process can be successful in different hospitals and different health systems.

**Disclosure:** All authors have declared no conflicts of interest.

**P05.015 OUTCOMES OF MINIMALLY INVASIVE ESOPHAGECTOMY WITH ADVANCED STAGE DISEASE**

Susanne Carpenter<sup>1</sup>, Chee-chee Stucky<sup>2</sup>, Bernadette Laxa<sup>2</sup>, Helen Ross<sup>2</sup>, Jonathan Ashman<sup>2</sup>, Kristi Harold<sup>2</sup>, Dawn Jaroszewski<sup>1</sup>

<sup>1</sup>Mayo Clinic Arizona, Phoenix/UNITED STATES OF AMERICA, <sup>2</sup>Mayo Clinic Arizona, Phoenix/AZ/UNITED STATES OF AMERICA

**Background:** Minimally invasive esophagectomy (MIE) is a common approach to early esophageal cancers but the optimal surgical approach for advanced stages is debated. This study evaluates MIE in a patient population with predominantly advanced malignancies in conjunction with trimodality therapy.

**Methods:** A retrospective review of patients undergoing MIE from November 2006 to November 2010 was performed.

**Results:** 80 consecutive patients underwent MIE. Mean age was 63 (range 26–88 years), and 64 (80%) were male. Pre-operatively, 46 (59%) patients were staged IIb or higher. Five high-risk patients staged IIa received neoadjuvant chemoradiotherapy, with a total 50 (63%) patients receiving neoadjuvant chemoradiotherapy. 24 (30%) patients underwent postoperative adjuvant therapy. 12 (17%) cervical anastomoses and 68 (83%) thoracic anastomoses were performed. 42% of cervical anastomoses versus 11% of thoracic anastomoses developed strictures requiring dilation. 2 (3%) patients with gastric conduit leak and 3 (1.5%) with anastomotic leak required reoperation. With mean 24 month follow-up (median 22, range 4–59 months), overall survival was 58%. There were 2 in-hospital mortalities, and 3 patients died within 90 days from pulmonary-related causes. At last follow-up, 7 patients were alive with evidence of disease and 42 (56%) patients were alive with no active disease. Disease-free survival for patients with pre-operative stage I disease was 80%, stage IIa 54%, IIb 50%, and III or greater 48%.

**Discussion:** MIE is an acceptable surgical therapy for advanced-stage esophageal malignancies. Neoadjuvant chemoradiotherapy did not impair the

performance of cases thoraco-laparoscopically or negatively affect clinical outcomes.

**Disclosure:** All authors have declared no conflicts of interest.

**P05.016 A STUDY OF NUTRITIONAL SCREENING PRIOR TO SURGICAL TREATMENT OF ESOPHAGEAL CANCER**

Yoshihiko Naritaka, Masano Sagawa, Takeshi Shimakawa, Noriyuki Isohata, Shinichi Asaka, Kentaro Yamaguchi, Atsuko Usuda, Minoru Murayama, Takao Katsube, Hajime Yokomizo, Shunichi Shiozawa, Kenji Ogawa  
Tokyo Women's Medical University Medical Center East, Tokyo/JAPAN

**Background:** In patients undergoing esophageal cancer surgery, perioperative nutritional management is important, so nutritional screening should be performed to understand each patient's preoperative nutritional state. This study was performed to examine the relationship between nutritional screening indices on hospital admission and postoperative clinical courses.

**Methods:** 123 patients were enrolled in the study. There were 109 males and 14 females aged between 39 and 85 years. The nutritional screening indices were: patients age 65 and over, concurrent diabetes mellitus, body mass index (BMI) of less than 18.5 or more than 25, Onodera's prognostic nutritional index of less than 40, and serum albumin level of less than 3.6 g/dl. These nutritional screening indices were evaluated for a relationship with the incidence of postoperative complications, the number of postoperative hospital stay, and long-term hospitalization.

**Results:** Incidences of postoperative complications were significantly higher in patients age 65 and over (60%) in comparison to those under 65 (39%). The number of postoperative hospital stay was also significantly greater for patients age 65 and over (36 days) than in those under 65 (25days), and in those with a BMI of less than 18.5 (37days) than in those with a BMI of more than 25 (27days). 13 (42%) patients among those with a BMI of less than 18.5 experienced long-term hospitalization, while there was 2(11%) patient among those with a BMI of more than 25, showing a significant difference between the two groups.

**Discussion:** Indices regarding patients age 65 and over, patients with a BMI of less than 18.5 and Onodera's PNI of less than 40 may be useful among



those studied for predicting incidences of postoperative complications and the possibility of long-term hospitalization.

**Disclosure:** All authors have declared no conflicts of interest.

**P05.017 INTRATUMORAL PERINEURAL INVASION IS ASSOCIATED WITH POOR SURVIVAL IN PATIENTS WITH SQUAMOUS CELL CARCINOMA OF THE ESOPHAGUS**  
*H Volkan Kara, Adamu Issaka, Barkin Eldem, Hakan Ozalper, Zeynep Bilgi, N Onur Ermerak, Emine Bas Bozkurtlar, Cigdem Ataizi Celikel, Hasan F Batirel*  
*Marmara University Faculty Of Medicine, Istanbul/TURKEY*

**Background:** Important prognostic factors in squamous cell carcinoma (SCC) of the esophagus are lymphatic metastasis and depth of tumor invasion. However, histologic features of the tumors also have a role in recurrence and prognosis. We analyzed the prognostic role of intratumoral lymphatic (LI), vascular (VI) and perineural invasion (PNI)

**Methods:** Patients who had transthoracic esophagectomy for SCC between 2005–2011 were evaluated for intratumoral LI, VI and PNI. Demographic data, the number of dissected/metastatic LNs, overall and cancer-specific survival and recurrence were analyzed. Statistical evaluation was performed using T-test and Kaplan-Meier survival analysis.

**Results:** There were 40 patients (Age  $55 \pm 10$ , 25 females). 17 were post chemoradiation (8 salvage). In-hospital mortality was 10%. Complete surgical resection was achieved in 95%. Average number of dissected lymph nodes were  $16 \pm 10$ . 13 patients had lymph node metastasis. Overall and cancer-specific median survivals were 35.5 and 64 months. There was no significant difference between patients with and without LI and VI regarding overall and cancer-specific survivals. Overall and cancer specific median survivals were significantly shorter in patients with PNI and without PNI (36 vs 20 months,  $p = 0.049$  and 64 vs 20 months,  $p = 0.002$ ). The lymph nodes dissected and the frequency of preoperative chemoradiation in patients with and without PNI were not significantly different. There were 8 patients with 7 locoregional and 1 distant recurrences

**Discussion:** Intratumoral perineural invasion is associated with poor prognosis in patients with esophageal SCC. Role of adjuvant treatment remains to be sought in this group of patients.

**Disclosure:** All authors have declared no conflicts of interest.

**P05.018 FREE JEJUNAL GRAFT REPAIR AFTER PHARYNGO-LARYNGO-ESOPHAGECTOMY: A RISK FACTOR ANALYSIS FOR THE DEVELOPMENT OF A POSTOPERATIVE EATING DISORDER**

*Ippei Yamana, Takeshi Shiraishi, Toyoo Shiroshita, Seiichiro Hoshino, Tatsuya Hashimoto, Toru Miyake, Hironari Shiwaku, Takayuki Sueta, Takashi Nakagawa, Yuichi Yamashita*  
*Fukuoka University School Of Medicine, 0180/JAPAN*

**Background:** Reconstruction with a free jejunal graft (FJG) has been widely accepted for patients undergone a pharyngo-cervical esophageal resection. These patients often suffer a variety of complications regarding their post-operative peros function. We investigated the risk factors associated with the development of an eating disorder after FJG reconstruction.

**Methods:** A retrospective analysis was conducted using a clinical chart review of 30 patients who, between the years of 1995 and 2010, consecutively underwent a reconstruction with a FJG. Mortality, morbidity, and postoperative quality of life were examined, with a special focus on eating disorders. An eating disorder was defined as the requirement for enteral nutrition for more than 14 post operation days (PODs), not including an anastomotic stricture or leakage. Potential clinical factors were extracted and the relationship of these variables to a postoperative eating disorder was examined by both univariate and multivariate analyses.

**Results:** One patient died in the hospital due to fatal postoperative bleeding from an arterial anastomosis of a FJG. Postoperative complications occurred in 14 patients (46.7%). Nine patients developed eating disorder (30%). Multivariate analysis demonstrated that induction radiation therapy (>60 Gy) was an independently significant factor for developing a postoperative eating disorder.

**Discussion:** One risk factor for the development of a postoperative eating disorder is prior radiation therapy (>60 Gy). As a result, the development of surgical or medical innovations to decrease the frequency of this morbidity after this operation may be necessary in order to maintain the quality of life of the patient.

**Disclosure:** All authors have declared no conflicts of interest.

**P05.019 ESOPHAGEAL STRIPPING CREATES A CLEAR OPERATIVE FIELD FOR LYMPH-NODE DISSECTION ALONG THE LEFT RECURRENT LARYNGEAL NERVE IN PRONE VIDEO-ASSISTED THORACOSCOPIC SURGERY OF ESOPHAGUS(VATS-E).**

*Hiroshi Makino<sup>1</sup>, Hiroshi Maruyama<sup>1</sup>, Hiroshi Yoshida<sup>1</sup>, Tsutomu Nomura<sup>2</sup>, Takeshi Matsutani<sup>2</sup>, Nobutoshi Hagiwara<sup>2</sup>, Masao Miyashita<sup>2</sup>, Tadashi Yokoyama<sup>1</sup>, Atsushi Hirakata<sup>1</sup>, Yoshimune Takao<sup>1</sup>, Hiroki Sumiyoshi<sup>1</sup>, Masahiro Hotta<sup>1</sup>, Tomohiro Hayakawa<sup>1</sup>, Eiji Uchida<sup>2</sup>*  
*<sup>1</sup>Department Of Surgery, Nippon Medical School, Tama-Nagayama Hospital, Tokyo/JAPAN, <sup>2</sup>Department Of Surgery, Nippon Medical School, Tokyo/JAPAN*

**Background:** A clear operative view of the middle and lower mediastinum for VATS-E has been obtained in prone position. However, the working space in the upper mediastinum is limited and lymph-node dissection along the left recurrent laryngeal nerve is difficult in prone position. We report to overcome the problem by our technique.

**Methods:** Forty one patients (20 in left lateral and 21 in prone position), with esophageal squamous cell carcinomas underwent VATS-E, respectively.

At first the patients are fixed at semi-prone position because both prone and left lateral positions can be set by rotating. Five ports are used at the 3<sup>rd</sup>, 5<sup>th</sup>, 7<sup>th</sup> and 9<sup>th</sup> intercostal space. The pneumothorax by maintaining CO<sub>2</sub> insufflation pressure of 6 mmHg is made. Esophagectomy and the lymph nodes around the trachea and bronchus, above the diaphragm and along the bilateral recurrent laryngeal nerves are performed in prone position. Working space at the left upper mediastinal area is limited, and the residual esophagus is stripped in the reverse direction and retracted toward the neck to obtain the space and the lymph nodes are dissected. Lymph-node dissection along the left recurrent laryngeal nerve were performed for all and 5 patients after esophageal stripping in prone VATS-E.

**Results:** 1.The rate of anastomotic leak and postoperative pneumonia were 0%(0/21) and 9.5%(2/21), respectively.

2.The rate of recurrent laryngeal nerve paralysis were 18.8%(3/16) without stripping and 20%(1/5) with stripping, respectively.

**Discussion:** Our result indicates that esophageal stripping in prone VATS-E allows for safe and straight forward lymph node dissection along the left recurrent laryngeal nerve.

**Disclosure:** All authors have declared no conflicts of interest.

**P05.020 ESOPHAGECTOMY PRECEDED BY THE LAPAROSCOPIC TRANSHIATAL APPROACH FOR ESOPHAGEAL CANCER**

*Atsushi Shiozaki, Hitoshi Fujiwara, Yasutoshi Murayama, Shuhei Komatsu, Yoshiaki Kuriu, Hisashi Ikoma, Masayoshi Nakanishi, Daisuke Ichikawa, Kazuma Okamoto, Toshiya Ochiai, Yukihiro Kokuba, Eigo Otsuji*  
*Division Of Digestive Surgery, Department Of Surgery, Kyoto Prefectural University Of Medicine, Kyoto/JAPAN*

**Background:** We started to perform esophagectomy preceded by the laparoscopic transhiatal approach (LTHA) for patients with esophageal cancer from 2009. This study was designed to determine the efficacy of esophagectomy preceded by LTHA with regard to the perioperative outcomes of esophageal cancer.

**Methods:** An abdominal wall sealing device was put in an upper abdomen, and 4 ports were inserted. After the division of gastrosplenic ligament by hand-assisted laparoscopic surgery, the esophageal hiatus was opened and carbon dioxide was introduced into the mediastinum. Abruption of the distal esophagus was performed up to the level of the tracheal bifurcation. En bloc dissection of the posterior mediastinal lymph nodes was performed. Next, cervical lymphadenectomy, reconstruction via a retrosternal route with a gastric tube, and anastomosis from a cervical approach were performed. Finally, a small thoracotomy was made to extract the thoracic esophagus and allow upper mediastinal lymphadenectomy to be performed. The treatment outcomes of 27 esophageal cancer patients who underwent LTHA-preceding esophagectomy were compared with those of 33 patients who underwent the transthoracic approach preceding esophagectomy without LTHA.

**Results:** The total operative time and the number of resected lymph nodes did not differ between the two groups. The intrathoracic operative time and operative bleeding were significantly decreased by LTHA. Postoperative respiratory complications occurred in 18.5% of patients treated with LTHA and 30.3% of those treated without it.

**Discussion:** Our surgical procedure provides a good surgical view of the posterior mediastinum, and markedly shortens the intrathoracic operative time without increasing major postoperative complications.

**Disclosure:** All authors have declared no conflicts of interest.

**P05.021 CAN A HIGH VOLUME SURGEON OPEN A NEW MINIMALLY INVASIVE ESOPHAGECTOMY PROGRAM WITHOUT COMPROMISING OUTCOMES?**

Michael Reidy<sup>1</sup>, Katie S Nason<sup>2</sup>, James Luketich<sup>2</sup>, Omar Awais<sup>1</sup>, Kurt Stahlfeld<sup>1</sup>

<sup>1</sup>University Of Pittsburgh Medical Center Mercy, Pittsburgh/PA/UNITED STATES OF AMERICA, <sup>2</sup>University Of Pittsburgh Medical Center, Pittsburgh/PA/UNITED STATES OF AMERICA

**Background:** Efforts have been made to centralize esophageal surgery to high-volume hospitals (HVH) because improved operative outcomes for complex cancer surgeries have been demonstrated. Esophagectomy continues to be performed at low volume hospitals (LVH), however, due to factors such as ethnicity, type of insurance, urgency of operation, patient co-morbidities, and geography. A high-volume surgeon with expertise in

minimally invasive esophagectomy (MIE) opened a parallel esophageal program at a LVH. We report initial outcomes (LVH versus HVH) and the following two years to determine if the results are sustainable.

**Methods:** From 2005–2008, 234 MIE were performed at the HVH. The same surgical team performed 14 MIE at the LVH in 2008. In the year prior, esophagectomy had not been performed at the LVH. From 2009–2010, 127 and 37 MIE were performed at HVH and LVH respectively. Patient demographics and outcomes between the two institutions were compared.

**Results:** Over all years, there was no significant difference in patient demographics regarding age, sex, race, pre-existing co-morbidities and operation for malignancy. Operative time, lymph node retrieval, intensive care and hospital length of stay, rate of major morbidity and mortality were similar in the initial year and maintained in the subsequent time frame (Table).

	2008 LVH n = 14	2005–2008 HVH n = 234	p	2009–2010		p
				LVH n = 37	HVH n = 127	
OR time-min (median, IQR)	436 (408–539)	505 (449–562)	0.234	525 (493–588)	613 (549–681)	<0.001
LN count (median, IQR)	22 (19–27)	22 (16–29)	0.196	27 (21–40)	25 (19–32.5)	0.197
leu LOS (median, IQR)	2 (2–5)	2 (1–3)	0.699	2 (1–4)	2 (1–3)	0.712
LOS (median, IQR)	6.5 (5–7)	7 (6–12)	0.701	7 (6–11)	7 (5–13)	0.525
major morbidities (%)	4 (28.57)	57 (24.36)	0.722	11 (29.73)	44 (34.65)	0.693
chylothorax (%)	1 (7.14)	6 (2.56)	0.315	3 (8.11)	1 (0.79)	0.036
anastomotic leak (%)	0 (0)	19 (8.14)	0.267	2 (5.41)	15 (11.81)	0.365
30 day mortality (%)	0 (0)	4 (1.71)	0.622	0 (0)	2 (1.57)	1.000

**Discussion:** With appropriate planning and support, a high volume MIE surgeon can translate his HVH outcomes to a LVH when starting a new program. These results were sustainable the following two years.

**Disclosure:** All authors have declared no conflicts of interest.

**P05.022 A STUDY OF ADDITIONAL THERAPY AFTER ENDOSCOPIC RESECTION (EMR/ESD) FOR SUPERFICIAL ESOPHAGEAL CANCER**

Kenji Kobayashi, Taro Aoki, Ko Takachi, Kiyonori Nishioka, Yukiko Tsukao, Myung Mi Cho  
Kinki Central Hospital, Itami City/JAPAN

**Background:** In Japan, superficial esophageal cancer is commonly performed by EMR/ESD for Tis(M1) and tumor invades lamina propria(M2) as curative therapy, and for tumor invades muscularis mucosae(M3) and the upper one third layer of tumor invades submucosa(SM1) as diagnostic resection. According to pathological study, when it reports that there is vessel invasion, we perform an additional treatment. We report for process of additional therapy after EMR/ESD for superficial esophageal cancer in our hospital.

**Methods:** Out of 57 cases, were performed 24EMR cases and 33 ESD cases from 1997 through 2011. Depends on preoperative clinical diagnosis, EMR/ESD is performed for M1,2 as absolute therapy, for M3 and SM1 as relative therapy, and for beyond SM2 as palliative therapy.

**Results:** According to histological classification for 57 SCC cases, 23cases were M1, 20cases were M2, 5cases were M3, 3cases were SM1, and 6cases were beyond SM2. For M1-3, only one case was confirmed vessel invasion. Thus, we additionally administered chemotherapy (FP) for this case, and there was no recurrence. all of three cases for SM1 were confirmed vessel invasion, therefore, we also performed additional radiation and/or chemotherapy.

**Discussion:** For pathological finding of M3 and SM1 cases that obtained by EMR/ESD, if vessel invasion is negative, there is no need for additional therapy. However, if vessel invasion is positive, we recommend additional radiation and/or chemotherapy after EMR/ESD.

**Disclosure:** All authors have declared no conflicts of interest.

**P05.023 SENTINEL NODE NAVIGATION SURGERY IS ACCEPTABLE FOR CLINICAL T1 AND N0 ESOPHAGEAL CANCER**

Yoshikazu Uenosono, Takaaki Arigami, Shigehiro Yanagita, Takahiko Hagihara, Yoshiaki Kita, Hideo Arima, Yasuko Uchikado, Masataka Matsumoto, Hiroshi Okumura, Takashi Aikou, Shoji Natsugoe  
Kagoshima University, Kagoshima/JAPAN

**Background:** If the sentinel node (SN) concept is established for esophageal cancer, it will be possible to safely reduce the extent of lymphadenectomy. Our objective was to perform SN mapping in esophageal cancer to assess distribution of lymph node metastases with the goal to reduce the need for extensive lymphadenectomy.

**Methods:** One hundred-thirty four patients who underwent esophagectomy with lymph node dissection were enrolled. The number of patients with

clinical T1, T2 and T3 tumor was 60, 31, and 32, respectively. Eleven patients also received neoadjuvant chemo-radiation therapy (CRT). <sup>99m</sup>Tc-Tin colloid was injected endoscopically into the esophageal wall around the tumor 1 day before surgery. SNs were identified using radioisotope (RI) uptake. RI uptake of all dissected lymph nodes was measured during and after surgery. Lymph node metastases including micrometastases were confirmed by hematoxyline eosin and immunohistochemical staining.

**Results:** Detection rates of SNs were 93.3% in cT1, 100% in cT2, 87.5% in cT3, and 45.5% in CRT patients. In the 120 cases where SNs were identified, lymph node metastases were found in twelve patients with cT1, 18 with cT2, 24 with cT3 tumor and 3 with CRT. Accuracy rate of SN mapping was 98.2% in cT1, 80.6% in cT2, 60.7% in cT3 and 40.0% in CRT patients. Although one false negative case had cT1 tumor, the lymph node metastasis was detected preoperatively.

**Discussion:** SN mapping can be applied to patients with cT1 and cN0 esophageal cancer. SN concept might enable to perform less invasive surgery with reduction of lymphadenectomy.

**Disclosure:** All authors have declared no conflicts of interest.

**P05.024 ADENOCARCINOMA OF THE ESOPHAGOGASTRIC JUNCTION: HEALTH RELATED QUALITY OF LIFE AFTER IVOR LEWIS ESOPHAGECTOMY AND TRANSHIATAL EXTENDED GASTRECTOMY**

Hans Fuchs, Arnulf Hölscher, Elfriede Bollschweiler, Stefan Mönig, Wolfgang Schröder, Christian Gutschow  
University Of Cologne, Cologne/GERMANY

**Background:** Ivor Lewis esophagectomy and transhiatal extended gastrectomy are alternative procedures in the therapy of adenocarcinoma of the esophagogastric junction type 2 according to Siewert's classification. The influence of these operations on health related quality of life (HRQL) is incompletely understood.

**Methods:** 102 Patients with cancer free survival of at least 12 months after esophageal resection (n = 51) and after extended transhiatal gastrectomy with Roux-en-Y reconstruction (n = 51) were identified from a prospectively maintained database. Both groups were similar concerning sex and age distribution, the duration of follow up, and the rate of neoadjuvant therapy. EORTC questionnaires were sent out to assess health related general (QLQ-C30) and cancer-specific (OG-25) quality of life. A numeric score was calculated in each conceptual area to compare HRQL in both groups.

**Results:** All 102 patients completed the self-rated questionnaires. There was no significant impact of neoadjuvant treatment, minimally invasive approach, or duration of follow-up on HRQL. Also, global health status, functional scales, and symptom scores were similar in both groups except for an increased prevalence of pulmonary symptoms (dyspnea (p < 0.01) and cough (p < 0.05)) in patients after Ivor Lewis esophagectomy.

**Discussion:** HRQL after Ivor Lewis Esophagectomy and transhiatal extended gastrectomy is similar except for pulmonary symptoms. Our findings may play a role for the choice of the surgical strategy in Siewert type 2 adenocarcinoma.

**Disclosure:** All authors have declared no conflicts of interest.

**P05.025 PERCUTANEOUS RADIOLOGICAL GASTROSTOMY IN OESOPHAGEAL CANCER PATIENTS: A FEASIBLE AND SAFE ACCESS FOR NUTRITIONAL SUPPORT DURING MULTIMODAL THERAPY**

Mathieu Messager<sup>1</sup>, Guillaume Piessen<sup>2</sup>, Williams Tessier<sup>1</sup>, Nicolas Briez<sup>1</sup>, Olivier Ernst<sup>2</sup>, Christophe Mariette<sup>2</sup>  
<sup>1</sup>Chru Lille, Lille/France, <sup>2</sup>University Hospital Of Lille, France, Lille/France

**Background:** Percutaneous endoscopic gastrostomy is not widely used in malnourished oesophageal cancer (OC) patients, because of concerns about feasibility in obstructive tumours, suitability of the stomach as a substitute, and potential inoculation metastasis. Percutaneous radiological gastrostomy (PRG) could be an optimal alternative.

**Methods:** Experience among 1205 consecutive patients with OC from 2000 to 2010 was reviewed. PRG was proposed for malnourished patients for whom neoadjuvant chemoradiation was scheduled. PRG placement success rate and major complications were analyzed. A matched-cohort analysis was constructed in patients who underwent oesophagectomy with gastroplasty (n = 759) to evaluate the impact of PRG placement on suitability of gastric pull-up and on postoperative course. From 76 resected patients with PRG, 152 randomly selected controls without PRG were matched 2/1 by gender, age, ASA grade, cTNM stage and neoadjuvant treatment.

**Results:** PRG placement was planned in 269 (22.3%) patients, mainly with locally advanced OC (63.8%), and was feasible in 259 (96.3%) patients. 60-day PRG-related mortality and major morbidity rates were 0% and 3.8%. For resected patients with gastroplasty, both groups were comparable regarding perioperative characteristics except for malnutrition more frequent in the PRG group (P < 0.001). During operation, PRG takedown and site closure were uncomplicated. Use of stomach was possible in all 76 patients. Despite higher malnutrition rate in PRG group, overall and oesophageal surgery related morbidity rates were similar between the 2 groups (P > 0.432).

**Discussion:** PRG is feasible, safe and useful in non-selected patients with OC and does not compromise suitability of stomach as an oesophageal substitute in patients deemed to be resectable.

**Disclosure:** All authors have declared no conflicts of interest.

**P05.026 USING SURGICAL NU-KNIT FOR HEMOSTASIS AROUND RECURRENT LARYNGEAL NERVE DURING TRANSTHORACIC ESOPHAGECTOMY FOR ESOPHAGEAL CANCER.**

Yasushi Rino, Norio Yukawa, Roppei Yamada, Tsutomu Sato, Takashi Oshima, Munetaka Masuda  
Department Of Surgery, Yokohama City University, Yokohama/JAPAN

**Background:** We thought that using electrocautery for hemostasis caused recurrent laryngeal nerve palsy. We reflected the prolonged use of electrocautery and employed SURGICAL NU-KNIT to achieve hemostasis nearby the recurrent laryngeal nerve. We assessed that using SURGICAL NU-KNIT hemostasis prevented or not postoperative recurrent laryngeal nerve palsy, retrospectively. The present study was evaluated to compare using electrocautery hemostasis with using SURGICAL NU-KNIT hemostasis during lymphadenectomy along recurrent laryngeal nerve. The variables compared were morbidity rate of recurrent laryngeal nerve palsy, operation time, and blood loss.

**Methods:** Between January 2010 and August 2011, we use SURGICAL NU-KNIT to achieve hemostasis without strong compression. This group is named group N (mean age: 67.6 years; age range: 56–76 years; 18 men, 1 woman). On the other hand, except the preceding period, we use electrocautery to achieve hemostasis. This group is named group E (mean age: 65.2 years; age range: 49–75 years; 8 men, 1 woman). We investigated the rate of recurrent laryngeal nerve palsy, operation time, and blood loss in patients who underwent esophagectomy with lymphadenectomy, retrospectively.

**Results:** We use SURGICAL NU-KNIT to achieve hemostasis without strong compression. This group is named group N. On the other hand, we use electrocautery to achieve hemostasis. This group is named group E. Complication rate of recurrent laryngeal nerve palsy was higher in group E (55.6%) than group N (5.3%) (p = 0.007).

**Discussion:** Even hemostasis using SURGICAL NU-KNIT was slightly more time-consuming than using electrocautery, we concluded that it would be useful to prevent recurrent laryngeal nerve palsy.

**Disclosure:** All authors have declared no conflicts of interest.

**P05.027 POSTOPERATIVE AIR WAY MANAGEMENT WITH CRYOTHYROIDOTOMY TUBE AFTER ESOPHAGECTOMY**

Yuichi Otsuka, Satoshi Nara, Tamaki Noie, Kei Ito, Yasushi Harihara, Kaoru Furushima, Toshiro Konishi  
Ntt Medical Center Tokyo, Tokyo/JAPAN

**Background:** Postoperative respiratory complication is accounting for major morbidity in esophagectomy.

**Methods:** In order to reduce respiratory complications and access airway easily for sputum suction, we inserted cryothyroidotomy tube and evaluated feasibility and safety of cryothyroidotomy after esophagectomy. From 2001 to 2010, we had 215 cases of esophagectomy and 160 (74.4%) patients had cryothyroidotomy. Minit-Ttch II- Non-Seldinger Kit was used for this procedure and the tube was inserted just after the tracheal extubation in the OR.

**Results:** Duration of ICU stay was for 2–18 days. In 135 cases (84.4%), ICU stay was for 2 days. Cryothyroidotomy tube remained to be inserted for 8–29 days and average of inserted duration was for 11.6 days. Severe respiratory complications were observed in 17 cases (10.6%) in this series. Laryngeal spasm was observed in 3 cases on the insertion of cryothyroidotomy tube and these patients needed tracheal re-intubation in the OR. In long term observation, laryngeal polyp on the inserted site was observed in 1 case and this was resected by ENT surgeon.

**Discussion:** In our series, air way management with the cryothyroidotomy tube was inserted safely and we found low incidence of respiratory complications. Cryothyroidotomy is thought to be one of the alternatives in air way management after esophagectomy instead of conventional tracheotomy.

**Disclosure:** All authors have declared no conflicts of interest.

**P05.028 SURGICAL APPROACH FOR CANCER LOCATED AT THE ABDOMINAL ESOPHAGUS**

Shinsuke Takeno<sup>1</sup>, Shin-ichi Yamashita<sup>2</sup>, Toshihiko Moroga<sup>2</sup>, Satoshi Yamamoto<sup>2</sup>, Katsunobu Kawahara<sup>2</sup>, Yoshiaki Takahashi<sup>1</sup>, Yuichi Yamashita<sup>1</sup>

<sup>1</sup>Gastroenterological Surgery, Fukuoka University Faculty Of Medicine, Fukuoka/JAPAN, <sup>2</sup>Surgery Ii, Oita University Faculty Of Medicine, Yufu/JAPAN

**Background:** There are some reports from the West concerning surgical treatment for adenocarcinoma of lower esophagus or esophagogastric junction. However, a few studies have been reported from the East where squamous cell carcinoma is histological majority to date to our knowledge. The aim of the present study is to clarify the result and feasibility of surgery for cancer of the lower esophagus.

**Methods:** Of 353 patients with surgically resected esophageal cancer without preoperative supplement therapy, 44 patients with cancer located mainly at abdominal esophagus were enrolled in this study. Thirty-four males and 10 females, ranged 47 to 82 years old (mean; 67.4 years old), were included. Thirty-six and eight cases were diagnosed as squamous cell carcinoma and adenocarcinoma respectively. Thirteen patients underwent transhiatal esophagectomy, 18 underwent lower thoracic esophagectomy by left thoracotomy, and 13 underwent esophagectomy right thoracic approach by open thoracotomy or thoracoscopy.

**Results:** Ten cases, including two adenocarcinoma and eight squamous cell carcinoma, involved mediastinal lymph node although lymph node dissection varied in each surgical approach. Five year survival rate was 75% in adenocarcinoma and 31.9% in squamous cell carcinoma respectively, and the cases with adenocarcinoma revealed a more favorable prognosis than the cases with squamous cell carcinoma (p = 0.05). In contrast, there was no significant prognostic difference between surgical approach (P = 0.34).

**Discussion:** The patients with squamous cell carcinoma revealed unfavorable prognosis because of the higher risk of mediastinal lymph node metastasis. Such cases might require thoracic lymph node dissection in order to improve the prognosis after surgery.

**Disclosure:** All authors have declared no conflicts of interest.

**P05.029 ESOPHAGEAL CANCER IN THE YOUNG: A POPULATION-BASED ANALYSIS OF 1,095 PATIENTS**

Attila Dubeccz<sup>1</sup>, Norbert Solymosi<sup>2</sup>, Michael Schweigert<sup>1</sup>, Rudolf J Stadlhuber<sup>1</sup>, Dietmar Ofner<sup>3</sup>, Jeffrey H Peters<sup>4</sup>, Hubert J Stein<sup>1</sup>  
<sup>1</sup>Klinikum Nürnberg, Nuremberg/GERMANY, <sup>2</sup>Szent Istvan University, Budapest/HUNGARY, <sup>3</sup>Paracelsus Private Medical University, 5020/AUSTRIA, <sup>4</sup>Department Of Surgery, University Of Rochester Medical Center, Rochester/NY/UNITED STATES OF AMERICA

**Background:** PURPOSE: To evaluate population-based demographics and survival of young patients with esophageal cancer in the United States.

**Methods:** We identified 1,095 patients under 40 years of age with cancer of the esophagus and the gastric cardia diagnosed between 1973 and 2008 from the Surveillance, Epidemiology, and End Results (SEER) database. Demographic variables and cancer-related survival were assessed and compared to all patients >40 years old (n = 65,930). Influence of available variables on survival was analyzed with logistic regression.

**Results:** Percentage of young patients with esophageal cancer is less than 2% and is declining since the 1990s. More than fifty percent are diagnosed in metastatic stage. Only 74% of patients with potentially resectable esophageal cancer underwent surgery. Median cancer-related survival (13 months vs. 11 months) and five-year survival (22% vs. 18%) was significantly higher than in older patients. Multivariate-analysis identified surgical treatment (OR: 5.046) as the only independent predictor of 5-year survival. Percentage of non-white patients, distal cancer and adenocarcinoma were significantly higher when compared to all patients.

**Discussion:** Most young patients with esophageal cancer are diagnosed in metastatic stage in the United States. Survival in patients under 40 years of age is better than in older patients. Patients undergoing surgical treatment have improved survival.

**Disclosure:** All authors have declared no conflicts of interest.

**P05.030 RISK FACTORS ASSOCIATED WITH THE SUPRACLAVICULAR NODE METASTASIS IN PATIENTS WITH SUBMUCOSAL CARCINOMA OF THE THORACIC ESOPHAGUS**  
Shin-ichi Kosugi<sup>1</sup>, Tatsuo Kanda<sup>1</sup>, Kazuhito Yajima<sup>1</sup>, Takashi Ishikawa<sup>1</sup>, Tsutomu Suzuki<sup>2</sup>, Katsuyoshi Hatakeyama<sup>1</sup>  
<sup>1</sup>Division Of Digestive And General Surgery, Niigata University Graduate School Of Medical And Dental Sciences, Niigata/JAPAN, <sup>2</sup>Niigata University Graduate School Of Health Sciences, Niigata/JAPAN

**Background:** Submucosal (SM) carcinoma of the thoracic esophagus often spreads widely via lymphatics even to the supraclavicular node (SCN); therefore, the standard treatment for this disease remains esophagectomy with three-field lymphadenectomy (3FL) in Japan. The objective of this study was to elucidate the risk factors associated with metastasis to the SCN in patients with SM carcinoma of the thoracic esophagus.

**Methods:** Seventy-six patients with clinically SM carcinoma of the thoracic esophagus who underwent esophagectomy with 3FL were retrospectively reviewed.

**Results:** Six patients were found to have pathologically mucosal carcinoma, one of whom had paratracheal node metastasis. Thirty-six (51%) of 70 patients with pathologically SM carcinoma had nodal disease, with incidences of cervical, mediastinal, and abdominal node metastasis of 20%, 29%, and 20%, respectively. Of 14 patients with cervical node metastasis, the primary tumor location was the upper thoracic esophagus in 5 and the middle thoracic esophagus in 9. The cervical paraesophageal node was involved in 7 patients, the SCN in 6, and both in 1. Of 7 patients with SCN metastasis, nodal involvement was found in the SCN alone in 3, in the SCN along with the paratracheal node in 1, and in the SCN along with abdominal node in 3. SCN metastasis was associated with histopathological grading, lymphatic permeation, and intramural metastasis, and poor differentiation was an independent risk factor ( $p = 0.0321$ ).

**Discussion:** Metastasis to the SCN develops irrespective of mediastinal nodal status. Cervical neck dissection should be performed in patients with poorly differentiated SM carcinoma of the upper or middle thoracic esophagus.

**Disclosure:** All authors have declared no conflicts of interest.

**P05.031 MARKER FOR EARLY DETECTION OF ANASTOMOTIC LEAKAGE FOR ESOPHAGEAL CANCER**

Eijiro Edagawa, Harushi Osugi, Shigeru Lee, Satoru Kishida, Masato Okawa, Yukiko Niwa, Ken Gyobu, Yasunori Matsuda  
Department Of Gastroenterological Surgery, Osaka City University Graduate School Of Medicine, Osaka/JAPAN

**Background:** In esophagectomy for cancer, anastomotic leakage is one of life-threatening complications. We identify marker for early detection of anastomotic leakage, and validate them.

**Methods:** From April 2007 to March 2011, 204 patients have undergone one-stage subtotal esophagectomy and gastric reconstruction through posterior mediastinum. Patients were divided into a screening set (Group A n = 108) and a validation set (Group B n = 96). In Group A, we investigated WBC count, C-reactive protein (CRP), body temperature, pulse rate, platelet count, fibrinogen, fibrin degradation products and anti-thrombin III until postoperative day (POD) 7. The results were checked for significance with t test between leakage group and non-leakage group. ROC curve for detection of anastomotic leakage was constructed. In Group B, we validated its cut-off level prospectively. Other inflammatory complication rate was 0.1% in Group A and 2% in Group B.

**Results:** For CRP, the value of POD3 to POD7 when we set 1 to value of POD2 (we called changing rate) has a significantly higher anastomotic leakage than non-leakage group, was remarkable on POD3 ( $p = 0.0007$ ). ROC curve obtained based on the changing rate of POD3, and to calculate the cut-off value was obtained 95.2% sensitivity, as the threshold to 73.8%. For fibrinogen, there was a significant difference in POD4, the cut-off value was calculated to obtain 712 mg/dl as the threshold, 89.5% specificity in ROC curve. We validated in Group B, leakage group was significantly higher than non-leakage group in CRP, but not for fibrinogen.

**Discussion:** CRP is certainly useful to detect anastomotic leakage in early postoperative period.

**Disclosure:** All authors have declared no conflicts of interest.

**P05.032 THE TRANS-DIAPHRAGMATIC ESOPHAGECTOMY FOR SUPERFICIAL ESOPHAGEAL CANCER PATIENTS**

Hideo Matsumoto, Yuko Kaida, Hisako Kubota, Haruaki Murakami, Masaharu Higashida, Noriaki Manabe, Ken Haruma, Masafumi Nakamura, Toshihiro Hirai  
Kawasaki Medical School, Kurashiki, Okayama/JAPAN

**Background:** The trans-diaphragmatic esophagectomy (TDE) is involved the lymph node dissection of lower mediastinum through an incision in the diaphragm hiatus obviating thoracotomy.

This less invasive esophagectomy is sufficiently effective not only in superficial esophageal cancer, in which invasion is limited to the T1 layer, but also in advanced esophageal cancer in the lower part without lymph node metastasis in the upper mediastinal area.

**Methods:** Forty-eight patients underwent TDE from April 2003 to December 2010. For advanced esophageal cancer patients, we added an adjuvant chemo-radiation therapy with S-1/Docetaxel according to the pathological diagnosis.

**Results:** The number of patients of pathological stage 0, IA, IB, IIA, IIB, IIIB and IV was 14, 14, 2, 7, 5 and 3, respectively. The five-year survival rate of all the forty-eight cases was 72.4%. That of stage 0, IA, and IB was 100%. The three-year survival rates of stage IIA, IIB and IIIB were 83.3%, 100% and 40%, respectively.

These outcomes were not inferior to those achieved the trans-thoracic esophagectomy (TTE) in our institution. As for complications of TDE, the rates of minor anastomotic leakage, pneumonia and temporary recurrent nerve paralysis were 4.5%, 0% and 4.5%, respectively. TDE was associated with a lower incidence of complications than TTE.

**Discussion:** TDE, a less invasive method for the surgical treatment of esophageal cancer, might be recommended for early-stage and lower advanced-stage esophageal cancer patients without lymph nodes metastasis in the upper mediastinal area.

**Disclosure:** All authors have declared no conflicts of interest.

**P05.033 ENDOSCOPIC SUBMUCOSAL DISSECTION (ESD) USING NEW DEVICE MUCOSECTOM2 FOR ESOPHAGEAL CANCERS**

Yoshiro Kawahara<sup>1</sup>, Seiji Kawano<sup>1</sup>, Keisuke Hori<sup>1</sup>, Hiroyuki Okada<sup>1</sup>, Kazuhide Yamamoto<sup>2</sup>

<sup>1</sup>Department Of Endoscopy, Okayama University Hospital, Okayama/JAPAN, <sup>2</sup>Gastroenterology & Hepatology, Okayama University Graduate School Of Medicine Dentistry And Pharmaceutical Sciences, Okayama/JAPAN

**Background:** We developed and reported a safe and easy technique of the ESD using Mucosectom (Pentax Japan) for gastric cancers. Because the wall of esophagus is very thin and its lumen is very narrow, en-bloc resection for esophageal tumors by ESD is thought to be a very difficult procedure in gastrointestinal tract. We have developed New-type Mucosectom (Mucosectom2) to carry out ESD safely. We display our ESD technique for early esophageal cancers using Mucosectome2.

**Methods:** Mucosectom is composed with flexible plastic shaft and cutting wire. Plastic shaft moves a muscular layer side; cutting wire moves a mucosal layer side of the submucosa during ESD, and then procedure itself becomes safe. To adjust the esophageal lesion, we improved the conventional Mucosectom. The blade length has been shortened 5 mm to 2.5 mm and the diameter has become thinner than that of the conventional type. We used and evaluated this Mucosectome2 in 54 esophageal ESD cases.

**Results:** We could complete the esophageal ESD by Mucosectome2 in all cases. By using this new device, we could dissect the submucosa very quickly. The mean (95% CI) procedure time was 58.49 (53.76–63.21) min in the conventional group and 27.12 (21.78–32.45) min in the Mucosectom2 group. The procedure time of esophageal ESD with Mucosectom2 group is significantly shorter than that with conventional group. The mean of differences is 24.73(15.82–33.64) min ( $P < 0.0001$ ).

**Discussion:** We present a novel method of ESD for early esophageal cancers using Mucosectom2, which can realize safer, easier, and less time-consuming ESD compared to previous methods using other devices.

**Disclosure:** All authors have declared no conflicts of interest.

#### P05.034 PREOPERATIVE PATHOLOGICAL COLONIZATION OF THE TRACHEOBRONCHIAL SYSTEM PREDICTS POSTOPERATIVE PULMONARY COMPLICATIONS AFTER ESOPHAGECTOMY

Marc Bludau, Arnulf Hölischer, Christian Gutschow, Wolfgang Schröder  
*Department Of General-, Visceral- And Cancer Surgery, University Of Cologne, Cologne/GERMANY*

**Background:** After transthoracic esophagectomy respiratory complications significantly contribute to postoperative morbidity and mortality. The etiology is known to be multifactorial. The aim of this study was to proof the correlation between preoperative microbiological colonization of the tracheo-bronchial system and postoperative respiratory complications.

**Methods:** In this study, 65 patients with transthoracic esophagectomy and gastric reconstruction because of esophageal cancer (43 Adenocarcinoma, 22 SSC) were included. 41 patients (63,1 %) with a locally advanced tumor received neoadjuvant radiochemotherapy following a standardized protocol (40 Gy, 5 FU, Cisplatin). After induction of anesthesia and endotracheal intubation the endoluminal exudates were collected for further microbiological work-up. During the postoperative course criteria of pulmonary dysfunction was diagnosed with prolonged ICU stay, pathologic chest X-ray or pathology in the postoperative microbiological analysis of the tracheal exudate.

**Results:** The overall morbidity in this group was 46,2 % (30/65 patients), in-hospital-mortality 4,6% (3/65 patients). In 13 of 65 patients (20%) we could prove a pathological colonization in the tracheal exudate. 8 of these 13 patients developed pneumonia in the postoperative course. By contrast 5 of 52 patients had a pathological colonization in the tracheal exudate and had no pulmonary dysfunction. In the statistical analysis with Fisher exact Test a preoperative pathological colonization in the tracheal exudates leads significantly to more frequent pulmonary dysfunction ( $p > 0,001$ ). The preoperative radiochemotherapy caused no more frequent pathological colonization of the tracheal exudates.

**Discussion:** The preoperative pathological colonization of the tracheal exudates predisposes the development of postoperative pulmonary complications. Preoperative antibiotic therapy needs to be discussed.

**Disclosure:** All authors have declared no conflicts of interest.

#### P05.035 EFFICACY AND SAFETY OF ENDOSCOPIC SUBMUCOSAL DISSECTION FOR ESOPHAGEAL SQUAMOUS CELL CARCINOMA

Ryuta Takenaka<sup>1</sup>, Yoshiro Kawahara<sup>2</sup>, Keisuke Hori<sup>2</sup>, Seiji Kawano<sup>2</sup>, Hiroyuki Okada<sup>2</sup>, Koji Takemoto<sup>1</sup>, Akihiko Taira<sup>1</sup>, Hirofumi Tsugeno<sup>1</sup>, Shigeatsu Fujiki<sup>1</sup>

<sup>1</sup>Tsuyama Central Hospital, Tsuyama/JAPAN, <sup>2</sup>Department Of Endoscopy, Okayama University Hospital, Okayama/JAPAN

**Background:** Endoscopic submucosal dissection (ESD) was developed for gastric cancers to achieve en-bloc resection and to enable precise histological assessments. Recently, it is applied to esophageal malignancies. However, because esophageal wall has no serous membrane, pneumomediastinum is easily occurred even when the muscularis propria is explored. In addition, stricture after the therapy occasionally becomes a problem. The aim of this study was to assess the feasibility and safety of the ESD for esophageal malignancies.

**Methods:** A total of 192 patients with esophageal squamous cell carcinoma were treated using ESD technique between July 2003 and December 2011. Clinical outcomes of ESD were evaluated.

**Results:** The median age of the patients was 68 years (range, 38–91 years) and the mean size of the tumor was 23.5 mm. En-bloc resection was achieved in 189 lesions (98.4%) and the median operating time was 85 minutes (range, 20–240 minutes). There was no bleeding which required blood transfusion. Pneumomediastinum was occurred in 16 patients (8.3%), all of which were managed by conservative medical treatments. Stricture related to ESD occurred in 27 patients (14%), in which endoscopic balloon dilatation were required. Local recurrences were found in 3 patients within the median follow-up duration of 20 months, whereas metachronous esophageal cancers were confirmed in 21 patients during the same periods.

**Discussion:** ESD is feasible and safety for the treatment of superficial esophageal malignancies because it provides high en-bloc resection and a low rate of complication which is successfully managed by medical treatments.

**Disclosure:** All authors have declared no conflicts of interest.

#### P05.036 RECURRENT LARYNGEAL NERVE MONITORING DURING THORACOSCOPIC ESOPHAGECTOMY IN THE PRONE POSITION.

Yoshifumi Ikeda, T Inoue, E Ogawam, M Horikawa, T Koide, Tsuyoshi Inaba, Ryoji Fukushima

*Department Of Surgery, Teikyo University School Of Medicine, Tokyo/JAPAN*

**Background:** A thoracoscopic esophagectomy may minimize injury to the chest wall and reduce the surgical invasiveness, and there have been several reports of its feasibility and curability. This procedure is traditionally performed in the left lateral decubitus position, but recently the advantages of a thoracoscopic esophagectomy in the prone position have been reported. Compared to the left lateral decubitus position, better operative exposure, and improved surgeon ergonomics have been demonstrated in the prone position. However, the surgeon is unfamiliar the view in the prone position. Since surgery of esophagus has the potential to result in postoperative impairment or damage of the recurrent laryngeal nerve (RLN), surgeon is especially worried about the nerve can be detected or not in the prone position. To date, surgical adjuncts, such as intraoperative neuromonitoring, are being applied to prevent RLN injury during thyroid operation. Therefore, we try to use this system in thoracoscopic esophagectomy in the prone position.

**Methods:** The patient was under general anesthesia and was intubated with Medtronic Xomed Nerve Integrity Monitor Standard Reinforced EGM Endotracheal Tube. The patient was initially placed in a prone position. The right arm only was raised cranially to expose the right axillary fossa. Single-lung ventilation was performed with bronchial blocker.

**Results:** Intraoperative, noninvasive RLN stimulation was performed to identify and then aid in dissection of the RLN, and to test the nerve at the end of the initial surgery. The right RLN was identified around the subclavian artery and ascends along the superior lobe of the pleura. Since the nerve has some esophageal branches, the main trunk is incidentally missed. The left RLN must be distinguished from the cardiac branches. We monitored a nerve signal during surgical procedure, and detected the nerve exactly.

**Discussion:** Intraoperative RLN identification and monitoring during single-lung ventilation surgery is technically feasible, easy, and reliable.

**Disclosure:** All authors have declared no conflicts of interest.

#### P05.037 RESULTS OF THE INTRODUCTION OF A MINIMALLY INVASIVE ESOPHAGECTOMY PROGRAM IN A TERTIARY REFERRAL CENTER

Rachel Blom<sup>1</sup>, Jean Klinkenbijn<sup>1</sup>, Markus Hollmann<sup>1</sup>, Jacques Bergman<sup>1</sup>, Miguel Cuesta<sup>2</sup>, Willem Bemelman<sup>1</sup>, Olivier Busch<sup>1</sup>, Mark Van Berge Henegouwen<sup>1</sup>

<sup>1</sup>Academic Medical Center, Amsterdam/NETHERLANDS, <sup>2</sup>Vumc, Amsterdam/NETHERLANDS

**Background:** Esophagectomy is accompanied by a high postoperative complication rate. Although not yet proven by randomized clinical trials, minimally invasive esophageal surgery (MIE) appears to be a promising technique that might be associated with a lower pulmonary morbidity rate. The objective of this study was to describe the implementation of in a tertiary referral center and to compare the results of our first series of (MIE) to conventional open esophagectomies.

**Methods:** MIE was implemented after several procedures had been performed by a surgeon with extensive experience with MIE. Preoperative characteristics and the postoperative course of patients who underwent a transthoracic esophagectomy were prospectively registered. Morbidity and overall hospital stay were compared between MIE and open resections performed in the same period.

**Results:** 90 esophageal cancer patients underwent a transthoracic resection, 41 patients by means of a MIE. Preoperative characteristics were comparable for both groups. The duration of surgery was longer in the MIE group (6.0 vs. 5.2 hours,  $p < 0.001$ ) and median blood loss was lower (100 ml vs. 500 ml ( $p < 0.001$ )). There was only a trend towards a shorter hospital stay in the MIE group (11 vs. 13 days,  $p = 0.072$ ), pulmonary complications occurred in 20% of patients in the MIE group vs. 31% in the open group ( $p = 0.229$ ). The overall complication rate was 51% in the MIE group vs. 63% in the open group,  $p = 0.249$ .

**Discussion:** Implementation of MIE in our center was successful and it appears to be a safe technique for patients with potentially curable esophageal carcinoma.

**Disclosure:** All authors have declared no conflicts of interest.

**P05.038 IMPLEMENTATION OF AN ENHANCED RECOVERY PROTOCOL IN ESOPHAGEAL SURGERY**

Rachel Blom, Mark Van Heijl, Willem Bemelman, Markus Hollmann, Jean Klinkenbijn, Olivier Busch, Mark Van Berge Henegouwen  
*Academic Medical Center, Amsterdam/NETHERLANDS*

**Background:** A recent development in gastrointestinal surgery is the implementation of enhanced recovery after surgery (ERAS) programs. Evidence regarding the benefit of these programs in patients undergoing esophageal surgery is scarce. We investigated the feasibility and possible benefit of a perioperative ERAS program in patients undergoing esophagectomy for malignant disease.

**Methods:** The ERAS program was initiated in 2009. Patients who underwent esophagectomy and were treated according to the ERAS program were included. ERAS items included preoperative nutrition, early detubation, early removal of nasogastric tube and early mobilization. Primary outcome parameters were hospital stay and the incidence of postoperative complications. Outcome parameters in the ERAS cohort were compared to a cohort of patients who underwent surgical resection in the year prior to the implementation of the ERAS protocol. A feasibility analysis was performed among a sample of ERAS patients to determine the number of achieved items per patient.

**Results:** 181 patients underwent esophagectomy between 2008 and August 2010. 103 patients were included in the ERAS program (ERAS+ group) and compared to 78 patients who underwent an esophagectomy in 2008 (ERAS– group). Overall hospital stay was 14 days vs. 15 days (ERAS+ and ERAS– respectively,  $p = 0.013$ ). There were no significant differences in the incidence of postoperative complications in both groups. The percentage of achieved items varied between 42 and 93% per item.

**Discussion:** The implementation of an ERAS program in esophageal surgery was feasible and resulted in a small but significant reduction of overall hospital stay, whereas overall morbidity was not affected.

**Disclosure:** All authors have declared no conflicts of interest.

**P05.039 THE ESOPHAGEAL INVASION AND MEDIASTINAL LYMPH NODE METASTASIS OF ESOPHAGO-GASTRIC JUNCTION CANCER**

Tetsuhiro Owaki, Hiroshi Okumura, Masataka Matsumoto, Yasuto Uchikado, Ken Sasaki, Itaru Omoto, Tetsuro Setoyama, Sumiya Ishigami, Yoshikazu Uenosono, Shinichi Ueno, Shoji Natsugoe  
*Kagosima University Hospital, Kagoshima/JAPAN*

**Background:** In an esophago-gastric junction (EGJ) cancer, transhiatal approach is desirable for tumor within 3 cm invasion beyond EGJ, because of a few complications. However, there are no standard methods for EGJ tumor with 3 cm and more invasion. We analyzed the esophageal invasion and mediastinal LN metastases, compared with histological results and mode of recurrence for EGJ cancer.

**Methods:** A total of 130 patients with EGJ cancer were enrolled. EGJ cancer was defined as tumors which center were located within 2 cm above and below the EGJ. We analyzed the histologic findings, surgical methods, modes of recurrence and prognosis.

**Results:** When tumor invaded esophageal wall beyond 21 mm, mediastinal LN metastasis was found. The upper mediastinum LN metastasis was found in the patient with 40 mm or more esophagus invasion. Mediastinal LN metastasis was found in 17 of 55 patients (31%) who had esophageal invasion with 25 mm and more. Abdominal procedure was selected in 17 of 55 patients (31%) who had esophageal invasion within 20 mm, however, mediastinal LN recurrence was not found. The 5-year survival rates of patients with 20 mm or more esophageal invasion and within 20 mm esophageal invasion was 57 % and 40% respectively. When the number of metastasis were divided into less than 5, and 5 and more, the prognosis was significantly better in the former than in the latter (27% vs. 60%,  $p = 0.013$ ).

**Discussion:** When EGJ tumor invades into esophageal wall beyond 20 mm and more, thoraco-abdominal approach should be selected. In the patients with LN metastases with 5 and more, new strategy should be considered.

**Disclosure:** All authors have declared no conflicts of interest.

**P05.040 A CASE OF LYMPHOGRAPHY WHICH WAS USEFUL TO RECOVER FROM CHYLOTHORAX AFTER ESOPHAGECTOMY**

Mitsugu Endo, Yoshihiko Naritaka, Takeshi Shimakawa, Shinichi Asaka, Noriyuki Isohata, Kentaro Yamaguchi, Minoru Murayama, Atsuko Usuda, Akira Miyaki, Soichi Konno, Shunichi Shiozawa, Kazuhiko Yoshimatsu, Kenji Ogawa  
*Tokyo Women'S Medical University Medical Center East, Tokyo/JAPAN*

**Background:** Chylothorax after esophagectomy is not major but a potentially life-threatening complication. Once chylothorax happened after esophagectomy, management for the recovery is not always easy. We report one case that lymphography was an effective method for the treatment of lymphatic leakage when conservative therapy fails.

**Methods:** Case report: A 72-year-old man presenting with squamous cell carcinoma of the lower esophagus underwent esophagectomy after neoadjuvant chemotherapy. The thoracic drainage tube was removed on POD 9. Chest X-rays showed a massive fluid collection in the left thoracic on POD 12. More than 3000 ml of chylous fluid were drained. The patient was performed the continuous drainage and scheduled the treatment with Octreotide for several days. On POD 19, he was performed with mass ligation of the thoracic duct. But the discharge of chylous fluid continued even after the operation.

**Results:** On POD 24, we performed the lymphography. We could figure out the leakage point, and it was another duct previous ligated by the surgical operation. We made his diagnosis as double thoracic duct. On POD 25, he was performed with mass ligation including the leakage point of the thoracic duct shown by the lymphography. Fluid collection was decreased and finally he was cured.

**Discussion:** From this case, lymphography is suggested as the useful exam to get the chance to identify the leakage point of thoracic duct. This case indicates when chylothorax after esophagectomy happened and hard to cure with conservative therapy, lymphography should be considered to try before the surgical mass ligation of the thoracic duct.

**Disclosure:** All authors have declared no conflicts of interest.

**P05.041 MODIFICATION OF THE PROCEDURE FOR ESOPHAGEAL RECONSTRUCTION AFTER RESECTION OF ESOPHAGEAL CANCER**

Takeshi Shimakawa, Yoshihiko Naritaka, Shinichi Asaka, Noriyuki Isohata, Mitsugu Endo, Atsuko Usuda, Kentaro Yamaguchi, Hajime Yokomizo, Shunichi Shiozawa, Kazuhiko Yoshimatsu, Takao Katsube, Kenji Ogawa  
*Tokyo Women'S Medical University Medical Center East, Tokyo/JAPAN*

**Background:** Reconstruction after esophagectomy is still associated with the highest risk of anastomotic leakage among all of the gastrointestinal anastomoses. In 1994, the reconstruction phase of our procedure was modified aiming to reduce the risk of anastomotic leakage. We evaluated usefulness of our modified procedure.

**Methods:** 32 patients before the modification of reconstruction, were included in Group A, whereas Group B included 127 patients after the modification. Group C included 90 patients after the furthermore modification. In Group A, a thin gastric tube was constructed along the greater curvature. In Group B, the gastric tube was made thinner and longer. We could preserve a vessel feeding the terminal segment of the gastric tube that secured ample blood supply to this segment. The cut end of the cervical esophagus was anastomosed to the posterior wall of the gastric tube near the greater curvature, where adequate blood supply is available, and the anastomotic line was covered with omentum. In Group C, the cut end of the gastric tube was closed with a liner stapler of triple rows staples, and the clavicle head was resected for enlargement of the thoracic inlet area.

**Results:** In Group A, anastomotic leakage occurred in 15.6%. In Group B, minor leaks occurred 3.9%, indicating a marked decrease. In Group C, minor leaks occurred 3.3%, indicating a marked decrease.

**Discussion:** The method of esophageal reconstruction currently performed at our department does not require special techniques, but the occurrence of anastomotic leakage is very low.

**Disclosure:** All authors have declared no conflicts of interest.

**P05.042 MINIMALLY INVASIVE SURGERY FOR THORACIC ESOPHAGEAL SURGERY UNDER THORACOSCOPY AND LAPAROSCOPY**

Hisayuki Matsushita, Hideaki Shimizu  
*Tochigi Cancer Center, Utsunomiya/JAPAN*

**Background:** We recently began performing thoracic mobilization of the esophagus in the prone position and laparoscopic reconstruction with gastric roll as a minimally invasive surgery in cases of thoracic esophageal cancer. The aim of this study was to evaluate the feasibility and efficiency of thoracoscopic esophagectomy following laparoscopic reconstruction.

**Methods:** Ten consecutive operations were performed between September 2009 and December 2011. Operative time, estimated blood loss, and complications were evaluated.

**Results:** Mean operative time was 692 min (range 518–1044). There were no cases of conversion to open surgery. Mean blood loss was 300 g (range 55–592). Paralysis of recurrent laryngeal nerve occurred in two cases. Minor leakage occurred in one case. All patients were able to walk the day after the operation and there was no pneumonia after surgery.

**Discussion:** Thoracoscopic and laparoscopic esophageal surgery for thoracic esophageal cancer can be regarded as minimally invasive, although the operation takes a long time.

**Disclosure:** All authors have declared no conflicts of interest.

**P05.043 PATIENTS' PREFERENCES FOR SURGICAL MANAGEMENT OF ESOPHAGEAL CANCER: A DISCRETE CHOICE EXPERIMENT**

Bas Wijnhoven<sup>1</sup>, Eva Niers<sup>2</sup>, Esther De Bekker-Grob<sup>2</sup>

<sup>1</sup>Erasmus Mc – University Medical Center Rotterdam, Rotterdam/ NETHERLANDS, <sup>2</sup>Erasmus Mc – University Medical Center Rotterdam, Rotterdam/NETHERLANDS

**Background:** Knowing patients' preferences towards surgical treatment may help to optimize counseling patients or to adjust the treatment strategy according to their needs and demands.

**Methods:** A discrete choice experiment was conducted among adult patients who had undergone esophagectomy. Patients were asked on their preferences for aspects of surgical management for esophageal cancer using scenarios based on: risk of in-hospital mortality, risk of persistent GI symptoms, chance of 5-year survival, risk of surgical and non-surgical complications, and hospital volume of esophageal cancer surgery.

**Results:** The response was 68% (104/142). All aspects proved to influence the patients' preferences ( $p < 0.05$ ). However, substantial preference heterogeneity was identified. Patients were willing to trade-off 9.5% (CI: 2.4%–16.6%) 5-year survival chance to obtain a surgical treatment with 30% lower long-term absolute risk of GI symptoms, or 8.1% (CI: 4.0%–12.2%) 5-year survival chance for being treated in a high instead of a low volume hospital. Patients accepted a less effective treatment or a higher risk of persistent GI symptoms, if the surgery of esophageal cancer took place in a higher volume hospital with a lower risk of in-hospital mortality and morbidity.

**Discussion:** This study provides insight into the trade-offs patients with esophageal cancer are willing to consider concerning an operative treatment. This can be informative to physicians regarding factors and variability that are of influence on patients' preferences for an esophagectomy and could enable improved counseling.

**Disclosure:** All authors have declared no conflicts of interest.

**P05.044 SATISFACTION ON DISEASE AND TREATMENT-RELATED INFORMATION IN PATIENTS WHO UNDERWENT OESOPHAGECTOMY FOR CANCER**

Bas Wijnhoven, Pieter Van Hagen, Renee Acosta

Erasmus Mc – University Medical Center Rotterdam, Rotterdam/ NETHERLANDS

**Background:** It is crucial to carefully provide information on cancer, its treatment and prognosis to a patient, to prevent feelings of anxiety and fear and to increase patient's satisfaction, compliance to treatment and self efficacy. The aim of this study was to determine patient satisfaction with the provided information on oesophageal cancer and its treatment.

**Methods:** Some 62 patients who underwent oesophagectomy for cancer between January 2008 and January 2010 without evidence of recurrent disease were invited to complete the EORTC INFO-26 questionnaire. The answers to the 28 questions were converted into a 0–100 point scale, with 0 being 'not satisfied' and 100 being 'very satisfied'.

**Results:** The response rate was 74% (46 patients). Most patients (69.6%) were male, mean age was 63 years. The mean overall score on satisfaction with the provided information was 57 points. Patients were most satisfied with information given on the diagnostic procedures (mean score 64 points) and least satisfied with information on the impact of cancer on their family and social life (mean score 13 points). There was no significant difference in satisfaction between men and women, age groups or levels of education. Some 43.5% of patients indicated that they would have liked to receive more information on nutrition after surgery and toxicity of chemotherapy.

**Discussion:** Patients' satisfaction with the provided information on oesophageal cancer was only moderate and was not related to patients' demographics. This study indicates that optimization of providing information by healthcare workers in our hospital is needed.

**Disclosure:** All authors have declared no conflicts of interest.

**P05.045 THE INFLUENCE OF POSTOPERATIVE COMPLICATIONS ON RECURRENCE AND LONG-TERM SURVIVAL AFTER ESOPHAGECTOMY FOR ESOPHAGEAL CANCER**

Arzu Oezcelik, Shahin Ayazi, Steven R Demeester, Joerg Zehetner, Jeffrey A Hagen, Tom R Demeester

Department Of Surgery, University Of Southern California, Los Angeles/ UNITED STATES OF AMERICA

**Background:** The aim of this study was to identify factors associated with postoperative complications and to evaluate whether the severity of postoperative complications as classified using the Clavien classification was associated with cancer recurrence and survival.

**Methods:** The records of all patients who underwent an esophagectomy for cancer between 2002 and 2007 were reviewed. Postoperative complications were graded using the Clavien Classification, and scored from minor (Grade I) through the most serious (Grade IV). We defined major complications as those  $\geq$  grade IIIb.

**Results:** The study population consisted of 422 patients with a median age of 63 years. Neoadjuvant therapy was given in 94 patients (22%). En bloc, transhiatal and minimally invasive esophagectomies were performed. Postoperative complications occurred in 191 patients (45%). Complications were considered minor (Clavien grade I-IIIa) in 116 (27%) and major (grade IIIb or IV) in 75 (18%). On multivariate analysis, increasing age, stage, blood transfusion and Clavien classification  $\geq$  grade IIIb complications were independent negative predictors of survival. Factors associated with cancer recurrence included tumor stage, blood transfusion and major postoperative complications. Factors associated with Clavien grade IIIb or higher complications included increasing age and blood transfusion. Neoadjuvant therapy, tumor stage and type of resection were not associated with postoperative complications.

**Discussion:** The study suggests that in addition to known prognostic factors such as tumor stage, the occurrence of major complications are associated with a higher frequency of recurrence and decreased survival after esophagectomy for cancer. Esophagectomy should be done in experienced centers where major complications are minimized.

**Disclosure:** All authors have declared no conflicts of interest.

**P05.046 IS THE NUMBER OF LYMPH NODES REMOVED AND THE TYPE OF RESECTION ASSOCIATED WITH POSTOPERATIVE COMPLICATIONS AFTER ESOPHAGECTOMY FOR ESOPHAGEAL CANCER?**

Arzu Oezcelik, Shahin Ayazi, Jessica M Leers, Steven R Demeester, Joerg Zehetner, Jeffrey A Hagen, Tom R Demeester

Department Of Surgery, University Of Southern California, Los Angeles/ UNITED STATES OF AMERICA

**Background:** Several studies have shown that the type of resection and the number of removed lymph nodes are independent prognostic factor for an improved survival after esophagectomy for esophageal cancer. The aim of this study was to evaluate whether the type of resection and the number of removed lymph nodes have an influence on postoperative complications.

**Methods:** The records of all patients who underwent an esophagectomy for cancer between 2002 and 2007 were reviewed. The stage, intraoperative data, pathology reports, postoperative complications and the outcome were reported. Postoperative complications were graded using the Clavien Classification. Major complications were defined as complications  $\geq$  grade IIIb.

**Results:** The study population consisted of 365 patients with a median age of 63 years. En bloc esophagectomy was performed in 229 patients (55%) and transhiatal in 136 (33%). The mean number of removed lymph nodes was 54 after en bloc and 22 after transhiatal esophagectomy. Major complications after an en bloc esophagectomy were seen in 42 patients (18%) and after a transhiatal esophagectomy in 23 (17%). The median ICU and hospital stay was 4 and 17 days respectively. On multivariate analysis, survival was improved after en bloc esophagectomy and with increasing number of removed lymph nodes. However type of resection and number of lymph nodes removed were not associated with major postoperative complications.

**Discussion:** The study shows that the type of resection and the number of lymph nodes removed are not associated with major postoperative complications. Further it confirms previous studies that the survival is improved after en bloc esophagectomy with increased number of lymph nodes removed.

**Disclosure:** All authors have declared no conflicts of interest.

**P05.047 SAFE ESOPHAGEAL RECONSTRUCTION BY ILEOCOLIC INTERPOSITION.**

Takaaki Ensako<sup>1</sup>, Hideo Matumoto<sup>1</sup>, Yuu Muta<sup>1</sup>, Yuko Kaida<sup>1</sup>, Hisako Kubota<sup>1</sup>, Haruaki Murakami<sup>1</sup>, Masaharu Higashida<sup>1</sup>, Ken Haruma<sup>2</sup>, Masafumi Nakamura<sup>1</sup>, Toshihiro Hirai<sup>1</sup>

<sup>1</sup>Department Of Digestive Surgery, Kawasaki Medical School, Okayamaken/ KURASIKI/JAPAN, <sup>2</sup>Department Of Gastroenterological Medicine, Kawasaki Medical School, KURASIKI,okayama/JAPAN

**Background:** Many techniques have been proposed for esophageal reconstruction after esophagectomy when a gastric tube cannot be employed. There are 2 essential criteria for such a substitute: substitute length and sufficient blood supply. We propose ileocolic interposition as an easy and safe option.

**Methods:** Two technical aspects contributing to the high success rate of this method are the preservation of an intact arterial network allowing normal blood flow to the ileocolic area, and the ability to quantify blood flow using a Doppler pulse flow meter. The preservation of the right colic artery is

important, because its interruption would reduce blood supply to the long ileum segment. Between July 2003 and October 2008, we used this method in 6 patients in whom a gastric tube was not an option. We assessed perioperative morbidity and swallowing difficulties in each patient, quantifying dysphagia on scale of 0 to 4.

**Results:** There was no mortality and no anastomotic leak. There was one wound infection and, in one patient, recurrent nerve paralysis was observed. The post-operative hospital stay was  $29.5 \pm 10.8$  days. The average dysphagia score for the 6 patients was  $0.17 \pm 0.41$  after the operation. All patients can eat normally, without any dietary limitations.

**Discussion:** Ileocolonic interposition after esophagectomy requires careful assessment of the vascular supply. In this small series morbidity was low and there was no perioperative mortality. We believe that this is an easy and safe method of reconstruction after esophagectomy in cases in whom a gastric tube cannot be used as a substitute.

**Disclosure:** All authors have declared no conflicts of interest.

#### P05.048 DIAPHRAGMATIC HERNIA AFTER OPEN AND MINIMALLY INVASIVE ESOPHAGECTOMY

Claudia Ringhofer<sup>1</sup>, Johannes Lenglinger<sup>2</sup>, Margit Eisler<sup>2</sup>, Sebastian F Schoppmann<sup>1</sup>, Gerhard Prager<sup>1</sup>, Ahmed Ba-Ssalamah<sup>1</sup>, Reza Asari<sup>1</sup>, Gerald Hlavin<sup>3</sup>, Johannes Zacherl<sup>1</sup>

<sup>1</sup>Medical University Of Vienna, Department Of Surgery, Vienna/AUSTRIA,

<sup>2</sup>Dept. Of Surgery, Vienna/AUSTRIA, <sup>3</sup>Muw, Medical Statistics, Vienna/AUSTRIA

**Background:** Since the introduction of minimally invasive esophagectomy (MIE) in our department the incidence of postoperative diaphragmatic herniation (PDH) apparently increased. The aim of our study was to evaluate the rate of PDH.

**Methods:** 153 patients who underwent MIE (n = 73) or open esophagectomy (OE, n = 80) with orthotopic gastric pull-up were included. The hiatus was not narrowed or sutured with the neoesophagus. The median time of follow up was 15.9 months (range, 1.34–96.8).

**Results:** Nine patients (5.9%) were identified with a PDH, interval until diagnosis was 7.1 months (range, 2 days–93.8) after esophagectomy. MIE and number of lymphnodes were marginally associated with PDH rate. Incidence of PDH was 2.5% (2/80) and 9.6% (7/73, p = 0.063) after OE and MIE, respectively, and 2.5% (2/79) and 10.4% (7/67, p = 0.069) in patients with a lymphnode count below (n = 79) and at or above (n = 74) the median of 18 nodes. In 5 patients elective PDH repair was performed laparoscopically. 3 patients were referred to an emergency operation. Among patients with PDH repair one patient experienced PDH recurrence 8 months after reoperation and refused a redo. In one case we found carcinosis and tumour recurrence within the hiatus and terminated the procedure without repair.

**Discussion:** Patients with MIE and a high count of harvested lymphnodes are at risk to develop a PDH. In these patients sutures between the crura and the neoesophagus or placement of posterior hiatoplasty sutures should be evaluated. Elective laparoscopic repair of PDH usually is safely feasible and is followed by a fair outcome.

**Disclosure:** J. Zacherl: Covidien, ethicon, Novartis, Pfizer, B. Braun, AMI, Nycomed-Takeda, Roche, Olympus, Medigus: Invited lecture fee, advisory board fee, sponsoring of scientific and educational meetings, workshops, expert meetings, scientific trial case fee  
All other authors have declared no conflicts of interest.

#### P05.049 IVOR LEWIS ESOPHAGECTOMY FOR ESOPHAGEAL CANCER: OUTCOME OF A FAST RECOVERY PROTOCOL

Johannes Zacherl<sup>1</sup>, Reza Asari<sup>1</sup>, Edith Fleischmann<sup>2</sup>, Barbara Kabon<sup>2</sup>, Gerhard Prager<sup>1</sup>, Franz Martin Riegler<sup>1</sup>, Sebastian F Schoppmann<sup>1</sup>

<sup>1</sup>Univ. Clinic Of Surgery, Vienna/AUSTRIA, <sup>2</sup>Univ. Clinic Of Anesthesiology, Vienna/AUSTRIA

**Background:** Esophagectomy for esophageal cancer is hampered by remarkable morbidity, hospital mortality is caused by pulmonary complications in the majority of lethal outcomes. A fast recovery protocol has been introduced to enhance recovery and to reduce postoperative morbidity.

**Methods:** Patients, who underwent Ivor Lewis esophagectomy between March 2007 and November 2011, were perioperatively treated according to a multimodal protocol. Associations between several tumour parameters, patient characteristics, surgical data and protocol failure have been evaluated.

**Results:** Ninety consecutive patients (median age 64,3 years; range 34–86 years) were included to the fast recovery protocol. Of them, 45% of patients were classified as ASA-2 and 12% as ASA-3. 73% of patients received neo-adjuvant treatment. R-0 resection rate was 89%. Median hospital stay was 12 days (range; 7–53 days), 90% of patients were immediately extubated after surgery or were ventilated shorter than one day. Postoperative major morbidity (Clavien-Dindo classification 3, 4 and 5) was 20%, respiratory mor-

bidity was 11%. Hospital mortality was 3,3%. Protocol failure was registered in 37%, readmission rate was 2,2%. Factors associated with failure were preexisting combined comorbidities, blood transfusions, thoracoscopic reconstruction and major morbidity.

**Discussion:** The fast recovery protocol was fulfilled by about two thirds of patients undergoing Ivor Lewis resection, which is a suitable procedure for a fast track management. Pulmonary complication and pneumonia rate were kept comparably low without increasing surgical complications.

**Disclosure:** J. Zacherl: Covidien, ethicon, Novartis, Pfizer, B. Braun, AMI, Nycomed-Takeda, Olympus: Invited lecture fee, advisory board fee, sponsoring of scientific and educational meetings, workshops, expert meetings, scientific trial case fee  
G. Prager: Covidien, Ethicon, AMI  
All other authors have declared no conflicts of interest.

#### P05.050 A COMPARISON OF THE EARLY QUALITY OF LIFE OUTCOMES BETWEEN OPEN AND LAPAROSCOPIC GASTRIC MOBILISATION DURING TWO-PHASE OESOPHAGECTOMY FOR CANCER

Ashok Menon, Sotonye Tolofari, Mohammed Al-Rashedy, Jennifer Stockton, Benjamin Knight, Jonathan Vickers, Laura Formela, Khurshid Akhtar, P S Senapati  
Salford Royal Hospital, Salford/UNITED KINGDOM

**Background:** Laparoscopic gastric mobilisation (LGM) is thought to be associated with lower postoperative morbidity and reduced length of hospitalization. However, there is a paucity of data comparing it with open gastric mobilisation (OGM) in terms of postoperative health-related quality of life (HRQL). This study aims to evaluate differences in HRQL between these groups in the early postoperative period.

**Methods:** The European Organisation for Research and Treatment Quality of Life Questionnaire Core 30 (EORTC QLQ-30) was administered to 20 patients preoperatively, and 1-month following two-phase oesophagectomy with OGM (n = 7), and two-phase oesophagectomy with LGM (n = 13). The thoracic phase was performed with an open approach in both groups. Mann Whitney U tests were used to compare HRQL between open and laparoscopic resections, and related-sample Wilcoxon signed rank tests were used to compare 1-month and preoperative HRQL.

**Results:** There was no significant difference in median preoperative functional and global HRQL between the LGM and OGM groups (18 v 11, p = 0.18; 10 v 11, p = 0.70). Functional HRQL worsened significantly at 1-month with OGM (18 v 11, p = 0.02), but not with LGM (15 v 18, p = 0.81). Global HRQL was significantly higher at 1-month in LGM compared with OGM (10 v 8, p = 0.03), but there were no significant differences between preoperative and 1-month global HRQL in either group.

**Discussion:** These results indicate that functional HRQL may recover to baseline levels faster with LGM compared with OGM even at 1-month, which may indicate that the laparoscopic approach is associated with faster postoperative recovery.

**Disclosure:** All authors have declared no conflicts of interest.

#### P05.051 ESOPHAGEAL BYPASS AS A STRATEGY FOR T4 ESOPHAGEAL CANCER TREATMENT

Yutaka Tokairin<sup>1</sup>, Yasuaki Nakajima<sup>2</sup>, Kenro Kawada<sup>1</sup>, Akihiko Hoshino<sup>1</sup>, Takuya Okada<sup>1</sup>, Swangsri Jirawat<sup>1</sup>, Shunsuke Ohta<sup>1</sup>, Tairo Ryotokuji<sup>1</sup>, Naoto Fujiwara<sup>1</sup>, Tetsuro Nishikage<sup>1</sup>, Kagami Nagai<sup>1</sup>, Tatsuyuki Kawano<sup>1</sup>

<sup>1</sup>Department Of Esophagogastric Surgery, Tokyo Medical And Dental University, Tokyo/JAPAN, <sup>2</sup>Tokyo Medical And Dental University, Tokyo/JAPAN

**Background:** T4 esophageal cancer cases are generally indicated for chemoradiotherapy (= CRT). However, many of the T4 cases had stenosis of the esophagus or fistula formation in the airway. The esophagus frequently narrows after CRT whether the response is good or not. As a result, esophageal bypass was performed first followed by CRT in these T4 cases.

**Methods:** The surgical technique of esophageal bypass is based on making an esophago-gastro anastomosis at the cervical area through the retrosternal route.

**Results:** The procedure has been performed in 21 cases with T4 esophageal cancer since 2002. The sex ratio was 17:4 (male/female), the mean of age was 68.3 years. Six cases had stenosis of the esophagus and 15 cases had fistula formation in the airway. Retrosternal gastric tube reconstruction was applied to 20 cases (type Y gastric tube: 8 cases) and ante-chest wall ileocecal reconstruction was applied to 1 case. Mild pneumonia was observed in four cases, empyema in one case and no suture failure. The hospital stay after the operation was 26.5 days (median), CRT was performed in 8 cases after the operation.



**Discussion:** Esophageal bypass allows patients with an airway fistula to consume food and receive CRT. This bypass method is therefore thought to be a useful therapeutic strategy for patients with T4 esophageal cancer.

**Disclosure:** All authors have declared no conflicts of interest.

#### P05.052 CRYOPRESERVATION OF THE TRACHEA CAN REDUCE ITS ANTIGENICITY WITHOUT DESQUAMATION OF EPITHELIAL LAYER

Arpad Juhász<sup>1</sup>, Sumeet Mittal<sup>2</sup>, Norbert Lippai<sup>3</sup>, Aron Altorjay<sup>1</sup>  
<sup>1</sup>St Georg University Teaching Hospital, Szekesfehervar/HUNGARY,  
<sup>2</sup>Creighton University Medical Center, Dept Of Surgery, Omaha/NE/  
UNITED STATES OF AMERICA, <sup>3</sup>Geza Hetenyi County Hospital, Dept  
Of Pathology, Szolnok/HUNGARY

**Background:** Cryopreserved tracheal allograft has been used successfully for esophageal replacement in canine model. Working hypothesis for the success was based on expected desquamation of epithelial layer and associated decreased antigenicity during cryopreservation. However cryopreservation of human tracheal samples collected at tracheostomy resulted in no significant desquamation. The aim of this study was to examine the extent of desquamation of epithelial layer of cryopreserved dog's trachea.

**Methods:** After ethical committee approval five-cm-long tracheal segments from 6 dogs were cryopreserved in liquid nitrogen for 21 days respectively. Circular samples were taken from the ends of the graft (A), 1 cm from the end (B) and from the middle of the graft (C). Histological examination was performed using haematoxylin-eosin. Thickness of the epithelial layer in each group was measured and compared.

**Results:** Histology shows that cryopreservation can shrink the epithelial layer from the ends to the midpart of the graft. Intact epithelium was found in 0/6(0%), 2/6(33%) and 6/6(100%) samples A, B and C respectively.

**Discussion:** Cryopreservation of canine trachea proceeds in a centripetal fashion from the cut edges. Loss of epithelium layer (and possibly antigenicity) at the cut edges seems sufficient to prevent graft rejection in canine model. Alternatively loss of epithelium is not central to antigenic properties of the tracheal graft. Further studies are needed before cryopreserved tracheal grafts can be used in humans.

**Disclosure:** All authors have declared no conflicts of interest.

#### P05.053 SURGICAL APPROACH TO ESOPHAGEAL SUB-MUCOSAL TUMORS.

Orli Friedman Eldar, Hanoch Kashtan  
Rabin Medical Center, Surgery B, Petach Tikva/ISRAEL

**Background:** Submucosal tumors of the gastrointestinal tract are mainly Leiomyoma or Gastro-Intestinal Stromal Tumor (GIST). Surgical resection is currently considered treatment of choice for these tumors. Tumor location at the esophagus or gastro-esophageal junction (GEJ) is rare and presents a surgical challenge.

**Methods:** A retrospective review of medical charts of patients underwent surgery for esophageal submucosal lesions between 2003–2011. We evaluated clinical presentation, diagnostic tools, type of operation, early and late complications, and long term results according to the tumor's histological type.

**Results:** A total of 11 patients (8 male, 3 females, average age 60 y) were operated due to submucosal esophageal tumor. Final histological examination demonstrated Leiomyoma in 6 patients (two of them were operated without pre-operative biopsies), and GIST in 5 patients (of which 2 patients had a pre-op biopsy of Leiomyoma). Mean tumor size was 4.17 cm for Leiomyoma and 4.8 cm for GIST. Seven patients underwent enucleation, while the other 4 had a GEJ segmental resection. There was no operative mortality, nor post-operative major complications. All 5 GIST patients had an R<sub>0</sub> resection and did not need adjuvant therapy. Mean follow up period was 27 months. All patients were alive with no evidence of recurrence.

**Discussion:** Surgical resection of esophageal submucosal tumors is safe, however enucleation is preferred over segmental resection, if it is possible technically and- in the case of GIST- R<sub>0</sub> resection can be achieved. The yield of pre-operative biopsy is unclear, its impact on surgical approach can be misleading, and it may be reserved for specific cases only.

**Disclosure:** All authors have declared no conflicts of interest.

#### P05.054 GASTRIC TUBE NECROSIS FOLLOWING MINIMALLY INVASIVE OESOPHAGECTOMY: THE EXPERIENCE OF A SPECIALIST UNIT

Lisa Ramage, Andrew Davies, Jean Deguara, Abraham Botha  
St Thomas' Hospital, London/UNITED KINGDOM

**Background:** Gastric tube necrosis is a devastating complication of oesophageal cancer surgery that has been associated with minimally invasive oesoph-

agectomy (MIO). Some suggest gastric ischaemic preconditioning may reduce ischaemic complications. Our aims are to present a series of 158 consecutive MIOs, including a number of cases of gastric tube ischaemia of which 4 (2.53%) developed frank conduit necrosis. These are discussed in order to extract any learning points.

**Methods:** Data was collected prospectively of MIOs from 2005–2011 carried out by a single surgeon. No patients underwent gastric ischaemic preconditioning. Cases of gastric tube necrosis were identified.

**Results:** 158 patients were identified. Inpatient mortality was 2.53%. Gastric tube necrosis occurred in 4 patients (2.53%). One presented with an anastomotic leak, the others with pleural effusions and chest sepsis. All returned to theatre. One died as an inpatient. An ultrasonic dissector injury to the gastro-epiploic arcade had occurred in two cases. In another, the gastric tube was strangulated within the hiatus. In the remaining case, no clear mechanical cause was identified. All 4 cases occurred within the first 73 cases of the surgical learning curve; the latter 85 being completed without event.

**Discussion:** In our series, gastric tube necrosis appears to be a learning curve issue. We would extrapolate from our most recent 85 cases that prophylactic measures such as ischemic pre-conditioning become less relevant as the operating surgeon's experience increases. Instead, meticulous attention to preserving the gastro-epiploic arcade and careful positioning of the gastric conduit through an adequately sized hiatus are key factors.

**Disclosure:** All authors have declared no conflicts of interest.

#### P05.055 PATIENT PROGNOSIS AND DISTRIBUTION OF LYMPH NODE METASTASIS IN JAPANESE PATIENTS WITH BARRETT'S ADENOCARCINOMA: COMPARISON WITH ADENOCARCINOMA AND SQUAMOUS CELL CARCINOMA OF THE ESOPHAGOGASTRIC JUNCTION

Kazuhiro Yajima<sup>1</sup>, Tatsuo Kanda<sup>1</sup>, Shin-ichi Kosugi<sup>1</sup>, Kenji Usui<sup>1</sup>, Yu Sato<sup>1</sup>, Kaoru Sakamoto<sup>1</sup>, Takashi Ishikawa<sup>1</sup>, Tsutomu Suzuki<sup>2</sup>, Katsuyoshi Hatakeyama<sup>1</sup>  
<sup>1</sup>Division Of Digestive And General Surgery, Niigata University Graduate School Of Medical And Dental Sciences, Niigata/JAPAN, <sup>2</sup>Niigata University Graduate School Of Health Sciences, Niigata/JAPAN

**Background:** The aim of this study was to clarify distribution of lymph node metastasis and the prognosis in Japanese patients with BAE.

**Methods:** Ten patients underwent potentially curable resection for BAE between 1985 and 2010. To gain a better understanding of the clinicopathological characteristics of BAE, 75 (19 adenocarcinoma; AD, 56 squamous cell carcinomas; SCC) patients with carcinoma of the esophagogastric junction (EGJ) were also included. In the present study, EGJ carcinomas were defined as tumors with an epicenter located in the lower esophagus 0–2.0 cm from the EGJ.

**Results:** Radical esophagectomy with mediastinal lymphadenectomy was performed in seven patients with BAE (70%) and in 52 patients with SCC (93%). Conversely, gastrectomy with lower esophagectomy was performed in 11 patients with AD (58%; P < 0.01). There were no significant differences in the frequency of node metastasis in the left cardia and lower mediastinum between the three groups with respective frequencies of 50% and 20% in BAE, 42% and 28% in AD, and 45% and 24% in SCC (P = 0.948 and P = 1.000). Similarly, there were no significant differences in the 5-year survival rates between the three groups: 54.0% for patients with BAE, 31.2% with AD, and 48.9% with SCC (P = 0.766).

**Discussion:** The frequency of node metastases in the lower mediastinum was high, regardless of histological type, in carcinoma of the EGJ. There were no significant differences in prognosis between the three groups. On the basis of these findings, esophagectomy with lower mediastinal lymphadenectomy is recommended for patients with BAE.

**Disclosure:** All authors have declared no conflicts of interest.

#### P05.056 OUTCOME OF SUBTOTAL ESOPHAGECTOMY FOR ESOPHAGEAL CANCER IN PATIENTS AGED 70 YEARS OR OLDER

Shunji Endo<sup>1</sup>, Nobutaka Hatanaka<sup>2</sup>, Yukinobu Yoshikawa<sup>2</sup>, Wataru Kamiike<sup>2</sup>  
<sup>1</sup>Higashiosaka City General Hospital, Higashiosaka/JAPAN, <sup>2</sup>National Hospital Organization Kure Medical Center/Chugoku Cancer Center, Kure/JAPAN

**Background:** Subtotal esophagectomy for esophageal cancer is high risk surgery, and we often hesitate to perform it in elderly patients. We reviewed outcomes of subtotal esophagectomy in patients aged 70 years or older.

**Methods:** During the past 10 years, 71 patients underwent subtotal gastrectomy for esophageal cancer in our institution, including 20 patients aged 70 years or older and 51 patients under 70 years old. We compared surgical outcomes between group A (n = 20, 70–83 years old) and group B (n = 51,

42–69 years old). Group A included 12 males and 8 females, while group B included 46 males and 5 females. Group A included significantly more females ( $p = 0.01$ ). Cancer stages showed no significant differences between the two groups.

**Results:** Postoperative complications included respiratory failure in 8 patients in group A and 5 patients in group B, and the frequency was significantly higher in group A ( $p < 0.01$ ). Delirium was recognized in 4 patients in group A only ( $p < 0.01$ ). The rate of anastomotic leakage, paralysis of recurrent nerve, and heart failure showed no significant differences between the two groups. Postoperative death for complications was experienced in 2 patients of group B. Three-year survival rate was 50% in group A, and 64% in group B, which showed no significant difference ( $p = 0.87$ ).

**Discussion:** For patients aged 70 years or older, subtotal esophagectomy may cause postoperative respiratory complications more than in younger patients, but prognosis was not significantly worse.

**Disclosure:** All authors have declared no conflicts of interest.

#### P05.057 IS THE CONCERN ABOUT THE NEGATIVE IMPACT OF NEOADJUVANT THERAPY ON EARLY SURGICAL RESULTS JUSTIFIED? OUR EXPERIENCE WITH CARCINOMA OF THE ESOPHAGUS AND ESOPHAGO-GASTRIC JUNCTION

*Alexandr Pazdro, Tomas Harustiak, Milan Smejkal, Martin Snajdauf, Robert Lischke*

*3rd Department Of Surgery, First Faculty Of Medicine, Charles University Of Prague And The Motol University Hospital, Prague/CZECH REPUBLIC*

**Background:** Preoperative chemo(radio)therapy has become a standard of care for locally advanced esophageal cancer. Its impact on improved resectability rate and long-term survival has become recognized. Deterioration of early surgical results after neoadjuvant therapy is constantly debated.

**Methods:** We retrospectively reviewed 301 operated patients. We compared the resectability rate and postoperative mortality and morbidity in three groups of patients: with no preoperative treatment (NPT,  $n = 179$ ), with neoadjuvant chemotherapy (CT,  $n = 52$ ) and with neoadjuvant chemoradiotherapy (CRT,  $n = 70$ ).

**Results:** Resection was possible in 246 patients. NPT versus CT and CRT was associated with postoperative mortality in 3.5% versus 0% ( $p = 0.333$ ) and 5.1% ( $p = 0.697$ ) respectively, postoperative morbidity in 51% versus 36% ( $p = 0.09$ ) and 63% ( $p = 0.16$ ) respectively, anastomotic leakage in 20% versus 11% ( $p = 0.186$ ) and 22% ( $p = 0.848$ ) respectively and pulmonary complications in 30% versus 15% ( $p = 0.054$ ) and 37% ( $p = 0.324$ ) respectively. Unresectable disease was intraoperatively found in 22% NPT patients, 10% CT patients and 16% CRT patients. For subgroup of esophageal adenocarcinoma ( $n = 218$ ), NPT ( $n = 136$ ) was associated with 24% rate of unresectable disease compared to 11% after CT or CRT ( $n = 82$ ,  $p = 0.021$ ).

**Discussion:** We did not notice any significant difference in the rate of early postoperative complications and mortality between patients treated with preoperative therapy and without it. In the subgroup of esophageal adenocarcinoma we observed a significant increase in resectability rate after neoadjuvant treatment.

Supported by the project (Ministry of Health, Czech Republic) for conceptual development of research organization 00064203 (University Hospital Motol, Prague, Czech Republic).

**Disclosure:** All authors have declared no conflicts of interest.

#### P05.058 THE CLINICAL VALUE OF LYMPHADENECTOMY AROUND LEFT RENAL VEIN IN SIEWERT TYPE II ADENOCARCINOMA OF THE ESOPHAGOGASTRIC JUNCTION

*Shinji Mine<sup>1</sup>, Kazuhiko Yamada<sup>2</sup>, Souya Nunobe<sup>1</sup>, Naoki Hiki<sup>1</sup>, Takeshi Sano<sup>1</sup>*

*<sup>1</sup>Department Of Gastroenterological Surgery, Cancer Institute Hospital Ariake, Tokyo/JAPAN, <sup>2</sup>Department Of Gastroenterological Surgery, Cancer Institute Hospital, Tokyo/JAPAN*

**Background:** The aim of this study is to investigate the clinical value of lymphadenectomy around left renal vein in patients with Siewert type II adenocarcinoma of the esophagogastric junction (AEG).

**Methods:** Between 1987 and 2008, 330 patients with AEG underwent surgical resection in our institution. Among these patients, a total of 156 patients with Siewert type II AEG treated by R0-I surgical resection was retrospectively investigated for the distribution of lymph node involvement and prognosis.

**Results:** 107 patients underwent total gastrectomy with D2 lymphadenectomy. 100 patients received lymphadenectomy around left renal vein area. Based on the incidences of each node involvement, the lymph node stations were divided into 3 tiers. The first tier, which was most frequently involved,

included the lymph nodes around right cardia, lesser curvature, left cardia, or left gastric artery, with involvement of 30–47%, and 5-year survival rates in patients with positive nodes were 38–48%. The lymph nodes around splenic artery, lower mediastinum, left renal vein, or celiac axis constituted the second tier, with involvement of 13–20% and 5-year survival rate of 10–30%. With regard to the lymph node around left renal vein, the incidence of involvement was 18%, and 5-year survival rate with positive node was 17%.

**Discussion:** The lymph node station around splenic artery, lower mediastinum, left renal vein, or celiac axis could be the second frequently involved tier in Siewert type II AEG. Lymphadenectomy around left renal vein should be considered in order to complete R0 resection in Siewert type II advanced AEG.

**Disclosure:** All authors have declared no conflicts of interest.

#### P05.059 ESOPHAGEAL BYPASS OPERATION PRIOR TO DEFINITIVE CHEMORADIO THERAPY IN ADVANCED ESOPHAGEAL CANCER WITH AIRWAY INVASION

*Jun Hihara, Yoichi Hamai, Manabu Emi, Yoshiro Aoki, Yoshihiro Miyata, Morihito Okada*

*Department Of Surgical Oncology, Research Institute For Radiation Biology And Medicine, Hiroshima University, Hiroshima/JAPAN*

**Background:** Advanced esophageal cancer with airway invasion is often complicated by esophagorespiratory fistulas during or after chemoradiotherapy (CRT). Covered expandable stents are usually used in such condition, however, respiratory complication and interruption of treatment will be forced. We have performed esophageal bypass operation prior to CRT in esophageal cancer with airway invasion.

**Methods:** Between 1997 and 2010, 17 patients underwent esophageal bypass operation for esophageal cancer with airway invasion. Two had symptomatic esophagobronchial fistula at initial diagnosis. All patients had radiological finding of airway invasion of primary tumor. All patients underwent esophageal bypass operation prior to CRT. Esophageal bypass was performed using gastric tube through retrosternal route and a tube esophagostomy was made from the distal esophageal stump. Patients underwent CRT at least 14 days after the operation.

**Results:** Postoperative complications were anastomotic leakage ( $n = 2$ ), recurrent laryngeal nerve paralysis ( $n = 2$ ), pneumonia ( $n = 2$ ), abdominal abscess ( $n = 2$ ) and torsion of gastric tube ( $n = 1$ ). There was no 30-day mortality and in-hospital mortality was 11.8% ( $n = 2$ ) due to cancer progression. Fourteen (82%) were able to resume normal oral food intake and 3 (18%) were able to take liquids only. The overall response rate of CRT was 64.7%. Though 4 patients developed esophagoairway fistulas during CRT, they had little respiratory symptom and could continue oral intake. MST was 10 months and 3 had more than 4 years survival.

**Discussion:** Esophageal bypass prior to CRT for patients with airway invasion was useful for completing CRT and keeping oral intake until late in the course of the disease.

**Disclosure:** All authors have declared no conflicts of interest.

#### P05.060 RESPONSE GRADES TO TELEPHONE FOLLOW-UP AND ITS INFLUENCING FACTORS FOR PATIENTS WITH ESOPHAGEAL CARCINOMA AFTER ESOPHAGECTOMY

*Qiang Gao<sup>1</sup>, Hui Shi<sup>1</sup>, Long-qi Chen<sup>2</sup>*

*<sup>1</sup>West China School Of Medicine, Chengdu/CHINA, <sup>2</sup>West China Hospital, Chengdu/CHINA*

**Background:** The primary therapeutic result and the interviewer's ability dealing with patients current health concerns might be the most important influence factors to follow-up response enthusiasm. Therefore, a well planned and strictly executed follow-up schedule with proper health instruction could be crucial to the quality of follow-up.

**Methods:** A telephone follow-up survey was conducted on patients with documented esophageal carcinoma undergoing an esophagectomy in our department from January to June of 2009. After excluding the cases lost to follow-up, the remaining patients were divided into two groups according to their or the relatives response grades to telephone follow-up as Grade I or II. The possible factors influencing the response grades were investigated by using both univariate and multivariate analyses.

**Results:** There were totally 326 patients were followed, while 26 of them were lost, with the lost to follow-up rate of 8.0%. The univariate analysis showed that at the time of follow-up, the survival status ( $\chi^2 = 35.464$ ,  $P = 0.000$ ), survival time ( $Z = -5.485$ ,  $P = 0.000$ ), complications/comorbidities ( $\chi^2 = 9.167$ ,  $P = 0.002$ ), TNM stages ( $\chi^2 = 10.236$ ,  $P = 0.006$ ) and the relationship to patient ( $\chi^2 = 8.938$ ,  $P = 0.011$ ) were significantly different between two groups. The further multivariate logistic regression analysis demonstrated that only TNM stages (OR = 6.347,  $P = 0.011$ ) and complications/comorbidities (OR = 1.649,  $P = 0.048$ ) were the independent factors influencing the response grades.

**Discussion:** The primary therapeutic outcome and the interviewer's ability dealing with patients current health concerns might be the most important influence factors to follow-up response enthusiasm. Therefore, a well planned and strictly executed follow-up schedule with proper health instruction could be crucial to the quality of follow-up.

**Disclosure:** All authors have declared no conflicts of interest.

#### **P05.061 EFFECTS OF PERIOPERATIVE CORTICOSTEROID ADMINISTRATION ON POSTOPERATIVE COMPLICATIONS FOLLOWING ESOPHAGECTOMY**

Yao Chen<sup>1</sup>, Qiang Gao<sup>1</sup>, Long-qi Chen<sup>2</sup>

<sup>1</sup>West China School Of Medicine, Chengdu/CHINA, <sup>2</sup>West China Hospital, Chengdu/CHINA

**Background:** It is still controversial concerning the perioperative corticosteroid administration aiming to inhibit the inflammatory mediators. The objective of this meta-analysis is to evaluate the effects of perioperative use of corticosteroid during esophagectomy for esophageal carcinoma.

**Methods:** A comprehensive search strategy was carried out in Cochrane Central Register of Controlled Trials (CENTRAL), MEDLINE, EMBASE, three Chinese databases (CBM, CNKI and VIP). Including eligible studies confined to randomized clinical trial (RCT). Participants must be the patients undergoing esophagectomy. The intervention was perioperative corticosteroid administration, and the control group received a placebo infusion, such as saline water. The evaluated factors included postoperative complications and the variation of inflammatory mediators. All extracted data were meta-analyzed using Review Manager 5.1 software.

**Results:** After scanning obtained studies, only 6 eligible studies were selected. The following parameters all showed significant reduction with the use of methylprednisolone: IL-6 immediately after operation, postoperative day 1 (POD1), and POD 3, IL-8 immediately after operation and PaO<sub>2</sub>/FiO<sub>2</sub> on POD3. Moreover, any organ failure, cardiovascular complications and pulmonary morbidities were all less frequently seen in patients with corticosteroid usage. However, the remaining factors showed no statistical differences, IL-8 on POD1, IL-6 before operation and on POD5, PaO<sub>2</sub>/FiO<sub>2</sub> after operation, mortality, anastomotic leak, severe infection, renal failure and hepatic failure.

**Discussion:** Prophylactic administration of methylprednisolone in perioperative period in esophageal carcinoma undergoing esophagectomy could probably reduce the incidence of some kinds of postoperative complications and inhibit the inflammatory reaction.

**Disclosure:** All authors have declared no conflicts of interest.

#### **P05.062 MINIMALLY INVASIVE ESOPHAGECTOMY IN PATIENTS OVER 70 YEARS**

Mazin Eljamal<sup>1</sup>, Douglas Mathisen<sup>2</sup>

<sup>1</sup>Prince Hamzah Hospital, Amman/JORDAN, <sup>2</sup>Mass General Hospital, Boston/UNITED STATES OF AMERICA

**Background:** To assess the feasibility of esophagectomy for esophageal cancer in patients over 70 years, and to study the outcome in these patients, including those who received pre-, postoperative chemoradiation therapy or both, and who did not receive it.

**Methods:** During a 10-year period (1990–2000) 114 patients with carcinoma of the esophagus were treated at our institution. The outcome and results of surgery and pre- and postoperative chemoradiation, and survival were studied and analyzed.

**Results:** Mean age of the patients was 75.7 years. The main symptom was dysphagia. The tumor was removed through left thoracoabdominal, Iver-Lewis, three-hole incision or transhiatal approach. The final diagnosis was adenocarcinoma / adenocarcinoma in Barrett's in 80% of patients. Squamous cell carcinoma in 17.5% and others in 2.5% of the patients. We did not have intraoperative deaths. There were 4 perioperative deaths, related to respiratory, renal failure or mesenteric occlusion. 61% of patients received pre-, postoperative chemoradiation therapy, or both, according to the surgeon's preference, patient's condition or acceptance. Mean follow-up time was 7.5 years. 48.3% survived over 5 years, of which 14.9% lived over 10 years, while 51.7% died within five years after surgery.

**Discussion:** Surgical treatment, with or without chemoradiation therapy, for esophageal carcinoma in patients aged 70 years and over (Whose age was considered a relative contraindication for surgery in the past) is a safe procedure, feasible, justified and well tolerated in this group of patients (Low morbidity and mortality) with good results, including improvement of quality of life, and a significant long-term survival.

**Disclosure:** All authors have declared no conflicts of interest.

#### **P05.063 OVERWEIGHT PATIENTS OPERATED ON FOR CANCER OF THE ESOPHAGUS SURVIVE LONGER THAN NORMAL WEIGHT PATIENTS**

Matteo Cagol<sup>1</sup>, Carlo Castoro<sup>2</sup>, Marco Scarpa<sup>1</sup>, Rita Alfieri<sup>1</sup>, Francesco Cavallin<sup>1</sup>, Silvia Bettin<sup>1</sup>, Elisabetta Trevellin<sup>1</sup>, Alberto Ruol<sup>1</sup>, Roberto Vettor<sup>1</sup>, Ermanno Ancona<sup>3</sup>

<sup>1</sup>Surgical Oncology, Veneto Oncological Institute, Padua/ITALY, <sup>2</sup>Veneto Institute Of Oncology, Padua/ITALY, <sup>3</sup>University Of Padua, Department Of Surgical And Gastroenterological Sciences, Clinica Chirurgica 1, Padua/ITALY

**Background:** Esophageal adenocarcinoma is often associated to obesity. The aim of this study was assess the surgical and oncological outcome and the survival of overweight and obese patients with esophageal cancer.

**Methods:** Data of 1127 patients with esophageal cancer presenting from 2000 to 2008 at the Regional Center of the Esophageal Diseases were prospectively collected. Detailed anthropometric data about the BMI before the disease onset were available for 464 patients who were then included in this study. Sixty seven of them were classified as obese (BMI > 30), 199 were classified as overweight (BMI 25–29.9) and 168 were classified as normal weight (BMI < 24.9). Outcome and survival of the three groups were compared. Frequency and survival analysis were preformed.

**Results:** No significant difference was observed among the three groups in term of disease survival. At multivariate survival analysis the only independent predictors of overall survival after radical esophagectomy were a BMI between 25 and 29.9 [HR = 0.63(0.43–0.93), p = 0.02], pT stage 3 or 4 [HR = 2.13 (1.34–3.26), p < 0.01] and pN 1 status [HR = 1.84 (1.20–2.82), p < 0.01].

**Discussion:** Overweight patients seem to cope better with esophageal cancer and esophagectomy than normal weight patients. This data seem to suggest that in spite of several unfavorable features a moderate increase of weight may be helpful to survive after esophagectomy for cancer.

**Disclosure:** All authors have declared no conflicts of interest.

#### **P05.064 NEWLY DEVELOPED THORACOSCOPIC INTRATHORACIC ESOPHAGOGASTRIC ANASTOMOSIS IN ESOPHAGEAL CANCER SURGERY**

Hiroya Takeuchi, Hirofumi Kawakubo, Tai Omori, Yuko Kitagawa  
Department Of Surgery, School Of Medicine, Keio University, Tokyo/ JAPAN

**Background:** We recently developed an easy and secure thoracoscopic intrathoracic esophagogastric anastomosis procedure that uses a circular stapler with transoral placement of the anvil for patients with esophageal cancer who underwent thoracoscopic esophagectomy.

**Methods:** After the thoracoscopic esophagectomy, the esophagus was transected obliquely at the level of upper posterior mediastinum using a linear stapler. Orvil<sup>TM</sup> was placed at the edge of the staple line of the esophageal stump, which was relatively at an acute angle to the stump. Next the gastric conduit was pulled through the esophageal hiatus into the right thoracic cavity. The shaft of a 25-mm circular stapler was inserted and placed into the gastric conduit from the gastrotomy. Circular stapling was undertaken in a conventional manner thoracoscopically. The access opening on the stump of the gastric conduit was closed with a linear stapler intracorporally.

**Results:** The anastomotic procedure was completed in 21 patients. Intraoperative complications or conversions to open surgery from thoracoscopic surgery were not observed in any patient. There were no severe postoperative complications, such as anastomotic leaks or gastric conduit necrosis. Postoperatively, 1 patient (4.8%) experienced temporary anastomotic stenosis, which was successfully treated by endoscopic balloon dilation several times in the outpatient clinic.

**Discussion:** The current study revealed that our novel thoracoscopic intrathoracic esophagogastric anastomosis was technically easy and safe with minimal morbidity. This novel procedure is feasible and reliable as minimally invasive surgery for patients with thoracic esophageal cancer.

**Disclosure:** All authors have declared no conflicts of interest.

#### **P05.065 THE INFLUENCE OF YOUNG AGE ON OUTCOME AFTER OESOPHAGECTOMY FOR CANCER**

Anna Van Nistelrooij, Jan Van Lanschot, M Spaander, H Tilanus, Bas Wijnhoven  
Erasmus Medical Centre, Rotterdam/NETHERLANDS

**Background:** The incidence of oesophageal cancer rises among all age groups. Controversy exists about the clinical presentation and prognosis of young patients. The aim of this study was to compare the clinicopathological

characteristics and outcome after surgery between patients aged  $\leq 50$  years and patients aged  $>50$  years with oesophageal cancer.

**Methods:** Patients diagnosed with oesophageal carcinoma who underwent oesophagectomy in January 1990 to December 2010 in a single institution were selected from a prospective database. Patients aged  $\leq 50$  years at diagnosis ( $n = 163$ ) were compared with those  $>50$  years ( $n = 1151$ ) with respect to clinicopathological stage and oncological outcome.

**Results:** Younger patients had less co-morbidity ( $p < 0.001$ ). There were no significant differences in tumour location, histology, differentiation and TNM-stage. In both groups, 37% of the patients underwent neoadjuvant chemo(radio)therapy. In the older group 53% developed one or more non-surgical complications vs. 42% in the younger-aged group ( $p = 0.012$ ). In-hospital mortality was 6.3% for patients over 50 years compared to 1.8% for younger patients ( $p = 0.021$ ). While 5-year overall survival was significantly better for the younger patients as compared to the elderly (41% vs. 31%,  $p < 0.001$ ), median disease-specific and disease-free survival did not differ between both groups (36 vs. 29 months,  $p = 0.105$  and 49 vs. 28 months,  $p = 0.079$  respectively). Multivariate analysis identified age, co-morbidity, surgical complications, tumour differentiation, resection margins and TNM-stage as independent predictors of overall survival.

**Discussion:** A considerable proportion (12%) of patients diagnosed with resectable oesophageal carcinoma aged  $\leq 50$  years. Phenotypic tumour characteristics were comparable for both age groups as well as the disease-specific survival.

**Disclosure:** All authors have declared no conflicts of interest.

#### P05.066 CORRELATION OF POSITRON EMISSION TOMOGRAPHY AND ENDOSCOPIC ULTRASOUND WITH PATHOLOGY IN PATIENTS UNDERGOING NEOADJUVANT THERAPY FOR ESOPHAGEAL CANCER

Susanne Carpenter<sup>1</sup>, Dawn Jaroszewski<sup>1</sup>, Chee-chee Stucky<sup>2</sup>, Helen Ross<sup>2</sup>, Harshita Paripati<sup>2</sup>, Jonathan Ashman<sup>2</sup>, Kristi Harold<sup>2</sup>

<sup>1</sup>Mayo Clinic Arizona, Phoenix/UNITED STATES OF AMERICA, <sup>2</sup>Mayo Clinic Arizona, Phoenix/AZI/UNITED STATES OF AMERICA

**Background:** Optimal staging modalities following neoadjuvant chemoradiotherapy (nCRT) for esophageal cancer are controversial. This study examines experience with endoscopic ultrasound (EUS) and positron emission tomography/computed tomography (PET/CT) in patients undergoing nCRT for esophageal cancer.

**Methods:** This retrospective review comprised all patients treated for esophageal carcinoma with neoadjuvant chemoradiotherapy (nCRT) and mini-

mally invasive esophagectomy (MIE) at Mayo Clinic in Arizona from November 2006-November 2011.

**Results:** 64(65%) patients underwent nCRT prior to MIE. 57(89%) underwent EUS, and 64(100%) underwent PET/CT prior to receiving nCRT. The distribution of patients by pre-treatment stage was as follows: 7(11%) stage IIa, 6(9%) stage IIb, 42(66%) stage III, and 9(14%) IVa. The majority of patients received concurrent nCRT with a platinum plus a fluoropyrimidine alone 13(20%) or with paclitaxel 34(53%). The median radiation dose was 50.4 Gy. Following nCRT, 7(11%) patients underwent repeat EUS and 58(91%) patients underwent repeat PET/CT. Maximum nodal or tumor standardized uptake value (SUV) decreased in 47(73%) patients. In the 7 patients who underwent repeat EUS, 4 demonstrated improved and 3 demonstrated stable post-nCRT disease, and all had decreased SUV on PET. Overall, 48(75%) patients were downstaged on final pathology (71% of those undergoing repeat EUS and 79% of those who were downstaged by PET).

**Discussion:** PET/CT can underestimate residual disease burden following nCRT. Further studies are needed using combination of EUS and PET/CT to stage patients after nCRT in order to determine the potential clinical applicability of these two modalities together.

**Disclosure:** All authors have declared no conflicts of interest.

#### P05.067 PREOPERATIVE TRUNCAL MUSCLE MASS IS A MARKER OF SURVIVAL FOLLOWING ESOPHAGECTOMY FOR CANCER

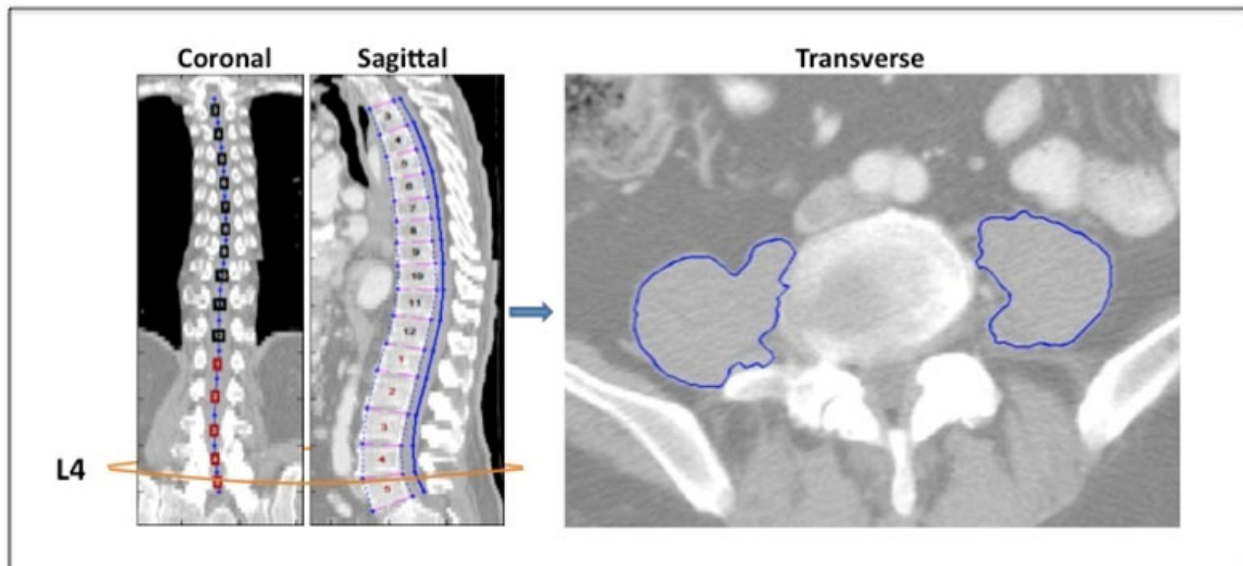
Andrew Chang, Kyle Sheetz, Lili Zhao, Sven Holcombe, Stewart Wang,

Rishindra Reddy, Jules Lin, Mark Orringer

University Of Michigan, Ann Arbor/UNITED STATES OF AMERICA

**Background:** Preoperative risk assessment, particularly for patient frailty, remains largely subjective. This study evaluated the relationship between truncal muscle mass and patient outcomes following esophagectomy for malignancy.

**Methods:** Using preoperative computed tomography(CT) scans in 230 subjects undergoing transhiatal esophagectomy for cancer between 2001 and 2010, lean psoas muscle cross-sectional area(LPA) was determined (Figure) as a measure of truncal muscle mass. Cox proportional hazards regression was employed to analyze overall(OS) and disease-free survival(DFS). Akaike Information Criterion was used to determine model strength. A cohort of 57 subjects received neoadjuvant chemoradiation(NCRT) in a phase II clinical trial. For this smaller cohort, staging(pre-NCRT) and re-staging(pre-operative) CT scans were reviewed to obtain serial LPA measurements.



**Results:** In multivariate analysis controlling for patient and tumor characteristics, among subjects who had not received NCRT, increasing LPA correlated with improved OS (HR 0.340, 95% CI 0.118–0.933) and DFS (HR 0.369, 95% CI 0.144–0.918). LPA was of equivalent or higher significance than stage. LPA did not correlate with perioperative outcomes. LPA was not predictive of survival among patients receiving NCRT. In the clinical trial cohort higher preoperative LPA was associated with improved OS (HR 0.360, 95% CI 0.146–0.828), independent of post-treatment stage.

**Discussion:** LPA appears to be an independent predictor of overall and disease-free survival, equivalent to tumor stage, in patients undergoing esophagectomy for malignancy. Changes in muscle mass during preoperative treatment may confound this relationship. Assessment of truncal muscle mass, such as lean psoas area, may provide an objective measure for risk stratification prior to esophagectomy.

**Disclosure:** All authors have declared no conflicts of interest.

**P05.068 COMPARISON BETWEEN RETROSTERNAL AND POSTERIOR MEDIASTINAL GASTRIC TUBE RECONSTRUCTION AFTER ESOPHAGECTOMY FOR ESOPHAGEAL CARCINOMA AT THREE HIGH VOLUME CENTERS**

Makoto Yamasaki<sup>1</sup>, Hiroshi Miyata<sup>1</sup>, Takushi Yasuda<sup>2</sup>, Osamu Shiraiishi<sup>2</sup>, Tsuyoshi Takahashi<sup>3</sup>, Masaaki Motoori<sup>4</sup>, Masahiko Yano<sup>4</sup>, Masaki Mori<sup>1</sup>, Yuichiro Doki<sup>1</sup>

<sup>1</sup>Departments Of Gastroenterological Surgery, Graduate School Of Medicine, Osaka University, Suita Osaka/JAPAN, <sup>2</sup>Department Of Surgery, Kinki University School Of Medicine, Osaka/JAPAN, <sup>3</sup>Department Of Gastroenterological Surgery, Graduate School Of Medicine, Osaka University, Suita Osaka/JAPAN, <sup>4</sup>Osaka Medical Center For Cancer And Cardiovascular Diseases, Osaka, Japan., Osaka/JAPAN

**Background:** To assess the impact of the route of gastric conduit reconstruction after esophagectomy for esophageal cancer on postoperative outcome. Reconstruction after esophagectomy is mainly performed through the retrosternum (RS) or posterior mediastinum (PM). However, there is still controversy regarding the best approach.

**Methods:** 299 patients who underwent radical esophagectomy for esophageal cancer at three high volume centers between 2008 and 2009 were analyzed. Among them, RS was selected in 167 patients and PM in 118, while the antethoracic route was used in 14 patients. Postoperative morbidity, mortality, and long-term outcome were compared.

**Results:** There were no differences between patients of the two route groups with respect to operative blood loss (RS: 753 ± 519, PM: 748 ± 414 g), postoperative complications such as pulmonary complications (RS: 15%, PM: 10.2%), anastomotic leakage (RS: 9.0%, PM: 5.1%) and vocal cord palsy (RS: 12.6%, PM: 13.6%), while the operating time (RS: 566 ± 97, PM: 472 ± 79 min; p < 0.0001) was shorter in PM than RS. The proportion of patients who lost weight after surgery was significantly less in the PM than RS at 6 months (10.0%, 12.0%; p = 0.04) and 1 year (8.6% versus 11.1%; p = 0.025). Multivariable analysis identified preoperative BMI and reconstruction route as significant and independent factors associated with long-term weight loss.

**Discussion:** The results indicate that gastric tube reconstruction through the posterior mediastinal route after esophagectomy can prevent postoperative malnutrition without increasing postoperative complications.

**Disclosure:** All authors have declared no conflicts of interest.

**P05.069 MINIMALLY INVASIVE ESOPHAGECTOMY: EXPERIENCE OF 136 CASES IN A HIGH-VOLUME CENTER**  
Yosuke Izumi, Tomoyoshi Suzuki, Akinori Miura, Tsuyoshi Kato  
Department Of Surgery, Tokyo Metropolitan Cancer And Infectious Diseases Center, Komagome Hospital, Tokyo/JAPAN

**Background:** MIE has potential advantages, as well as disadvantages that need to be addressed. The aim of this study was to assess our outcomes and report detailed results in a high volume center.

**Methods:** From 2000 to 2010, MIE was performed in 136 patients. Procedures included a combined thoracoscopic/laparoscopic approach (CTL) for intrathoracic esophageal cancer (105 cases) and a laparoscopic transhiatal (LTH) approach for cancer located at the esophago-gastric junction (31 cases). Short-term and long-term outcomes were investigated.

**Results:** The median postoperative hospital stay was 16 (range, 10–79) days. A total of 37 patients underwent neoadjuvant therapy. Morbidities included pneumonia (7 cases, 5.1%), recurrent laryngeal nerve palsy (15 cases, 14%), and anastomotic leakage (5 cases, 3.7%). There was no 30-day mortality. The mean operative time was 474 minutes for CTL and 254 minutes for LTH. The mean blood loss was 432 ml for CTL and 254 minutes for LTH. The mean blood loss was 432 ml for CTL and 351 ml for LTH. The 5-year survival rate was 100% for Stage 0, 96.9% for Stage I, 84.9% for Stage II, 44.7% for Stage III, and 30% for Stage IVA. The recurrence sites were local in 8 and distant in 11 cases.

**Discussion:** The 5-year survival rate with MIE seemed to be equivalent to those of open esophagectomy with fewer complications. In conclusion, a high-volume center with extensive experience doing MIE should continue to use this approach with modifications dependent on new technology as one component of multidisciplinary strategy for esophageal cancer.

**Disclosure:** All authors have declared no conflicts of interest.

**P05.070 RECURRENCE PATTERNS AFTER ESOPHAGECTOMY FOR SQUAMOUS CELL CARCINOMA**

Jun Feng Liu  
Department Of Thoracic Surgery, Fourth Hospital, Hebei Medical University, Shijiazhuang/CHINA

**Background:** This study was conducted to investigate the recurrence patterns of esophageal cancer after surgery in order to improve treatment option and recurrence control.

**Methods:** From January 2007 to August 2007, 204 consecutive outpatients who underwent esophagectomy for squamous cell carcinoma. These included 144 males and 60 females, mean age being 60.6 years. Esophagectomy with 2-field lymphadenectomy through left thoracotomy was performed. There were 8 patients with stage 0 disease, 20 stage I, 83 stage IIa, 12 stage IIb, 44 stage IIIa, and 37 stage IIIb disease. Disease free survival (DFS) was analyzed with Kaplan-Meier method.

**Results:** The median follow-up time was 17.6 month. Twenty nine patients were found with recurrence or metastasis, including supraclavicular lymph node metastasis in 9 patients, mediastinal lymph node metastasis in 9 including 5 with recurrent nerve paralysis, metastasis in the liver in 5 and in the lungs in 2, and metastasis to the thyroid, the cervical vertebrae, the celiac lymph node and recurrence at anastomosis in 1 patient, respectively. DFS was 88.4 months, and the median time for recurrence or metastasis was 17.7 months. There are no metastasis and recurrence in patients with stage 0 disease (0/8), 5.0% (1/20) in stage I disease, 9.6% (8/83) in stage IIa, 25.0% (3/12) in stage IIb, 18.1% (8/44) in stage IIIa, and 24.3% (9/37) in stage IIIb.

**Discussion:** Supraclavicular and mediastinal lymph nodes and liver are the major targeted tissue or organ for esophageal cancer metastasis. Patients with stage IIb or more advanced disease are the risk population for the metastasis.

**Disclosure:** All authors have declared no conflicts of interest.

**P05.071 MINIMALLY INVASIVE ESOPHAGECTOMY FOR ESOPHAGOGASTRIC JUNCTION (EGJ) ADENOCARCINOMA: RESULTS ON 61 CONSECUTIVE HYBRID IVOR-LEWIS OPERATION**

Stefano Santi, Giovanni Pallabazzer, Biagio Solito, Simone D'Imporzano  
Azienda Ospedaliero Universitaria Pisana, PISA/ITALY

**Background:** In the last 20 years EGJ adenocarcinoma is dramatically increased and nowadays is the most frequent indication for esophagectomy. In the same years minimally invasive (MI) procedures have been widely applied to esophagectomy. Ivor-Lewis operation (ILs) represent our preferred approach. Even if a totally MI – ILs has been described concerns remains on the safety of intrathoracic anastomosis. The present study evaluate feasibility, postoperative outcome and mid term oncological results of hybrid Ivor Lewis (Hy-ILs) approach to EGJ cancer

**Methods:** From 2002 to 2011 66 patients were submitted to an Hy-ILs operation for EGJ adenocarcinoma. Mean age was 65 year (39–85). The tumor Siewert classification was type 1: 42 and type 2I: 19 38 patients (61%) were locally advanced (>T2 N1). A neoadjuvant treatment was performed in 25% of the patients.

**Results:** 3 patients (4,7%) were excluded because occult peritoneal metastases founded during laparoscopic exploration. There were 2 conversion due to adhesion. Therefore, for this study, we considered 61 patients. Operative time was 315' (270–445). Mean blood loss was 310 cc (250–650 cc) ICU stay was 24 hour (12–240) and Hospital stay was 13 days (10–45). The mean harvested lymph node was 23 (3–45) Mortality was 0% ; overall morbidity was 32% and respiratory complications was 7,8%. 3 and 5 year survival rate was 53% and 47%.

**Discussion:** In our opinion laparoscopic approach to EGJ adenocarcinoma is safe, may avoid operation in patients with occult hepatic or peritoneal disease, and present adequate oncological results.

**Disclosure:** All authors have declared no conflicts of interest.

**P05.072 EARLY RELAPSE AND COMPLETE RESPONSE TO IMATINIB IN A CASE OF OPERATED OESOPHAGEAL MALIGNANT STROMAL TUMOUR.**

Maria Garcia Avila<sup>1</sup>, Rafael Lopez Pardo<sup>1</sup>, Jorge Villanueva Garcia<sup>2</sup>, Zoe De Julian<sup>1</sup>, Cristina Lopez Gonzalez<sup>1</sup>, Carlos Nieto Lopez<sup>1</sup>, Iñaki Fraile<sup>1</sup>

<sup>1</sup>Hospital Virgen De La Salud, Toledo/SPAIN, <sup>2</sup>Hospita Virgen De La Salud, Toledo/SPAIN

**Background:** Gastrointestinal stromal tumours (GIST) is the most frequent mesenchymal neoplasm in digestive tract (1–3%), originated in C-kit proto-oncogen mutation. Oesophageal localization is very infrequent (1–3% GIST) and difficult to diagnose and treat. We present a case of a high grade oesophageal GIST treated surgically in 2004, with an early relapse and complete response to Imatinib till actual date.

**Methods:** We present a case of a 56 years male consulting for dysphagia and bradycardia. Cardiac echography revealed a 7 cm retrocardiac mass. Ultrasonographic endoscopy described a 7 cm heterogenic mass originated in muscular layer of distal oesophagus. Endoscopic biopsy was normal. Tomography showed no other findings neither other organs involvement.

**Results:** Surgery was performed on July 2004. Transhiatal oesophagectomy was carried out but tumour pseudocapsule was disrupted. Pathological

analysis showed a 7 cm GIST with 40 mitosis per 50 hpf. Three months later, patient consulted for pleural effusion. Tomography showed 13 cm mass located at diaphragmatic hiatus comprising inferior cava vein. Pleural liquid cytology was normal. Imatinib treatment was given at 400 mg per day. Complete radiological response was achieved until actual date.

**Discussion:** Oesophageal location for GIST is quite unfrequent. Although preoperative treatment with Imatinib in large masses is desirable, in our case this possibility was not established. Early relapse and complete response to Imatinib during 8 years in a high grade GIST, demonstrate that multimodal treatment in this type of tumour has to be always initially set.

**Disclosure:** All authors have declared no conflicts of interest.

#### P05.073 INCOMPLETE RESECTION (R2) VS EXPLORATORY THORACOTOMY FOR T4 ESOPHAGEAL CARCINOMA

Yukiko Niwa, Harushi Osugi, Shigeru Lee, Satoru Kishida, Masato Okawa, Ken Gyobu, Yasunori Matsuda, Eijiro Edagawa  
*Department Of Gastroenterological Surgery, Osaka City University Graduate School Of Medicine, Osaka/JAPAN*

**Background:** As preoperative assessment and diagnosis of local extent of the primary tumor to other organ (T4) had limitation, we sometimes diagnose unresectable esophageal carcinoma by intraoperative findings. The aim of this study was to decide treatment strategy of surgical T4 esophageal carcinoma.

**Methods:** We reviewed retrospectively 21 patients with squamous cell carcinoma underwent operation for T4 thoracic esophageal carcinoma from 2007 to 2011 in our institution. 17 patients were underwent incomplete resection (R-group) and 4 patients were underwent exploratory thoracotomy (N-group).

**Results:** The mean age, tumor location in the proximal/middle/distal 1/3 of the thoracic esophagus was 62 years (range: 47–72), 0/12/5 in R-group and 56 years (46–80), 1/3/0 in N-group, respectively.

Induction therapy was administered in 10 (59%) patients (chemotherapy:8, chemoradiotherapy:2) and 1 patient in N group (chemotherapy). The mediastinal structure (carina/trachea/aorta/pleura/pulmonary vein/cealic artery) invaded by the primary carcinoma or lymph node metastases was in 0/6/3/3/4/1 in R-group and 2/1/1/0/0/0 in N-group. Postoperative chemoradiotherapy/chemotherapy were administered 13/9 in R-group and 4/0 patients in N-group. Follow-up ranged from 3.8 to 53 months (median, 15 months). Median survival time was 15.3 months in R- group and 21.7 months in N-group. There was no significant difference between two groups in survival ( $p = 0.54$ ).

**Discussion:** No benefit was found for reduction surgery.

**Disclosure:** All authors have declared no conflicts of interest.

#### P05.074 ENDOSCOPIC TREATMENT WITH SENTINEL NODE DISSECTION FOR SUPERFICIAL ESOPHAGEAL CANCER

Yasuto Uchikado<sup>1</sup>, Yoshikazu Uenosono<sup>1</sup>, Hiroshi Okumura<sup>2</sup>, Masataka Matsumoto<sup>1</sup>, Tetsuhiro Owaki<sup>1</sup>, Yoshiaki Kita<sup>1</sup>, Ken Sasaki<sup>2</sup>, Takaaki Arigami<sup>1</sup>, Takahiko Hagihara<sup>1</sup>, Daisuke Matsushita<sup>1</sup>, Sumiya Ishigami<sup>1</sup>, Shoji Natsugoe<sup>1</sup>

<sup>1</sup>*Department Of Digestive Surgery, Breast And Thyroid Surgery Graduate School Of Medical Sciences, Kagoshima University, Kagoshima/JAPAN,*

<sup>2</sup>*Department Of Digestive Surgery, Breast And Thyroid Surgery Graduate School Of Medical Sciences, Kagoshima University, Kagoshima/JAPAN*

**Background:** Owing to the development of endoscopic device, recently we have more safely performed endoscopic treatment for superficial esophageal cancer. In Japan, esophageal mucosal and submucosal layers are divided in to three, namely M1, M2 and M3, and SM1, SM2 and SM3. M1 and M2 cancer are applicable for endoscopic submucosal dissection (ESD) or endoscopic mucosal resection (EMR) and SM2 and SM3 for surgical treatment. However, treatment strategy is controversial for M3 and SM1 cancer. We have recently tried to do the ESD with sentinel node (SN) sampling for M3 and SM1 cancer in the esophagus.

**Methods:** Twenty-five patients with M3 and SM1 without clinical lymph node metastasis (cNO) were enrolled in this study. These patients were analyzed regarding clinicopathological factors, postoperative therapy and recurrence.

**Results:** In the pathological tumor depth, the number of patients with M1, M2, M3 and SM1 tumors was 7, 5, 9, and 4, respectively. Although lymph node metastasis was not found by routine histological examination, micrometastasis by immunostaining was detected in two SNs. Lymphatic or vascular invasion was found in 4 patients. One patient underwent esophagectomy with lymphadenectomy and the others chemoradiation therapy. During follow-up, one patient underwent additional ESD for local recurrence, however all patient is alive without recurrence.

**Discussion:** ESD with SN dissection is one of the useful method for clinical M3 and SM1 cancer without clinical nodal metastasis, because of preservation of esophagus.

**Disclosure:** All authors have declared no conflicts of interest.

#### P05.075 CLINICOPATHOLOGICAL FINDINGS FOR ADENOCARCINOMA OF THE ESOPHAGOGASTRIC JUNCTION

Masaharu Higashida, Hideo Matsumoto, Hisako Kubota, Masafumi Nakamura, Toshihiro Hirai  
*Kawasaki Medical School, Kurashiki, Okayama/JAPAN*

**Background:** The lamina muscularis mucosae in the cardia of the stomach is thin, which allows for an adenocarcinoma of the esophagogastric junction (AEG) to more rapidly invade the submucosal layer than do the other types of gastric cancer. The prognoses for AEG involving the esophagogastric junction are far worse than for of AEGs not involving this junction.

**Methods:** From April 2003 to November 2010, 40 patients with AEG were operated on our department. In the cases of extended total gastrectomy, the esophagus was resected at 5 cm from the tumor margin.

**Results:** 36 patients underwent extended total gastrectomy, and 4 patients underwent transhiatal esophagectomy. The final classifications were as follows: stage I 3; stage IIA 3; stage IIB 9; stage III 13, stage IVA 2; and stage IVB 10. Recurrences were identified in the lymph node (8 patients), in the peritoneum (6 patients), in the liver (2 patients) in the bone (1 patient) and in the skin (1 patient). 2 cases that were stage I and II showed liver metastasis within 6 months after the operation. The recurrences at the resected margin were not observed. The 3-year survival rates were stage I 50%, stage IIA 66.7%, stage IIB 60.1%, Stage III 56.2%, Stage IVA 100% and stage IVB 33.3%. Tumors were tested for HER2 status; 22.5% of patients were HER2-positive. The 3-year survival rates of patients with HER2-positive were 51%. Patients with HER2-negative were 31%.

**Discussion:** AEG revealed worse prognosis. Moreover, in early stage 2 cases revealed liver metastasis. Therefore AEG might need more aggressive adjuvant chemotherapy.

**Disclosure:** All authors have declared no conflicts of interest.

#### P05.076 THE SIGNIFICANCE OF EXTRACAPSULAR LYMPH NODE INVOLVEMENT IN NODE-POSITIVE PATIENTS WITH ADENOCARCINOMA OF THE DISTAL OESOPHAGUS AND GASTRO-OESOPHAGEAL JUNCTION

Javed Sultan, Charlotte Foley, Shajahan Wahed, Jon Shenfine, Nick Hayes, S Michael Griffin  
*Northern Oesophago-Gastric Cancer Unit, Royal Victoria Infirmary, Newcastle Upon Tyne/UNITED KINGDOM*

**Background:** Due to the limited number of studies, the aim was to assess the biological significance of extracapsular lymph node involvement (ECLNI) in patients undergoing subtotal oesophagectomy.

**Methods:** Prospective data was collected from consecutive patients undergoing radical two stage oesophagectomy for adenocarcinoma between January 2006 and March 2011. Primary endpoint was to assess the impact of ECLNI on survival compared to intracapsular nodal involvement only (ICNI) in node positive patients using Kaplan-Meier log-rank analysis.

**Results:** A total of 235 patients underwent oesophagectomy with curative intent. The median number of nodes resected was 34 (range 20–79). The median follow up was 23 months (range 10–71 months). Pathological staging included: carcinoma in situ n = 11, 1a n = 51, 1b n = 16, 2a n = 34, 2b n = 19, 3a n = 42, 3b n = 26 and 3c n = 36; thus, the number with pathological node positive disease was 123 (ECLNI n = 70, ICNI n = 53). Between the groups, there was no significant difference in those receiving neo-adjuvant chemotherapy, demographics, morbidity or hospital stay. The median survival in patients with ECLNI was 18 months (95% confidence interval, 14.4–21.6) compared with 29 months (95% confidence interval, 24.6–33.4) in those with node positive disease with ICNI only ( $p = 0.001$ ). The median survival decreases significantly with increasing ECLNI ( $p = 0.001$ ): 1 or 2 nodes 24 months, 3–6 nodes 12 months and 11 months with 7 or more nodes with extracapsular spread.

**Discussion:** The presence of ECLNI identifies a subgroup of patients with significantly poorer long-term survival. The number of ECLNI further supplies important prognostic information.

**Disclosure:** All authors have declared no conflicts of interest.

#### P05.077 NOVEL TECHNIQUES ON GASTRIC CONDUIT RECONSTRUCTION AFTER ESOPHAGECTOMY

Jiro Nakamura, Takuo Takehana, Takeshi Hasegawa, Kazuhiro Yamamoto  
*Saku Central Hospital, Saku City/JAPAN*

**Background:** Anastomotic leakage reportedly occurs in 10–30% of cases with esophagectomy for esophageal cancer. The occurrence rates are much higher than those of operations for other digestive organ cancers. As anastomotic leakage makes the patient's QOL much worse, we have to prevent leakage with scrupulous care. Having introduced some novel techniques to prevent leakage, here we present those techniques and the results.

**Methods:** In three periods, reconstruction was performed after esophagectomy with the gastric conduit in different methods. From January 2003, the subtotal gastric conduit was used (Group I). From July 2006, the subtotal gastric conduit was used with bloodletting from the short gastric vein (Group II). From July 2008, a thin gastric conduit, 3.5~4 cm wide, was used with bloodletting and preserving the rt. epiploic vein (Group III). We studied the leakage rate in each group.

**Results:** The leakage rate was 40% in Group I, 4.5% in Group II, and 0% in Group III.

**Discussion:** The most important points in preventing anastomotic leakage are good arterial supply and relief of congestion in the gastric conduit. A thin conduit is useful for good arterial supply, because we can raise the conduit more easily to a high position and make anastomosis at the lower part of the stomach. Bloodletting and the preservation of the rt. epiploic vein are useful for venous return and relief of congestion. We conclude that our novel techniques are much effective for preventing anastomotic leakage after esophagectomy.

**Disclosure:** All authors have declared no conflicts of interest.

#### P05.078 THE SURGICAL STRATEGY OF ESOPHAGEAL CANCER FOR ELDERLY PATIENTS WHO WERE OLDER THAN 75 YEARS

**Kosuke Narumiya**, Masaho Ota, Takuya Sato, Yuji Shirai, Shin Yamamoto, Hiroko Ide, Harushi Osugi, Masakazu Yamamoto  
*Institute Of Gastroenterology, Tokyo Women'S Medical University, Tokyo JAPAN*

**Background:** Esophagectomy for Esophageal cancer is one of the most invasive surgical procedures. With the recent increase in the aging population, we often encounter elderly patients with esophageal cancer. The purpose of this study was to evaluate the surgical strategy of esophageal cancer for elderly patients who are older than 75 years.

**Methods:** Between 1996 and 2010, we performed curative esophagectomy in 741 patients. 76 patients were more than 75 years old. The clinical results of 76 patients (Group 1) who underwent esophagectomy were compared with 665 patients (Group 2) who were less than 74 year old.

**Results:** The rate of Coexistence disease in Group 1 were 55% (vs 36%) which is cardiovascular disease, pulmonary dysfunction and brain disease. The rate of Cancer of synchronism were 16.9% (vs 5.6%), of the T1 and T2 were 77% (vs 39%), of the thoracotomy were 73% (vs 90%), of the location of main tumor which were in lower esophagus were 49% (vs 38%). The rate of the complication after the operation and during SIRS were almost same. The significant differences were not in mortality, morbidity or clinical outcome.

**Discussion:** We must perform the esophagectomy for the elderly patients who were selected the selected patients to maintain the same outcome between more than 75 years and less than 74 with esophageal cancer because the elderly patients with esophageal cancer have much coexistence disease and cancer of synchronism to maintain the outcome.

**Disclosure:** All authors have declared no conflicts of interest.

#### P05.079 DIAGNOSIS AND SURGICAL TREATMENT FOR ADVANCED GASTRIC CARCINOMA WITH OESOPHAGEAL INVASION – RESULTS FROM A SINGLE INSTITUTION

**Atom Katayama**, Masaru Hirata  
*Jr Tokyo General Hospital, Tokyo JAPAN*

**Background:** Left thoracoabdominal approach (LT) has often been adopted in operations for gastric carcinoma with oesophageal invasion; however, JCOG9502 study has shown that abdominal transhiatal approach (TH) would be favourable when the oesophageal invasion is within 3 cm. However, due to the possible discrepancy between preoperative findings and the pathological findings of the surgical specimen, this criterion may have some limitations.

**Methods:** There were seventeen cases of gastric carcinoma with oesophageal invasion resected at our institution between 2003–2011. The operation was performed under LT in 11, and under TH in 6 cases. Two cases had peritoneal carcinomatosis (P1) and palliative resection was performed. For patients without peritoneal carcinomatosis (P0) LT was adopted in 11, and TH in 4 cases. Clinicopathological findings were analysed.

**Results:** Overall, the length of the oesophageal invasion was accurately evaluated (<3 cm/≥3 cm) preoperatively in 59%, overestimated in 29%, and underestimated in 12% of the cases. In P0 cases the figures were 60%, 27%, 13%, respectively. In type 1–3 carcinoma the figures were 75%, 25%, 0%, and in type 4 carcinomas 43%, 29%, 29%, respectively. In P0 cases, the proximal margin (PM) was positive in none of the cases in LT and 75% in TH group (P = 0.001). The PM was positive in 13% in type 1–3 and 29% in type 4 carcinomas. There was no operative mortality. The morbidity rate was 18% in LT and 17% in TH group.

**Discussion:** LT would be a reasonable choice in selected cases, even when the oesophageal invasion is preoperatively estimated to be within 30 mm.

**Disclosure:** All authors have declared no conflicts of interest.

#### P05.080 NEOADJUVANT CHEMOTHERAPY AND TWO-STAGE OESOPHAGECTOMY FOR LOCALLY ADVANCED OESOPHAGEAL CANCER

**Shajahan Wahed**, Richard Frame, Amaran Krishnan, Javed Sultan, Jon Shenfine, S Michael Griffin  
*Northern Oesophago-Gastric Cancer Unit, Royal Victoria Infirmary, Newcastle Upon Tyne UNITED KINGDOM*

**Background:** Randomised studies have demonstrated significant survival benefits with neoadjuvant chemotherapy prior to oesophagectomy for locally advanced oesophageal cancer. This study aimed to evaluate these survival benefits in a single centre cohort of patients versus standardised radical surgery alone.

**Methods:** Patients with pre-operatively staged T3/4 or N1 (TNM6) oesophageal cancer, who underwent 2-stage oesophagectomy with radical lymphadenectomy between January 2003 and December 2008, were identified from a prospectively maintained database. Demographics, neoadjuvant chemotherapy regimen, staging, R0 resections, histology, lymph node yields and positivity were analysed. Disease-free and overall survivals were calculated using the Kaplan-Meier method.

**Results:** Oesophagectomy was performed on 307 patients, 214 of who met the inclusion criteria (171 neoadjuvant chemotherapy, 43 surgery alone). Neoadjuvant chemotherapy patients were younger (median age 63 versus 77, P < 0.001) and had higher disease stages pre-operatively (P = 0.007).

Neoadjuvant patients had more lymph nodes removed (medians 36 (29–42) versus 28 (22–40), P = 0.016). Similar R0 resections were achieved between both groups (92% and 93%, P = 0.889).

Median overall survival was higher for neoadjuvant patients (35 months 95%CI 27–43 versus 22 95%CI 3–41, P = 0.018), including when adjusted for pre-operative stage (P = 0.026). At 3 years, 85 (50%) of neoadjuvant patients and 19 (44%) surgery alone patients were alive (P = 0.496). 30-day mortality was 1.8% and 6.8% for neoadjuvant and surgery alone patients respectively (P = 0.064).

**Discussion:** This non-randomised study supports the benefits of neoadjuvant chemotherapy combined with 2-stage oesophagectomy. However, the importance of radical surgery with meticulous peri- and post-operative care was also highlighted by excellent longer-term outcomes in patients not suitable for neoadjuvant chemotherapy.

**Disclosure:** All authors have declared no conflicts of interest.

#### P05.081 RELATIONSHIP AMONG MODALITY OF NODAL METASTASIZATION AND THE PRESENCE/ABSENCE OF INTESTINAL METAPLASIA IN THE ESOPHAGUS (BE) AND IN THE STOMACH (GIM) FOR A ADENOCARCINOMA OF THE ESOPHAGUS AND CARDIA (ADEC).

**Alberto Ruffato**<sup>1</sup>, Antonietta D'Errico<sup>2</sup>, Beatrice Aramini<sup>1</sup>, Marialuisa Lugaresi<sup>1</sup>, Deborah Malvi<sup>2</sup>, Maria Rosaria Aprile<sup>3</sup>, Giandomenico Rauli<sup>1</sup>, Sandro Mattioli<sup>1</sup>

<sup>1</sup>Division Of Thoracic Surgery, Gyn Care & Research, Maria Cecilia Hospital, Cotignola (Ravenna), Center For The Study And Therapy Of Diseases Of The Esophagus. Alma Mater Studiorum – University Of Bologna, Italy, Bologna ITALY, <sup>2</sup>Department Of Oncology And Hematology, Pathology Division, "Felice Addarii" Institute, Alma Mater Studiorum – University Of Bologna, Italy, Bologna ITALY, <sup>3</sup>Division Of Pathology, Ausl Ravenna, Italy, Ravenna ITALY

**Background:** Pathogenesis of ADEC is controversial; we investigated the lymphatic spreading in a group of 194 patients consecutively operated upon for ADEC.

**Methods:** Preoperatively patients underwent the histological search for BE in mucosa surrounding ADEC and GIM in the gastric corpus and antrum mucosa. Patients in which BE was documented underwent sub total esophagectomy and gastric pull up (group 1), others underwent esophagectomy at the azygos vein + total gastrectomy with Roux Y esophagojejunostomy (group 2). Radical lymphadenectomy was identical in both procedures except for the greater curvature station.

**Results:** Histology confirmed the preoperative BE grouping which is reported with distribution of pN+ within the presence of BE in table 1. BE- tumors spread to the same abdominal stations with a higher rate of nodal metastases for GIM-adenocarcinomas (p = 0.001). Groups are not different (p > 0,05) for sex, age, mortality, morbidity, R0 resection rate and grading. Median number (IQR) of resected nodes is 29 (15–36.5) in 1 and 30 (20–40) in 2 (p = .51). GIM was detected in 4% of group 1 and in 36% of group 2 (p = 0.001). 5 year overall survival is 42%; survival tends to be worst for BE- GIM-, better for BE- GIM+.

<i>pN+</i> nodes stations	Group 1 54 pts.		Group 2 140 pts.		<i>p</i>
	#	%	#	%	
<i>Lesser curvature</i>	9	16.7	89	63.5	<b>0.001</b>
<i>Paracardiac</i>	9	16.7	43	30.7	0.07
<i>Greater curvature</i>	0	0	23	16.5	<i>ND</i>
<i>Pancreatic &amp; Pyloric</i>	0	0	11	7.8	0.07
<i>Spleen</i>	1	1.8	3	2.1	0.66
<i>Celiac Trunk</i>	3	5.5	12	8.6	0.67
<i>Hepatic Artery</i>	1	1.8	5	3.6	0.85
<i>TNM Stations 8-9</i>	18	33.3	6	4.2	<b>0.001</b>
<i>TNM Station 7</i>	2	3.7	1	0.7	0.38
<i>TNM Stations 4-3</i>	2	3.7	0	0	0.13

<i>Site of Recurrence</i>	Group 1 16 pz.		Group 2 58 pz.		<i>p</i>
	#	%	#	%	
<i>-Anastomosis</i>	2	12	8	14	0.83
<i>-Mediastinal nodes</i>	7	44	10	17	<b>0.05</b>
<i>-Lomboarctic nodes</i>	0	0	13	22	<b>0.04</b>
<i>-Distant</i>	7	44	27	47	0.94

**Discussion:** Thoracic nodal stations were involved in group 1 only, opposite to perigastric and abdominal nodes that were predominantly involved in group 2, with a more aggressive nodal involvement for BE- GIM- tumors. These data suggest the existence of three different types of tumor in ADEC, further investigation is necessary.

**Disclosure:** All authors have declared no conflicts of interest.

#### P05.082 VIDEO-ASSISTED THORACOSCOPIC ESOPHAGECTOMY COMBINED WITH PRIOR LAPAROSCOPIC TRANSHIATAL APPROACH

Hitoshi Fujiwara, Atsushi Shiozaki, Shuhei Komatsu, Daisuke Ichikawa, Kazuma Okamoto, Yasutoshi Murayama, Yoshiaki Kuriu, Hisashi Ikoma, Masayoshi Nakanishi, Toshiya Ochiai, Yukihito Kokuba, Eigo Otsuji  
Division Of Digestive Surgery, Department Of Surgery, Kyoto Prefectural University Of Medicine, Kyoto/JAPAN

**Background:** Minimally invasive esophagectomy by using video-thoroscopic technique has been widely accepted as an alternative to open surgery for esophageal cancer. However, thoroscopic manipulation at lower mediastinum in left lateral decubitus position has a difficulty in terms of ergonomics. To overcome this problem, we have introduced prior laparoscopic transhiatal approach (LTHA) since 2009. The purpose of this study is to clarify the usefulness of our transhiatal-transthoracic combination approach in video-assisted esophagectomy (VAE).

**Methods:** Perioperative outcomes of the patients who underwent VAE with prior LTHA for thoracic esophageal cancer were retrospectively analyzed. Surgical procedure: Abdominal and transhiatal manipulations are performed by HALS technique in supine position. After gastric mobilization, transhiatal esophageal mobilization with lower mediastinal lymphadenectomy is performed. After deviding abdominal esophagus, stomach roll is made and retrosternal reconstruction with cervical anastomosis is performed. Then, thoroscopic manipulation is performed in left lateral decubitus position. After deviding the azygos vein arch, esophagus is extirpated and lymphadenectomy concentrated on upper mediastinum is performed. In recent series, transhiatal use of long devices enabled secure esophageal mobilization up to the upper mediastinal level. As a result, during transhiatal approach, esophagus is easily extirpated after deviding cervical esophagus, and thoroscopic manipulation confined to upper mediastinal lymphadenectomy is possible.

**Results:** Median total operation and thoroscopic times were 372 and 100 min in VAE with LTHA, which were shorter than those in VAE without LTHA, and the number of the retrieved nodes was equal to that in open esophagectomy.

**Discussion:** VAE with prior LTHA enables efficient mediastinal lymphadenectomy with excellent ergonomics.

**Disclosure:** All authors have declared no conflicts of interest.

#### P05.083 LEFT THORACOABDOMINAL SURGERY FOR EGJ TUMORS

Masaki Ueno, Harushi Udagawa, Sachiko Kaida, Hisashi Shinohara, Syusuke Haruta  
Surgery, Tokyo/JAPAN

**Background:** We evaluated the characters of EGJ tumor using our data of left thoracoabdominal approach.

**Methods:** We performed a retrospective analysis of 236 cases who underwent R0 surgery for primary adenocarcinoma of EGJ or upper 1/3 stomach via a left thoracoabdominal approach for lower mediastinal lymph node dissection. Subjects were classified into 3 groups, Sievert type II < AEG II; 73 cases >, type III with esophageal invasion < AEG III; 61 > and type III

without esophageal invasion < AGC; 102 >. Rate of lymph nodes metastasis and survival rate is compared among the three groups.

#### Results:

	AEG II	AEG III	AGC
n = 236	73	61	102
T1/T2 deeper(T2 deeper%)	28/45 (61.6%)	4/57(93.4%)	30/72(70.6%)
LN meta -/+ (+ %)	33/40(54.8%)	14/47(77.0%)	52/48(47.1%)
Size (average)	40.0 mm	70.6 mm	52.1 mm
5-YSR	74.1%	58.6%	77.1%

AEG III were deeper, larger and marked higher LNs metastasis rate than other 2 groups. AEG II vs. III in T2 deeper; LNs meta were 80.0% vs. 80.7%, 5YSR were 64.3% vs. 55.4%. AEG III vs. AGC in T2 deeper; 5YSR = 55.4% vs. 68.4%, 5YSR of T3/T4 were 54.8 vs. 60.4, 5YSR of LNs positive cases were 57.7 vs. 64.0. Rate of mediastinal LNs metastasis were 8.2% in AEG II, 13.1% in AEG III and 0% in AGC.

**Discussion:** In the depth of the tumor is limited to T2 or deeper, the prognosis of the three groups were not significant different. AEG III showed mediastinal LNs involvement comparable to AEG II.

**Disclosure:** All authors have declared no conflicts of interest.

#### P05.084 OUR EXPERIENCE ABOUT 19 CASES OF OESOPHAGEAL ADENOCARCINOMA

Vincenzo Cavallaro, Vito Catania  
Azienda Policlinico University Of Catania, Catania/ITALY

**Background:** The adenocarcinoma of the oesophagus is a very important disease within the neoplastic pathology of the digestive tract for its no favourable prognosis and for its natural history that not only conducts to dysphagia and neoplastic wasting, but also to malnutrition, main cause of mortality. The complex anatomy of the viscera involved causes notable surgical technical difficulties.

**Methods:** The aim of our study is a comparison between the two variety of the technique according to Lewis-Santy. In the first (a) the abdominal and the thoracic steps are timely separated, in the second (b) the two steps are timely linked. 19 patients underwent to surgery: 12 patients in accord to the technique (a) and 7 patients in accord to technique (b)

**Results:** Method (a): less technique difficulties Method (b): 1) briefer operating time 2) easier gastric transposition 3) better outcome

**Discussion:** We analyse the main topics, outlining the strengths and weaknesses of the two methods

Preview and conclusion Regardless more technique difficulties, we prefer the technique timely linked

**Disclosure:** All authors have declared no conflicts of interest.

#### P05.085 IS NASOGASTRIC TUBE NECESSARY AFTER ESOPHAGECTOMY

Yang Hu<sup>1</sup>, Yong-fan Zhao<sup>2</sup>, Yong Yuan<sup>1</sup>, Xi Zheng<sup>1</sup>  
<sup>1</sup>Department Of Thoracic Surgery, West China Hospital, Sichuan University, Chengdu/CHINA, <sup>2</sup>West China Hospital, Chengdu/CHINA

**Background:** Nasogastric(NG) tube was proved to be necessary after esophagectomy because it can prevent the dilation of intra-thoracic stomach(ITS) and the postoperative Gastroesophageal reflux(GER). But the use of NG tube will bring about numerous complications and worsen the gross experience of patients. If we can limit the dilation of intra-thoracic stomach with medical sealant glue, is NG tubes still Necessary?

**Methods:** 147 patients with esophageal cancer were randomly divided into groups with NG tube and without NG tube after surgery. According to the operation mode, patients in each group were subdivided into Sweet group and Ivor Lewis group. In the operation, medical sealant glue was used to embed the stomach into mediastinum. The variables recorded for each patient included the gross feeling(with a 1-10 score system), the minimum diameter of ITS on the level of inferior pulmonary vein(with CT), the severity of GER(with Reflux Symptom Questionnaire), the need for placing/replacing the NG tube, the need for gastrointestinal prokinetic drugs, as well as the duration of postoperative hospitalization, pulmonary complications, anastomosis leak.

**Results:** After stratified analysis of operation mode, we found the gross feeling of patients is significantly worse in NG-tube group than that in without NG-tube group(p < 0.05). No difference was found in severity of GER, dilation of ITS, occurrence of complications, as well as the need for gastrointestinal prokinetic drugs and placing/replacing the NG tube between two groups.

**Discussion:** With the use of medical sealant glue to embed the stomach into mediastinum, NG tube is no longer necessary after esophagectomy.

**Disclosure:** All authors have declared no conflicts of interest.



**P05.086 ESOPHAGEAL CARCINOSARCOMA ASSOCIATED WITH REMITTING SERONEGATIVE SYMMETRICAL SYNOVITIS WITH PITTING EDEMA SYNDROME**

Reiji Saito, Takumi Kato, Yosataka Enomoto, Katsu Hirayama  
*Hiraka General Hospital, Yokote City, Akita/JAPAN*

**Background:** Remitting seronegative symmetrical synovitis with pitting edema syndrome is a rare disease characterized by the acute development in aged persons of symmetrical tenosynovitis, edema of dorsum of the hands and feet, seronegativity for rheumatoid factor, and good response to steroids.

**Methods:** We report herein a case of esophageal carcinosarcoma with remitting seronegative symmetrical synovitis with pitting edema (RS<sub>3</sub>PE) syndrome.

**Results:** A 67-year-old man was admitted to our hospital with arthralgia and edema of the upper and lower limbs, anorexia and loss in weight. From general condition, inflammatory reaction (WBC 10700 /l, CRP 6.64 mg/dl), MRI findings and seronegativity for rheumatoid factor, the diagnosis of RS<sub>3</sub>PE syndrome was made. We searched for a malignant tumor and detected a large (13 cm in size) protrusive smooth tumor in middle thoracic esophagus. The histological diagnosis of a biopsy sample was esophageal sarcoma. His conditions had getting better by oral intake of prednisone (10 mg/day). He underwent an esophagectomy in a right thoracotomy and reconstructed by a gastric tube via posterior mediastinal route. Pathological findings revealed carcinosarcoma invaded to the submucosal layer without lymph-node metastasis. Postoperative course was uneventful and the patient has been doing well without prednisone and with no recurrence at 8 months after operation.

**Discussion:** This is the first case report of esophageal carcinosarcoma with RS<sub>3</sub>PE syndrome. It is important to recognize this rare disease and rapidly search for any underlying malignant tumors.

**Disclosure:** All authors have declared no conflicts of interest.

**P05.087 HEALTH-RELATED QUALITY OF LIFE IN PATIENTS ESOPHAGEAL CANCER: PREDICTORS ANALYSIS AT THE DIFFERENT STEPS OF TREATMENT**

Marco Scarpa<sup>1</sup>, Luca Saadeh<sup>2</sup>, Rita Alfieri<sup>2</sup>, Matteo Cagol<sup>1</sup>, Alessandra Fasolo<sup>2</sup>, Giovanni Zaninotto<sup>3</sup>, Ermanno Ancona<sup>4</sup>, Carlo Castoro<sup>5</sup>  
<sup>1</sup>Veneto Institute Of Oncology, Padova/ITALY, <sup>2</sup>Surgical Oncology, Veneto Oncological Institute, Padova/ITALY, <sup>3</sup>Department Of General Surgery, Ss Giovanni E Paolo Hospital, Ulss 12, Venezia/ITALY, <sup>4</sup>University Of Padua, Department Of Surgical And Gastroenterological Sciences, Clinica Chirurgica I, Padua/ITALY, <sup>5</sup>Istituto Oncologico Veneto, Padova/ITALY

**Background:** The aim of this study was to analyze quality of life before and after esophagectomy for esophageal cancer

**Methods:** 126 consecutive patients have been enrolled in this prospective study from 2009 to 2011. The patients answered to three quality of life questionnaires at diagnosis of esophageal cancer, after the neoadjuvant therapy, after surgery and at 1, 3, 6 and 12 months after surgery. The questionnaires were administered during the hospitalization and outpatient visits. The questionnaires were the Italian version of the EORTC QLQ-C30, QLQ-OES18 and IN-PATSAT32 models. Univariate and multivariate analysis were performed.

**Results:** Global quality of life (QL2 item) improved after neoadjuvant therapy compared to the baseline levels at diagnosis, it decreased immediately after surgery and then it improved after 1 year of follow up. One year after esophagectomy QL2 item inversely correlated with postoperative complications and only these complication were independent predictor of good quality of life. Dysphagia (DYS item) improved dramatically after surgery. After surgery DYS was independently predicted by the presence of skin complication of chemo radiation, hospital stay duration and the use of jejunostomy.

**Discussion:** Even if in the short-term quality of life seems to be negatively influenced by esophagectomy after 12 months the scale returns to baseline levels. Older patients seem to cope more easily with neoadjuvant therapy while complication of chemo radiation and of surgery deeply affect quality of life at different stage of the natural history of the disease.

**Disclosure:** All authors have declared no conflicts of interest.

**P05.088 CLINICOPATHOLOGICAL RESULTS OF SQUAMOUS CELL CARCINOMA OF ESOPHAGOGASTRIC JUNCTION (ABDOMINAL ESOPHAGUS)**

Kazuhiko Yamada, Shinji Mine, Souya Nunobe, Takeshi Sano  
*Department Of Gastroenterological Surgery, Cancer Institute Hospital, Tokyo/JAPAN*

**Background:** Abdominal esophagus is very short length and near to the diaphragmatic hiatus to the orifice of the cardia of the stomach. The treatment for squamous cell carcinoma of esophagogastric junction (AeSCC) is controversial. We analyzed clinicopathological data for 50 cases of AeSCC.

**Methods:** We retrospectively reviewed the medical records of resectable 50 patients (3.2%) who underwent esophagectomy between 1987 and 2011 at the Cancer Institute Hospital. Overall survival, and the influences of various clinicopathologic prognostic factors were analyzed. Staging classification was used UICC 7th.

**Results:** Surgical approach was undergone with right thoracotomy (n = 21), left thoracotomy (n = 23), transhiatal (n = 5) and blunt dissection (n = 1). The 5-year overall survival rate was 60.1%. The rate of LN metastasis was 64% (T1: 55%, T2: 67% T3+4a: 67%). The rate of mediastinal LN metastasis was 0/30%(T1/T2-4), and that of abdominal LN metastasis was 67/64%(T1/T2-4). Univariate analysis shows that stage (Stage 1A-2B vs. 3A-C), residual tumor, venous invasion, mediastinal LN metastasis (upper, middle and lower) and the number of abdominal LN metastasis (more than 4 nodes) were influenced survival.

**Discussion:** For AeSCC patients, abdominal and mediastinal lymph node metastasis was frequent. T1 tumor might be recommended for transhiatal approach and T2-T4 tumor might be necessary for abdominal and mediastinal LN dissection with thoracotomy.

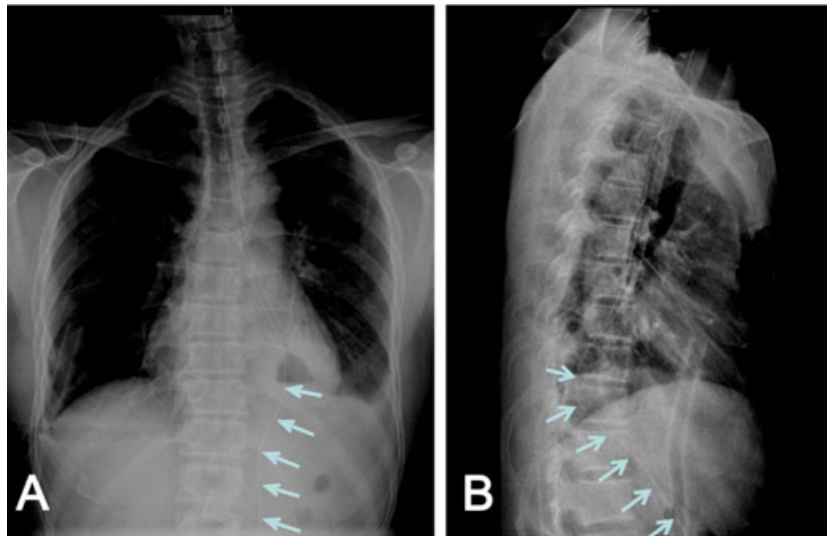
**Disclosure:** All authors have declared no conflicts of interest.

**P05.089 NONINVASIVE FORWARD NASOJEJUNAL FEEDING TUBE PLACEMENT DURING IVOR-LEWIS ESOPHAGECTOMY**

Wen-ping Wang, Kang-ning Wang, Hui Shi, Qiang Gao, Long-qi Chen  
*Department Of Thoracic Surgery, West China Hospital, Sichuan University, Chengdu/CHINA*

**Background:** Enteral feeding is now dominantly performed for postoperative nutrition and nasojejunal feeding tube is widely used. No report so far has been published on noninvasive forward nasojejunal feeding tube placement during Ivor-Lewis esophagectomy. In this study, we have improved the surgical procedures and investigated the feasibility of forward placement of nasojejunal tube during Ivor-Lewis esophagectomy.

**Methods:** Between Jan. 2010 through Jun. 2011, 54 patients with esophageal carcinoma underwent Ivor-Lewis esophagectomy in our department. The mean age was 58.8 ± 7.5 years (range, 40–74 years). General surgical procedures included briefly as follows: 1) Stomach mobilizing, enlargement of esophageal hiatus and pyloroplasty by finger squeezing via laparotomy; 2) Tubular stomach reconstruction, esophageal resection and intrathoracic esophagogastric anastomosis via right posterolateral thoracotomy; 3) Forward placement of feeding tube through patient's nostrils to the duodenum, under the guidance of surgeon's fingers that palpate the pylorus through the hiatus.



**Results:** Among all 54 patients undergoing Ivor-Lewis esophagectomy, 15 cases failed to place the feeding tube into the duodenum during surgery, with the success rate of nasojejunal feeding tube placement as 72.2% (39/54). Six patients with successful tube placement did not receive enteral feeding due to other reasons and was converted to parenteral group. There were significant differences at nutrition supportive cost, time of gastric tube retaining, serum albumin on 7th postoperative day between enteral group and parenteral group.

**Discussion:** The novel forward placement of nasojejunal feeding tube during Ivor-Lewis operation provides a noninvasive, feasible, simple and economical method for postoperative nutrition support.

**Disclosure:** All authors have declared no conflicts of interest.

#### P05.090 TRANSCERVICAL ENDOSCOPIC ESOPHAGEAL MOBILIZATION DURING TRANSHIATAL ESOPHAGECTOMY

William Tisol<sup>1</sup>, Mario Gasparri<sup>1</sup>, George Haasler<sup>1</sup>, Daryl Pearlstein<sup>2</sup>  
<sup>1</sup>Medical College Of Wisconsin, Milwaukee/UNITED STATES OF AMERICA, <sup>2</sup>Medical College Of Wisconsin, Milwaukee/WI/UNITED STATES OF AMERICA

**Background:** The transhiatal esophagectomy (THE) is limited by blind blunt mobilization of the esophagus and the inability to perform thoracic lymphadenectomy. Techniques for transcervical endoscopic esophageal mobilization (TEEM) during THE are sporadically reported in the literature. Conceptually, the idea is appealing as it allows for esophageal mobilization under direct visualization and for thoracic lymphadenectomy. Our technique for TEEM during THE is described and results are reported.

**Methods:** A retrospective review of a prospectively maintained quality assurance database identified 51 patients who underwent TEEM during THE over a 26 month period (7/2009–9/2011). The technique involves esophageal mobilization through a left cervical incision using endoscopic vein harvesting instrumentation. Dissection planes are developed circumferentially around the esophagus from the thoracic inlet to the diaphragm hiatus under direct vision. Paraesophageal vessels and thoracic lymph nodes are dissected using bipolar electrocautery.

**Results:** Surgical indications included 48 patients with esophageal carcinoma, 2 patients with end-stage achalasia, and 1 patient with gastroesophageal disruption. All patients underwent successful TEEM without conversion to alternative techniques. Thoracic lymphadenectomy was performed in 35 patients with 4.5 thoracic lymph nodes biopsied per patient. Mean operative time was 172 minutes and mean estimated blood loss was 370 ml. Anastomotic leak developed in 4 patients and 1 death occurred in the peri-operative period.

**Discussion:** TEEM is a safe and efficient adjunct to THE. The technique offers esophageal dissection under direct vision, efficient operative times, low intraoperative blood loss and the opportunity for thoracic lymphadenectomy that would not be possible during traditional THE.

**Disclosure:** All authors have declared no conflicts of interest.

#### P05.091 A NEW METHOD FOR TREATING INTRACTABLE CHYLOTHORAX AFTER ESOPHAGECTOMY

Yang Hu<sup>1</sup>, Yong-fan Zhao<sup>2</sup>, Yong Yuan<sup>1</sup>, Xi Zheng<sup>1</sup>  
<sup>1</sup>Department Of Thoracic Surgery, West China Hospital, Sichuan University, Chengdu/CHINA, <sup>2</sup>West China Hospital, Chengdu/CHINA

**Background:** To confirm the assumption that chylothorax after esophagectomy could be treated with increasing pressure surrounding the crevasses of thoracic duct.

**Methods:** 10 patients of chylothorax after esophagectomy were enrolled. Conservative treatment including drainage and total parental nutrition failed in all 10 patients. Secondary thoracic duct ligation given to 4 patients also failed. Low-fat diet was given after enrollment. Except for drainage, intrathoracic injection of 50% glucose solution was given everyday to form adhesion. After 7 days, no matter how much the drainage was, the chest tube was removed and normal diet was given. X ray film was repeated to record the change of the fluid in chest on 0, 2, 7 and 14days after tube removal. If there's no significant increasing in pleural fluid, the patient would discharge.

**Results:** After tube removal, no increasing in pleural fluid was documented in 5 patients. Increasing was found in other 5 patients. But pleural fluid decreased without any treatment in all these 5 patients 14 days after tube removal. No recurrence of chyle leak was recorded when followed up.

**Discussion:** The potential space in thoracic cavity is very limited for the rigid chest wall and the intrathoracic adhesion. When stopping drainage, the pressure surrounding the crevasses of thoracic duct will soon increase for the accumulation of fluid. Once the pressure surrounding the crevasses reaches that in chyle vessel, the leakage of chyle will stop. Then the break will heal. We think any postoperative even traumatic chylothorax could be treated with this method.

**Disclosure:** All authors have declared no conflicts of interest.

#### P05.092 CERVICAL ANASTOMOSIS IN ESOPHAGEAL CANCER

Miguel Calle Baraja, Ohiane Gutierrez, Iñaki Martinez, Hector Marin, Jose Ignacio Santidrian, Jesús Maria Oleagoitia, Alberto Colina  
Hospital De Cruces, 48903/SPAIN

**Background:** There is a lively controversy between supporters of the cervical anastomosis and the defenders of the thoracic anastomosis in the treatment of esophageal cancer. Supporters of individualizing treatment for each patient, we performed cervical anastomosis preferentially. By reviewing our series, we try to find out if this option is safe, does not increase the incidence of complications, stenosis and fistulas and easier to treat if once submitted.

**Methods:** Between 2005 and 2011, 69 patients, mean age 60 years, 92% men. Suffering from adenocarcinoma in 55% of cases and epidermoid carcinoma in 40%. In 88% of cases a transhiatal esophagectomy with manual cervical anastomosis was performed. Made with maximum diameter with monofilament suture stitches of 3/0 absorbable medium term. Radiological control at 5 days.

**Results:** The incidence of anastomotic leaks is 15% (10 cases), 3 were subclinical. There was no evidence of increased respiratory complications in

these patients. Mortality was nil. There were 15 cases of stenosis of the anastomosis, 12 of them presented previous fistula. In 53% of cases, the stenosis was resolved with 1 or 2 dilations. Overall mortality of transhiatal surgery is 8.2% (4 cases). The median survival is 16 months.

**Discussion:** The manual cervical anastomosis presents an acceptable fistula rate, mostly subclinical. It is easily solved with a minimum number of dilations. We believe that the transhiatal surgery with cervical anastomosis has its indications in the treatment of esophageal cancer.

**Disclosure:** All authors have declared no conflicts of interest.

#### P05.093 MODERN MANAGEMENT OF ESOPHAGEAL CANCER: IMPACT ON SURVIVAL

Nikita Chapurin, Christian Peyre, Stefan Niebisch, Candice Wilshire, Thomas Watson, Virginia Litle, Carolyn Jones, Hongyue Wang, Nikolay Balov, Jeffrey H Peters  
*University Of Rochester Medical Center, Rochester/NY/UNITED STATES OF AMERICA*

**Background:** Esophagectomy alone traditionally was the standard of care for resectable esophageal cancer. With advances in preoperative staging modalities, endoscopic therapies, chemoradiotherapy protocols and surgical techniques that include an aggressive lymphadenectomy, treatment of resectable esophageal cancer now is individualized based on the stage of disease, patient characteristics and institutional expertise. Our aim was to review the impact of this modern treatment paradigm on survival.

**Methods:** Cases of resectable esophageal cancer, treated from 1993–2012 were retrospectively analyzed and placed into 2 groups (Group 1: 1993–2004; Group 2: 2004–2012) delineated by the introduction of the routine use of neoadjuvant chemoradiotherapy and en-bloc esophagectomy. Demographic, clinical and pathologic characteristics were compared between the two groups. Multivariate analysis was performed to identify factors impacting survival.

**Results:** Since 1993, 439 patients have undergone esophagectomy. Treatment and pathologic characteristics are listed in supporting Figure. Median survival ( $45.3 \pm 8$  vs.  $24.2 \pm 3$  months,  $p = 0.05$ ) and 5-year survival (43.0% vs. 31.2%,  $p = 0.008$ ) were improved in Group 2 with a similar trend in patients with stage III disease (median  $24.3 \pm 2$  vs.  $17.4 \pm 1$  months,  $p = 0.05$ ; 5-year 22.4% vs. 14.1%  $p = 0.11$ ). Multivariate analysis identified increasing number of resected nodes and adjuvant therapy as predictors of improved survival, while increased age and number of involved nodes were associated with decreased survival.

	Group 1 (n = 188)	Group 2 (n = 251)	P Value
<b>Approach to Resection</b>			
En Bloc	0.7% (1)	27.0% (68)	
Transhiatal	75.7% (109)	56.0% (141)	
Other	8.3% (34)	17.1 (43)	
<b>Use of Multimodality Therapy</b>			
Neoadjuvant	0.7%	40.5%	<0.001
Adjuvant	23.4%	28.6%	0.30
<b>Median &lt;#&gt; Nodes Removed (IQR)</b>	9 (5–14)	16 (10–24)	<0.001
<b>Pathologic Stage (TNM)</b>			
0 (complete responders)	0%	5.2% (13)	0.001
1	15.0% (21)	26.7% (67)	
2	34.3% (48)	26.7% (67)	
3	50.7% (71)	41.4% (104)	

**Discussion:** An aggressive treatment strategy with multimodality therapy and extensive lymphadenectomy resulted in improved survival for resectable esophageal cancer over a traditional approach of esophagectomy alone.

**Disclosure:** All authors have declared no conflicts of interest.

#### P05.094 LAPAROSCOPIC ASSISTED STAGED OESOPHAGEAL RESECTION (LASOR).

Darmarajah Veeramootoo, Amanda Bond, Lui Forni, Howard Wakeling, Khaled Hamdan, Krishna Singh  
*Worthing Hospital, Worthing/UNITED KINGDOM*

**Background:** Oesophagectomy for cancer is associated with significant morbidity. Laparoscopic approaches have the potential for reducing complications from this procedure. The LASOR strategy was developed to facilitate improved staging, optimise gastric conduit preparation, supplement nutrition and reduce the duration of the abdominal part of definitive resectional surgery. This paper assesses the merits of the LASOR approach.

**Methods:** Between March 2003 and February 2012, 47 patients underwent a LASOR. This is a 2 stage procedure: 1. Staging laparoscopy; mobilisation of the greater curve of the stomach whilst preserving the right gastro-epiploic arcade, allowing evaluation of the lesser sac, ischaemic conditioning of the gastric fundus; and finally insertion of a feeding jejunostomy. After a delay

period, stage 2: Laparoscopic gastric mobilisation is completed; the conduit is fashioned and open thoracic anastomosis is performed. All outcomes were entered in a prospective database which was analysed.

**Results:** Forty-seven patients (M: F = 3:1) were enlisted; median age 65 years (34–76). Neo-adjuvant chemotherapy was offered to 68% of patients. There were no conversions. Post-operatively there were no cases of anastomotic leak or mortality. There was 1 lesser curve staple line failure, 1 pressure necrosis of the distal conduit from a misplaced Naso-Gastric tube, 1 chylothorax and 1 leak from jejunostomy site. Median lymph node harvest was 15 (range 4–42) and length of stay 12 days.

**Discussion:** LASOR is a safe and feasible strategy which facilitates adequate staging, nutritional supplementation and may well encourage healing at the gastro-oesophageal anastomosis.

**Disclosure:** All authors have declared no conflicts of interest.

#### P05.095 ESOPHAGECTOMY FOR CANCER: SURGEON CASE VOLUME MAY BE MORE IMPORTANT THAN HOSPITAL VOLUME FOR GOOD QUALITY OF OUTCOME.

Georges Decker, Hélène Groot Koerkamp  
*Zithalnik, Luxembourg/LUXEMBOURG*

**Background:** Esophagectomy for cancer is considered to be one of the operations with the strongest volume outcome-relationships. Numerous studies have shown that so-called “high-volume” hospitals achieve lower mortality and morbidity rates and also better oncological outcome than “low-volume” hospitals. However, definitions and ideal volume cut-offs remain controversial and the real determinants of good quality of care in esophageal cancer surgery remain to be clearly defined. These determinants are important to be found since in some areas, “centralization” may not be a realistic option.

**Methods:** We retrospectively analyzed the outcome of 63 cancer esophagectomies performed by a single surgeon between 2002 and 2011 in 2 subsequent “low-volume” community hospitals (34 resections over 7 years and 29 resections over 5 years). In fact, the 2 hospitals were “low-volume” but the surgeon was a “high-volume” surgeon as he had also performed more than 190 cancer esophagectomies in another University hospital during the same time period.

**Results:** Sixty-three patients of median age 65 years (36 to 83) underwent subtotal esophagectomy with partial gastrectomy and radical lymph node dissection (2 field in 56 patients, 3-field in 7 patients). Induction chemo- or chemoradiation was administered in 14% of patients. Tumor histology was adenocarcinoma in 71% and squamous cell cancer in 27%. All but 1 patient had a trans-thoracic resection, the majority by left thoraco-abdominal and cervical approach. All but 5 patients (92%) had their anastomosis in the neck. Ninety-day mortality was 1.6% due to respiratory failure in one patient. Prospective complication assessment found deviations from the ideal protocol in 67% of patients and reoperations in 11% of patients. Complete resections (R0) were obtained in 92% of patients. A median of 37 lymph nodes (8 to 69) were examined and 68% of patients had at least one lymph node involved (median 2). After 30 months of follow-up, the overall median survival was 29 months and KM 5-year survival probability was 46% despite the fact that 65% of all patients were in pTNM stages 3 or 4. Estimated 5-year survival for N+ patients was 37% versus 61% in N0 patients ( $p = 0.03$ ).

**Discussion:** Our results suggest that for cancer esophagectomy, the individual surgeon’s experience may be a much more important determinant of outcome than “hospital volumes”. To the contrary of general believe, “low-volume” hospitals with adequate organization and equipment can achieve surgical and oncological outcome similar to large tertiary reference centers.

**Disclosure:** All authors have declared no conflicts of interest.

#### P05.096 SURVIVAL EFFECTS OF CERVICAL LYMPH NODE RECURRENCE AFTER ESOPHAGEAL CANCER SURGERY WITH TWO-FIELD LYMPH NODE DISSECTION

Geun Dong Lee<sup>1</sup>, Yong-hee Kim<sup>1</sup>, Deok Heon Lee<sup>2</sup>, Seung-il Park<sup>1</sup>  
<sup>1</sup>Asan Medical Center, University Of Ulsan College Of Medicine, Seoul KOREA, <sup>2</sup>Kyungpook National University Hospital, Daegu KOREA

**Background:** The purpose of this study is to investigate the characteristics of patients who developed cervical lymph node recurrence after esophageal cancer surgery with two-field lymph node dissection.

**Methods:** Between January 2000 and December 2010, 490 consecutive patients who had undergone esophagectomy for esophageal squamous-cell carcinoma, were enrolled in this study. Of those patients, 471 underwent two-field lymph node dissection and 19 patients underwent three-field lymph-node dissection.

**Results:** There were 457 male patients with a mean age of 62.5 years. The median follow-up interval was 35 months. Recurrence was seen in 101

(20.6%) of these patients. The median time to recurrence following surgery was 13.2 months. Isolated cervical lymph node recurrence (group A) developed in 22 (4.5%) patients (21 in two-field and one seen on three-field lymph node dissection,  $p = 0.59$ ), loco-regional recurrence only and without cervical lymph node recurrence (group B) in 30 (6.1%), and distant recurrence with or without loco-regional recurrence (group C) in 49 patients (10.0%). There was no difference in the two- and five-year recurrence-free survival rates among the three groups (27.3% and 9.1% in group A, 26.7% and 6.7% in group B, and 22.4% and 6.1% in group C). However, there was a significant difference in the overall two- and five-year survival rates between group A and group C (67.2% and 26.2% in group A, 56.7% and 13.5% in group B, and 32.7% and 9.4% in group C,  $p = 0.020$ ). Upper esophageal cancer and positive recurrent laryngeal node were independent risk factors determined by univariate and multivariate analysis.

**Discussion:** This study shows that there was a similar incidence of cervical lymph node recurrence between 4.5% of the two-field lymph-node dissection patients and 5.2% of the three-field lymph node dissection patients. The overall survival rate of patients with isolated cervical recurrence was relatively better than that of the patients with other sites of recurrence. Independent risk factors for cervical recurrence were the presence of upper esophageal cancer and metastatic recurrent laryngeal lymph nodes at the time of surgery.

**Disclosure:** All authors have declared no conflicts of interest.

#### P05.097 OPERATIVE OUTCOMES OF COLONIC INTERPOSITION IN THE TREATMENT OF ESOPHAGEAL CANCER: A THREE DECADES EXPERIENCE

Daniel Tong, Simon Law, Fion Chan

Department Of Surgery, The University Of Hong Kong, Hong Kong/  
HONG KONG

**Background:** Colonic interposition is the treatment of choice when the stomach cannot be used for reconstruction after esophagectomy for esophageal cancer. The aim of present study was to review our experience on colonic interposition.

**Methods:** A prospectively collected database on esophageal cancer patients from 1982–2010 was reviewed. The indications, morbidity, mortality, survival and potential predictive factors of these patients were analyzed.

**Results:** A total of 119 patients were identified for study. Of whom, 62 had palliative bypass surgery and 46(74.2%) were performed in 80s, 16 (25.8%) in 90s, and none in 00s. For the remaining 57 patients, the median age was 64 (28–82) and 49 (86%) were male. The median blood loss was 850 ml (150–2500 ml), and the median operative duration was 302 min (150–465 min). The reasons of using colonic interposition included: stomach was involved by tumor ( $n = 18$  (31.6%)), prior gastrectomy ( $n = 34$  (59.6%)), presence of peptic ulcer ( $n = 3$  (5.3%)) and other ( $n = 2$  (3.5%)). There were 4 (7%) had conduit gangrene required re-exploration. Nine (15.8%) patients had either clinical or subclinical anastomotic leakage. The median survival was 34.8 months (17–52 months). The 30-day mortality rate was 3.5% ( $n = 2$ ) and the hospital mortality rate was 15.8% ( $n = 9$ ). Presence of major post-operative medical complications such as stroke or myocardial infarction ( $p = 0.026$ , HR 2.114, 95%CI 1.094–4.084) was identified to be predictive factor for poor survival.

**Discussion:** Colonic interposition remained an important treatment option in patients with prior gastrectomy or when the stomach was invaded by the tumor. The operative procedure was complex and could associated with high morbidity rate.

**Disclosure:** All authors have declared no conflicts of interest.

#### P05.098 A SIMPLE AND SAFE METHOD MINIMIZES CHYLOTHORAX AFTER MINIMALLY INVASIVE ESOPHAGECTOMY

Yaxing Shen<sup>1</sup>, Lijie Tan<sup>2</sup>

<sup>1</sup>Thoracic Division, Zhongshan Hospital, Fudan University, Shanghai CHINA, <sup>2</sup>Thoracic Division, Shanghai CHINA

**Background:** Chylothorax was an uncommon but potentially life-threatening complication after esophagectomy. Previously, prophylactic ligation of thoracic duct was introduced to decrease the incidence of chylothorax after esophagectomy. However, this procedure was traumatic, and time-consuming as well. We herein present a simple method in preventing post-operative chylothorax, and examine its efficacy in compared with thoracic duct ligation during minimally invasive esophagectomy (MIE).

**Methods:** We retrospectively reviewed data from a cohort of 224 consecutive patients who underwent MIE for esophageal cancer (EC) over a 5-year period at our institution. Among these patients, pre-operative milk administration (10 hours ahead of surgery) was given on 178 patients from July 2008–December 2011 (group A), and 46 patients underwent prophylactic ligation of thoracic duct from June 2006–June 2008 were enrolled as histori-

cal controls (group B). The clinical characteristics including patient demographics, operation features, and the rate and type of complications were recorded for both groups. Statistical analysis was used to identify differences between the two groups.

**Results:** All patients underwent thoracoscopic esophagectomy without conversion to open thoracotomy. Two groups were comparable in patient demographics and operation features. After surgery, the operative mortality (0% versus 2.17%,  $p = 0.205$ ) and the overall complication (39.89% versus 36.96%,  $p = 0.717$ ) was close in group A and B. According to the definition as per the Society of Thoracic Surgeons (STS), a total of 4 cases of chylothorax was observed in this study, the incidence ratio was significantly lower than group B (0.56% versus 4.34%,  $p = 0.028$ ).

**Discussion:** Oral administration of milk facilitates identification of thoracic duct during minimally invasive esophagectomy, and is simpler and safer than thoracic duct ligation in preventing post-operative chylothorax. Further study based on larger volume is required to confirm this finding.

**Disclosure:** All authors have declared no conflicts of interest.

#### P05.099 UPSTAGING OF OESOPHAGO-GASTRIC JUNCTIONAL ADENOCARCINOMA USING THE 7TH TNM STAGING

Ramesh Yap Kannan<sup>1</sup>, George Exarchos<sup>1</sup>, Haythem Ali<sup>2</sup>, Rabih Wassel<sup>1</sup>, Ashraf Rasheed<sup>1</sup>

<sup>1</sup>Royal Gwent Hospital, Newport/UNITED KINGDOM, <sup>2</sup>Maidstone And Tunbridge Wells Nhs Trust, Maidstone/UNITED KINGDOM

**Background:** We intended on studying the impact of application of 7<sup>th</sup> TNM rules on staging of resected and pathologically reported OJG adenocarcinomas during the last 10 years stratifying them according to the 7<sup>th</sup> edition TNM staging and compare against the original staging and assess the possible impact of the different strata in nodal staging on survival

**Methods:** A retrospective database was set to capture the clinico-pathological data of all consecutive potentially curative resections of OJG adenocarcinomas over the last 10 years in two UK Upper GI Units. Less than 12 lymph nodes was considered inadequate (Nx). All cases were re-staged according to the 7<sup>th</sup> TNM staging rules. We studied the correlation between re-staging and survival

**Results:** 152 pathology reports confirming OJG adenocarcinomas were reviewed. Adequate lymphadenectomy (minimum criteria of 12 lymph nodes) was noted in 124. Overall nodal upstaging was noted in 94 (62%) reports when the 7<sup>th</sup> TNM rules were applied. In the group that had adequate lymphadenectomy, 76 reports (61%) were upstaged.

**Discussion:** The adoption of the 7<sup>th</sup> TNM staging rules in this cohort of patients lead to a more accurate stratification of the nodal staging. Further studies to test the prognosticating ability of this better defined lymphatic staging are needed. We urge the royal college of pathologists to adopt the 7<sup>th</sup> edition as it provides a detailed documentation of the lymphatic staging and offers a valuable opportunity for further research to elucidate the possible link between lymphadenectomy and survival in oesophageal cancer and may drive an up-lift in the UK surgical lymphadenectomy standards.

**Disclosure:** All authors have declared no conflicts of interest.

#### P05.100 MINIMALLY INVASIVE SURGERY FOR ESOPHAGEAL CANCER: AN 8-YEAR SINGLE CENTER EXPERIENCE WITH 70 PATIENTS

Do Wan Kim<sup>1</sup>, Ju Sik Yun<sup>1</sup>, Sang Yun Song<sup>2</sup>, Kook Joo Na<sup>2</sup>

<sup>1</sup>Chonnam National University Hospital, Gwangju/KOREA, <sup>2</sup>Chonnam National University Hwasun Hospital, Jeollanamdo, Hwasun/KOREA

**Background:** Minimally invasive surgery for esophageal cancer (MIES) has been increasingly performed. Despite widespread use, potential benefits of MIES remain controversial, especially in oncologic aspects.

**Methods:** Between September 2004 and December 2011, 70 patients underwent MIES at our institution. The medical records of patients were reviewed retrospectively.

**Results:** Mean age at operation was  $63.8 \pm 8.2$  years, and there were three females. Forty two patients underwent complete MIES and 28 patients underwent hybrid MIES. The histologic types were adenocarcinoma in 2 patients, high grade dysplasia in 3 patients and the others were squamous cell carcinoma. Postoperative stage of patients was stage 0 in 11, I in 40, II in 15 and III in 4. Mean thoracic operative time was  $158 \pm 52$  minutes and mean abdominal operative time was  $198 \pm 90$  minutes. And the mean operative time of both phase decreased gradually, reflecting the learning curve for MIES. Mean number of retrieved lymph nodes was  $16.6 \pm 8.4$ . Mean hospital stay was  $13.3 \pm 6.0$  days and the 30-day mortality was 4.3%. Overall morbidity was 47.1%, and most common postoperative complication was vocal cord paralysis in 9 patients. In 3-phase operation group ( $n = 48$ ), pulmonary complications were more frequent in the lateral position (3/17,

17.6%) than the prone position(1/31, 3.2%), but this was not statistically significant( $p = 0.084$ ). The median follow-up duration was 27 months. Overall 5-year survival rate was 49.1% with Kaplan-Meier estimates.

**Discussion:** Minimally invasive surgery for esophageal cancer(MIES) is a safe and feasible procedure with acceptable outcomes. Further randomized prospective studies are needed.

**Disclosure:** All authors have declared no conflicts of interest.

#### P05.101 TRANSHIATAL CHEST DRAINAGE FOLLOWING MINIMALLY INVASIVE ESOPHAGECTOMY

Tairo Ryotokuji, Yosuke Izumi, Tomoyoshi Suzuki, Akinori Miura, Tsuyoshi Kato  
*Department Of Surgery, Tokyo Metropolitan Cancer And Infectious Diseases Center, Komagome Hospital, Tokyo/JAPAN*

**Background:** Patients following esophagectomy often requires left chest tube drainage on the 3 or 4 postoperative day due to pleural effusions in the contralateral thoracic cavity of the right transthoracic procedure. Transthoracic intercostal drain placement is standard practice. However these chest tubes cause pain and hamper mobility, sometimes causing morbidity and delaying recovery. In patients following minimally invasive esophagectomy(MIE), these drains sometimes ruined the advantage of MIE. We introduced a novel transhiatal drainage for postoperative left pleural effusions. The aim of this study is to investigate whether transhiatal chest tube drainage is effective and safe following minimally invasive esophagectomy.

**Methods:** We placed 28Fr intercostal tube for right thoracic cavity and transhiatal silastic drain for left thoracic cavity intraoperatively. From September 2005 we introduced transhiatal chest drainage using silastic drains. At the same time we stopped left subphrenic abdominal drainage. Transhiatal chest tube drainage in the left pleural cavity is performed in 54 patients undergoing minimally invasive esophagectomy including both thoracoscopic and laparoscopic approach.

**Results:** No patient developed clinically significant pleural effusions in the left thoracic cavity, requiring further drainage. No complications were noted, associated with transabdominal chest tube and no drain for abdominal cavity.

**Discussion:** Transhiatal chest tube drainage of the left pleural cavity is an effective and safe means of draining the chest, following minimally invasive esophagectomy. This technique can also be applied to transthoracic esophagectomy.

**Disclosure:** All authors have declared no conflicts of interest.

#### P05.102 MINIMALLY INVASIVE ESOPHAGO-GASTRECTOMY WITH COLONIC INTERPOSITION: EARLY EXPERIENCE

Vaithiswaran V, Praveenraj P, Palanivelu C, Parthasarathy R, Kedar Patil  
*Gem Hospital And Research Center, 641045/INDIA*

**Background:** Incidence of adenocarcinoma of the lower end of the esophagus is increasing world over. For growth involving lower end of esophagus and a large part of the proximal stomach an esophago-gastrectomy is required. In such situations, colonic interposition is a good option for reconstruction. Here we describe minimally invasive esophago – gastrectomy with colonic interposition and its outcome in 5 patients.

**Methods:** All five patients were male and had adenocarcinoma involving lower esophagus and significant component of the proximal stomach. They had only partial response to neo-adjuvant chemotherapy. They underwent minimally invasive esophago – gastrectomy with colonic interposition. The laparoscopic part included mobilization stomach, and mobilization of the colon to form a colonic conduit based on the left colic vessels. The esophageal mobilization was carried out in prone position through a right thoracoscopic approach. The colonic conduit was pulled up through a laparoscopically created sub-sternal conduit and the cervical anastomosis was completed.

**Results:** The procedure was successfully completed in all patients without intraoperative complications. There was no major morbidity or mortality. One patient had self-limiting leak at esophago-colic anastomosis at the neck and another had self-limiting peri jejunostomy leak.

**Discussion:** Minimally invasive esophago – gastrectomy with colonic interposition is feasible for carcinoma of the lower end of the esophagus involving lower end of esophagus and a large part of the proximal stomach. This complex procedure can be performed with acceptable morbidity.

**Disclosure:** All authors have declared no conflicts of interest.

#### P05.103 RECONSTRUCTIVE (PLASTIC) SURGICAL TECHNIQUES OF THE GENERAL SURGEON, FOR THE MANAGEMENT OF SEVERE ANASTOMOTIC COMPLICATION AFTER ESOPHAGECTOMY

Hitoshi Satodate, Haruhiro Inoue, Shin-ei Kudo  
*Showa University Northern Yokohama Hospital, Yokohama/JAPAN*

**Background:** Complication associated with anastomosis after esophagectomy causes serious morbidity and mortality. Anastomotic leak could be managed conservatively, but if the defect is large, reoperation is demanded. And intractable anastomotic stricture could also be a very difficult problem. Generally, reconstructive surgeon (commonly plastic surgeon) would take charge of those kinds of problems. But in our hospital, there is no reconstruction specialist, and we have successfully managed by ourselves for above mentioned problems.

**Methods:** Case1 A 72-year-old female with squamous cell carcinoma underwent esophagectomy and gastric conduit reconstruction. After that, partial necrosis at the tip of the gastric conduit was appeared. The diameter of the defect was about 2.5 cm. We performed sternocleidomastoid myocutaneous patch-esophagoplasty for that defect. Case2 A 69-year-old male with squamous cell carcinoma underwent thoracoscopic esophagectomy, gastric conduit reconstruction. After that, severe anastomotic stricture was occurred. Even guide-wire couldn't be passed. Then esophageal re-reconstruction using a pedicled jejunum with microvascular augmentation was carried out. Microvasculer anastomosis was made with the second jejuna vessels and the left internal thoracic vessels.

**Results:** Above mentioned cases postoperative courses were uneventful and satisfactory. No leaks were found after the second operation.

**Discussion:** We believe basic techniques of the reconstructive (plastic) surgery, including skinflap and microvascular anastomosis, is useful especially for the esophageal surgeon to manage above mentioned anastomotic complication. We will show our clinical practice.

**Disclosure:** All authors have declared no conflicts of interest.

#### P05.104 SURGICAL TREATMENT OF ESOPHAGEAL CANCER AFTER NEOADJUVANT THERAPY: PRELIMINAR RESULTS ON 63 CASES

Ivan Ceccanello, Rubens Sallum, Flavio Roberto Takeda, Julio Rocha, Ulysses Ribeiro, Sergio Szachnowicz  
*Department Of Gastroenterology – Esophageal Surgical Division, University Of São Paulo School Of Medicine, São Paulo – Brazil, São Paulo/BRAZIL*

**Background:** Neoadjuvant treatment has been consolidated as an effective and safe alternative in esophageal cancer, especially in advanced stages.

In Brazil, in the last five years has been the choice in high-volume centers, although costs and individual care still restrict this statement

**Objective:** Analyze the results of this first series of patients undergoing neoadjuvancy followed by surgical treatment, focused on the pathological response of the lesion in adenocarcinoma AC and squamous cell carcinoma SCC

**Methods:** Method: From 2005 to 2011, 63 consecutive esophageal SCC and AC patients were submitted to neoadjuvant therapy followed by esophagectomy with lymphadenectomy. Two groups were studied according to demographics data, staging, mortality, pathological response, overall survival.

**Results:** 33 cases were (52.4%) of SCC and 30 AC. Mean follow up was 36 months (6 to 137). The mean age was 54 years. Lesions T3, T4 or T2 N+ were referred for this treatment. Patients with SCC underwent esophagectomy with thoracoscopic lymphadenectomy and AC by treated by transhiatal approach. There was no operative mortality in this series. There was a decrease in lesion size in all operated cases and downstaging in 33/62 (53,2%) and 8 of them with pathologic complete response: 6/33 (18,2%) SCC and 2/30 (6,7%) AC. 13 patients died of disease (20,6%), with 35 patients alive without disease.

**Discussion:** Conclusions: Neoadjuvant treatment seems to be effective and safe (without mortality) in selected cases. The pathologic complete response was more frequent in SCC than in AC.

**Disclosure:** All authors have declared no conflicts of interest.

#### P05.105 AN EFFICACY OF IMMUNO-MODULATING DIET(IMD) IN PERIOPERATIVE PATIENTS OF ESOPHAGEAL CANCER: A RANDOMIZED CONTROLLED TRIAL.

Michitaka Suzuki, Haruhiro Inoue, Hitoshi Satodate, Shinei Kudo  
*Digestive Disease Center, Showa University Northern Yokohama Hospital, Yokohama, Kanagawa/JAPAN*

**Background:** We conducted a prospective randomized study to examine the efficacy of immuno-modulating diet(IMD) in perioperative patients of

esophageal cancer. This diet, MHN-02(Meiji, Japan), is enriched with whey-hydrolyzed peptide, prebiotics and anti oxidizing vitamins and has low glycemic index.

**Methods:** 30 patients of esophageal cancer were randomly assigned to IMD group (n = 15) or standard group(n = 15). Before operation, they drank 600 ml feeding per day for 5 days. From POD2, feeding was administrated by jejunostomy tube. The laboratory data and the incidence of complications were compared between the two groups. Primary endpoint was occurrence of infections complications.

**Results:** There were no significant difference in body temperature, CRP, WBC, lymphocytes, IL-6, TNF-alpha. SIRS durations were 1.9days in IMD group and 3.1days in standard group, but no significant difference existed. Albumin in POD4 was significantly higher in IMD group compared with standard group. Retinol binding protein was higher in every postoperative day in IMD group, but no significant difference existed. Blood glucose levels in POD1,3,5,9 were significantly lower in IMD group compared with standard group. Major complications in IMD group were two anastomotic leakage and one pneumonia, while in standard group two leakage, one cerebral infarction, two wound infection and seven pneumonia.

**Discussion:** This IMD reduced infectious complications and was useful in postoperative blood glucose control. Effect on anti-inflammatory action were still unclear.

**Disclosure:** M. Suzuki: This study is financially supported by Meiji corp. All other authors have declared no conflicts of interest.

#### P05.106 OUTCOMES OF LAPAROSCOPIC GASTRIC MOBILISATION DURING TWO-PHASE ESOPHAGECTOMY FOR CANCER

Ashok Menon, Sophie Bennett, Mohammed Al-Rashedy, Vinutha Shetty, P S Senapati, Khurshid Akhtar  
Salford Royal Hospital, Salford/UNITED KINGDOM

**Background:** Laparoscopic gastric mobilisation (LGM), during two-phase oesophagectomy, is becoming increasingly popular. However there remain concerns regarding safety and oncological efficacy. The study aims to describe our experience with LGM with emphasis on these issues.

**Methods:** A retrospective review was carried out on patients undergoing LGM as part of a two-phase oesophagectomy for cancer or high grade dysplasia between September 2009 and October 2011. Primary outcome measures were: inpatient complication rates, 30- and 90-day re-operation, readmission, and mortality rates, margin status, and numbers of lymph nodes retrieved.

**Results:** 40 patients underwent two-phase oesophagectomy with LGM during the study period, of which 26 patients had open thoracic resection, with 14 having thoracoscopic resection. The median age of the cohort was 65 years (42-85), with a male preponderance of 4:1. There was one conversion to laparotomy (3%), five conversions to thoracotomy (36%), one chylothorax (3%), with no instances of anastomotic leaks or gastric conduit ischaemia/necrosis in the series. Circumferential and longitudinal resection margin positivity was 10%, and 0% respectively. The median number of lymph nodes retrieved was 21 (7-52). There was no in-patient mortality during the index admission. 30 day rates of readmission, re-operation, and mortality were 13%, 8%, and 0% respectively. 90-day rates of readmission, re-operation, and mortality were 18%, 8%, and 3% respectively. Median length of hospital stay was 14 days (7-37), with a median of 1 day (1-10) spent in critical care.

**Discussion:** When compared with national audit data for oesophagectomy, these results show that LGM is a safe and oncologically sound procedure.

**Disclosure:** All authors have declared no conflicts of interest.

#### P05.107 SYNCHRONOUS SQUAMOUS CELL CARCINOMA OF THE ESOPHAGUS AND STOMACH FOLLOWING CAUSTIC INGESTION

Maria F.C.D.V. Freitas, Ruy França Almeida, Paulo Roberto Corsi, Celso Castro Pochini, Danilo Gagliardi  
Santa Casa Of São Paulo, São Paulo/BRAZIL

**Background:** Corrosive ingestion can lead to acute and long-term complications. Stricture formation is the main long term complication, while the most dreaded complication, carcinoma, occurs in up to 7% of the cases. Strictures caused by caustic ingestion are treated with endoscopic dilations in the majority of cases but even so surgical procedures may be needed - from gastrostomy for feeding to esophagectomy. We present a case of synchronous stomach and esophagus squamous cell carcinoma in a patient with caustic stricture.

**Methods:** Case report and literature review.

**Results:** We describe the case of a 47 year old male who suffered caustic injury to the esophagus 30 years ago. The patient had undergone endoscopic

dilations in another service until he developed a device and started self dilation of his esophageal stricture, 23 cm distal from the incisor teeth. He begun endoscopic dilation in our service 7 years ago and was also submitted to surgical closure of a gastrotomy orifice he carried for 26 years. During follow-up an epidermoid cancer of the stomach was detected simultaneously to intraepithelial neoplasia in the esophagus - which presented also Barrett esophagus. An esophagogastrectomy with colonic interposition was performed, complicated in the postoperative period by Herpes Zoster and Radial Artery thrombosis.

**Discussion:** This case presents many rare features such as squamous cell carcinoma of the stomach and synchronous carcinoma of the stomach and esophagus. In this case foreign body granuloma was present near the stomach cancer, suggesting that the latter was related to the long-term tube site.

**Disclosure:** All authors have declared no conflicts of interest.

#### P05.108 MORE PATHOLOGICALLY COMPLETE RESPONDERS AFTER A LONGER INTERVAL BETWEEN CHEMORADIOTHERAPY AND SURGERY FOR OESOPHAGEAL CANCER

Joel Shapiro<sup>1</sup>, Pieter Van Hagen<sup>1</sup>, Bas Wijnhoven<sup>1</sup>, Zohra Faiz<sup>1</sup>, Ate Van Der Gaast<sup>2</sup>, Jan Van Lanschot<sup>1</sup>, On Behalf Of The Cross Study Group<sup>3</sup>  
<sup>1</sup>Department Of Surgery, Erasmus Mc, Rotterdam/NETHERLANDS,  
<sup>2</sup>Department Of Medical Oncology, Erasmus Mc, Rotterdam/  
NETHERLANDS, <sup>3</sup>Rotterdam/amsterdam/NETHERLANDS

**Background:** The tumour regression grade (TRG) in the surgical resection specimen has been recognised as a valuable prognostic factor for survival in patients who underwent neoadjuvant chemoradiotherapy (nCRT) for oesophageal cancer. Little is known about the influence of the length of the interval between nCRT and surgery on the TRG observed in the resection specimen. Aim of this study was to determine the correlation between this interval and the TRG.

**Methods:** Patients treated with nCRT (five weekly courses of Carboplatin/Paclitaxel with 41.4 Gy of concurrent radiotherapy) for resectable oesophageal cancer between 2002-2009 were identified. The interval between the end of nCRT and surgery, and the TRG in the resection specimen, including adjacent lymph nodes, was determined for each patient.

**Results:** Two hundred and twenty-nine patients were included. Median age was 59.6 years and the majority of patients (74%) had an adenocarcinoma. A microscopically radical resection was performed in 216/229 (94%) patients. The median interval between nCRT and surgery was 46 days [p25-p75: 39-55]. No significant differences were found in TRG distribution between patients with intervals under and over the median interval. The percentage of pathologically complete responders (TRG1) was 52% in patients with an interval of more than 55 days (>p75) vs. 27% in patients with an interval of less than 55 days (<p75) (p = 0.001).

**Discussion:** In patients with a relatively long interval (>p75) between nCRT and surgery, more pathologically complete responders were observed. These results suggest that prolonging the interval between nCRT and surgery might increase the pathologically complete response rate.

**Disclosure:** All authors have declared no conflicts of interest.

#### P05.109 MEDICAL AND ECONOMIC RELEVANCE OF THE 7TH EDITION OF TNM CLASSIFICATION OF ESOPHAGEAL AND GASTRIC CARCINOMA

Christoph T Baltin, Elfriede Bollschweiler, Ralf Metzger, Arnulf Höltscher, Stefan Paul Mönig  
Department Of General-, Visceral- And Cancer Surgery, University Of Cologne, Cologne/GERMANY

**Background:** From a medical point of view, the 7th edition of the TNM classification will result in significant changes for esophageal and gastric carcinoma. Nearly all adenocarcinoma of the esophagogastric junction (EGJ carcinoma) will be classified as esophageal carcinoma. Depending on codification, this may lead to different allocations and potential shifts in the number of cases. The objective of this study is an analysis of the relevance of the above changes for adenocarcinoma of the esophagogastric junction from a medical and economic point of view to arrive at recommendations for codification.

**Methods:** The present study compares the number of esophageal carcinoma cases (C15.8) on the one hand with the number of cardia carcinoma (C16.0) on the other hand over a time horizon of ten years based on the new and the old TNM classification at a high-volume centre. DRGs represent the basis for the billing, which follows from the main diagnosis and the main surgical service delivered. The diagnosis on the basis of ICD 10 version 2011 differentiates between a carcinoma of the distal esophagus and the gastric tract (ICD C15.8) and a cardia carcinoma (ICD 16.0). According to the 7th TNM classification, an esophageal carcinoma already exists if the centre of

the tumor is located within five centimetres of the esophageal junction and the z-line is infiltrated at the same time. This applies for all EG carcinoma of type I and II as well as for a majority of type III carcinoma.

**Results:** In the new TNM classification, the number of cases of esophageal carcinoma will increase, while in turn there will be a lower number of gastric carcinoma. The main diagnosis esophageal carcinoma ICD C15.8 will be classified as DRG G03A for the corresponding surgery and be billed at EUR 16,552. In case of a main diagnosis of cardia carcinoma ICD C16.0, there will be two different DRGs with significantly different billing amounts, depending on the documented principal surgical service. Differences in excess of EUR 4,000 (i.e., approximately 35%) could result, depending on documented primary diagnosis and surgical procedure of esophageal and gastric carcinoma.

**Discussion:** The new TNM classification will lead to a strong increase in the number of cases of esophageal carcinoma and to a decrease in the number of cases of gastric cancer, likely including a series of effects for minimum amounts. The medical and economic relevance underlines the strong importance of a detailed and faultless documentation of clinical findings.

**Disclosure:** All authors have declared no conflicts of interest.

#### P05.110 GASTRIC TUBE VASCULARIZATION AFTER ESOPHAGECTOMY WITH GASTROPLASTY: ENDOSCOPIC AND HISTOLOGICAL STUDY ON A CONSECUTIVE SERIES OF PATIENTS

Matteo Porta, Uberto Fumagalli Romario, Martina Ceolin, Pietro Muselli, Paola Spaggiari, Nico Pagano, Alessandro Repici, Riccardo Rosati

*Istituto Clinico Humanitas, Rozzano/ITALY*

**Background:** Aim: to identify some morphological and histological modifications indicative of gastric mucosa ischemia and then predictive of an anastomotic complication occurrence, in a group of patients submitted to esophagectomy with gastroplasty.

**Methods:** Methods: 21 patients submitted to esophagectomy with gastroplasty underwent a pre-operative endoscopy with gastric fundus mucosal biopsies and at least one endoscopic control before po day 8, with perianastomotic biopsies of gastric tube mucosa. Morphological and histological reports were classified following predefined criteria, so attributing an endoscopic and an anatomic-pathologic score that allowed to compare pre- and post-operative trophic status of gastric mucosa.

**Results:** Results: post-operative complication rate was 38% (8/21), of which 5 anastomotic leaks. One out of 5 patients whose post-operative course was complicated by an anastomotic fistula, died for reasons not leak-related (mortality = 4,8%). In two patients out of these 5, whose post-operative course was seriously influenced by the leak, an endoscopic score greater than that of patients with a normal course was observed. Histological score (determined by the presence or absence of some histological findings showing an ischemic condition) of those patients with a post-operative course complicated by a leak, was considerably greater than that of patients with a normal post-operative course. No adverse events related with the execution of a post-operative endoscopy was registered.

**Discussion:** Conclusions: according to data from this small group of patients, it seems like that combining endoscopic reports with the histological findings on mucosal biopsies, we can obtain a score that could be predictive of the occurrence of a leak.

**Disclosure:** All authors have declared no conflicts of interest.

#### P05.111 IMPLICATIONS OF LYMPH NODE INVOLVEMENT IN PT1B ESOPHAGEAL CANCER

Marie C Ziesat<sup>1</sup>, Sabha Ganai<sup>2</sup>, Mitchell C Posner<sup>2</sup>, Marco G Patti<sup>2</sup>, Vivek N Prachand<sup>2</sup>, Irving Waxman<sup>2</sup>, Vani Konda<sup>2</sup>, Uzma Siddiqui<sup>2</sup>, Mark K. Ferguson<sup>2</sup>

<sup>1</sup>The University Of Chicago, Chicago/UNITED STATES OF AMERICA,

<sup>2</sup>The University Of Chicago Medical Center, Chicago/UNITED STATES OF AMERICA

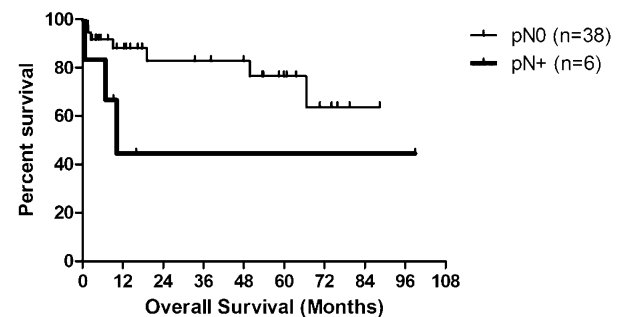
**Background:** The ideal management of esophageal cancer with submucosal invasion (T1b) is uncertain due to varying reports of lymph node metastasis.

**Methods:** We performed a retrospective review of 282 consecutive esophagectomies from 2002–2012, identifying 61 pT1b lesions. 17 patients who underwent induction chemotherapy were excluded leaving 44 patients for this analysis. Median follow-up was 15 months.

**Results:** pT1b patients were 63 ± 12 years old, 80% male, and had a BMI of 29 ± 6 kg/m<sup>2</sup>. 43 (98%) patients were staged with EUS, identifying 39 (91%) with uN0 and 4(9%) with uN1 disease. Preoperative PET was used in 21 (48%). R0 resections were achieved in all 44 patients, with 25 (57%) having 12 or greater lymph nodes resected (mean 16 ± 12). Pathology revealed 38

(86%) adenocarcinomas and 6 (14%) squamous cell carcinomas. Lymphovascular invasion was found in 7 (16%) patients. 37(84%) of patients were pN0, 5(11%) were pN1, 1(2%) was pN2, and 1(2%) was pN3. EUS accurately predicted N stage in 38(86%), with 2(5%) being upstaged from N0 to N1, 1(2%) from N0 to N2, and 2(5%) downstaged from N1 to N0 (p < 0.01). 25 (57%) of patients had no or minor complications, with in-hospital death occurring in 3 (7%) patients. Overall five-year survival of pT1b patients was 71.5%. Node-positive final pathology demonstrated an expected decrease in five-year overall survival from 76.4% to 44.4% (0.18 (95% CI 0.03–1.24, p = 0.08).

#### Survival of pT1b lesions by Nodal Status



**Discussion:** Given the biology of T1b lesions and risk of lymph node involvement, one should use endoscopic resection as definitive management with caution.

**Disclosure:** All authors have declared no conflicts of interest.

#### P05.112 RESULTS OF THORACOSCOPIC RADICAL ESOPHAGECTOMY IN 418 PATIENTS WITH THORACIC ESOPHAGEAL CANCER

Shigeru Lee, Harushi Osugi, Satoru Kishida, Masato Okawa, Yukiko Niwa, Ken Gyobu, Eijiro Edagawa  
*Department Of Gastroenterological Surgery, Osaka City University Graduate School Of Medicine, Osaka/JAPAN*

**Background:** Since 1996, video-assisted thoracoscopic esophagectomy together with extensive lymphadenectomy (VATS) has been performed in 418 patients with thoracic esophageal cancer. The efficacy of VATS was studied.

**Methods:** Methods: VATS was indicated for the patients with 1) no extensive pleural adhesion, 2) no contiguous tumor spread, 3) pulmonary function capable of sustaining single-lung ventilation, and 4) no previous radiotherapy. We use 4 ports around a 5 cm mini-thoracotomy on 5th intercostal space. We laid emphasis on utilizing magnifying effect of video, obtained by positioning the camera at close vicinity to the dissection.

**Results:** VATS was converted to open surgery in 43 patients due to pleural adhesion, T4, and etc. We had no emergency conversion. Duration of thoracic procedure and retrieved nodes were 192 min. and 34. The blood loss during thoracic procedure was 193 g. The incidence of pulmonary complication was 5% and reduction of %VC was 11%, 15% at 4 weeks and 12 weeks after surgery. 5-year survival rate was 91%(pStage 0), 90% (pStage I), 68%(pStage II), 56%(pStage III), 28%(pStage IVa), after thoracoscopic surgery (Guide Lines for the Clinical and Pathologic Studies on Carcinoma of the Esophagus, 10th Edition, Japan Esophageal Society). Recurrence was confirmed in 105 patients and the initial patterns were homogeneous in 43, lymphatic in 57 (36 were out of the mediastinum and 21 were in the mediastinum), and local in 5. Therefore the local control rate after thoracoscopic surgery was 93%.

**Discussion:** VATS for thoracic esophageal cancer can be performed with safety and efficacy.

**Disclosure:** All authors have declared no conflicts of interest.

#### P05.113 LAPAROSCOPIC TRANSHIATAL ESOPHAGECTOMY COMBINED WITH LEFT THORACOSCOPY IN A PATIENT WITH BARRETT ADENOCARCINOMA: A CASE REPORT

Michio Tokura<sup>1</sup>, Yosuke Izumi<sup>2</sup>, Akinori Miura<sup>2</sup>, Tsuyoshi Kato<sup>2</sup>  
<sup>1</sup>Tokyo Metropolitan Cancer And Infectious Diseases Center, Komagome Hospital, Tokyo/JAPAN, <sup>2</sup>Department Of Surgery, Tokyo Metropolitan Cancer And Infectious Diseases Center, Komagome Hospital, Tokyo/JAPAN

**Background:** Esophageal squamous cell cancer located in the lower third of the esophagus often indicates surgery with left transthoracic approach. Surgery with left thoracotomy is less invasive than right thoracotomy, but

thoracotomy itself is associated with morbidity and delayed recovery in cancer patients who are typically older and malnourished and often have pulmonary or cardiovascular complications.

**Methods:** A 65-year-old man diagnosed as esophageal carcinoma introduced our hospital. After further examinations, he was diagnosed as early Barrett adenocarcinoma and operation was performed. We conducted lower third esophagectomy with laparoscopic transhiatal approach and esophago-jejunosomy using a circular stapler. Following these procedures, we used left thoracoscopy for the observation in the intrathoracic anastomosis. The thoracoscopic examination revealed the completion of the anastomosis and the insufficiency of blood supply at the stump of jejunum. We performed the resection of the stump and finished operation. He was discharged without any complications on postoperative day 25 and remains alive 9 years.

**Results:** The laparoscopic transhiatal approach was efficient in patients with distal esophageal cancer. However, we often faced difficulty in the intrathoracic anastomosis. The observation of the intrathoracic anastomosis using left thoracoscopy is useful to decrease the complication of the leakage. We could observe ischemia of the stump of jejunum and cut the stump using left thoracoscopy in this case.

**Discussion:** The laparoscopic transhiatal approach combined with left thoracoscopy technique becomes more reliable method for the esophageal cancer in the lower third and gastro-esophageal junction.

**Disclosure:** All authors have declared no conflicts of interest.

#### P05.114 MEDIASTINOSCOPIC TRANSHIATAL ESO@PHAGECTOMY FOR CARCINOMA OF THE LOWER THIRD OF THE ESOPHAGUS USING ON-THE -TABLE ENDOSCOPY

Akinori Miura, Tsuyoshi Kato, Yosuke Izumi  
Department Of Surgery, Tokyo Metropolitan Cancer And Infectious Diseases Center, Komagome Hospital, Tokyo/JAPAN

**Background:** We introduced mediastinoscopic transhiatal esophagectomy for the patients of esophageal cancer in the lower third esophagus. In the earlier experience, we faced difficulty in the intrathoracic anastomosis. We introduced the peroral anvil technique (EEA OrVil?) for intrathoracic anastomosis with circular stapler and examined anastomosis using endoscopy.

**Methods:** Between August 2008 and August 2010, we introduced the peroral anvil technique (EEA OrVil?) for intrathoracic anastomosis using endoscopy with circular stapler for 19 cases. We performed the mediastinoscopic transhiatal approach for the esophageal cancer in the lower third esophagus. We checked the cut line of the esophagus and the intrathoracic anastomosis using endoscopy. We assessed the efficacy and safety for the procedure with a retrospective analysis.

**Results:** There were 16 men and 3 women. Median age was 67 years (range, 57–80). There was a past history of another cancer in 6 cases and 3 patients had interstitial pneumonia due to neoadjuvant chemoradiotherapy. The mean operative time was 225 minutes. Mean blood loss was 454 g. Mean length of resected esophagus was 7.5 cm. Mean postoperative stay was 18 days. There was no complication of pneumonitis. Minor leakage was noted in 2 cases.

**Discussion:** Mediastinoscopic transhiatal esophagectomy has the potential to replace the esophagectomy with left thoracotomy as the radical treatment for esophageal cancer located in the lower third of the esophagus. Endoscopic examination was very helpful in the intrathoracic anastomosis using peroral anvil.

**Disclosure:** All authors have declared no conflicts of interest.

#### P05.115 LIMITED RESECTION FOR EARLY ADENOCARCINOMA OF DISTAL ESOPHAGUS – CASE REPORT

António M. Gouveia<sup>1</sup>, John Preto<sup>1</sup>, Hugo Sousa<sup>1</sup>, Antonio Pereira<sup>1</sup>, Gil Faria<sup>1</sup>, Manuela Baptista<sup>2</sup>, José Barbosa<sup>1</sup>, José Costa Maia<sup>1</sup>  
<sup>1</sup>Centro Hospitalar De São João / University Of Porto Medical School, Porto/PORTUGAL, <sup>2</sup>Unidade Esófago-Gastro-Duodenal, Serviço De Cirurgia Geral, Centro Hospitalar De São João, Porto/PORTUGAL

**Background:** Extended esophagectomies are associated with a remaining risk of considerable postoperative morbidity and mortality. The quality of life of these patients may be compromised as well. This fact has led to limited resections of adenocarcinomas of the distal esophagus and/or esophagogastric junction.

**Methods:** Case report

**Results:** 83 years-old man with comorbidities, presenting anemia. Esophagogastroduodenoscopy revealed esophagitis with a flat/depressed lesion (Paris IIb-c) in the distal esophagus (5 cm in diameter), and biopsy disclosed a carcinoma. Ultrasonography showed a lesion limited to the mucosal layer and a perilesional lymph node with 5 mm (uT1m N1). Pre-treatment thoracoabdominal CT did not reveal any sign of distant spread of the disease.

The patient was submitted to a distal esophageal and esophagogastric junction resection with (limited) lymph node dissection, and jejunal interposition for reconstruction (Merendino procedure). No major complications were observed in the postoperative period (only a small right pleural effusion) and he was discharged from the hospital at the 12<sup>th</sup> postoperative day. Pathological examination documented an intestinal type submucosal adenocarcinoma of the esophagus, with no metastases in the 20 removed regional lymph nodes (pT1b N0).

**Discussion:** Limited Resection (Merendino procedure) is indicated in mucosal carcinoma (T1a) of the distal esophagus / esophagogastric junction which cannot be completely removed by interventional endoscopy. Furthermore, it may be a suitable surgical alternative for selected cases of submucosal carcinoma in these locations.

**Disclosure:** All authors have declared no conflicts of interest.

#### P05.116 SURGICAL STRESS IN ESOPHAGECTOMY BETWEEN ONE-LUNG VENTILATION AND TWO-LUNG VENTILATION

Kosuke Narumiya, Masaho Ota, Takuya Sato, Shin Yamamoto, Yuji Shirai, Harushi Osugi, Hiroko Ide, Masakazu Yamamoto  
Institute Of Gastroenterology, Tokyo Women'S Medical University, Tokyo/JAPAN

**Background:** Esophagectomy for esophageal cancer is one of the most invasive surgical procedures. We often experienced pulmonary complication after esophagectomy. Generally one-lung ventilation is used for thoracic surgery but we perform esophagectomy with two lung ventilation to reduce the pulmonary complication after the esophagectomy. In this study, we exam the changes of IL6 and neutrophil elastase in epithelial lining fluid covered by bronchoscopic microsampling methods.

**Methods:** Between 2007 and 2009, 10 patients were performed esophagectomy with one-lung ventilation (GroupA), the other 10 patients were performed it with two-lung ventilation(GroupB).

We exam the three points, Pre-operation, post-operation and 1 POD.

**Results:** In the left lung, between one lung ventilation and two lung ventilation, neutrophil elastase with one lung ventilation in 1 POD is higher than two lung ventilation.

**Discussion:** Generally We must perform the esophagectomy with one-lung ventilation. But we have experienced many pulmonary complications. And so many patients of esophageal cancer have much coexistence disease because of smoking, drinking and so lifestyle. To reduce of pulmonary complications and less surgical stress, two-lung ventilation is useful ventilation.

**Disclosure:** All authors have declared no conflicts of interest.

#### P05.117 RESULTS OF RESECTION AND THREE AREA LYMPH NODE DISSECTION IN THORACIC ESOPHAGEAL CANCER

Zafer Ferahkose<sup>1</sup>, Osman Yüksel<sup>2</sup>, Merter Gülen<sup>2</sup>, Arif Mert Atak<sup>2</sup>, Ersin Özdemir<sup>1</sup>, Murat Akin<sup>2</sup>  
<sup>1</sup>Bayındır Hospital, Ankara/TURKEY, <sup>2</sup>Gazi University Medical School Department Of Surgery, Ankara/TURKEY

**Background:** The extended of surgery and extended lymph node dissection in esophagus surgery are important in decreasing locoregional recurrences and improving the survivals. In this study, we aimed to evaluate the results of resection and three area lymph node dissection in thoracic esophageal cancer.

**Methods:** We enrolled 68 patients who had undergone curative resections and three area lymph node dissections for thoracic esophagus cancer in recent 20 years. Histopathologic results of all of the patients were squamous cell carcinoma. Ages, gender, complications, 5-year survival rates of the patients and also the sizes, localizations, lengths of effected segments, and stages of the tumor were evaluated in the study.

**Results:** The distribution of the number of tumors in upper, middle and lower thoracic esophagus were 7, 49 and 12 respectively. The mean length of the tumor size was 6.3 cm. There were 37 patients with stage IIA whereas 21 patients with stage III. The 5-year survival rate was 65%. Seven patients died due to the complications the most of which were lung related.

**Discussion:** The most important prognostic factor in the surgery of esophagus cancer is the having chance of curative resection and extended lymph node dissection. Extended lymph node dissection and clearing of the regional lymph nodes are important in improving the survival in thoracic esophageal cancer.

**Disclosure:** All authors have declared no conflicts of interest.



**P05.118 THE EFFECT OF EXTENDED SURGERY IN LOWER 1/3 ESOPHAGEAL CANCER OR TYPE I ESOPHAGOGASTRIC JUNCTION TUMORS ON SURVIVAL**

Osman Yüksel<sup>1</sup>, Kürat Dikmen<sup>1</sup>, Zafer Ferahkose<sup>2</sup>, Arif Mert Atak<sup>1</sup>, Murat Akin<sup>1</sup>, Ersin Özdemir<sup>2</sup>

<sup>1</sup>Gazi University Medical School Department Of Surgery, Ankara/TURKEY, <sup>2</sup>Bayındır Hospital, Ankara/TURKEY

**Background:** The reason of the discussion about the type of excision and lymph node dissection in esophagus cancer is depend on the different survival results of different surgical treatments. It's still debate that the standard treatment for lower 1/3 esophageal cancer or type I esophagogastric junction tumors is whether transhiatal or transthoracic. Here in this study, we aimed to evaluate the treatment approaches for distal esophageal cancer.

**Methods:** Total 32 patients who had undergone curative resection and two areas lymph node dissection in the recent 20 years enrolled to the study for lower 1/3 esophageal cancer or type I esophagogastric cancer. The data about age, gender, the size of tumor, the localization of tumor, the length of effected segment, the stage of the tumor, applied surgical treatment, the extend of lymph node dissection, complications following the operations and 5-year survival rates were collected.

**Results:** The histopathology of the tumors composed of squamous cell carcinoma and adenocarcinoma. While 12 patients had lower 1/3 esophageal cancer, 20 patients had type I esophagogastric junction tumor. Neoadjuvant chemotherapy were given to 5 of the patients with lower 1/3 esophageal cancer and 8 of the patients with esophagogastric junction tumors. The number of patients with stage III is higher in both groups. While most of the patients with lower 1/3 esophageal cancer were undergone transthoracic approach, only half of the patients with type I esophagogastric junction tumors were undergone transthoracic approach.

**Discussion:** Appropriate neoadjuvant approaches and proper surgical treatments with low morbidity provide better survivals in patients with lower 1/3 esophageal cancer or type I esophagogastric junction cancers.

**Disclosure:** All authors have declared no conflicts of interest.

**P05.119 ANASTOMOTIC LEAKS AFTER ESOPHAGECTOMY: THE ROLE OF ANASTOMOTIC LOCATION**

Stefano Cafarotti, Venanzio Porziella, Maria Letizia Vita, Maria Teresa Congedo, Elisa Meacci, Stefano Margaritora, Pierluigi Granone  
Catholic University, Department Of General Thoracic Surgery, Rome/ITALY

**Background:** Esophageal anastomotic leaks are associated with considerable morbidity and mortality. Studies comparing the outcome of cervical and intrathoracic anastomosis following esophagectomy are small in size and poorly standardized with respect to surgical approach and anastomotic technique (only nine paper in a recent systematic review). The purpose of this study was to assess the effect of anastomotic location (thoracic or cervical) on anastomotic leak incidence and severity in a large series comparative study.

**Methods:** Between 2002 and 2007, we performed a curative-intent extended esophagectomy in 63 patients with cancer of the esophagus. The clinical outcome of 46 cervical anastomosis (Group A) and 17 thoracic anastomosis (Group B) were analyzed, including leak healing, morbidity, and mortality.

**Results:** The dehiscence rate was 11.1% in group A and 7.93% in group B. When dehiscence occur in the cervical region 24.5% of patients died before the thirtieth post-operative day compared to 60% of patients with thoracic anastomotic leaks.

**Discussion:** On the basis of our findings we suggest the use of esophagectomy with cervical anastomosis due to lower mortality rate related to dehiscence.

**Disclosure:** All authors have declared no conflicts of interest.

**POSTER SESSION P06: MOTILITY DISORDERS – October 17, 2012 12:30–13:30**

**P06.01 THE OUTCOME OF LAPAROSCOPIC SURGERY WITH AND WITHOUT SHORT GASTRIC VESSEL DIVISION FOR ACHALASIA**

Yasunori Akutsu, Naoyuki Hanari, Isamu Hoshino, Tsuguaki Kono, Masaya Uesato, Kiyohiko Shuto, Toshiyuki Natsume, Hideki Hayashi, Mikito Mori, Hisahiro Matsubara  
Department Of Frontier Surgery, Chiba University, Chiba/JAPAN

**Background:** Short gastric vessel division (SGVD) has been performed as a part of fundoplication after myotomy for achalasia. However, whether or not SGVD is necessary is still unknown.

**Methods:** Material and method: Sixty-nine patients with achalasia underwent a laparoscopic surgery with or without SGVD. The length of the

surgery, amount of bleeding and duration of postoperative fever, duration of postoperative starvation and duration of postoperative stay were collected. A questionnaire was administered to assess the postoperative improvement of symptoms, body weight and patients' satisfaction.

**Results:** Results: The duration of postoperative fever was 3.7 days in the SGVD (+) and 2.6 days in the SGVD (-), (P = 0.194), and the duration of postoperative starvation was 3.4 days in the SGVD (+) and 2.5 days in the SGVD (-), (P = 0.724). The duration of postoperative hospital stay was 9.1 days in SGVD (+) and 7.3 days in SGVD (-), (P = 0.054). The symptoms completely disappeared in 55% in the SGVD (+) and in 54% in the SGVD (-), (P = 0.588). As for patients' satisfaction, 95% in the SGVD (+) and 92% in the SGVD (-) answered that the outcome was "satisfactory" (P = 0.326). The pre- and postsurgical body weight increment rate was 7.3% in the SGVD (+) and 8.2% in the SGVD (-), (P = 0.354).

**Discussion:** There were no significant differences in the outcome regardless of SGVD.

**Disclosure:** All authors have declared no conflicts of interest.

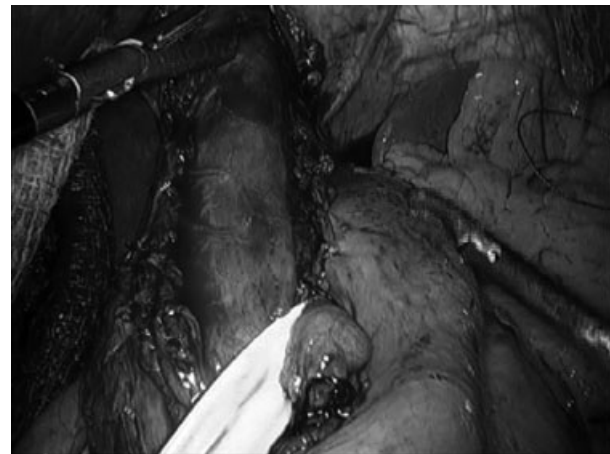
**P06.02 LONG TERM QUALITY OF LIFE AFTER LAPAROSCOPIC HELLER MIOTOMY AND FUNDOPLICATION FOR ACHALASIA TREATMENT**

Andre Brandalise, Nilton Aranha, Nelson Brandalise, Claudia Lorenzetti  
Fundacao Centro Medico Campinas, Campinas/BRAZIL

**Background:** Dysphagia is the major symptom in achalasia. Many treatment options have been proposed in the last years and we intend to present the long term results of laparoscopic Heller myotomy in association with a partial fundoplication.

**Methods:** A specific dysphagia score questionnaire was answered by 56 patients between August 1997 and April 2010, before surgery and during follow-up.

The surgery consisted in a 7–8 cm long myotomy associated with a partial fundoplication with 3 lines of suture: posterior to the esophagus, on the left and on the right edge of the myotomy (Heller-Pinotti).



**Results:** There were 35 women and 21 men. The average operating time was 81 minutes (60–110 min). There were two cases of mucosal perforation noted during surgery and repaired with simple suture, covered by the fundoplication. There were no others complications.

The mean hospitalization period was 1,9 days.

Fifty patients (89%) completed the dysphagia score questionnaire at the follow-up (from 6 to 153 months – average of 53 months).

Comparing pre and postoperative scores, the mean total score dropped from 8,5 to 0,2 points (p < 0,0001) and the mode, which was 10, changed to zero.

Only three (6%) individuals persisted with a score of 6 or 8 and were considered as treatment failure.

**Discussion:** Surgical treatment with the association of a long myotomy and an anti-reflux procedure offers excellent long term results.

These results should be at least reproduced by the new treatment modalities.

**Disclosure:** All authors have declared no conflicts of interest.

### P06.03 TREATMENT OF ESOPHAGO-GASTRIC JUNCTION HYPERTONICITY ALTERS UPPER ESOPHAGEAL SPHINCTER FUNCTION IN PATIENTS WITH ACHALASIA.

Lucas Wauters<sup>1</sup>, Margot Selleslagh<sup>2</sup>, Lukas Van Oudenhove<sup>3</sup>, Guy Boeckxstaens<sup>3</sup>, Taher Omari<sup>3</sup>, Jan Tack<sup>3</sup>, Nathalie Rommel<sup>4</sup>

<sup>1</sup>University Of Leuven, Leuven/BELGIUM, <sup>2</sup>Kuleuven, Leuven/BELGIUM, <sup>3</sup>University Of Leuven, Targid, Leuven/BELGIUM, <sup>4</sup>University Of Leuven, Dept Neurosciences, Exporl, Leuven/BELGIUM

**Background:** Treatment of esophago-gastric junction hypertonicity in patients with achalasia aims at reducing lower esophageal sphincter(LES) pressure through balloon dilation, botox injection or surgery. The secondary effect of treatment on upper esophageal sphincter(UES) function in these patients is unknown. We assessed the association between alterations in LES pressure resulting from therapy and UES pressure patterns in achalasia patients.

**Methods:** High-resolution manometry recordings from 53 achalasia patients were reviewed. Manometric tracings and type of achalasia were classified according to Pandolfino et al(08) and deglutitive UES relaxation to Ghosh et al(06). Basal pressure (BP), 4-second integrated relaxation pressure (IRP4) in LES and minimal relaxation pressure (MRP), peak pharyngeal contraction (PP), relaxation interval (RI), mean intrabolus pressure (IBP), deglutitive sphincter resistance (DSR) in UES were studied. Statistical analysis : mixed model analyses.

**Results:** Data were available from 53 patients (52.7±18.6 yrs, 29 M). LES BP and IRP4s (44 ± 21 vs 26 ± 18 mmHg; p < .0001 and 28 ± 12 vs 16 ± 12 mmHg; p < .0001 respectively) and UES IBP and MRP (32 ± 11 vs 27 ± 8 mmHg; p < .01 and 18 ± 8 vs 15 ± 7 mmHg; p = .01) were reduced after balloon dilation. Positive association between age and LES BP (p = .005) and an association between type of achalasia and LES BP (p = .023) was found. Post-hoc t-tests showed higher LES BP in type 3 compared to type 1&2. Change in IRP4 (pre-vs post-treatment) correlated with change in MRP (p = .046).

**Discussion:** This study demonstrates that treatment of LES hypertonicity in achalasia patients affects both LES and UES function independent of age, gender, type of achalasia, type of treatment and number of treatments. Decreasing sphincter resistance in the LES post therapy corresponds with deeper relaxation of UES resting pressure.

**Disclosure:** All authors have declared no conflicts of interest.

### P06.04 ASSESSMENT OF ESOPHAGEAL MOTOR FUNCTION RELATED TO THE SYMPTOM OF DYSPHAGIA USING COMBINED MULTICHANNEL INTRALUMINAL IMPEDANCE AND MANOMETRY

Noriaki Manabe, Hideaki Tsutsui, Hiroshi Imamura, Hiroaki Kusunoki, Hideo Matsumoto, Jiro Hata, Toshihiro Hirai, Ken Haruma  
Kawasaki Medical School, Kurashiki/JAPAN

**Background:** Little is known about which parameters of esophageal motility would mostly associated with the symptom of dysphagia. The aim of this study was to evaluate esophageal motor function related to the symptom of dysphagia using Combined multichannel intraluminal impedance-esophageal manometry (MII-EM).

**Methods:** From September 2007 through December 2011, after excluding patients with organic diseases, 287 consecutive patients including normal subjects (140 men, 147 women; mean age 56.9 years) who underwent MII-EM were recruited. They all completed a self-administered 7-point Likert scale questionnaire about upper gastrointestinal symptoms before undergoing diagnostic tests.

**Results:** There were two kinds of esophageal motor functions related to the symptom severity of dysphagia: integrated relaxation pressure (IRP) and the ratio of normal peristalsis (Table 1). **Table 1. Relation between symptom severity of dysphagia and esophageal motor function -Pearson's correlation analysis method-**

Esophageal motor function	coefficient of correlation	P value
PFV (cm/sec)	0.27	<0.01
DCI (mmHg.cm.sec)	0.12	0.21
IRP (mmHg)	0.42	<0.01
Ratio of normal peristalsis (%)	-0.40	<0.01
CBT (liquid) (%)	-0.23	<0.01
CBT (viscous) (%)	-0.18	<0.05
Distal esophageal amplitude (mmHg)	-0.095	0.15
LESP (mmHg)	0.29	<0.01
The ratio of LES relaxation (%)	-0.11	0.17

NOTE: We considered it to have a clinically significant relationship when the absolute value of the coefficient of correlation was more than 0.40. PFV, pressurization front velocity; DCI, distal contractile integral; CBT, complete bolus transit; LESP, lower esophageal sphincter pressure.

**Discussion:** The symptom of dysphagia was affected by esophageal body and lower sphincter function to the same degree.

**Disclosure:** All authors have declared no conflicts of interest.

### P06.05 ZENKER DIVERTICULUM: EVALUATION OF SURGICAL AND ENDOSCOPIC TREATMENTS.

Maria Aparecida Henry, Mauro Lerco, José Vicente Tagliarini  
School Of Medicine – Botucatu – Unesp, Botucatu/BRAZIL

**Background:** The aim of this study was to comparatively evaluate the clinical and therapeutical aspects of patients with Zenker diverticulum submitted to surgical and endoscopic approaches.

**Methods:** Retrospective analysis of 36 patients with Zenker diverticulum. They were divided in 2 groups: Group 1 (n = 24) - diverticulectomy plus cricopharyngeal myotomy using left cervicotomy; Group 2 (n = 12) – endoscopic diverticulostomy with linear stapling.

**Results:** No deaths occurred in either group. Four patients suffered immediate postoperative complications in Group 1 (2 small fistula and 2 hoarseness); none in Group 2. Four Group 2 patients (33%) suffered late postoperative complications (dysphagia recurrence); a new endoscopic procedure was necessary. No recurrence of dysphagia was seen in Group 1. Mean follow-up was 33 months for Group 1 and 28 months for Group 2.

**Discussion:** Both procedures are effective for dysphagia remission. Surgery has proven more effective as symptoms disappear after one procedure. Endoscopic treatment should be used in the elderly or those with comorbidities.

**Disclosure:** All authors have declared no conflicts of interest.

### P06.06 USING THE HELLER-PINOTTI SURGERY TO TREAT THE HYPERTENSIVE LOWER ESOPHAGEAL SPHINCTER

Maria Aparecida Henry, Mauro Lerco  
School Of Medicine – Botucatu – Unesp, Botucatu/BRAZIL

**Background:** The hypertensive lower esophageal sphincter is a motor disorder of low incidence. It is characterized by high pressure in the lower esophageal sphincter (higher than 45 mmHg), with normal sphincter relaxation and peristalsis. The predominant symptom is dysphagia generally associated with thoracic pain. The treatment for such disease can be clinical (calcium channel blockers), endoscopic (botulinum toxin injection, cardia dilation) or surgical (cardiomyotomy). Objective: To present the clinical and therapeutic aspects of patients with this disease who underwent the Heller-Pinotti surgery.

**Methods:** Two adult patients with negative serology for Chagas disease were operated due to complaints about dysphagia. The manometric study showed pressures in the lower esophageal sphincter from 82.2 to 48.5 mmHg, respectively. Cardiomyotomy with a partial antireflux valve (Heller-Pinotti) was performed on both patients.

**Results:** Their development was satisfactory, with dysphagia remission and weight gain.

**Discussion:** The Heller-Pinotti surgery is an excellent therapeutic option for the hypertensive lower esophageal sphincter.

**Disclosure:** All authors have declared no conflicts of interest.

### P06.07 ESOPHAGECTOMY IN AN ACHALASIA PATIENT WHO HAD PREVIOUSLY UNDERGONE PROXIMAL GASTRECTOMY

Tomotaka Shibata<sup>1</sup>, Natsuya Katada<sup>1</sup>, Shinichi Sakuramoto<sup>1</sup>, Hiroaki Mieno<sup>1</sup>, Masayuki Nemoto<sup>1</sup>, Keishi Yamashita<sup>1</sup>, Tsuyoshi Noguchi<sup>2</sup>, Masahiko Watanabe<sup>1</sup>  
<sup>1</sup>Surgery, Sagamiharu/JAPAN, <sup>2</sup>Surgical Division, Center For Community Medicine, Faculty Of Medicine, Oita University, Yufu City, Oita/JAPAN

**Background:** We report a case of an achalasia patient who underwent esophagectomy 30 years after proximal gastrectomy.

**Methods:** A 59-year-old woman with achalasia underwent proximal gastrectomy 30 years ago. Her symptoms showed temporary improvement, but they soon recurred. For 30 years after surgery, she had been eating only cookies every day. When she visited our hospital, we performed an upper gastrointestinal series, which showed a sigmoid-shaped dilated esophagus and a bird-beak-shaped lower esophagus with stenosis. Endoscopic examination showed residual food in the esophagus; nevertheless, a fiberscope could pass through the lower esophageal sphincter (LES). A manometric examination showed that the LES pressure was 15.7 mmHg, percentage of LES relaxation was 67%, and body motility had disappeared. Pneumatic dilation was performed 2 times, but the symptoms did not improve.

**Results:** Thereafter, we performed esophagectomy and reconstruction via the subcutaneous route. During the postoperative course, slight esophagojejunal anastomotic leakage occurred, but it gradually improved. Pathological examination indicated superficial squamous cell carcinoma in the proximal edge of the esophagus.

**Discussion:** Now, her eating habits are normal, and the anastomosis is being observed carefully. Few cases of esophagectomy in an achalasia patient who had previously undergone proximal gastrectomy have been reported in the literature.

**Disclosure:** All authors have declared no conflicts of interest.

#### P06.08 MINIMALLY INVASIVE SURGERY FOR ACHALASIA

Daniel Tong, Simon Law, Fion Chan  
*Department Of Surgery, The University Of Hong Kong, Hong Kong/  
HONG KONG*

**Background:** There are various surgical treatment approaches for achalasia. The outcome of achalasia patients treated with surgery is evaluated.

**Methods:** From 1994 to 2011, 63 with achalasia were treated by myotomy with or without anti-reflux procedure. The demographics and peri-operative outcomes were analyzed.

**Results:** The median age of the studied population was 37 years (range: 13–67) and 29 (46%) were men. The median duration of symptoms prior to presentation was 18 months (range: 1–36). Prior to surgery, 12 (19%) patients had had non-operative intervention; one patient (1.6%) had botulinum toxin injection and 11 (17.5%) had balloon dilatation. The median number of dilatations was 1 (range: 1–5). Surgical procedures evolved over time; which included thoracoscopic myotomy (n = 9, 14.3%), laparoscopic myotomy (n = 13, 20.6%), laparoscopic myotomy plus Dor hemifundoplication (n = 27, 42.9%), and robotic-assisted laparoscopic myotomy plus Dor hemifundoplication (n = 14, 22.2%). There was no conversion to open surgery. Four patients (6.3%) had esophageal mucosal perforations, all were repaired with no postoperative leak. Pulmonary complication was higher using the thoracoscopic compared to laparoscopic approach, at 33.3% vs. 1.9% (p < 0.01). The duration of follow-up was 25 months (range: 1–150). The mean dysphagia score improved from 3.08 to 1.22 postoperatively. Reflux esophagitis was documented in 9 (40.9%) and 1 (2.4%) patients without and with anti-reflux procedure respectively (p < 0.01). Two patients required balloon dilatation related to persistent dysphagia.

**Discussion:** Minimally invasive surgery for achalasia provides durable and excellent symptomatic relief. Anti-reflux procedure significantly reduces postoperative acid reflux.

**Disclosure:** All authors have declared no conflicts of interest.

#### P06.09 A CASE OF ESOPHAGEAL ACHALASIA COMPLICATED BY EARLY GASTRIC CANCER

Fumiaki Yano, Nobuo Omura, Kazuto Tsuboi, Masato Hoshino, Seryon Yamamoto, Shunsuke Akimoto, Yoshio Ishibashi, Norio Mitsumori, Hideyuki Kashiwagi, Katsuhiko Yanaga  
*Jikei University School Of Medicine, Tokyo/JAPAN*

**Background:** Gastric cancer is known as a common gastrointestinal malignancy in Asian people. On the other hand, the incidence of achalasia is low at 1 in 100,000 in Japan. We report a patient who has esophageal achalasia complicated by early gastric cancer.

**Methods:** A 65-year-old male patient was pointed out to have abnormality in the esophagus by the barium contrast examination. He then underwent endoscopy to examine the esophagus. Although his esophagus was normal, he was diagnosed to have early gastric cancer and was referred to us. The depth of tumor invasion assessed by endoscopic ultrasonography was submucosal invasion. Therefore, we decided to perform gastrectomy. In an esophageal contrast X-ray in our hospital, the lower esophagus was significantly curved and the greatest transverse diameter of the esophagus was 43 mm. Finally, he was diagnosed to have esophageal achalasia complicated by early gastric cancer.

**Results:** Laparoscopic Heller myotomy (HM) and Dor fundoplication, as well as laparoscopy-assisted distal partial gastrectomy were performed using a total of 5 trocars. First, he underwent HM. We usually divide the whole short gastric vessels to relieve the tension from the wrap but not in this patient to avoid lack of blood flow of the remnant stomach. The duration of surgery was 295 min and the blood loss was minimal. During HM, esophageal mucosal injury was confirmed and repaired laparoscopically. His postoperative course was unremarkable except for left shoulder pain and he was discharged postoperative day 21.

**Discussion:** We experienced a case of esophageal achalasia complicated by early gastric cancer.

**Disclosure:** All authors have declared no conflicts of interest.

#### P06.10 PRIMARY LAPAROSCOPIC CARDIOMYOTOMY FOR ACHALASIA: EXPERIENCE OF A SPECIALIST UPPER GI UNIT. IS IT TIME FOR CENTRALISATION?

Alex Humphreys, Alex Karran, Ashraf Rasheed  
*Gwent Institute For Minimal Access Therapy, Newport/UNITED KINGDOM*

**Background:** Despite recognition of laparoscopic cardiomyotomy (LCM) as the standard of care in the management of achalasia, the number remains to be small and the outcome is variable. The aim of this study is to audit the clinical outcome of primary laparoscopic cardiomyotomy for such an uncommon disease “achalasia of the cardia” in a specialist upper GI unit.

**Methods:** A retrospective data base of all laparoscopic cardiomyotomy cases performed at our unit in the last 5 years was constructed including patient's demographics, indications, diagnostic work up, details of surgical technique, success rate, operating time, duration of hospital stay, symptomatic relief of chest pain, dysphagia, regurgitation, globus sensation, persistent or recurrent dysphagia at three months and annual clinical follow-up visits.

**Results:** There were 10 cases of LCM (median age of 43, range 17–68 yrs old), 6 males and 4 females. Nine had documented follow up (4 to 104 weeks). The primary presenting symptoms included variable levels of dysphagia in 6 cases, regurgitation in 2, nausea in 4, vomiting in 4, indigestion in 3, weight loss in 4 and haematemesis in 2. Barium swallow, endoscopy, pH and manometry were attempted in all cases. Four out of the 10 patients had a failed pneumatic dilatation and no patients in this series underwent Botulinum toxin injection. Six patients underwent anterior fundoplication. Four out of the 9 patients reported complete resolution of symptoms (3 had anti-reflux surgery), 4 had mild persistent symptoms and one patient reported severe recurrent symptoms demanding re-operation.

**Discussion:** Reasonable symptomatic relief is achieved in this series however; no firm conclusions can be drawn from such a small series. The low procedure volume for this uncommon disease supports the need for centralization.

**Disclosure:** All authors have declared no conflicts of interest.

#### P06.11 PNEUMATIC BALLOON DILATATION OF THE PYLORUS IN POSTOPERATIVE PATIENTS WITH SYMPTOMS SUGGESTIVE OF GASTRIC OUTLET OBSTRUCTION

Jon Tsai<sup>1</sup>, Jessica Ericson<sup>2</sup>, Berit Sunde<sup>3</sup>, Mats Lindblad<sup>1</sup>, Lars Lundell<sup>1</sup>, Magnus Nilsson<sup>1</sup>

<sup>1</sup>Karolinska University Hospital Huddinge, Gastrocentrum K53, Stockholm SWEDEN, <sup>2</sup>Karolinska University Hospital Huddinge Gastrocentrum B73, Stockholm/SWEDEN, <sup>3</sup>Karolinska University Hospital Huddinge, Gastrocentrum K61, Stockholm/SWEDEN

**Background:** Functional gastric outlet obstruction may occur after esophagectomy and also after repetitive anti-reflux procedures. Endoscopic, through the scope, balloon dilatation (<20 mm diameter) of the pylorus has often been used to address this condition. We here report the experience of pneumatic dilatation of the pyloric sphincter region according to the same principle as used for the lower esophageal sphincter (LES) in achalasia.

**Methods:** A review of all patients who had undergone pneumatic dilatation of the pylorus sphincter because of gastric outlet obstruction at the Karolinska University Hospital, between 2006–2011, was completed. The dilatations were done under general anesthesia and ranged from 30 to 35 mm in balloon diameter.

**Results:** 13 patients had been treated accordingly after an esophagectomy and 4 after a repetitive anti-reflux procedure. The median time between esophagectomy and the first dilatation was 100 days and after anti reflux surgery the corresponding time was 534 days. The patients underwent a total of 30 dilatations to a final median diameter of 30 mm after esophagectomy and 35 mm after anti-reflux surgery. The median follow-up time was 205 days after esophagectomy and 57 days after anti-reflux surgery. Nausea and regurgitation improved significantly in patients after esophagectomy (p < 0.001, Fisher's test). No significant overall effect was observed in those having similar complaints after anti-reflux surgery.

**Discussion:** Pneumatic dilatation of the pylorus using a large diameter pneumatic balloon seems to be an effective and safe method for treating gastric-graft outlet obstruction after esophagectomy, an effect, which cannot be seen after failed anti-reflux surgery.

**Disclosure:** All authors have declared no conflicts of interest.

#### P06.12 EXTENDING MYOTOMY MORE THAN TWO CENTIMETERS ON THE GASTRIC SIDE DOES NOT INFLUENCE THE FINAL OUTCOME OF LAPAROSCOPIC HELLER-DOR FOR ESOPHAGEAL ACHALASIA

Renato Salvador<sup>1</sup>, Valentina Caruso<sup>2</sup>, Mario Costantini<sup>1</sup>, Luca Faccio<sup>1</sup>, Giulia Pozza<sup>1</sup>, Paolo Parise<sup>2</sup>, Loredana Nicoletti<sup>1</sup>, Stefano Rocchietto<sup>2</sup>, Giorgia Dogà, Francesco Cavallin<sup>3</sup>, Ermanno Ancona<sup>1</sup>, Giovanni Zaninotto<sup>2</sup>

<sup>1</sup>University Of Padua, Department Of Surgical And Gastroenterological Sciences, Clinica Chirurgica 1, Padua/ITALY, <sup>2</sup>Department Of General Surgery, Ss Giovanni E Paolo Hospital, Ulss 12, Venezia/ITALY, <sup>3</sup>Surgical Oncology, Istituto Oncologico Veneto, Iov-Irccs, Padova/ITALY

**Background:** The right length of the myotomy on the gastric side for esophageal achalasia is still a debated issue. We aimed to investigate the final outcome after classic myotomy (CM) as compared with a longer myotomy on the gastric side (LM) in two cohorts of patients.

**Methods:** 44 achalasia patients underwent laparoscopic Heller-Dor were considered; patients with a sigmoid-shaped esophagus were excluded. Symp-

toms were scored using a detailed questionnaire. Barium-swallow, endoscopy and esophageal manometry were performed before and 6 months after the treatment; 24-hour pH-monitoring was performed 6 months after the procedure. CM was defined as a gastric myotomy length in the range of 1.5–2.5 cm, while LM was 2.5–3 cm in length. The surgical treatment (CM or LM) was adopted in two consecutive cohorts. Treatment failure was defined as a postoperative symptom score >10<sup>th</sup> percentile of the preoperative score (i.e. >8).

**Results:** 20 patients had CM and 24 had LM. The patients' demographic and clinical parameters (age, symptom-score, symptoms duration, esophageal diameter, manometric-pattern) were similar in the two groups. The median follow-up was 24 months (IQR:12–39). One patient in each group was a failure. After the treatment, there was a significant decrease in both groups' symptom score, and resting/residual pressure ( $p < 0.01$ ), with no statistically significant differences between the two groups in terms of post-operative symptom score, resting-residual pressure, total/abdominal length and esophageal diameter.

**Discussion:** Extending the length of the myotomy on the gastric side does not seem to change the final outcome of the laparoscopic Heller-Dor procedure.

**Disclosure:** All authors have declared no conflicts of interest.

#### P06.13 REMISSION OF ARTHRITIS AFTER ESOPHAGECTOMY IN THREE PATIENTS WITH SEVERE ACHALASIA

Karl-erik Johansson, Per Eriksson, Claudia Jacobs  
*Department Of Surgery, Linköping/SWEDEN*

**Background:** Sero-negative, intermittent and non-erosive arthritis was observed after intestinal by pass surgery. Bacterial overgrowth and immune complex formation have been considered as pathogenetic factors. Surgical restitution of normal bowel anatomy is curative.

**Methods:** Three patients with end-stage achalasia and arthritis from the departments of rheumatology and surgery at a university hospital are presented.

**Results:** 1. 42-year male, 1993 food retention, 1995 balloon dilatation. October 2005 acute polyarthritis with CRP 284 mg/l. November 2005 gastrostomy, draining tube in the esophagus and antibiotics. February 2006 Ivor-Lewis esophagectomy. No joint symptoms at long term follow up. 2. 56-year male with dysphagia for 30 years and arthralgia. 2000 laparoscopic myotomy due to obstruction and severe esophageal dilatation. Postoperative anemia and polyarthritis and a month later PEG. 2002 laparoscopic myotomy again. The joint symptoms became chronic. He got 1500 kcal in the gastrostomy. The patient tried prednisolone, methotrexate, sulfasalazine, infliximab, etanercept, adalimumab and anakinra. 2008 esophagectomy with gastric pull up and a cervical anastomosis. Two years later no signs of arthritis and normal swallowing. 3. Female born in 1921, was treated with self-dilatations for 18 years. 1962 transthoracic myotomy. 1965–1972 8 episodes of arthralgia in peripheral joints. 1972–1976 ESR 11–52 mm. Short courses of prednisolone and aspirin. 2005 transhiatal esophagectomy due to bleeding ulcer. Three months later substernal coloninterposition. Now she is free from joint symptoms and can eat normally.

**Discussion:** "Retention esophagitis" promotes translocation of toxins from bacterial and fungal infections. The disease mechanisms causing arthritis are probably the same as those after intestinal by pass.

**Disclosure:** All authors have declared no conflicts of interest.

#### P06.14 SPONTANEOUS ESOPHAGEAL RUPTURE IN A PATIENT WITH CHRONIC RENAL FAILURE

Yosuke Kano, Shin-ichi Kosugi, Kenji Usui, Yu Sato, Kaoru Sakamoto, Takashi Ishikawa, Kazuhito Yajima, Tatsuo Kanda, Katsuyoshi Hatakeyama  
*Division Of Digestive And General Surgery, Niigata University Graduate School Of Medical And Dental Sciences, Niigata/JAPAN*

**Background:** Spontaneous esophageal rupture is usually caused by a sudden increase in intraesophageal pressure, such as occurs with vomiting, with the most commonly affected site being the left posterolateral wall of the lower esophagus.

**Methods:** Herein, we report on a case of unusual esophageal rupture that occurred in the absence of an episode of vomiting.

**Results:** A 58-year-old man who had chronic renal failure due to polycystic kidney disease and had been on hemodialysis for 3 years suddenly developed chest discomfort and pain. He had not experienced any episodes of vomiting and had not overindulged in food and drink prior to the onset of symptoms. He was given a diagnosis of esophageal rupture at a local hospital and was referred to our hospital for surgical intervention. Computed tomography revealed a severely dilated esophagus with considerable debris in the lumen and a perforation in the right wall of the middle esophagus. At surgery, the

esophageal tear (~8 cm in length) was sutured in two layers under right thoracotomy and was reinforced with the pedicled omentum that was pulled up through the esophageal hiatus. Although leakage followed by mediastinal abscess occurred, it was managed satisfactorily by surgical drainage. The patient was discharged on postoperative day 48. Esophageal manometry prior to discharge revealed no decrease in lower esophageal sphincter pressure after swallowing, which was consistent with esophageal achalasia.

**Discussion:** The spontaneous esophageal rupture that occurred in this patient without prior vomiting may be related to a motor disorder of the esophagus.

**Disclosure:** All authors have declared no conflicts of interest.

#### P06.15 A NOVEL DISPOSABLE MINIATURIZED ENDOSCOPE FOR ASSESSMENT OF ESOPHAGEAL MOTOR FUNCTION

Chul-hyun Lim, Myung-gyu Choi, Yu Kyung Cho, Myong-ki Baeg, Jae Myung Park  
*The Catholic University Of Korea, Seoul/KOREA*

**Background:** Recently, A novel disposable miniaturized endoscope with a portable system (E.G.Scan™, IntroMedic Co, Ltd, Seoul, Korea) has been developed by modifying capsule endoscopy. This device provides unsedated esophagoscopy in outpatients and is in clinical trials to monitor acute upper gastrointestinal bleeding. The aim of this study was to assess the feasibility of miniaturized endoscopy to test esophageal motor function.

**Methods:** Participants underwent both esophageal high resolution manometry and miniaturized endoscopy on separate days. Motility observation via miniaturized endoscopy was made with three sets of five wet swallows of 3 ml distilled water at 1, 8 and 16 cm above the Z-line. Esophageal manometry was performed using high resolution manometry (Sierra scientific instruments, Inc, Los Angeles, USA).

**Results:** 7 healthy volunteers and patients (6 achalasia, 4 scleroderma) participated in this study. The normal findings of miniaturized endoscopy were as follows; (1) as swallow-induced relaxation and oral elevation of LES occurs, the capsule crosses the Z-line into the gastric lumen. After passage of water followed by gas, complete closure of LES with return to its previous position can be seen by the capsule. (2) In the esophageal body's resting stage, an air-bubble can be seen in the center of the radially wrinkled and occluded lumen. A swallow-induced relaxation followed by complete occlusive contraction clears the water and air, the lumen closes and returns to the resting occluded radial wrinkles. The results obtained by miniaturized endoscopy were comparable to those of the high resolution manometry & clinical information (Table).

**Table. Endoscopic Findings of the participant according to diagnosis**

Endoscopic Finding		Healthy	Achalasia	Scleroderma
		(N = 7) Normal	(N = 6) Turbid Fluid Retention	(N = 4) Reflux esophagitis Patent LES
LES	swallow-induced relaxation	7 (100%)	0 (0%)	2 (50%)
	poor relaxation	0 (0%)	0 (0%)	2 (50%)
	no relaxation	0 (0%)	6 (100%)	0 (0%)
	LES contraction after relaxation	7 (100%)	NA	0 (0%)
Mid-Body	radially wrinkled and occluded lumen	7 (100%)	0 (0%)	2 (50%)
	complete contraction	7 (100%)	1* (16.7%)	2 (50%)
	no or poor contraction	0 (0%)	5 (83.3%)	2 (50%)
	normal peristalsis	7 (100%)	0 (0%)	2 (50%)
	no peristalsis	0 (0%)	6 (100%)	1 (25%)
	poor peristalsis	0 (0%)	0 (0%)	1 (25%)
	complete transit	7 (100%)	0 (0%)	1 (25%)
no or incomplete transit	0 (0%)	6 (100%)	3 (75%)	

\*Type III Achalasia

**Discussion:** In addition to the endoscopic functions, miniaturized endoscopy can accurately characterize normal esophageal motor functions, enabling us to diagnose esophageal motility disorders. In view of its portability and no need for sedation, miniaturized endoscopy may have the potential of widespread application especially in outpatient clinics.

**Disclosure:** All authors have declared no conflicts of interest.

**P06.16 LAPAROSCOPIC ESOPHAGOGASTROSTOMY WITH ESOPHAGOPEXY: AN ALTERNATIVE TO ESOPHAGECTOMY FOR MEGAESOPHAGUS DUE TO ACHALASIA**

Asit Arora, Amit Javed, Anil Agarwal  
Gb Pant Hospital & Mam College, New Delhi INDIA

**Background:** The treatment of esophageal achalasia targets the sphincter (LES) and pneumatic dilatation or cardiomyotomy is effective in most patients. This treatment however is less satisfactory in patients with megaesophagus and many authors recommend esophagectomy as the primary treatment. We describe a simple minimally invasive technique which can be an effective alternative treatment option in these patients.

**Methods:** The procedure is performed laparoscopically using an umbilical camera port and 3 working ports. The gastroesophageal junction/lower esophagus is mobilized so that a part of the redundant intrathoracic esophagus is pulled into the abdomen and is suture fixed to the esophageal hiatus (esophagopexy). A small gastrotomy is made at the cardia and an endoscopic stapler (Endo-GIA) is introduced such that one end of the stapler is in the fundus and the other in lower esophagus across the LES. Firing of the stapler results in a wide esophagogastrotomy with disruption of the sphincter. A nasogastric tube is passed across the anastomosis into the stomach and the anterior gastrotomy is closed.

**Results:** Three patients (two males and one female) with megaesophagus were considered for this procedure. The age of the patients was 17, 31 and 36 years and mean duration of dysphagia was 5 (range 1–8) years. The mean duration of surgery was 140 minutes and the mean operative blood loss 50 ml. All patients were allowed orally by 3rd postoperative day. At a mean follow-up of 14 months, all patients are euphagic to both solid and liquid diet, have no symptoms of reflux and esophagogram has shown a significant reduction in the size and tortuosity of the megaesophagus.

**Discussion:** Esophagogastrotomy provides effective relief of dysphagia in patients with megaesophagus and can be an effective alternative treatment option in these patients with esophagectomy being reserved as the last resort for non responders.

**Disclosure:** All authors have declared no conflicts of interest.

**P06.17 LONG-TERM EVALUATION OF PATIENTS WITH ESOPHAGEAL PERFORATION AFTER PNEUMATIC DILATATION FOR IDIOPATHIC ACHALASIA**

Fernando Mingol<sup>1</sup>, Vicente Ortiz<sup>2</sup>, Homero Beltran<sup>1</sup>, Maria Aguilar<sup>1</sup>, Manuel De Juan<sup>1</sup>

<sup>1</sup>Hospital Universitario Y Politecnico La Fe, Valencia SPAIN, <sup>2</sup>Hospital Universitario Y Politecnico La Fe, Valencia SPAIN

**Background:** To assess the quality of life (HRQoL) and long-term clinical outcome in patients undergoing surgery for esophageal perforation after pneumatic dilatation (PD) for achalasia.

**Methods:** 510 patients with achalasia have been treated in our hospital by forced dilatation. Nine cases (1.7%) had a perforation that required surgical treatment, 6 of them after the first session of PD and 3, after the second session. Perforation diagnosis: clinical data, chest X-ray or CT (orally water-soluble contrast in suspected cases). Achalasia diagnosis: esophageal manometry, esophagogram and upper endoscopy. Surgery: perforation suture, Heller's myotomy and DOR fundoplication. Patients evaluation: 3 months after surgery. In 6 cases there has been a recent evaluation (mean 5.5 years; limits 1–19 years) clinical and HRQoL (SF-36) and specific (AE-18) instruments for HRQoL, manometry, impedance-pH monitoring, esophagogram and endoscopy.

**Results:** In 9 cases, (5 female), mean age 53 years (SD 20 years). The median time from the PD to surgery was 24 (2–48) hours; 16 (7–58) days for average stay. Patients improvement was 100% at short and in the long term (90%). Generic HRQoL was lower than in the general Spanish population, but specific HRQoL was similar than patients treated with PD without complications. LES pressure was 27 (11–36) mmHg prior to PD, 5 (0–8) mmHg at 3 months and 5 (0–8) mmHg in the long term.

**Discussion:** Patients who require surgery after PD have a good status based on subjective and objective data, HRQoL, assessed at long-term, is lower than general population but similar to those treated with PD without complications.

**Disclosure:** All authors have declared no conflicts of interest.

**P06.18 LAPAROSCOPIC MYOTOMY PLUS FUNDOPPLICATION (LM+F) FOR END STAGE CHAGAS' ACHALASIA – 10 YEAR FOLLOW-UP**

Ivan Ceconello<sup>1</sup>, Rubens Sallum<sup>2</sup>, Julio Rocha<sup>3</sup>, Ary Nasi<sup>1</sup>, Sergio Szachnowicz<sup>2</sup>, Francisco Seguro<sup>2</sup>, Flavio Takeda<sup>1</sup>

<sup>1</sup>Esophageal Surgical Division Univ Of Sao Paulo, Sao Paulo BRAZIL, <sup>2</sup>University Of Sao Paulo, Sao Paulo BRAZIL, <sup>3</sup>Esophageal Surgical Division Univ Of Sao Paulo, Sao Paulo, Brazil, Sao Paulo BRAZIL, <sup>4</sup>Department Of Gastroenterology – Esophageal Surgical Division, University Of São Paulo School Of Medicine, São Paulo - Brazil, São Paulo BRAZIL, <sup>5</sup>Hospital Das Clinicas - Fmusp, São Paulo BRAZIL

**Background:** In Chagas' achalasia (CA), the esophageal myotomy is the most frequently performed surgical procedure. However, results of the long-term follow up for advanced forms became often a topic of discussion. The aim of this study is to evaluate the outcome following LM+F for end-stage CA patients treated.

**Methods:** 32 patients classified as end-stage CA were submitted to LM+F and followed up. Seventeen were males (53.1 %) and 15, female, median age of 54,8 years (range 18–83).

**Results:** Average follow-up was 10,1 years (range 2,3–13,2 yrs). Complete relief of dysphagia was observed in nineteen patients (59,3%) and improved significantly in other eight (25,0%), both without further treatment (86,9%). Poor results was achieved in the remaining five cases (15,6%), three of them underwent posteriorly esophagectomy (9,3%) and the other was treated with endoscopic dilatation. Average body mass index ranged from 18,1 kg/m<sup>2</sup> preoperatively to 23,6 kg/m<sup>2</sup>, postoperatively. No mortality was observed in those cases during the follow-up period.

**Discussion:** Laparoscopic M+F can be an adequate and safe approach for selected cases of advanced achalasia and exclude the majority of cases from esophagectomy that may be used posteriorly.

**Disclosure:** All authors have declared no conflicts of interest.

**P06.19 WHAT HAPPENS WITH THE WEAK MOTILITY OF BARRETT'S ESOPHAGUS (BE) AFTER ANTIREFLUX SURGERY (ARS)?**

Angela Falcao<sup>1</sup>, Sergio Szachnowicz<sup>2</sup>, Ary Nasi<sup>1</sup>, Rubens Sallum<sup>2</sup>, Francisco Seguro<sup>2</sup>, Ivan Ceconello<sup>2</sup>

<sup>1</sup>Esophageal Surgical Division Univ Of Sao Paulo, Sao Paulo BRAZIL, <sup>2</sup>Department Of Gastroenterology – Esophageal Surgical Division, University Of São Paulo School Of Medicine, São Paulo – Brazil, São Paulo BRAZIL

**Background:** Abnormal esophageal motility is frequent in Barrett's esophagus; isn't yet clear if is a primary abnormality or a consequence of injury. Non-propagated contractions, simultaneous or low amplitude contractions compromise esophageal clearance. That suggests extension of the inflammatory process to the muscle layer, affecting esophageal motility. Surgical treatment would decrease the inflammation of the esophageal mucosa improving the change in esophageal motor function. Objective: Access the effect of antireflux surgery on esophageal motility in patients with Barrett's esophagus with esophageal motility disorder.

**Methods:** We evaluated 19 consecutive Barrett's patients operated with esophageal dismotility. Inclusion criteria were: 12 months of minimum follow-up, asymptomatic patients out of PPIs, with endoscopy study without esophagitis and topic fundoplication.

**Results:** 60% of patients with severe hypocontractility of the esophageal body contraction improved, reaching normal value in 55.5% of them. In 26.6% contraction got worse and 13.3% remained with severe hypocontractility. Ten patients (66.6%) did not showed abnormalities in esophageal peristalsis (EP) pre or postop. Two patients (13.3%) without preoperative dismotility developed alterations, 2 with abnormal EP did not improved and one (0.6%) with previous esophageal dismotility improve the EP. Besides the motility alterations there were no patients with dysphagia after surgery even with abnormal EP.

**Discussion:** Conclusion: After surgical treatment for Barrett's majority of patients improved esophageal contractility, although patients achieve clinical control by pH metry, the improve of the Esophageal dismotility was observed just in one patient. No case of dysphagia was observed.

**Disclosure:** All authors have declared no conflicts of interest.

**P06.20 HIGH RESOLUTION MOTILITY ASSESSMENT OF THE ESOPHAGEAL BODY IN PATIENTS WITH PARAESOPHAGEAL HIATAL HERNIA**

Stefan Niebisch, Marek Polomsky, Candice Wilshire, Carolyn Jones, Virginia Litle, Christian Peyre, Thomas Watson, Jeffrey H Peters  
*University Of Rochester Medical Center, Rochester/UNITED STATES OF AMERICA*

**Background:** The clinical management of patients with paraesophageal hernia (PEH) has become quite common. Given the primary focus on hernia repair, the utility of motility testing in those patients is unclear. The availability of High Resolution Manometry (HRM), often emergent presentation and complex anatomy limit the routine use of preoperative motility. Our aims were to characterize preoperative esophageal function in patients with PEH and to determine the prevalence of esophageal dysmotility.

**Methods:** Eighty patients (age  $64.5 \pm 11.9$  years; BMI  $30.7 \pm 5.8$ ; 65% female) with PEH, who underwent preoperative HRM from December 2006 to October 2011, formed the study population. HRMs were reanalyzed using current motility classifications. Assessment of the lower esophageal sphincter (LES) was possible in 26% in which the catheter was passed through the diaphragmatic crura.

**Results:** Esophageal body function including wave propagation and circular muscle strength was normal in 35/80 (44%) of patients. A simultaneous/spastic contraction pattern was present in 17.5% and abnormal contraction strength in another 17.5%. Manometric evidence of functional outflow obstruction was present in 36.3% of patients. One patient met criteria for Achalasia. Manometric evidence of the sliding component of the PEH was present in 81% with a mean length of  $4.1 \pm 2.1$  cm. Overall LES length was short in 67% patients and 10% were hypertensive at rest.

**Discussion:** Significant abnormalities are present in a large percentage of patients with PEH. Nineteen percent have severely compromised circular muscle strength. These data suggest that HRM should be included in the preoperative evaluation of patients with PEH whenever possible.

**Disclosure:** All authors have declared no conflicts of interest.

**P06.21 ERLY SURGICAL COMPLICATIONS OF COLONIC INTERPOSITION**

Luca Faccio<sup>1</sup>, Silvia Mantoan<sup>1</sup>, Gianpietro Zanchettin<sup>1</sup>, Michele Valmasoni<sup>1</sup>, Mario Costantini<sup>1</sup>, Tiziana Morbin<sup>1</sup>, Rita Alfieri<sup>2</sup>, Matteo Cagol<sup>2</sup>, Carlo Castoro<sup>2</sup>, Alberto Ruol<sup>1</sup>, Ermanno Ancona<sup>1</sup>  
<sup>1</sup>*University Of Padua, Department Of Surgical And Gastroenterological Sciences, Clinica Chirurgica 1, Padova/ITALY*, <sup>2</sup>*Surgical Oncology, Veneto Oncological Institute, Padova/ITALY*

**Background:** Colonic Interposition (CI) is the most common technique of reconstruction of the alimentary tract in patients with esophageal diseases when the stomach cannot be used. The aim of this study was to evaluate early surgical complications after CI.

**Methods:** From 1989 to 2010, 159 patients underwent CI for benign (62 pts) or malignant diseases (97 pts) of the esophagus (M/F:102/57, median age 53 years, FU > 6 months). We defined as short-term complications those occurring within 3 months after surgery.

**Results:** Intraoperative complications were: 13 recurrent laryngeal nerve lesions, 2 spleen injuries. Postoperative complications were: 13 leakages (11 of the proximal and 2 of the distal anastomosis: all were treated conservatively); 3 colonic necroses that required reintervention and 1 necroses limited to the colonic mucosa, treated conservatively. We observed 6 strictures of the proximal anastomosis (5 treated with endoscopic dilations and 1 with surgical revision) and 3 of the distal anastomosis (1 required reoperation). Other complications were: 6 bleeding (4 required reoperation), 4 abdominal abscesses (drained radiologically), 3 chylothorax (1 needed reoperation). We recorded 6 postoperative deaths; one death was related to surgical complications.

**Discussion:** CI is technically demanding, and the risk of developing severe surgical complications is not negligible. Patients with malignancies have a higher incidence of short-term complications compared to patients with benign diseases (38% vs. 27%), especially laryngeal nerve lesions (11% vs. 3%) and anastomotic leakages (12% vs. 1.6%). All postoperative deaths were recorded in patients with malignant diseases.

**Disclosure:** All authors have declared no conflicts of interest.

**P06.22 THE VALUE OF HIGH RESOLUTION MANOMETRY FOR REMEDIAL ANTIREFLUX SURGERY**

Jessica Leers, Hans Fuchs, Sebastian Brinkmann, Marc Bludau, Wolfgang Schröder, Elfriede Bollschweiler, Arnulf Hölischer, Christian Gutschow  
*Department Of General, Visceral And Tumorsurgery, University Of Cologne, Cologne/GERMANY*

**Background:** Failure after laparoscopic fundoplication is increasing due to the rising number of procedures and the longer follow-up. Remedial proce-

dures are technically challenging and show lower success rate and patient satisfaction. Thus, a tailored approach after detailed evaluation is necessary. The aim of this study was to evaluate the value of High Resolution Manometry (HRM) for operative decision.

**Methods:** We reviewed our prospectively maintained database to identify patients after laparoscopic Nissen fundoplication. Only patients who received HRM were included. A total of 10 patients with a mean age of 56 years were identified. All patients underwent complete diagnostic evaluation including symptoms, quality of life (GIQLI Score), upper endoscopy, 24h pH metry, high resolution manometry and fluoroscopy.

**Results:** All patients presented with symptoms after antireflux surgery. Reflux (80%) and dysphagia (50%) were the leading symptoms. Dual high pressure zone presenting separated plication and hiatus was identified in 8 patients and defective LES was found in 6 patients. Pathologic esophageal motility was found in 6 patients with partially non peristaltic and hypoton amplitudes.

**Discussion:** High Resolution Manometry is a valid and important diagnostic tool for operative decision making after antireflux surgery. We were able to use High Resolution Manometry for a tailored approach in remedial antireflux surgery.

**Disclosure:** All authors have declared no conflicts of interest.

**P06.23 LATE REINTERVENTIONS AFTER COLONIC INTERPOSITION FOR BENIGN DISEASES**

Silvia Mantoan<sup>1</sup>, Luca Faccio<sup>1</sup>, Gianpietro Zanchettin<sup>1</sup>, Michele Valmasoni<sup>1</sup>, Mario Costantini<sup>1</sup>, Tiziana Morbin<sup>1</sup>, Matteo Cagol<sup>2</sup>, Rita Alfieri<sup>2</sup>, Carlo Castoro<sup>2</sup>, Alberto Ruol<sup>1</sup>, Ermanno Ancona<sup>1</sup>  
<sup>1</sup>*University Of Padua, Department Of Surgical And Gastroenterological Sciences, Clinica Chirurgica 1, Padova/ITALY*, <sup>2</sup>*Surgical Oncology, Veneto Oncological Institute, Padova/ITALY*

**Background:** Colonic interposition (CI) is the first-choice reconstruction technique after esophagectomy in patients with various benign conditions. Aim of this study was to evaluate long-term outcomes of CI.

**Methods:** From 1989 to 2010, 62 consecutive patients with esophageal caustic stricture (n = 51) or other diseases (n = 11) underwent CI (M/F:23/39, median age 41 years, FU > 6 months). We analyzed patients who underwent surgical revision for outflow obstruction, more than 3 months after CI. The severity of symptoms and accurate functional and imaging studies established the necessity of reoperation.

**Results:** Late complications necessitating reintervention after CI occurred in 8 patients (13 %), all affected by severe dysphagia. Colonic kinking was present in 5 patients (surgical shortening was used in 4, adhesiolysis only in one); 2 patients had an endoscopically intractable stricture of the upper anastomosis requiring surgical revision; one patient with colonic compression at the thoracic inlet required partial clavicle resection. More than one reintervention was necessary in two patients. Median time between CI and reoperation was 36.1 months (3–128 months). Postoperative mortality was nil. Follow up showed a good quality of life also in patients who underwent redo surgery.

**Discussion:** CI is the first surgical choice for digestive tract reconstruction in patients with esophageal caustic injury or other benign diseases. CI regardless of its technical complexity, guarantees good long-term outcomes in 87% of cases. Late complications requiring one or more reoperations were observed in 13% of our patients, without worsening further long term outcomes.

**Disclosure:** All authors have declared no conflicts of interest.

**P06.24 THE SURGICAL TREATMENT AND THE OUT COME OF ACHALASIA IN SUDAN**

Seifeldin Mahdi, Mohamed Elmekki Ahmed  
*University Of Khartoum, Faculty Of Medicine, Dept. Of Surgery., Khartoum/SUDAN*

**Background:** Achalasia of the cardia is the third common cause of dysphagia in sudan. It accounts for 0.4–1.0% of all upper GI endoscopies done in the major hospitals in Khartoum. Among all the options, surgery remains the treatment with the best clinical response.

**Methods:** Twenty-four patients with achalasia of the cardia were treated in a single unit in Khartoum Teaching Hospital between May 2006 -Dec.2011. The patients were followed for a mean period of 22.9 months (range 4–67 month) to determine the clinical response to surgery.

**Results:** The mean age was 41(14.7 Sd) years. The male to female ratio was 13:11. The main presenting symptoms were dysphagia reported by all the patients, followed by heartburn in (54.2%), nocturnal regurgitation in (45.8%), and weight loss in (78.8%) of the patients. Eleven patients (45.8%) have had received previous treatment for achalasia without improvement or with recurrence of symptoms. Four patients needed nutritional support before surgery. The operation done were open myotomy+ fundoplication for 20 patients, myotomy alone for 3 patients and feeding jejunostomy for one patient who was considered too ill to undergo surgery. The satisfaction with

surgery was excellent or good in 20 patients (83.3%). Post operatively dysphagia persisted in 3 patients, but all responded to dilatation and/or drugs.

**Discussion:** In our settings in Sudan surgery for achalasia offers a good long term relief of the patient symptoms

**Disclosure:** All authors have declared no conflicts of interest.

#### P06.25 EFFECT OF MEBEVERINE ON LOWER OESOPHAGEAL SPHINCTER PRESSURE IN ACHALASIA

*Alessandra D'Alessandro, Francesco De Giorgi, Eleonora Efficie, Rosa D'Aniello, Marcella Pesce, Giovanni Sarnelli, Rosario Cuomo  
Univeristy Of Naples "Federico II", Naples/ITALY*

**Background:** Mebeverine is an antispasmodic drug used in the management of IBS. Mebeverine acts directly on the gut muscle cells by blocking intracellular sodium and calcium entrance in order to prevent cell's contraction. Recent in vitro evidence also suggests that mebeverine-induced muscle relaxation is induced by the release of neuronal nitric oxide. The aim of our study is to evaluate the effects of mebeverine on lower oesophageal sphincter (LOS) pressure in achalasia.

**Methods:** Ten naive-achalasia patients (4 males, age:  $60 \pm 18$  years) were studied. All subjects underwent a stationary manometry, with LOS resting and residual pressures being measured by a sleeve sensor. During the procedure LOS pressures were respectively recorded 15 min before and 15, 30 and 60 mins after intragastric infusion of 200 mg of saline-dissolved mebeverine.

**Results:** Compared to baseline, mebeverine significantly reduced LOS resting pressure ( $63 \pm 25$ ,  $55 \pm 22$ ,  $47 \pm 26$  and  $45 \pm 8$  mmHg;  $p < 0.01$  at 30 and 60 mins vs. basal). Conversely, mebeverine did not affect LOS residual pressure.

**Discussion:** In achalasia mebeverine significantly reduces LOS resting, but it did not affect LOS residual pressure. Further larger studies are needed to confirm our finding. However data suggest, that at least in humans, mebeverine mainly acts on the cholinergic pathway, rather than on the inhibitory, nitregeric part of the LOS tone.

**Disclosure:** All authors have declared no conflicts of interest.

#### P06.26 LONG-TERM COMPARISON BETWEEN PATIENTS SUBMITTED TO EMERGENCY SURGERY FOR ESOPHAGEAL PERFORATION AFTER DILATION FOR ACHALASIA AND PATIENTS SUBMITTED TO ELECTIVE SURGERY

*Lorena Rodríguez Gómez, Inmaculada Domínguez Serrano, Rocío Santos Ranaño, Pablo Talavera Eguizábal, Julio Pérez De La Serna, Elia Pérez-Aguirre, Andrés Sánchez-Permaute, Antonio José Torres García  
Hospital Clínico San Carlos, Madrid/SPAIN*

**Background:** Introduction. Treatment of esophageal perforation after pneumatic dilation for achalasia should include the treatment of the perforation plus the treatment of the achalasia. Aim. To analyze the clinical and functional results of patients submitted to emergency surgery for esophageal perforation and those electively operated for achalasia.

**Methods:** Fourteen patients were submitted to surgery for esophageal perforation from 1993 to 2011. The operation consisted on mediastinal drainage, suture of the perforation, esophageal myotomy and partial antireflux procedure, which was no different to the technique perforated electively.

**Results:** There was no postoperative mortality. No patient submitted to elective surgery needed a second operation, while 1 patient submitted to emergency surgery needed a second operation for intractable gastroesophageal reflux and another needed postoperative dilations due to severe peptic esophagitis and esophageal stricture. Dysphagia was more prevalent between non-perforated patients, 57 vs 28% ( $p = n.s.$ ). Chest burn was more frequent between perforated patients, 21,3% vs 7,1% ( $p = n.s.$ ). Regurgitation presented in a similar percentage in both series.

**Discussion:** Patients submitted to emergency surgery for perforated achalasia after pneumatic dilation tend to suffer more from gastroesophageal reflux in the long term, while patients submitted to elective surgery usually have a higher rate of dysphagia. A possible solution could be to perform a more complete antireflux procedure in perforated patients.

**Disclosure:** All authors have declared no conflicts of interest.

#### P06.27 PERFORMANCE OF JUICE TEST IN THE PREDICTION OF ACID EXPOSURE AT ESOPHAGEAL PH MONITORING

*Fernando Fornari, Michel Fernandes, Juliane Lima, Raquel Wolfart, Marina Oliveira  
Universidade De Passo Fundo, Passo Fundo/BRAZIL*

**Background:** It has been demonstrated that a prolonged pH drop in the distal esophagus after deglutition of orange juice, as measured by a parameter named delta5, can be useful to predict acid exposure in patients investigated with reflux testing. The purpose of our study was to estimate juice test performance in the prediction of esophageal acid exposure.

**Methods:** Eighty patients referred for esophageal pH monitoring underwent juice test. After placement of the pH sensor at 5 cm above the lower sphincter, patients were instructed to perform rapid multiple swallows of orange juice (pH 2.5). In the following day the pH catheter was removed and tracings analyzed. Delta5 in  $\text{mol.s.dm}^{-3}$  was calculated as the area under the curve between pH drop from 5 to pH recovery to 5 after juice deglutition. Data from 10 patients with atypical symptoms and normal acid exposure ( $< 4.3\%$ ) were used to calculate a reference value for Delta5 (90<sup>th</sup> percentile).

**Results:** The cut cutoff of the Delta5 was 33. Among 70 patients, there were 45 with increased acid exposure and 25 patients with normal acid exposure. A positive juice test (Delta5  $\geq 33$ ) showed sensitivity of 42% (95%CI 29–56%), specificity of 76% (57–89%), and positive predictive value of 64% (45–79%) for abnormal acid exposure. Test accuracy was 59%.

**Discussion:** Our results indicate that the juice test had high specificity and good positive predictive value for increased acid exposure. This simple and safe procedure might be useful for identification of non-diseased subjects investigated for GERD, potentially increasing the reflux testing performance.

**Disclosure:** All authors have declared no conflicts of interest.

#### P06.28 OUTCOMES FOLLOWING PER-ORAL ENDOSCOPIC MYOTOMY (POEM) FOR NON-ACHALASIA NEUROMUSCULAR DISORDERS OF THE ESOPHAGUS.

*Ashwin Kurjan<sup>1</sup>, Christy Dunst<sup>2</sup>, Ahmed Sharata<sup>2</sup>, Neil Bhayani<sup>1</sup>, Kevin Reavis<sup>2</sup>, Lee Swanstrom<sup>2</sup>*

*<sup>1</sup>Providence Portland Medical Center, Portland/OR/UNITED STATES OF AMERICA, <sup>2</sup>The Oregon Clinic, Portland/UNITED STATES OF AMERICA*

**Background:** Per-Oral Endoscopic Myotomy (POEM) has recently been described as an alternative to conventional myotomy for neuromuscular disorders of the esophagus. While outcomes in achalasia are good, there is a paucity of literature for Non-Achalasia Neuromuscular Disorders (NAND). Long myotomies historically have unpredictable and generally poor outcomes. We present our outcomes in this group of patients using this novel endoluminal approach.

**Methods:** Patients undergoing POEM for NAND between 11/2011 and 10/2012 were included. Pre/postoperative symptom scores and manometry data were collected.

**Results:** Seven patients underwent POEM for NAND. Five of seven had improvement in symptoms over median follow-up of 2 months (1 to 15 months). Three patients diagnosed with nonrelaxing lower esophageal sphincters (LES) had complete resolution of dysphagia and chest pain (2 and 15 months). Two of these also had nutcracker esophagus. Four patients diagnosed with diffuse esophageal spasm (DES) reported no change in either their dysphagia or chest pain (follow-up 1 to 2 months). One DES patient reported slight improvement in the frequency of the chest pain and dysphagia (followup 2 months). One other DES patient reported only rare dysphagia and chest pain (followup 13 months), albeit she underwent two postoperative endoscopic dilations for chest pain and dysphagia.

**Discussion:** POEM appears to be an effective treatment for Non-Achalasia Neuromuscular Disorders of the distal esophagus (hypertensive LES and nutcracker). POEM for NAND primarily of the esophageal body (Diffuse Esophageal Spasm) does not have similar postoperative outcomes.

**Disclosure:** All authors have declared no conflicts of interest.

#### P06.29 CLINICAL OUTCOMES AND PATIENT SATISFACTION OF ESOPHAGECTOMY FOR END-STAGE ACHALASIA

*Alex Wilkes, Sumeet Mittal, Kalyana Nandipati, Masato Hoshino, Tommy Lee*

*Creighton University Medical Center, Dept Of Surgery, Omaha/NE/ UNITED STATES OF AMERICA*

**Background:** End-stage achalasia is a challenging problem where one must contend with not only a dysfunctional lower esophageal sphincter (LES), but also a tortuous, dilated esophageal body that limits effectiveness of LES-directed therapy. Although patients may complain of achalasia-like symptoms of dysphagia and regurgitation after esophagectomy, it is an important option to consider.

**Methods:** 18 patients underwent esophagectomy for end-stage achalasia between 2003 and 2011. Of these, 12 patients responded to a survey consisting of the Eckardt Achalasia Score and other questions related to gastrointestinal quality of life.

**Results:** Follow-up ranged from 7 to 96 months. 75% of patients reported occasional or no dysphagia and 67% reported occasional or no regurgitation. 75% reported no dietary restrictions. 75% of our patients reported satisfaction with the procedure and 83% reported a willingness to have the procedure done in retrospect. A higher Eckardt Score did not correlate with either of these, indicating high satisfaction even in those with residual symptoms.

**Discussion:** Esophagectomy is an effective treatment for end-stage achalasia for the majority of patients with a high satisfaction rate. Even patients with residual symptoms were happy with their outcomes, suggesting esophagectomy provides acceptable symptom trade-off in this population of patients.

**Disclosure:** All authors have declared no conflicts of interest.

#### P06.30 CASE REPORT – CRICOPHARYNGEAL ACHALASIA PRESENTED WITH GASTROLARYNGOESOPHAGEAL REFLUX SYMPTOM

Sutthiphol Ariyasathitman<sup>1</sup>, Paraya Assanasen<sup>2</sup>, Monthanee Puengphong<sup>3</sup>  
<sup>1</sup>Voice and Swallowing Clinic, Department of Otolaryngology Head and Neck Surgery, Faculty of Medicine Navamindradhiraj University, Vajira Hospital, Bangkok/THAILAND, <sup>2</sup>Department of Otolaryngology Head and Neck Surgery, Faculty of Medicine Siriraj Hospital, Mahidol University, Bangkok/THAILAND, <sup>3</sup>Department of Radiology, Faculty of Medicine Navamindradhiraj University, Vajira hospital, Bangkok/THAILAND

**Background:** Cricopharyngeal achalasia is the rare etiology of dysphagia. The failure of relaxation of cricopharyngeus muscle is the main cause of swallowing problem. Clinical manifestations of this disease include globus pharyngitis, gastrolaryngoesophageal reflux or upper airway obstruction in child. Esophagogram is a non-invasive investigation with specific radiological findings which include posterior shelf-like semi-circular filling defect caused by hypertrophy of the cricopharyngeus muscle, barium filling at vallecular, distension of hypopharynx, and prominence of posterior wall of pharyngeal membrane at the level of C-6.

**Methods:** We report the 50-year-old female who presented with food sticking at midline of lower part of neck. Physical examination showed edema and injection of bilateral true vocal cord and posterior arytenoids. Life-style modification and double dose of proton pump inhibitor (PPI) were applied in this patient. Two months later, his reflux finding score was improved but globus sensation and food sticking were not better. Esophagogram was then performed to rule out pathology of esophagus.

**Results:** Barium swallowing showed prominence of cricopharyngeus muscle with normal postcricoid region. Cricopharyngeal achalasia was then diagnosed. Complication of cricopharyngeal achalasia is increased pressure at upper esophagus which can lead to pharyngo-esophageal diverticulum. Appropriate treatment should then be performed. Botulinum toxin injection at cricopharyngeus muscle is commonly used for treatment of cricopharyngeal achalasia since it is simple, non invasive and less time consuming procedure but recurrence rate is still high. Cricopharyngeus myotomy is the treatment of choice for cricopharyngeal achalasia although it is more invasive and gastrolaryngoesophageal reflux can occur.

**Discussion:** Cricopharyngeal achalasia could present with globus pharyngitis or sensation and gastrolaryngoesophageal reflux which failed to life-style modification and double dose of PPI. Esophagogram is non invasive and beneficial investigation for diagnosis of cricopharyngeal achalasia.

---

#### POSTER SESSION P07: HIATAL HERNIA – October 17, 2012 12:30–13:30

---

##### P07.01 GANGRENE OF THE ESOPHAGOGASTRIC JUNCTION CAUSED BY STRANGULATED HIATAL HERNIA – OPERATIVE CHALLENGE OR SURGICAL DEAD END?

Michael Schweigert<sup>1</sup>, Attila Dubez<sup>1</sup>, Lukas Thumfart<sup>1</sup>, Dietmar Oefner-Velano<sup>2</sup>, Hubert J Stein<sup>1</sup>

<sup>1</sup>Department Of General And Thoracic Surgery, Klinikum Nuernberg Nord, Nürnberg/GERMANY, <sup>2</sup>Department Of Surgery, Paracelsus Medical University Salzburg, Salzburg/AUSTRIA

**Background:** Gangrene of the esophagogastric junction due to incarcerated hiatal hernia is an extremely uncommon emergency situation. Gastric strangulation takes place resulting in infarction and necrosis of the cardia. Early symptoms are mainly unspecific and so diagnosis is often considerable delayed. Aim of the study is to share experience in dealing with this devastating condition.

**Methods:** We encountered three male patients with gangrene of the esophagogastric-junction caused by strangulated hiatal hernia within the last two years. Clinical symptoms, surgical procedures and outcome were retrospectively analyzed.

**Results:** Early symptoms were massive vomiting accompanied by retrosternal and epigastric pain. Hiatal hernia was already known in all patients. Nevertheless clinical presentation was initially misdiagnosed as cardiovascular disorders. Upon emergency laparotomy gangrene of the esophagogastric junction was obvious while in one case even necrosis of the whole stomach occurred after considerable delayed diagnosis. Transmediastinal esophagectomy with resection of the proximal stomach and gastric pull-up with cervical anastomosis was performed in two cases. Esophagogastric-

ectomy with delayed reconstruction by retrosternal colonic interposition was mandatory in the case of complete gastric gangrene. Finally all sufferers recuperated well.

**Discussion:** Strangulation of hiatal hernia with subsequent gangrene of the esophagogastric junction is a life-threatening condition. Straight diagnosis is mandatory to avoid further necrosis of the proximal gastrointestinal tract as well as severe septic disease. Transmediastinal esophagectomy with interposition of a gastric tube and cervical anastomosis should be the procedure of choice if the distal stomach is still viable. Otherwise esophagogastric resection is unavoidable. Delayed cervical anastomosis or reconstruction is advisable in instable, septic patients.

**Disclosure:** All authors have declared no conflicts of interest.

##### P07.02 SAFE USE OF POLYPROPYLENE MESH IN THE HIATUS. TECHNIQUE AND RESULTS AFTER LONG TERM FOLLOW-UP

Andre Brandalise, Nilton Aranha, Nelson Brandalise, Claudia Lorenzetti  
Fundacao Centro Medico Campinas, Campinas/BRAZIL

**Background:** The recurrence rate after laparoscopic surgery for large paraesophageal hernias is high. The use of a mesh in the hiatus is proposed by many authors, but it is still a controversial issue. The main concern is the potential risk of erosion or stricture

**Methods:** We present a series of 70 patients with large paraesophageal hernias in whom a polypropylene mesh was used to reinforce the hiatal suture.

There were 47 primary type II-IV paraesophageal hernias and 23 recurrent paraesophageal hernias. After the cruroplasty, the mesh is cut in an “U” shape and, in the curved area, a silastic catheter is sewn to avoid contact of the esophagus with the polypropylene edge. After the mesh is secured in place with staples, we perform the fundoplication and at the end of the procedure the mesh is covered with omentum, avoiding contact of the gastric fundus and fundoplication with the mesh.

**Results:** We analyzed 48 patients with follow-up greater than 6 months.

The mean follow up period is 60 months (6 to 140 months).

Forty (83%) patients have complete resolution of their symptoms, 5 have GERD symptoms and 3 have some degree of dysphagia.

No signs of recurrence in RX and/or endoscopy was found in 44 (91,6%) patients. The 4 recurrences of hernias are small, and all of them were reoperations.

We found no complications related to the mesh (erosion or stricture)

**Discussion:** We conclude that with the proper technique, polypropylene mesh is safe and effective to prevent recurrence in large hiatal hernias.

**Disclosure:** All authors have declared no conflicts of interest.

##### P07.03 SIMULTANEOUS ENDOVIDEOSURGICAL TREATMENT HIATAL HERNIA AND GASTROESOPHAGEAL REFLUX DISEASE

Oleg Galimov, Anton Shkunding

Bashkortostan State Medical University, Ufa/RUSSIAN FEDERATION

**Background:** The aim of the study was to examine the results of one-stage correction endovideosurgical hiatal hernia and gastroesophageal reflux disease, which leads to the restoration of normal anatomy by repositioning and retention of the cardia below the diaphragm, as well as the creation of antireflux barrier, which is ensured by the constant acute cardiofundal angle.

**Methods:** Simultaneous endovideosurgical treatment for hiatal hernia and gastroesophageal reflux disease successfully performed in 163 patients.

Significantly improve the diagnostic results of hiatus hernia allows our proposed method endoscopic balloon traction, which allows us to establish the true size of esophageal opening.

We propose a new method of surgical treatment, technical in effect which is based on the prevention of complications associated with abnormal narrowing of the esophageal opening, as well as sliding sleeves, and thus the deterioration of the properties of antireflux cardia. In addition, the advantage of the method is the relative ease of technology implementation and the possibility of widespread use in surgical hospitals.

**Results:** In 149 (91.4%) patients in the immediate postoperative period have disappeared all of the major manifestations of the disease and they are discharged from the recovery for 4–8 days after surgery. Early postoperative complications were diagnosed in 14 patients with the most common early postoperative complication was transient dysphagia.

**Discussion:** The use of a new method in patients led to a reduction in the duration of postoperative hospital stay, as well as marked early activation of patients and the rapid recovery of the motor-evacuation function of the gastrointestinal tract.

**Disclosure:** All authors have declared no conflicts of interest.



**P07.04 ROBOTIC GIANT PARAESOPHAGEAL HERNIA REPAIR**

Mario Gasparri, Ghulam Murtaza, William Tisol, George Haasler  
*Medical College Of Wisconsin, Milwaukee/WI/UNITED STATES OF AMERICA*

**Background:** Laparoscopy is the standard for treatment of giant paraesophageal hernias (GPEH). Advanced skills are required to completely dissect the hernia sac and repair the hiatus. A robotic approach may provide better visualization and dexterity while achieving a durable repair. We report our experience with robotic GPEH repair.

**Methods:** We reviewed all patients undergoing robotic GPEH repair since 2008. We defined GPEH as the sac extending cephalad to the inferior pulmonary vein. All patients underwent barium swallow on postoperative day one and have been followed in clinic following discharge.

**Results:** Since March 2008, 20 patients underwent robotic repair of GPEH. Mean age was 68 ± 11 (43–84) and mean BMI 29.1 ± 5.4 kg/m<sup>2</sup> (16–40). Mean operative time was 205 ± 58 minutes (141–349). Fundoplication was performed in 11/20 patients. No intraoperative complications were observed and there were no conversions to laparotomy. Postoperative imaging confirmed successful repair in all patients. Mean length of stay was 3.0 ± 1.3 days (2–7). Postoperatively, there were two complications; one prolonged nausea and one atrial fibrillation which resulted in prolonged stays of 7 and 5 days respectively. At short to mid-term follow-up ranging from 2 to 47 months (average 22), all repairs are intact and all patients free of symptoms.

**Discussion:** Robotic GPEH repair is safe and feasible. Subjectively, surgeons reported excellent visualization and dexterity with greater ability to dissect proximally into the mediastinum. Objectively, these results show acceptable operative times, short hospital stays and low complication rates with good short to mid-term durability. Further follow-up is required to assess long-term durability and freedom from symptoms.

**Disclosure:** All authors have declared no conflicts of interest.

**P07.05 LAPAROSCOPIC MESH REPAIR OF PARAHIATAL HERNIA**

Andrew Wong  
*Changi General Hospital, Singapore/SINGAPORE*

**Background:** Parahiatal hernia is a rare condition defined by the presence of a muscular defect in the diaphragm adjacent to an intact oesophageal hiatus. Most parahiatal hernias previously reported in the literature were repaired primarily, with several further reinforced by mesh. We report a case of a parahiatal hernia repaired laparoscopically using a composite mesh.

**Methods:** A middle-aged woman presented with vomiting and epigastric pain. Computed tomography scan showed a giant paraesophageal hernia with intrathoracic gastric volvulus. At the time of surgery, the muscular defect was found to be lateral to an attenuated left crus of the diaphragm with a normal oesophageal hiatus. The defect was ringed by chronic fibrous tissue and could not be apposed for a tension-free primary repair. A laparoscopic mesh repair was performed using a composite mesh which was further covered with the hernia sac to prevent potential erosion into oesophagus or stomach. An anterior partial fundoplication was added to fix the stomach below the hiatus.

**Results:** The patient was started on liquids and ambulating on the first post-operative day. She progressed gradually to diet and was discharged on the fifth post-operative day. At subsequent follow-up in the outpatient clinic, she remained symptom free. There was no recurrence on routine contrast study at 6-months post-operative.

**Discussion:** Laparoscopic repair of parahiatal hernia can be safely performed by laparoscopic surgeons familiar with the repair of paraesophageal hernia. In circumstances where large defect size or fibrosis prevents tension-free primary repair, the use of a composite mesh can provide effective repair of the hernia.

**Disclosure:** All authors have declared no conflicts of interest.

**P07.06 SURGICAL REPAIR OF A GIANT PARAESOPHAGEAL HERNIA RESOLVES ANEMIA IN THE MAJORITY OF CASES**

Michael Hermansson<sup>1</sup>, Steven R Demeester<sup>1</sup>, Joerg Zehetner<sup>1</sup>, Kimberly S Grant<sup>1</sup>, Daniel S Oh<sup>1</sup>, Jeffrey A Hagen<sup>2</sup>  
<sup>1</sup>Dept Of Surgery University Of Southern California, Keck Medical Center Of USC, Los Angeles/CA/UNITED STATES OF AMERICA, <sup>2</sup>University Of Southern California, Keck Medical Center Of USC, Los Angeles/CA/UNITED STATES OF AMERICA

**Background:** The association between anemia and paraesophageal hernia (PEH) is well known. Nonetheless, extensive evaluation for an alternative source of bleeding in patients with PEH is common. The aim of this study was to evaluate the impact of surgical repair on anemia in patients with PEH.

**Methods:** A retrospective chart review was performed of all patients who underwent primary repair of a large PEH between 1998–2010. Patients with incomplete records were excluded. Patients with a history of anemia were contacted and the status of their anemia was determined.

**Results:** A history of anemia was present in 47/161 patients (29%). Detailed postoperative follow-up was available in 34 patients with anemia and they formed the study group. Median age was 64 years. There were 12 males and 22 females. The median duration of anemia prior to PEH repair was 4 years. Patient evaluation and treatment are shown in the table. Cameron ulcers were identified on preoperative upper endoscopy in 5 patients. None of the other studies identified a potential source of bleeding. At a median follow-up of 59 months resolution of anemia had occurred in 29 patients (85%). No patient has required a blood transfusion for anemia after PEH repair.

<b>Preoperative tests for anemia</b> (2.3 tests /patient)	<i>EGD</i>	49
	<i>Colonoscopy</i>	20
	<i>Capsule enteroscopy</i>	6
	<i>Push enteroscopy</i>	1
	<i>Tagged red blood scan</i>	2
	<i>Small bowel follow through</i>	1
<b>Type of fundoplication</b>	<i>Nissen</i>	23 (68%)
	<i>Partial</i>	11 (32%)

**Discussion:** Anemia is common in patients with a giant PEH, and surgical PEH repair resolved the anemia in 85% of patients. Extensive evaluation for an alternative explanation of the anemia in patients with a giant PEH should not be performed unless the anemia persists after PEH repair.

**Disclosure:** All authors have declared no conflicts of interest.

**P07.07 LAPAROSCOPIC SLEEVE GASTRECTOMY AND HIATAL HERNIA REPAIR FOR THE MANAGEMENT OF MORBID OBESITY COMPLICATED BY HIATAL HERNIA WITH OR WITHOUT GASTROESOPHAGEAL REFLUX DISEASE**

Emanuele Soricelli, Angelo Iossa, Francesca Abbatini, Giovanni Casella, Benedetto Cali, Carmelisa Dammario, Nicola Basso  
*Surgical Medical Department For Digestive Diseases, "Umberto I" University Hospital, Rome/ITALY*

**Background:** Gastroesophageal reflux disease (GERD) with or without hiatal hernia (HH) is now recognized as an obesity related comorbidity, involving up to 70% of patients undergoing bariatric surgery. At present Roux-en-Y gastric Bypass (RYGB) is recommended as the most effective bariatric procedure when GERD symptoms and/or HH are present. To the contrary the indication to laparoscopic Sleeve gastrectomy(LSG) associated with hiatal hernia repair (HHR) in these patients is still debated. Aim of this paper is to report our experience of 95 patients submitted to LSG and HHR in our department.

**Methods:** From July 2009 to December 2011 378 LSG have been performed in our department. Ninety-five patients with a mean body mass index (BMI) of 43.9 ± 2.3 kg/m<sup>2</sup> underwent LSG with HHR. Clinical outcomes have been evaluated in terms of GERD symptoms resolution or improvement, interruption of antireflux medications, and X-ray evidence of HH recurrence.

**Results:** Forty patients (42.1%) were symptomatic for GERD before surgery. Intra-operative diagnosis of HH occurred in 55 cases (57.9%) of the overall crural defects undergoing repair, with an incidence up to 72% in the last 66 cases performed from January 2011 to December 2011. After a mean follow-up of 12 months mean BMI was 33.2 ± 6.5 kg/m<sup>2</sup>. GERD remission occurred in 33 patients (82.5%). In the other 7 patients (17.5%) PPI medications were continued at diminished doses (15 mg/die vs 40 mg/die) with complete control of symptoms in 5 patients. No HH recurrences nor complications related to HHR occurred.

**Discussion:** HHR associated to LSG has been shown to be an effective option for the management of morbidly obese patients with GERD and/or HH, with no cases of "de novo" post-operative GERD development. An extensive dissection of the hiatal crura is always recommended in order to ascertain more precisely the presence of HH. The reduction of the lower part of the esophagus into the abdomen along with HHR seems to be of importance for the resolution or improvement of reflux symptoms.

**Disclosure:** All authors have declared no conflicts of interest.

**P07.08 SLIDING HIATAL HERNIA IN THE ELDERLY**

Roberto Scilletta, Beniamino Scilletta, Stefano Puleo  
*Azienda Ospedaliera Vittorio Emanuele – Policlinico Catania, Catania/ITALY*

**Background:** Aim of this study was to evaluate the results of laparoscopic surgery in elderly patients over 65 years, with Sliding Hiatal Hernia (SHH) with typical and atypical respiratory symptoms, who have been followed up for 5 years.

**Methods:** 235 patients have been operated from 2003 to 2010. We conducted a study on 30 patients over 65 years belonging to that group.

Patients characteristics:

- Mean age 69 years, 22 females and 8 males
- Typical and atypical symptoms in 18, in 12 typical
- Reflux esophagitis grade II in 14, III in 6, NERD in 10
- Radiography: SHH in 29 patients, in 1 case 2 / 3 of the stomach in the chest.
- Preoperative value:
  - LES pressure: 5.4 mmHg (range 3.8 to 8.1), LES length: 1 cm
  - pHmetry median: 66.1

Surgery: Nissen Rossetti (NR) 360 ° fundoplicatio in 24; in 5 Toupet fundoplicatio 270°. Section of short gastric vessels (SGV) in 16, and no section in 14.

**Results:** Postoperative transient dysphagia in 2 patients without section of SGV and in 1 with section. No permanent dysphagia. Resolution of symptoms in the 87% of 19 patients.

Mean postoperative LES pressure: 5 mmHg; LES length: 3–4 cm; De Meester score: 8.4.

Resolution of esophagitis in 4, with no typical and atypical symptoms.

SHH recurrence in 2 patients at 3 years, recurrence of typical and atypical symptoms in 4, in 3 of these there were no section of the SGV.

**Discussion:** Surgery is, indeed, safe and effective and age does not represent a contraindication.

**Disclosure:** All authors have declared no conflicts of interest.

#### P07.09 THE USE OF PROSTHESIC MESH IN THE SURGICAL REPAIR OF GIANT PARAESOPHAGEAL HERNIAS

Lisa Zanatta<sup>1</sup>, Mario Costantini<sup>1</sup>, Renato Salvador<sup>1</sup>, Tiziana Morbin<sup>1</sup>, Nicola Passuello<sup>1</sup>, Gloria Dogá, Giulia Pozza<sup>1</sup>, Giovanni Zaninotto<sup>2</sup>, Ermanno Ancona<sup>1</sup>

<sup>1</sup>University Of Padua, Department Of Surgical And Gastroenterological Sciences, Clinica Chirurgica 1, Padua/ITALY, <sup>2</sup>Department Of General Surgery, Ss Giovanni E Paolo Hospital, Ulss 12, Venezia/ITALY

**Background:** Surgical repair for large paraesophageal hiatal hernia by primary suture is associated with a high recurrence rate. Therefore, the application of prosthetic meshes has been suggested and used by most surgeons.

**Methods:** Patients undergoing laparoscopic correction of large hiatal hernia were prospectively evaluated. Two different meshes (circular, double-face, PTFE/Polypropilene, 43 Patients, and semicircular PTFE/ePTFE, 39 patients) were used in subsequent periods.

**Results:** From 1997, 82 patients underwent the operation (22 male); the median age was 67 years (40–85). 58 patients had a type II-III hernia, with >1/3 of the stomach herniated; 24 had an upside-down stomach. Mortality was 1.2% (1 case). The median follow-up was 66 months (1–162). The overall success rate was 81.5%: we observed 2 early recurrences and dysphagia for misplaced mesh, which required reoperation. In 7 patients we had to perform dilatations for dysphagia, that in 2 cases resulted in esophageal or gastric penetration of the mesh (both in the circular mesh group). Six patients had a symptomatic (and radiological) recurrence (re-operation was eventually performed in 2: 1 laparoscopic new hernia reduction, 1 transthoracic Collis-Nissen).

**Discussion:** Laparoscopic repair of large paraesophageal hiatal hernia with reinforcement mesh is feasible and provides an acceptable recurrence rate. Some mesh-related severe complications may occur, especially related to the shape and the nature of the mesh. In our experience the use of the semicircular PTFE/ePTFE mesh seems to be safer and associated with a lower incidence of complications, but the shorter follow-up in these patients must be taken into account when considering these results.

**Disclosure:** All authors have declared no conflicts of interest.

#### P07.10 1998–2011: OUTCOME, COMPLICATIONS AND REDO SURGERY IN 830 PATIENTS UNDERWENT LAPAROSCOPIC ANTIREFLUX SURGERY AT A REFERRAL CENTER

Simone D'Imporzano, Giovanni Pallabazzer, Biagio Solito, Domenico Viggiano, Stefano Santi  
Azienda Ospedaliero Universitaria Pisana, Pisa/ITALY

**Background:** Nowadays laparoscopic antireflux surgery is a valid treatment option in severe forms and in young GERD patients.

**Methods:** From 1998 to 2011, 830 patients underwent a primary laparoscopic fundoplication for GERD at Referral Center for Diagnosis and Treatment for Esophageal Disease, AOUP, Pisa, Italy.

**Results:** Fundoplication types constructed: Nissen 600, Toupet 230. Perioperative complications: pneumothorax 8 (0.9%), gastric perforation 6 (0.7%), hemorrhage 4 (0.5%), arrhythmia 5 (0.6), thrombophlebitis 5 (0.6%), pneu-

monia 2 (0.2%), 0 deaths. 5 p.(0.5%) required a redo for acute intrathoracic migration. P. were evaluated at 4 weeks, 6–12 months after surgery; thereafter, they were evaluated annually performing a barium swallow. Clinical follow-up was 87 months (6–120 months), success rate was 92%. Still on PPI therapy were 8%. 71 patients (8.6%) had lasting dysphagia (>12 weeks), 13 patients with dysphagia underwent redo(Toupet). 43 patients (5.2%) had recurrence GERD, 16/43 (37.2%) underwent redo.21 patients (2.5%) had gas bloat syndrome, 1 redo fundoplication.Causes of failure: intrathoracic wrap migration (15 p.), telescoping (1 p) and tight funduplications (14 p.). All redo operations were performed laparoscopically. Only 3 open (10%) due to esophageal (1 patient) and gastric (2 patients) perforation. The success rate of the redo surgery was 84%.

**Discussion:** Antireflux surgery for refractory GERD is safe, feasible and has satisfactory outcome in 92% of p.Redo surgery was performed in 30/830 (3.6%), 13 for dysphagia, 16 GERD and 1 gas bloat syndrome. High volume center improve patients outcome especially as the cases become more complex with the possible need for revisional surgery.

**Disclosure:** All authors have declared no conflicts of interest.

#### P07.11 ANTI-REFLUX SURGERY AFTER CONGENITAL DIAPHRAGMATIC HERNIA REPAIR

Tom Verbelen, Toni Lerut, Willy Coosemans, Paul De Leyn, Philippe Naftex, Dirk Van Raemdonck, Hans Van Veer, Herbert Decaluwé  
Department Of Thoracic Surgery University Hospitals Leuven, Leuven/ BELGIUM

**Background:** Preventive anti-reflux surgery (ARS) at the moment of congenital diaphragmatic hernia (CDH) repair has been suggested by some authors, especially in subgroups with a herniated liver or patch requirement. We evaluated the incidence and associated factors of gastro-esophageal reflux disease (GERD) and the need for subsequent ARS in our CDH patients.

**Methods:** We retrospectively reviewed our CDH database. Demographics, prenatal treatment, type of repair, intra-operative findings and incidences of GERD and ARS were recorded.

**Results:** Between July 1993 and November 2009, CDH repair was performed in 77 infants. Eight died. Seven were lost to follow-up. 22 out of 62 patients were prenatally treated with fetoscopic endoluminal tracheal occlusion (FETO). GERD was diagnosed in 31 patients. One year after starting GERD treatment, 42% of them were still taking medication. Univariate analysis of associated factors shows that among others, patch repair, herniated liver, but also FETO are associated with ARS. Liver herniation is the only independent predictor for GERD and ARS. In CDH subgroups with patch repair, a herniated liver or previous FETO, the incidences of GERD and anti-reflux surgery are 61% and 32%, 73% and 38%, and 71% and 43%, respectively.

**Discussion:** Of our CDH patients, 50 % develops GERD and 21% needs ARS. Routine ARS at the time of CDH repair seems not justified despite raised incidences of GERD and ARS in certain subgroups. FETO creates a new cohort of survivors with a higher risk for undergoing ARS. The surgical group in particular reflects the complex physiopathology in these patients.

**Disclosure:** All authors have declared no conflicts of interest.

#### P07.12 ONE HUNDRED PERCENT FOLLOW UP OF A CASE SERIES OF PATIENTS OPERATED UPON FOR TYPE II-IV HIATUS HERNIA (II-IV HH) IN THE ARCH OF 30 YEARS

Beatrice Aramini, Marialuisa Lugaesi, Alberto Ruffato, Ottorino Perrone, Sandro Mattioli  
Division Of Thoracic Surgery, Gvm Care & Research, Maria Cecilia Hospital, Cotignola (Ravenna), Center For The Study And Therapy Of Diseases Of The Esophagus. Alma Mater Studiorum - University Of Bologna, Italy, Bologna/ITALY

**Background:** Medical and surgical literature often points out the risk of bias in interpreting results of GERD-HH surgery because of the frequent incompleteness and relatively short time of post operative follow up. Because of the peculiarity of the Italian NHS and society (low % of migration), we have the opportunity to report on a case series totally followed up according to a protocol for an unusually long time.

**Methods:** 66 patients (median age 67.5 years) (41 women, 25 men) with II-IV HH underwent surgery from 1980 to 1994 with the “open” surgical approach and 34 (median age 69 years) (26 women, 8 men) in the period 1995–2010 with minimally invasive techniques. Patients at given time underwent interview, barium swallow and endoscopy. Results were considered poor in case of relapse of symptoms, endoscopic esophagitis any grade, hiatus hernia, post operative antireflux medical therapy. Follow up time was calculated from surgery to the last complete follow up.

**Results:** The cumulative post-operative mortality was 3/100, 97 patients were followed up for a median period of 96 months (IQR 25.5–201) : 12 months,

11 patients; 13–36 months, 8 patients; 37–60 months, 17 patients; 61–120 months, 22 patients; 121–216 months, 22 patients; and 217–440 months, 17 patients. Hiatal hernia (HH) relapse occurred in 6/97 (6.2%). Satisfactory results were obtained in 92.8%, excellent in 39.2%, good in 43.2%, fair in 10.4%, and poor in 7.2% (6 HH relapse, 1 esophagitis without HH relapse).

**Discussion:** Surgery for type II-IV hiatal hernia may be objectively satisfactory after years decades.

**Disclosure:** All authors have declared no conflicts of interest.

#### P07.13 SURGICAL REPAIR OF TYPE II-IV HIATAL HERNIA: FREQUENCY OF TRUE SHORT ESOPHAGUS AND RESULTS

Marialuisa Lugaresi, Beatrice Aramini, Alberto Ruffato, Sandro Mattioli, Ottorino Perrone

*Division Of Thoracic Surgery, Gvm Care & Research, Maria Cecilia Hospital, Cotignola (Ravenna), Center For The Study And Therapy Of Diseases Of The Esophagus. Alma Mater Studiorum – University Of Bologna, Italy, Bologna/ITALY*

**Background:** The surgical management of type II-IV hiatal hernia is controversial. Failure to recognize the condition of short esophagus may concur to the high rate of hernia's recurrence. We measured intraoperatively the distance between the gastro-esophageal junction (GEJ) and the hiatus (length of the abdominal esophagus) in patients undergoing surgery for type II-IV hiatus hernias.

**Methods:** 34 patients underwent minimally invasive surgery. After isolation of the GEJ and resection of the sac, the position of the gastric folds was localized endoscopically and two clips were applied. The distance between the clips and the diaphragm (abdominal esophagus) was measured with a dedicated ruler after mediastinal dissection. In case of abdominal esophagus <1.5 cm a Collis-Nissen was performed.

**Results:** 17 (50%) floppy Nissen and 17 (50%) thoracoscopic Collis-laparotomic Nissen were performed. In the latter group, (all type III-IV hernia), after mediastinal mobilization the length of the abdominal esophagus was  $\leq 1.5$  cm. Post-operative mortality was 5.8% and morbidity 17.6%. Global results (median follow up 48 months) were excellent in 43.8%, good in 50%, fair in 3.1%, and poor in 3.1%. Hiatal hernia relapse occurred in 3.1% of patients.

**Discussion:** True short esophagus is present in 50% of type III-IV and in none of type II hiatus hernia. The intraoperative measurement of the length of the abdominal esophagus is an objective method for recognizing these patients.

**Disclosure:** All authors have declared no conflicts of interest.

#### P07.14 HIATAL HERNIA REINFORCEMENT WITH A DUAL-MESH.

Inmaculada Domínguez Serrano, Elia Pérez-Aguirre, Lorena Rodríguez Gómez, Norman Cervantes Juárez, Esteban Martín Antona, Alejandra García Botella, Andrés Sánchez-Pernate, Antonio José Torres García  
*Hospital Clínico San Carlos, Madrid/SPAIN*

**Background:** Treatment of antireflux failure of primary or recurrent hiatal hernia is usually followed by a high recurrence rate. Aim: To analyse our experience with the use of a circular dual-mesh for hiatal reinforcement.

**Methods:** 57 patients were included, 40 submitted to a primary operation and 17 to a revisional surgery. In the first case, indication was a huge hiatal defect (8 cm or more than 3 stitches needed for closure); for revisional cases, indication was partial or total migration to the thorax or paraesophageal hernia.

**Results:** Median Follow-up was 24 months (3–60). All operations but one were performed laparoscopically with two conversions. Postoperative complication rate was 17%, principally pleural effusions and urinary infections. One patient died due to a fundic perforation. At one year from surgery 67% of the patients were asymptomatic; 19 referred dysphagia, which was moderate in 2 cases (3.4%). Dysphagia was not related to the type of fundoplication performed. One mesh inclusion has been detected in one asymptomatic patient. Four hernia recurrences have been detected between patients submitted to a primary surgery (10%) and in 3 cases submitted to a revisional operation (18%). There was no association between hernia recurrence and the type of primary hernia or the type of fundoplication performed.

**Discussion:** Mesh reinforcement of the hiatus with a “dual-mesh” is a useful technique for the treatment of primary hiatal hernia or hernia recurrence after a previous fundoplication

**Disclosure:** All authors have declared no conflicts of interest.

#### P07.15 REPAIR OF LARGE HIATAL HERNIAS BY MESH IMPLANTATION

Andras Balint

*St. Emeric Hospital Dept. Of Surgery, Budapest/HUNGARY*

**Background:** The recurrence of hiatal hernias following surgery unacceptable high (up to 42%). This is the reason why surgeons should find more effective solution to this problem.

**Methods:** At our Department in case of large hiatal hernia ( $d > 6$  cm) or rigid, stiff cruras we apply laparoscopic mesh implantation. The final step of the procedure is the creation of a floppy fundic wrap. We report the data of 33 patients, 10 men and 23 women, median age 64 y.

**Results:** Following surgery we experienced symptomatic improvement. However specific mesh related complications can occur infrequently. In one case 6 months after surgery fever and dysphagia developed caused by an abscess drained spontaneously into the esophageal lumen. The mesh was removed. In another patient 3 months after surgery progressive dysphagia occurred. The narrowing of the GE junction was caused by extensive scar formation around the mesh requiring the removal of the mesh. In another case on the 3rd postoperative day partial esophageal wall necrosis and perforation occurred. Reoperation was done, the patient recovered. The latter two patients had short esophagus besides the hiatal hernia. In two cases we experienced late recurrence of hiatal hernia causing symptoms.

**Discussion:** The functional results of hiatal reconstruction surgery using mesh implantation are good enough. However we would like to call attention to the open questions: appropriate indication, the size, shape and material of meshes, the mode of anchoring the mesh and the difficulties of the management of real short esophagus.

**Disclosure:** All authors have declared no conflicts of interest.

#### P07.16 SELECTIVE USE OF BIOLOGICAL MESH FOR TENSION-FREE REPAIR OF COMPLEX AND RECURRENT PARA-OESOPHAGEAL HERNIA

Hannah Travers, James Brewer, Darmarajah Veeramootoo, Neil Smart, Saj Wajed

*Royal Devon And Exeter Hospital, Exeter/UNITED KINGDOM*

**Background:** The utilisation of mesh for crural augmentation in para-oesophageal hernia (PEH) surgery to prevent early recurrence is controversial: This study evaluated the efficacy of integrating a porcine dermal collagen mesh (Permacol TM) to create a “tension-free” repair.

**Methods:** The prospectively maintained oesophago-gastric database was employed to identify patients who underwent a laparoscopic repair of complex-primary or recurrent PEH, incorporating Permacol TM into the cruroplasty, between October 2004 and February 2012. Post-operative follow-up consisted of out-patient clinical review at 6 weeks, followed by an open access appointment which patients attended if symptoms recurred and were investigated to exclude PEH recurrence.

**Results:** Forty-three patients (13 male), median age 77(range 29–91) underwent mesh-reinforced PEH repair (36 complex-primary (84%), 7 recurrent (16%).Gastroplasty was required in 3 (7%), fundoplication was performed in 24 (56%), gastropexy alone in 18 (44%). Open conversion was necessary in 2 (4.6%). There was no mortality. Complications included: oesophageal perforations 2 (4.6%) treated conservatively, in-patient post-operative partial recurrence 2 (4.6%), who underwent successful surgical re-intervention. The median follow-up was 22 months (range 1–88). 17 patients (40%) were discharged after a single clinic review with no further problems; 15 patients (35%) returned and were re-investigated but only 1 (2%) had confirmed recurrence, at 37 months, requiring revisional surgery. No serious mesh-related complications including erosion or infection have been observed.

**Discussion:** Tension-free augmentation of complex hiatal defects with selective use of biological mesh appears to be safe and reliable. Medium term follow-up demonstrates very low rates of symptomatic recurrence.

**Disclosure:** All authors have declared no conflicts of interest.

#### P07.17 TYPE IV HIATAL HERNIA: IN NEED OF REAPPRAISAL

Marcello Migliore, Damiano Calvo, Alessandra Criscione, Giuseppina Pulvirenti

*Thoracic Surgery, Dept Of Surgery, University Of Catania, Catania/ITALY*

**Background:** A type IV hiatal hernia (HH) is characterized by a large defect in the phrenoesophageal membrane, allowing abdominal organs in addition to the stomach, such as colon, spleen, pancreas, and small intestine, to herniate into the mediastinum. The published literature lacks long term results of surgical treatment for type IV HH.

**Methods:** A systematic review was performed to evaluate the results of surgical treatment of type IV HH. For this analysis a PUBMED search of

articles was conducted using simple key words that included: HH, HH and paraesophageal (PEHH), and HH and type IV.

**Results:** 4979 articles on HH, 470 on PEHH hernias and only 9 papers reporting explicitly on type IV HH were found. Among the 470 PEHH published manuscripts, some with large surgical experiences also reported on surgical treatment of type IV HH. Type IV HH always was a small subgroup, and short and long term surgical results were not well shown. Surprisingly, of the 9 manuscripts reporting specifically on type IV HH, 8 were case reports, and 1 included types III and IV HH.

**Discussion:** There is the need for improved outcomes analysis for surgical management of type IV HH.

**Disclosure:** All authors have declared no conflicts of interest.

---

#### POSTER SESSION P08: BENIGN DISEASE – MISCELLANEOUS – October 17, 2012 12:30–13:30

---

##### P08.01 MOTILITY DISORDERS IN CHILDREN AND ADOLESCENTS WITH EOSINOPHILIC ESOPHAGITIS

Savvas Karkelis<sup>1</sup>, Christos Christodoulou<sup>2</sup>, Ioannis Giannousis<sup>2</sup>, Miltiadis Rodias<sup>2</sup>, Gerasimos Stefanidis<sup>2</sup>, Ioanna Panagiotou<sup>1</sup>, Eleftheria Roma<sup>1</sup>  
<sup>1</sup>University Of Athens, <sup>A</sup> Department Of Paediatrics, Athens/GREECE,  
<sup>2</sup>Athens Naval Hospital, Gastroenterology Unit, Athens/GREECE

**Background:** Eosinophilic esophagitis in children and adolescents is a disease diagnosed at an increasing rate during the last years. It is known that eosinophilic infiltration of esophageal wall can cause secondary esophageal motility disorders in adults. The aim of the study was to investigate esophageal motility and to measure esophageal wall thickness in children and adolescents with eosinophilic esophagitis.

**Methods:** Two cases are presented: a 12 years old boy with intermittent dysphagia, weight loss and chest pain for the last 3 months before his admission and a 13 years old boy with a 2 months gradually deteriorating dysphagia and chest pain. In both adolescents laboratory findings, cardiac examination and chest x-ray were normal. An 8 weeks PPI's course had no effect and barium swallow imaging study revealed no specific findings. Upper GI endoscopy revealed normal esophageal mucosa, whereas histology findings were typical of eosinophilic esophagitis in both patients. Esophageal motility was investigated by conventional esophageal manometry and esophageal wall thickness was measured by radial endoscopic ultrasound.

**Results:** Manometry study in both adolescents demonstrated findings compatible with nutcracker esophagus. Radial endoscopic ultrasound revealed significant thickening of the esophageal wall (mainly in the lower third of the esophagus), including mucosa, submucosa muscularis and muscularis propria.

**Discussion:** Motility disorders and thickening of the esophageal wall probably contributed to symptoms. Children and adolescents with suspected eosinophilic esophagitis should be further investigated by manometry and endoscopic ultrasound to detect motility disorders and structural abnormalities of the deeper layers of esophagus, even without abnormal endoscopic findings.

**Disclosure:** All authors have declared no conflicts of interest.

##### P08.02 A CASE OF LAPAROSCOPIC SURGERY AFTER ENDOSCOPIC SUBMUCOSAL DISSECTION FOR ACHALASIA WITH ESOPHAGEAL DYSPLASIA

Kazuto Tsuboi, Nobuo Omura, Fumiaki Yano, Masato Hoshino, Seryon Yamamoto, Shunsuke Akimoto, Hideyuki Kashiwagi, Katsuhiko Yanaga  
*Jikei University School Of Medicine, Tokyo/JAPAN*

**Background:** We report a case that underwent laparoscopic Heller-Dor surgery at the time of relatively short period after ESD for esophageal dysplasia.

###### Methods:

The case is a 63-year-old man who had experienced dysphagia for 15 years. He had been diagnosed as achalasia at a clinic and observed as an outpatient. Upper GI endoscopy showed esophageal dysplasia, which was treated by endoscopic submucosal dissection (ESD). Then, he was referred to our department because he hoped surgical management for achalasia. At two months after ESD, the scar of ESD has healed and no new lesion was detected by GI endoscopy. Therefore, we planned to perform laparoscopic Heller-Dor surgery.

**Results:** The operation time was 174 minutes and intra-operative blood loss was minimal. Water intake was started on the first post-operative day and meal on the second day, and he was discharged on the fourth post-operative day.

**Discussion:** Patients with achalasia have a risk of developing esophageal cancer as a result of chronic exposure of the esophageal mucosa to retained saliva and food. Hence, we should perform pre-operative GI endoscopy for patients with achalasia to rule out concomitant malignant lesions. The current patient was able to undergo laparoscopic Heller-Dor surgery after ESD because he was observed by endoscopy strictly.

**Disclosure:** All authors have declared no conflicts of interest.

##### P08.03 A CASE OF UPSIDE DOWN STOMACH THAT REQUIRED LONG TIME FOR A DIAGNOSIS

Kazuto Tsuboi, Nobuo Omura, Fumiaki Yano, Masato Hoshino, Seryon Yamamoto, Shunsuke Akimoto, Hideyuki Kashiwagi, Katsuhiko Yanaga  
*Jikei University School Of Medicine, Tokyo/JAPAN*

**Background:** A 56-year-old woman had been treated for depression by a psychoneurologist in our hospital. She experienced sudden vomiting, difficulty of oral intake and body weight loss. She was admitted to our hospital because the psychoneurologist judged progression of disease. GI endoscopy after hospitalization revealed only mixed hiatal hernia. As the symptoms had not improved after conservative treatment, she was referred to our department.

**Methods:** Because X-ray of the chest performed at admission showed an abnormal shadow with the air fluid level in the mediastinum, we examined upper GI series, which demonstrated so-called upside stomach in which most of the stomach had herniated into the thoracic cavity. Therefore, we planned laparoscopic hiatal hernia repair and fundoplication after decompression of the stomach. At first, detachment was performed between the esophagus and the hernia sac using a left-sided approach technique. Then, the excessive hernia sac was removed. After mobilization of the whole stomach to the normal position in the abdominal cavity, the esophageal hiatus that was stretched open was sutured in 4 places. To prevent another prolapse, a fundic wrap was fixed to each ipsilateral diaphragmatic crus. Furthermore, fundoplication according to the Toupet method was performed.

**Results:** The operation time was 183 minutes and intra-operative blood loss was minimal. The post-operative course was uneventful, and the patient remains free of symptoms.

**Discussion:** Upside down stomach is a rare clinical condition in Japan. For patients with hiatal hernia who suddenly experience vomiting and passage disorder of food, exploration of the upside down stomach is necessary.

**Disclosure:** All authors have declared no conflicts of interest.

##### P08.04 A CASE OF LAPAROSCOPIC COLLIS-NISSEN FUNDOPPLICATION WITH MYOTOMY FOR ESOPHAGEAL STENOSIS DUE TO SEVERE REFLUX ESOPHAGITIS

Kazuto Tsuboi, Nobuo Omura, Fumiaki Yano, Masato Hoshino, Seryon Yamamoto, Shunsuke Akimoto, Hideyuki Kashiwagi, Katsuhiko Yanaga  
*Jikei University School Of Medicine, Tokyo/JAPAN*

**Background:** The patient was a 16-year-old male who experienced vomiting since early childhood. When he became 6 years old, he complained of dysphagia which gradually worsened. In April 2010, he already had esophageal stenosis and short esophagus by upper gastrointestinal series. He was referred to our department for surgery because five times of pneumatic dilation failed to improve his symptom. Therefore, we planned to perform laparoscopic Collis-Nissen fundoplication.

**Methods:** As the upper part of the stomach had incarcerated into the mediastinum due to short esophagus, the stomach near the hiatus was exposed using left-sided approach. Although the abdominal esophagus was exposed gradually, it was impossible to pull the esophago-gastric junction into the abdominal cavity. We performed myotomy around the esophago-gastric junction because the esophageal bougie was stuck at this location. After inserting an esophageal bougie into the stomach, stapled wedge gastropasty was performed using Endo GIA®. Then, 2 cm long Nissen fundoplication was undergone at approximately 3 cm below the esophago-gastric junction. Also, the part of bulging mucosa after myotomy were patched by the technique of Dor method.

**Results:** The operation time was 325 minutes and intra-operative blood loss was minimal. He was discharged on the eighth post-operative day. The post-operative course was uneventful, and the patient remains free of symptoms.

**Discussion:** In Japan, patients with short esophagus that require laparoscopic Collis-Nissen fundoplication are very rare. Besides, it is extremely rare that the esophageal bougie cannot be inserted into the stomach for calibration.

**Disclosure:** All authors have declared no conflicts of interest.

**P08.05 A CASE OF THORACOSCOPIC TUMORECTOMY FOR ESOPHAGEAL LEIOMYOMA LOCATED IN THE NEIGHBORHOOD OF NEAR THE AORTIC ARCH**

Kazuto Tsuboi, Nobuo Omura, Fumiaki Yano, Masato Hoshino, Seryon Yamamoto, Shunsuke Akimoto, Hideyuki Kashiwagi, Katsuhiko Yanaga  
*Jikei University School Of Medicine, Tokyo/JAPAN*

**Background:** A 31-year-old man arrived at our department for persisted dysphagia. This symptom was identified to originate from esophageal leiomyoma, for which thoracoscopic tumorectomy was planned.

**Methods:** The patient was positioned in the left lateral decubitus position. As the tumor was located on the left side of the esophagus between the aortic arch and the superior border of the azygos vein, it was difficult to identify. After exposure of the esophagus around the tumor, we twisted the esophagus by a Penrose drain in order to see the front of the tumor. We performed myotomy in front of the tumor without injury of the capsule of the tumor subsequently. Furthermore, we successfully resected the tumor without injury of the mucosa and capsule. After resection of the tumor, we sewed up the muscularis at the part of bulging mucosa.

**Results:** The operation time was 217 min. and intra-operative blood loss was minimal. Water intake was started on the first post-operative day and meal on the second day, and he was discharged on the fourth post-operative day. The post-operative course was uneventful, and the patient remains free of symptoms.

**Discussion:** As for the operative approach for leiomyoma of the thoracic esophagus, the minimally invasive thoracoscopic surgery is going to take the place of conventional thoracotomy. The thoracoscopic tumorectomy is usually performed with the left lateral decubitus position. However, the degree of difficulty of this operation usually rise when the tumor is located on left side of the thoracic esophagus.

**Disclosure:** All authors have declared no conflicts of interest.

**P08.06 A CASE OF LAPAROSCOPIC TUMORECTOMY WITH DOR FUNDOPLICATION FOR ESOPHAGEAL LEIOMYOMA LOCATED ABOVE THE ESOPHAGO-GASTRIC JUNCTION**

Kazuto Tsuboi, Nobuo Omura, Fumiaki Yano, Masato Hoshino, Seryon Yamamoto, Shunsuke Akimoto, Hideyuki Kashiwagi, Katsuhiko Yanaga  
*Jikei University School Of Medicine, Tokyo/JAPAN*

**Background:** A 31-year-old man had experienced dysphagia for one year. He was referred to our department because the symptom worsened. GI endoscopy showed an esophageal submucosal tumor that occupied semicircumferentially above the esophago-gastric junction, which was diagnosed as leiomyoma by histopathological examination. Pre-operative manometry and 24-hour pH metry revealed no abnormality of esophageal motility and acid exposure. Therefore, we planned laparoscopic excision for the symptomatic tumor.

**Methods:** After circumferential dissection of the abdominal esophagus, myotomy was performed on the tumor which was wrapped by capsule. Esophageal bougie was inserted orally in order to facilitate identification of the border between the tumor and the esophageal mucosa. The tumor was successfully excised without damage of the mucosa and capsule. Because the tumor occupied two-third of the circumference of the esophagus, exposed areas of the mucosa became expansive. Consequently, we performed cardioplasty by the Dor method to cover the bulging mucosa.

**Results:** The operation time was 111 minutes. and intra-operative blood loss was minimal. Water intake was started on the first post-operative day and meal on the second day, and he was discharged on the fifth post-operative day. The postoperative course was uneventful, and the patient remains free of symptoms.

**Discussion:** We report a case for whom we added cardioplasty at the same time of laparoscopic tumorectomy for a submucosal tumor located above the esophago-gastric junction in order to avoid reflux esophagitis after surgery.

**Disclosure:** All authors have declared no conflicts of interest.

**P08.07 ESOPHAGEAL SCHWANNOMA: THREE CASES OF HIGH 18F-FLUORODEOXYGLUCOSE UPTAKE IN POSITRON EMISSION TOMOGRAPHY IMAGING**

Kaoru Sakamoto<sup>1</sup>, Shin-ichi Kosugi<sup>1</sup>, Tatsuo Kanda<sup>1</sup>, Hajime Umez<sup>2</sup>, Yasuoki Mashima<sup>3</sup>, Toshiro Ozaki<sup>1</sup>, Seiichi Hirota<sup>3</sup>, Katsuyoshi Hatakeyama<sup>1</sup>

<sup>1</sup>Division Of Digestive And General Surgery, Niigata University Graduate School Of Medical And Dental Sciences, Niigata/JAPAN, <sup>2</sup>Division Of Cellular Molecular And Molecular Pathology, Niigata University Graduate School Of Medical And Dental Sciences, Niigata/JAPAN, <sup>3</sup>Pet Imaging Diagnostics, Tachikawa Medical Center, Nagaoka/JAPAN, <sup>4</sup>Department Of Radiology, Niigata Cancer Center Hospital, Niigata/JAPAN, <sup>5</sup>Department Of Surgical Pathology, Hyogo College Of Medicine, Nishinomiya/JAPAN

**Background:** Esophageal schwannoma is rare and its definite preoperative diagnosis is difficult to make.

**Methods:** We report herein three patients presenting with esophageal schwannoma and discuss the diagnostic strategy.

**Results:** Conventional radiological studies indicated typical solid submucosal tumors of the thoracic esophagus. FDG-PET imaging revealed a mass with increased FDG accumulation, which suggested that the tumors had malignant potential and led us to speculate gastrointestinal stromal tumors (GISTs). The first patient underwent enucleation of the tumor, which was diagnosed as schwannoma after pathological examination. In the second and third patients, imatinib was administered to assess metabolic response. PET performed one week after the administration revealed that FDG accumulation in the tumors was not attenuated. On the basis of these findings, we suspected that these tumors were schwannomas rather than GISTs. The second patient underwent esophagectomy because of the tumor bulk and third one underwent tumor enucleation. Immunohistochemical staining revealed that all the tumors were positive for S-100 protein and the final diagnosis was esophageal schwannoma.

**Discussion:** FDG-PET combined with imatinib administration may be useful for the differential diagnosis of esophageal submucosal tumors.

**Disclosure:** All authors have declared no conflicts of interest.

**P08.08 MINIMALLY-INVASIVE ENDOSCOPIC SUBMUCOSAL DISSECTION WITH A PULSED LASER-INDUCED WATER JET DEVICE IN THE SWINE ESOPHAGUS**

Chiaki Sato<sup>1</sup>, Toru Nakano<sup>1</sup>, Masato Yamada<sup>1</sup>, Atsuhiko Nakagawa<sup>2</sup>, Takashi Kamei<sup>1</sup>, Go Miyata<sup>1</sup>, Akira Sato<sup>1</sup>, Teiji Tominaga<sup>2</sup>, Susumu Satomi<sup>1</sup>

<sup>1</sup>Division Of Advanced Surgical Science And Technology, Tohoku University Graduate School Of Medicine, Sendai, miyagi/JAPAN, <sup>2</sup>Department Of Neurosurgery, Tohoku University Graduate School Of Medicine, Sendai, miyagi/JAPAN

**Background:** A drawback of endoscopic submucosal dissection (ESD) for early stage gastrointestinal tumors is the lack of instruments that can safely assist with the procedure. We developed a pulsed water jet device that can be incorporated into a gastrointestinal endoscope. The aims of this study were to demonstrate the usefulness and safety of this instrument, and to minimize the thermal damage during esophageal ESD in swine.

**Methods:** The device comprised a 5 Fr catheter, a 14 mm stainless tube for generating the pulsed water jet, a nozzle, and an optical quartz fiber. The pulsed water jet was generated at pulse rates of 3 Hz by ejecting physiological saline (4°C) within the stainless tube with a holmium-doped yttrium-aluminum-garnet (Ho: YAG) laser at 1.1 J/pulse. The impact force of the pulsed water jet was 1.3 N/Pulse. The submucosa of the esophagus was dissected directly under endoscopic view using both the pulsed water jet device and a conventional electrocautery device during the ESD. The resected tissues and dissected beds were histologically examined to evaluate thermal damage.

**Results:** ESD using the pulsed water jet device was successful, caused no harmful bleeding, and kept the endoscopic view clean under the selected settings. The extent of thermal damage in the resected specimens and resection beds using the pulsed jet device was significantly lower than that using the conventional electrocautery device.

**Discussion:** The pulsed jet device has the potential to become a safe and reliable instrument for ESD, while inducing minimal tissue injury.

**Disclosure:** All authors have declared no conflicts of interest.

**P08.09 LAPAROSCOPIC RESECTION OF ESOPHAGEAL STROMAL TUMOUR: ESOPHAGECTOMY OR ENUCLEATION?**

Eng Hong Pok, Kin Fah Chin, Peng Choong Lau, Chee Loong Yeap  
*University Malaya Medical Center, Kuala Lumpur/MALAYSIA*

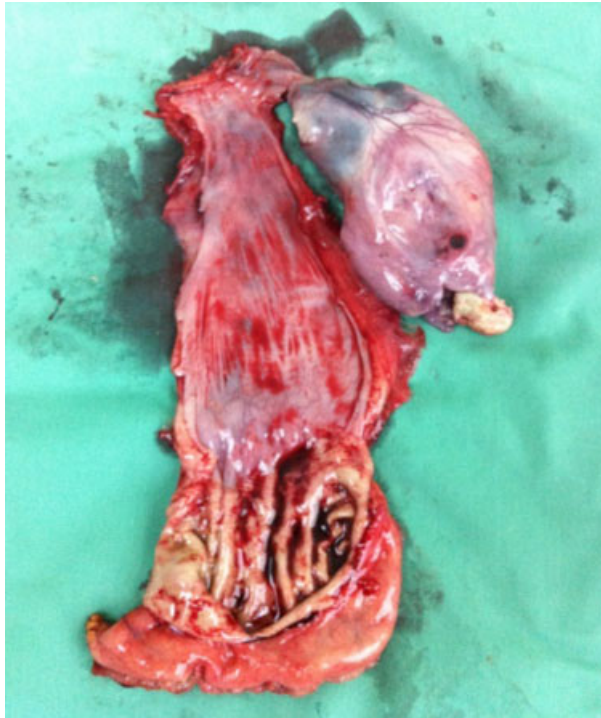**Background:** Esophageal stromal tumour (GIST) is rare entity and therefore the diagnosis and technical aspects of surgical resection still remain unclear. As esophageal surgery carry high morbidity, we present our laparoscopic approach for the treatment of this potentially malignant tumour.

**Methods:** We report 3 cases of suspected esophageal GIST which were successfully resected through minimal invasive surgery. The diagnostic workup included upper gastrointestinal endoscopy, endoscopic ultrasound and computed tomography.

**Results:** All tumours were from the lowest third of the esophagus, and the most common complaint was dysphagia. Thoraco-laparoscopic esophagectomy was performed for one large intraluminal esophageal tumour. Another two small extraluminal tumours were resected by laparoscopic enucleation. The large resected tumour was pathologically confirmed to be GIST, the rest were leiomyoma and duplication cyst.

**Discussion:** Esophageal GIST presents a diagnostic challenge and as it may be difficult to differentiate with other benign oesophageal tumour as they may appear similar clinical, endoscopic or radiographic appearance.

Esophageal GIST resections usually involve enucleation or resection. Esophagectomy is indicated for large tumour as there is a risk of recurrence through enucleation technique. However, enucleation of leiomyoma or cyst is safe provided the blunt dissection should be careful to avoid rupture of the tumour. Laparoscopic resection of esophageal GIST is a safe and feasible approach that demonstrates excellent view of the anatomy, which are advantageous compared to convention surgery.



**Disclosure:** All authors have declared no conflicts of interest.

#### P08.10 THORACOSCOPIC ESOPHAGECTOMY FOR CORROSIVE ESOPHAGEAL STRICTURE: FRIEND OR FOE?

Eng Hong Pok, Kin Fah Chin, Peng Choong Lau, Chee Loong Yeap  
*University Malaya Medical Center, Kuala Lumpur/MALAYSIA*

**Background:** Corrosive esophageal strictures are a distressing disease with the mainstay of treatment is endoscopic dilatation. However, if the strictures are extensive, prolonged dilatational therapy is ineffective with the risk of perforation. Surgery is less commonly indicated as it is associated with high morbidity and mortality. However, with the advancement of minimally invasive surgical approaches, satisfactory surgical outcome of could be achieved.

**Methods:** We would like to share our centre's experience of thoracoscopic esophagectomy for 5 patients with extensive corrosive esophageal strictures between 2009 to 2012.

**Results:** Pre-operative optimization with nutritional support by combination of enteral or parenteral support is essential to improve post-operative outcome. We routinely resected the diseased esophagus to allow anatomic placement of the esophageal conduit. Stomach is a good conduit and the colon should be reserved for cases where the stomach is also scarred. The mean operative time is 10.2 hours with most the time spent in resection of the damaged esophagus. One post-operative mortality due to aspiration pneumonia. Cervical anastomotic leak occurred in one patient and was managed with esophageal stenting. Two patients developed anastomotic stricture which were successfully dilated. The remaining two patients are symptom free during follow up.

**Discussion:** Thoracoscopic resection of the scarred esophagus could be done without increase in mortality and morbidity by experienced surgeon. It provides a feasible and safe passage for anatomical placement of the esophageal conduit. We advocate early surgical resection rather than prolonged endoscopic dilatation

**Disclosure:** All authors have declared no conflicts of interest.

#### P08.11 MANAGEMENT OF COMPLEX STRICTURES

Hideyuki Kashiwagi, Fumiaki Yano, Nobuo Omura, Kazuto Tsuboi, Masato Hoshino, Seryon Yamamoto, Shunsuke Akimoto  
*Jikei University School Of Medicine, Tokyo/JAPAN*

**Background:** A stenosis of the esophagus causes a particular problem for the affected patients; dysphagia or difficulty of swallowing. The esophageal stenosis is caused by a benign condition or a malignant disease. In general, the management of malignant or benign esophageal strictures is different and requires a different treatment approach. A benign esophageal stricture, which is the result of mucosal injury culminating in fibrosis, is not a disease but rather a complication of an underlying disease.

**Methods:** Esophageal dilation is a widely accepted treatment for esophageal stenosis. Through-the-scope balloon dilation (TTS-BD) is popular and the first-line treatment for benign esophageal stricture in Japan. Postoperative esophageal strictures have frustrated the surgeon, and the frequency, severity and contributing factors depend on the type of the surgery. Anastomotic strictures occur at the esophagogastrostomy after esophagectomy or at the esophagojejunostomy after total gastrectomy, which are sometimes complex strictures. They are usually managed by TTS-BD and require repeated dilation sessions to maintain patency. Dysphagia caused by hiatal hernia or achalasia is often treated by laparoscopic hiatal hernia repair or Heller-Dor procedure. And postoperative dysphagia after fundoplication or cardioplasty is caused by mechanical stenosis and/or peptic stricture, which becomes to be complex stricture.

**Results:** Postoperative dysphagia is managed by TTS-BD at first, but sometimes needs surgical intervention. We have performed laparoscopic reoperations, i.e. hernia repair or Heller-Dor procedure, for esophageal complex strictures after fundoplication or cardioplasty.

**Discussion:** Laparoscopic surgical treatments showed high open conversion rate, but effectiveness for esophageal complex strictures.

**Disclosure:** All authors have declared no conflicts of interest.

#### P08.12 LAPAROSCOPIC RETROSTERNAL BYPASS FOR CORROSIVE STRICTURE OF THE ESOPHAGUS

Amit Javed, Anil Agarwal  
*Gb Pant Hospital & Mam College, New Delhi/INDIA*

**Background:** Surgical management of corrosive stricture of the esophagus entails replacement of the scarred esophagus with a gastric or colonic conduit. This has traditionally been done using the conventional open surgical approach. We herein describe the first ever reported minimally invasive technique for performing retrosternal esophageal bypass using a stomach conduit.

**Methods:** Patients with corrosive stricture involving the esophagus alone with a normal stomach were selected. The surgery was performed with the patient in a supine position using 4 abdominal ports and a transverse skin crease neck incision. Steps included mobilization of the stomach and division of the gastroesophageal junction, creation of a retrosternal space, transposition of stomach into the neck (via retrosternal space), and a cervical esophagogastric anastomosis.

**Results:** Four patients with corrosive stricture of the esophagus underwent this procedure. The average duration of surgery was 260 (240–300) minutes. All the patients could be ambulated on the first postoperative day and were allowed oral liquids between the 5th-7th day. At a mean follow up of 6.5 (3–9) months all are euphagic to solid diet and had excellent cosmetic results.

**Discussion:** Laparoscopic bypass for corrosive stricture of the esophagus using a gastric conduit is technically feasible. It results in early post operative recovery, effective relief of dysphagia and excellent cosmesis in these young patients.

**Disclosure:** All authors have declared no conflicts of interest.

#### P08.13 A SURGICAL CASE OF ESOPHAGEAL LEIOMYOMATOSIS

Hideaki Shimizu, Tomoaki Saito, Hisayuki Matsushita  
*Tochigi Cancer Center, Utsunomiya/JAPAN*

**Background:** Esophageal leiomyoma is the most common benign disease in the esophagus, but esophageal leiomyomatosis is a rare, peculiar entity among esophageal diseases.

**Methods:** We report a surgical case of esophageal leiomyomatosis, with a review of the literature.

**Results:** A 37-year-old man with a 27-year history of mild dysphagia was suspected of having a mediastinal tumor on a chest X-ray at a regular medical checkup, and was referred to our hospital. Chest and abdominal CT showed thickening of the upper to lower esophageal wall. Histopathological examination following CT-guided biopsy of the esophageal wall revealed interlacing bundles of spindle cells with eosinophilic cytoplasm. These findings, along with those of immunohistochemical staining, led to a

diagnosis of esophageal leiomyomatosis. He underwent subtotal thoracic esophagectomy through right thoracotomy and laparotomy and cervical esophagogastric anastomosis with a retrosternal route. Gross examination of the resected specimen showed a tumor, 96 × 68 × 55 mm in its greatest dimensions, in the lower esophagus, and multiple nodules arranged longitudinally up to the upper esophagus. Intraoperative frozen-section examination showed that the horizontal margin of the resected specimen was histologically negative, but the resected margin was positive for tumor cells on postoperative histopathological examination. The patient was discharged uneventfully on the 19th postoperative day. Since the resection margin of the cervical esophagus was positive, he was followed-up regularly.

**Discussion:** We conclude that this is a sporadic case of leiomyomatosis because of the absence of a family history of the disease, as well as of renal disease and ocular lesions.

**Disclosure:** All authors have declared no conflicts of interest.

#### P08.14 ADAPTATION OF THE PULSED LASER-INDUCED LIQUID JET (LILJ) TECHNOLOGY FOR ENDOSCOPIC SUBMUCOSAL DISSECTION EVALUATING THE PHYSICAL PROPERTIES OF THE ESOPHAGUS

Masato Yamada, Toru Nakano, Chiaki Sato, Atsuhiko Nakagawa, Go Miyata, Takashi Kamei, Akira Sato, Teiji Tominaga, Susumu Satomi  
*Tohoku University Graduate School Of Medicine, Sendai,miyagi/JAPAN*

**Background:** The pulsed laser-induced liquid jet (LILJ) device was designed to endoscopically dissect tissue without thermal injury. This study sought to determine the optimal hydrodynamic conditions for the pulsed water jet to dissect the submucosa of the esophagus, investigate the mechanism of dissection of the submucosa and evaluate its physical properties.

**Methods:** Pulsed water jets were ejected from a nozzle by accelerating cold physiological saline using a pulsed holmium: yttrium-aluminum-garnet laser. The impact force of the pulsed water jet was measured by a force meter to evaluate the optimal hydrodynamic conditions to dissect the submucosa in a swine model. The resection beds and resected tissue specimens generated using this device were examined histologically. The physical properties of each layer of the swine esophagus were evaluated to measure the breaking stress by TENSIPRESSER™.

**Results:** The submucosal layer of the esophagus was dissected while preserving the small vessels, without injuring the muscular layer, and maintaining a clear surgical field. The mean breaking stress of the mucosal, submucosal and muscular layer were  $1.32 \pm 0.19$ ,  $0.12 \pm 0.04$  and  $1.41 \pm 0.4$  MPa respectively.

**Discussion:** The results indicated that the impact force of the pulsed water jet was well controlled by changing the laser energy and standoff distance (the distance between the tip of the nozzle and the optical fiber) and that the pulsed water jet device is useful in the dissection of the submucosa since this layer requires minimal force for mechanical dissection among all layers of the esophagus in a swine model.

**Disclosure:** All authors have declared no conflicts of interest.

#### P08.15 THE VARIATION IN SYMPTOMATIC AND ENDOSCOPIC PRESENTATION OF EOSINOPHILIC OESOPHAGITIS

Michael Samuel James Wilson, Adam Simpson, Susan Colley, Robert Stirling, Christopher Haigh, Stephen E Attwood  
*North Tyneside General Hospital, North Shields/UNITED KINGDOM*

**Background:** Eosinophilic oesophagitis (EoE) is variably diagnosed in the UK and often missed. Dysphagia is the main symptom but the pattern varies widely. In 2004, a patient database was established in Northumbria Healthcare Trust. We studied the variation in presentation and endoscopic findings.

**Methods:** All dysphagic patients undergo oesophageal biopsy at endoscopy. The peak eosinophil count per high power field (eos/hpf) in lower, mid and upper oesophageal biopsies was recorded.

**Results:** We have diagnosed 88 patients with EoE; 73 (83%) male, 15 female. Median age at diagnosis was 47 (range 16–84 y). 78 (89%) patients had  $\geq 15$  eos/hpf, 2 (2%) had  $< 15$  eos/hpf and in 8, (9%) the pathologists diagnosed EoE without reporting the count. Mean duration of symptoms was 3.3 years ( $< 1$  month to 30 years). The presenting complaints were: dysphagia 74 (84%), bolus obstruction 45 (51%), and heartburn 17 (19%). Endoscopy appeared normal in 15 (17%), or consistent with reflux oesophagitis 6 (7%). The remaining 66 (75%) were suggestive of EoE: strictures 8 (12%), Schatzki rings 9 (14%), white exudates 9 (14%) and rings, trachealisation, furrows and nodularity in the remainder. 29 (33%) patients have been treated with topical steroids, 23 (26%) with montelukast and 4 (5%) required endoscopic dilatation. 15 had mild symptoms requiring no therapy after diagnosis.

**Discussion:** Our study demonstrates the variation in reported symptoms and endoscopic findings of EoE. The range of symptom severity influences the

clinical approach. Some patients require no therapy. Follow up of each case is necessary, due to the diverse and unpredictable progress of the disease.

**Disclosure:** All authors have declared no conflicts of interest.

#### P08.16 VARIABLE REPORTING AND DIAGNOSIS OF EOSINOPHILIC OESOPHAGITIS ACROSS THE UK: DATA FROM THE BSG NATIONAL REGISTER

Michael Samuel James Wilson<sup>1</sup>, Adam Simpson<sup>1</sup>, Jamal O Hayat<sup>2</sup>,

Howard Ellison<sup>3</sup>, Jin-yong Kang<sup>2</sup>, Stephen E Attwood<sup>1</sup>

<sup>1</sup>North Tyneside General Hospital, North Shields/UNITED KINGDOM,

<sup>2</sup>St George's Hospital, London/UNITED KINGDOM, <sup>3</sup>British Society Of Gastroenterology, London/UNITED KINGDOM

**Background:** Eosinophilic oesophagitis (EoE) was first described over 20 years ago. In 2010, the British Society of Gastroenterology (BSG) established a national register. The aim was to determine UK prevalence, identify centres for research and areas where education may be beneficial. We report data collected to January 2012.

**Methods:** A voluntary, anonymised web-based register was established. Sex, date of birth, postcodes, duration and pattern of symptoms, eosinophil count and treatments were recorded.

**Results:** Data for 315 patients was analysed; 229 from five centres, 86 from 30 other centres, none from 70 centres. Age ranged from 0–85 years; 236 males, 77 females (3:1). 249 (79.0%) patients had  $\geq 15$  eosinophils per high power field (eos/hpf), 11 (4%) had  $< 15$  eos/hpf, 55 (17%) had no count recorded. The main presenting complaints were: dysphagia in 250 (79%), bolus obstruction in 127 (40%) and heartburn in 59 (19%). Endoscopy appeared normal in 47 (15%) or consistent with reflux oesophagitis in 25 (8%). The remaining 243 (77%) were suggestive of EoE: strictures in 43, Schatzki ring in 10, white exudates in 16 and rings, trachealisation or furrows in the remainder.

**Discussion:** Dysphagia or bolus obstruction are the most common symptoms. 23% of patients have no endoscopic signs to suggest EoE. Therefore biopsy of all patients with dysphagia should be performed regardless of endoscopic appearance. There is variable reporting of EoE in the UK. Several centres had sufficient patients to facilitate research. However for those centres with no patients submitted, it is unclear whether no patients were diagnosed or if they were simply not entered into the register.

**Disclosure:** All authors have declared no conflicts of interest.

#### P08.17 NON-MALIGNANT RESPIRATORY TRACT FISTULATION FROM THE ESOPHAGUS. A LETHAL CONDITION WHERE NOVEL THERAPEUTIC OPTIONS ARE EMERGING.

Peter Elbe<sup>1</sup>, Jon Tsai<sup>2</sup>, Lars Lundell<sup>3</sup>, Mats Lindblad<sup>3</sup>, Magnus Nilsson<sup>2</sup>

<sup>1</sup>Karolinska University Hospital, Stockholm/SWEDEN, <sup>2</sup>Karolinska

University Hospital Huddinge, Gastrocentrum K53, Stockholm/SWEDEN,

<sup>3</sup>Karolinska University Hospital, Stockholm/SWEDEN

**Background:** Fistulas between the esophagus and the respiratory tract can occur as a complication to anastomotic dehiscence after esophageal resection without any signs of remaining tumor growth. The traditional approach is to deviate the proximal portion of the esophagus and transpose the conduit into the abdomen. With the introduction and development of self-expandable metal stents (SEMS), new therapeutic options have emerged. We have prospectively evaluated a stent based strategy to manage these life threatening situations.

**Methods:** At Karolinska University Hospital all patients with esophagorespiratory fistulas during 2003–2011 followed a stent based strategy. On clinical suspicion a CT scan was performed and an endoscopy to assess the esophagus, the conduit and the respiratory tree. The double stent strategy meant that SEMS were applied on the alimentary and airway side to cover the fistula from both sides.

**Results:** 17 cases was treated, of which 13 had a fistulation after an esophageal resection due to cancer and 4 cases a benign underlying disease. Out of 17 patients three had a salvage esophagectomy/conduit resection and proximal endoesophagectomy. The average duration of hospital stay was 58 days. Only 2 succumbed directly related to the fistulation and one later due to recurrent tumor growth. Only one fistulation healed completely without reconstruction.

**Discussion:** When a non-malignant esophagorespiratory fistula is diagnosed attempts should be made to close the fistula by SEMS from both directions. Thereby a majority of patients can be managed with prospects of a successful initial outcome but virtually all will subsequently require an eventual one stage resection and reconstruction.

**Disclosure:** All authors have declared no conflicts of interest.

**P08.18 SURGICAL MANAGEMENT AND OUTCOMES OF SEVERE GASTROINTESTINAL INJURIES DUE TO CORROSIVE INGESTION**

Amit Javed, Sujoy Pal, Peush Sahni, Tushar Kanti Chattopadhyay  
*All India Institute Of Medical Sciences, New Delhi/INDIA*

**Background:** To report our experience in surgically managing severe injuries to the gastrointestinal tract due to corrosive ingestion.

**Methods:** Retrospective review of patients who underwent emergency surgery for severe gastrointestinal injuries following corrosive ingestion. Severe corrosive injuries defined as full thickness necrosis with perforation of the esophagus/stomach (with/without involvement of the adjacent viscera) with resultant mediastinitis or peritonitis.

**Results:** Between 1983 and 2010, 209 patients with corrosive injury of the esophagus were managed. Of these, 13 (6.2%) patients underwent emergency surgery for severe corrosive injury. The median age was 22 years and median interval between corrosive ingestion and surgery was 24 hours. The surgical procedures done included esophagogastrectomy alone (n = 6), esophagogastrectomy with duodenectomy (n = 4), esophagogastrectomy with pancreaticoduodenectomy (n = 1), esophagogastrectomy with splenectomy (n = 1), and distal gastrectomy with duodenectomy (n = 1). Two patients died in the postoperative period and one after discharge awaiting the second surgery. The factors significantly predictive of mortality following such an injury included renal failure at presentation, metabolic acidosis, delay >24 hours between corrosive ingestion and surgery, and corrosive induced adjacent organ injury (p < 0.001, 0.02, 0.005, and 0.015 respectively). Ten patients underwent subsequent surgery for restoration of alimentary tract continuity. Median follow-up (following restoration) was 36.5 months. One patient developed cervical anastomotic stricture which was successfully managed by dilatation. Another developed severe aspiration necessitating laryngeal inlet closure and permanent tracheostomy.

**Discussion:** Management of severe corrosive injury involves prompt resuscitation and urgent surgical debridement. Although subsequent restoration of continuity may be complicated, long-term outcomes are acceptable in majority.

**Disclosure:** All authors have declared no conflicts of interest.

**P08.19 FISTULA AORTO ESOFÁGICA. DUAL STENT THERAPY: AORTICO AND ESOFAGICO, WITH GOOD EVOLUCIóN.**

Hugo Héctor Otaño  
*Fundación Médica De Rio Negro Y Neuquén, Cinco Saltos, Rio Negro/ ARGENTINA*

**Background:** Patient of 70 years of age, with prothesis aortic by disección type B of 7 years. The prothesis lesionó the aorta and the esofago, causing a high, 2 stroke gastrointestinal bleeding as describes it Dr Chiari. In a patient in a very serious state was decided by placing a new prothesis in orta toraxica and a stent in the esofago Poliflex type. with good evolution. high 14 days with oral feeding.

**Methods:** Only case. Selection of a stent for this case. selection of a therapy according to the patient and the current situation.

**Results:** Good evolución. Control of gastrointestinal bleeding which is the main cause of death and control of the mediastinitis is the other cause of death. and early feeding patient dl. high day 14 with intake according to the procedure.

**Discussion:** before the arrival of the stent, these patients were operated. with very aggressive surgeries. esofagectomias, esofagica, cervical esofagostoma, gastrostomia exclusion of food. with 75% of mortalida in different series. the use of stent believe that it will improve the evolution of these pacientes. necesitaba removable stent but with sufficient radial force and the Boston Poliflex was well.

**Disclosure:** H.H. Otaño: Fundacio Medica de RIO nEGRO Y nEUQUEN

**P08.20 INITIAL OUTCOMES OF SYMMETRICALLY FLARED COVERED NITINOL STENTS FOR ESOPHAGEAL PATHOLOGIES**

Costas Bizekis, David W Yaffee, Brian Solomon, Yu Xia, Harvey I Pass, Eugene A Grossi, Michael Zervos  
*New York University School Of Medicine, New York/UNITED STATES OF AMERICA*

**Background:** Covered stents have become part of the armamentarium for treating various esophageal pathologies. A recently available, low profile, fully covered metal stent with symmetrical flares (FCMSF) may offer improved deployment and resistance to migration.

**Methods:** A retrospective review of 58 esophageal FCMSF placed in 47 consecutive patients by a single thoracic surgeon between March 2010 and February 2012 was performed. Pathologies included benign and malignant stricture and leak. Stents were placed endoscopically under general anesthe-

sia using a 6 mm deployment system; bidirectional maneuverability was possible. Dysphagia score (0-4) was prospectively recorded. Leak treatment was assessed with postoperative esophagrams.

**Results:** Mean age was 62.0 years. Sixteen of 58 stents (28%) were placed urgently/emergently. All patients had successful stent deployment with 0% stent-related hospital morbidity/mortality. Overall post-operative morbidity occurred following 12/58 stents, including arrhythmia, pneumonia, pneumothorax, urinary retention, hemodynamic instability, and COPD exacerbation. In patients with stricture (n = 29), mean dysphagia scores were reduced from 3.0 preoperatively to 1.2 post-operatively (p < 0.001). For leak, stent therapy (+/- drainage) avoided formal esophageal operation in 94% (17/18). Fifteen stents were removed during follow-up, 4 after migration. Mean overall survival was 2.3 ± 2.6 months for stricture (21/35 remain alive) and 8.7 ± 9.6 months for leak (16/18 remain alive). Mean duration of stent therapy was 4.9 ± 4.8 months for stricture (29/35 remain in situ) and 3.5 ± 3.2 months for leak (10/20 remain in situ). Mean hospital stay was 3.9 ± 7.0 days.

**Discussion:** FCMSF are an effective therapy for both esophageal strictures and leaks. The symmetrical covered flares likely contribute to the low observed migration rate.

**Disclosure:** C. Bizekis: Covidien Speakers Bureau Olympus Speakers Bureau E.A. Grossi: Medtronic Speakers Bureau, Royalty Edwards Consultant, Royalty Estech, Royalty M. Zervos: Covidien Speakers Bureau Olympus Speakers Bureau  
All other authors have declared no conflicts of interest.

**P08.21 PYOMYOSITIS OF ESOPHAGUS**

Frank C Lin, Chin-shaw Tsai  
*Tung's Taichung Metroharbor Hospital, Taichung/TAIWAN*

**Background:** Inflammatory disease of esophagus are common. It happens in mucosa layer mostly such as GERD. Abscess is unusual and can be seen in perforation of esophagus mostly. Abscess of whole esophageal muscular layer is rare.

**Methods:** We presented a case with abscess in the muscle of esophagus.

**Results:** A 46 y/o heroin addict male with enterocutaneous fistula wave and wean. He had abscess over the entire muscular layer of thoracic esophagus with intact mucosa. He was treated with thoracotomy, debridement of esophageal wall, antibiotics, and adequate drainage. He survived with his esophagus preserved.

**Discussion:** Abscess of whole muscular layer of esophagus with intact of mucosa is very rare. Extension from the enterocutaneous fistula or hematogenous spreading from heroin abuse were the possible mechanisms of this patient. The life of the patient can be saved without sacrifice of the esophagus.

**Disclosure:** All authors have declared no conflicts of interest.

**P08.22 TAILORED TREATMENT TO PATIENTS WITH FUNCTIONAL DISORDERS OF THE DISTAL ESOPHAGUS CAUSING HIGH DYSPHAGIA**

Marcello Migliore<sup>1</sup>, Damiano Calvo<sup>1</sup>, Giuseppina Pulvirenti<sup>1</sup>, Alessandra Criscione<sup>1</sup>, Gaetano Catania<sup>2</sup>, Francesco Basile<sup>2</sup>  
<sup>1</sup>Thoracic Surgery, Dept Surgery, University Of Catania, Catania/ITALY, <sup>2</sup>General Surgery, Department Of Surgery, University Of Catania, Catania/ITALY

**Background:** High dysphagia (HD) is reported by about 30% of individuals with distal functional esophageal disease (DFED). Literature lacks of studies reporting the results of the surgical treatment for HD in patients with DFED

**Methods:** Patients were identified from a prospective maintained database of manometric studies. All treated patients with HD as presenting symptom associated with the final diagnosis of DFED were included. Parameters studied were: age, sex, associated symptoms, barium meal and the result of treatment. The lower (LES) and Upper esophageal sphincter (UES) resting pressure and relaxation, amplitude and duration of pharyngeal contraction, coordination between the pharyngeal contraction and the UES relaxation, and the coordination between the closure of the UES and the first esophageal contraction were also studied.

**Results:** Twenty one patients, 12 male and 9 female (mean age 47 yo). Sixteen patients had esophageal achalasia (EA) and 5 patients a Tight Nissen fundoplication (TNF). Associated symptoms were globus pharyngeus, retrosternal pain and regurgitation. Incoordination between the closure of the UES and the first esophageal contraction was present in 17 patients (13 achalasia, 4 TNF). Ten patients with EA underwent dilatation and 6 esophageal myotomy of the LES. All patients with TNF following several attempts of dilatation, underwent re-operation and the 360° wrap was dismantled.



After treatment, HD disappeared in all patients with TF and in 14 (87%) patients with EA. Follow up is complete (5–12 years).

**Discussion:** Tailored treatment of functional disorders of the distal esophagus causing HD permits to resolve the symptom in 90 % of patient.

**Disclosure:** All authors have declared no conflicts of interest.

#### P08.23 ASSESSMENT OF QOL IN RELATION TO THE TYPE OF RECONSTRUCTION IN COMPLEX CORROSIVE STRICTURES OF UPPER GI TRACT

Servarayan Murugesan Chandramohan, Benet Duraisamy, D Madhusudhanan, A Amudhan  
Madras Medical College And Rajiv Gandhi Government General Hospital, Chennai INDIA

**Background:** Corrosive injuries of the upper gastrointestinal tract is one of the common cause for Upper gastrointestinal strictures in the Indian sub-continent. Frequently, esophageal substitution surgeries with either tubularised stomach or colon is done to bypass the strictured esophagus.

**Methods:** This study analyses the quality of life following the two types of reconstructive surgeries: gastric pull-up vs. coloplasty. (Colon Substitution). We used SF-36 General Health Questionnaire and self-made disease-specific questionnaire. All Patients who underwent conduit surgery at our department between march 2009 and February 2011 were asked to fill this questionnaire one month and one year following the surgery. The results of the two time periods are compared for better differentiation.

**Results:** A total of 44 patients were included in the study. Among them 12 underwent gastric pull-up and 32 patients underwent coloplasty. Patients undergoing coloplasty had higher mean scores in both physical and mental health components at one month and one year follow-up and was found to be statistically significant in most of the components analysed. Also, reflux related scores; weight related scores and psychological scores were significantly higher for coloplasty patients at one year follow-up.

**Discussion:** Long term results of colon as esophageal substitute is better than gastric pull-up.

**Disclosure:** All authors have declared no conflicts of interest.

#### P08.24 BYPASS ESOPHAGOCOLOPLASTY AT COMBINATIVE POST CORROSIVE CICATRICAL NARROWINGS OF A GULLET

Erbol Shaihiyev<sup>1</sup>, Zhetbergen Arzykulov<sup>2</sup>, Shakir Zhuraev<sup>1</sup>, Arman Aliev<sup>1</sup>  
<sup>1</sup>A.N. Syzganov, S National Scientific Centre Of Surgery, Almaty/ KAZAKHSTAN, <sup>2</sup>National Scientific Centre Of Surgery, Almaty/ KAZAKHSTAN

**Background:** For many years, treatment of chemical burns of the esophagus and its implications continues to remains an actual problem.

**Methods:** 109 pts aged 16–71 yrs underwent shunt esophagocoloplasty. All patients with post-burn cicatricial narrowing of the esophagus. Men 52(47.7%), 57 women (52.3%).

Cause of esophagus affection were swallowed aggressive chemical agents. 82 (75.2%) accidental pts, 27 (24.8%) suicide pts. In 67(61.5%) pts damaging agent was an acid. Affections with alkali were in 33(30.3%) patients. Burn with unknown chemical agent in 9 (8.2%) pts. In 72 (66.1%) pts we have found a combined lesion of the esophagus and stomach. In 25 (22.9%) cases there were combined narrowing of the pharynx and esophagus. In 12 (11.0%) pts we have found isolated cicatricial stenosis of the esophagus. For colotransplant we used the left colon in 62 (56.9%) cases; the left colon with segment of sigmoid colon in 46 (42.2%) cases; in one case (0.9%) we used right colon. Colotransplant we placed retrosternal in the anterior mediastinum. Long-term results were studied in 102 (93.6%) pts in a period of 5 months to 15 years.

**Results:** Positive remote result was achieved in 78 (85%) of patients. Stenosis of the anastomosis in the neck was observed in 20 (18.3%) patients. Mortality 4 (3.7%).

**Discussion:** Compliance with the basic principles of reconstructive-restorative treatment, can provide positive long-term result.

**Disclosure:** All authors have declared no conflicts of interest.

#### P08.25 THE EXPERIMENTAL EVALUATION OF BIOCMPATIBILITY OF THE GENIPIN BIOTYPE ARTIFICIAL ESOPHAGUS

Jian-hua Deng<sup>1</sup>, Guang-guo Ren<sup>2</sup>  
<sup>1</sup>Dujiangyan People'S Hospital, Dujiangyan/CHINA, <sup>2</sup>Sichuan Provincial Tumor Hospital, Chengdu/CHINA

**Background:** To investigate the biocompatibility of the genipin biotype artificial esophagus.

**Methods:** The biocompatibility of the genipin biotype artificial esophagus was primarily evaluated by using the acute and subacute toxicity tests, hemolysis test, cytotoxicity test, and muscle implantation test.

**Results:** No acute or subacute toxicity was revealed with the genipin biotype artificial esophagus; Its hemolysis rate was 0.559% (less than 5%); The cytotoxicity scores were 0 and 1 grade; a mild inflammatory reaction with a small amount of lymphocytic infiltration was observed in rabbit's muscle one week after implantation; a large number of lymphocytes and eosinophils around the material were observed four weeks after implantation, but reduced with a significantly decreased inflammatory reaction 12 weeks after implantation.

**Discussion:** Our findings showed that the genipin biotype artificial esophagus would be a promising biomaterial with good biocompatibility for clinical application.

**Disclosure:** All authors have declared no conflicts of interest.

#### P08.26 ROUX EN Y GASTROJEJUNOSTOMY FOR THE TREATMENT OF COMPLEX ESOPHAGO-GASTRIC PROBLEMS

Beatrice Aramini, Marialuisa Lugesari, Alberto Ruffato, Ottorino Perrone, Sandro Mattioli  
Division Of Thoracic Surgery, Gym Care & Research, Maria Cecilia Hospital, Cotignola (Ravenna), Center For The Study And Therapy Of Diseases Of The Esophagus. Alma Mater Studiorum – University Of Bologna, Italy, Bologna/ITALY

**Background:** Roux en Y gastrojejunostomy has been proposed for the treatment: a) of complex benign esophageal problems generally in alternative to distal esophagus resection; b) of complex redo antireflux surgery; c) of associated gastric antrum and gastro-esophagal junction diseases, to avoid acid-alkaline esophageal reflux, common after Billroth II gastrojejunostomy. The Roux Stasis Syndrome (RSS) may impair results in 10% to 50% of cases. Aim of the study is to evaluate the incidence of RSS after Roux en Y gastrojejunostomy performed avoiding division of the jejunal mesentery, the gastrojejunal terminolateral anastomosis being vertical to optimize emptying.

**Methods:** Of 38 patients, 27 were followed up in long term. Patients were consecutively submitted to distal gastric resection for neoplastic or functional disease of the esophageal and/or gastric tract and reconstruction with Roux en Y jejunostomy. Patients were followed up with clinical interview, barium swallow, endoscopy.

**Results:** Mortality was 2.6% and morbidity was 16.2%. Median follow-up was 113.6 months (range 6–192 months). RSS were found in 2 on 27 patients (7.4%). Two patients (with caustic injury) were then subjected to esophago-colo-gastroplasty for esophageal stenosis not otherwise treatable, one patient (already undergone two redo surgery for esophageal achalasia) complained of significant dysphagia. In the remaining patients the functional result is satisfactory.

**Discussion:** Roux en Y gastrojejunostomy is an effective option for the treatment of complex esophago-gastric problems. The Roux Stasis Syndrome may be minimized with few technical details.

**Disclosure:** All authors have declared no conflicts of interest.

#### P08.27 A CASE OF AN ESOPHAGEAL GRANULAR CELL TUMOR REMOVED WITH ENDOSCOPIC SUBMUCOSAL DISSECTION AFTER ENDOSCOPIC VARICEAL LIGATION IN A CIRRHOTIC PATIENT

Eiko Okamoto, Mayumi Kondoh, Takao Shibayama  
Toshima Hospital, Tokyo/JAPAN

**Background:** Endoscopic treatment for esophageal submucosal tumor has been recently established, but esophageal varices put the treatment at high risk of bleeding.

**Methods:** A 43-year-old man was admitted for alcoholic liver cirrhosis. Endoscopy revealed esophageal varices and a 15 mm hemispherical submucosal tumor in the lower thoracic esophagus. For esophageal varices, we performed an endoscopic variceal ligation (EVL) 2 times. We couldn't detect esophageal varices after EVL, but a submucosal tumor changed features, looked like reddened molar-like appearance. Biopsy showed a granular cell tumor (GCT), positive for S-100 protein. Endoscopic ultrasonography disclosed that the tumor was located in the lamina propria mucosae and extended into the submucosal superficial layer.

**Results:** We performed an endoscopic submucosal dissection (ESD) with a needle knife. There were some blood vessels in the submucosal layer, but we could control them with a cautery device. No bleeding or perforation occurred, and the tumor was free from the vertical margins of the resected specimen.

**Discussion:** Endoscopic resection is currently reported in an approach for total resection of GCT. However, in cirrhotic patients esophageal varices

make the resection difficult because of bleeding. After EVL made varices disappeared, we could safely perform ESD without any complications. That's because ESD permits us to see directly blood vessels and to resect the tumor safely even if there are remaining thick vessels. We report herein the usefulness of ESD for GCT after EVL for esophageal varices.

**Disclosure:** All authors have declared no conflicts of interest.

#### P08.28 ACQUIRED TRACHEO-ESOPHAGEAL FISTULA CAUSED BY EXPOSED ALUMINIUM PHOSPHIDE TABLETS

Satpal Singh Virk, Pankaj Sihag, Sushil Budhiraj  
Dayanand Medical College & Hospital, Ludhiana/INDIA

**Background:** Acquired tracheo-esophageal fistula (TEF) is a rare complication that can occur from variety of causes. The common causes of non-malignant TEF are prolonged tracheal intubation, penetrating and blunt trauma, button batteries, esophageal diverticulum, impacted foreign body, corrosive ingestion etc. We report a series of acquired TEF caused by ingested exposed aluminium phosphide tablet (AIP). AIP is a lethal protoplasmic toxin used as fumigant pesticide and has systemic toxicity. Tablet exposed to air lose their systemic toxicity but can cause severe local damage at the site of lodgment.

**Methods:** Prospectively collected data of patients with diagnosis of tracheo-esophageal fistula was analysed retrospectively with regard to etiology, presentation, management and their long term follow-up.

**Results:** Five cases of esophageal injury due to attempted suicide with AIP tablets were managed in our department. Four patients had pneumonitis and one dysphagia. Endoscopic dilatation was attempted in one patient while stent placement was done in another one patient. Primary closure of tracheal rent and resection and end to end esophageal anastomosis was done in four and colonic interposition in one patient. All patients were followed up from 24-48 months.

**Discussion:** AIP is one of the most common suicide agents in northern India, where it is freely used as grain preservative. In sick patients staged surgical intervention, endoscopic method, or combination of both have been employed. In fit patients, definitive surgical methods are preferred. AIP usually involves short segment of esophagus, closure of tracheal rent and resection of part of esophagus and anastomosis is sufficient

**Disclosure:** All authors have declared no conflicts of interest.

#### P08.29 UNUSUAL GIANT ESOPHAGEAL LEIOMYOMA COMPRESSING INFERIOR VENA CAVA AND COMPLICATED BY ESOPHAGO-PLEURAL FISTULA.

Pietro Bruschini<sup>1</sup>, Tiziano De Giacomo<sup>2</sup>, Daniele Diso<sup>1</sup>, Sokratis Tsagharopoulos<sup>1</sup>, Federico Francioni<sup>1</sup>

<sup>1</sup>Department Of Thoracic Surgery University Of Rome, Rome/ITALY,

<sup>2</sup>Department Of Thoracic Surgery University Of Rome La Sapienza, Rome/ITALY

**Background:** Leiomyoma is the most common benign tumour of the esophagus; its growth causes symptoms due to partial obstruction of the esophageal lumen. In severe cases extra luminal growth causes compression of adjacent organs. Surgical treatment remains the main therapeutic option for symptomatic and complicated patients.

**Methods:** A 30-years-old woman was admitted to a peripheral hospital for abdominal and chest pain, and legs edema. CT showed a voluminous parenchymatous mediastinal mass, expanding to postero-inferior mediastinum and compressing inferior vena cava and suprahepatic veins and hepatomegaly. Suspecting lymphoproliferative disease, it was performed a thoracoscopic biopsy of the mass. Histological examination demonstrated that the pathological tissue was a leiomyoma of the esophageal wall. After few days, patient developed fever and empyema (treated with chest drainage). For this reason patient was referred to our Department. Esophagogastro-duodenoscopy revealed an esophageal-pleural fistula and an "ab-estrinsec" compression of the right esophagus wall. CT and MR showed the mass extending through the diaphragm and compressing suprahepatic veins. Abdominal-US confirmed hepatomegaly and ascites. Surgical treatment was performed. We decided for laparotomic access to safely separate suprahepatic veins from the mass and to remove its transjugal adhesions. Then we performed a partial esophagectomy via thoracotomic access followed by esophagus-gastric anastomosis.

**Results:** There were no postoperative complications and the patient completely recovered was discharged after two weeks. A clinical-radiologic follow-up after six months confirmed complete regression of symptomatology.

**Discussion:** To the best of our knowledge, this is the first case of giant esophageal leiomyoma causing symptomatic compression of inferior vena cava.

**Disclosure:** All authors have declared no conflicts of interest.

#### P08.30 A CASE OF BOERHAAVE'S SYNDROME MANAGED SECOND TRANSHIATAL APPROACH WITH EXTERNAL ESOPHAGEAL DRAINAGE USING A T-TUBE

Hisao Kano, Kenji Mimatsu, Atsushi Kawasaki, Youichi Kuboi, Nobutada Fukino, Kazutoshi Kida, Takatsugu Oida  
Social Insurance Yokohama Central Hospital, Kanagawa Yokohama JAPAN

**Background:** Boerhaave's syndrome is a spontaneous rupture of the esophagus, which is a rare condition with a high mortality rate. Standard therapy is operation with primary closure and fundoplication. Recently primary treatment divided three categories, conservative, endoscopic, and surgical approach. But second therapy is not clear for un-success case of primary treatment. We have treated elderly patient with external T shaped drainage tube insertion into the esophagus, after leakage of primary suture.

**Methods:** A 67 years old male was visited with chief complaint of front chest pain. His past history was COPD. The patient suddenly occurred front chest pain on coughing in swallowing a meal. CT scan revealed pneumomediastinum and right pleural effusion a little, suggestive of esophageal perforation. Upper GI series showed leakage is not obvious. First therapy was antibiotics and nasogastric suction, conservative. 2 days later, pneumomediastinum was enlarged, and had highgrade fever. First operation performed, trans abdominal hiatal approach, primary closure and omentoplasty for abdominal esophagus left side perforation. 9 days later patient had upper side mediastinal abscess, and peritonitis for anastomosis leakage. Second operation performed, trans cervical drainage for mediastinal abscess, and transhiatal approach with external esophageal drainage using a T-tube.

**Results:** Oral intake was started on postoperative day 24. T-tube removed postoperative day 47.

**Discussion:** External esophageal drainage using a T-tube for Boerhaave's syndrome thought one of the minimal invasive techniques for late or second spontaneous esophageal operation.

**Disclosure:** All authors have declared no conflicts of interest.

#### P08.31 THE MINIMAL ESOPHAGOSTOMY ON THE CONSERVATOR TREATMENT OF ESOPHAGUS PERFORATION

Marnay Carvalho, Bruno Zilberstein, Renato De Araujo Pereira, Juliana Ferreira, Cely Bussons, Guilherme Tommasi Kappaz  
Gastromed Instituto Zilberstein, São Paulo/BRAZIL

**Background:** The esophagostomy is the main method used on esophagic lesions to divert the saliva direction, but it obligatory implicates the esophagus resection and complex reconstruction methods. Whit the objective to avoid this drawbacks, was proposed the minimal esophagostomy utilization in this cases.

**Methods:** Case 1 – female patient, 73 years old with esophagus perforation seven days after hiatoplasty surgery because of a recurrent hiatal hernia. Case 2 – female patient, 26 years old, with esophagus perforation six days after bariatric surgery because of unstoppable vomiting. Both patients underwent to laparoscopy to clean and drain the abdominal cavity with jejunostomy in the case 1 and gastrostomy in the case 2, associated with thoracoscopy to drain the thorax. Minimal esophagostomy with foley probe n.20 was performed in both patients. The technical steps are presented in this poster.

**Results:** Both patients underwent without problems with oral diet introduced in the 60th (Case 1) and 90th (Case 2) days after surgery. The three months follow up showed the complete resolution of the fistulae.

**Discussion:** The minimal esophagostomy is an easy and viable choice to be considered on the conservator treatment of esophagus perforation.

**Disclosure:** All authors have declared no conflicts of interest.

#### P08.32 ESOPHAGEAL PYOGENIC GRANULOMA AFTER ESOPHAGECTOMY

Shin Yamamoto<sup>1</sup>, Masaho Ota<sup>1</sup>, Kosuke Narumiya<sup>2</sup>, Takuya Sato<sup>1</sup>, Yuji Shirai<sup>1</sup>, Harushi Osugi<sup>3</sup>, Masakazu Yamamoto<sup>1</sup>  
<sup>1</sup>Institute Of Gastroenterology, Tokyo Women'S Medical University, Tokyo JAPAN, <sup>2</sup>Gastrointestinal Surgery, Tokyo/JAPAN, <sup>3</sup>Department Of Gastroenterological Surgery, Osaka City University Graduate School Of Medicine, Osaka/JAPAN

**Background:** A 60-year-old man complained of dysphagia. He had undergone esophagectomy for esophageal carcinoma in 1998.

**Methods:** Follow-up endoscopy and CT scanning were performed at regular intervals after the operation.

**Results:** Endoscopic examination only reveals reflux esophagitis in July, 2005, but a smooth elevated lesion with a diameter of 5 mm was detected in the remnant in esophagus in July, 2006. The lesion had increased in diameter to 10 mm and become polypoid by February, 2007.

**Discussion:** Biopsy of the lesion showed hemangioma, and endoscopic polypectomy was performed in the March, 2007. Pathological examination revealed granulation tissue in the stroma with proliferation of dilated capillaries, so the lesion was diagnosed as pyogenic granuloma.

**Disclosure:** All authors have declared no conflicts of interest.

### P08.33 TRANSORAL TREATMENT OF ZENKER DIVERTICULUM: HOW TO IMPROVE THE RESULTS

*Martina Ceolin*, Uberto Fumagalli, Matteo Porta, Ugo Elmore, Lavinia Barbieri, Riccardo Rosati  
*Istituto Clinico Humanitas Irccs, Milan., Rozzano/ITALY*

**Background:** In Transoral diverticulo-esophagostomy an endoscopic stapler is inserted transorally after introduction of a Weerda diverticuloscope; it divides the septum between pouch and esophagus. Postoperative results depend on the completeness of the section of septum. Pulling the septum towards the stapler increases the length of this section and improves the results of the operation.

**Methods:** Aim: To analyze our results in terms of outcome of transoral approach in the treatment of ZD and to evaluate improvement of results by changes in surgical technique

**Results:** 80 patients were scheduled for transoral treatment of ZD, which was completed in 77 of them. 52 patients had a diverticulo-esophagostomy with the application of a modified linear stapler (Group A); in the remaining 25 patients the septum was pulled by means of 2 stay suture positioned on the septum with an Endostich (Group B). In Group A 13 patients (25%) complained persistent dysphagia due to residual spur: 10 patients were treated with flexible endoscopy to complete the levelling of the residual spur; 2 patients underwent second transoral treatment; 1 patient underwent open diverticulectomy. In Group B 2 patients (8%) underwent hook section of the residual septum. At a median clinical FU of 32 months 96% were satisfied and complained no dysphagia

**Discussion:** Transoral treatment of ZD showed good results in terms of hospital stay, symptom reduction and patients' satisfaction, in a few case the results were optimized by complementary treatment. The use of Endostich allowed to obtain a complete section of the septum and symptoms relief without other endoscopic procedure.

**Disclosure:** All authors have declared no conflicts of interest.

### P08.34 SURGICAL THERAPY OF EPIPHRENIC DIVERTICULUM. REVIEW OF THE LITERATURE AND OWN EXPERIENCE

*Christian Gutschow*, Wolfgang Schröder, Jessica Leers, Marc Bludau, Hans Fuchs, Elfriede Bollschweiler, Arnulf Hölischer  
*Department Of General-, Visceral- And Cancer Surgery, University Of Cologne, Cologne/GERMANY*

**Background:** Epiphrenic diverticulum is a rare pathology of the foregut. Surgery is indicated in symptomatic diverticula refractory to conservative measures. A number of different strategies including minimally invasive and open techniques have been recommended to treat symptomatic patients; however, actually there is no general recommendation for a specific procedure or approach.

**Methods:** 24 series with 404 surgical patients were identified by review of the literature from 1992 to 2010. In addition, data from our own series of 12 surgical patients were included. Data were analyzed regarding peri-, and postoperative outcome.

**Results:** Open and minimally invasive surgery (MIS) was used in 273 and 143 patients, respectively; with thoracotomy (63.1%) and laparoscopy (26.9%) being the preferred approaches. Excellent or good symptom control was similar after MIS and open techniques (76–100% and 85–100%, respectively), but mortality was higher after conventional (4.8%) compared with the MIS approach (2.1%). However, total morbidity was higher (28.7% vs 19.0%) owing to increased leakage rates (16.1% vs 7.7%) in MIS compared with conventional surgery.

**Discussion:** Excellent symptomatic outcome can be achieved by both open and MIS techniques. However, careful patient selection is recommended because of a relatively high surgical risk.

**Disclosure:** All authors have declared no conflicts of interest.

## POSTER SESSION P09: PALLIATIVE TREATMENTS – October 17, 2012 12:30–13:30

### P09.01 SALVAGE PHOTODYNAMIC THERAPY IS EFFECTIVE AND SAFE TREATMENT FOR THE PATIENTS WITH LOCAL FAILURE AFTER CHEMORADIOTHERAPY FOR ESOPHAGEAL SQUAMOUS CELL CARCINOMA

*Yoko Mashimo*<sup>1</sup>, Manabu Muto<sup>1</sup>, Kosuke Ueda<sup>1</sup>, Yoshinao Ozaki<sup>1</sup>, Yusuke Amanuma<sup>1</sup>, Takahiro Horimatsu<sup>2</sup>, Shuko Morita<sup>1</sup>, Yasumasa Ezoe<sup>2</sup>, Shin'ichi Miyamoto<sup>2</sup>, Tomonori Yano<sup>3</sup>, Koji Higashino<sup>4</sup>  
<sup>1</sup>Department Of Gastroenterology And Hepatology, Kyoto University Graduate School Of Medicine, Kyoto/JAPAN, <sup>2</sup>Kyoto University Hospital, Kyoto City/JAPAN, <sup>3</sup>National Cancer Center Hospital East, Kashiwa JAPAN, <sup>4</sup>Department Of Gastrointestinal Oncology, Osaka Medical Centre For Cancer And Cardiovascular Diseases, Osaka/JAPAN

**Background:** Definitive Chemoradiotherapy (CRT) is one of the curative treatment options for the patients with esophageal squamous cell carcinoma (ESCC). Local failure after CRT remains a major problem for ESCC patients. The aim of this study was to evaluate the efficacy and the safety of salvage local treatment by photodynamic therapy (PDT).

**Methods:** Salvage PDT was indicated for the patients with local failure after completion of CRT for ESCC. The indications of salvage PDT were as follows: 1) the depth of local failure was estimated to be within T2, 2) patients' refusal or patients' poor physical condition to undergo salvage esophagectomy, 3) written informed consent. PDT was performed using an excimer dye laser at 48 and 72 hours after intravenous administration of Photofrin.

**Results:** From August 2007 to February 2012, 165 consecutive ESCC patients were treated with definitive CRT. Among them, 18 patients (11%) underwent salvage PDT. At the time of salvage PDT, 12 patients were diagnosed as cT1N0M0, 5 were cT2N0M0 and 1 was cT1N1M1 (LYM). The complete response at the primary site was achieved in 10 patients (55.6%). Over a median follow-up period of 19.6 months, the 1-year overall and progression free survival rates were 81.9% and 42.9%, respectively. Adverse events were mild esophageal stricture in 4/18 (22.2%) patients, esophageal obstruction due to necrotic tissue in 8/18 (44.4%) and photosensitivity in 3/18 (16.7%).

**Discussion:** Salvage PDT is an effective and safe treatment option for carefully selected patients with local failure after completion of CRT for ESCC.

**Disclosure:** All authors have declared no conflicts of interest.

### P09.02 RECURRENT OESOPHAGEAL CANCER COMPLICATED BY TRACHEOESOPHAGEAL FISTULA - MANAGEMENT BY MEANS OF PALLIATIVE ENDOSCOPIC STENTING

*Michael Schweigert*<sup>1</sup>, Attila Dubez<sup>1</sup>, Martin Beron<sup>1</sup>, Rudolf J Stadlhuber<sup>1</sup>, Dietmar Oefner-Velano<sup>2</sup>, Hubert J Stein<sup>1</sup>  
<sup>1</sup>Department Of General And Thoracic Surgery, Klinikum Nuernberg Nord, Nürnberg/GERMANY, <sup>2</sup>Department Of Surgery, Paracelsus Medical University Salzburg, Salzburg/AUSTRIA

**Background:** Recurrent-oesophageal-cancer is a crushing condition. Cancer-related fistulization between oesophagus and tracheobronchial tree adds further difficulty. Unless closure of the fistula is achieved, death from pulmonary sepsis is imminent. Surgical options are limited by local tumor growth, previous operations and radiotherapy as well as by impaired functional status. Here endoscopic-stent-insertion might provide a reasonable alternative.

**Methods:** The outcome of patients who received endoscopic-stent-implantation for tracheoesophageal fistula due to recurrent-oesophageal cancer between 2006 and 2011 were reviewed in a retrospective case study. Altogether 7 patients were identified.

**Results:** There were 6 male and one female patient with a median-age of 57.4 years. Successful stent-placement was always feasible. Double stenting of trachea and oesophagus was carried out in 3 cases while insertion of a solitary tracheal or oesophageal stent was performed each in 2 sufferers. Complete closure of the communication between oesophagus and respiratory system was accomplished in all cases by stent-implantation. Mean survival following stent insertion was 77 days (5–162), while one patient is still alive 91 days after placement of a tracheal-stent. Five patients were finally discharged home after adequate oral intake had been achieved. Fatal aspiration pneumonia with respiratory failure occurred in two cases.

**Discussion:** Endoscopic-stent-implantation provides an easy and ubiquitous available technique for closure and palliation of tracheoesophageal fistula caused by recurrent oesophageal cancer. Immediate sealing of the fistula and relieve of symptoms related to aspiration is achieved while hazardous operations are avoided. Therefore, we recommend endoscopic-stent-insertion as

treatment of choice in case of tracheoesophageal fistula caused by recurrent esophageal cancer.

**Disclosure:** All authors have declared no conflicts of interest.

#### P09.03 ESOPHAGEAL STENT FOR ADVANCED ESOPHAGEAL CANCER

Masafumi Konosu, Yusuke Kimura, Takeshi Iwaya, Yuji Akiyama, Hisataka Fujiwara, Satoshi Nishizuka, Hiroyuki Nitta, Kouki Otuka, Masahiro Kashiwaba, Keisuke Koeda, Akira Sasaki, Masaru Mizuno, Go Wakabayashi

*Iwate Medical University, Morioka/JAPAN*

**Background:** Esophageal stenosis and fistulation of the respiratory tract in advanced esophageal cancer can drastically worsen prognosis and quality of life (QOL). In recent years, esophageal self-expandable metal stent insertion has come to be widely used for the purpose of improving QOL in such patients. Here, we examined the outcome of esophageal stent insertion for advanced esophageal cancer performed in our department.

**Methods:** Subjects were 28 esophageal cancer patients who underwent esophageal stent insertion between January, 2000 and November, 2011. Degree of dysphagia improvement, complications from stent insertion and survival period were assessed.

**Results:** The median age was 65 years and all patients were male. The TNM stage was Stage III in 20 patients and Stage IV in 8 patients. The purpose for stent insertion was relief from stenosis in 20 patients and fistula closure in 8 patients. Grade of dysphagia (Neuhaus dysphagia score) improved by the stent insertion: Grade 3.1 on average before and 2.1 after insertion. Complications with insertion were chest pain in 3 patients, reflux symptoms in 1 patient and fatal bleeding in 1 patient. The median survival time was 50 days (day 1 to 213).

**Discussion:** While the stent insertion can provide quick improvement of QOL in patients with advanced stage esophageal cancer, it may result in fatal complications such as bleeding. The stent insertion may therefore be an optional procedure for these patients.

**Disclosure:** All authors have declared no conflicts of interest.

#### P09.04 CLINICAL EFFECT OF ENTERAL NUTRITION BY PERCUTANEOUS ENDOSCOPIC GASTROSTOMY (PEG) DURING THE CHEMORADIOTHERAPY FOR ESOPHAGEAL SQUAMOUS CELL CARCINOMA

Atsushi Takeno, Shigeyuki Tamura, Hirofumi Miki, Shin Nakahira, Rei Suzuki, Ken Nakata, Yutaka Takeda, Takeshi Kato

*Kansairosai Hospital, Hyogo/JAPAN*

**Background:** Patients with esophageal squamous cell carcinoma (ESCC) often have disorder of nutrition caused by obstruction to the passage of food at the beginning of the treatment. An aggressive nutrition therapy is essential to maintain the long-term chemoradiotherapy (CRT). We have placed percutaneous enteral tube systems by endoscopic techniques and introduced enteral nutrition in patients with ESCC scheduled to undergo CRT or radiotherapy (RT). We retrospectively studied the effect of enteral nutrition by PEG during CRT or RT.

**Methods:** Fifty-four patients with ESCC undergoing CRT or RT between 2006 and 2009 in Kansai Rosai Hospital were reviewed retrospectively. They were divided into two groups: 34 patients in PEG group and 20 patients in non-PEG group.

**Results:** Patients' characteristics between two groups including sex, age, location, previous treatment and performance status were not different significantly. In the other hand, depth of primary tumor, availability of oral nutrition and body mass index (BMI) had significant difference. Incidence of hematological toxicity was not different. (PEG group 29% VS non-PEG group 55%) Transitions of albumin, hemoglobin and total lymphocyte count were similar, too. Median survival time was 719 days for PEG group compared with 600 days for non-PEG group. (Log-rank test  $p = 0.88$ )

**Discussion:** Enteral nutrition by PEG during CRT and RT didn't contribute to reduce toxicity and improve the survival. Prospective study is needed to test these observations.

**Disclosure:** All authors have declared no conflicts of interest.

#### P09.05 TREATMENT OUTCOMES AND PROGNOSTIC FACTORS OF THORACIC ESOPHAGEAL CANCER WITH CLINICAL EVIDENCE OF ADJACENT ORGAN INVASION

Yoichi Hamaj, Jun Hihara, Manabu Emi, Yoshiro Aoki, Morihito Okada

*Department Of Surgical Oncology, Research Institute For Radiation Biology And Medicine, Hiroshima University, Hiroshima/JAPAN*

**Background:** We aimed to determine which prognostic factors are involved in the management of locally advanced esophageal cancer with invasion of adjacent organs.

**Methods:** We retrospectively investigated the therapeutic outcomes of 77 patients with thoracic esophageal cancer and clinical evidence of adjacent organ invasion but no distant metastasis. Definitive chemoradiation therapy (CRT) comprised the main treatment for 66 patients. Eight patients with tumors that were reduced after receiving 40 Gy of CRT underwent trans-thoracic esophagectomy, and 3 received radiation therapy.

**Results:** The median survival time (MST) in all patients was 11.5 months, and the 1-, 3-year survival rates were 49.5 and 19.5%, respectively. The MST of patients undergoing definitive CRT and CRT followed by esophagectomy were 11.1 and 16.4 months, respectively, and survival duration did not significantly differ between them ( $p = 0.392$ ). Univariate analysis of prognosis revealed that pre-treatment hemoglobin ( $<13$  vs.  $\geq 13$  g/dL,  $p = 0.046$ ) and serum albumin ( $<3.5$  vs.  $\geq 3.5$  g/dL,  $p = 0.002$ ) levels, as well as tumor length ( $<60$  vs.  $\geq 60$  mm,  $p = 0.032$ ), and clinical response to CRT (CR/PR vs. SD/PD,  $p = 0.004$ ) were significant factors. Multivariate analysis of these factors indicated that serum albumin level (HR, 2.61; 95%CI, 1.36–5.03;  $p = 0.004$ ) and the response to CRT (HR, 2.64; 95%CI, 1.37–5.60;  $p = 0.004$ ) were significant factors affecting survival.

**Discussion:** Our results indicate that not only the effect of CRT but also improved nutritional status prolongs the survival of patients with locally advanced esophageal cancer accompanied by adjacent organ invasion.

**Disclosure:** All authors have declared no conflicts of interest.

#### P09.06 SURVIVAL AFTER RECURRENT ESOPHAGEAL CARCINOMA HAS NOT IMPROVED OVER THE PAST 18 YEARS

Rachel Blom, Kim Van Oudenaarde, Sjoerd Lagarde, Jean Klinkenbijn, Maarten Hulshof, Hanneke Wilmink, Jacques Bergman, Olivier Busch, Mark Van Berge Henegouwen

*Academic Medical Center, Amsterdam/NETHERLANDS*

**Background:** A substantial number of patients will develop recurrent disease after potentially curative esophagectomy for esophageal carcinoma. In the literature, survival after recurrent esophageal carcinoma is 6–8 months if diagnostic imaging is routinely performed during follow-up. In the Netherlands, imaging is not part of standard follow-up. The aim of the present study was to determine survival after diagnosis of recurrent disease in patients after potentially esophagectomy without routine imaging during follow-up.

**Methods:** All esophageal cancer patients who underwent esophagectomy between 1993 and 2010 were followed for evidence of recurrent esophageal carcinoma. Location, symptoms, diagnosis and treatment of recurrent disease were registered in a prospectively monitored database.

**Results:** A total of 493/1088 patients (45%) who underwent potentially curative esophagectomy between 1993 and 2010 developed recurrent disease. Median interval between initial esophagectomy and recurrence was 10.5 months. The majority of patients (51%) was diagnosed with distant metastases located in the liver, bone, or lung (60%). Median survival after diagnosis of recurrent disease was 3 months. When patients were divided into three groups according to year of surgery, there was no difference in median survival after recurrent disease ( $p = 0.931$ ).

**Discussion:** Survival after diagnosis of recurrent esophageal carcinoma in patients who undergo follow-up without routine imaging after esophagectomy is approximately 3 months and has not improved over the past 18 years.

**Disclosure:** All authors have declared no conflicts of interest.

#### P09.07 USEFULNESS OF ULTRAFLEX STENTS SETTING FOR THE MANAGEMENT OF TRACHEBRONCHIAL STENOSES IN ESOPHAGEAL CARCINOMA

T Inoue, Yoshifumi Ikeda, E Ogawam, M Horikawa, T Koide,

Tsuyoshi Inaba, Ryoji Fukushima

*Department Of Surgery, Teikyo University School Of Medicine, Tokyo/JAPAN*

**Background:** Airway stents have gained increasing popularity in the management of challenging tracheobronchial obstruction based on the simplicity of their placement and the lack of good alternative approaches. Careful and judicious stent placement has provided significant and life-saving airway improvement in many patients. We present our experience with the use of the ultraflex stents in the management of airway complications in esophageal carcinoma and analyzed the relationships between survival after tracheobronchial stenting and clinical features.

**Methods:** Twelve patients with esophageal carcinoma underwent placement of ultraflex stents for respiratory distress caused by tracheobronchial invasion. Mean age of the patients was  $62.3 \pm 9.4$  years (range 51–79 years), and there were 10 men and 2 women. All patients had histologically confirmed squamous cell carcinoma of the esophagus. Tumor resection had been performed in 7 patients, curative surgical intervention in 4 and a palliative

operation in 3. Tumor resection had not been performed in 5 patients, bypass surgery in 4 and chemo-radiation therapy in the remaining 1 patient. The sites of stenoses included the trachea in 7 patients, and left main bronchus in 5. The causes of the tracheobronchial stenoses involved primary tumor invasion in 4 patients, mediastinal lymph node invasion in 5, and mediastinal recurrence in 3. The ultraflex stent (wallstent; Boston Scientific, Natick, MA) was placed using flexible bronchoscopy under local anaesthesia and sedation.

**Results:** Since careful and judicious stent placement has provided significant, complications of stent placement was nothing and all patients received chemotherapy after stents insertion. In 2 patients of tracheal stenoses, tracheal intubations carried out by the intensive care unit for complaints of severe respiratory stridor. Another 10 patients had respiratory distress and were admitted to the hospital. After stents insertion, immediate relief of respiratory symptoms was obtained in all patients. The mean survival after stent insertion was  $105 \pm 71$  days. Causes of death were re-obstruction in 2, airway bleeding in 2, and cancer progression in 8. Multivariate analysis in age, gender, treatment degree, tumor resection, the site of stenting and the cause of stenosis revealed that tumor resection and the site of the stenting were the significant and independent risk factor for the survival (P

**Discussion:** Stents setting can immediately improve patients' quality of life and tumor resection and the site of the stenting were the significant and independent risk factor for the survival.

**Disclosure:** All authors have declared no conflicts of interest.

#### P09.08 EFFECTIVENESS OF THE NITI-S™ ESOPHAGEAL STENT PLACED FOR THE TREATMENT OF MALIGNANT ESOPHAGEAL STRICTURE

Yoshihiko Naritaka, Takeshi Shimakawa, Shinichi Asaka, Noriyuki Isohata, Kentaro Yamaguchi, Atsuko Usuda, Minoru Murayama, Takao Katsube, Shunichi Shiozawa, Hajime Yokomizo, Kazuhiko Yoshimatsu, Kenji Ogawa  
*Tokyo Women'S Medical University Medical Center East, Tokyo/JAPAN*

**Background:** Esophageal stent placement has been extensively performed in the treatment of patients with malignant esophageal stricture, yet occasional cases involving difficulty in stent insertion are encountered. We encountered 3 cases in which the Niti-S™ esophageal stent, a new model with improved maneuverability, was used with encouraging results.

**Methods:** Case 1: The hilar lung cancer and its mediastinal lymph node metastasis pressed the esophagus extramurally and caused the marked stenosis. Case 2: A metastatic lymph node along the left laryngeal nerve caused the stenosis of the trachea. A primary esophageal lesion located at the middle esophagus also caused the marked stenosis. At first, trachea stent was placed because of dyspnea, and two weeks later, we placed an esophageal stent. Case 3: Esophageal cancer at lower thoracic esophagus after definitive radiation therapy caused the marked stenosis. Because of the stenosis of esophago-gastric junction, We used an esophageal stent with a long cover in order to prevent a reflux into the esophagus.

**Results:** The Niti-S™ stent is characterized by easy insertion and well maintained indwelling, even in patients with marked stricture, due to an external delivery system diameter as small as 16.5 F. We inserted the stent within 15 minutes, and the symptom of stricture was improved immediately for each cases.

**Discussion:** Therefore, the newly developed indwelling Niti-S™ esophageal stent could be easily inserted and satisfactorily immobilized in the current patients, who presented with marked stricture which had until then been controlled with difficulty using conventional devices. The Niti-S™ will likely become widely used for esophageal intubation in the future.

**Disclosure:** All authors have declared no conflicts of interest.

#### P09.09 EXAMINATION OF UTILITY IN PATIENTS OF ADVANCED OR RECURRENT SQUAMOUS CELL ESOPHAGEAL CANCER TREATED WITH DOCETAXEL, CISPLATIN, AND FLUOROURACIL (DCF)

Takayuki Kij<sup>1</sup>, Hiroya Takiuchi<sup>1</sup>, Masahiro Gotoh<sup>1</sup>, Motoki Yoshida<sup>1</sup>, Hitoshi Nishitani<sup>1</sup>, Shin Kuwakado<sup>1</sup>, Kazuhide Higuchi<sup>2</sup>  
<sup>1</sup>Department Of Cancer Chemotherapy Center, Osaka Medical College, Osaka/JAPAN, <sup>2</sup>2nd Department Of Internal Medicine, Osaka Medical College, Osaka/JAPAN

**Background:** Chemotherapy, the combination of cisplatin and 5-fluorouracil (5-FU), is demonstrating a response rate of 36% for esophageal cancer. To evaluate the safety and efficacy of using docetaxel, cisplatin, and fluorouracil (DCF) in patients with advanced or recurrent esophageal cancer.

**Methods:** The subjects were 19 patients (18 males and 1 females: median age 60 years). 19 patients fulfilled the following criteria: Those who were histologically confirmed to have squamous cell carcinoma of the esophagus and

those in stage IV(UICC) or recurrent. Chemotherapy using DCF was performed as the treatment, adequate organ functions, bone marrow, liver, and renal, and ECOG performance status (PS) 0-2. Chemotherapy using DCF was performed, the patients who were evaluated for response rate and were evaluated for the progression free survival and the overall survival, and the toxicity profiles of treatment.

**Results:** The 19 patients consisted of 18 males and 1 females with a median age of 60 years. Response rate was 57.8% by RECIST criteria. Disease control rate was 89.4%. Grade 3 or 4 adverse events included leukopenia in 7 (36.8%) patients, neutropenia in 9 (47.3%), anemia in 2 (10.5%), anorexia in 8(42%), AST in 4(21%), ALT in 3(15.7%), hyponatremia in 1(5%), encephalopathy with hyperammonemia in 1(5%), nausea in 1(5%), and CRE in 1(5%). Median PFS was 165 days and Median overall survival was 287 days from the start of using DCF.

**Discussion:** Chemotherapy using DCF was achieved a good response rate and disease control rate, and acceptable overall survival considering the squamous cell esophageal cancer patient population.

**Disclosure:** All authors have declared no conflicts of interest.

#### P09.10 TRITERPENES AUGMENT THE INHIBITORY EFFECTS OF ANTICANCER DRUGS ON GROWTH OF HUMAN ESOPHAGEAL CARCINOMA CELLS IN VITRO AND SUPPRESS EXPERIMENTAL METASTASIS IN VIVO.

Hirofumi Yamai<sup>1</sup>, Yota Yamamoto<sup>2</sup>, Yoshihito Furukita<sup>2</sup>, Junichi Seike<sup>2</sup>, Akira Tangoku<sup>2</sup>

<sup>1</sup>Department Of Surgery, Kochi Red Cross Hospital, Kochi/JAPAN,

<sup>2</sup>Department Of Thoracic, Endocrine Surgery And Oncology, Tokushima University Hospital, Kuramoto, Tokushima/JAPAN

**Background:** Treatment of recurrent esophageal cancer is still difficult and new therapeutic methods are needed. Recent studies have shown that triterpenes have anti-neoplastic effects and to reinforce the activity of anticancer drugs against several tumor cell lines. It is expected that some supplements will enhance the inhibitory effects of anticancer drugs on esophageal squamous carcinoma cells.

**Methods:** The anti-neoplastic effects of combinations of anticancer drugs (5-fluorouracil, irinotecan and cisplatin) and triterpenes (ursolic acid, betulinic acid, oleanolic acid and a Japanese apricot extract (JAE) containing triterpenes) on esophageal squamous carcinoma cells were examined by the WST-8 assay in vitro and in vivo.

**Results:** Triterpenes and JAE showed additive and synergistic cytotoxic effects, respectively, on esophageal squamous carcinoma cells (YES-2cells) by combinational use of 5-fluorouracil. JAE and 5-fluorouracil induced cell cycle arrest at G2/M phase and at S phase, respectively, and caused apoptosis in YES-2 cells. A new animal model of esophageal cancer causing tumor colonization of the peritoneal cavity and producing bloody ascites was made by injecting YES-2 cells into the peritoneal cavity of a SCID mouse. In this model, 5-fluorouracil inhibited colonization of tumor cells in the peritoneum. The addition of JAE to 5-fluorouracil augmented the suppression of experimental metastasis of the peritoneum. The numbers of peritoneal nodules of more than 2 mm in diameter in mice treated with 5-fluorouracil and JAE were less than those in mice treated with 5-fluorouracil alone or JAE alone.

**Discussion:** These results suggest that triterpenes are effective supplements for enhancing the chemotherapeutic effect of 5-fluorouracil on esophageal cancer.

**Disclosure:** All authors have declared no conflicts of interest.

#### P09.11 PALLIATIVE INTERVENTIONS FOR ADVANCED OR RECURRENT ESOPHAGEAL CARCINOMA

Tomoyuki Kakuta<sup>1</sup>, Shin-ichi Kosugi<sup>1</sup>, Takashi Ishikawa<sup>1</sup>, Ryuta Sasamoto<sup>2</sup>, Kazuhito Yajima<sup>1</sup>, Tatsuo Kanda<sup>1</sup>, Katsuyoshi Hatakeyama<sup>1</sup>  
<sup>1</sup>Division Of Digestive And General Surgery, Niigata University Graduate School Of Medical And Dental Sciences, Niigata/JAPAN, <sup>2</sup>Division Of Radiation Oncology, Niigata University Graduate School Of Medical And Dental Sciences, Niigata/JAPAN

**Background:** The aim of this study was to assess the safety and efficacy of palliative interventions for patients with advanced or recurrent esophageal carcinoma.

**Methods:** A total of 107 patients with esophageal carcinoma who underwent palliative interventions from 1997 to 2011 were enrolled. Insertion of a self-expandable metallic stent (SEMS), tube enterostomy for enteral nutrition (EN), and palliative esophagectomy (PE) were performed in 31, 49, and 27 patients, respectively. Clinicopathological characteristics, short- and long-term outcomes of each group were retrospectively reviewed.

**Results:** Intervention-related complications occurred in 22.6% of the SEMS group, 10.2% of the EN group, and 96.3% of the PE group. The hospital

mortality rate of the PE group was 29.6%. Median dysphagia score (MDS) before SEMS insertion was 3, and decreased to 1 after insertion; MDS was not significantly improved after PE. Chemo- and/or radiotherapy were added in 32.3% of the SEMS group, 75.5% of the EN group, and 33.3% of the PE group. The median survival times after intervention were 111 days, 196 days, and 219 days, respectively ( $P = 0.0018$ ). The mean ratios of home care time to survival time were 0.37, 0.38, and 0.37, respectively.

**Discussion:** For patients with advanced or recurrent esophageal carcinoma, PE is unacceptable because of its high invasiveness and relative ineffectiveness. Tube enterostomy combined with additional treatment may have the potential to improve the prognosis. SEMS insertion appeared to be useful for palliation of dysphagia.

**Disclosure:** All authors have declared no conflicts of interest.

#### P09.12 SURGICAL PALLIATION WITH AN ISOPERISTALTIC GASTRIC TUBE FOR BYPASS OF UNRESECTABLE MALIGNANT ESOPHAGEAL OBSTRUCTION

Yoshihiro Nabeya, Matsuo Nagata, Takumi Ota, Nobuhiro Takiguchi, Atsushi Ikeda, Osamu Kainuma, Hiroaki Souda, Akihiro Cho, Seongjin Park, Hidehito Arimitsu, Hiroshi Yamamoto  
*Chiba Cancer Center, Chiba/JAPAN*

**Background:** Little is known about the efficacy of surgical intervention for malignant esophageal obstruction (MEO) in patients with unresectable cancer.

**Methods:** We reviewed 26 patients (male/female = 21/5; mean 63 years) who underwent esophageal bypass with an isoperistaltic, greater curvature gastric tube (modified technique of Postlethwait's method, retrosternal/antesternal = 15/11) for inoperable MEO (esophageal carcinoma/others = 22/4) between 1993 and 2010. All patients received catheter jejunostomy, and were followed up for >1 year. Short/long-term outcomes after surgery were evaluated in terms of the following clinicopathological status: age, gender, histopathology, cTNM, location and length of tumor (stenosis), history of CRT, duration of preoperative complaints, bronchoesophageal fistula, bleeding, and intraoperative blood transfusion.

**Results:** (1) Although five patients (19%) developed anastomotic leakage, oral intake was eventually restored in 25 patients (96%) by POD 7–46 (median = POD 11). While no patient died within 30 days after operation, nine patients failed to survive the operation without discharge. The other 17 patients left hospital on POD 15–120 (median = 38). No variable examined was found to be significantly associated with morbidity. (2) The median survival time of all 26 patients was 5.4 months, and six patients (including an 8-year survivor) have survived >1 year. Statistical analyses revealed that age <60 years old or tumor bleeding statistically appeared to be a poor prognosticator, though the significance was marginal ( $P = 0.06$  and  $0.09$ , respectively).

**Discussion:** Surgical intervention may be considered to restore the QOL in patients with MEO, while the morbidity rate and the prognosis in younger patients with bleeding have yet to be improved.

**Disclosure:** All authors have declared no conflicts of interest.

#### P09.13 PHASE II STUDY OF CONCURRENT ELECTIVE LYMPH NODE ACCELERATED HYPER-FRACTIONATED RADIOTHERAPY AND CISPLATIN-BASED CHEMOTHERAPY FOR ESOPHAGEAL SQUAMOUS CELL CARCINOMA

Baosheng Li, Dongqing Wang  
*Shandong Cancer Hospital, Jinan/CHINA*

**Background:** To improve survival and local control (LC) of esophageal squamous cell carcinoma (ESCC), phase II study on elective lymph node irradiation (ENI) late course accelerated hyper-fractionated radiotherapy (LCAHRT) combined with concurrent chemotherapy (CHT) was performed.

**Methods:** Total 68 ESCC patients were recruited. The first course of radiation covered the primary lesion, regional metastatic and high risk lymph node (LN), 2 Gy/fraction, 5 days a week for a dose of 40 Gy. In the second course, LCAHRT was delivered to the primary tumor and regional metastatic LN, twice a day for an additional 19.6 Gy in 1.4 Gy/fraction. The total delivered dose was 59.6 Gy/34 fractions. Two cycles of cisplatin-based chemotherapy were given concurrently.

**Results:** According to the AJCC staging, there was 15 (22.1%) patients in stage II, 30 (44.1%) in III, and 23 (33.8%) in IVa. The median overall survival (OS) was 34.4 months (95% CI 19.1–49.6 months) with the 1-, 3-, 5-year OS were 75.5%, 46.5%, 22.7%, respectively. The 1-, 3-, 5-year LC were 83.0%, 67.2%, 50.2%, respectively. For patients with stage II–III, the 1-, 3-, and 5-year OS were 78.6%, 49.4%, and 39.9%, whereas 68.3%, 41.0%, and 15.4% for stage IVa ones. The most frequent acute high-grade ( $\geq 3$ ) toxicities were esophagitis (26.4%) and leucopenia (32.4%). Serious pulmonary fibrosis

(1.5%) and esophageal stenosis (1.5%) were infrequent, however, gastrointestinal hemorrhage (5.9%) and esophagus perforation (7.4%) were relatively higher.

**Discussion:** Concurrent ENI LCAHRT and CHT was tolerated and yielded favorable survival and locoregional control. However, the acute toxicity and late complication should be aware.

**Disclosure:** All authors have declared no conflicts of interest.

#### P09.14 CONCURRENT CHEMO-RADIOTHERAPY WITH WEEKLY LOW DOSE DOCETAXEL FOR ESOPHAGEAL CANCER PATIENTS

Koji Nakai, Takashi Ozaki, Masanori Yamada, Junichi Fukui, Hiromi Mukaide, Tatsuya Kanbara, Taku Michiura, Songtae Kim, Kentaro Inoue, Keigo Yamamichi, Yasushi Nakane, A-hon Kwon  
*Department Of Surgery, Kansai Medical University, Moriguchi/JAPAN*

**Background:** Concurrent chemo-radiotherapy with 5-FU and CDDP (FP) for esophageal squamous cell carcinoma (SCC) is common. However, the treatment with FP combined chemotherapy has a problem against renal dysfunction, high ages and low grade performance state (PS) cases. Docetaxel (DOC), which is a new generation of chemotherapeutic agent, has been reported to have an increased radio-sensitivity for SCC at head and neck. In this study, we evaluated the effects of concurrent chemo-radiotherapy with low dose DOC for esophageal SCC.

**Methods:** Among eleven cases of chemo-radiotherapy with DOC, 7 cases were at the first medical examination, 2 cases were down levels of PS after underwent to neo-adjuvant chemotherapy with FP, and 2 cases were recurrence after FP treatment. In the case of first medical examination, 4 cases were PS 3 or 4, and 3 cases were renal failure, heart failure and Stage IVb, respectively. Patients received radiation (2 Gy/day, 5 days per week and 6 weeks, total 60 Gy) and DOC administration (10 mg/m<sup>2</sup>, once per week for 6 consecutive weeks).

**Results:** There were 4 cases of CR, 3 cases PR and 2 cases of PD, resulting in 77.8% of the overall response rate. There were no observations for severe grade 3 or over adverse effects. Two cases were the death of patients before evaluation due to interstitial pneumonia and aspiration pneumonia, respectively.

**Discussion:** Results demonstrated that chemo-radiotherapy with low dose DOC can be feasible with a high response rate and low toxicity, indicating that DOC is a radiation sensitizer for esophageal SCC patients.

**Disclosure:** All authors have declared no conflicts of interest.

#### P09.15 AIRWAY STENTING FOR MALIGNANT AIRWAY OBSTRUCTION.

Takeshi Nagahama, Katsunori Ami, Masayuki Andou, Kuniyoshi Arai  
*Dept. Of Surgery, Toshima Hospital, Tokyo/JAPAN*

**Background:** Airway obstruction due to esophageal malignancy is urgent situation that need immediate treatment. In most cases additional multidisciplinary treatment is essential. We have evaluated the result of airway stent for malignant airway obstruction.

**Methods:** From 2008 three cases of esophageal cancer and one case of malignant lymphoma with airway obstruction were treated by tracheal stent. Retrospective evaluation for stenting and additional treatment was carried out.

**Results:** Two patients with esophageal cancer and one patient with malignant lymphoma were primary cases and the other esophageal cancer was recurrent case. Three patients demonstrated progressive dyspnea due to airway obstruction and the other complained of dysphagia with mild dyspnea. All patient were treated by non-covered Ultraflex tracheal stent. After insertion of airway stent, the patient's dyspnea was improved immediately. Two patients with esophageal cancer received adjuvant chemo-radiotherapy and other two patients received adjuvant chemotherapy. One patient with recurrent esophageal cancer is surviving 4 years after chemo-radiotherapy without recurrence. Another patient with primary esophageal cancer has died of cancer two years after initial chemo-radiotherapy. One patient with primary esophageal cancer resistant to chemotherapy has died of cancer and one patient with malignant lymphoma is still receiving chemotherapy.

**Discussion:** Airway obstruction due to malignancy is urgent situation needed multidisciplinary treatment. Airway stenting could successfully relief serious dyspnea and afford time to receive multidisciplinary treatment. Chemo radiation after stenting for esophageal stricture is still controversial due to serious adverse event, however for our patients additional treatment after tracheal stenting could be successfully carried out.

**Disclosure:** All authors have declared no conflicts of interest.

#### P09.16 MALIGNANT GASTRO-TRACHEAL FISTULA FOLLOWING ESOPHAGECTOMY

Alessandra Criscione, Damiano Calvo, Giuseppina Pulvirenti, Marcello Migliore  
*Thoracic Surgery, Dept Surgery, University Of Catania, Catania/ITALY*

**Background:** Gastro-tracheal fistula is a very uncommon complication of esophagectomy. Reports in the literature are few. Life expectancy in patients with malignant GTF is, at best, poor. We report a patient with late presentation of a gastrotracheal fistula following esophagectomy for cancer.

**Methods:** A 43 year-old-male patient with a middle-third esophageal carcinoma was treated using a transhiatal approach. Two years postoperatively, the patient developed dysphagia, and the CT demonstrated a right paratracheal mass. General condition deteriorated, another CT-scan demonstrated pneumo-mediastinum with a gastro-tracheal fistula, which was confirmed with gastrographin swallow and bronchoscopy. The patient was admitted in poor general condition with bilateral pneumonia, and was operated upon by endoscopic stent placement. The fistula was identified using the bronchoscope, and a 18 × 40 mm AERO stent was deployed into the trachea. A postoperative X-ray showed the correct position of the stent.

**Results:** The day after the procedure, the patient presented no respiratory or swallowing impairment. An esophagogram demonstrated the complete closure the gastrotracheal fistula. The patient continued to be treated with appropriate antibiotics, according to culture sensitivity, and antiulcer therapy. On the 3<sup>rd</sup> postoperative day, the patient was allowed to eat an oral diet, and was discharged. The patient was monitored with esophagograms, fiberoptic bronchoscopy and chest CT-scans. The successful closure of the gastrotracheal fistula was confirmed.

**Discussion:** The successful closure of the gastrotracheal fistula was confirmed. The patient remained asymptomatic maintaining an oral feeding until he died, 4 months after the placement of the tracheal device. The cause of death was malignant cachexia.

**Disclosure:** All authors have declared no conflicts of interest.

#### P09.17 EVALUATION OF AN INFLAMMATION-BASED PROGNOSTIC SCORE (GPS) IN PATIENTS WITH UNRESECTABLE ADVANCED ESOPHAGEAL CARCINOMA UNDERGOING DEFINITIVE CHEMORADIOTHERAPY (CRT)

Kazuhiro Nishikawa<sup>1</sup>, Kazuhiro Iwase<sup>1</sup>, Junji Kawada<sup>1</sup>, Tsuyoshi Takahashi<sup>2</sup>, Toyokazu Aono<sup>1</sup>, Shinichi Takeda<sup>1</sup>, Hiroshi Yoshida<sup>1</sup>, Masaya Nomura<sup>1</sup>, Hiroshi Tamagawa<sup>1</sup>, Kenichi Omori<sup>1</sup>, Chu Matsuda<sup>1</sup>, Takashi Deguchi<sup>1</sup>, Hirokazu Sawami<sup>1</sup>, Shigeyoshi Higashi<sup>1</sup>, Satoshi Umeda<sup>1</sup>, Koichi Deguchi<sup>1</sup>, Shigetoshi Shimamoto<sup>1</sup>, Shunji Endo<sup>3</sup>, Yasuhiro Tanaka<sup>1</sup>  
<sup>1</sup>*Osaka General Medical Center, Osaka/JAPAN*, <sup>2</sup>*Department Of Gastroenterological Surgery, Graduate School Of Medicine, Osaka University, Suita, Osaka/JAPAN*, <sup>3</sup>*Higashiosaka City General Hospital, Higashiosaka/JAPAN*

**Background:** The aim of the study was to examine the value of the combination of an elevated C-reactive protein and hypoalbuminaemia (Glasgow Prognostic Score: GPS) in predicting survival after definitive chemoradiotherapy (CRT) for unresectable advanced esophageal carcinoma.

**Methods:** The 90 first-onset unresectable advanced esophageal carcinoma cases were subjects. The GPS was constructed as follows: Patients with both an elevated C-reactive protein (>10 mg/l) and hypoalbuminaemia (<35 g/l) were allocated a score of 2. Patients in whom only one or none of these biochemical abnormalities was present were allocated a score of 1 or 0, respectively. Overall survival curves were constructed using the Kaplan-Meier method, and were compared using log-rank tests. The hazard ratio (HR) estimated by Cox regression models.

**Results:** GPS0-1 cases (n = 63, MST: 499D) demonstrated the better survival benefit than GPS2 cases (n = 27, MST: 222D) (p = 0.0041). On univariate analysis of those patients with unresectable advanced esophageal carcinoma, the GPS (p = 0.0083) was significantly associated with overall survival.

**Discussion:** The results of the present study indicate that the GPS, before treatment, predicts overall survival after definitive CRT for unresectable advanced esophageal carcinoma.

**Disclosure:** All authors have declared no conflicts of interest.

#### P09.18 BRAIN METASTASES AFTER ESOPHAGECTOMY FOR ESOPHAGEAL CARCINOMA

Takuya Sato, Masaho Ota, Kosuke Narumiya, Kenji Kudo, Yuji Shirai, Shin Yamamoto, Harushi Osugi, Masakazu Yamamoto  
*Institute Of Gastroenterology, Tokyo Women'S Medical University, Tokyo/JAPAN*

**Background:** Brain metastases after surgery for esophageal cancer are rare and information regarding the natural history is limited.

**Methods:** Between 1992 and 2012, 1077 patient underwent surgery for esophageal cancer at Tokyo Women's Medical University, of those, 9 patients (0.84%) had a diagnosis of brain metastasis after surgery. We collected clinical data and performed a retrospective review.

**Results:** As for pathological stage of primary esophageal cancer, there were stage I in 1 patients, stage II in 1 patients, stage III in 5 patients, and stage IVa in 2 patients. Tumor histologies were adenocarcinoma in 2 patients, squamous cell carcinoma in 6 patients, and undifferentiated carcinoma in 1 patient. The median duration from esophagectomy to a diagnosis of brain metastasis was 212 days (40-555days). All patients experienced symptoms of central nerve system when given a diagnosis of brain metastasis. The average size of brain metastases was 3.6 cm. There were 4 patients with single brain lesion and 4 patients with multiple brain lesions. The metastases were treated with whole-brain radiation therapy in 2 patients, knife in 6 patients, radiation therapy in 2 patients and operation in 3 patients. The median survival after a diagnosis of brain metastasis was 155 days (48-540days). All 3 patients who underwent operation survived more than 155 days.

**Discussion:** It might be better to perform CT or MRI taking into consideration of the possibility of brain metastasis when symptoms of central nerve system are seen after esophagectomy.

**Disclosure:** All authors have declared no conflicts of interest.

#### P09.19 PLASMA GLUTATHIONE RESPONSES TO B-VITAMINS SUPPLEMENTATION IN AESOPHAGEAL-CANCER PATIENTS

Maria Aparecida Henry<sup>1</sup>, Vânia Lamônica<sup>2</sup>, Fernando Moreto<sup>1</sup>, Roberto C Burini<sup>1</sup>

<sup>1</sup>*School Of Medicine - Botucatu - Unesp, Botucatu/BRAZIL*, <sup>2</sup>*Universidade Paulista - Unip, Baurul/BRAZIL*

**Background:** Premature death of patients with esophageal cancer (AC) is associated with higher concentrations of plasma total GSH and lower lymphocytes counts as shown previously. With the aim to investigate further this variation we studied the evolution of AC patients receiving B-vitamin related to the GSH synthesis pathway.

**Methods:** The study involved 9 men with TNM grade E-III (n = 4) and E-IV (n = 5) assessed at baseline and after 2 weeks of intervention receiving either B-vitamin (10 ml) or placebo (syrup sugar) in a cross over design. The assessments included anthropometry (and BMI calculation), blood hematology and plasma biochemistry including malondialdehyde and glutathione (GSH and GSSG). Statistical comparisons were made by ANOVA and Student's t-paired tests.

**Results:** At baseline patients were eutrophic, normoalbuminemic, normolipidaemic, with normal HOMA-IR, normal leukocytes and lymphocytes counts and presenting high C-reactive protein (CRP; >0.6 g/L). Interventions with either placebo or vitamins resulted in significant increasing of body weight and urea. The vitamin group responded differently from placebo by increasing HDL-cholesterol and leukocytes and decreasing lymphocytes. However, there were no changes in CRP, malondialdehyde and glutathione parameters.

**Discussion:** These preliminary data suggest minor effects of these doses of vitamins supplementation on the improving of GSSG/GSH relationship in this sample of patients.

**Disclosure:** All authors have declared no conflicts of interest.

#### P09.20 EFFICACY AND SAFETY OF COMBINED DOCETAXEL AND NEDAPLATIN AS SECOND-LINE CHEMOTHERAPY IN PATIENTS WITH ADVANCED ESOPHAGEAL CANCER

Akitoshi Kimura, Hitoshi Kawasaki, Naoki Wajima, Makoto Nakai, Kenichi Hakamada

*Graduate School Of Medicine, Hirosaki University, Aomori/JAPAN*

**Background:** Although chemotherapy using cisplatin (CDDP) and 5-fluorouracil (5-FU) is the standard treatment for unresectable locally advanced esophageal cancer, there is no standard regimen for second line chemotherapy after a failure of first-line regimen. This study evaluated efficacy and safety of combined docetaxel (TXT) and nedaplatin (CDGP) as a second-line regimen.

**Methods:** Between 2008 and 2011, 18 patients with metastasis or local recurrence of esophageal cancer treated with biweekly TXT 30 mg/m<sup>2</sup> and CDGP 40 mg/m<sup>2</sup>. Eleven patients treated with radiotherapy. Response was evaluated two every cycle. Most of patients received this regimen in the outpatient chemotherapy room.

**Results:** The patients received a median of 9 cycles of treatment (4-30 cycles). Response rate was 22.2%. Median time to progression and median survival time were 8.3 and 8.5 months. Neutropenia and anemia of grade3 were seen in 10 (56%) and 7 (39%) patients. Furthermore, no severe nonhematological adverse events or treatment-related death were observed.

**Discussion:** The combination chemotherapy of TXT plus CDGP in the outpatient setting is well tolerated and might be a useful as second-line chemotherapy for advanced esophageal cancer.

**Disclosure:** All authors have declared no conflicts of interest.

#### P09.21 MID-TERM RESULTS OF PHOTODYNAMIC THERAPY FOR EARLY ESOPHAGEAL SQUAMOUS CELL CANCER

Hee Chul Yang, Jung-moon Lee, Wonsuk Choi, In-hag Song, Sukki Cho, Kwahnmien Kim, Sanghoon Jheon  
*Seoul National University Bundang Hospital, Seongnam-sil KOREA*

**Background:** Photodynamic therapy (PDT) for early neoplastic lesions arising in esophagus is being accepted as an attractive alternative to surgical esophagectomy. However, its indications and efficacy remain uncertain. The aim of this study was to evaluate the feasibility of PDT in the patients with early esophageal squamous cell cancer.

**Methods:** Between April 2005 and June 2011, 16 patients diagnosed with esophageal squamous cell carcinoma underwent PDT with curative intent. Indications for esophageal PDT were clinical T1N0M0 lesion in 14 patients, local recurrence after Ivor Lewis operation in 1 patient and remnant tumor in resection margin after endomucosal resection (EMR) in 1 patient. Follow-up endoscopy was performed after 2–3 days to confirm the lesion and remove the necrotic tissue. After discharge, recurrence or stenosis was regularly checked through endoscopic examination.

**Results:** The median age of patients was 63 years (range: 45–80 years). Complete remission was achieved in 12 patients (75%), who had a median follow-up of 23 months (range: 9–64 months) and no recurrence during the period. Four patients who had residual tumor could be confirmed within mean 1.7 months and subsequently underwent EMR (n = 1), surgical esophagectomy (n = 2), and radiotherapy (n = 1). Esophageal stricture after PDT occurred in 3 patients (18.8%), who received balloon dilatation or bougienation. There were no other complications such as esophageal perforation or photosensitivity.

**Discussion:** PDT in early esophageal squamous cell cancer can achieve long disease-free survival as a viable alternative, especially for poor candidates of surgery or endoscopic resection.

**Disclosure:** All authors have declared no conflicts of interest.

#### P09.22 GLASGOW PROGNOSTIC SCORE (GPS) IS AN INDEPENDENT PROGNOSTIC FACTOR IN ADVANCED ESOPHAGEAL CANCER PATIENTS TREATED WITH SECOND-LINE CHEMOTHERAPY.

Ryohei Kawabata, Hiroshi Imamura, Tomono Kishimoto, Hiroyoshi Takemoto, Mutsumi Fukunaga  
*Sakai Municipal Hospital, Sakai JAPAN*

**Background:** Since metastatic esophageal cancer is an incurable disease, the goals for chemotherapy are to palliate symptoms and improve survival. Although most patients with metastatic esophageal cancer will develop progressive disease following front-line chemotherapy, it remains uncertain who is a candidate for second-line chemotherapy. In this study, we evaluated the prognostic significance of clinical factors in advanced esophageal cancer patients treated with second line chemotherapy.

**Methods:** 30 patients treated with the second-line combination therapy using docetaxel and nedaplatin at our hospital between 2005 and 2009 were enrolled in this study. Background characteristics of these patients were analyzed as prognostic factors.

**Results:** The median age was 68 years (range: 54–89 years), with 23 men and 7 women. The majority of the patients (93.3%) had ECOG performance status of either 0 or 1. All patients were histologically diagnosed with squamous cell carcinoma. Initial therapy for metastasis/recurrence consisted of standard 5-FU plus cisplatin chemotherapy (46.6%) or chemoradiotherapy (53.3%). Seven patients (23.3%) had an elevated C-reactive protein concentration with hypoalbuminemia (GPS: 2). The univariate analysis and multivariate regression analysis indicated that GPS of 2 was an independent negative prognostic factor for overall survival. (p = 0.0006, hazard ratio: 30.87, 95%CI: 4.38–217.65)

**Discussion:** The Glasgow prognostic score was an important and independent prognostic factor in advanced esophageal cancer patients treated with second-line chemotherapy.

**Disclosure:** All authors have declared no conflicts of interest.

#### P09.23 ROLE OF 99MTC-SUCRALFATE SCANNING IN CARCINOMA OF THE OESOPHAGUS

Vinay Sharma  
*Charlotte Maxeke Johannesburg Academic Hospital, University Of Witwatersrand, Johannesburg SOUTH AFRICA*

**Background:** Background: The confirmation of the presence of ulceration in the oesophagus due to malignancy has value for both diagnosis and management. Presently, endoscopy is the gold standard for assessment of ulceration.

**Methods:** Material and methods: Ninety patients of Carcinoma oesophagus were included in the study between 2007 and 2010. The site of lesion was middle third in 39 (43%). The length of lesion was 5–10 cm in 54 (60%) patients. Twenty-one (23%) had Ulcerative lesions on endoscopy. All patients had a 99 m Tc –Sucralfate scan prior to treatment. The patients were asked to drink a 10 ml suspension of 99 m Tc –Sucralfate and Dynamic images taken for 60 seconds. Sequential images of the oesophagus were acquired at 2 minutes, 2 hours and 4 hours following ingestion. Aim: To test the sensitivity and positive predictive value of a 99 mTc – Sucralfate scan in delineating ulceration in the oesophagus before treatment and during the follow up period and Whether it could reduce the need for invasive endoscopic procedures in patients with cancer of oesophagus.

**Results:** Results –78 of 90(87%) had increased uptake on both dynamic and static images. The site of uptake correlated in 68 of 90(76%) patients with lesions seen on barium swallows and Endoscopy. The Sensitivity, Specificity, Positive Predictive value and Negative predictive value were 100% and 6.8%, 20.5% and 100% respectively.

**Discussion:** Conclusion: The technique is non invasive, simple to perform and well tolerated by patients. The low positive predictive value does NOT support the use of sucralfate tagging to replace endoscopy in the assessment of ulceration at present.

**Disclosure:** All authors have declared no conflicts of interest.

#### POSTER SESSION P10: NEW DIAGNOSTIC MODALITIES FOR ESOPHAGEAL CANCER – October 17, 2012 12:30 – 13:30

##### P10.01 THE PRESENT SITUATION OF EARLY ESOPHAGEAL CANCER TREATMENT OF HAKODATE DISTRICT

Masanori Ohara, Jyun Konno, Hiromi Hirata, Masaaki Yamasiro  
*National Hakodate Hospital, Hakodate JAPAN*

**Background:** Discovery frequency of early esophageal cancer increases and is enlarging endoscopic therapeutic adaptation technically. We investigated it about the number of the discovery, therapy of early esophageal cancer of 2010 in Hakodate that was a Japanese standard local city.

**Methods:** When Hakodate-city includes periphery with a population of about 300,000, it forms about 400,000 medical circle. We performed questionnaire survey in five hospitals which enforced endoscopic submucosal dissection (ESD). It was assumed that a definition of early esophageal cancer was limited to mucosa. We assumed age, sex, discovery methods, lesion, pathological findings at therapy, a complication an investigation item.

**Results:** Early esophageal cancer was 29 patients, and the esophageal cancer total number was 140 patients. 22 patients were male and 7 patients were female. All cases were discovered with endoscopic examination. Iodine stain was also used in 16 cases, and NBI endoscopy was used in 12 cases. The therapy enforced EMR for 7 cases, ESD for 13 cases, APC for one case, surgery for 5 cases, radiation for one case and follow-up for 2 cases. Complication after ESD were seen in 3 cases (perforation in one, severe stricture in one and mediastinal emphysema in one)

**Discussion:** Treatment mainly on endoscopic treatment was performed at about 90% by a diagnosis of mucosal cancer. On the other hand, operation was performed at about 10 % by overinterpretation. a case to become follow-up was present without starting treatment with a super senior patients immediately. NBI endoscopy and iodine stain were useful in early diagnosis.

**Disclosure:** All authors have declared no conflicts of interest.

##### P10.02 PROGNOSTIC SIGNIFICANCE OF IL-6 EXPRESSION IN CANCER CELLS IN PATIENTS WITH ADVANCED ESOPHAGEAL CANCER.

Masayuki Yoneda, Hitoshi Fujiwara, Atsushi Shiozaki, Akinobu Furutani, Shuhei Komatsu, Daisuke Ichikawa, Kazuma Okamoto, Yukihito Kokuba, Eigo Otsuji  
*Division Of Digestive Surgery, Department Of Surgery, Kyoto Prefectural University Of Medicine, Kyoto JAPAN*

**Background:** IL-6 expression in serum has been shown to be associated with tumor progression and prognosis in patients with esophageal cancer. The



purpose of this study was to clarify the relationship between IL-6 expression in cancer cells and prognosis in patients with advanced esophageal cancer with special interest in possible influence of chemoradiotherapy on IL-6 expression in cancer cells.

**Methods:** Thirty-five patients with clinical T3 or T4 esophageal squamous cell carcinoma (ESCC) who underwent induction chemoradiotherapy followed by esophagectomy (CRT group) and 27 patients with clinical T3 or T4 ESCC who underwent surgery without any preoperative therapies (Surgery group) between 2000 and 2010, were analyzed in this study. IL-6 expression in cancer cells in the resected tumor specimens was evaluated by immunohistochemical staining.

**Results:** IL-6-positive cancer cells were detected with the incidence of 37% and 25% in the resected tumor specimens of CRT group and surgery group, respectively. IL-6-positive group showed poor prognosis compared with IL-6-negative group in CRT group ( $p = 0.005$ ), whereas no significant difference was observed in surgery group ( $p = 0.0057$ ).

**Discussion:** Our results suggest that IL-6 expression in cancer cells may play a role in poor prognosis in close association with resistance to chemoradiotherapy in patients with advanced esophageal cancer.

**Disclosure:** All authors have declared no conflicts of interest.

#### P10.03 CLINICAL UTILITY OF MAGNIFYING ENDOSCOPY WITH NBI IN PREDICTING THE DEPTH OF SUPERFICIAL ESCC ACCORDING TO THE SIZE OF CARCINOMA

Keisuke Hori<sup>1</sup>, Hiroyuki Okada<sup>1</sup>, Yoshiro Kawahara<sup>1</sup>, Sayo Kobayashi<sup>2</sup>, Daisuke Kawai<sup>2</sup>, Minoru Matubara<sup>2</sup>, Masahide Kita<sup>2</sup>, Takao Tuzuki<sup>2</sup>, Seiji Kawano<sup>1</sup>, Junichiro Nasu<sup>2</sup>, Kazuhide Yamamoto<sup>2</sup>  
<sup>1</sup>Department Of Endoscopy, Okayama University Hospital, Okayama JAPAN, <sup>2</sup>Gastroenterology & Hepatology, Okayama University Graduate School Of Medicine Dentistry And Pharmaceutical Sciences, Okayama JAPAN

**Background:** The invasion depth of superficial esophageal squamous cell carcinoma (ESCC) is important in determining therapeutic strategy. The aim of this study was to investigate the clinical utility of magnifying endoscopy with narrow band imaging (Magnifying NBI) in predicting the depth of superficial ESCC according to the size of the carcinoma.

**Methods:** The techniques were carried out in 164 superficial ESCC resected by endoscopic submucosal dissection. The lesions were classified into three groups by the size: Group A; length < 25 mm and circumferential extension < 1/3 ( $n = 78$ ), Group B; length < 50 mm, and circumferential extension < 2/3, except Group A ( $n = 59$ ), Group C; length  $\geq 50$  mm or circumferential extension  $\geq 2/3$  ( $n = 27$ ). The invasion depth was divided into three: EP or LPM, MM or SM1, and more than SM2. Classification of Japan esophageal society was used to diagnose the invasion depth of esophageal cancer endoscopically.

**Results:** There were 127 pEP or LPM cancers, 33 pMM or pSM1 cancers, and 4 more than pSM2 cancers. Diagnostic accuracy for pEP or pLPM, pMM or pSM1, and more than pSM2 were 91%, 90% and 98%, respectively. Overall diagnostic accuracy for the invasion depth was 93%. The overall diagnostic accuracy according to the size of the lesion categorized as Group A, B, and C was 95%, 95%, and 63%, respectively. All misdiagnosed lesions in Group C (10/27) had circumferential extension  $\geq 2/3$ .

**Discussion:** Magnifying NBI is useful for estimating the depth of invasion of superficial ESCC. But the diagnosis for wide spreading superficial ESCC was difficult. Effective technique for close inspection of such lesions is needed.

**Disclosure:** All authors have declared no conflicts of interest.

#### P10.04 INEFFECTIVENESS OF 18F-FLUORODEOXYGLUCOSE POSITRON EMISSION TOMOGRAPHY IN THE EVALUATION OF TUMOUR RESPONSE AFTER COMPLETION OF NEOADJUVANT CHEMORADIATION IN OESOPHAGEAL CANCER

Guillaume Piessen<sup>1</sup>, Gregory Pety<sup>2</sup>, Alain Duhamel<sup>1</sup>, Xavier Mirabel<sup>3</sup>, Damien Huglo<sup>1</sup>, Christophe Mariette<sup>2</sup>  
<sup>1</sup>University Hospital Of Lille, Lille/France, <sup>2</sup>University Hospital Of Lille, France, Lille/France, <sup>3</sup>Oscar Lambret Center, Lille/France

**Background:** After primary chemoradiation (CRT), a non-invasive evaluation of the tumor response could help in the treatment decision to identify patients who may benefit from surgery. The objective of this prospective trial was to evaluate the role of FDG-PET in the assessment of tumor response after the completion of neoadjuvant (CRT) in patients with locally advanced resectable oesophageal cancer.

**Methods:** Operable patients with clinically staged T3N0-1M0 oesophageal cancer were enrolled. The complete treatment plan included neoadjuvant CRT (cisplatin + 5-Fluorouracil / 45 Gy) followed 6-8 weeks later by an oesophagectomy. Intratumoural pre- and post-treatment FDG-standardized

uptake values were assessed (SUV1, SUV2, percentage change). These variables were correlated with pathologic and morphologic responses and survival. Investigators were blinded to the FDG-PET results unless metastatic disease was suspected.

**Results:** Out of 60 total patients, 46 underwent the complete treatment plan. A major pathological response occurred in 19.6% of patients and was associated with a favorable outcome ( $P = 0.057$ ). Neoadjuvant CRT led to a significant reduction in intratumoural FDG-uptake ( $P < 0.001$ ). No significant association was seen between a pathologic response (either complete or major) and the FDG-PET results ( $P > 0.280$ ). The SUV2 value was correlated with a morphological response and the possibility to perform an R0 resection ( $P < 0.018$ ; ROC analysis: SUV2 threshold = 5.5). No significant association was found between metabolic imaging and recurrence or survival.

**Discussion:** FDG-PET does not effectively correlate with pathologic response and long-term survival in patients with locally advanced oesophageal cancer undergoing neoadjuvant CRT followed by surgery

**Disclosure:** All authors have declared no conflicts of interest.

#### P10.05 DEVELOPMENT OF THE NEW DIAGNOSTIC AND THERAPEUTIC TARGET USING HUMAN ANTIBODY-RADIOISOTOPE MOLECULAR IMAGING TECHNIQUE

Jong Ho Park, Hae Won Lee, Tae Sup Lee, Junhye Kwon  
Korea Cancer Center Hospital, Seoul/KOREA

**Background:** A malignant esophageal cancer, squamous cell carcinoma is the 6<sup>th</sup> prevalent cancer in Korean males. Despite the use of current surgical techniques combined with various treatment modalities, such as radiotherapy and chemotherapy, the overall 5-year survival rate of ESCC remains at 40-60%. To overcome this dismal situation, we have attempted to find clinically useful biomarkers. In this study, we report that overexpression of Integrin alpha 6 (ITGA6) in esophageal cancer tissue & cells. Also we examined it about the possibility for novel target for early detection or treatment.

**Methods:** We assessed ITGA6 expression level in ESCC tissue and cell lines using RT-PCR, Western blot, FACS and Immunohistochemistry. Then absorption of <sup>125</sup>I labeling ITGA6 antibody was evaluated in the xenograft models in nude mice.

**Results:** ITGA6 was highly expressed in tumor tissue and cancer cell lines over 70% of cases. ITGA6 is major adhesion receptor for laminin and is suggested to be involved in tumor cell invasion and metastasis. We evaluated the effect of antibody for ITGA6 using TE-8 cell lines (ESCC cell line) mouse xenograft model. After injection of <sup>125</sup>I-ITGA6 antibody, we assessed the biodistribution of I-125 labeled integrin alpha6 antibody in TE-8 xenograft model. In the ESCC model, the absolute tumor uptake is  $3.95 \pm 0.91$  at 2 hr and  $5.93 \pm 1.19$  at 24 hr. These biodistribution data of ESCC animal model indicate that ITGA6 antibody therapy might be a good treatment in ESCC.

**Discussion:** ITAG might be a promising target of a novel biomarker for developing alternative diagnostic or therapeutic modalities.

**Disclosure:** All authors have declared no conflicts of interest.

#### P10.06 TUMOR VOLUME AND RESPONSE PREDICTION IN NEOADJUVANT THERAPY FOR ESOPHAGEAL CARCINOMA

Rachel Blom<sup>1</sup>, Inge Steenbakkers<sup>2</sup>, Guido Lammering<sup>3</sup>, Roy Vliegen<sup>1</sup>, Eric Belgers<sup>1</sup>, Wendy Schreurs<sup>1</sup>, Charlotte De Jonge<sup>1</sup>, Marius Nap<sup>1</sup>, Meindert Sosef<sup>1</sup>

<sup>1</sup>Atrium Medical Center, Heerlen/NETHERLANDS, <sup>2</sup>Maastro Clinic, Maastricht/NETHERLANDS, <sup>3</sup>Maastro, Maastricht/NETHERLANDS

**Background:** Neoadjuvant therapy (NT) is increasingly applied in esophageal cancer (EC) patients. In general, small tumors are associated with a survival benefit compared to large tumors. Little is known however, about the relationship between initial tumor volume and response to NT. The aim of this study was to determine whether pre-therapy tumor volumes on PET-CT in EC patients are correlated with response to NT in the resection specimen.

**Methods:** A consecutive series of patients underwent diagnostic PET-CT scanning prior to NT and esophagectomy. Tumor volumes were determined on PET-CT. An automated tumor contour was generated using specified standard uptake value thresholds. Response to NT was determined in the resection specimen according to the Mandard-score. Patients were divided into different groups according to response to NT.

**Results:** From January 2008-May 2011, 115 patients underwent an esophagectomy. Tumor volumes determined on PET-CT were available in 79 patients. 30 patients (38%) had no residual tumor at the location of the primary tumor. 3/30 patients (10%), had residual tumor cells in the lymph nodes; 27 patients (34%) had a complete pathologic response. There was a trend towards a better response in patients with a smaller tumor volume ( $p = 0.084$ ).

**Discussion:** This study shows a trend towards a correlation between response to NT in EC patients with a small tumor volume on PET-CT. However, tumor volumes in both groups were overlapping, and a complete local response may be accompanied with residual disease in the lymph nodes; therefore, tumor volume on diagnostic PET-CT should not be used to differentiate between responders and non-responders.

**Disclosure:** All authors have declared no conflicts of interest.

#### P10.07 CLINICAL IMPACT OF PERIOPERATIVE SERUM P53 ANTIBODY TITERS IN PATIENTS WITH ESOPHAGEAL CARCINOMA.

Hideaki Shimada, Satoshi Yajima, Yoko Oshima, Tatsuki Nanami, Masaaki Itoh, Kunihiro Yamazaki, Hironori Kaneko  
*Toho University School Of Medicine, Tokyo/JAPAN*

**Background:** p53 genetic alterations of tumors have been reported to induce auto-reactive serum IgG antibodies in patients with cancer. We herein review the clinical impact of serum p53 antibodies (s-p53 Abs) for the patients with esophageal carcinoma.

**Methods:** s-p53-Abs were assessed by ELISA; a highly specific and quantitative p53 Abs ELISA kit (MESACUP anti-p53 Test; Medical & Biological Laboratories Co. Ltd. Nagoya, Japan) in patients with esophageal carcinoma before and one-month after surgery. The cut-off value was 1.3 U/mL to classify sero-positive patients. The clinical impact of s-p53-Abs was assessed to evaluate patients' prognosis and tumor recurrence after surgery.

**Results:** Among all patients, positive rate of s-p53 Abs was 32% before surgery. Serum titers were significantly reduced after surgery. High serum antibody titer was associated with poor prognosis ( $p < 0.05$ ). Some of T1 tumors can also be sero-positive. The positive rate of serum p53-Abs in patients with stage I tumors was higher than other conventional serum tumor markers. Among sero-positive patients, non-decreased titer group showed significantly unfavorable survival ( $P < 0.01$ ). Sero-positive patients even after surgery more likely suffered from recurrent disease than sero-conversion group. Multivariate analysis revealed that postoperative s-p53-Abs was an independent risk factor for worse survival ( $p < 0.05$ ).

**Discussion:** Serum p53 antibody was useful blood test to detect early stage of esophageal carcinoma and was also identify high risk group for tumor recurrence and a poor prognosis in patients with advanced stage of esophageal carcinoma.

**Disclosure:** All authors have declared no conflicts of interest.

#### P10.08 COMPARATIVE EVALUATION OF ENDOSCOPIC ULTRASONOGRAPHY AND FLUORODEOXYGLUCOSE-POSITRON EMISSION TOMOGRAPHY/COMPUTED TOMOGRAPHY FOR PREOPERATIVE DIAGNOSIS OF METASTATIC LYMPH NODES IN ESOPHAGEAL SQUAMOUS CELL CARCINOMA

Ken Sasaki<sup>1</sup>, Hiroshi Okumura<sup>2</sup>, Tetsuhiro Owaki<sup>2</sup>, Yasuto Uchikado<sup>2</sup>, Masataka Matsumoto<sup>2</sup>, Yoshiaki Kita<sup>2</sup>, Yoshikazu Uenosono<sup>2</sup>, Sumiya Ishigami<sup>2</sup>, Shuichi Hokita<sup>1</sup>, Shoji Natsugoe<sup>1</sup>  
<sup>1</sup>*Department Of Digestive Surgery, Breast And Thyroid Surgery Graduate School Of Medical Sciences, Kagoshima University, Kagoshima/JAPAN,*  
<sup>2</sup>*Department Of Digestive Surgery, Breast And Thyroid Surgery Graduate School Of Medical Sciences, Kagoshima University, Kagoshima/JAPAN*

**Background:** Precise evaluation of metastatic lymph nodes (LNs) is important in patients with esophageal squamous cell carcinoma (ESCC). Recently, fluorodeoxyglucose-positron emission tomography/computed tomography (PET) is considered as a useful diagnostic mean. The purpose of the present study is to compare the preoperative nodal metastasis between PET and endoscopic ultrasonography (EUS).

**Methods:** Diagnostic accuracy of EUS and PET were retrospectively compared in 42 ESCC patients treated with curative operation without neoadjuvant therapy. Metastatic LNs were diagnosed based on boundary and internal echo by EUS, and FDG uptake measured by the maximum standardized uptake value (SUVmax) in PET. Regarding PET examination, the lymph nodes in which SUVmax was 2.5 and more were diagnosed as being metastasis. Finally, these results were compared with the histological findings.

**Results:** Histologically 38 LNs were diagnosed as being metastatic. The sensitivity, specificity and accuracy rate by EUS and PET was 57.9, 98.4 and 94.7%, and 23.7/97.9/91.1%, respectively. Seven metastatic LNs were detected by both PET and EUS. Two metastatic LNs were detected by only PET, because of outside of EUS scanning area. Most of metastatic LNs detected by PET were more than 1 cm in size. Twelve metastatic LNs were detected by only EUS and six of them were less than 1 cm in diameter. Seventeen metastatic LNs were not diagnosed by both tools because of their small occupied metastatic area less than 2 mm in size.

**Discussion:** At present, EUS is useful for detecting nodal metastasis and PET is useful to detect LNs outside of EUS scanning area.

**Disclosure:** All authors have declared no conflicts of interest.

#### P10.09 THERMOGRAPHIC EVALUATION OF THE GASTRIC TUBE VIABILITY DURING ESOPHAGECTOMY

Katsunori Nishikawa<sup>1</sup>, Masami Yuda<sup>2</sup>, Yujiro Tanaka<sup>2</sup>, Akira Matsumoto<sup>2</sup>, Hiroaki Aoki<sup>2</sup>, Yuichiro Tanishima<sup>2</sup>, Fumiaki Yano<sup>2</sup>, Yoshio Ishibashi<sup>2</sup>, Koji Nakada<sup>2</sup>, Norio Mitsumori<sup>2</sup>, Nobuo Omura<sup>2</sup>, Katsuhiko Yanaga<sup>2</sup>  
<sup>1</sup>*Jikei University School Of Medicine, Tokyo/JAPAN,* <sup>2</sup>*Jikei University School Of Medicine Department Of Surgery, Tokyo/JAPAN*

**Background:** The stomach is used as a substitute for the esophagus after esophagectomy because of its abundant blood supply and favorable elasticity. However, poor vascularization of the proximal region of the gastric tube (GT) can be impaired, leading to anastomotic leakage or gastric tube ischemia. The purpose of this study is to examine the usefulness of thermal imaging (TI) system for intraoperative evaluation of gastric tube viability.

**Methods:** One-hundred and eight patients who underwent esophagectomy by using TI system were examined retrospectively. Temperature decline rate at anastomosis (TD-r) and ratio of length supplied by the right gastroepiploic artery to the whole length of GT actually used for esophageal replacement (RGEA-r) were calculated by TIs. Parameters of such factors were compared among the anastomotic leakage (AL), anastomotic stenosis (AS), and uneventful (UE) groups.

**Results:** Thirteen patients developed AL and 19 patients showed postoperative AS. In most GTs, surface temperature showed prominent drop distal to the area of blood supply from RGEA. Mean TD-r and RGEA-r for AL/AS were 0.17/0.13 and 0.67/0.74, respectively, while those of UE were 0.11 and 0.79, respectively. Comparison of TD-r and RGEA-r among AL, AS, and UE were statistically significant ( $p < 0.05$ ).

**Discussion:** TI system is non-invasive with high reproducibility in detecting GT viability during esophagectomy. When TIs of GT shows low RGEA-r with high TD-r, extra caution should be paid to anastomotic complications after esophagectomy.

**Disclosure:** All authors have declared no conflicts of interest.

#### P10.10 SENTINEL LYMPH NODE BIOPSY USING INTRAOPERATIVE INDOCYANINE GREEN FLUORESCENCE IMAGING NAVIGATED WITH PREOPERATIVE CT LYMPHOGRAPHY FOR SUPERFICIAL ESOPHAGEAL CANCER

Akira Tangoku  
*Department Of Thoracic, Endocrine Surgery And Oncology, The University Of Tokushima Graduated School, Tokushima/JAPAN*

**Background:** Sentinel lymph node (SLN) concept has been introduced to gastrointestinal cancer, but still remains controversial for esophageal cancer. We have developed preoperative SLN navigation system using Multi Detector (MD) computed tomographic lymphography (CTLG) which predict not only precise number and location of the SLNs but also existence of lymph node metastasis.

**Methods:** Total of 2 mL of water soluble iodine tracer (Iopamidol) was administered gently into the submucosa at 4 different areas surrounding the tumor (0.5-ml each) with endoscopic injection sclerotherapy needle. Five minutes after injection, 3D CTLG was performed to identify SLNs and lymphatic routes. During the operation, SLNs have been also identified identification using intraoperative indocyanine green (ICG) fluorescence imaging (IGFI) navigated by preoperative CTLG. ICG was injected around the tumor. Fluorescence imaging was obtained by infrared ray electronic endoscopy. Thoracoscope-assisted esophagectomy was performed to confirm fluorescent lymph nodes detected by CTLG.

**Results:** Lymphatic vessels and SLNs were identified preoperatively using CTLG. Intraoperative detection was performed using IGFI. Lymph node metastases were found in four cases, including one case with SLN occupied by metastatic tumor that were not enhanced with both methods. The other cases were accurately identified.

**Discussion:** Preoperative CTLG visualized the correct number and site of SLNs in surrounding anatomy during routine computed tomography during the routine screening for local invasion and distant metastasis. Referring to CTLG, SLNs were identified using IGFI, resulting in successful SLN navigation and saving time and cost. This method appears clinically applicable as a less-invasive method for treating superficial esophageal cancer.

**Disclosure:** All authors have declared no conflicts of interest.

**P10.11 STAGING, TREATMENT AND PROGNOSIS: IS 18F-FLUORODEOXYGLUCOSE POSITRON EMISSION TOMOGRAPHY/COMPUTED TOMOGRAPHY (FDG-PET/CT) A POSSIBLE LINK OF UNION?**

Laura Evangelista, Rita Alfieri, Carlo Castoro, Vanna Chiarion Sileni, Sara Galuppo, Silvia Stragliotto, Fabio Pomerri, Pier Carlo Muzzio, Anna Rita Cervino  
*Istituto Oncologico Veneto, PadovaITALY*

**Background:** To assess the additional diagnostic value of FDG-PET/CT in staging of esophageal cancer (EC) and to evaluate the prognostic role of metabolic parameters in EC patients before and after neo-adjuvant treatment.

**Methods:** we retrospectively evaluated 29 EC patients who underwent FDG-PET/CT before and after neo-adjuvant therapy. All PET/CT imaging parameters were calculated: minimum, average, maximum standardized uptake value (SUV) and total lesion glycolysis (TLG). Diagnostic advantages of PET/CT over conventional imaging (CI) were determined. The relationships between baseline and after-therapy SUV and TLG,  $\Delta$ SUV and  $\Delta$ TLG for the primary site and prognosis were assessed using standard criteria.

**Results:** 29 patients were assessed for the initial staging. Thirteen patients (45%) were incorrectly staged based on CI; PET/CT was able to identify distant lymph node involvement in 7 patients (59%) and distant metastases in 4 (31%). Twenty-five patients had baseline and post-neoadjuvant PET/CT scan. The median SUV<sub>max</sub> before and after neoadjuvant therapy were 10.38 and 3.53 (Wilcoxon test,  $p < 0.001$ ). Only few semi-quantitative parameters obtained by PET/CT after neoadjuvant therapy seemed to have a prognostic value; in particular TLG after neoadjuvant therapy and  $\Delta$ TLG were significantly different between disease-free and died patients (0.12 vs. 6.46; 0.49 vs. 15.51 and 100% vs. 94%, respectively; all  $p < 0.05$ ).

**Discussion:** PET/CT is able to detect distant metastases. Metabolic imaging does not improve the patient's outcome, but it can avoid unnecessary surgery. Although not routinely reported, post-neoadjuvant TLG and  $\Delta$ TLG might be considered as useful prognostic parameters and should be further evaluated prospectively.

**Disclosure:** All authors have declared no conflicts of interest.

**P10.12 PET-GUIDED PROGNOSIS: A PROMISING ROLE OF METABOLIC IMAGING IN ESOPHAGEAL CANCER**

Laura Evangelista, Rita Alfieri, Carlo Castoro, Vanna Chiarion Sileni, Sara Galuppo, Silvia Stragliotto, Fabio Pomerri, Pier Carlo Muzzio, Anna Rita Cervino  
*Istituto Oncologico Veneto, PadovaITALY*

**Background:** To evaluate the prognostic value of FDG-PET/CT after neo-adjuvant therapy in locally advanced esophageal cancer (EC) patients.

**Methods:** Among 108 EC patients who underwent FDG-PET/CT after neo-adjuvant treatment, we selected 56 patients without evidence or suspicious for distant metastases. All patients were followed for a median period of 12 months (range: 2–37 months) from nuclear imaging. PET/CT findings were correlated with surgical management and long-term prognosis. Chi-square test was used for categorical variables and t-Student test for continuous data. Survival curves were computed using Kaplan Meier method. A  $p$  value  $< 0.05$  was considered statistically significant.

**Results:** 15 patients had negative and 41 positive (27 vs. 73%) PET/CT after neo-adjuvant therapy. 6/15 underwent radical-intent surgery and 9/15 did not, whereas 31/41 performed surgery and 10/41 did not ( $p < 0.05$ ). After a median time of 12 months, 25 patients were disease-free, 18 relapsed and 11 died. The overall-survival was different between patients with negative and positive scan (93.3vs.74.4%;  $p = 0.139$ ). The event-free survival was higher in patients with negative than with positive PET/CT after treatment (73.3vs.35.9%;  $p < 0.087$ ). Considering patients with positive PET/CT, in non-surgery subset only 1 patient was alive without evidence of disease while in surgery subset 13 patients were disease-free (10 vs. 44%,  $p < 0.001$ ).

**Discussion:** PET/CT could stratify the recurrence risk of EC patients based on treatment efficacy; after 12 months from PET/CT, 89% of patients with negative scan who did not undergo surgery, resulted disease-free. A positive PET/CT after neo-adjuvant therapy should be followed by surgery for improving the event-free survival.

**Disclosure:** All authors have declared no conflicts of interest.

**P10.13 SUV THRESHOLD BY FDG PET/CT: A POSSIBLE SIGN OF RESIDUAL MICROSCOPIC DISEASE IN LOCALLY ADVANCED ESOPHAGEAL CANCER**

Laura Evangelista, Rita Alfieri, Carlo Castoro, Vanna Chiarion Sileni, Sara Galuppo, Silvia Stragliotto, Fabio Pomerri, Pier Carlo Muzzio, Anna Rita Cervino  
*Istituto Oncologico Veneto, PadovaITALY*

**Background:** to evaluate the additional prognostic data from semiquantitative analysis of PET/CT in patients with locally advanced esophageal cancer (EC) who underwent scan in post-neoadjuvant setting.

**Methods:** we retrospectively reviewed PET/CT from 56 EC patient and without evidence or suspicious for metastases. All patients were followed for a median period of 12 months (range: 2–37 months) from nuclear imaging. At visual analysis, PET/CT was considered abnormal when a FDG-uptake outside physiological sites was recognized. Semiquantitative data were calculated, such as SUV<sub>max, min, average</sub> and were correlated with prognosis. Chi-square was applied from comparing categorical variables. Survival curves were computed using Kaplan Meier method.

**Results:** Out of 56 patients, 41 (73%) had an abnormal PET/CT and thus considered as metabolic non-responders. Twenty-three patients had a complete response to therapy evaluated by biopsy or histology. Fifteen patients (27%) had a SUV average  $< 2.00$  (1<sup>st</sup> group); 5 (9%) had a SUV average 2.00–2.50 (2<sup>nd</sup> group); 13 (23%) had a SUV average 2.50–3.50 (3<sup>rd</sup> group) and finally 23 (41%) had a SUV average  $> 3.50$  (4<sup>th</sup> group). After 12 months, in the 1<sup>st</sup> group 11 (73%) patients were disease-free and 7 were disease-free both in the 3<sup>rd</sup> and 4<sup>th</sup> group (54 and 30%, respectively), whereas none patients resulted disease-free in the 2<sup>nd</sup> group. The overall survival was different among SUV average subsets (93.3vs.60vs.92.3vs.66.7%, respectively;  $p = 0.071$ ).

**Discussion:** Patients with small and focal areas of FDG-uptake with a SUV average from 2.0–2.50 showed a high risk of adverse events during follow-up. An accurate visual analysis associated with low SUV average can be useful for recognizing microscopic residual tumor after neoadjuvant therapy.

**Disclosure:** All authors have declared no conflicts of interest.

**P10.14 MICROVASCULAR CLASSIFICATION OF SUPERFICIAL SQUAMOUS CELL CARCINOMA OF ESOPHAGUS DETECTED BY MAGNIFIED ENDOSCOPY**

Jirawat Swangsri  
*Tokyo Medical And Dental University, TokyoJAPAN*

**Background:** Esophageal cancer is 8th common GI cancer in the world. Year 2008–10,000 Japanese esophageal cancer patients registered and 1/3 of patient were superficial cancer. Early detection is the best way to improve patient survival outcome particular mucosal lesion which without lymphatic involvement. Even though the classification of early esophageal cancer was published many years ago, however the accurate information of microvascular of superficial cancer still unclear and necessary for clinical application.

**Methods:** 217 IPCL images which took by magnified endoscopy from 16 esophagectomy specimens are studied in two aspect, first is classify by morphologic features. Second aspect by measuring IPCL dimensions for statistic analysis, this data will support morphologic appearance to determine characteristic of microvascular pattern.

**Results:** The microvascular morphology are classified to 4 basic major pattern are Spiral loop, Wide loop, Glomerular and Reticular pattern. Mostly of m1 lesion are simple vascular thin bundle and homogeneous. Feature of m2 lesion are more thickening of microvascular bundle outline and more complex in Reticular pattern. Characters of m3 lesion are most thickening of microvascular bundle outline and most complexity. Spiral loop pattern is most common pattern of all depth. The dimensions of m1,m2 and m3 are significant different in tumor depth, outline and cover area.

**Discussion:** Microvascular pattern of early cancer of esophagus are unique and dynamic change. It will increase in dimensions and complexity related with tumor growth. For accuracy diagnosis by using endoscopic finding the basic structure and overall featuring are important for combine consider.

**Disclosure:** All authors have declared no conflicts of interest.

**P10.15 PREDICTION OF SURVIVAL USING COMBINED FLUORODEOXYGLUCOSE POSITRON EMISSION TOMOGRAPHY/COMPUTED TOMOGRAPHY (PET/CT) AFTER NEOADJUVANT THERAPY IN PATIENTS WITH ADVANCED ESOPHAGEAL CANCER.**

Masahiko Yano, Masaaki Motoori, Yoshiyuki Fujiwara, Kentaro Kishi, Tatsushi Shingai, Shingo Noura, Masayuki Ohue, Hiroaki Ohigashi, Osamu Ishikawa  
*Osaka Medical Center For Cancer And Cardiovascular Diseases, Osaka, Japan., Osaka/JAPAN*

**Background:** Neoadjuvant therapy (NAT) followed by surgery for advanced esophageal cancer improves the prognosis in responders, whereas it may give no clinical benefit, or it might be even harmful in non-responders. Precise response evaluation is important for decision-making of the treatment.

**Methods:** Fifty six patients with UICC stage IIB-IV esophageal cancer were treated with NAT (10 chemoradiotherapy and 46 chemotherapy), followed by surgery. <sup>18</sup>F-fluorodeoxyglucose positron emission tomography/computed tomography (PET/CT) was performed twice for each patient, before and after NAT.

**Results:** The patients were divided into several groups according to the pretreatment maximal standardized uptake value (pre-NAT-SUVmax), post-NAT-SUVmax and %SUVmax of the main tumors (T) or the metastatic nodes (N). Neither pre-NAT-SUVmax-T, pre-NAT-SUVmax-N, %SUVmax-T nor %SUVmax-N correlated significantly with disease-free survival (DFS). With regard to the post-NAT-SUVmax-T, the low group (<3.0) had a significantly (p = 0.017) better DFS than the middle (≥3.0, <7.5) or high (≥7.5) groups. Similarly, for the post-NAT-SUVmax-N, the high group (3.0≤) showed a significantly (p = 0.002) worse DFS than the middle (≥2.0, <3.0) and low (<2.0) groups. When a cut-off value of 3.0 was used for both the post-NAT-SUVmax-T and -N, patients with both of these two values lower than 3.0 (T < 3.0 and N < 3.0) showed significantly better effectiveness of NAT based on pathological examination, earlier pathological T stages, earlier pathological stages, fewer number of metastatic nodes and better DFS than those with T ≥3.0-N ≥3.0 and the remaining groups.

**Discussion:** Post-NAT-SUVmax-T and -N could be useful predictors for DFS in patients with advanced esophageal cancer.

**Disclosure:** All authors have declared no conflicts of interest.

**P10.16 DETECTION OF CIRCULATING TUMOR CELLS IN PATIENTS WITH ESOPHAGEAL SQUAMOUS CELL CARCINOMA**

Daisuke Matsushita, Yoshikazu Uenosono, Takaaki Arigami, Takahiko Hagihara, Naosi Haraguchi, Yasuto Uchikado, Hiroshi Okumura, Shoji Natsugoe  
*Department Of Digestive Surgery Graduate School Of Medical And Dental Sciences Kagoshima University, Kagoshima City/JAPAN*

**Background:** The circulating tumor cells (CTC) has been reported to be one of important recurrent factors by molecular biological studies. Recently, Cellsearch system (CSS) has been developed as a simple blood assay for CTC detection. In the present study, we analyzed the relationship between the presence or absence of CTC and the therapeutic efficacy in patients with esophageal carcinoma (ESCC).

**Methods:** Three ESCC cell lines were used to assess the sensitivity and specificity of CSS. Next, we examined CTC in 44 patients (A group: 24 operable cases and B group: 20 unresectable or recurrent cases). In this study, all blood samples were collected before treatment, including 14 samples after chemoradiation therapy (CRT).

**Results:** Cell spiking study demonstrated the linear relationship between the expected CTC numbers and the number of CTC determined by CSS in each serial dilution. Before treatment, CTC positive rates in A and B groups was 20.8% (5/24) and 35.0% (7/20). In B groups, patients with CTC positivity tended to have distant metastasis, compared with CTC negativity. The patients with CTC negativity tended to have locally advanced tumors compared with CTC positivity. In 14 patients who were assessed CTC before and after CRT, partial responder (PR), stable disease (SD), and progressive disease (PD) was identified in 6, 3, and 5 patients. The incidence of CTC was related with effect of CRT.

**Discussion:** CTC assay may be useful for predicting tumor progression and monitoring the therapeutic efficacy in patients with ESCC.

**Disclosure:** All authors have declared no conflicts of interest.

**P10.17 PREOPERATIVE STAGING OF CLINICALLY NODE-NEGATIVE ESOPHAGEAL CANCER BY THE COMBINATION OF 18F-FLUORODEOXYGLUCOSE POSITRON EMISSION TOMOGRAPHY AND COMPUTED TOMOGRAPHY (FDG-PET/CT)**

Masahiko Yano, Masaaki Motoori, Kentaro Kishi, Yoshiyuki Fujiwara, Tatsushi Shingai, Shingo Noura, Masayuki Ohue, Hiroaki Ohigashi, Osamu Ishikawa  
*Osaka Medical Center For Cancer And Cardiovascular Diseases, Osaka, Japan., Osaka/JAPAN*

**Background:** Although lymph node metastasis is a significant prognostic factor in patients with esophageal cancer, the sensitivity and specificity of conventional imaging modalities such as computed tomography (CT) and magnetic resonance imaging system (MRI) is limited. This retrospective study examined the usefulness of the combination of <sup>18</sup>F-fluorodeoxyglucose (FDG)-positron emission tomography (PET)/CT in the diagnosis of lymph node metastasis in esophageal cancer patients who were diagnosed node-negative by conventional imaging modalities.

**Methods:** We compared the postoperative pathological findings and preoperative PET/CT findings in 81 consecutive clinically node-negative esophageal cancer patients who underwent esophagectomy with lymphadenectomy. All patients had resectable tumor (T1-T3) and were node-negative based on preoperative conventional examinations.

**Results:** Of the 81 patients, 37 had pathological node metastasis in surgical specimens. PET/CT diagnosis of node metastasis was made by using several cut-off values of maximum standardized uptake value (SUVmax). The sensitivity, specificity and accuracy of PET-CT diagnosis were 32.4%, 70.4% and 53.1% at SUVmax of 1.8, 29.7%, 79.5% and 56.8% at 2.0, 21.6%, 90.9% and 59.3% at 2.5, 16.2%, 95.4% and 59.3% at 3.0, and 10.8%, 97.7% and 56.8% at 3.5, respectively. When a SUVmax cut-off value of 1.8 was employed, the disease-free survival rate was significantly worse in PET/CT-node-positive patients (PET-N(+)) than PET-N(-) patients.

**Discussion:** The diagnostic sensitivity of PET/CT for subclinical lymph node metastasis in clinically node-negative patients is low but this combination modality can potentially identify patients with poor prognosis.

**Disclosure:** All authors have declared no conflicts of interest.

**P10.18 CYFRA 21-1 AND SCC AS TUMOR MARKERS FOR ESOPHAGEAL EPIDERMOID CARCINOMA**

Elsa Castelo Alvarez, Ruben Gonzalo Gonzalez, Andrea Gonzalez Tamargo, Ester Fernando Macias, Belen Porrero Guerrero, Ana Madalina Frunza, Lourdes Sanz Alvarez, Estrella Turienzo Santos, Juan Jose Gonzalez Gonzalez  
*Hospital Universitario Central De Asturias, Oviedo/SPAIN*

**Background:** Biological markers CYFRA 21.1 and SCC are used in the diagnostic studies of epithelial tumors, among others the esophageal epidermoid carcinoma, and can be related to different prognostic factors, as well as to the survival for this kind of tumor.

**Methods:** Predictive diagnostic value of these markers was available from 126 patients with esophageal epidermoid carcinoma who were treated in our Department between January 1989 and December 2010. The values of CYFRA 21.1 and SCC are correlated with the depth of invasion, presence of lymph node involvement, metastasis, tumor stage, tumor differentiation, resection, and survival.

**Results:** The mean CYFRA 21.1 value was 2.57 ng/ml (SD = 0.37, range = 0.1–27 ng/ml). High pre-treatment CYFRA 21.1 levels were identified in 27 out of 115 patients. The mean SCC value was 1.82 ng/ml (SD = 0.25, range = 0.1–21.9 ng/ml.) High pre-treatment SCC levels were identified in 38 out of 126 patients. According to the different variables of the study, a relation was established between the high CYFRA values, the poorly differentiated and advanced T stage tumors, but also with the low values, and the possibility of resective surgery and longer survival outcomes. Regarding SCC, there was a relationship between higher levels and an advanced T and TNM stage.

**Discussion:** CYFRA 21.1 and SCC have proved to be useful markers as they are correlated with tumor differentiation, depth of invasion, TNM stage, possibility of resection, and survival, something which can help to decide on the most appropriate kind of treatment for each patient and offer an individual prognosis.

**Disclosure:** All authors have declared no conflicts of interest.

**P10.19 STAGING LAPAROSCOPY WITH NEAR-INFRARED FLUORESCENCE IMAGING USING SYNTHESIZED INDOCYANINE GREEN LIPOSOMAL DERIVATIVE**

Isamu Hoshino<sup>1</sup>, Tetsuro Maruyama<sup>1</sup>, Yasunori Akutsu<sup>1</sup>, Aki Komatsu<sup>1</sup>, Naoyuki Hanari<sup>1</sup>, Mikito Mori<sup>1</sup>, Yasuo Yoneyama<sup>1</sup>, Naoki Akanuma<sup>1</sup>, Yuka Isozaki<sup>1</sup>, Nobuyoshi Takeshita<sup>1</sup>, Hideki Hayashi<sup>2</sup>, Yutaka Tamura<sup>3</sup>, Taro Toyota<sup>4</sup>, Hisahiro Matsubara<sup>1</sup>

<sup>1</sup>Department Of Frontier Surgery, Chiba University, Chiba/JAPAN,

<sup>2</sup>Research Center For Frontier Medical Engineering, Chiba University, Chiba/JAPAN,

<sup>3</sup>Department Of Bioinformatics, Chiba University, Chiba/JAPAN,

<sup>4</sup>Department Of Applied Chemistry And Biotechnology, Chiba University, Chiba/JAPAN

**Background:** Peritoneal dissemination is one of the most important problems for esophagocardial cancer. Peritoneal dissemination occurred frequently in poorly differentiated adenocarcinoma and could not be detected before an operation. In spite of developments of the diagnostic modalities, many patients are exposed to unnecessary laparotomy and the morbidity associated with non-therapeutic laparotomy is not negligible. We herein propose a new fluorescence imaging technology using nanoparticle to detect peritoneal dissemination.

**Methods:** The near-infrared-fluorescing, containing indocyanine green (ICG), liposomal probes were synthesized and used as a tracer molecule. Balb/c nu/nu mice were i.p. injected with  $5 \times 10^5$  KATOIII or MKN45 cells. Twelve days later, mice were given i.v. injections of liposomal probes at the dose of 0.15 mg/kg. After 24 hours, mice were euthanized and laparotomy was performed. An infrared ray laparoscopy system (IRLS; Olympus Medical Systems Co., Tokyo, Japan) was used to identify the disseminated tumors. Disseminated tumor nodules were collected from the mice with or without injections of liposomal probes and were replaced into swine peritoneal cavity. Then, replaced nodules were detected using IRLS.

**Results:** The disseminated nodules in mice were detected by IRLS without any difficulties. Even, 1 mm nodules were also detected due to the positive fluorescence signals. The nodules replaced into the swine peritoneal cavity were clearly and promptly founded by IRLS.

**Discussion:** Our study showed that the near-infrared-fluorescing liposomal probes can effectively target peritoneal disseminated tumors and easily detected by IRLS. A regulatory preclinical toxicity study and a clinical trial are needed for future clinical use.

**Disclosure:** All authors have declared no conflicts of interest.

**P10.20 ENDOSCOPIC DIAGNOSIS OF EARLY CARCINOMA OF THE ORAL CAVITY AND LARYNGOPHARYNX IN PATIENTS WITH ESOPHAGEAL SQUAMOUS CELL CARCINOMA USING A TRANSNASAL ULTRATHIN ENDOSCOPE**

Kenro Kawada, Tatsuyuki Kawano, Takuya Okada, Naoto Fujiwara, Shunsuke Ohta, Jirawat Swangsri, Tairo Ryotokuji, Yutaka Miyawaki, Yutaka Tokairin, Yasuaki Nakajima, Tetsuro Nishikage, Kagami Nagai  
Department Of Esophagogastric Surgery, Tokyo Medical And Dental University, Tokyo/JAPAN

**Background:** New diagnostic techniques have dramatically increased the number of detection of superficial pharyngeal cancer. However, otorhinolaryngeal sites of some patients cannot be examined by transoral esophago-gastroduodenoscopy (EGD) due to patients' gag reflex. On the other hand, transnasal EGD can be performed smoothly because of its attenuation of the gag reflex.

**Methods:** To evaluate the diagnostic value of transnasal EGD using a FICE system in detecting another primary head and neck cancers in patients with esophageal cancer (EC) or head and neck cancer(HNC) during the screening of the oral cavity and the Valsalva maneuver. Three hundred seventeen EC or HNC patients (EC 274, HNC 112, EC combined with HNC 69) underwent transnasal EGD screening with both a white light and an FICE system between October 2009 and October 2011. The Valsalva maneuver and screening of the oral cavity was also performed.

**Results:** A total of 34 superficial cancers were found in 26 patients (8.2%) by transnasal EGD. In particular, 21 primary hypopharyngeal cancers were detected in this study. In addition, four cases of mesopharyngeal cancer, four cases of the floor of the mouth, and three cases of soft palate, buccal mucosa and larynx in one case were found. Fifteen of those cases were determined to have intraepithelial neoplasia. The FICE system enables easily observation of the presence of scattered brown dots to diagnose superficial cancers.

**Discussion:** Therefore, transnasal endoscopy may become the standard examination modality for the screening of the oral cavity, pharynx and larynx.

**Disclosure:** All authors have declared no conflicts of interest.

**P10.21 HIGH RESOLUTION MAGNETIC RESONANCE (MR) WITH PHASED-ARRAY SURFACE COIL IN THE LOCAL STAGING OF ESOPHAGEAL CANCER**

Daniela Cenzi<sup>1</sup>, Massimiliano Motton<sup>1</sup>, Andrea Zanoni<sup>2</sup>, Simone Giacomuzzi<sup>3</sup>, Stefania Montemezzi<sup>1</sup>, Giovanni De Manzoni<sup>3</sup>

<sup>1</sup>Division Of Radiology, Azienda Ospedaliera-Universitaria Integrata

Verona, Verona/ITALY, <sup>2</sup>Upper G.I. Surgery Division University

Of Verona, Verona/ITALY, <sup>3</sup>Upper G.I. Surgery Division, University Of Verona, Verona/ITALY

**Background:** To assess technical feasibility and diagnostic accuracy of high-resolution MR in the pre-surgical staging of esophageal cancer.

**Methods:** 20 consecutive Patients with esophageal cancer underwent MR using a surface coil. The same protocol was performed in all Patients: sagittal TSE T2-weighted sequence, high-resolution para-axial TSE T2-weighted and STIR sequences, both ECG-triggered, DWI and post-gadolinium images.

We assessed technical feasibility, considered as the capability to obtain detailed images of the esophageal wall layers and surrounding structures. We also evaluated diagnostic accuracy, correlating MR staging with histopathology in Patients who underwent surgery or comparing MR staging with the conventional methods for staging – defined as a combination of EUS, CT and PET-CT.

**Results:** Technical feasibility of MR was 100%, although poor quality imaging was observed in 2/20 Patients (10%). In 2 Patients RM identified double localization of esophageal cancer. 6/20 underwent surgical treatment after MR: in 5/6 staging correlated with histopathology (diagnostic accuracy in T1-T2 tumors: 83.5%), with a better definition in T staging than EUS in 2/5. In remaining 14 Patients, 5 never underwent surgery, while 9 underwent neo-adjuvant treatment before resection. Between them, 8 underwent EUS before treatment: MR was found comparable in T stage (100% correlation). MR detected more pathologic lymph-nodes than EUS, resulting in better N staging (correlation with CT/PET-CT: 80%).

**Discussion:** MR may be an alternative non-invasive method for staging for esophageal cancer, at least comparable to EUS in local staging. A larger field of view than EUS might increase accuracy in assessing lymph-node involvement and better characterization in vascular infiltration.

**Disclosure:** All authors have declared no conflicts of interest.

**P10.22 EXTRACAPSULAR LYMPH NODE SPREAD: A PROGNOSTIC FACTOR IN ADENOCARCINOMAS OF THE ESOPHAGO-GASTRIC JUNCTION**

Stefan Paul Mönig<sup>1</sup>, Uta Drebber<sup>2</sup>, Alexander Urbanski<sup>1</sup>, Ralf Metzger<sup>1</sup>, Elfriede Bollschweiler<sup>1</sup>, Arnulf Hölscher<sup>1</sup>

<sup>1</sup>Department Of General-, Visceral- And Cancer Surgery University Of

Cologne, Cologne/GERMANY, <sup>2</sup>University Hospital Cologne, Institute Of Pathology, Cologne/GERMANY

**Background:** Lymphatic spread is one of the most relevant prognostic factors for adenocarcinomas of the esophago-gastric junction. The current UICC pN staging system is based on the number of metastatic lymph nodes and does not take into consideration the characteristics of the metastatic lymph nodes itself. The aim of the current study was to examine the prognostic value of extracapsular lymph node involvement (LNI) in adenocarcinomas of the esophago-gastric junction and to find correlations with clinicopathological parameters.

**Methods:** Tissue samples were obtained from 92 patients with type II and III carcinomas of the esophago-gastric junction who underwent transhiatal extended gastrectomy with D2-lymphadenectomy. The number of resected lymph nodes, number of metastatic lymph nodes and number of metastatic lymph nodes with extracapsular LNI were determined. Extracapsular spread was defined as infiltration of cancer cells beyond the capsule of the metastatic lymph node.

**Results:** 63 (68.5%) patients had lymph node metastasis. In 43 (46.7%) cases also extracapsular LNI was detected. Extracapsular LNI was significantly associated with higher pN-category, higher pM-category and higher UICC stages. According to the Kaplan-Meier log-rank statistical method, extracapsular LNI was significantly associated with poor survival ( $p = 0.017$ ).

**Discussion:** Extracapsular LNI is associated with higher tumor stages and is a negative prognostic factor in type II and III carcinomas of the esophago-gastric junction. In future staging systems for gastric cancer, extracapsular LNI should be considered.

**Disclosure:** All authors have declared no conflicts of interest.

**POSTER SESSION P11: ESOPHAGEAL  
CARCINOGENESIS – October 17, 2012 12:30–13:30****P11.01 MODULATION OF CHEMOSENSITIVITY BY INSULIN-  
LIKE GROWTH FACTORS IN HUMAN ESOPHAGEAL  
ADENOCARCINOMA**Alan Casson<sup>1</sup>, Ronghua Zhao<sup>2</sup><sup>1</sup>University Of Saskatchewan, Royal University Hospital, Saskatoon  
CANADA, <sup>2</sup>University Of Saskatchewan, Saskatoon/CANADA

**Background:** As resistance to chemotherapy is associated with recurrence of esophageal adenocarcinoma (EADC), the aim of this study was to evaluate whether insulin-like growth factors (IGFs, recently implicated in esophageal tumorigenesis), modulate chemosensitivity to Cisplatin (CDDP) and 5-Fluorouracil (5-Fu).

**Methods:** Quantitative PCR and Western analysis were used to study mRNA and protein expression of IGF1, IGF1 Receptor (IGF1R) and IGF2 in human esophageal cell lines: Het1A (immortalized normal epithelium), OE33 and JHEsoAd1 (EADC). The effect of various concentrations of IGFs, CDDP and 5-Fu, alone and in combination, on cell proliferation and clonogenicity were evaluated by MTT and colony formation assays. PCR-array was used to study expression of 84 critical genes related to the PI3K pathway.

**Results:** Relative to Het1A, OE33 underexpressed IGF1 and IGF2 mRNA ( $P < 0.05$ ). By contrast, JHEsoAd1 underexpressed IGF1, but overexpressed IGF2. Administration of either IGF1 (250 ng/ml) or IGF2 (500 ng/ml) to cell cultures resulted in increased cellular proliferation of JHEsoAd1 cells (after IGF1:  $1.24 \pm 0.05$  vs.  $1.00 \pm 0.00$  untreated,  $P < 0.01$ ; after IGF2:  $1.15 \pm 0.06$  vs.  $1.00 \pm 0.06$  untreated,  $P < 0.05$ ). As expected, cell proliferation and clonogenicity were inhibited by CDDP and/or 5-Fu (dose range 1–4 ug/ml). These cytotoxic effects were overcome by administration of either IGF1 or IGF2, and were associated with upregulation and downregulation of selected PI3K/AKT pathway genes.

**Discussion:** These results demonstrate the potential for IGFs to enhance cytotoxic efficacy of two standard chemotherapeutic agents in human esophageal cells. IGF modulation of selected PI3K/AKT-related genes suggests novel molecular regulatory pathways downstream from IGF1R, providing further insight into esophageal tumor biology.

**Disclosure:** All authors have declared no conflicts of interest.

**P11.02 EARLY DETECTION OF PHARYNGEAL CANCER USING  
HIGH VISION ENDOSCOPE IN PATIENTS WITH ESOPHAGEAL  
CANCER**Takashi Ogata, Hiroshi Kuwabara, Akira Tsuburaya,  
Takafumi Watanabe, Takako Yoshii  
Kanagawa Cancer Center, Yokohama/JAPAN

**Background:** Head and neck cancer(HNC) are always detected at an advanced stage, and their prognosis are very bad. On the other hand, esophageal squamous cell cancer(ESCC) sometimes coexist with HNC, especially pharyngeal cancer. So we endoscopists must detect it in early stage when we check esophagus.

**Methods:** The aims of study is to examine the frequency of HNC detection using high vision endoscope using NBI or not at first visit of ESCC or after treatment of ESCC, and examine its treatment. The methods of endoscopic observation is to observe pharynx by white light at first followed by NBI using H260 or H260z endoscope (Olympus co.,LTD).

**Results:** From April 2008 to February 2012, endoscopic observation of ESCC before treatment was carried out of 139 cases by two special endoscopists, and was discovered 14 cases(10%) of HNC simultaneously. 10 cases(71%) of HNC were detected in early stage, and 4 cases(28%) were treated by ESD. But 3 cases(21%) were detected by NBI examination after conventional examination. On the other hand, endoscopic observation after ESCC treatment was carried out 456, and was discovered 12 cases(2.6%) of HNC metachronously. 11 cases(92%) of HNC were detected in early stage, and 10 cases(83%) were treated by ESD. But 3 cases(25%) were detected by NBI examination after conventional examination.

**Discussion:** HNC is detected early by high vision endoscopy with NBI in patients with ESCC. As a result, it allows non-invasive treatment such as ESD in HNC. It is desirable that it should be careful observation of pharynx in patients with ESCC.

**Disclosure:** All authors have declared no conflicts of interest.

**P11.03 PREDICTIVE FACTORS FOR EARLY RECURRENCE IN  
PATIENTS WITH ESOPHAGEAL SQUAMOUS CELL CARCINOMA  
AFTER CURATIVE RESECTION**Hiroki Shimizu, Hitoshi Fujiwara, Atsushi Shiozaki, Kazuma Okamoto,  
Daisuke Ichikawa, Shuhei Komatsu, Yasutoshi Murayama,  
Yoshiaki Kuriu, Hisashi Ikoma, Masayoshi Nakanishi, Toshiya Ochiai,  
Yukihito Kokuba, Eigo OtsujiDivision Of Digestive Surgery, Department Of Surgery, Kyoto Prefectural  
University Of Medicine, Kyoto/JAPAN

**Background:** Esophageal cancer has remained a disease with poor prognosis upon early recurrence, even if curative resection with combined modality treatment was performed. In this study, the clinicopathological predictive factors for early recurrence in patients with curative resected esophageal cancer were retrospectively evaluated.

**Methods:** Eighty-one consecutive patients, who had recurrence of primary esophageal squamous cell carcinoma after curative resection, were analyzed. The patients were classified into two subgroups by time of recurrence (within 180 days of surgery or later): an early group and a late group.

**Results:** Twenty-seven and 54 patients were classified into early and late groups, respectively. Patients in the early group had significantly deeper tumors than the late group. The initial recurrence patterns were not significantly different between the two groups, and distant recurrences were found in two-thirds of patients in both groups. The 1-year survival rates of patients in the early and late groups were 11% and 62%, respectively. The survival rate after recurrence of patients in the early group was significantly poorer than that of patients in the late group (p

**Discussion:** Early distant recurrences of esophageal cancer frequently occurred even after curative surgery. The number of pathological lymph node metastases with three or more was the independent risk factor for early recurrence in patients with esophageal cancer after curative resection.

**Disclosure:** All authors have declared no conflicts of interest.

**P11.04 CLINICAL SIGNIFICANCE OF KI-67 LABELING INDEX IN  
PATIENTS WITH ESOPHAGEAL SQUAMOUS CELL CARCINOMA**Atsushi Shiozaki, Daisuke Iitaka, Hitoshi Fujiwara, Daisuke Ichikawa,  
Shuhei Komatsu, Kazuma Okamoto, Yasutoshi Murayama,  
Yoshiaki Kuriu, Hisashi Ikoma, Masayoshi Nakanishi, Toshiya Ochiai,  
Yukihito Kokuba, Eigo OtsujiDivision Of Digestive Surgery, Department Of Surgery, Kyoto Prefectural  
University Of Medicine, Kyoto/JAPAN

**Background:** Although the Ki-67 labeling index (LI) is frequently used to determine the proliferative activity of various cancers, no consensus has been reached about its clinicopathological significance in esophageal squamous cell carcinoma. In the present study, we sought to determine an adequate Ki-67 LI cut off value and investigated its prognostic significance in esophageal squamous cell carcinoma.

**Methods:** The Ki-67 LI was calculated by immunohistochemistry for 49 primary tumor samples obtained from patients with esophageal squamous cell carcinoma, and the correlations between the Ki-67 LI and various clinicopathological features or prognosis were analyzed.

**Results:** The Ki-67 LI of the tumors ranged from 5.3% to 55.9%. The mean Ki-67 LI increased from 27.4% in pN0 tumors to 40.3% in pN3 tumors. The five-year survival rate decreased as the Ki-67 LI increased. When the patients were divided into 2 groups using an Ki-67 LI cut off value of 35%, the 5-year survival rate of the patients with Ki-67 LI of <35% was 82.9%, which was significantly higher than that of the patients with Ki-67 LI of  $\geq 35\%$  (35.7%). The percentage of pN positive tumors was significantly higher among the patients with Ki-67 LI of  $\geq 35\%$  (85.7%) than in patients with Ki-67 LI of <35 (48.6%). Multivariate analysis demonstrated that pT and pN categories and the Ki-67 LI were independent prognostic factors.

**Discussion:** These observations indicate that the Ki-67 LI is correlated with lymph node metastasis and can be used as an independent prognostic factor for patients with esophageal cancer by selecting an adequate cut off value.

**Disclosure:** All authors have declared no conflicts of interest.

**P11.05 SURGICALLY-INDUCED CHRONIC REFLUX IN RATS: AN  
ACCURATE MODEL FOR STUDYING ESOPHAGEAL  
CARCINOGENESIS?**Caroline Gronnier<sup>1</sup>, Guillaume Piessen<sup>2</sup>, Emilie Bruyère<sup>2</sup>, Nicolas Briez<sup>2</sup>,  
Jérôme Bot<sup>2</sup>, David Buob<sup>2</sup>, Isabelle Van Seuning Van Seuning<sup>2</sup>,  
Emmanuelle Leteurtre Leteurtre<sup>2</sup>, Christophe Mariette<sup>2</sup><sup>1</sup>Inserm, Umr837, Jean-Pierre Aubert Research Center, Team 5 «Mucins,  
Epithelial Differentiation And Carcinogenesis», Lille/France, <sup>2</sup>University  
Hospital Of Lille, France, Lille/France

**Background:** Cytotoxicity mechanisms of reflux leading to Esophageal Adenocarcinoma (EA) remain poorly understood. The aim of the study was to

perform a critical appraisal of accuracy of a surgically-induced chronic gastro-duodenal reflux rat model.

**Methods:** Among 285 Sprague Dawley rats, two experimental groups were constructed performing esoduodenal anastomosis with or without gastrectomy to induce duodeno-esophageal reflux (DER group, n = 119) and duodeno-gastro-esophageal reflux (DGER group, n = 124). Control groups included (i) esophageal anastomosis with Roux-en-Y loop, (ii) laparotomy alone, (iii) subtotal gastrectomy (DGR group), (iv) proton pump inhibitor group (PPI group). Rat esophagus was harvested for histological and molecular analysis.

**Results:** Prevalence of Barrett Esophagus (BE), dysplasia and EA in experimental groups was 40.7%, 6.5%, and 11.1%, respectively. DGR group's analysis suggested that BE occurred through de novo intestinal metaplasia and migration of duodenal cells. From 13 EA, 5 were mixed adenocarcinomas. No distant metastases were identified. Rat lesions' molecular characteristics of BE (Villin, Cdx-2, Muc2) and EA (VEGF, COX2, ErbB1, Ki67, Smad4, PI3K, NFkB) were similar to those found in humans. BE was more frequently, and dysplasia and EA less frequently, in the DER group when compared to the DGER group (44.4 vs. 23.8%, P = 0.038 and 6.7% vs. 25.4%, P = 0.012, respectively). In the PPI group, esophageal lesion occurred less frequently vs DGER group (p = 0.019).

**Discussion:** Despite histological and molecular similarities with humans, pathophysiological accuracy of the rat esoduodenal reflux model for studying esophageal carcinogenesis is questionable. Demonstration of the pivotal role of gastric juice reinforces some recent clinical views.

**Disclosure:** All authors have declared no conflicts of interest.

#### P11.06 IDENTIFICATION OF EMX2 AS A POTENTIAL CANCER STEM CELL (CSC)-RELATED GENE FOR ESOPHAGEAL SQUAMOUS CELL CARCINOMA

Shoichi Fumoto<sup>1</sup>, Katarina Gradin<sup>1</sup>, Hideaki Nakamura<sup>1</sup>, Tsuyoshi Noguchi<sup>2</sup>, Lorenz Poellinger<sup>1</sup>

<sup>1</sup>Department Of Cell And Molecular Biology, Karolinska Institutet, Stockholm/SWEDEN, <sup>2</sup>Surgical Division, Center For Community Medicine, Faculty Of Medicine, Oita University, Yufu City, Oita/JAPAN

**Background:** The cancer stem cell model is still hypothetical in solid tumors and no clinically useful marker has been found for it. EMX2 is a transcription factor that has been extensively studied in the development of the central nervous system but has so far never been studied as a tumor-related gene.

**Methods:** EMX2 expression levels were evaluated by real-time RT-PCR analyses in 20 esophageal squamous cell carcinoma (ESCC) cell lines and 18 ESCC tissue samples. The clinical prognosis was assessed using a Kaplan-Meier analysis. The effects of EMX2 overexpression on colony formation capacity in soft agar, and tumorigenicity in immunodeficient (NOD)-scid mice were examined in ESCC cell lines. The SP (side population) and MP (main population) fractions sorted from EMX2 overexpressing and control cells by Hoechst red and Hoechst blue filters using FACSARIA were subjected to colony formation assay with soft agar, and comprehensive gene expression analysis.

**Results:** The EMX2 expression status in ESCC cell lines showed an all-or-none pattern, and was highly associated with colony formation capacity in soft agar, increased tumorigenicity in immunodeficient mice, and poor prognosis for the patients. Only the SP cells with EMX2 overexpression, but not MP cells or vector transfected cells, showed high colony formation capacity. Moreover, several CSC-related genes and HIF-1 $\alpha$  target genes were up-regulated in the SP cells following EMX2 overexpression.

**Discussion:** We propose that EMX2 gene is a novel prognostic marker for ESCC regulating tumorigenicity and anchorage-independent growth, and may function as a CSC-related gene in ESCC.

**Disclosure:** All authors have declared no conflicts of interest.

#### P11.07 ROLES OF XB130, A NOVEL ADAPTOR PROTEIN, IN ESOPHAGEAL SQUAMOUS CELL CARCINOMA

Atsushi Shiozaki<sup>1</sup>, Toshiyuki Kosuga<sup>1</sup>, Hitoshi Fujiwara<sup>1</sup>, Daisuke Ichikawa<sup>1</sup>, Shuhei Komatsu<sup>1</sup>, Kazuma Okamoto<sup>1</sup>, Yasutoshi Murayama<sup>1</sup>, Yoshiaki Kuriu<sup>1</sup>, Hisashi Ikoma<sup>1</sup>, Masayoshi Nakanishi<sup>1</sup>, Toshiya Ochiai<sup>1</sup>, Yukihito Kokuba<sup>1</sup>, Mingyao Liu<sup>2</sup>, Eigo Otsuji<sup>1</sup>

<sup>1</sup>Division Of Digestive Surgery, Department Of Surgery, Kyoto Prefectural University Of Medicine, Kyoto/JAPAN, <sup>2</sup>Latner Thoracic Surgery Research Laboratories, University Health Network Toronto General Research Institute, Toronto/ON/CANADA

**Background:** Adaptor proteins can participate in the regulation of various cellular functions. A novel adaptor protein, XB130, has been implicated as a substrate and regulator of tyrosine kinase-mediated signaling and in controlling cell proliferation and apoptosis in several cancer cells. However, its

expression and role in gastrointestinal cancer have not been investigated. In the present study, we sought to determine the role of XB130 in cell cycle progression of esophageal squamous cell carcinoma cells and examine its expression and effects on the prognosis of patients with esophageal cancer.

**Methods:** Expression of XB130 in human esophageal squamous cell carcinoma cell lines was analyzed by western blotting and immunofluorescent staining. Knockdown experiments with XB130 siRNA were conducted, and the effect on cell cycle progression was analyzed. Immunohistochemistry of XB130 for 52 primary tumor samples obtained from patients with esophageal squamous cell carcinoma undergoing esophagectomy was performed.

**Results:** XB130 was highly expressed in TE2, TE5, and TE9 cells. In these cells, knockdown of XB130 using siRNA inhibited G<sub>1</sub>-S phase progression and increased the expression of p21, the cyclin-dependent kinase inhibitor. Immunohistochemistry showed that 71.2% of the patients expressed XB130 in the nuclei and/or cytoplasm of esophageal squamous cell carcinoma cells. Further, nuclear expression of XB130 was an independent prognostic factor of postoperative survival.

**Discussion:** These observations suggest that the expression of XB130 in esophageal squamous cell carcinoma cells may affect cell cycle progression and impact prognosis of patients with esophageal cancer. A deeper understanding of XB130 as a mediator and/or biomarker in esophageal cancer is implicated.

**Disclosure:** All authors have declared no conflicts of interest.

#### P11.08 ROLES OF XCT, CYSTEINE/GLUTAMATE TRANSPORTER, IN ESOPHAGEAL SQUAMOUS CELL CARCINOMA

Atsushi Shiozaki, Daisuke Iitaka, Hitoshi Fujiwara, Daisuke Ichikawa, Shuhei Komatsu, Kazuma Okamoto, Yasutoshi Murayama, Yoshiaki Kuriu, Hisashi Ikoma, Masayoshi Nakanishi, Toshiya Ochiai, Yukihito Kokuba, Eigo Otsuji

Division Of Digestive Surgery, Department Of Surgery, Kyoto Prefectural University Of Medicine, Kyoto/JAPAN

**Background:** xCT is a component of the cysteine/glutamate transporter, which plays a key role in glutathione synthesis. Although previous studies have shown that it is highly expressed in several cancer cell lines and plays a role in their proliferation, its clinical significance remains to be fully elucidated. We knocked down xCT in esophageal squamous cell carcinoma cells and examined its expression in patients with esophageal cancer and its effects on their prognosis.

**Methods:** xCT expression in human esophageal squamous cell carcinoma cell lines was analyzed by Western blotting and immunofluorescent staining. Knockdown experiments were conducted with xCT siRNA, and the effect of xCT knockdown on cell cycle progression was analyzed. The cells' gene expression profiles were analyzed by microarray analysis. An immunohistochemical analysis of 49 primary tumor samples obtained from patients with esophageal cancer was also performed.

**Results:** xCT was highly expressed in TE13 and KYSE170 cells. In these cells, the knockdown of xCT using siRNA inhibited G<sub>1</sub>-S phase progression. Microarray analysis identified 1652 genes whose expression levels in TE13 cells were altered by the knockdown of xCT. Pathway analysis showed that the top-ranked canonical pathway was the G<sub>1</sub>/S checkpoint regulation pathway. Immunohistochemical staining showed that xCT is mainly found in the nuclei of carcinoma cells, and that its expression is related to lymph node metastasis and is an independent prognostic factor.

**Discussion:** These observations suggest that the expression of xCT in esophageal squamous cell carcinoma cells might affect the cell cycle and impact on the prognosis of patients with esophageal cancer.

**Disclosure:** All authors have declared no conflicts of interest.

#### P11.09 GRANULOCYTE-COLONY STIMULATING FACTOR (G-CSF)-PRODUCING ESOPHAGEAL SQUAMOUS CELL CARCINOMA.: A CASE REPORT

Takeshi Shimakawa, Yoshihiko Naritaka, Shinichi Asaka, Kentaro Yamaguchi, Minoru Murayama, Takao Katsube, Akira Miyaki, Noriyuki Isohata, Shunichi Shiozawa, Hajime Yokomizo, Kazuhiko Yoshimatsu, Kenji Ogawa

Tokyo Women'S Medical University Medical Center East, Tokyo/JAPAN

**Background:** G-CSF-producing malignant tumor of the esophagus is extremely rare. We report a case of a 70-year-old man who was diagnosed to have G-CSF-producing esophageal squamous cell carcinoma (SCC).

**Methods:** The patient was diagnosed as possibly having moderately differentiated SCC based on a histological examination of endoscopic biopsy specimens. Further examination led to a final diagnosis of esophageal carcinoma (type 2, T3, N2, M0, Stage III). After the patient received 3 courses of FAP (5FU, ADM, CDDP) neoadjuvant chemotherapy, complete response of the esophageal lesion and stable disease of the lymph node metastases had been achieved.

**Results:** The patient's white blood cell was increased on admission, but normalized after chemotherapy. So the patient underwent subtotal esophagectomy and two-field lymph node dissection. The histological efficacy of the chemotherapy was determined to be Grade 3 of the esophageal lesion and Grade 1a of intramural metastasis in stomach. After 3 months of the surgery, liver metastasis was detected and the white blood cell was increased again with no evidence of systematic infection or hematological disease. Then, the patient's serum G-CSF concentration was examined and found to be 254 pg/ml. Immunohistochemical examination showed cells that were positive for antibodies against G-CSF in the resected specimen. Therefore, we diagnosed the patient as having G-CSF-producing esophageal SCC. The patient received chemotherapy, but he died of tumor one year after the surgery.

**Discussion:** The prognosis of G-CSF-producing esophageal SCC is also extremely poor, and it was reported that many patients died within approximately one year after diagnosis.

**Disclosure:** All authors have declared no conflicts of interest.

#### P11.10 INVESTIGATION OF METHYLATION OF E-CADHERIN PROMOTER REGION IN IRANIAN PATIENTS WITH SQUAMOUS CELL CARCINOMA OF ESOPHAGUS (SCCE)

Shahla Mohammad Ganji<sup>1</sup>, Elham Samei<sup>2</sup>, Ferdous Rastgar-Jazi<sup>1</sup>, Abbas Sahebghadam-Lotfi<sup>1</sup>, Mojgan Saghadzadeh<sup>3</sup>, Frozandeh Fereidooni<sup>4</sup>  
<sup>1</sup>Nigeb, Tehran/IRAN, <sup>2</sup>Department Of Genetics, Science And Research Branch, Islamic Azad University, Tehran, Tehran/IRAN, <sup>3</sup>Department Of Microbiology, Qom Branch, Islamic Azad University, Qom/IRAN, <sup>4</sup>Department Of Pathology, Cancer Institute, Imam Khomeini Hospitals Complex, Tehran/IRAN

**Background:** It is observed the downregulation of E-cadherin(CDH1) gene expression in many carcinomas. The initial studies on methylation of the E-cadherin promoter established a relationship between E-cadherin silencing and the methylation of CpG islands in several carcinoma cell lines. To this aim, we studied the methylation status of CDH1 in patients with SCCE in Iran as the first study in this field.

**Methods:** For this reason, we studied for methylation at the CDH1 on 44 fresh tumor tissues and 19 non-tumor adjacent normal tissues, obtained from 44 patients affected by SCCE in Iran. We have done the bisulfate treatment on DNAs extracted of tissues for carrying up methylation-specific polymerase chain reaction(MSP). MSP has done with two set of specific primers for methylated and unmethylated status of CDH1. Moreover, we have examined the expression of this gene by RT-PCR with two set of specific primers for CDH1 and  $\beta$ -actin.

**Results:** The results showed the 54.5% methylation at the CDH1 in the tumor samples, while none of the non-tumor tissues exhibited the aberrant methylation. Also, RT-PCR experiments confirmed the expression of E-cadherin in all of non-tumor samples and unmethylated tissues. Among biopathological features, a significant association was found between Lymph node invasion of tumors as well as stages T2 and T3 of tumors with methylation of CDH1 ( $P < 0.05$ ).

**Discussion:** These data suggest that epigenetic silencing via aberrant methylation of the E-cadherin promoter is the critical mechanism for inactivation of this gene in esophageal cancer.

**Disclosure:** All authors have declared no conflicts of interest.

#### P11.11 TUMOR SUPPRESSOR PROTEINS AS THE CANDIDATE OF EARLY ESOPHAGEAL TUMORIGENESIS MARKERS

Hiroshi Okumura, Yasuko Uchikado, Yoshiaki Kita, Itaru Omoto, Masataka Matsumoto, Tetsuhiro Owaki, Sumiya Ishigami, Shoji Natsugoe  
Department Of Digestive Surgery, Breast And Thyroid Surgery Graduate School Of Medical Sciences, Kagoshima University, Kagoshima/JAPAN

**Background:** The FHIT (Fragile Histidine Triad) and Nit1 genes are tumor suppressor genes, and their deficiency confers a cancer prone phenotype in mice. We have assessed the tumor susceptibility of Fhit<sup>-/-</sup>/Nit1<sup>-/-</sup> double knockout mice and observed spontaneous and carcinogen induced tumorigenicity, and evaluate whether Nit1 and Fhit deficiency can be an early esophageal tumorigenesis marker.

**Methods:** Fhit knockout mice (FKO, n = 25) and Fhit and Nit1 double knockout mice (DKO, n = 37) were generated and evaluated the esophageal tumor development with or without an administration of carcinogen; N-nitrosomethylbenzylamine (NMBA). Then, the expressions of cyclinD1, Ki-67, and Bcl-2 in gastrointestinal tract tissues of DKO, and normal mice were examined and compared. Additionally, the expressions of Fhit and Nit1 protein in human esophageal cancer tissue were examined.

**Results:** Among those four groups, FKO/NMBA-, FKO/NMBA+, DKO/NMBA-, DKO/NMBA+, grossly observed tumor number of upper digestive

were 0/ 3.1/ 0.3/ 5.0, respectively. In histological examination, the incidence of epithelial dysplasia was 0/ 45/ 33/ 62% in esophagus. The expressions of CyclinD1 and Ki-67 in the normal epithelial tissue of DKO mice were higher, while Bcl-2 expression was very low compared with wild type mice. The reduced expression ratio of Nit1 or Fhit protein in human esophageal cancer tissue were 82% (Nit1: 48%/ Fhit: 69%), and there was no significant correlation between those two proteins.

**Discussion:** To evaluate the expression of Nit1 or/ and Fhit in the esophageal epithelial might be useful for early detection of cancer.

**Disclosure:** All authors have declared no conflicts of interest.

#### P11.12 CLINICOPATHOLOGICAL FEATURES OF ESOPHAGEAL MALIGNANT TUMOR IN PATIENTS UNDER 50 YEARS OLD

Yoshiko Aikawa<sup>1</sup>, Yasuhiro Tsubosa<sup>2</sup>, Hiroshi Sato<sup>2</sup>, Hirofumi Yasui<sup>3</sup>, Masaki Tanaka<sup>2</sup>, Hiroaki Sawai<sup>2</sup>, Takuji Kaburagi<sup>2</sup>, Satoshi Kamiya<sup>2</sup>  
<sup>1</sup>Shizuoka Cancer Center, Sunto-gun Shizuoka/JAPAN, <sup>2</sup>Shizuoka Cancer Center, Nagaizumi/JAPAN, <sup>3</sup>Shizuoka Cancer Center, Shizuoka/JAPAN

**Background:** Esophageal malignant tumor (EMT) often develop from 60 to 70 years of age. EMT patients under 50 years old constitute only about 6%. So the clinicopathological features are not known in detail. We examined the features of the patients treated in our hospital.

**Methods:** We examined 39 patients under 50 years old with EMT. The male to female ratio was 29:10. Curative surgery (S) was performed on 9 patients, curative or palliative chemoradiotherapy (CRT) on 20, chemotherapy (C) on 4, and endoscopic resection (ER) on 6.

**Results:** The classification of clinical staging was Stage I for 11 patients, Stage IIA for 4, Stage III for 6, Stage IVA for 5, and Stage IVB for 13. Regarding histological type, 36 cases were squamous cell carcinomas and 3 cases were others. The 3-year survival rate for ER group, S group, CRT group and C group was 100%, 72.9%, 42.1% and 0%, respectively. In S group, there were no hospital deaths, and the median hospital stay after surgery was 18 days. The completion rate of CRT was 100%. There were no grade 4 adverse events in any of the patients who underwent CRT.

**Discussion:** The EMT patients after ER or S had good prognoses. There were few postoperative complications. Even where complications occurred, recovery was quick. Furthermore, there were no grade 4 adverse events in any of the cases of CRT. So for EMT patients under 50 years of age we should perform accurate three-field lymph node dissection or definitive chemoradiotherapy. Then long-term prognoses might be expected.

**Disclosure:** All authors have declared no conflicts of interest.

#### P11.13 EXPRESSION OF CYCLOOXYGENASE2 (COX2) AND P53 IN RAT ESOPHAGEAL CANCER INDUCED BY REFLUX OF DUODENAL CONTENTS.

Naoki Hashimoto  
Kinki University, Osakasayama/JAPAN

**Background:** It is known that reflux of duodenal contents can induce mucosal injury, stimulate cell proliferation, and promote tumorigenesis. Cyclooxygenase (COX2), an inducible form of COX, has been implicated in both inflammation and carcinogenesis. We examined the expression of COX2 and P53 in rat esophageal lesions induced by duodenal contents reflux.

**Methods:** Thirty 8 week old male wistar rats were exposed to duodenal content esophageal reflux. All animal underwent an esophagoduodenal anastomosis(EDA) with total gastrectomy in order to produce chronic esophagitis. Ten rats were the sham (Control). They were sacrificed at the 40<sup>th</sup> week. Their esophagi were examined for HE, COX2, P53 and Proliferating cell nuclear antigen (PCNA).

**Results:** CLE was observed in 40% at the 40<sup>th</sup> week. Severe dysplasia in the lower esophagus occurred 100%, squamous cell carcinoma was observed in 40% and adenocarcinoma was observed 30% at the 40<sup>th</sup> week. PCNA labeling index of dysplasia and cancer (75 ± 5) was higher than that of control (30 ± 5). COX2 immunoreactivity was mainly observed in infiltrating cells and fibroblasts in the stroma. There were some epithelial cells of SCC and ADC strongly expressed COX2 protein. Wild type p53 protein accumulation was observed as a positive nuclear staining in ADC, while it was negative in SCC.

**Discussion:** Reflux of duodenal contents into the esophagus led to ADC and SCC in rat. COX2 may play an important role in esophageal cancer by duodenal content reflux. Our present results suggest an association between wild type P53 accumulation and COX2 expression in ADC, with no such relation seen in SCC.

**Disclosure:** All authors have declared no conflicts of interest.



#### P11.14 CLINICAL SIGNIFICANCE OF UBIQUITIN-LIKE PROTEIN IN ESOPHAGEAL SQUAMOUS CELL CARCINOMA

*Yoshio Ishibashi*, Hideyuki Kashiwagi, Norio Mitsumori, Nobuo Omura, Koji Nakada, Katsunori Nishikawa, Fumiaki Yano, Kazuto Tsuboi, Yuichiro Tanishima, Akira Matsumoto, Koji Takada, Katsuhiko Yanaga  
*Jikei University School Of Medicine Department Of Surgery, Tokyo JAPAN*

**Background:** SUMO-1 (small ubiquitin-related modifier-1) is a novel ubiquitin-like protein that is conjugated like ubiquitin, by a set of enzymes to cellular regulatory proteins including oncogenes and tumor suppressor genes. In this study, we aimed to investigate the significance of SUMO-1 expressions in cancerous esophageal lesions as a prognostic factor.

**Methods:** Tissue samples from 101 patients with esophageal squamous cell carcinoma were stained with anti-SUMO-1 antibody for immunohistochemical analysis. Using oligonucleotide microarrays, we analysed total RNA expression levels of ubiquitin-related genes in paired cancerous and normal tissue operative specimens in 12 patients. Immunoblot analysis of the paired cancerous and normal tissue samples were examined using an anti-SUMO-1 antibody.

**Results:** SUMO-1 overexpression in cancerous tissues was related to lymphatic vessel invasion ( $p < 0.001$ ). Hierarchical clustering analysis using gene expression ratios (cancer/normal) divided the 12 patients into two groups. The expression of SUMO-1 was up-regulated in the poor prognostic cluster. Various bands of proteins conjugated with SUMO-1 were present in both cancerous and normal tissues. In esophageal squamous cell carcinoma, some peculiar bands which were absent in the normal tissue were recognized.

**Discussion:** In esophageal squamous cell carcinoma, overexpression of SUMO-1 correlated with lymphatic vessel invasion and a poor prognosis. SUMO-1 conjugation may important in the course of tumorigenesis.

**Disclosure:** All authors have declared no conflicts of interest.

#### P11.15 EXPRESSION AND FUNCTION OF TOLL-LIKE RECEPTORS IN ESOPHAGEAL CANCER CELLS

*Yusuke Sato*, Satoru Motoyama, Kei Yoshino, Tomohiko Sasaki, Akiyuki Wakita, Yushi Nagaki, Syuetsu Usami, Junichi Ogawa  
*Akita University Graduate School Of Medicine, Akita JAPAN*

**Background:** Toll-like Receptors (TLRs) are receptor proteins that recognize specific molecular patterns derived from bacteria, virus, fungus and other pathogenic agent (PAMPs: pathogen associated molecular patterns) and has crucial role in activation of innate immunity and following acquired immunity. TLRs also recognize endogenous molecular patterns released from injured or dying own cells (DAMPs: damage associated molecular patterns) and induces chronic inflammation. Recent evidences show that TLRs are expressed in several types of cancers and are associated with carcinogenesis, cancer progression and metastasis. However, relationship between TLRs and esophageal cancer is not well understood.

**Methods:** We analyzed mRNA expression status of TLR1-10 among 16 esophageal cancer cell lines (14 squamous cell carcinoma and 2 adenocarcinoma) by RT-qPCR using Light Cycler 480. To clarify the functional activity of TLRs those are highly expressed by esophageal cancer cells, cell line proliferation assay with TLR ligands treatment were employed. Moreover, mRNA expression change of several kinds of cytokines after TLR ligands treatment was analyzed by RT-qPCR.

**Results:** Esophageal cancer cells showed strong expression of TLR3, 4, 5 and 6 compared to PBL (peripheral blood leukocytes). Especially, TLR3 showed about 40 times high expression of PBL in all esophageal squamous cell carcinoma lines. Treatment with Poly(I:C), ligand of TLR3 reduced proliferation of esophageal cancer cells and upregulated mRNA expressions of several kinds of cytokines through TLR signaling.

**Discussion:** TLR3 is strongly expressed in all esophageal squamous cell carcinoma lines and has a crucial role in the proliferation of these cells. Therefore TLR3 is a candidate of molecular target treatment for esophageal squamous cell carcinoma.

**Disclosure:** All authors have declared no conflicts of interest.

#### P11.16 BARRETT'S ESOPHAGUS AND ADENOCARCINOMA RISK: THE EXPERIENCE OF THE NORTH-EAST ITALIAN REGISTRY (EBRA)

*Lisa Zanatta*<sup>1</sup>, Paola Parente<sup>2</sup>, E.B.R.A. Group<sup>1</sup>  
<sup>1</sup>University Of Padua, Department Of Surgical And Gastroenterological Sciences, Clinica Chirurgica I, Padua ITALY, <sup>2</sup>Pathological Department, Padua ITALY

**Background:** Barrett's Esophagus (BE) is associated with an increased risk of esophageal adenocarcinoma (EAC), characterized by a dismal prognosis – unless patients are detected early by BE surveillance programs. No

consistent data are available on the prevalence of BE-related cancer and on the ideal surveillance schedule or the risk factors for cancer.

**Methods:** In 2004, a regional registry of BE patients was established in our region (the EBRA Registry), after establishing the diagnostic criteria (endoscopic landmarks, biopsy protocol, histological classification) and the timing of follow-up (tailored to histology).

**Results:** HG-IEN (intra-epithelial neoplasia) and EAC detected at first endoscopy or in the first year of follow-up were considered as cases of prevalent disease; 841 patients with at least 2 endoscopies (median 3 [IQR: 2–4]; median follow-up = 44.6 [IQR: 24.7–60.5] months) formed the study group (M/F = 646/195, median age 60 [IQR: 51–68]). Twenty-two patients progressed to HG-IEN or BAC (incidence 0.72 per 100 patient/years) after a median 40.2 (26.9–50.4) months. At multivariate analysis, endoscopic abnormalities, i.e. ulceration or nodularity ( $p .0002$ , RR 7.6, CI 2.63–21.9), LG-IEN ( $p .02$ , RR 3.7, CI 1.22–11.43), and BE length ( $p .01$ ; RR 1.16, CI 1.03–1.30) were associated with BE progression. Among the LG-IEN patients, the incidence of HG-IEN/EAC was 3.17 patient/years, i.e. six times higher than in IEN patients without IM.

**Discussion:** These results suggest that in the absence of intraepithelial neoplastic changes, BE carries a low risk of progression to HG-IEN/BAC; strict surveillance is advisable in cases with endoscopic abnormalities, LG-IEN or long BE segments.

**Disclosure:** All authors have declared no conflicts of interest.

#### P11.17 CLINICOPATHOLOGICAL STUDIES OF ESOPHAGEAL CARCINOMA ASSOCIATED WITH ACHALASIA: ANALYSES OF ITS CARCINOGENESIS USING HISTOLOGICAL PROCEDURES

*Osamu Chino*, Akihito Kazuno, Eisuke Ito, Minoru Nakui, Tadashi Hara, Soichiro Yamamoto, Tomoko Hanashi, Yoshifumi Kise, Takayuki Nishi, Hideo Shimada, Soji Ozawa, Hiroyasu Makuuchi  
*Tokai University School Of Medicine, Isehara, Kanagawa JAPAN*

**Background:** Esophageal carcinoma is the most serious late complication of achalasia. Chronic inflammatory irritation may induce carcinogenesis of the esophageal squamous epithelium. However, the detailed mechanism of carcinogenesis in achalasia has not been clarified histopathologically.

**Methods:** We analyzed seventeen cases of achalasia-associated squamous cell carcinoma of the esophagus clinicopathologically. We analysed six cases, surgically or endoscopically resected, using histological and immunohistochemical procedures. The invasive parts in situ carcinoma, dysplasia as well as hyperplasia were examined.

**Results:** The patients ranged in age from 48 to 76 years, with a mean age of 63.4 years. The mean interval between the diagnosis of achalasia and carcinoma was 22.9 years. Eight of the seventeen cases were superficial cancers, and the other nine cases were advanced cancers. Radiographically, nine of the seventeen cases were sigmoid type, the other eight cases were flask type. Six cases were grade III, the other eleven cases were grade II. Endoscopically, seven carcinomas were protruding type, and the others were superficial depressed type and ulcerative type. Histological mapping of the resected specimens demonstrated marked hyperplastic changes of stratified squamous epithelium and multiple foci of dysplastic changes. The squamous cell carcinomas showed differentiated type with low-grade atypia, closely associated with dysplastic foci. Immunohistochemical over-expression of p53 was detected in the invasive parts, in situ carcinoma, and dysplasia.

**Discussion:** Chronic inflammatory irritation may induce hyperplastic esophagitis and eventually malignant transformation of esophageal epithelium associated with dysplasia-carcinoma sequence. Long-term follow-up for patients with achalasia by endoscopic screening is recommended.

**Disclosure:** All authors have declared no conflicts of interest.

#### P11.18 MULTIPLE EARLY CARCINOMAS OF THE ESOPHAGUS ASSOCIATED WITH ACHALASIA TREATED BY ENDOSCOPIC SUBMUCOSAL DISSECTION

*Osamu Chino*, Akihito Kazuno, Eisuke Ito, Minoru Nakui, Soichiro Yamamoto, Takayuki Nishi, Hideo Shimada, Soji Ozawa, Hiroyasu Makuuchi  
*Tokai University School Of Medicine, Isehara, Kanagawa JAPAN*

**Background:** Achalasia is known as a risk factor of squamous cell carcinoma of the esophagus. The increased risk of developing esophageal carcinoma has been postulated in the patients with long-standing achalasia. Chronic inflammatory irritation by retained food may induce carcinogenesis of the esophageal squamous epithelium.

**Methods:** A case of two lesions of early esophageal carcinomas associated with postoperative achalasia treated by endoscopic submucosal dissection (ESD) is reported clinicopathologically.

**Results:** A 46-year-old man was made diagnosis of esophageal achalasia in 2001, flask type and Grade II measuring 5 cm in diameter, and had been

treated by pneumatic dilatation for symptomatic achalasia conservatively. The patient was operated by Tokai University method, Heller's long esophagomyotomy, Hill's posterior cardiopexy, fundoplication and selective proximal vagotomy using a laparotomy in August 2009. One year and three months after the operation, two lesions of early carcinomas of type 0-IIb and 0-IIc, each 1 cm in size, were detected in the middle thoracic esophagus, and treated by endoscopic submucosal dissection using EEMR-tube double-channel ESD method. Pathological examination of the each lesion revealed proliferation of squamous cell carcinoma in situ (T1a-EP: M1).

**Discussion:** The entire esophageal mucosa around the carcinoma demonstrated hyperplastic changes of stratified squamous epithelium and foci of intraepithelial neoplasia. In the patient of achalasia, food stasis in esophagus is thought to induce chronic hyperplastic esophagitis, converting eventually to malignant transformation. Careful long-term follow-up for patients of achalasia by endoscopic screening is recommended, even if after the treatment by pneumatic dilatation or operation for achalasia.

**Disclosure:** All authors have declared no conflicts of interest.

#### P11.19 BARRETT'S ESOPHAGUS: OXIDATIVE DAMAGE AND TELOMERIC DYSFUNCTION

Marika Picocchi<sup>1</sup>, Romilda Cardin<sup>1</sup>, Chiara Tieppo<sup>1</sup>, Gemma Maddalo<sup>2</sup>, Massimo Rugge<sup>3</sup>, Matteo Fassan<sup>3</sup>, Valerio Zorzetto<sup>1</sup>, Giovanni Zaninotto<sup>1</sup>, Fabio Farinati<sup>1</sup>  
<sup>1</sup>Department Of Surgical Oncological And Gastroenterological Sciences, University Of Padova, Padova/ITALY, <sup>2</sup>Venetian Oncological Institute, Irccs, Padova/ITALY, <sup>3</sup>Department Of Medical Diagnostic Sciences, Padova/ITALY

**Background:** Barrett's esophagus (BE) develops in a scenario of chronic inflammation linked to oxidative DNA damage. OGG1 gene polymorphism plays a role in 8-hydroxydeoxyguanosine (8-OHdG) repair. Telomeres length is maintained by telomerase activity, with limited data available in BE. Telomeres' elongation determines cell immortalization. The aim was to evaluate the role of 8-OHdG, OGG1 polymorphism, telomerase activity and telomere's length (TL) in BE.

**Methods:** Forty patients with Short (SSBE) or Long segment (LSBE) BE and 20 with GERD without BE (C) were included. Two biopsies were used to study: 8-OHdG levels (HPLC-ED); OGG1 polymorphism (PCR and RFLP); telomerase activity and TL (RT-PCR).

**Results:** The levels of 8-OHdG were twice as high in BE than in C ( $p = 0.0005$ ). Telomerase activity was significantly increased in both SSBE ( $p = 0.02$ ) and LSBE ( $p = 0.05$ ) compared to C. Regarding TL, there was a significant difference between SSBE and LSBE ( $p = 0.04$ ), with greater length in LSBE. The correlation between 8-OHdG and telomerase activity was significant overall ( $\rho = 0.50$ ,  $p = 0.0003$ ), in BE ( $\rho = 0.40$ ,  $p = 0.02$ ), in SSBE ( $\rho = 0.50$ ,  $p = 0.02$ ) and in C ( $\rho = 0.85$ ,  $p = 0.0001$ ). OGG1 polymorphism did not correlate with any parameter.

**Discussion:** In BE there is a strong correlation between oxidative damage and telomerase activity, confirming that telomeric DNA is particularly sensitive to oxidative damage. The similar levels of 8-OHdG and of telomerase activity in SSBE and LSBE, despite the different TL, indicate the presence of two different and separated phases, one early and one late, in carcinogenic process, the latter featuring a significant telomerase-mediated boost to cell immortalization.

**Disclosure:** All authors have declared no conflicts of interest.

#### P11.20 PROGNOSIS OF ESOPHAGEAL SQUAMOUS CELL CARCINOMA IN PATIENTS POSITIVE FOR HUMAN EPIDERMAL GROWTH FACTOR RECEPTOR FAMILY CAN BE IMPROVED BY INITIAL CHEMOTHERAPY WITH DOCETAXEL, FLUOROURACIL AND CISPLATIN

Yota Yamamoto<sup>1</sup>, Hiromichi Yamai<sup>2</sup>, Junichi Seike<sup>1</sup>, Takahiro Yoshida<sup>3</sup>, Yasuhiro Yuasa<sup>4</sup>, Yoshihito Furukita<sup>1</sup>, Koichiro Kajiuira<sup>1</sup>, Masakazu Goto<sup>1</sup>, Hirokazu Takechi<sup>1</sup>, Yoshimi Bando<sup>1</sup>, Akira Tangoku<sup>1</sup>  
<sup>1</sup>Tokushima University Hospital, Tokushima/JAPAN, <sup>2</sup>Kochi Red Cross Hospital, Kochi/JAPAN, <sup>3</sup>Higashi Tokushima Medical Center, Tokushima/JAPAN, <sup>4</sup>Tokushima Red Cross Hospital, Tokushima/JAPAN

**Background:** The human epidermal growth factor receptor (HER) family, Ki-67 and p53 are important biomarkers for several malignancies. However, few studies have examined the role of these in prognosis and therapeutic sensitivity of esophageal squamous cell carcinoma (ESCC). The efficacy of triple-drug combination therapy with docetaxel, fluorouracil and cisplatin has recently been expected for ESCC.

**Methods:** Subjects comprised 142 patients with ESCC who underwent operation (OP group,  $n = 54$ ), neoadjuvant chemotherapy with docetaxel, fluorouracil and cisplatin (DFP therapy) followed by operation (NAC group,  $n = 37$ ) or initial systemic DFP therapy (CT group,  $n = 51$ ) between January

2004 and December 2010. Immunohistochemical expressions of epidermal growth factor receptor (EGFR), HER2, HER3, Ki67 and p53 were evaluated and compared to prognosis and sensitivity to DFP therapy.

**Results:** Positive correlations existed between EGFR, HER2 and HER3 expressions. In the OP group, EGFR was independently associated with postoperative recurrence in multivariate analysis ( $p = 0.036$ ). In the NAC group, EGFR correlated with pathological response to DFP therapy ( $p = 0.004$ ). In the CT group, EGFR, HER2 and HER3 correlated with clinical response to DFP therapy and EGFR was independently associated with favorable prognosis in multivariate analysis ( $p = 0.022$ ).

**Discussion:** EGFR represents a predictor of postoperative recurrence and sensitivity to triple-drug combination therapy including a taxane. EGFR-positive patients may show improved prognosis with taxane combination chemotherapy and molecular targeted therapy for HER family members.

**Disclosure:** All authors have declared no conflicts of interest.

#### P11.21 GENDER DIFFERENCES IN ESOPHAGEAL ADENOCARCINOMA GENOMICS

Virginia Litle<sup>1</sup>, Irina Kalatskaya<sup>2</sup>, Santhoshi Bandla<sup>1</sup>, Arjun Pennathur<sup>3</sup>, James Luketich<sup>3</sup>, Tony Godfrey<sup>1</sup>  
<sup>1</sup>University Of Rochester, Rochester/NY/UNITED STATES OF AMERICA, <sup>2</sup>Ontario Institute For Cancer Research, Toronto/ON/CANADA, <sup>3</sup>University Of Pittsburgh, Pittsburgh/PA/UNITED STATES OF AMERICA

**Background:** Esophageal adenocarcinoma (EAC) occurs with an 8:1 male:female incidence. This gender difference is poorly understood with previous reports concluding no gender differences in the established EAC risk factors of gastroesophageal reflux disease and obesity. Barrett's esophagus, the strongest risk factor for EAC, occurs only 2-3 times more often in men. We hypothesized that a genome-wide comparison of EAC specimens from men and women may identify significant differences and identify potential mechanistic pathways.

**Methods:** EAC samples (98 male; 21 female) were analyzed to identify gender-biased DNA copy number variations (CNV's) using Affymetrix SNP 6.0 arrays. Gene expression profiling was performed using Affymetrix U133 Plus 2 arrays. Genes that were differentially expressed between female and male samples ( $p$ -value  $< 0.05$ ; fold-change  $> 0.5$ ) were identified. Network-based analysis was performed using the functional interaction (FI) network. Markov Cluster Algorithm was used for network clustering.

**Results:** 28 CNVs containing 841 genes were identified with significantly higher frequency in female EAC samples than in male EAC's. 952 genes were differentially expressed between male and female EAC, including 52 from CNV regions. The combined gene-set was analyzed to create a gender-associated FI network. Clustering identified 14 clusters. One significant cluster contained several down-regulated chemokines including the pro-inflammatory IL-8.

**Discussion:** Functional network analysis of male and female EAC samples identified significant down-regulation in pro-inflammatory chemokines and receptors in women compared with men. These findings suggest that a stronger inflammatory response to prolonged insult (GERD) may be one reason for the gender bias in EAC incidence.

**Disclosure:** All authors have declared no conflicts of interest.

#### P11.22 ESOPHAGEAL SPINDLE CELL CARCINOMA: A CASE REPORT

Ja-mun Chong<sup>1</sup>, Katsunori Ami<sup>2</sup>, Takeshi Nagahama<sup>2</sup>, Masayuki Andou<sup>2</sup>, Kuniyoshi Arai<sup>2</sup>, Masafumi Takimoto<sup>3</sup>, Hidekazu Ota<sup>3</sup>  
<sup>1</sup>Dept. Of Pathology, Toshima Hospital, Tokyo/JAPAN, <sup>2</sup>Dept. Of Surgery, Toshima Hospital, Tokyo/JAPAN, <sup>3</sup>Second Dept. Of Pathology, Showa University, Tokyo/JAPAN

**Background:** Spindle cell carcinoma of the esophagus is a rare malignancy composed of carcinoma and sarcomatous components. It has also been referred to as carcinosarcoma, pseudosarcoma, pseudosarcomatous squamous cell carcinoma, and polypoid carcinoma, reflecting the unclarity of its pathogenesis. We described a case of spindle cell carcinoma of the esophagus.

**Methods:** A 53-year-old male visited our hospital to have treatment for esophageal tumor which was detected by annual medical check-up. In upper endoscopic examination, the tumor was found in the lower part of the esophagus, and the biopsy examination revealed that the tumor was squamous cell carcinoma. The patient was performed a transthoracic esophagectomy.

**Results:** Gross examination revealed a polypoid tumor surrounded with a slightly elevated lesion located in the lower esophagus and upper stomach. The tumor size was  $5.0 \times 3.5$  cm. Microscopically, the tumor consisted with squamous cell carcinoma component and sarcomatous component. Both

components invaded in the submucosal layer. The nodal metastasis was not found. There were multiple leiomyomas in the muscularis propria of the upper stomach near the sarcomatoid carcinoma. In immunohistochemical study, the carcinoma showed positive signal for cytokeratin AE1/AE3, cytokeratin 34betaE12, and p63 antibodies in the carcinoma component, and for vimentin antibody in the sarcomatoid component. The recurrence of the tumor is not found for two years after the operation.

**Discussion:** We present a case of spindle cell carcinoma of the esophagus. The carcinogenesis and pathogenesis of the carcinoma and review of the literature will be discussed.

**Disclosure:** All authors have declared no conflicts of interest.

#### P11.23 ANTITUMOR EFFECTS OF NOVEL HISTONE DEMETHYLASE INHIBITOR ON ESOPHAGEAL SQUAMOUS CELL CARCINOMA

Isamu Hoshino, Yasunori Akutsu, Aki Komatsu, Naoyuki Hanari, Mikito Mori, Yasuo Yoneyama, Naoki Akanuma, Yuka Isozaki, Tetsuro Maruyama, Nobuyoshi Takeshita, Hisahiro Matsubara  
*Department Of Frontier Surgery, Chiba University, Chiba/JAPAN*

**Background:** Epigenetic changes like histone modifications are thought to underlie a wide range of diseases including various cancers. The expression of genes can be influenced by the balance of histone acetylation and/or histone demethylation and it might occur that a collapse of the balance in many cancers. So far, we have tried to elucidate the Histone deacetylation on esophageal squamous cell carcinoma (ESCC) and evaluate the effect of histone deacetylase inhibitors on ESCC. In this study, we investigated the expression levels of histone demethylases in ESCC tissue specimens and the antitumor effects of histone demethylase inhibitors, LSD1 and JMJD2 inhibitors, on ESCC cell lines.

**Methods:** Immunohistochemical staining was performed in 20 samples which were collected from surgical esophageal cancer specimens. Cytoplasmic staining of histone demethylases, LSD1 or JMJD2, was evaluated. Cell growth was determined by MTT assay. Apoptosis was also detected by TUNEL assay. In vivo effects of LSD1 inhibitor was assessed using nude mice xenograft models.

**Results:** LSD1 expression was observed in almost all ESCC specimens, on the contrary JMJD1 expression was not. The sensitivities for LSD1 inhibitor of ESCC cells, T.Tn and TE2, were evaluated with IC50 values of 34.15 and 31.54 ig/mL, respectively. Induction of apoptosis by LSD1 inhibitor was shown by TUNEL assay. LSD1 inhibitor showed significant antitumor effects on ESCC xenograft models.

**Discussion:** LSD1 inhibitor showed the antitumor effect on ESCC cell lines. Histone demethylase could be a promising target for treatment ESCC. We are now planning to explore the gene expression profiling by histone demethylase.

**Disclosure:** All authors have declared no conflicts of interest.

#### P11.24 MIR-203 REGULATES TUMOR MIGRATION AND INVASION BY TARGETING LASP1 IN ESOPHAGEAL SQUAMOUS CELL CARCINOMA

Nobuyoshi Takeshita, Mikito Mori, Isamu Hoshino, Yasunori Akutsu, Naoyuki Hanari, Yuka Isozaki, Naoki Akanuma, Hisahiro Matsubara  
*Chiba University, Chiba/JAPAN*

**Background:** The expression of microRNA-203 (miR-203) is significantly down-regulated in ESCC. The aim of this study was to investigate the functional role of miR-203 and its target in ESCC.

**Methods:** To identify genes targeted by miR-203, a microarray analysis was performed using the miR-203-transfected ESCC cell lines. For loss-of-function studies, miR-203/si-LASP1-transfectants were subjected to proliferation, migration and invasion assay. The target protector assay was used to confirm the actual binding sites between miR-203 and LASP1 mRNA. The mRNA and protein expression of LASP1 in ESCC cell lines and clinical samples were evaluated by real-time RT-PCR and Western blot, respectively.

**Results:** Gain-of-function analysis revealed that miR-203 inhibited cell migration and invasion in ESCC cells. Genome-wide gene expression data and target site inhibition assays suggested that miR-203 directly regulates LIM and SH3 protein 1 (LASP1). Knockdown of LASP1 resulted in the inhibition of cell migration and invasion in ESCC cells. The results suggest that miR-203 and its target LASP1 may be associated with ESCC progression. In clinical ESCC specimens, the expression levels of miR-203 were down-regulated in cancer tissues, which were inversely correlated with the mRNA expression levels of LASP1. In addition, Kaplan-Meier curves and log-rank tests revealed that there was a significant correlation between the low expression levels of miR-203 and poor relapse free survival (RFS).

**Discussion:** The identification of a cancer network regulated by miR-203 could provide new insights into the potential mechanisms of ESCC carcinogenesis and cancer development.

**Disclosure:** All authors have declared no conflicts of interest.

#### P11.25 CLINICAL VALUE OF SERUM TISSUE-INHIBITOR OF METALLOPROTEINASE 1 IN PATIENTS WITH ESOPHAGEAL CANCER

Mirosław Kozłowski<sup>1</sup>, Barbara Mroczko<sup>2</sup>, Maciej Szmítkowski<sup>2</sup>, Robert Milewski<sup>3</sup>, Jacek Niklinski<sup>1</sup>, Jerzy Laudanski<sup>1</sup>  
<sup>1</sup>*Medical University Of Białystok, Department Of Thoracic Surgery, Białystok/POLAND*, <sup>2</sup>*Medical University Of Białystok, Department Of Biochemical Diagnostics, Białystok/POLAND*, <sup>3</sup>*Medical University Of Białystok, Department Of Statistics And Medical Informatics, Białystok, Poland, Białystok/POLAND*

**Background:** The activities of matrix metalloproteinases contribute to invasion and metastases of esophageal cancer. We investigated the correlation between pretreatment serum levels of tissue inhibitor of metalloproteinase 1 (TIMP-1) and clinicopathologic features and survival in patients with esophageal cancer.

**Methods:** Serum TIMP-1 was measured by enzyme-linked immunoadsorbent assay (ELISA) on 89 patients with esophageal cancer, and 30 healthy controls. Levels of TIMP-1 were analyzed by nonparametric tests and univariate and multivariate survival analysis.

**Results:** Serum TIMP-1 levels were significantly higher in patients with esophageal carcinoma than in the control group (p = 0.001). Subgroup analysis showed that sex (p = 0.048), histological type (p < 0.001) and tumour depth (p = 0.02) were correlated with an elevated levels of TIMP-1. During follow-up, patients with resected tumors and with elevated levels of TIMP-1 had a significantly lower disease-free survival (p = 0.005).

**Discussion:** In locally advanced esophageal cancer, high levels of pretreatment serum TIMP-1 may be useful in predicting disease-free survival in patients undergoing a potentially curative esophagectomy.

**Disclosure:** All authors have declared no conflicts of interest.

#### P11.26 THE STEP STUDY: A STUDY OF THE PREVALENCE OF ESOPHAGEAL SQUAMOUS DYSPLASIA (ESD) – INTERIM RESULTS IN AN AREA ENDEMIC FOR ESOPHAGEAL SQUAMOUS CELL CARCINOMA (ESCC)

Michael Mwachiro<sup>1</sup>, Russell White<sup>1</sup>, Steve Burgert<sup>1</sup>, Robert Chepkwony<sup>1</sup>, Sanford Dawsey<sup>2</sup>, Christian Abnet<sup>2</sup>  
<sup>1</sup>*Tenek Hospital, Bomet/KENYA*, <sup>2</sup>*National Cancer Institute, Bethesda/MD/ UNITED STATES OF AMERICA*

**Background:** ESCC shows marked variation in incidence throughout the world. Although relatively uncommon in most of the world, it is the most common malignancy seen at our institution. We therefore assume that ESD, the precursor lesion of ESCC, is common in our region. This study seeks to determine the prevalence of ESD in our region, and explore the impact of demographic data and environmental exposures, with a long range view of developing an appropriate screening program for this devastating disease.

**Methods:** 124 asymptomatic adults living within 50 km of our institution underwent trans-oral videoendoscopy of the esophagus with Lugol's chromoendoscopy, mapping of identified lesions, and biopsy with pathologic evaluation. The overall prevalence of ESD, the age-adjusted prevalence of ESD and the sex and age-specific prevalence of ESD by decade were calculated. Association between potential risk factors and ESD were analyzed by univariate and multivariate logistic regression.

**Results:** of Endoscopic Screening

Diagnosis	Number	Frequency(%)
Normal	35	28.2
Mild esophagitis	52	42.0
Moderate/severe esophagitis	10	8.1
Mild dysplasia	22	17.7
Moderate dysplasia	4	3.2
Severe dysplasia	1	0.8

**Discussion:**

ESD is present in 21% of asymptomatic adults in our region. We anticipate completing this study with 300 total subjects. The results of this study will strongly influence future research directed at identifying etiologic factors and developing a screening program for regions in which ESCC is endemic.

**Disclosure:** All authors have declared no conflicts of interest.

### P11.27 DYSREGULATION OF INFLAMMATORY PATHWAYS IN BARRETT'S OESOPHAGUS AND OESOPHAGEAL ADENOCARCINOMA

Nicholas Shannon<sup>1</sup>, Chin-ann Ong<sup>2</sup>, Rebecca Fitzgerald<sup>2</sup>

<sup>1</sup>Cambridge Research Institute, Cambridge/UNITED KINGDOM, <sup>2</sup>Mrc Cancer Cell Unit, Cambridge/UNITED KINGDOM

**Background:** An inflammatory microenvironment, described as the seventh hallmark of cancer, has been linked to Barrett's carcinogenesis; current literature covers investigation of multiple different inflammatory signalling pathways although usually in isolation. The aim of this study was to concurrently examine dysregulation of multiple inflammation associated pathways in the Barrett's carcinogenesis sequence.

**Methods:** Expression microarray data from 8 oesophageal datasets was analysed as an overall progression set (n = 107 normal squamous, 91 Barrett's, 93 OAC) and an independent late-progression set from the same group and platform (n = 12 Barrett's, 30 Dysplasia, 83 OAC). Gene set enrichment analysis used genesets representing KEGG signalling pathways (pathway components) or pathway activation (pathway signatures).

**Results:** In the overall dataset frequency of enrichment of several inflammation associated pathways increased: Toll like receptor (TLR) (p = 0.003), TGF $\alpha$  (p < 0.001) and JAK-STAT (p = 0.004). Decreased frequency of the notch pathway, a potential inflammation suppression pathway was also observed (p = 0.042). In the late-progression dataset the frequency of the same pathways increased, but the trend was non-significant (p > 0.05), overenrichment scores increased for TLR (p < 0.004), and JAK-STAT (p < 0.026). Decreased frequency of the notch pathway was also observed (p = 0.021) In both datasets frequency of enrichment of pathway signatures increased: JAK-STAT (p < 0.011), NF $\kappa$ B (p < 0.027), and TGF $\alpha$  (p < 0.05).

**Discussion:** Dysregulation of signalling pathway components, and signatures representing activation were observed for TLR/NF $\kappa$ B, JAK-STAT and TGF $\alpha$ . Dysregulation of these pathways is likely to contribute to development of oesophageal adenocarcinoma and potentially treatment response. Inflammation has also been associated with EMT, and evidence suggests this confers poorer prognosis in oesophageal adenocarcinoma.

**Disclosure:** All authors have declared no conflicts of interest.

### P11.28 INFLAMMATION AND CANCER: EPIGENETIC MECHANISMS AFFECTING NF-KAPPAB IN BARRETT'S ESOPHAGUS

Caterina Branca<sup>1</sup>, Annamaria Lanzillotta<sup>1</sup>, Marina Pizzi<sup>1</sup>, Luigi Minelli<sup>2</sup>,

Nicolò De Pretis<sup>2</sup>, Dario Moneghini<sup>2</sup>, Guido Missale<sup>2</sup>, Renzo Cestari<sup>2</sup>

<sup>1</sup>Dept. Of Biomedical Sciences And Biotechnology, Brescia/ITALY,

<sup>2</sup>Digestive Endoscopy, Department Of Surgery, University Of Brescia, Brescia/ITALY

**Background:** Barrett's esophagus (BE) is a preneoplastic condition, characterized by the presence of a columnar metaplasia, as a result of chronic gastroesophageal reflux disease (GERD). The mechanisms involved in the occurrence of BE and progression to adenocarcinoma has not yet been clarified.

The nuclear factor kappaB (NF- $\kappa$ B) is a transcription factor, mainly involved in inflammatory processes, that has been proposed as a possible element of conjunction between inflammation and cancer. Several studies have demonstrated that the transcriptional activity of NF- $\kappa$ B may be altered by epigenetic mechanisms. In particular, the acetylation of RelA at the K310 residue (RelA-K310) enhance its transcriptional activity. We hypothesize that K310 acetylation sustains the constitutive activation of NF-kappaB, identified in cancer.

**Methods:** In all enrolled patients an esophagogastroduodenoscopy was performed with biopsies of the esophageal squamous epithelium, of the cardiac and BE mucosa and malignancy, if present. On these tissue samples was carried out the extraction of nuclear proteins and evaluation of RelA, acetylated RelA-K310 by co-immunoprecipitation and Western blot analysis.

**Results:** Evaluation of acetylated RelA-K310 versus total RelA showed a significant increase in BE and neoplastic tissue compared with control tissue, and the comparison between the BE with and without dysplasia has shown a progressive increase in acetylated form in the evolution to neoplasia.

**Discussion:** Evaluation of epigenetic mechanisms targeting NF-kappaB in GERD can provide a new diagnostic marker of individual susceptibility to cancer in patients with BE, and to support the histopathological evaluation in order to better define the BE grading.

**Disclosure:** All authors have declared no conflicts of interest.

### P11.29 CLINICOPATHOLOGICAL AND PROGNOSTIC SIGNIFICANCE OF EGFR OVER-EXPRESSION IN ESOPHAGEAL SQUAMOUS CELL CARCINOMA

Ulysses Ribeiro, Ibere Soares, Flavio Roberto Takeda, Marcos Tacconi, Sergio Szachnowicz, Suely Marie, Venancio Alves, Julio Rocha, Rubens Sallum, Ivan Ceconello

Department Of Gastroenterology – Esophageal Surgical Division. University Of São Paulo School Of Medicine, São Paulo – Brazil, São Paulo/BRAZIL

**Background:** The epidermal growth factor receptor (EGFR) has become a promising target for novel anticancer therapy. Evaluation of its biological profiles including amplification, and protein expression in esophageal squamous cell carcinoma (SCC) is critical to establish the EGFR molecular feature suitable to select patients in anti-EGFR therapy. Aim: To verify EGFR protein expression in esophageal SCC in selected patients who had undergone similar surgical treatment.

**Methods:** Tissue specimens from 88 esophageal SCC and normal esophageal epithelium within the surgically resected specimens were histopathologically analyzed from primary neoplasia and normal esophagus. The levels of messenger RNA (mRNA) and EGFR were quantified in all cases.

**Results:** The grade of differentiation was well in 20.4% moderately in 55.9% and poor differentiated in 23.7%. T1 was staged in 12.6%, T2 in 19.4%, T3 in 52.4 and T4 in 4.9%, while N0 was detected in 40.8%, N1 in 38.8, N2 in 8.7 and N3 in 11.7%. EGFR protein expression was higher in 48.9% of the patients, in both immunohistochemical and molecular analysis. There was no correlation between EGFR protein expression and clinicopathologic characteristics, including gender, age, grade of differentiation, tumor location or staging. The overall survival was associated to T and N stage (0.02 and 0.03), but not with EGFR expression (0.30).

**Discussion:** EGFR protein expression is frequently upregulated in esophageal squamous cell carcinoma, however, there was no association to studied clinicopathological features. Further prospective trials on targeted therapy against EGFR may confirm its value as novel approach to treating these tumors.

**Disclosure:** All authors have declared no conflicts of interest.

### P11.30 ROLE OF HPV TO ESOPHAGEAL CARCINOGENESIS

Cleber Kruel, Luis Felipe Ribeiro Pinto, Suellen Herbst, Cintia Ferrao, Tatiana Simão

Universidade Federal Do Rio Grande Do Sul, 440002/BRAZIL

**Background:** Although the role of HPV in carcinogenesis has been well established in many cancers, its contribution to esophageal squamous cell carcinoma (ESCCs) is still controversial, due to the wide variation in HPV prevalence and subtype observed, and to the detection methodologies applied.

**Methods:** Therefore, we determined, through GP5+/GP6+ nested PCR with direct sequencing and in situ hybridization assays, the prevalence of HPV in 264 samples from high and medium ESCC incidence areas of Brazil, and correlated it with the presence of surrogate markers such as p16 expression and TP53 mutations, as well as patients clinicopathological characteristics

**Results:** We showed that HPV is present in 13% of the tumors, but with a 3-fold variation between patients from high and medium ESCC incidence areas

**Discussion:** Although most HPV positive tumors (74%) were infected with HPV16 infection, a high risk subtype, the presence of HPV in ESCC was not associated with p16 expression, and absence or lower frequency of TP53 mutations. Different from head and neck tumors, HPV positive ESCCs were not associated with lower patient age, lower frequency of tobacco or alcohol consumption, or increased overall survival We conclude that although the high risk HPV 16 is the main subtype found in Brazilian patients and HPV infection is more prevalent in tumors from the high ESCC incidence area, the role of HPV in ESCC carcinogenesis in our population is questionable since it does not alter HPV associated surrogate markers or patients' clinicopathological parameters.

**Disclosure:** All authors have declared no conflicts of interest.

### P11.31 FIBROBLAST ACTIVATION IN THE TUMOR MICROENVIRONMENT PROMOTES TUMOUR CELL INVASION AND RESISTANCE TO CHEMOTHERAPY IN OESOPHAGEAL ADENOCARCINOMA

T J Underwood, A Heyden, M F Derouet, F Noble, J N Primrose, J P Blaydes, G Thomas

Cancer Sciences Unit, University Of Southampton Somers Cancer Research Building Southampton, Southampton/UNITED KINGDOM

**Background:** Stromal fibroblasts can undergo modifications that create a supportive microenvironment for tumour growth, invasion and metastasis.

This study investigates the role of Cancer Associated Fibroblasts (CAF) in oesophageal adenocarcinoma (EAC).

**Methods:** Functional biological analyses comparing primary fibroblasts from tumour stroma (CAF) and normal oesophagus (NOF) were performed using organotypic culture, siRNA gene silencing, transwell invasion, collagen-1 gel contraction, and colony forming assays. T-Tests were performed for statistical analyses.

**Results:** CAF displayed an activated phenotype, as demonstrated by  $\alpha$ -SMA stress fibre formation and increased collagen-1 gel contraction in comparison to NOF ( $p = 0.007$ ). This phenotype was replicated by TGF- $\beta$  treatment of NOF. CAF conditioned medium supported tumour colony formation in the presence of cisplatin compared to NOF conditioned medium ( $p < 0.05$ ). Ex-vivo analysis revealed a 2-fold ( $p < 0.05$ ) increase in EAC cell invasion in response to CAF conditioned medium in transwell assays and in 3D organotypic models containing co-cultures of fibroblasts and EAC cells. Downregulation of the CAF secreted molecule Periostin (PN) resulted in a 70% reduction in tumour cell invasion in transwells ( $p < 0.05$ ), and a total loss of invasion in organotypic culture. The formation of  $\alpha$ -SMA stress fibres and collagen-1 gel contraction was PN dependent in CAF and TGF- $\beta$  treated NOF.

**Discussion:** Oesophageal primary CAF are activated cells that protect EAC cells from chemotherapy and promote invasion. The fibroblast-derived protein Periostin is required for fibroblast activation, which supports a hypothesis of autocrine regulation of the CAF phenotype. Targeting pathways that determine fibroblast activation may offer a novel therapy for oesophageal cancer.

**Disclosure:** All authors have declared no conflicts of interest.

---

#### POSTER SESSION P12: IATROGENIC AND CAUSTIC ESOPHAGEAL LESIONS – October 17, 2012 12:30–13:30

---

##### P12.01 TIMES AND TRENDS IN THE TREATMENT OF SPONTANEOUS PERFORATION OF THE ESOPHAGUS FROM HERMAN BOERHAAVE TO PRESENT AGE

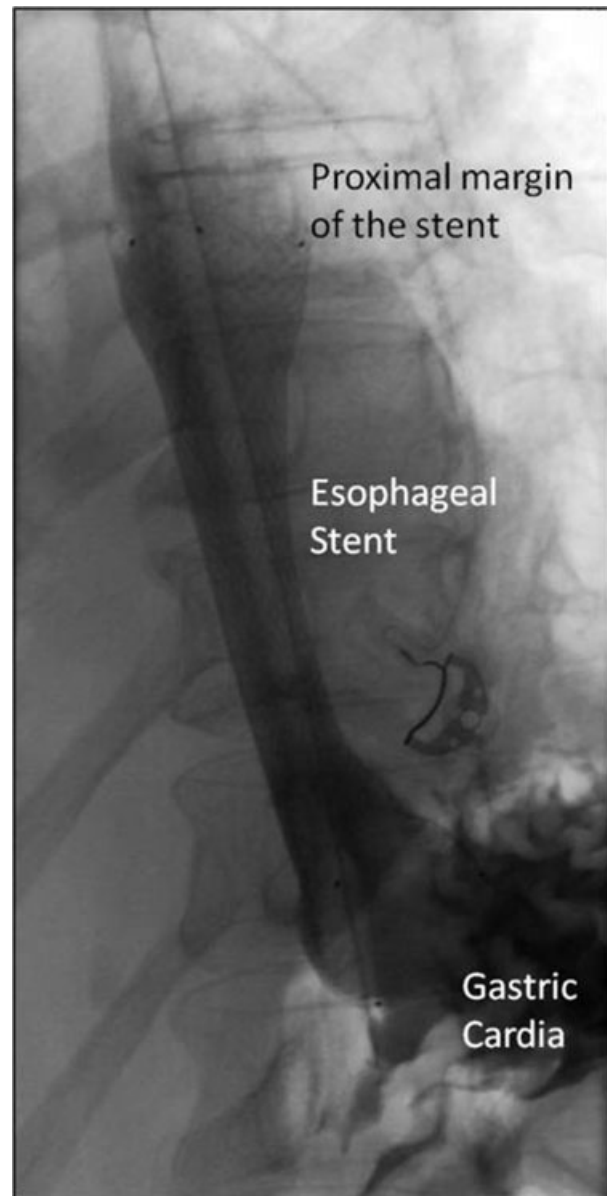Michael Schweigert<sup>1</sup>, Rory Beattie<sup>2</sup>, Norbert Solymosi<sup>3</sup>, Karen Booth<sup>2</sup>, Attila Dubecz<sup>1</sup>, Andrew Muir<sup>2</sup>, Dietmar Oefner-Velano<sup>4</sup>, Jim Mcguigan<sup>2</sup>, Hubert J Stein<sup>1</sup>

<sup>1</sup>Department Of General And Thoracic Surgery, Klinikum Nuernberg Nord, Nuernberg/GERMANY, <sup>2</sup>Department Of Cardiothoracic Surgery Royal Victoria Hospital, Belfast/UNITED KINGDOM, <sup>3</sup>Szent Istvan University, Budapest/HUNGARY, <sup>4</sup>Department Of Surgery, Paracelsus Medical University Salzburg, Salzburg/AUSTRIA

**Background:** Postemetic rupture of the esophagus is a devastating condition which was first described by Herman Boerhaave in 1724. Since then various suggestions for proper treatment of this otherwise fatal disorder have been made. Esophagectomy, diversion, suture as well as non-operative-management including endoscopic-measures have been proposed. However, there remains still considerable diversity of opinion regarding the optimal approach. Therefore we report on our experience in dealing with Boerhaave-Syndrome.

**Methods:** We encountered 15 patients with spontaneous esophageal perforation in our institution between 01/2006 and 12/2011. Average age was 58 years. A differentiated algorithm for treatment was favored. Circumscribed lesions were sealed by endoscopic insertion of a self-expanding-stent. Subtotal ruptures induced transmediastinal esophagectomy with delayed reconstruction. All cases were retrospectively analyzed.

**Results:** Successful endoscopic stent-implantation with prompt closure of the leakage was accomplished in 12 cases. In the further course all needed debridement of pleural empyema. Stent dislocation occurred but endoscopic re-intervention was always feasible. Results were gratifying in 10 cases and following full recuperation stent-explanation was performed without difficulty. Transmediastinal esophagectomy was mandatory in three cases. Delayed reconstruction with retrosternal gastric-pull-up was eventually carried out in two while one died from septic shock with multi organ failure.



**Discussion:** Boerhaave-Syndrome remains a life-threatening condition up to present times. A differentiated algorithm implying endoscopic-stent-insertion for circumscribed lesions and transmediastinal esophagectomy in case of subtotal rupture brought about promising results which compare favorably with thus far reported outcome. The esophagus can be preserved in the majority of cases while esophagectomy is limited to massive destruction of the organ.

**Disclosure:** All authors have declared no conflicts of interest.

##### P12.02 NEW ENDOSCOPIC TREATMENTS FOR THE BRONCHO- GASTRIC FISTULA AFTER TRANSTHORACIC ESOPHAGECTOMY – AN ARGON PLASMA COAGULATION AND A REVERSED MUCOSAL FLAP TECHNIQUE-

Makoto Kobayashi

Hakodate Goryoukaku Hospital, Hakodate City/JAPAN

**Background:** We contrived two new procedures for the treatment of broncho-gastric fistulas which are difficult to close using conventional endoscopic methods.

**Methods:** We tried two types of new endoscopic treatments for the fistula after transthoracic esophagectomy. One method is a procedure using an argon plasma coagulation, and another is a reversed mucosal flap technique.

**Results:** A fistula was observed one month after esophagectomy in a man of approximately 60 years. Argon plasma coagulation (APC) was conducted following conventional endoscopic clipping technique which failed to bite

the region caused of changing the mucosal surface as a slippery cicatrix. After APC cauterized around the fistula, the new-born mucosa was able to achieve a complete closure of the tracheal fistula. Another tracheal fistula occurred in a woman of approximately 40 years at 21 postoperative days after esophagectomy, and we tried to close using a reversed mucosal flap technique. First, the submucosal region around the fistula was elevated by an injected fluid, and cut lines into the mucosa on both sides of the orifice were made by an endoscopic hook knife. Then the fistula was covered over the reversed mucosal flaps by some clips and a closure was completed. Postoperative courses of both patients were uneventful and no recurrence of the fistula was seen one years after the treatment.

**Discussion:** We conclude that these two procedures have become new options for endoscopic treatments of the broncho-gastric fistula in cases were a complete closure using conventional clipping methods may be difficult.

**Disclosure:** All authors have declared no conflicts of interest.

#### P12.03 THE CHARACTERISTICS OF THE PATIENTS OF GASTRO-ESOPHAGEAL REFLUX DISEASE AFTER GASTRIC SURGERY USING 24-H COMBINED MULTICHANNEL INTRALUMINAL IMPEDANCE-PH MONITORING

Fumiaki Yano, Nobuo Omura, Kazuto Tsuboi, Masato Hoshino, Seryon Yamamoto, Shunsuke Akimoto, Yoshio Ishibashi, Norio Mitsumori, Hideyuki Kashiwagi, Katsuhiko Yanaga  
*Jikei University School Of Medicine, Tokyo/JAPAN*

**Background:** Duodeno-gastro-esophageal reflux is a common event after gastric surgery and can result in severe symptoms and mucosal injury. The protease inhibitors and prokinetic agents are administered but these medical therapies are largely ineffective. The aim of this study was to evaluate the characteristics of the patients of gastro-esophageal reflux disease (GERD) after gastric surgery.

**Methods:** Combined multichannel intraluminal impedance-pH monitoring (MII-pH) was used for 2 patients who underwent total gastrectomy (TG) or distal partial gastrectomy (DG) for gastric cancer. Duodeno-gastro-esophageal reflux episodes were detected using impedance and characterized by pH as acid or non-acid reflux. Intraesophageal pH < 4 holding time (pH < 4), DeMeester score (DMs), the numbers of acid and non-acid reflux episodes were calculated with the patient in both liquid and gas reflux. The symptom index (SI) and symptom association probability (SAP) were also evaluated.

**Results:** The results were listed below.

	pH<4HT (%)	Longest episode (min)	Reflux events > 5 min.	DeMeester score
Patient 1	0	0	0	0.8
Patient 2	0	0	0	0.8

	LAR	LNAR	GAR	GNAR	All reflux
Patient 1	0	49	1	26	76
Patient 2	0	68	0	47	115

LAR/LNAR; Liquid acid reflux/non-acid reflux, GAR/GNAR; Gas acid reflux/non-acid reflux

	Symptom Index %; Heartburn (Liq/Gas)			Symptom Index %; Regurgitation (Liq/Gas)		
	Acid	Non-acid	All	Acid	Non-acid	All
Patient 1	0/3	26/19	26/23	0/20	40/0	40/20
Patient 2	0/0	43/43	43/43	0/0	0/0	0/0
	Association probability %; Heartburn (Liq/Gas)			Association probability %; Regurgitation (Liq/Gas)		
	Acid	Non-acid	All	Acid	Non-acid	All
Patient 1	0/0	30/73	30/72	0/0	0/0	0/0
Patient 2	0/0	55/64	55/64	0/0	0/0	0/0

**Discussion:** 1) Non-acid reflux events were mainly detected after gastric surgery but unknown GAR was confirmed after TG. 2) SI for heartburn and regurgitation was negative. 3) SAP for heartburn was higher than that of regurgitation. Non-acid reflux after gastric surgery may cause heartburn rather than regurgitation.

**Disclosure:** All authors have declared no conflicts of interest.

#### P12.04 CAUSTIC INJURIES OF THE ESOPHAGUS IN AFRICAN COUNTRIES: A FREQUENT BUT HIDDEN SORROW.

Toni Lerut<sup>1</sup>, Bm Touré<sup>2</sup>, A Samateh<sup>3</sup>

<sup>1</sup>University Hospital Leuven, Leuven/BELGIUM, <sup>2</sup>Ignace Deen Hospital Conakry, Guinée, Conakry/GUINEA, <sup>3</sup>Royal Victorian Teaching Hospital Banjul, Banjul/GAMBIA

**Background:** Caustic injuries of the esophagus in children are common in several African countries. Survivors of the acute injury often develop severe stenosis. However medical support in particular technologic infrastructure to adequately treat these patients is deficient. A preliminary experience with the treatment of these children in the setting of developing countries is presented.

**Methods:** A supportive program was started in Guinée and Gambia. Local surgeons were taught how to introduce a "endless tread" through the ste-

notic esophagus and gastrostomy without the use of an endoscope and how to dilate the strictures with bougies.

**Results:** In 2011 until February 2012 55 children were admitted. All needed a feeding gastrostomy. Passage of the endless thread and subsequent dilatation was possible in 50 patients. There was no procedure related mortality. Seven patients died during follow up: 2 due to consequences of gastrostomy leak and subsequent infection, 1 from an acute gastroenteritis, 1 due to gastric fundus necrosis, 3 because of lack of financial possibilities. In 26 patients oral feeding was resumed so that gastrostomy could be removed (11 being occasionally dilated). The 24 remaining patients were able to swallow again their saliva and to resume some oral feeding (liquids or semisolids)

**Discussion:** Acute corrosive injuries of the esophagus are frequent but under-reported events in African countries. Late stenoses are usually severe necessitating gastrostomy. Using a simple technique to dilate these lesions is effective in most of the patients with acceptable related mortality. This technique is easy to teach to and by local surgeons themselves. However treatment of undilatable strictures requiring esophageal reconstruction remains a major challenge.

**Disclosure:** All authors have declared no conflicts of interest.

#### P12.05 ESOPHAGEAL PERFORATION – TREND TOWARDS ENDOSCOPIC TREATMENT

Peter Grimminger, Till Herbold, Hartmut Schäfer, Marc Bludau, Wolfgang Schröder, Arnulf Hölscher  
Department Of General-, Visceral- And Tumorsurgery, University Of Cologne, Cologne/GERMANY

**Background:** Esophageal perforation is rare, but despite improvements in detection, surgical techniques, and intensive care medicine, esophageal perforation remains potentially fatal. For treatment of esophageal perforation, there are several treatment options. Depending on the cause and extent of the perforation the treatment is primary surgical, endoscopic interventional or conservative. The intention for the presented retrospective study is to evaluate the causes and treatment in order to draw conclusions for appropriate therapy for this disease.

**Methods:** Esophageal perforations treated between 1996 and 2011 were assessed. These were 71 patients with a median age of 52 years. Clinical data was reviewed and analyzed retrospectively.

**Results:** Iatrogenic injury was the most frequent cause of esophageal perforation (n = 43, 60%), followed by Boerhaave-syndrome (n = 19, 27%) and traumatic perforation caused by accidentally swallowed foreign bodies (n = 7, 10%). In two patients, the reasons were not determinable. The patients were operated in 50.7%, 25 patients (35.2%) were treated endoscopically with stent (n = 23) or endo-VAC (n = 2), 9 patients were treated conservatively with antibiotics and nasogastric tube and one patient died before treatment. Before 2008 operation was performed in 57% (25/44) and after 2008 the proportion of patients who underwent surgery dropped to 41% (11/27), while 50.2% (14/27) received endoscopic management (stent, n = 12 and endo-VAC, n = 2). The hospital mortality was 7% (6.8% before 2008 and 7.4% after 2008).

**Discussion:** The evaluation of the individual management of esophageal perforation in a 15 year period shows a trend towards endoscopic treatment, with low mortality.

**Disclosure:** All authors have declared no conflicts of interest.

#### P12.06 RADIAL INCISION AND CUTTING (RIC) METHOD IS MORE EFFECTIVE THAN CONTINUED ENDOSCOPIC BALLOON DILATION (EBD) FOR REFRACTORY ANASTOMOTIC STRICTURE: A COMPARATIVE STUDY

Shuko Morita<sup>1</sup>, Ikuo Aoyama<sup>1</sup>, Manabu Muto<sup>1</sup>, Yasumasa Ezoe<sup>1</sup>, Tomonori Yano<sup>2</sup>, Yusuke Yoda<sup>2</sup>, Keiko Minashi<sup>2</sup>, Takahiro Horimatsu<sup>1</sup>, Shin'ichi Miyamoto<sup>1</sup>, Atsushi Ohtsu<sup>2</sup>, Tsutomu Chiba<sup>1</sup>  
<sup>1</sup>Kyoto University Hospital, Kyoto City/JAPAN, <sup>2</sup>National Cancer Center Hospital East, Kashiwa/JAPAN

**Background:** There is no effective treatment for gastroesophageal anastomotic strictures that are refractory to repeated endoscopic balloon dilation (EBD) or bougie. To relieve the symptoms of dysphagia and keep a wide lumen, we developed a new incisional treatment, radial incision and cutting (RIC).

**Methods:** We conducted a retrospective cohort study to evaluate the efficacy, safety and long-term patency by the RIC and EBD. Grade of dysphagia was evaluated using the dysphagia score. RIC was indicated when the patient complained of dysphagia and when 10 mm or larger diameter endoscope could not pass through the stricture site despite at least 3 repeated sessions of EBD.

**Results:** From May 2006 to March 2011, 32 patients were treated by RIC. The median number of EBD sessions per patient before RIC was 10 (range, 3–56) and the median latency of strictures requiring EBD before RIC was 5.8 months (1.3–172). During same period, 22 consecutive patients were received more than 4 repeated EBD sessions at least 1-week interval. The median duration from the first EBD to the fourth EBD was 1.6 months (1–5). No serious adverse events associated with RIC were observed. Immediately after RIC, 81.3% (26/32) of the patients were able to eat solid food. Median follow-up periods of the RIC and EBD group were 14.8 months (1.9–42.1) and 17.2 months (1–43.7). The 6-month and 12-month patency rates were significantly different between the RIC and EBD group (65.3% vs 19.8%,  $P < 0.01$ , 61.5% vs 19.8%,  $P < 0.01$ ).

**Discussion:** RIC is an effective and safe method.

**Disclosure:** All authors have declared no conflicts of interest.

#### P12.07 MANAGEMENT OF UPPER INTESTINAL LEAKS USING AN ENDOSCOPIC VACUUM-ASSISTED CLOSURE SYSTEM (E-VAC)

Marc Bludau, Arnulf Hölscher, Till Herbold, Peter Grimminger, Christian Gutschow, Wolfgang Schröder  
Department Of General-, Visceral- And Cancer Surgery, University Of Cologne, Cologne/GERMANY

**Background:** Esophageal perforation as well as postoperative leakage of esophagostomy is considered to be life-threatening conditions due to the development of mediastinitis and consecutive sepsis. Possible treatment options need to drain the mediastinal septic focus and to close the esophageal wall defect or the dehiscent anastomotic stapler line. Vacuum-assisted closure (VAC) is a well-established treatment modality of superficial infected wounds and is based on a negative pressure, applied to the wound via a vacuum sealed sponge. The endoluminal VAC therapy is a novel method with limited experience on esophageal application.

**Methods:** In this report the experience of a high volume center with endoluminal VAC therapy in patients with leaks of the esophagus is summarized.

**Results:** Between October 2010 and February 2012 eleven patients (age range 43–86 years) with esophageal defects were treated using the endoluminal VAC application. Three patients had a spontaneous, two patients an iatrogenic and six patients a postoperative esophageal defect. The average duration of application was 10.4 days with an average change of 3.8 VAC systems. In 4 of 11 patient endoluminal VAC therapy was combined with the placement of self-expanding metal stents. Complete restoration of the esophageal defect was achieved in 9 of 11 patients. Two patients died due to prolonged sepsis.

**Discussion:** This report demonstrates that endoluminal VAC therapy adds a treatment option of esophageal defects.

**Disclosure:** All authors have declared no conflicts of interest.

#### P12.08 ESOPHAGEAL PERFORATIONS: REVIEW OF OUTCOMES FROM A SINGLE-INSTITUTION SERIES

Hugo Santos-Sousa, Tiago Bouça-Machado, André Gonçalves, John Preto, António M. Gouveia, José Barbosa, José Costa-Maia  
Centro Hospitalar De São João / University Of Porto Medical School, Porto/PORTUGAL

**Background:** Esophageal perforation is an important therapeutic challenge. The aim of this study was to review the outcomes of esophageal perforations treated by a specialized unit in esophageal surgery.

**Methods:** Retrospective review of 52 consecutive patients with non-malignant esophageal perforation, between January 1991 and December 2008. Demographics, cause and location of perforation, time of diagnosis, management results and outcomes were evaluated. Management and outcomes trends over time were also evaluated. For that the cases were catalogued in three groups of 6 consecutive years.

**Results:** Spontaneous perforation occurred in 9 (17.3%) patients. Iatrogenic perforations were present in 15 (28.8%) patients and 28 (53.8%) patients had traumatic perforations. In half of the patients, diagnosis was obtained in the first 24 hours. The perforation's location was cervical in 14 (26.9%) cases, thoracic in 31 (59.6%) and abdominal in 7 (13.5%). Traumatic perforations were diagnosed significantly later than in other causes ( $p = 0.02$ ). In 9 patients (17.3%) treatment was non-operative. For the patients submitted to surgery (82.7%), in 23 cases (53.5%) a primary repair was performed, in 18 (41.9%) a bipolar exclusion and in 2 (3.8%) a conservative operative approach (drainage only). There were significant differences in the type of operative treatment according to the location ( $p = 0.035$ ) [thoracic perforations were more often treated with bipolar exclusion]. In the analysis of the trends over time, there were significant differences in the location ( $p = 0.027$ ) and the type of management ( $p = 0.012$ ) [more patients treated with primary repair in the last periods]. Morbidity and mortality rates were 46.2% and 13.5%, respectively. There were significant differences in morbidity according to the cause of perforation ( $p = 0.047$ ) [iatrogenic perforations had less morbidity] and the type of management ( $p = 0.041$ ) [patients treated conservatively either operatively or non-operatively had lower morbidity rate], but only the type of management was an independent risk factor in the logistic regression analysis (OR 0.071, CI95% 0.007–0.696,  $p = 0.003$ ). There were significant differences in mortality according to age ( $p = 0.022$ ) [older patients with higher mortality rate] and age was an independent risk factor in multivariate analysis (OR 1.095, CI95% 1.003–1.196,  $p = 0.005$ ). There weren't significant differences in morbidity and mortality rates over time.

**Discussion:** An approach to esophageal perforation based on injury severity and the degree of mediastinal and pleural contamination is of paramount importance. Although operative management remains the standard in the majority of patients with esophageal perforation, non-operative management may be successfully implemented with a low morbidity rate, in selected patients.

**Disclosure:** All authors have declared no conflicts of interest.

**P12.09 ESOPHAGEAL PERFORATION CAUSED BY FISH BONE LEADING TO PSEUDOANEURYSM RUPTURE : A CASE REPORT**

Koichi Ono, Yoshinori Suzuki, Hidetomo Yamauhi, Yoshiaki Sekishita, Masaru Fujimori  
*Obihiro Kousei General Hospital, Obihiro-si, Hokkaido/JAPAN*

**Background:** Fish bone accidental swallowing is not rare in Japan and Asia countries because of fish food culture, but esophageal perforation induced by fish bones is rare. We present a case who needed two surgical management for pseudoaneurysm due to esophageal perforation by fish bone.

**Methods:** A 58-year-old women was admitted to our hospital because of hematemesis 9-days after accidental swallowing of a fish bone. Computed tomography showed a fish bone in the mediastinal abscess and pseudoaneurysm of the aortic arch. An infected pseudoaneurysm rupture and mediastinitis caused by aorto-esophageal fistula was diagnosed. For initial treatment, aneurysmectomy, aortic patch plasty and transhiatal esophagectomy was done.

**Results:** Fifty days after the surgery, she had discharged, but 83 days from surgery, follow-up CT showed the relapse of pseudoaneurysm on the aortoplasty site. For second treatment, endovascular stent graft placement was selected because conventional surgical re-operation was considered very difficult.

**Discussion:** To manage infected pseudoaneurysm caused by aorto-esophageal fistula, infection control after surgery is most important. Close CT follow-up and long term antibiotic treatment is needed.

**Disclosure:** All authors have declared no conflicts of interest.

**P12.10 THREE CASES OF SPONTANEOUS ESOPHAGEAL PERFORATION**

Risako Yamashita, Ippei Yamana, Toyoo Shiroshita, Takeshi Shiraiishi, Yuichi Yamashita

*Fukuoka University Hospital, Fukuoka City/JAPAN*

**Background:** Spontaneous perforation of the esophagus occurs rarely, and its mortality and morbidity is generally high if it is lately diagnosed and treated.

**Methods:** We experienced 3 cases of spontaneous perforation at our institution from 2006 to 2011. Medical records of 3 patients with spontaneous perforation of esophagus were retrospectively analyzed in our institution.

**Results:** The patients were all males, and 43, 74 and 66 years old, respectively. The location of perforation were all left side posterior wall of the esophagus. Primary closure with intercostal musculocutaneous flap was performed in two cases within 6 hours from the onset. Open thoracic drainage and enterostomy for nutrition was done over 4 days after the onset. All patients were uneventful after operation and started oral intake after postoperative day 14, 15 and 77 days, respectively. The day of discharge from hospital was postoperative days 34, 26 and 82 days, respectively.

**Discussion:** Primary closure within 6 hours from the onset was successful treatment for a patient with spontaneous perforation of esophagus. Adequate drainage and management of nutrition were also successful treatment for a patient with delayed treatment with spontaneous perforation of esophagus. Early diagnose and surgical treatment is very important for spontaneous perforation of esophagus. However, drainage and nutrition by enteral is an effective treatment for a patient with delayed diagnose and treatment.

**Disclosure:** All authors have declared no conflicts of interest.

Conduit N = 11	Disease	Initial procedure	Revision	Follow up	Outcome
Stomach (reverse tube = 1) N = 8	1. Corrosive = 6 2. Malignancy = 2	Esophageal bypass = 4 Esophageal resection = 4	1a. Local excision of stricture and end to end anastomosis = 6 1b. Stricture excision and colon pull up due to inadequate length = 2	8 years = 1 5 years = 2 2 years = 3 1 year = 1 (died) 6 months = 1	No dysphagia = 5 Dilatation = 3 (Leak = 1)
Colon N = 3	3. Corrosive injury of esophagus and stomach = 3	Esophageal bypass = 3	3a. local excision and re-anastomosis = 1 3. Sternotomy, laparotomy, mobilization of conduit, stricture excision and re-anastomosis = 2	3 years = 1 2 years = 2	No dysphagia = 3

**Discussion:** The duration of development of complete re-strictures ranged from 3 months to two years. No definite predisposing factor could be associated. Revision surgeries were not associated with major morbidities. The local excision and anastomosis required expertise in mobilization and anastomosis. The excision of manubrio-clavicle in four cases helped in performing the anastomosis. The cases requiring sternotomy had longer strictures and were technically demanding. In all cases oral intake was started on 7-10<sup>th</sup> post operative day following a contrast study. Two cases had grade II dysphagia and one had grade III. These three cases responded to dilatation.

**Disclosure:** All authors have declared no conflicts of interest.

**P12.11 PLEURAL EMPYEMA DUE TO PERFORATED SIGMOID DIVERTICULITIS**

Rudolf J Stadlhuber<sup>1</sup>, Attila Dubecz<sup>1</sup>, Michael Schweigert<sup>1</sup>, Dietmar Ofner<sup>2</sup>, Hubert J Stein<sup>1</sup>

<sup>1</sup>Department Of General And Thoracic Surgery, Klinikum Nuernberg Nord, Nuernberg/GERMANY, <sup>2</sup>Paracelsus Private Medical University, 5020/ AUSTRIA

**Background:** We herein present a rare postsurgical complication after left colon interposition for esophageal replacement.

**Methods:** A chart review of 9 cases with left colon interposition for esophageal replacement in the years 2005 till present revealed 2 cases of perforated sigmoid diverticulitis.

**Results:** Both patients had to be reoperated several times with severe respiratory insufficiency, septic shock and pleural empyema due to a perforated diverticulum of the intrathoracic colon conduit.

Age	Sex	Indication	Pre OP colonoscopy	Redo OP after x d	Intraoperativ Findings
76	m	esophageal carcinoma, after Billroth II resection for ulcer disease	no pathological findings	8d	thoracotomy: perforated intrathoracic diverticulum, good vascularization of the colon
77	m	recurrent esophageal carcinoma after previous gastric interposition	no pathological findings	12d	thoracotomy: perforated intrathoracic diverticulum, good vascularization of the colon

**Discussion:** We suggest to invert and oversee all intraoperativ visible diverticula during primary surgery. If any predispositional factors for diverticular disease are known one might want to prefer the right colon as conduit since right-sided diverticular disease is uncommon and reported to occur in 1-2% of surgical specimens in European and American series.

**Disclosure:** All authors have declared no conflicts of interest.

**P12.12 REVISION SURGERY FOR COMPLETE REFRACTORY BENIGN CERVICAL ESOPHAGEAL ANASTOMOTIC STRICTURES: LIGHT AT THE END OF THE TUNNEL**

Nihar Ranjan Dash, Sujoy Pal, Peush Sahni, Tushar Kanti Chattopadhyay

*Department Of Gi Surgery, All India Institute Of Medical Sciences, New Delhi/INDIA*

**Background:** There is no definite answer to the problem of benign complete, refractory strictures of cervical esophago-conduit anastomosis. Revision surgery is better said than done because of factors like lack of local healthy tissue, previous leaks, lack of route and lack of new conduit.

**Methods:** During last 21 years revision surgery was performed on 11 cases of complete cervical anastomosis strictures where the guide wire could not be passed.

**Results:** Four were from 1482 esophageal anastomoses done in our institute.

**P12.13 POST-ESOPHAGECTOMY CHYLOTHORAX SUCCESSFULLY TREATED WITH THE COMBINATION OF THORACIC DUCT CLIPPING AND OCTREOTIDE ADMINISTRATION**

Hiroshi Okumura, Yasuko Uchikado, Tetsuhiro Owaki, Masataka Matsumoto, Tetsuro Setoyama, Yoshiaki Kita, Itaru Omoto, Ken Sasaki, Toshihide Sakurai, Sumiya Ishigami, Shoji Natsugoe  
*Department Of Digestive Surgery, Breast And Thyroid Surgery Graduate School Of Medical Sciences, Kagoshima University, Kagoshima/JAPAN*

**Background:** This paper reports the case of a 61-year-old man with esophageal cancer who experienced chylothorax after esophagectomy and was



successfully treated with thoracic duct clipping and octreotide administration.

**Methods:** Previously the patient had a head and neck cancer treated with multimodality treatment: neoadjuvant chemoradiation therapy, operation, and adjuvant CRT. Then, esophagectomy with lymph node dissection without resection of the thoracic duct was performed via a right thoracoabdominal approach.

**Results:** On postoperative day 1, enteral nutrition was started. On day 5, the chest tube drainage increased to 2000 ml per day. On day 7, the drainage fluid increased to 3000 ml per day, and its color turned cloudy white. We then performed lymphoscintigraphy and diagnosed the patient as having chylothorax. Immediately we administered octreotide; however, it could not stop the leakage. On day 13, we performed an operation: a fat-rich supplement was administered through the jejunostomy tube before the operation, the thoracic duct injury was readily identified, and we clipped the thoracic duct in the superior mediastinum, followed by octreotide treatment. On day 18, the drainage stopped, and the patient was discharged on day 38.

**Discussion:** Octreotide administration combined with surgical treatment should be considered as a treatment option for chylothorax, which is a rare complication of esophagectomy.

**Disclosure:** All authors have declared no conflicts of interest.

#### P12.14 ADENOCARCINOMA ARISING IN A COLONIC INTERPOSITION FOLLOWING ESOPHAGECTOMY FOR CORROSIVE ESOPHAGITIS

Takuya Sato, Masaho Ota, Kosuke Narumiya, Kenji Kudo, Yuji Shirai, Shin Yamamoto, Harushi Osugi, Masakazu Yamamoto  
*Institute Of Gastroenterology, Tokyo Women'S Medical University, Tokyo/JAPAN*

**Background:** Although carcinoma in the reconstructed gastric tube after esophagectomy is sometimes seen, carcinoma in a colon interposition is very rare.

**Methods:** We report a case of a 77 year-old woman with adenocarcinoma in a colon interposition after esophagectomy.

**Results:** She underwent esophagectomy, external fistula of the esophagus, and jejunostomy, for corrosive esophagitis in 1982 and reconstruction with left colon through the subcutaneous route in 1985. On April 2010 she presented at a local hospital with passage disturbance and a polypoid lesion about 40 mm in diameter located at approximately 18 cm from the front teeth in a colon graft was detected on upper gastrointestinal endoscopy. The biopsy yielded a diagnosis of adenocarcinoma. She was referred to our hospital for further examination and treatment. Ultrasonography revealed that the tumor invades muscle layer. No lymph node metastases were detected on Computed tomography. Based on a diagnosis of carcinoma in colonic interposition we performed partial resection of the colonic graft. Pathological findings were well differentiated adenocarcinoma (tub1) pMP (INFb) lyl v0 pPM0 pDM0 pRM0. The postoperative course was good, and the patient was discharged on the 21 day after the surgery. No recurrence or metastasis to other organs was detected after surgery on Computed tomography and Ultrasonography, but she died from pneumonia 13 months after surgery.

**Discussion:** This report describes an unusual late complication of a carcinoma arising in a colon interposition used to replace the esophagus.

**Disclosure:** All authors have declared no conflicts of interest.

#### P12.15 A PROSPECTIVE STUDY ON PATTERN AND OUTCOME OF ACUTE CORROSIVE INJURY IN A TERTIARY CENTRE

Arunkumar Krishnan, Jayathi Venkataraman  
*Stanley Medical College, Chennai/INDIA*

**Background:** A corrosive injury to the upper gastrointestinal tract is a common problem and has a wide spectrum of presentations. Aim of the present study was to determine the immediate clinical presentation and outcome following corrosive ingestion and its sequel after 6 months.

**Methods:** Thirty-eight patients with history of acute corrosive injury i.e. those presenting within 24 hrs of corrosive ingestion were included. Details of corrosive agent and clinical presentation were documented. Upper endoscopy to assess the degree and extent of injury was done and graded based on Zargar's classification. Reassessment was done after 6 months.

**Results:** All patients consumed a liquid form of corrosive. 34 patients had oral lesion, 25 had laryngeal edema and 18 aspiration pneumonia. The mean quantum of acid ingestion was 62.8 ml for Grade III injury, and 33.8 ml for Grade II injury. The grade of injury at 24 hours in 13 patients was Grade III in 3 patients grade II and I in 5 patients each. There were 7 deaths, one due to laryngeal oedema and respiratory failure and 6 due to esophageal perforation. Three patients developed esophageal stricture at 6 months and required serial dilation; one patient had Bilroth I for antral stricture, one

other patient with esophageal and antral stricture required dilatation for esophageal stricture and surgery for gastric outlet obstruction.

**Discussion:** Early endoscopy is important in establishing the extent of the injury. During the acute phase, intensive care admittance is often necessary. Total parenteral nutrition is a useful adjunct. Death is often due to esophageal perforation. Follow up important to prevent sequel such as adenocarcinoma

**Disclosure:** All authors have declared no conflicts of interest.

#### P12.16 A CASE OF ACUTE PHLEGMONOUS ESOPHAGITIS

Nagahama Masayoshi, Hiroyuki Karimata, Tatsuya Kinjo, Hideaki Shimoji, Tadashi Nishimaki  
*Department Of Digestive And General Surgery, Graduate School Of Medicine, University Of The Ryukyus, Nishihara-cho, Okinawa/JAPAN*

**Background:** Phlegmonous infection involving the digestive tract has been reported to have a poor prognosis. However, the pathogenesis and clinical features of acute phlegmonous esophagitis have remained unclear due to the rarity of the disease.

**Methods:** We herein report a case of acute phlegmonous esophagitis that showed a fulminant course during chemoradiotherapy treatment for uterine cancer. A 47-year-old woman was referred to the Department of Gynecology of the Ryukyu University Hospital with a diagnosis of stage IIB carcinoma of the uterine cervix, as defined by the International Federation of Obstetricians and Gynecologists classification in November, 2010.

**Results:** Before resection, she underwent two courses of induction chemotherapy that consisted of intravenous infusion of paclitaxel (175 mg/m<sup>2</sup>) and cisplatin (50 mg/m<sup>2</sup>) on day 1 with an interval of 3 weeks between courses. The patient had septic shock 10 hours after postprandial nausea and vomiting, and a computed tomographic scan showed diffuse thickening of the esophageal wall. Severe leucopenia that was refractory to the administration of granulocyte colony-stimulating factor persisted during the first few days. The patient fortunately survived after intensive treatment.

**Discussion:** The acute phlegmonous esophagitis of the present case might have been evoked and worsened by chemoradiotherapy through emetic and myelosuppressive adverse effects, respectively. Although its incidence is extremely rare, acute phlegmonous esophagitis may occur as a life-threatening complication of chemoradiotherapy.

**Disclosure:** All authors have declared no conflicts of interest.

#### P12.17 DENVER PERITONEOVENOUS SHUNT FOR INTRACTABLE ASCITES AFTER ESOPHAGECTOMY

Yoshito Nakou<sup>1</sup>, Hitoshi Fujiwara<sup>2</sup>, Atsushi Shiozaki<sup>2</sup>, Yasutoshi Murayama<sup>2</sup>, Shuhei Komatsu<sup>2</sup>, Yoshiaki Kuriu<sup>2</sup>, Hisashi Ikoma<sup>2</sup>, Masayoshi Nakanishi<sup>2</sup>, Daisuke Ichikawa<sup>2</sup>, Kazuma Okamoto<sup>2</sup>, Toshiya Ochiai<sup>2</sup>, Yukihito Kokuba<sup>2</sup>, Eigo Otuji<sup>2</sup>  
<sup>1</sup>*Kyoto Prefectural University Of Medicine, Kyoto/JAPAN*, <sup>2</sup>*Department Of Digestive Surgery, Kyoto Prefectural University Of Medicine, Kyoto/JAPAN*

**Background:** Intractable ascites after surgery for digestive cancer are often due to impaired liver function, postoperative lymphorrhea, and peritoneal metastasis, and its difficulties on the diagnosis and the control are reported. Here, we report a case of intractable ascites after surgery for esophageal cancer successfully treated by Denver peritoneovenous shunt.

**Methods:** The patient was a 70-year old male with lower thoracic esophageal cancer (T1N1M0, Stage IIB) and gastric cancer in the upper body (T1N0M0, Stage IA), who underwent subtotal esophagectomy and proximal gastrectomy with reconstruction using colon interposition in January, 2011. His postoperative recovery was uneventful, and he was discharged at 48 days after the operation. In April, 2011, he complained of abdominal distension.

**Results:** Ultrasonography demonstrated massive ascites and, the cytology of ascites was class II. PET/CT revealed the mediastinal lymph node recurrence. Although DCF chemotherapy (5-FU 600 mg/m<sup>2</sup> day1-5, DOC 60 mg/m<sup>2</sup> day1, CDDP 50 mg/m<sup>2</sup> day4, x2 courses) was performed, the massive ascites was not improved. Lymphorrhea in the abdominal cavity was not detected by lymphangiography. In the examination of ascites, appearance, specific gravity, protein concentration, the LDH ratio suspected transudate ascites, whereas the Rivalta reaction, the number of cells, the cell ingredient suspected exudative ascites. The cytology of ascites was also class II after the chemotherapy. Although the definite diagnosis was unclear, Denver peritoneovenous shunt was performed in August, 2011. The ascites was decreased markedly after the operation, and he was discharged at 23 days after the operation without complications.

**Discussion:** In conclusion, Denver peritoneovenous shunt is a simple procedure, and it can be applied with success in the treatment of intractable ascites.

**Disclosure:** All authors have declared no conflicts of interest.

**P12.18 MANAGEMENT AND OUTCOME OF NECROSIS OF THE ESOPHAGEAL SUBSTITUTE AFTER ESOPHAGECTOMY.**

Michele Valmasoni<sup>1</sup>, Tania Saibene<sup>1</sup>, Gianpietro Zanchettin<sup>1</sup>, Renato Salvador<sup>1</sup>, Luca Faccio<sup>1</sup>, Silvia Mantoan<sup>1</sup>, Carlo Castoro<sup>2</sup>, Rita Alfieri<sup>2</sup>, Matteo Cagol<sup>2</sup>, Tiziana Morbin<sup>1</sup>, Alberto Ruol<sup>1</sup>, Ermanno Ancona<sup>1</sup>  
<sup>1</sup>University Of Padova - Clinica Chirurgica 1, Padova/ITALY, <sup>2</sup>Veneto Institute Of Oncology, Padova/ITALY

**Background:** Reconstruction after esophagectomy is a high-risk operation. Conduit complications can be life-threatening, especially necrosis of the esophageal substitute (NES), which requires prompt diagnosis and challenging surgical management.

**Methods:** NES was retrospectively analyzed using a prospective database of 1212 patients (1111 for malignancy and 101 for benign disorders) who underwent esophageal reconstruction after esophagectomy between 1992 and 2010.

**Results:** 15 patients developed NES (1.2%) after esophagectomy for cancer in 12 cases (0.9%), and for benign disorders in 3 (0.2%). NES developed after cervical and intrathoracic gastric pull-up in 6 (40%) and 4 (26.7%) patients, respectively, and after cervical and intrathoracic colon interposition in 4 (26.7%) and in 1 (6.6%) patient, respectively. NES was diagnosed after a median interval of 8 days (3-17): through the temporary safety cervical stoma (n = 3), with endoscopy (n = 9), or on cervical surgical exploration (n = 5). 11 pts (73.4%) required take-down of the conduit and pre-sternal repositioning, (delayed reconstruction with skin or myocutaneous flaps was performed in 9 of these patients), 2 (13.3%) required resection of the necrotic tract and re-anastomosis, 1 required esophageal defect suture and reinforcement with muscular flap and 1 case was treated conservatively with cervical drainage. NES-related mortality was 17.6% (3 patients).

**Discussion:** Early recognition and expert management of NES is mandatory to reduce mortality and to permit successful reconstruction of the alimentary tract.

**Disclosure:** All authors have declared no conflicts of interest.

**P12.19 SHOULD EVERY TRANSHIATAL HERNIA AFTER ESOPHAGECTOMY BE REPAIRED?**

Georges Decker<sup>1</sup>, Jacques Kayser<sup>2</sup>, Carlo Faber<sup>2</sup>  
<sup>1</sup>Zithalnik, Luxembourg/LUXEMBOURG, <sup>2</sup>Zithaklinik, Luxembourg/LUXEMBOURG

**Background:** Postoperative transhiatal migration of abdominal organs into the thoracic cavity is a relatively rare complication. It has been reported to occur more frequently after minimally invasive esophagectomy than after conventional esophagectomy. Despite the fact that reoperative surgery in this context has a significant risk for morbidity, it is usually advised that all patients with postoperative transhiatal herniation should undergo surgical correction.

**Methods:** We report a case of Ivor-Lewis hybrid esophagectomy for pT2bN0M0 adenocarcinoma of the gastro-esophageal junction operated in 2004 by laparoscopy and right thoracotomy. The patient developed a massive postoperative transhiatal herniation of the transverse colon into her left chest. At the time this herniation was discovered, it had retrospectively existed for at least 3 years without significant symptoms. Consequently the patient was treated conservatively for more than 5 years.

**Results:** During 89 months of oncologic follow-up, no tumor recurrence and no new digestive symptoms or complications nor change in size of the transhiatal herniation occurred.

**Discussion:** This rare case observation shows that selected patients with post-esophagectomy transhiatal bowel herniation can be treated conservatively over prolonged time periods. Surgical correction of this complication should be proposed only in patients with excellent oncological prognosis or when significant symptoms exist.

**Disclosure:** All authors have declared no conflicts of interest.

**P12.20 LAPAROSCOPIC REOPERATIONS FOR SEVERE DYSPHAGIA AFTER HELLER MYOTOMY WITH NISSEN FUNDOPLICATION FOR ACHALASIA.**

Georges Decker  
Zithalnik, Luxembourg/LUXEMBOURG

**Background:** Laparoscopic Heller myotomy efficiently palliates dysphagia in patients with achalasia. In order to reduce the risk of postoperative reflux, most surgeons add an antireflux mechanism to the myotomy. Most surgeons use partial funduplications (Dor or Toupet) for this purpose but some still advise to perform a total fundoplication, claiming a better reflux control without risk of disabling dysphagia. Although some authors report dysphagia after Heller myotomy with Nissen fundoplication, very few have reported the need for surgical reintervention.

**Methods:** We report 2 patients in whom a laparoscopic reoperation was performed for dysphagia, 5 respectively 12 years after Heller myotomy with short and floppy 360° funduplications. Both patients had significant persisting dysphagia after their initial operation. Their dysphagia progressively worsened and was resistant to endoscopic therapy (repeated Botox injections and/or repeat dilatations).

**Results:** Both reoperations were performed by laparoscopy. Intra-operative endoscopy was performed in both cases. In the first case the circular fundoplication was converted to a partial fundoplication without any additional myotomy. In the second patient, the existing myotomy line seemed incomplete and was extended both distally and proximally. There was no mucosal perforation nor any postoperative complication. At 20 respectively 3 months of follow-up there is no residual dysphagia and a significantly improved quality of life, despite reflux in the first patient requiring daily proton pump inhibitors.

**Discussion:** Our 2 reported cases confirm knowledge from the times of open Heller myotomy that in patients with achalasia, adding a circular fundoplication to Heller myotomy will progressively decompensate the esophagus. With sufficiently long follow-up, reoperations for dysphagia are likely to be required in most patients.

**Disclosure:** All authors have declared no conflicts of interest.

**P12.21 ESOPHAGOPERICARDIAL FISTULA**

Miguel Calle Baraja, Oihane Gutierrez, Iñaki Martinez, Hector Marin, Jose Ignacio Santidrian, Jesús Maria Oleagoitia, Alberto Colina  
Hospital De Cruces, 48903/SPAIN

**Background:** We present a case of esophagopericardial fistula, a rare and serious entity that can occur for benign, malignant or iatrogenic causes. In our case it appears after total gastrectomy for adenocarcinoma with subsequent stenosis in the esophagojejunostomy anastomosis and repeated attempts to settle it by dilation and placement of several stents.

**Methods:** A woman 61 years old operated in another Hospital for a gastric adenocarcinoma in 2006. Early she suffered an stenosis at the esophagojejunostomy anastomosis and then multiple dilations, placement of stents, with migration of them and intestinal perforation with peritonitis. In March 2011 she had a severe sepsis caused by an esophagopericardial fistula and she was transferred to our hospital.

**Results:** We proceed to an initial intervention with the Cardiac Surgery Service. We performed a thoracotomy with a pericardiectomy, extraction of the stent that caused the fistula and finally we sutured it. Although pericardial fistula was resolved, Then a distal stenosis appeared. The patient was reoperated 9 months later, We resected the esophagojejunostomy anastomosis and another new anastomosis were made.

**Discussion:** An esophagopericardial fistula is a rare and frightening complication for patient's life. It needs for its resolution of a prior thorough preparation, the establishment of a proper nutrition and good respiratory function and the union of a multidisciplinary team that brings together surgeons of various specialties and expert anesthetists both in the surgery and during the recovery in Reanimation.

**Disclosure:** All authors have declared no conflicts of interest.

**P12.22 ESOPHAGECTOMY AND RECONSTRUCTION FOR THE TREATMENT OF SECONDARY ESOPHAGOARTIC FISTULA AFTER THORACIC ENDOVASCULAR ANEURYSM REPAIR**

Toru Nakano, Go Miyata, Ko Onodera, Hirofumi Ichikawa, Takashi Kamei, Yusuke Taniyama, Akira Sato, Susumu Satomi  
Division Of Advanced Surgical Science And Technology, Tohoku University Graduate School Of Medicine, Sendai, miyagi/JAPAN

**Background:** The incidence of secondary esophagoaortic fistula after thoracic endovascular aortic repair (TEVAR) has increased with an increase in the number of patients undergoing TEVAR. This disease is fatal unless appropriately treated.

**Methods:** Three patients were diagnosed with secondary esophagoaortic fistula by computed tomography and treated in our hospital. One patient underwent in situ repair using cryopreserved allograft of thoracic aorta, esophagectomy, and omentopexy. Eight months later, he underwent esophago-gastrostomy with vascular reconstruction involving the internal thoracic artery. Two patients underwent TEVAR, to prevent bleeding, and esophagectomy subsequently on the same day. In situ repair using allografting and omentopexy were performed on another day. Esophagocolostomy or esophagojejunostomy was performed after 4 or 7 months for reconstruction.

**Results:** These patients were successfully treated by two-stage or three-stage surgeries during the acute phase. Two patients were discharged in good general condition; one died because of pyogenic spondylitis 15 months later.

**Discussion:** Diagnosis and treatment for this disease must be prompt to prevent fatalities. Enhanced computed tomography is useful in diagnosing

this disease. To prevent major bleeding, performing TEVAR in stents of previous treatment is useful. TEVAR using allografting and esophagectomy are necessary to control sepsis due to mediastinal infection. Omentopexy is helpful to control local infection; however, since it is difficult to use gastric tubes only for reconstruction, the colon or small intestine is involved in the reconstruction of the esophagogastrintestinal tract. This study indicates that two-stage or three-stage surgical procedures are appropriate for this disease.

**Disclosure:** All authors have declared no conflicts of interest.

#### P12.23 MERENDINO'S OPERATION ON THE TREATMENT OF GASTROCUTANEOUS FISTULA AFTER SLEEVE GASTROPLASTY

Marnay Carvalho, Bruno Zilberstein, Renato De Araujo Pereira, Juliana Ferreira, Cely Bussons, Guilherme Tommasi Kappaz  
*Gastromed Instituto Zilberstein, São Paulo/BRAZIL*

**Background:** The gastrocutaneous fistula of the esophagus-gastric transition after sleeve gastropasty has been more related recently, because the difficulty resolution. This presentation has the objective to describe and present the treatment of this fistulae cases using the merendino's surgery.

**Methods:** Female patient, 21 years old, 23 months after sleeve gastropasty with chronic esophagus-gastric transition fistula to the skin and pleural cavity. After unsuccessful endoscopic treatment using prosthesis, stomafix®, surgisis® and biologic glue, she went through surgical resection of the esophagus-gastric transition with intestinal interposing between the terminal esophagus and the proximal stomach (Merendino's surgery).

**Results:** The patient underwent fine, with total resolution of the fistula, accepting oral food well.

**Discussion:** The Merendino's surgery can be considered on the treatment of esophagus-gastric fistula after sleeve gastropasty, according to its necessity or the use of total gastrectomy.

**Disclosure:** All authors have declared no conflicts of interest.

#### P12.24 RETROGRADE DILATATION VIA CERVICAL COLOTOMY FOR ANASTOMOTIC STRICTURE FOLLOWING PHARYNGOCOLOPLASTY FOR CORROSIVE STRICTURE OF THE ESOPHAGUS

Amit Javed, Amit Jain, Anil Agarwal  
*Gb Pant Hospital & Mam College, New Delhi/INDIA*

**Background:** Recurrent dysphagia due to cicatrization of the cervical anastomosis is a common problem following a pharyngocoloplasty for corrosive stricture of the esophagus. Although in the majority, this is effectively managed by endoscopic dilatations, in a small proportion these strictures are refractory and necessitate surgical revision of the anastomosis. In the present paper, we describe a novel technique of retrograde dilatation of the anastomotic stricture by making a colotomy in the pulled up colonic conduit in the neck and its outcomes.

**Methods:** Patients with stricture of cervical anastomosis following pharyngocoloplasty for corrosive stricture of the esophagus who had failed endoscopic dilatation were considered for this procedure. A neck exploration via the previous incision was performed and the colonic conduit was identified. A colotomy was made and retrograde dilatation of the anastomotic stricture was performed using the Savary-Gilliard dilators delivering the dilators to the mouth across the anastomosis. After graded dilatations, a nasogastric tube was passed across the stricture and the colotomy closed.

**Results:** Five patients who had undergone pharyngocoloplasty for corrosive stricture were referred to us with dysphagia due to stricture of the cervical anastomosis in the last year. Three of these patients had a history of cervical anastomotic leak. Two patients could be dilated endoscopically and three who failed it underwent cervical exploration and retrograde dilatation as described. In all these patients there was an isolated anastomotic stricture and the remaining colon was healthy. Satisfactory dilatation could be achieved in all and the patients could be started on oral diet after 3 days. Two patients subsequently required few more sessions of endoscopic dilatation.

**Discussion:** Retrograde dilatation via cervical colotomy is effective in managing anastomotic strictures following pharyngocoloplasty which are refractory to endoscopic dilatation.

**Disclosure:** All authors have declared no conflicts of interest.

#### P12.25 MANAGEMENT OF ANASTOMOTIC LEAKS AND IATROGENIC PERFORATION AFTER ESOPHAGEAL SURGERY: SUCCESSFUL MANAGEMENT BY A COMBINED THORACOSCOPIC- ENDOSCOPIC APPROACH

Rajan P.S., Vaithiswaran V, Palanivelu C  
*Gem Hospital And Research Center, 641045/INDIA*

**Background:** Anastomotic leaks after minimally invasive esophageal resection can be devastating especially if the esophago-gastric anastomosis is intrathoracic due to mediastinitis and its sequel. Such a situation may also arise due to unidentified mucosal injury during laparoscopic Heller's cardiomyotomy. These patients require urgent intervention. Here we describe four cases where minimally invasive interventions were successful in managing such complications.

**Methods:** Two patients had undergone minimally invasive Ivor Lewis Esophagectomy and developed intrathoracic leak and developed mediastinitis. Early re-thoracoscopy was performed in prone position and thorough mediastinal and pleural lavage was given. In one of the patient the anastomosis was refashioned. In both patients endoscopic placement of self-expanding removable covered PTFE stent was done. Two other patients who underwent Laparoscopic Heller's cardiomyotomy were referred to our center with esophageal perforation and mediastinitis. Both patients underwent right thoracoscopic drainage of mediastinal and pleural collections and simultaneous endoscopic placement of removable covered PTFE stents.

**Results:** All patients were salvaged successfully and they improved dramatically in the postoperative period. There was no leak in the postoperative period as documented by contrast study. They were able to tolerate orally within a week of the intervention. The stents were removed 2 months following the procedure.

**Discussion:** Combined thoraco-endoscopic approach to esophageal leaks in which significant mediastinal contamination is present can be lifesaving. Availability of such minimally invasive approaches encourages early intervention and thereby avoiding prolonged morbidity or mortality.

**Disclosure:** All authors have declared no conflicts of interest.

#### P12.26 101 CASES OF ESOPHAGEAL INJURIES MANAGED BY A SINGLE TEAM : EARLY AND LATE OUTCOMES.

Sridhar Rathinam<sup>1</sup>, Manickavasagam Kanagavel<sup>2</sup>, Chandramohan Asmita<sup>3</sup>, Servarayan Murugesan Chandramohan<sup>3</sup>  
<sup>1</sup>Glenfield Hospital, Leicester/UNITED KINGDOM, <sup>2</sup>St Isabel Hospital, Chennai/INDIA, <sup>3</sup>Madras Medical College And Rajiv Gandhi Government General Hospital, Chennai/INDIA

**Background:** Oesophageal injuries and perforations are complex problems faced by the surgeons and interventional endoscopists. Clinical features depend upon the coexisting disease, site and size of the perforation and the time interval in detecting the perforation. The outcome in the management of esophageal injuries depend on multiple factors. No single surgeon will have large volume experience with long term follow-up. We ventured to analyse the pattern of presentation; management and outcome analysis of our experience.

**Methods:** A retrospective review of records from a prospectively maintained database of a single team experience working in three institutions with 101 patients between the period 1993 to 2011 was done. The factors analysed include the etiology, timing of presentation, surgical and non-surgical interventions, outcome and follow-up.

**Results:** The age group ranging from 11 to 72, the time of presentation was between 2 hours to 9 months. The treatment modalities were non-surgical therapy and surgery. The overall mortality was 16.8%. Corrosive – 42, Malignancy – 20, post cervical spine surgery – 4, Post vagotomy – 2, Denture – 8, Tuberculosis – 4, Endotracheal tube – 3, Tracheostomy – 1, Spontaneous – 4, Cutthroat – 4, Myotomy for achalasia – 5, Blade – 1, Crab clip – 1, Needle – 1. The Surgical strategies included coloplasty, transhiatal resection, drainage +/- diversion oesophagostomy, stent and primary repair depending on the timing of presentation.

**Discussion:** Esophageal injuries/perforation can be due to various factors and the management and the outcome depends upon the cause, time of presentation, type of management, comorbid conditions and the experience of the team.

**Disclosure:** All authors have declared no conflicts of interest.

#### P12.27 TREATMENT STRATEGIES IN ESOPHAGEAL ACUTE PERFORATIONS. A 20 YEARS EXPERIENCE

Rubén Gonzalo, Lorena Solar, María Moreno, Lourdes Sanz, Estrella Turienzo, Juan J Gonzalez  
*Hospital Universitario Central De Asturias, Oviedo/SPAIN*

**Background:** Acute esophageal perforation is a potentially life-threatening clinical condition and its diagnosis and management strategy has been controversial.

**Methods:** It's a retrospective study of all patients presented to the Department of Surgery of our third level University Hospital between January-1989/December-2010. Patient's demographics, timing and characteristics of presentation, etiology, localization, diagnosis, modalities of treatment and outcome were evaluated.

**Results:** Sixty four patients were treated, 39(60.9%) men and 25(39.1%) women with a range of age (16–90 years). Etiology of perforation was: 28 foreign bodies (43.8%), 18 spontaneous perforations (28.1%), 16(25%) iatrogenic (endoscopy 11, surgery 5), 1 blunt trauma and 1 caustic ingestion. The most common location of the lesion was thoracic esophagus, 34 cases, followed by cervical and abdominal with 15 injuries in each location. Treatment was carried out within 24 hours in 38 patients and 16(25%) had previous esophageal disease. Medical treatment was intended in 36 patients (56.2%) and 29 were treated with surgery including one with conservative treatment failure. Operative treatment was: primary repair buttressed in 22 patients, esophageal resection 3 and only surgical drainage in 4. Seven patients (23%) were reoperated on. Mortality was 9.4% (6/64 patients), 3/36 in the medical treatment group and 10.3% (3/29) in the surgical one. Thoracic location had the highest mortality rates. The only factor related with mortality was age upper 75 years.

**Discussion:** In this historical series the modalities of treatment were changing through selective application of nonoperative techniques, mortality is between the range of similar cohorts and the age of patients is the key factor on mortality.

**Disclosure:** All authors have declared no conflicts of interest.

#### P12.28 RETROSTERNAL COLONIC REPLACEMENT FOR DIFFUSE CORROSIVE ESOPHAGEAL STRICTURE: LONG TERM RESULTS OF A CLINICAL AND FUNCTIONAL STUDY

Venanzio Porziella, Stefano Cafarotti, Maria Letizia Vita, Maria Teresa Congedo, Elisa Meacci, Stefano Margaritora, Pierluigi Granone  
*Catholic University, Department Of General Thoracic Surgery, Rome/ ITALY*

**Background:** To verify functional long-term results in patients affected by diffuse corrosive esophageal stricture treated by retrosternal esophagocoloplasty. To investigate if long-term metabolic consequences are predictable in each patient.

**Methods:** From 1/2002 to 12/2006 ten patients affected by esophageal stricture related to ingestion of corrosive substance underwent to retrosternal cervical esophagocoloplasty (8 right and 2 left colon replacement). After 5 years, all patients were submitted to clinical examination, blood-test, endoscopy, Xray barium swallow, manometry, pH metry, hepatic ultrasound and radionuclide esophago-colonic study and 51-Cr blowed permeability.

**Results:** No postoperative mortality was observed. In 3 patients a fistula of the cervical anastomosis was treated with conservative approach. In 5 patients with dysphagia one or more pneumatic dilatations of the cervical anastomosis was required. All patient had weight gain. In 2 patients ultrasonography revealed a hepatic steatosis. In 3 patients a chronic inflammation of the transposed bowel was present at endoscopy.

Just in one patient manometry showed peristaltic-like-waves. No pathological acid reflux was observed at pH-metry. Radionuclide esophagocolonic study revealed an increased transit time with a retention index range of 10–100% at 1 minute. In all patients 51-Cr blowed permeability showed pathologic results (range: 4.49–9.53%, normal < 3%).

**Discussion:** Retrosternal esophagocoloplasty is an effective treatment of corrosive esophageal stricture. However, long term colonic mucous damage are possible, and 51-Cr blowed permeability can prematurely detected an higher reabsorption of potentially toxic substances. According to our results, follow-up of these patients cannot be only a simple evaluation of weight gain or of food transit

**Disclosure:** All authors have declared no conflicts of interest.

#### POSTER SESSION P13: DIFFICULT CASES – October 17, 2012 12:30–13:30

##### P13.01 ESOPHAGECTOMY FOR THORACIC ESOPHAGEAL CANCER WITH A DOUBLE AORTIC ARCH

Norihisa Uemura, Tetsuya Abe, Ryouyusuke Kawai, Masayuki Shinoda  
*Aichi Cancer Center, Nagoya/JAPAN*

**Background:** Thoracic esophageal cancer with a double aortic arch is extremely rare. This is only the second case report concerning surgery for thoracic esophageal cancer in a patient with a double aortic arch.

**Methods:** We herein report the case of a 63-year-old male with a double aortic arch who underwent an esophagectomy for clinical TNM Stage IIIA (cT3N1M0; UICC 2009) cancer in the lower thoracic esophagus. A CT scan

revealed two involved nodes along the left recurrent laryngeal nerve and also in the right upper mediastinum. We estimated that these nodes could be removed by sternotomy and through a right thoracotomy.

**Results:** The patient underwent esophagectomy with a three-field lymphadenectomy following neoadjuvant chemotherapy. We first performed a cervical lymphadenectomy with sternotomy in order to remove the lymph node metastasis along the bilateral recurrent laryngeal nerves, and then performed a mediastinal lymphadenectomy through a right thoracotomy. We confirmed the presence of the bilateral recurrent laryngeal nerves during mediastinal lymphadenectomy, and were thus able to ensure their complete resection. The patient's postoperative course was uneventful, without any left recurrent laryngeal nerve paralysis.

**Discussion:** In such cases, it is important to recognize the anatomy in the upper mediastinum, especially the relationship between the right and left aortic arch, and the recurrent laryngeal nerves. We were able to accurately understand the anatomical position of the recurrent laryngeal nerves by the precedent cervical lymphadenectomy with sternotomy in the present case. A complete resection of the involved nodes was therefore possible during the surgical procedures.

**Disclosure:** All authors have declared no conflicts of interest.

##### P13.02 BRAIN METASTASIS FROM ESOPHAGEAL CARCINOMA

Shunji Endo<sup>1</sup>, Tsutomu Dousei<sup>1</sup>, Masaki Okuyama<sup>1</sup>, Nariaki Fukuchi<sup>1</sup>, Kazuya Sakata<sup>1</sup>, Ken Konishi<sup>1</sup>, Yujiro Tsuda<sup>1</sup>, Yujiro Nakahara<sup>1</sup>, Kazuhiko Ishigaki<sup>1</sup>, Takuro Umeda<sup>1</sup>, Takahito Sugase<sup>1</sup>, Satoshi Nagaoka<sup>1</sup>, Yukinobu Yoshikawa<sup>2</sup>, Nobutaka Hatanaka<sup>2</sup>, Wataru Kamiike<sup>2</sup>, Junichi Nishijima<sup>1</sup>  
<sup>1</sup>Higashiosaka City General Hospital, Higashiosaka/JAPAN, <sup>2</sup>National Hospital Organization Kure Medical Center/Chugoku Cancer Center, Kure/JAPAN

**Background:** Esophageal carcinoma rarely metastasizes to the brain. The clinical features and prognosis have not been fully revealed or understood.

**Methods:** We reviewed the cases of brain metastasis from esophageal carcinoma in our institutions.

**Results:** We encountered 13 cases (1.8%) of esophageal carcinoma which metastasized to the brain, with 1 female and 12 males presenting. The median age was 64 years old (range 51–72). Tumor histology of the primary lesion was squamous cell carcinoma in 8 cases, undifferentiated carcinoma (small cell carcinoma) in 2, coexistence of both in 2, and endocrine cell carcinoma in 1. According to the 7th TNM classification, 1, 1, 1, 2, and 8 cases were in stages IA, IIB, IIIA, IIIC, and IV, respectively. Primary therapy included six surgical resections for stage IA-IV cases and seven chemoradiotherapy regimens for stage IV cases. The median duration between the primary therapy and brain metastasis was 8 months (range 1–18 months). Brain metastases were in the cerebrum in 8 cases and in the cerebellum in 6. Metastasis to other organs was found in 11 cases. Treatment for brain metastases included surgery with/without radiation in 5 cases and best supportive care in 8. The median survival after identification of brain metastases was 5 months (range 2–14 months) for surgery and 14 days (4–70 days) for best supportive care.

**Discussion:** Undifferentiated carcinoma was more likely to metastasize to the brain. If the patient is operable for brain metastasis, even long-term survival over one year can be expected.

**Disclosure:** All authors have declared no conflicts of interest.

##### P13.03 DISTANT OR LYMPH NODES RECURRENCE AFTER ENDOSCOPIC SUBMUCOSAL DISSECTION FOR SUPERFICIAL ESOPHAGEAL CANCER

Hiroaki Sawai<sup>1</sup>, Masaki Tanaka<sup>1</sup>, Naomi Kakushima<sup>2</sup>, Kohei Takizawa<sup>2</sup>, Hiroyuki Ono<sup>2</sup>, Yasuhiro Tsubosa<sup>1</sup>  
<sup>1</sup>Shizuoka Cancer Center, Shizuoka/JAPAN, <sup>2</sup>Shizuoka Cancer Center, Nagatsumi/JAPAN

**Background:** Endoscopic submucosal dissection (ESD) has become a standard treatment for superficial esophageal cancer (SEC) in Japan, and the adaptation of ESD for SEC has been expanding. Although we sometimes experience some recurrent cases after ESD, there are few reports about distant recurrence after ESD.

**Methods:** The aim of this study is to clarify details of distant or lymph node recurrence after ESD and their clinical courses. Among 258 patients who underwent ESD for SEC from January 2003 to December 2010 in our institute, distant or lymph node recurrence occurred in seven patients. We investigated their clinicopathological features, results of ESD and details of recurrence and clinical course.

**Results:** The clinicopathological features and the details of ESD were as follows; median age: 75 (55–83) yrs, location (U/Mu/Lt/Ae): 1/2/3/1, median tumor size: 44 (28–59)mm, en bloc resection: six cases, pathological tumor depth (MM/SM1/SM2): 2/2/3, positive lymphovascular invasion: 2 cases (pMM, SM2). Additional therapies were performed on five cases (surgery:

1 (pSM1), chemoradiotherapy(CRT): 2 (pMM, pSM2), chemotherapy(CT): 1 (pSM1), radiotherapy(RT): 1 (pSM2), observation: 2 (pMM, pSM2). The median period from ESD to recurrence was 22 (4.4–44)months. The sites of recurrence were mediastinal lymph node: 4 (pMM/pSM2:2/2), cervical lymph node: 1 (pSM1), paraaortic lymph node: 1 (SM1) and pulmonary metastasis with mediastinal lymph node: 1 (pSM2). The details of treatment after recurrence were surgery: 1 (pMM), neck dissection: 1 (pSM1), CRT: 1 (pSM1), CT: 1 (pMM), RT: 1 (pSM2) and best supportive care: 2 (pSM2). Five patients died because of esophageal cancer..

**Discussion:** Although the number of recurrent cases was small, we found recurrence on cases with additional treatments after ESD. Careful observation after ESD is considered to be necessary in presence or absence of additional therapy.

**Disclosure:** All authors have declared no conflicts of interest.

#### P13.04 TREATMENT OUTCOMES OF WHOLE CIRCUMFERENTIAL ENDOSCOPIC SUBMUCOSAL DISSECTION FOR WIDESPREAD SUPERFICIAL ESOPHAGEAL CANCER.

Masaki Tanaka, Hiroaki Sawai, Naomi Kakushima, Kohei Takizawa, Hiroyuki Ono, Yasuhiro Tsubosa  
*Shizuoka Cancer Center, Shizuoka/JAPAN*

**Background:** Endoscopic submucosal dissection (ESD) has become a standard treatment for superficial esophageal cancer in Japan. Although there are a few reports of whole circumferential ESD for widespread lesion, there remains the problem of its technical difficulties and perioperative complications. The aim of this study was to assess the safety of whole circumferential ESD and clarify the treatment outcome.

**Methods:** Between April 2005 and August 2011, 392 esophageal neoplasms in 346 consecutive patients were treated by ESD at a single cancer referral center. After excluding previously-treated lesions, 55 patients in 61 lesions with mucosal defects over three-fourth of the lumen were analyzed. We classified them in two groups by the circumference of mucosal defect, Group W [whole circumference:22 patients in 26 lesions] and Group O [not reached to whole circumference:33 patients in 35 lesions]. Short-term treatment outcomes, and perioperative complications were assessed.

**Results:** The mean size of the resected specimen was 58.1 mm in Group W vs. 56.5 mm in Group O. Median procedure time was significantly longer in Group W. (123.3 min. vs. 92.8 min.  $p = 0.035$ ) However, there was no significant difference in the rate of en bloc resection (96.2% vs. 100%). Concerning perioperative complication, perforation (11.5% vs. 0%), mediastinal emphysema (15.4% vs 0%), was higher in Group W. The rate of postoperative stricture (100% vs 89%) was rather high in both groups. All patients were treated conservatively and no surgical intervention was needed.

**Discussion:** The rate of perioperative complications was higher in the whole circumferential ESD group. We should make a careful judgment about the indication of whole circumferential ESD.

**Disclosure:** All authors have declared no conflicts of interest.

#### P13.05 A CASE OF SQUAMOUS CELL ESOPHAGEAL CARCINOMA IN A YOUNG PATIENT (27 YEARS OLD), 11 YEARS AFTER BONE MARROW TRANSPLANTATION FOR ACUTE LYMPHATIC LEUKEMIA

Yutaka Miyawaki, Yutaka Toukairin, Kenrou Kawada, Yasuaki Nakajima, Tetsuro Nishikage, Kagami Nagai, Tatsuyuki Kawano  
*Tokyo Medical And Dental University, Tokyo/JAPAN*

**Background:** Most patients presenting with esophageal squamous cell carcinoma (ESCC) are more than 60 years old. Young patients, especially those in their twenties are extremely rare. Bone marrow transplantation (BMT) offers curative therapy for malignant and nonmalignant lymphohematopoietic diseases and other disorders. However, one important complication among transplantation survivors is the development of secondary malignancies, particularly solid tumors. Although previous studies have demonstrated some solid cancers to occur after BMT in cohorts of transplants recipients, few ESCC cases have so far reported. This study presents the case of a 27-year-old male ESCC that had an onset of acute lymphatic leukemia at 12 year of age and eventually achieved complete remission with BMT at 17 year of age.

**Methods:** Peripheral blood, formalin-fixed paraffin-embedded primary tumor samples, and corresponding non-cancerous esophageal mucosa were obtained in order to evaluate the presence or absence of donor-derived cells in the ESCC tumor. A short tandem repeat (STR) analysis was conducted using genomic DNA from those tissue specimens.

**Results:** STR patterns were donor-derived in the peripheral blood and recipient-derived in the ESCC tumor and corresponding non-cancerous esophageal mucosa.

**Discussion:** Our findings indicated that there are no donor-derived cells in ESCC tumor and corresponding non-cancerous esophageal mucosa. In previous studies, transplant recipients who develop chronic graft-versus-host disease (GVHD) and its therapy may increase the risk for SCC of the oral cavity and skin. Our patient had a history of chronic GVHD and its therapy after BMT. This event may thus have played an important role in the development of juvenile ESCC.

**Disclosure:** All authors have declared no conflicts of interest.

#### P13.06 TWO CASES OF ESOPHAGEAL CANCER WITH ABERRANT RIGHT SUBCLAVIAN ARTERY, TREATED WITH THORACOSCOPIC ESOPHAGECTOMY

Yusuke Taniyama, Hirofumi Ichikawa, Takashi Kamei, Toru Nakano, Ko Onodera, Go Miyata  
*Tohoku University School Of Medicine, Sendai/JAPAN*

**Background:** An aberrant right subclavian artery (ARSA) is an uncommon anomaly. The incidence of this anomaly has been reported around 0.5%. This anomaly is also famous as to accompany the right non-recurrent laryngeal nerve (NRLN) and right thoracic duct (TD). In case of esophageal cancer surgery, these anomalies should be taken care during the surgery. We experienced two cases of esophageal cancer which has been diagnosed as ARSA before the surgery.

**Methods:** Case1: A 59 year-old woman who had received chemoradiotherapy for esophageal cancer was diagnosed as recurrence of the cancer. ARSA was detected by CT scan prior to the surgery. Thoracoscopic esophagectomy was performed, though lymphadenectomy was minimized because of salvage surgery. Antethoracic route was selected for gastric tube reconstruction. The patient is currently followed without recurrence for 4 year after surgery. Case2: A 73 year-old man was diagnosed as T1bN0 esophageal cancer. Pre-surgical examination revealed existence of ARSA. Thoracoscopic esophagectomy was done with radical lymphadenectomy. Although the patient had temporary left recurrent laryngeal nerve palsy, the patient is doing well for 6month after surgery.

**Results:** We could successfully treat two cases of esophageal cancer with ARSA by thoracoscopy without any major complication. In both cases, we could identify and preserve NRLN and right TD during the surgery.

**Discussion:** Pre-surgical diagnosis of ARSA is very important, but also anatomical location of NRLN and right TD should be noted in this surgery.

**Disclosure:** All authors have declared no conflicts of interest.

#### P13.07 SURGICAL RESULTS FOR LUNG ABSCESS RESULTING FROM ADVANCED ESOPHAGEAL CANCER

Hitoshi Kawasaki, Naoki Wajima, Makoto Nakai, Akitoshi Kimura, Kenichi Hakamada  
*Department Of Gastrointestinal Surgery, Graduate School Of Medicine, Hiroaki University, 036-8562/JAPAN*

**Background:** Development of malignant esophago-pulmonary fistulas in patients with esophageal carcinoma is a devastating and life-threatening complication. Unfortunately, at the time of diagnosis, the patient's performance and disease status usually precludes aggressive surgical therapy, thus reports of surgical management is very limited.

**Methods:** Patients with fistulas between the esophagus and pulmonary parenchyma were treated with operation. To assess these treatment, operative procedures, operative outcomes, post operative courses, and prognosis were evaluated.

**Results:** Three patients with fistulas between the esophagus and pulmonary parenchyma were treated with operation. Two patients underwent esophagectomy with one stage reconstruction and the other underwent esophagectomy with two stage reconstruction. No operative death and all patients discharged from hospital once. Mean survival time was 202 days, and one patient still alive at 360 days from operation.

**Discussion:** Kim et al. (AJR 2009) reported a mean survival of 100.9 days of 14 patients with esophagopulmonary fistulas after palliative treatment with covered expandable metallic stents, which is shorter than 202 days in the current study. These results in the current study suggest that operative resection might be tried for some esophageal carcinoma with esophagopulmonary fistulas and that its possible indications may be (1) without distant metastases, (2) under 65 years old and (3) 0–1 performance status at the time of penetration.

**Disclosure:** All authors have declared no conflicts of interest.

### P13.08 A CASE OF SIMULTANEOUS OPERATION OF ESOPHAGECTOMY FOR ESOPHAGEAL CANCER AND ZENKER DIVERTICULUM

Yuichiro Tanishima, Katsunori Nishikawa, Masami Yuda, Akira Matsumoto, Nobuo Omura, Hideyuki Kashiwagi, Katsuhiko Yanaga  
*Jikei University School Of Medicine, Tokyo/JAPAN*

**Background:** Zenker's diverticulum (ZD) is an uncommon hypopharyngeal diverticulum which occurs in an area of anatomical weakness known as Killian's dehiscence between the lower pharyngeal constrictor and the cricopharyngeus muscle.

**Methods:** We report a 60-year-old man with ZD who simultaneously suffered from esophageal cancer. ZD measured 3 cm in diameter at the pharyngo-esophageal junction by esophagography, and esophagoscopy revealed hemi-circumferential elevated tumor with a pathological diagnosis of squamous cell carcinoma. Clinical findings of esophageal cancer was T1N1M0, stage IIB (UICC).

**Results:** He was treated with two cycles of combination chemotherapy using 5-FU, Cisplatin and Docetaxel. Surgical treatment for ZD was performed initially from left cervical approach. ZD was easily recognized by air insufflation and was resected by a linear stapler without dividing the crico-pharyngeus muscle. Then thoraco-abdominal esophagectomy with three fields lymph node dissection was performed for thoracic esophageal cancer. A gastric tube was used for the esophageal conduit, and esophagogastric anastomosis was performed in the upper posterior mediastinum space. The post-operative course was uneventful, and the patient was discharged on the 18th postoperative day.

**Discussion:** Simultaneous operative treatment of esophageal cancer and Zenker diverticulum is rare, and herein we report such a case and review the literature.

**Disclosure:** All authors have declared no conflicts of interest.

### P13.09 A CASE OF SYNCHRONOUS CANCERS OF THE ESOPHAGUS AND THE AMPULLA OF VATER SUCCESSFULLY RESECTED BY TWO STAGE OPERATION

Keita Itatsu<sup>1</sup>, Masahide Fukaya<sup>2</sup>, Hideki Nishio<sup>1</sup>, Tomoki Ebata<sup>1</sup>, Yukihiko Yokoyama<sup>1</sup>, Tsuyoshi Igami<sup>1</sup>

<sup>1</sup>Division Of Surgical Oncology, Department Of Surgery, Nagoya University Graduate School Of Medicine, Nagoya/JAPAN, <sup>2</sup>Nagoya University Graduate School Of Medicine, Nagoya/JAPAN

**Background:** We present a case of synchronous cancers of the esophagus and the ampulla of Vater successfully resected by two stage operation.

**Methods:** A 69-year-old man was diagnosed with thoracic esophageal cancer and ampullary cancer. Esophageal cancer was staged as cT1b (SM), N0, M0, Stage IA, and ampullary cancer was staged as cT2, N0, M0, Stage IB. We chose two stage operations to reduce postoperative complication.

**Results:** At first operation, we performed subtotal esophagectomy with right thoracotomy, cervical and thoracic lymph node dissection, esophagostomy, and gastrostomy. 40 days after the first operation, we performed second operation, pylorus-preserving pancreatoduodenectomy with modified Child's reconstruction and gastric tube reconstruction via subcutaneous route. To keep blood flow of gastric tube, the right gastric artery and right gastroepiploic artery / vein were preserved. In addition, the left gastroepiploic artery / vein to left internal artery / vein were anastomosed by plastic surgery under surgical microscope. Minor leakages of esophagogastronomy and pancreaticojejunostomy healed by conservative treatment. The patient was discharged on day 118 after the first operation. Histological examination revealed moderately differentiated squamous cell carcinoma of esophagus, pT1a-MM, N0, Stage IA, and well differentiated adenocarcinoma of ampulla of Vater, pT1, N0, pStage I. All surgical margins were negative for cancer. He is now alive with a good quality of life without recurrence 1 year 4 months after operation.

**Discussion:** Simultaneous performance of esophagectomy and pancreatoduodenectomy is at high risk. Two stage operation presented here is recommended to make complicated, risky procedure safer.

**Disclosure:** All authors have declared no conflicts of interest.

### P13.10 A PATIENT WHO UNDERWENT THE MULTIDISCIPLINARY TREATMENT TO THE MALIGNANT GRANULAR CELL TUMOR OF THE ESOPHAGUS

Sachiko Kaida, Masaki Ueno, Hisashi Shinohara, Shusuke Haruta, Masatoshi Nakagawa, Harushi Udagawa

*Dept. Of Gastroenterological Surgery, Toranomon Hospital, Tokyo/JAPAN*

**Background:** A 43-year-old male presented at our hospital with dysphagia.

**Methods:** The upper gastrointestinal endoscopy revealed a type 2 tumor beginning at a site 35 cm from the incisor teeth to ECJ. The endoscopic

biopsy showed pathologically granular cell tumor. PET-CT demonstrated thickening of the lower esophageal wall and the strong unusual FDG accumulation in it, and the malignant pathological change was suspected. High accumulations in the right lobe of the liver suggested metastatic lesions.

**Results:** The lower esophagectomy, upper gastrectomy, jejunal interposition and biopsy of a liver tumor were performed under laparotomy and VATS in order to restore oral intake, to avoid bleeding and to obtain the tumor sample for chemotherapeutic sensitivity test. The 67 × 56 × 25-mm tumor with deep ulcer was observed in the lower esophagus. The tumor was penetrated the entire esophageal wall. Histologically, tumor cells had coarse eosinophilic granules of PAS stain positivity in cytoplasm. Severe venous invasion was observed. The results of immunohistological staining were S-100 (+), c-kit (-), alpha-SMA (-), AE1+AE3 (-), CD34 (-) and CD68 (+). The MIB-1 index was 8%. The tumor in the liver also showed the same results as the esophageal tumor. These indicated malignant granular cell tumor. Although various chemotherapy was carried out (5-FU+ADM+CDDP, CDDP+VP-16, CDDP+CPT-11 and DTX), none of these drugs could show significant effects and the patient passed away 1 year after operation.

**Discussion:** We reported a rare case of malignant granular cell tumor of the esophagus.

**Disclosure:** All authors have declared no conflicts of interest.

### P13.11 DISTAL RESECTION OF A GASTRIC TUBE USED AS AN ESOPHAGEAL SUBSTITUTE AFTER ESOPHAGECTOMY WITH THE PRESERVATION OF BLOOD SUPPLY TO THE UPPER REMNANT FOR METACHRONOUSLY DEVELOPED ADENOCARCINOMA

Tatsuya Kinjo, Hideaki Shimoji, Masayoshi Nagahama, Hiroyuki Karimata, Tadashi Nishimaki

*Department Of Digestive And General Surgery, Graduate School Of Medicine, University Of The Ryukyus, Okinawa/JAPAN*

**Background:** A gastric tube is the most common organ used as an esophageal substitute in patients undergoing esophagectomy. Total resection of a gastric tube complicated by metachronously developed adenocarcinoma is a serious problem because it brings excessive stress to esophagectomized patients and the function of the vital organs of whom is often reduced.

**Methods:** We have experienced a case of gastric tube cancer metachronously developed in which R0 resection could be performed by a distal resection of the gastric tube with the preservation of blood supply to the upper remnant. We herein report our technique of the surgery and the outcome.

**Results:** A 61-year-old woman had a Type 4 gastric cancer at the prepylorus of a gastric tube reconstructed during esophagectomy via the substernal route 13 years ago. The tumor was staged as cT3N0M0 by CT. Firstly, she underwent jejunostomy to recover a poor nutritional condition. Subsequently, she underwent tumor resection. Because of the presence of COPD, a total resection of the gastric tube was considered to be too invasive. So, she underwent a distal resection of the gastric tube through a partial sternotomy. The blood supply to the upper remnant was maintained by the preservation of the right gastroepiploic vessels. A jejunal Roux-Y was performed as a reconstruction surgery. Her postoperative course was uncomplicated. She has been recurrence free after surgery.

**Discussion:** This procedure may be useful as an alternative R0 resection in patients with gastric tube cancer, particularly in patients with poor performance status.

**Disclosure:** All authors have declared no conflicts of interest.

### P13.12 A CASE OF INTRATHORACIC HERNIA OF POST MEDINASTINAL SPACE AFTER SUBTOTAL ESOPHAGECTOMY AND TOTAL REMNANT GASTRECTOMY WITH LONG ROUX-EN Y RECONSTRUCTION

Takashi Ozaki, Koji Nakai, Masanori Yamada, Taku Michiura, Kentaro Inoue, Yasushi Nakane, A-hon Kwon

*Department Of Surgery, Kansai Medical University, Moriguchi/JAPAN*

**Background:** It is rare that the intrathoracic hernia of jejuna pull-up through the post mediastinal space after subtotal esophagectomy and total remnant gastrectomy in patients with esophageal cancer.

**Methods:** A 70 years old man with a history of distal gastrectomy (Billroth II) for gastric cancer underwent subtotal esophagectomy and total remnant gastrectomy. Reconstruction was performed by long Roux-en Y fashion through the post mediastinal route. Although the post-operative course was excellent, the dysphagia was appeared 1 year after surgery. At 2 years after surgery, the patient could not take any foods because of continuous vomiting. Chest X-ray and computed tomography indicated dilative reconstructive jejunum at the mediastinum. Gastrografin ingestion revealed that the jejunum was stretched and twisted due to an intrathoracic hernia of the jejuna pull-up.

**Results:** We decided to try re-surgical operation. The operative finding showed the hernia sac in the thoracic cavity and pull-up the reconstructive jejunum. We performed adhenectomy and fixed the jejunum to the mediastinum to prevent recurrence of the hernia. The patient's body weight increased after surgery.

**Discussion:** A jejunal reconstruction has the advantage of abundant blood flow. However, it cannot negate the possibility that linearization of the jejunum is limited by being prescribed in the mesenteric vascular network developed jejunum. After esophagectomy, post mediastinal pressure becomes negative pressure with breathing. So, intrathoracic hernia is caused by jejunum lifted up to the post mediastinal space. We recommend that the jejunum should be fixed to the mediastinum to prevent recurrence of the hernia.

**Disclosure:** All authors have declared no conflicts of interest.

#### P13.13 A CASE REPORT OF LONG-TERM SURVIVAL OF ENDOCRINE CELL CARCINOMA OF THE ESOPHAGUS WITH CHEMO-RADIATION THERAPY

Yukiko Tsukao, Kenji Kobayashi, Taro Aoki, Ko Takachi, Kiyonori Nishioka  
*Kinki Central Hospital, Itami City/JAPAN*

**Background:** We report a case where chemotherapy and radiation were effective in esophageal endocrine cell carcinoma.

**Methods:** The case was an 84 year-old male. He was diagnosed with middle intra-thoracic esophageal carcinoma cT3N1M0 Stage III, and esophageal endocrine cell carcinoma, which we treated with chemotherapy and radiation (5-FU/CDDP,60 Gy) from May 2007, plus 7 courses of adjuvant chemotherapy, and obtained cCR. Left-lung metastasis appeared in February, 2010 about 2 years and 9 months later, and Docetaxel/CDDP/5-FU was started as 2nd line chemotherapy. Although the lung metastatic nest initially disappeared in August, 2010, it re-appeared in October, 2010. Radiotherapy (40 Gy) was performed on this metastatic focus from June 2011, but a contractionary effect was not seen.

**Results:** At the moment, best supportive care is being given according to the patient's wishes. In this case, a long survival of 4 years, 10 months was obtained from the start of therapy.

**Discussion:** It is said that the prognosis of esophageal endocrine cell carcinoma is very poor, and it often leads to hematogenous and lymphatic metastasis at an early stage. In our hospital, the number of esophageal cancers treated for 12 years is 357, and of these, 8 cases were diagnosed as esophageal endocrine cell carcinoma. They recurred within 2 years after treatment, and although there were many cases (5 of 8) which died, there were also those where long-term survival (2 of 8) was obtained by multidisciplinary treatment as in this case. This suggests the possibility that radiation and chemotherapy are useful in esophageal endocrine cell carcinoma.

**Disclosure:** All authors have declared no conflicts of interest.

#### P13.14 A LONG SURVIVAL CASE OF ADVANCED ESOPHAGEAL SMALL CELL CARCINOMA TREATED BY CHEMORADIOTHERAPY AND CHEMOTHERAPY.

Kenji Kudo, Takuya Sato, Yuji Shirai, Kosuke Narumiya, Masaho Ota  
*Gastrointestinal Surgery, Tokyo/JAPAN*

**Background:** A 43 year-old woman underwent endoscopy due to a passage disturbance and a hoarseness at a local hospital, in February 2006. Then she was referred to our hospital for further examination. Endoscopy revealed a deep ulcerative lesion about 16 cm to 22 cm from the front teeth. Barium esophagography showed an irregular ulcerative lesion at the cervical esophagus. CT scan showed a wall thickness of the cervical esophagus and a swelling of lymph node No.101R. Biopsy specimen yielded a diagnosis of small cell carcinoma.

**Methods:** Based on a diagnosis of small cell carcinoma of the cervical esophagus T4 N1(101R) M0 cStageIII, we performed chemoradiotherapy referring to a phaseIII study for the treatment of Limited-Stage Small-Cell Lung Cancer (EP/TRT-IP III) : JCOG0202-MF. Radiotherapy was done from March 28 to May 3 in 2006. Total dose was 54 Gy (2 Gy a day) to the cervical esophagus and 40 Gy to supraclavicular lymph nodes. Chemotherapy was performed from March 28 to 30, regimen was EP (CDDP 80 mg/body day1 alone and VP-16 100 mg/body day1-day3). After this, the patient was given three courses of combination chemotherapy (CDDP60 mg/body day1, CPT-11 60 mg/body day1, 8, 15) from May 19 to September 15.

**Results:** There was a complete response to three courses of chemotherapy, with no evidence of disease recurrence. She is presently alive 6 years after the diagnosis.

**Discussion:** Small-cell carcinoma of the esophagus is rare disease, and it has a poor prognosis against various treatments. Now we report a long survival case of advanced esophageal small cell cancer.

**Disclosure:** All authors have declared no conflicts of interest.

#### P13.15 OUR EXPERIENCE OF TREATING ESOPHAGEAL UNDIFFERENTIATED CARCINOMA

Shunji Endo, Tsutomu Dousei, Masanobu Hayakawa, Shusei Tominaga, Hiroshi Nakai, Masaki Okuyama, Nariaki Fukuchi, Kazuya Sakata, Ken Konishi, Yasuyuki Kotsuma, Emiko Tomita, Yujiro Tsuda, Yujiro Nakahara, Kazuhiko Ishigaki, Takuro Umeda, Takahito Sugase, Satoshi Nagaoka, Amane Yamauchi, Junichi Nishijima  
*Higashiosaka City General Hospital, Higashiosaka/JAPAN*

**Background:** Esophageal undifferentiated carcinoma is a rare histopathological type. It is distinguished from endocrine cell carcinoma by differentiation of tumor cells. Esophageal undifferentiated carcinoma is thought to be highly malignant and to have poor prognosis, but its clinical behavior has not been fully analyzed because of rareness.

**Methods:** We reviewed clinical characteristics and prognoses of patients with esophageal undifferentiated carcinoma in our institution.

**Results:** Among 359 patients with esophageal carcinoma in our institution during the past 13 years, 8 patients (2.2%) were pathologically diagnosed to have undifferentiated carcinoma. Of those, 7 were small cell type and one was non-small cell type. Median age was 62 years old (range 51–72), with seven males and one female presenting. Clinical or pathological stages according to the UICC were Stage IIB in 2, IIIC in 3, and IV in 3, respectively. Treatment included surgery in 3 cases (Stage IIB, IIIC, IV), chemoradiotherapy in 3 (Stage IIB, IIIC, IV), best supportive care in 1 (Stage IV), and resection in 1 (Stage IIIC). The regimen of chemotherapy was CDDP+VP-16 in all cases. Prognoses were 58–404 days after surgery, and 169–847 days after chemoradiotherapy. By the terminal stage, liver metastasis was recognized in 4 cases, brain metastasis in 3 cases, lung metastasis in 2 cases, bone metastasis in 2 cases, and adrenal metastasis in 1 case.

**Discussion:** Esophageal undifferentiated carcinoma has poor prognosis. Chemoradiotherapy including CDDP and VP-16 may be more effective than surgery. Undifferentiated carcinoma has high potential of brain metastasis; therefore adequate surveillance of the brain is needed.

**Disclosure:** All authors have declared no conflicts of interest.

#### P13.16 A CASE OF ESOPHAGEAL ENDOCRINE CELL CARCINOMA

Shunji Endo, Seiichi Tawara, Ichizo Kobayashi, Amane Yamauchi, Tsutomu Dousei, Junichi Nishijima  
*Higashiosaka City General Hospital, Higashiosaka/JAPAN*

**Background:** Esophageal endocrine cell carcinoma is a rare histological type of esophageal cancer, and is said to have poor prognosis.

**Methods:** We experienced a case which metastasized to the brain in our institution.

**Results:** A 70-year-old male admitted to our hospital complaining of dysphagia. Esophagogastroduodenoscopy revealed esophageal tumor 12 cm in length from the middle thorax to esophagogastric junction. Biopsy revealed endocrine cell carcinoma small cell type. Chest and body CT showed that some mediastinal lymph nodes were bulkily swollen. Left adrenal metastasis was also pointed out. Cancer stage according to the UICC 7th edition was T4bN3M1 stage IV. Chemoradiation therapy including CDDP+VP-16 regimen was performed. Partial response was acquired; however, consciousness level suddenly dropped two months after chemoradiation therapy. Head CT revealed multiple brain metastases and hemorrhage. Chest and body CT also revealed lung, adrenal, and paraaortic lymph nodes metastases. The patient died 8 days after brain metastases were discovered.

**Discussion:** Prognosis of esophageal endocrine cell carcinoma was extremely poor even when concentrated treatment was administered.

**Disclosure:** All authors have declared no conflicts of interest.

#### P13.17 A CASE OF ESOPHAGEAL CARCINOMA ASSOCIATED WITH AN ABERRANT RIGHT SUBCLAVIAN ARTERY

Katsunori Ami, Takeshi Nagahama, Masayuki Andou, Kuniyoshi Arai  
*Dept. Of Surgery, Tokyo Metropolitan Toshima Hospital, Tokyo/JAPAN*

**Background:** An aberrant right subclavian artery was rare case because it was reported that the incidence rate was from 0.5 to 2.0 %.

**Methods:** We reported a rare case of esophageal carcinoma accompanied by an aberrant right subclavian artery. A 61-year-old man, complaining of dysphagia and chest pain, referred to our hospital. Esophageal endoscopy showed a protruding tumor at cervical esophagus that occupied almost the entire posterior wall. The result of biopsy was squamous cell carcinoma. Computed tomography revealed an anomaly of an aberrant right subclavian artery which passed through on the dorsal side of the esophagus. The metastasis of lymph node and another organ was not detected. This anomaly suggested that the right inferior laryngeal nerve, having no vessel around

which to recur, took a direct course to the larynx (non-recurrent inferior laryngeal nerve: NRILN).

**Results:** We operated that esophagectomy which three-field lymph node dissection and reconstruction with stomach tube through the post sternum. The pathological diagnosis was esophageal carcinoma (moderately differentiated squamous cell carcinoma, T2, N0, M0, Stage IIA).

**Discussion:** NRILN was associated with aberrant right subclavian artery (ARSA) and reported that combined with several deformity, for example right thoracic duct, right aortic arch et al. The three dimensional computed tomography was usefulness on diagnosis of this anomaly. In case with esophageal carcinoma, it was difficult that the decision of dissection area at right upper mediastinum at operation because NRILN. Our case was successful of conservative the NRILN therefore did not occur right recurrent nerve paralysis.

**Disclosure:** All authors have declared no conflicts of interest.

### P13.18 LONG-TERM SURVIVAL AFTER CHEMORADIO THERAPY FOR SUPERFICIAL SMALL CELL CARCINOMA OF THE ESOPHAGUS: A CASE REPORT

Yu Sato<sup>1</sup>, Shin-ichi Kosugi<sup>1</sup>, Tatsuo Kanda<sup>1</sup>, Tomoyuki Kakuta<sup>1</sup>, Kaoru Sakamoto<sup>1</sup>, Takashi Ishikawa<sup>1</sup>, Kazuhito Yajima<sup>1</sup>, Ryuta Sasamoto<sup>2</sup>, Tsutomu Suzuki<sup>3</sup>, Katsuyoshi Hatakeyama<sup>1</sup>

<sup>1</sup>Division Of Digestive And General Surgery, Niigata University Graduate School Of Medical And Dental Sciences, Niigata/JAPAN, <sup>2</sup>Division Of Radiation Oncology, Niigata University Graduate School Of Medical And Dental Sciences, Niigata/JAPAN, <sup>3</sup>Niigata University Graduate School Of Health Sciences, Niigata/JAPAN

**Background:** Primary small cell carcinoma of the esophagus is considered to be a highly malignant tumor because of rapid progression and poor prognosis. Many investigators have reported that surgical resection is the most essential therapy.

**Methods:** We report a case of superficial esophageal small cell carcinoma that was successfully treated using chemoradiotherapy.

**Results:** Screening esophagogastroduodenoscopy was performed for a 67-year-old man that revealed a tumor in the middle thoracic esophagus. Histopathological examination showed that the tumor was composed of small undifferentiated cells. The immunohistochemical results from synaptophysin and chromogranin A staining were positive. Endoscopy showed submucosal invasion by the tumor, but computed tomography did not detect metastatic disease. Among the various therapeutic options, the patient selected chemoradiotherapy, and he received 60 Gy of radiotherapy concurrent with chemotherapy that consisted of 5-fluorouracil and cisplatin. The esophageal tumor disappeared soon after the chemoradiotherapy, and neither local recurrence nor metastatic disease had developed 5 years after treatment.

**Discussion:** Chemoradiotherapy can be an effective option for selected patients with superficial small cell carcinoma of the esophagus. A multicenter prospective study is needed to establish a standard therapeutic strategy.

**Disclosure:** All authors have declared no conflicts of interest.

### P13.19 SURGICAL MANAGEMENT FOR CERVICAL ESOPHAGEAL CANCER SUSPECTED OF INVASION TO THE HYPOPHARYNX: LARYNGEAL PRESERVATION WITH ORIGINAL METHODS

Takuya Okada<sup>1</sup>, Kenro Kawada<sup>2</sup>, Naoto Fujiwara<sup>3</sup>, Tairo Ryotokuji<sup>3</sup>, Shunsuke Ohta<sup>3</sup>, Yutaka Miyawaki<sup>3</sup>, Akihiko Hoshino<sup>3</sup>, Tomoyoshi Suzuki<sup>3</sup>, Jirawat Swangsi<sup>3</sup>, Yutaka Tokairin<sup>3</sup>, Yasuaki Nakajima<sup>3</sup>, Tetsuro Nishikage<sup>3</sup>, Kagami Nagai<sup>3</sup>, Tatsuyuki Kawano<sup>3</sup>

<sup>1</sup>Tokyo Medical And Dental University, Tokyo/JAPAN, <sup>2</sup>Department Of Surgery, Tokyo Medical And Dental University, Tokyo/JAPAN, <sup>3</sup>Department Of Esophagogastric Surgery, Tokyo Medical And Dental University, Tokyo/JAPAN

**Background:** Surgery for cervical esophageal cancer is difficult to manage. Laryngectomy may be necessary when the cancer is located near pharynx. The problem is that the upper border of the lesion is often hard to detect even if a thin endoscope or Valsalva maneuver is applied.

**Methods:** A 56-year-old man presented with cervical esophageal cancer. Computed Tomography (CT) suggested lymph node metastases in the neck and abdomen. Surgical resection was planned rather than chemoradiation because of broad lymph node metastases, but the oral border of the lesion was unclear by endoscopy.

**Results:** The oral border was to be verified just before the esophagectomy. Under general anesthesia, the larynx was expanded using a curved laryngoscope, and the border could be clearly visualized by endoscopy, not reaching the hypopharynx. These findings indicated that the larynx could be preserved. The patient underwent thoracoscopic esophagectomy including three-field lymphadenectomy, and reconstruction with a gastric-tube. The

esophagus was dissected around orifice and cut as planned by pulling the trachea forward with an elastic cord. The anastomosis also succeeded with no difficulties. The pathological findings showed there was no remaining tumor, and the patient is living in good health without any relapse 1 year after the operation.

**Discussion:** Curved laryngoscopy is mainly used for diseases in pharynx or larynx. This equipment could therefore be of assistance when it is difficult to recognize the outline of cervical esophageal cancer by normal endoscopy. Shifting the trachea and adequate dissection around the esophageal orifice is necessary for a curative resection and safe anastomosis.

**Disclosure:** All authors have declared no conflicts of interest.

### P13.20 MULTIPLE HEMATOGENOUS METASTASIS AFTER CURATIVE SURGERY IN A PATIENT WITH PSTAGEI PRIMARY MALIGNANT MELANOMA OF THE ESOPHAGUS

Tomoyuki Okumura<sup>1</sup>, Yutaka Shimada<sup>1</sup>, Koki Kamiyama<sup>1</sup>, Tomoko Watanabe<sup>1</sup>, Sojo Hojo<sup>1</sup>, Ryota Hori<sup>1</sup>, Koshi Matsui<sup>1</sup>, Isaku Yoshioka<sup>1</sup>, Shigeaki Sawada<sup>1</sup>, Toru Yoshida<sup>1</sup>, Takuya Nagata<sup>1</sup>, Kazuhiro Tsukada<sup>1</sup>

University Of Toyama, Toyama/JAPAN

**Background:** Primary malignant melanoma of the esophagus is a rare disease representing 0.1% of all primary esophageal neoplasm. It is a very aggressive disease with poor prognosis, however, little is known about the oncogenesis and no standard therapies have been established.

**Methods:** The patient is a 65-year-old man. He underwent upper gastrointestinal endoscopy at a periodic medical checkup and found to have a pigmented small nodule in lower thoracic esophagus. The histological examination of biopsy samples confirmed diagnosis of malignant melanoma. The preoperative disease stage was T1N0M0 stage I and the patient received radical esophagectomy. The resected specimen showed weak spotted pigmentations throughout the esophagus. There were 2 flat lesions with strong pigmentation, and an elevated lesion with strong pigmentation (8 mm in diameter).

**Results:** Histopathological findings showed melanocytosis at the spotted pigmentations, melanoma in situ at the 2 flat lesions, and invasive melanoma at the elevated lesion. No lympho-vascular invasion was seen (ly0, v0). The final disease stage was pT1(sm) N0M0 fStage I and the patient was closely observed at outpatient service without adjuvant chemotherapy. Multiple liver and lung metastasis were found at 19 months after surgery and the patient is now receiving DAV-feron (DTIC/ACNU /VCR/ IFN- $\alpha$ ) therapy.

**Discussion:** It is possible that malignant melanoma developed through melanocytosis-melanoma sequence. The indication of biopsy before esophagectomy is controversial. Adjuvant chemotherapy for pStage I malignant melanoma patients is worth considering.

**Disclosure:** All authors have declared no conflicts of interest.

### P13.21 EVALUATION OF THERAPIES FOR PATIENTS WHO HAVE ESOPHAGEAL CANCER AND HEAD AND NECK CANCER SYNCHRONOUSLY

Nobukazu Hokamura<sup>1</sup>, Hisaharu Oya<sup>2</sup>

<sup>1</sup>National Cancer Center Hospital, Tokyo/JAPAN, <sup>2</sup>Nagoya University Hospital, Department Of Gastrointestinal Surgery (Surgery II), Aichi/JAPAN

**Background:** About 20% of patients with esophageal cancer (EC) have head and neck cancer (HNC). For these decades, chemoradiotherapy (CRT) has been performed to EC and HNC as curative modality. We retrospectively reviewed patients who had EC and HNC synchronously to analyze and evaluate their treatments and considered therapeutic strategy of these patients.

**Methods:** From 2003 to 2007, 30 patients with EC and HNC synchronously were treated in our institute. Of 10 underwent esophagectomy for EC (Group S). Residual 20 underwent CRT (Group C). We compared clinical characteristics and therapeutic results between Group S and C.

**Results:** Group S included 2 early EC and 8 advanced one. Of 5 had advanced HNC. Group C included 11 early EC and 9 advanced one. Of 8 had advanced HNC. Group S contained significantly more advanced EC. Six patients in Group S underwent EMR for HNC. Sixteen patients in Group C had CRT for HNC synchronously. Two died of EC and 1 died of HNC in Group S. Seven died of EC and 2 died of HNC in Group C. Overall 5-year survival was 53% in Group S and 34% in Group C.

**Discussion:** Group S seemed to have better prognosis even though it included more advanced EC. Although more than 60% patients with EC and HNC synchronously underwent CRT for both cancers, prognosis of them seemed worse than that of those underwent esophagectomy. Esophagectomy could be included into therapeutic strategy of these patients.

**Disclosure:** All authors have declared no conflicts of interest.



**P13.22 A CASE OF PRIMARY MALIGNANT AMELANOTIC MELANOMA OF THE ESOPHAGUS TREATED BY ENDOSCOPIC MUCOSAL RESECTION WITH DAV-FERON THERAPY.**

Katsumasa Saito, Kenro Kawada, Tatsuyuki Kawano, Yasuaki Nakajima, Kagami Nagai, Tetsuro Nishikage, Yutaka Tokairin, Takuya Okada, Tairo Ryotokuji, Jirawat Swangsri, Yutaka Miyawaki, Shunsuke Ohta, Naoto Fujiwara  
*Department Of Esophagogastric Surgery, Tokyo Medical And Dental University, Tokyo/JAPAN*

**Background:** Primary malignant melanoma of the esophagus (PMME) is a very rare and deadly disease. It is characterized by aggressive behavior and poor prognosis, even after surgical resection.

**Methods:** We report a case of a 64 year-old Japanese woman who was diagnosed as having a primary malignant melanoma. The patient visited another hospital complaining of heart burn. Esophagogastroduodenoscopy showed a white elevated tumor in the lower third of the esophagus, and was not diagnosed as PMME perioperatively. It measured about 1 × 1 cm. No other sites of metastatic disease were identified. Endoscopic mucosal resection (EMR) was performed.

**Results:** Histopathologically, the typical finding of junctional activity adjacent to the tumor mass and melanocytes were microscopically found, thus primary malignant amelanotic melanoma with junctional activity was confirmed, including pT1b, cN0, M0 (pStage I) according to Guide Lines for the Clinical and Pathologic Studies on Carcinoma of the esophagus. The atypical melanotic hyperplasia extended to the lateral margin of the resected specimen. A novel approach that consisted of postoperative dacarbazine (DTIC), nimustine (ACNU), viscristine (VCR), and interferon beta (INF- $\beta$ ) was used. The patient received 7 courses of DAV-feron therapy after EMR.

**Discussion:** The patient has been doing well without recurrence and is now 54 months after EMR. We report a successfully treated case of PMME involving EMR and DAV-feron therapy.

**Disclosure:** All authors have declared no conflicts of interest.

**P13.23 A REQUIREMENT OF PROPHYLACTIC TREATMENT AFTER ENDOSCOPIC RESECTION FOR SUPERFICIAL ESOPHAGEAL SQUAMOUS CELL CARCINOMA**

Tomohiro Tsuchida, Akiyoshi Ishiyama, Chika Taniguchi, Kenjiro Morishige, Sho Suzuki, Hirotsuka Ishikawa, Natsuko Yoshizawa, Mizuka Imai, Takanori Suganuma, Yusuke Horiuchi, Kosei Matsuo, Masami Ohmae, Kazuhisa Okada, Kaoru Kato, Toshiaki Hirasawa, Yorimasa Yamamoto, Junko Fujisaki  
*Cancer Institute Hospital, Tokyo/JAPAN*

**Background:** Although endoscopic resection (ER) is usually indicated for T1a-EP and T1a-LPM esophageal squamous cell carcinoma (ESCC), the prophylactic treatment after ER is necessary for T1a-MM and SM1 ESCC because of lymph node metastasis. However it is not so high rate of metastasis (10~20%), some patients are over-treated by the prophylactic treatment. The aim of this study is to inspect a risk factor of metastasis of T1a-MM and SM1 ESCC.

**Methods:** In the cases of pathological T1a-MM or SM1 ESCC undergoing ER in our hospital, I examined the relations with metastasis of vascular invasion and Droplet infiltration (DI). The DI, the infiltrative growth pattern that the nest of cancer infiltrates, is thought that it is one of the risk factor of metastasis.

**Results:** In 75 cases of T1a-MM or SM1 ESCC, there were 19 cases (25%) of vascular invasion-positive, 11 cases (15%) of DI-positive, and 9 cases (12%) of metastasis. In 8 cases of vascular invasion-positive and DI-positive, there were 5 metastasis cases (63%). In 3 cases of vascular invasion-negative and DI-positive, there were 2 metastasis cases (67%). In 11 cases of vascular invasion-positive and DI negative, there were 2 metastasis cases (19%). However there were 43 cases of vascular invasion-negative and the DI-negative, and these cases was not seen of metastasis.

**Discussion:** If either risk factor is positive, the prophylactic treatment is necessary. However, if vascular invasion and DI were both-negative, it was suggested that the prophylactic treatment was not necessary.

**Disclosure:** All authors have declared no conflicts of interest.

**P13.24 LOCALLY INVASIVE ESOPHAGEAL RHABDOMYOSARCOMA WITH LONG SURVIVAL: A CASE REPORT**

Reem M.H. Balila<sup>1</sup>, Seif Mahadi<sup>2</sup>, Baderin Yousif<sup>3</sup>, Kamal Mohamed<sup>4</sup>, Suliman Fedail<sup>3</sup>, Mohamed Elmakki Ahmed<sup>5</sup>  
<sup>1</sup>University Of Khartoum, Faculty Of Medicine, Dept. Of Surgery, Khartoum- Amaral/SUDAN, <sup>2</sup>University Of Khartoum, Faculty Of Medicine, Dept. Of Surgery, Khartoum/SUDAN, <sup>3</sup>Fedail Hospital, Khartoum/SUDAN, <sup>4</sup>University Of Khartoum, Faculty Of Medicine, Dept Of Surgery, Khartoum/SUDAN, <sup>5</sup>University Of Khartoum, Faculty Of Medicine, Dept Of Surgery, Khartoum/SUDAN

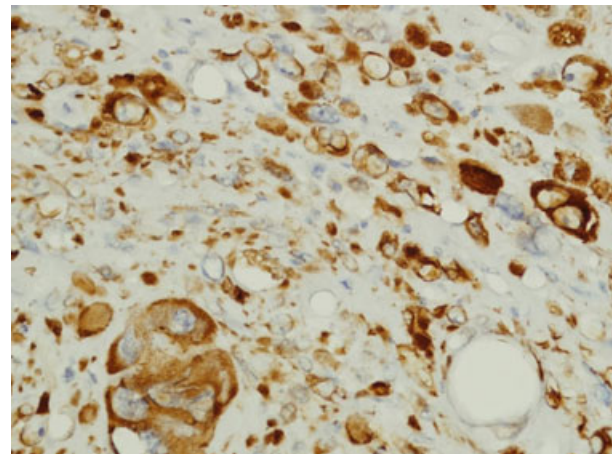
**Background:** Esophageal rhabdomyosarcoma is a very rare neoplasm. Only 16 cases were reported till 2006. It usually has a very poor prognosis (only 3 cases survived beyond one year in the literature). We report a case of locally invasive esophageal rhabdomyosarcoma with long survival postoperatively.

**Methods:** The following procedures were performed: upper GI endoscopy, thoracic CT scan with contrast, histopathology (H&E stain), and immunohistochemical staining with (Desmin, Myogenin, Vimentin, S100, SMA and CD117).

**Results:** A 60 yrs male, presented with slowly progressive intermittent dysphagia for more than a year. Upper GI endoscopy showed an intraluminal obstructing mass. CT scan with contrast showed an esophageal mass, possibly leiomyoma.

He underwent a right thoracotomy and a small mediastinal abscess was found and drained, its wall was taken as a biopsy. The esophagus was extremely dilated with an intraluminal palpable mass. The anterior surface of the esophagus was incised and a large pedunculated mass excised.

A diagnosis of esophageal rhabdomyosarcoma was made based on histopathology (sections stained with H&E showed markedly pleomorphic malignant cells, that were positive for Desmin, Myogenin, Vimentin and S100 and negative for SMA and CD117 on immunohistochemistry). The abscess wall was composed of the same tumour cells with surrounding necro-inflammatory tissues.



The patient received adjuvant chemotherapy post operatively. He is still alive 2 yrs post-surgery and free of recurrences.

**Discussion:** Esophageal rhabdomyosarcoma is extremely rare, its behaviour is poorly understood. This particular case had significantly different outcome than expected.

To understand the behaviour of such a tumour; every single case should be reported.

**Disclosure:** All authors have declared no conflicts of interest.

**P13.25 GASTRO-RESPIRATORY FISTULA: A SEVERE COMPLICATION IN THE ERA OF GASTRIC TUBE SUBSTITUTION FOLLOWING ESOPHAGECTOMY**

Long-qi Chen, Xiao-fei Zuo  
*West China Hospital, Chengdu/CHINA*

**Background:** The esophago/gastro-tracheal/bronchial fistula is a rare but life-threatening complication after esophagectomy for esophageal carcinoma. The aim of this study is to report our experience in dealing with this difficult case.

**Methods:** During Jan. 2010 through Feb. 2012, 1480 patients with esophageal carcinoma underwent an esophagectomy and gastric tube substitution, and 10 complicated a gastric tube-tracheal/bronchial fistula (0.85%). Their clinical data and results of treatment were reported.

**Results:** There were 9 males and 1 female, with a mean age of 58.5+/-8.2 years. The time of occurrence of fistula was 17 days at median and ranged 6 to 48 days. The fistulae were all with the crossing of gastric closure line. Treatment: One patient refused any further therapy and died of cachexia; Three underwent surgical repair, one cured and two died of aspiration and rupture of thoracic aorta; Four had a covered esophageal stent placement, two died of severe aspiration and the remaining 2 resumed oral intake since the fistulae located within 0.5 cm below the anastomotic orifice; The remaining 2 patient was discharged after placing bronchial stent primarily. After the reinforcement wrapping of gastric closure and the isolation of bronchus with artificial patch, no more such fistula was developed.

**Discussion:** As the wide application of gastric tube technique, the gastro-respiratory fistula is currently not rarely seen. Surgical repair gives a real cure but bares high risk. Bronchial stent placement shows better sealing effect then esophageal stent and patients could resume oral diet although no fistula healing was observed in any case.

**Disclosure:** All authors have declared no conflicts of interest.

### P13.26 A CASE OF THIGH BONE METASTASIS DETECTED TEN YEARS AFTER RADICAL SURGERY FOR ESOPHAGEAL SQUAMOUS CELL CARCINOMA

Takeshi Ishimoto, Hitoshi Fujiwara, Atsushi Shiozaki, Yasutoshi Murayama, Shuhei Komatsu, Yoshiaki Kuriu, Hisashi Ikoma, Masayoshi Nakanishi, Daisuke Ichikawa, Kazuma Okamoto, Toshiya Ochiai, Yukihito Kokuba, Eigo Otsuji  
*Department Of Digestive Surgery, Kyoto Prefectural University Of Medicine, Kyoto/JAPAN*

**Background:** Most of the recurrences of esophageal squamous cell carcinoma occur within two or three years after surgery, and their prognosis is extremely poor. Here, we report a case of thigh bone metastasis detected ten years after radical surgery for esophageal squamous cell carcinoma.

**Methods:** A 66-year-old male, who had undergone distal gastrectomy for gastric cancer in 1995, was performed subtotal esophagectomy with two-field lymph node dissection with reconstruction using colon interposition via retrosternal route in 1998. The pathological diagnosis was moderately differentiated squamous cell carcinoma (T1N0M0, Stage I).

**Results:** In September 2007, the patient suffered from pain of the left thigh, and radiography and MRI demonstrated osteolysis and femoral neck fracture in the left thigh bone. In January 2008, resection of the left thigh bone and femoral head prosthetic prosthesis were performed. The histopathological findings demonstrated the presence of moderately differentiated squamous cell carcinoma, and the diagnosis was bone metastasis from esophageal cancer. In May 2008, right lung metastasis was detected, and radiotherapy was performed. In August 2008, metastases to the left arm and the adrenal gland were detected, and we performed surgical resection for the former and RFA for the latter. After that, chemotherapy and best supportive care were performed, but he died in May 2010.

**Discussion:** Although the ratio of bone metastasis in the recurrence of esophageal squamous cell carcinoma tends to increase, bone metastasis detected 10 years after radical surgery is extremely rare.

**Disclosure:** All authors have declared no conflicts of interest.

### P13.27 ESOPHAGEAL SQUAMOUS CELL CARCINOMA WITH COMORBIDITY OF THORACIC AORTIC PSEUDOANEURYSM: CASE REPORT AND LITERATURE REVIEW

Wen-ping Wang<sup>1</sup>, Jian Yang<sup>2</sup>, Long-qi Chen<sup>1</sup>  
*<sup>1</sup>Department Of Thoracic Surgery, West China Hospital, Sichuan University, Chengdu/CHINA, <sup>2</sup>Department Of Cardiovascular Surgery, West China Hospital, Sichuan University, Chengdu/CHINA*

**Background:** Surgery is currently the main therapy of esophageal carcinoma. It is rare that ESCC and aortic aneurysm coexist in one patient. To our knowledge, no literature so far on surgical treatment to ESCC with comorbidity of aortic aneurysm has been reported. Here, we report such a case and discuss the surgical treatment, along with literature review.

**Methods:** A 58-year-old male patient was diagnosed as middle esophageal squamous cell carcinoma with comorbidity of thoracic aortic pseudoaneurysm. Contrast CT of chest scan discovered local protuberance with contrast solution filling at left lateral side of thoracic aortic isthmus, of which the maximum transverse section was 1.7 cm x 5.2 cm. Aortic endovascular covered stent implantation was firstly carried out followed by esophagectomy.

**Results:** No perioperative complication occurred. The patient began oral intake of fluid diet at 7<sup>th</sup> postoperative day. Chest film at 8<sup>th</sup> postoperative day showed there was no dislocation of aortic endovascular stent. The hospital stay after operation was nine days.

**Discussion:** It is an appropriate choice and recommended to perform aortic endovascular stent implantation before esophagectomy in order to avoid aneurysm rupture or fistula formation.

**Disclosure:** All authors have declared no conflicts of interest.

### P13.28 ESOPHAGEAL CANCER RESECTION AND RIGHT AORTIC ARCH: LEFT-SIDED APPROACH IN THE PRONE POSITION

Tetsuji Nobuhisa  
*Red Cross Hospital, Himeji/JAPAN*

**Background:** Esophagectomy is usually performed through a right thoracotomy because of the left position of the aortic arch. On the other hand, minimally invasive esophageal surgery has arisen in an attempt to reduce the significant complications associated with esophagectomy. We report a case of the left-sided thoracoscopic approach in the prone position in patient admitted for esophageal carcinoma and right-sided aortic arch.

**Methods:** We herein describe a 64-year-old male with esophageal carcinoma associated with right aortic arch. The procedures of our surgical techniques were as follows: (1) The patient was placed in prone position. (2) Three 12 mm-trocars and one 5 mm-trocar were used. (3) Subtotal esophagectomy and lymphadenectomy was performed by using the left-sided thoracoscopic approach in addition to the laparotomy. (4) Retrosternal esophagogastrotomy was performed for reconstruction.

**Results:** Operative time was 530 min. Blood loss was 200 g, and no perioperative transfusion was required. Postoperative recovery was uneventful. Histology showed the resection margins were clear. Surgical findings were as follows: (1) The left recurrent laryngeal nerve hooked around from the left to the right of the left ductus arteriosus, which connected the left pulmonary artery with the aortic diverticulum. (2) The right recurrent laryngeal nerve looped under the arch of aorta. (3) The recurrent laryngeal nerves were preserved when both of the recurrent laryngeal nerve lymph node chains were dissected. (4) Esophagus was effectively stripped after splitting the ductus arteriosus.

**Discussion:** The described procedure for esophageal carcinoma and right aortic arch is a minimally invasive alternative to the conventional thoracotomy that looks promising.

**Disclosure:** All authors have declared no conflicts of interest.

### P13.29 A CASE OF THE SUPERFICIAL BARRETT CARCINOMAS REPEATEDLY RECURRENT AND TREATED DURING LONG FOLLOW-UP PERIOD

Kazuo Koyanagi<sup>1</sup>, Tai Omori<sup>2</sup>, Kunihiko Hiraiwa<sup>1</sup>  
*<sup>1</sup>Department Of Surgery, Kawasaki City Hospital, Kanagawa/JAPAN, <sup>2</sup>Center Of Gastroenterological Endoscopy, School Of Medicine, Keio University, Tokyo/JAPAN*

**Background:** s: The precise clinical diagnosis of superficial carcinoma in the Barrett epithelium is difficult and further investigation is needed. We report the interesting case of superficial Barrett carcinomas that was repeatedly recurred and treated by multi-modality techniques during the long follow-up period.

**Methods:** Case report: A 51-year-old man was referred to our hospital for the treatment of a superficial adenocarcinoma arising from the long segment Barrett esophagus in 2003. Slightly elevated tumor (0-IIa) was located on the distal end of Barrett epithelium and endoscopic mucosal resection (EMR) was performed. Pathological examination revealed the G1 adenocarcinoma invaded to the mucosal layer and no vascular invasion. Then the periodical endoscopic examination was performed and detected the superficial and protruding tumor (0-Ip) located on the middle of the Barrett epithelium in 2007. EMR was performed and pathological examination revealed the non-small cell carcinoma invaded to the submucosal layer and slight lymphatic invasion. The patient was additionally treated by the chemoradiotherapy. In 2009, new lesion (slightly depressed type (0-IIc)) was found at the proximal end of the Barrett epithelium and treated by EMR. Pathological examination revealed the G1 adenocarcinoma invaded to the mucosal layer and no vascular invasion.

**Results:** In 2011, we found another 0-IIc lesion. Submucosal invasion was suspected by endoscopic examination and pathological findings of the biopsy specimens showed the G3 adenocarcinoma. We selected radical operation and pathological examination revealed the submucosal invasion and no lymphatic metastasis.

**Discussion:** Also, MIB-1 positive cells and p53 positive cells were appeared in the Barrett epithelium.

**Disclosure:** All authors have declared no conflicts of interest.

**P13.30 USEFULNESS OF ORAL PREDNISOLONE IN THE TREATMENT OF ESOPHAGEAL STRICTURE AFTER ENDOSCOPIC SUBMUCOSAL DISSECTION FOR SUPERFICIAL ESOPHAGEAL SQUAMOUS CELL CARCINOMA.**

Akiyoshi Ishiyama, Tomohiro Tsuchida, Chika Taniguchi, Sho Suzuki, Kenjiro Morishige, Natsuko Yoshizawa, Yusuke Horiuchi, Yasumasa Matsuo, Mizuka Imai, Takanori Suganuma, Hirotaka Ishikawa, Kazuhisa Okada, Masami Ohmae, Kiyohisa Dan, Manabu Kubota, Toshiaki Hirasawa, Yorimasa Yamamoto, Junko Fujisaki  
*Cancer Institute Ariake Hospital Division Of Gastroenterology, Tokyo JAPAN*

**Background:** Endoscopic submucosal dissection (ESD) permits en bloc removal of superficial esophageal squamous cell carcinoma. A circumferential mucosal defect involving over three fourths the circumference of the esophagus after ESD was significantly associated with the subsequent development of esophageal stenosis. So, it is necessary to prevent postprocedure stricture after ESD.

**Methods:** To evaluate the effectiveness of oral prednisolone in controlling postprocedure esophageal stricture. Design: Retrospective study. Setting: Endoscopy department in our hospital. Nine superficial esophageal lesions in nine patients who underwent semicircular ESD for esophageal squamous cell carcinoma involving over three fourths defect of the lumen from October 2011 through February 2012 were retrospectively studied. Intervention: Pre-emptive endoscopic balloon dilation (EBD) was not started until stenosis occurs. Esophageal stenosis was defined when a standard endoscope (9.8 mm in diameter) failed to pass through the stenosis. Oral prednisolone was started at 30 or 20 mg/day on the first day post-ESD. The prednisolone gradually tapered off and then was canceled eight weeks after six weeks.

**Results:** Only one of nine patients was occurred stricture. The number of EBD required was 6 on this patient. No complication, such as Candida esophagitis needed treatment, was happened in nine patients.

**Discussion:** Oral prednisolone may offer a useful preventive option for post-ESD esophageal stricture.

**Disclosure:** All authors have declared no conflicts of interest.

**P13.31 ADENOCARCINOMA OF THE TRANSPOSED COLON AFTER ESOPHAGEAL REPLACEMENT - THE LAST 43 YEARS REVIEW AND THE FIRST CASE OF SYNCHRONOUS TUMOR**

Rubens Sallum<sup>1</sup>, Gilton Fonseca<sup>2</sup>, Francisco Seguro<sup>3</sup>, Beatriz Azevedo<sup>2</sup>, Ivan Ceconello<sup>2</sup>

<sup>1</sup>University Of Sao Paulo, Sao Paulo/BRAZIL, <sup>2</sup>Esophageal Surgical Division Univ Of Sao Paulo, Sao Paulo/BRAZIL, <sup>3</sup>Hospital Das Clinicas – Fmusp, São Paulo/BRAZIL

**Background:** The use of colon for esophageal replacement is useful, but is subject to late complications as cancer. Aim: Report the first case of synchronous tumors in esophagocoloplasty and analysis of 21 other cases reported in the literature in 43 years

**Methods:** Method: A PubMed review of reported cases of those tumors was performed and variables as sex, age, reason for coloplasty, segment of transposed colon utilized, interval for cancer detection, tumor location, staging, therapeutic decision and outcome were analyzed

**Results:** Case report: Patient with congenital esophageal atresia underwent to esophagocoloplasty 40 years ago, developed a synchronous advanced adenocarcinoma of the transposed colon. Resection of the colon and reconstruction with the remained gastric tube was performed. Reoperation was necessary due to ischemic lesion of the upper gastric conduit. Lung metastases were detected, dying 9 months after surgery. Results: From 22 cases, 20 were adenocarcinomas and 2 adenomas. Male was 13 (59%) and malignant disease was the reason for coloplasty in half of cases. Lesion was more frequent in the distal third (10–45%) and in advanced stages (15–75%). The mean age was 68 years and average time of tumor detection since coloplasty was 19 years. Most of the tumors were resected (18–81%). There were six deaths related to the tumor or resection. No other paper reported synchronous tumors in the transposed colon.

**Discussion:** Conclusion: Cancer and adenoma may be detected at the very late follow up in the transposed colon (mean 19 years) and late endoscopic evaluation should be considered.

**Disclosure:** All authors have declared no conflicts of interest.

**P13.32 SMALL CELL TYPE OF NEUROENDOCRINE CELL CARCINOMA IN THE ESOPHAGUS APPEARING UNIQUE POLYPOID TUMOR**

Osamu Chino, Akihito Kazuno, Eisuke Ito, Tadashi Hara, Yoshifumi Kise, Tomoko Hanashi, Takayuki Nishi, Hideo Shimada, Soji Ozawa, Hiroyasu Makuuchi  
*Tokai University School Of Medicine, Isehara, Kanagawa/JAPAN*

**Background:** Neuroendocrine cell carcinoma rarely occurs in the esophagus as small cell carcinoma. No standard treatment for the carcinoma has been established yet. Although there have been several treatment modalities employing chemotherapy, radiation, surgical resection and combinations of those modalities, it is difficult to cure this tumor.

**Methods:** We present a case report of small cell type neuroendocrine cell carcinoma of the esophagus with a rare endoscopic form appearing submucosal tumor with histological and immunohistochemical analysis.

**Results:** 57-year-old woman. Endoscopic view showed a type I esophageal carcinoma appearing SMT with irregular and nodular surface stained with iodine. The biopsy specimen showed poorly differentiated carcinoma. Under the diagnosis of type I carcinoma of the middle thoracic esophagus, a standard esophagectomy using a right thoraco-laparotomy with three fields lymph nodal dissection was performed on November 2005. The pathological examination revealed a small cell type neuroendocrine cell carcinoma overlying non-neoplastic epithelium: the depth of invasion pT3, pN0, pStage II. The components of the squamous cell carcinoma were sporadically detected, while the majority of the invasive carcinoma was composed of small cell carcinoma. The carcinoma cells revealed positive for NCAM (CD56), SYN, CK20, CK-CAM5.2 and bcl-2, negative for CGA, NSE immunohistochemically. Multiple metastases in brain and lung were detected 3 months postoperatively, and systemic chemotherapy was performed. The patient was died 7 months after the operation.

**Discussion:** Small cell carcinoma of the esophagus has been reported to have poor prognosis, because of an aggressive tumor with early extensive and systemic metastasis generally. Studies to establish an effective treatment are required.

**Disclosure:** All authors have declared no conflicts of interest.

**P13.33 THORACOSCOPIC ESOPHAGECTOMY IN PRONE POSITION FOR ESOPHAGEAL CANCER AFTER LEFT PNEUMONECTOMY: REPORT OF A CASE.**

Alessandro Rosignoli, Marco Brizzolari, Massimo Vecchiato, Vittorio Durastante, Marco Zuccolo, Roberto Petri  
*S. Maria Misericordia Hospital, Udine/ITALY*

**Background:** Surgical resection represents the gold standard treatment of resectable esophageal cancer, but esophagectomy is still associated with high morbidity and mortality. Different minimally invasive techniques have been proposed. Esophagectomy after pneumectomy has been reported in few reports, and the surgical approach presents a challenge. We report a case of thoracoscopic esophagectomy in prone position in a 77-year-old female, who had undergone left thoracotomy pneumectomy for squamous cell lung cancer two years before.

**Methods:** A 77-year-old female, who had undergone left thoracotomy pneumectomy for squamous cell lung cancer (pT2N0 G3) two years before presented with dysphagia and chest pain. Oesophagoscopy and biopsy revealed a squamous cell carcinoma of the lower thoracic esophagus. A computer tomography (Fig. 1) showed a contracted pneumectomy space and no evidence of extra oesophageal extension of the carcinoma. Bronchoscopy showed no evidence of invasion of the bronchial tree; a pulmonary evaluation showed a severe reduction in CO transfer. A 3-hole esophagectomy with right thoracoscopic esophageal mobilization with the patient in prone position, laparoscopic and cervical anastomosis was performed.

**Results:** Total operative time was 230 minutes. Intensive care unit stay was 1 day and the patient was discharged after 13 days. We did not observe any major post-operative complication. Histological findings showed a squamous cell carcinoma with nodal metastasis (pT3N1).

**Discussion:** Minimally invasive 3-hole esophagectomy with thoracoscopic esophageal mobilization in prone position is a valid and feasible option for treatment of esophageal cancer in patients with previous radical operation for lung cancer.

**Disclosure:** All authors have declared no conflicts of interest.

**P13.34 PRIMARY MELANOMA OF THE ESOPHAGUS: CASE REPORT OF LONG TERM SURVIVAL AND LITERATURE SURVEY**  
Alexander Urbanski<sup>1</sup>, Ulrich Fetzner<sup>1</sup>, Hakan Alakus<sup>1</sup>, Arnulf Hölscher<sup>1</sup>, Stefan Paul Mönig<sup>2</sup>

<sup>1</sup>Department Of General And Visceral Surgery, University Hospital Of Cologne, Cologne/GERMANY, <sup>2</sup>Department Of General-, Visceral- And Cancer Surgery University Of Cologne, Cologne/GERMANY

**Background:** We present a case report of a patient 86 years of age, who was diagnosed with a primary esophageal melanoma 20 years ago. After radical transhiatal esophagectomy and lymphadenectomy of the lower mediastinum, superior gastric lymph nodes and esophagogastrostomy, a tumor stage of pT3N1M0 was determined. On follow-up, metastases of the melanoma were confirmed in the greater omentum, right diaphragm and liver and were completely removed by an operation two years later.

**Methods:** This case report follows the course of the patients disease over the space of time from 1991 up till today. Secondary, it gives an overview about the current data regarding the rare entity of the primary melanoma of the esophagus.

**Results:** Today, 20 years after the primary intervention, the patient is still without clinical proof of tumor without adjuvant therapy.

Due to dysphagia the patient underwent consecutive gastroscopy including endoscopic pneumatic dilatation.

The primary melanoma accounts for 0,1% of the malignomas of the esophagus and is considered a rarity with about 300 cases published.

On the basis of its embryological derivation, it mostly affects the middle and lower thirds of the esophagus. Aggressive growth and early incidence of metastases are characteristic for this entity. The prognosis is poor with a 5-year survival of 2–5% following R0-resection. The radical esophagectomy is the therapy of choice. There is no proof of benefit from adjuvant chemo- or radiotherapy.

**Discussion:** This case report shows, that the individual decision towards the resection of metastases can be beneficial, if a R0-situation can be reached.

**Disclosure:** All authors have declared no conflicts of interest.

**P13.35 HIATAL HERNIA AFTER MINIMALLY INVASIVE ESOPHAGECTOMY**

Marko Rojnica, Mustafa Hussain, Vivek N Prachand, Mark K. Ferguson  
The University Of Chicago, Chicago/UNITED STATES OF AMERICA

**Background:** It has recently been reported that hiatal hernia (HH) is more frequent after minimally invasive esophagectomy (MIE) than after open esophagectomy. We explored our database to determine whether our patients have an increased incidence of this problem.

**Methods:** A prospective database was used to identify patients on one surgical service who underwent MIE or open esophagectomy (OE; transhiatal, Ivor Lewis, hybrid) with immediate gastric reconstruction through the posterior mediastinum. Patients were included who survived more than 6 months and had a routine follow-up CT scan that could be used for assessment of HH.

**Results:** From 1992 to 2012, 36 MIE and 73 OE patients were identified. There were 81 men, the mean age was 60.1 years, and 65 (60%) underwent induction therapy. The interval between surgery and the most recent CT scan was longer for OE patients (40.1 vs 27.6 mos;  $p = 0.016$ ). There were no differences between the groups in age, gender, induction therapy, complications, or postoperative LOS. MIE patients had higher BMI (28.6 vs 26.0;  $p = 0.035$ ). Despite the shorter duration of follow-up, 6 (16.7%) HH were identified among MIE patients compared to none among the OE patients ( $p < 0.001$ ). Propensity score matching yielded a higher incidence of HH among MIE patients ( $p = 0.035$ ). One patient required reoperation for symptoms, while the remaining HH patients are asymptomatic.

**Discussion:** The incidence of hiatal hernia after MIE is higher than among patients undergoing OE. Improvement in MIE techniques may help reduce the incidence of postoperative hiatal hernia.

**Disclosure:** All authors have declared no conflicts of interest.

**VIDEO SESSION V1 – October 16, 2012 08:00–09:50**

**V1.01 USING THE ENDOSCOPIC FUNCTIONAL LUMINAL IMAGING PROBE TO GUIDE DILATATION IN PATIENTS WITH EOSINOPHILIC OESOPHAGITIS**

Adam Simpson<sup>1</sup>, Aron Ellefson<sup>2</sup>, Michael Samuel James Wilson<sup>1</sup>, Stephen E Attwood<sup>1</sup>

<sup>1</sup>North Tyneside General Hospital, North Shields/UNITED KINGDOM, <sup>2</sup>Ardmore Healthcare Limited, Amersham/UNITED KINGDOM

**Background:** This is a video which demonstrates how to perform an EndoFLIP (Endoscopic Functional Luminal Imaging Probe) test and provides

discussion of its utility in the context of clinical decision making in patients with eosinophilic oesophagitis (EoE). The EndoFLIP can be used as an adjunct alongside upper gastrointestinal endoscopy to guide decision making about the need for oesophageal dilatation in patients with EoE.

**Methods:** A video demonstration of the upper gastrointestinal endoscopy and subsequent EndoFLIP device insertion and usage is given. Cross-sectional area, distensibility and compliance of the oesophageal wall are calculated by the EndoFLIP and used to decide whether dilatation is appropriate for the individual patient.

**Results:** Two patients with EoE are demonstrated. The first patient had narrowing of the lower oesophagus with poor distensibility that required dilatation, and the subsequent increase in distensibility and cross-sectional area was demonstrated by comparing EndoFLIP measurements before and after dilatation. The second patient had narrowing only at the oesophago-gastric junction at the site of the lower oesophageal sphincter with normal distensibility measurements, therefore dilatation was not carried out.

**Discussion:** The EndoFLIP gives useful measurements of oesophageal wall distensibility, cross-sectional area and compliance, helping to select those patients who might benefit from dilatation and identifying the region of oesophagus to dilate. It also enables selection of an appropriately sized balloon dilator and provides an immediate objective measurement of the increase in oesophageal wall distensibility and cross-sectional area post-procedure. EndoFLIP testing is straight-forward to carry out, and can aid decision-making regarding the management of patients with EoE.

**Disclosure:** A. Ellefson: Employee of Ardmore Healthcare Limited

All other authors have declared no conflicts of interest.

**V1.02 LAPAROSCOPIC NISSEN FUNDOPLICATION WITHOUT SECTION OF THE SHORT GASTRIC VESSELS**

Andre Brandalise, Nilton Aranha, Nelson Brandalise, Claudia Lorenzetti  
Fundacao Centro Medico Campinas, Campinas/BRAZIL

**Background:** Many authors suggest that to perform an adequate total fundoplication, the ligation of the short gastric vessels is mandatory. That usually needs special instruments such as harmonic scalpel and has a potential risk of serious complications, such as bleeding, ischemic perforation of the gastric fundus and even splenectomy.

**Methods:** In the treatment of Gastroesophageal Reflux Disease, our group in Campinas has been using, since 2002, a technique to perform a fundoplication without ligating the short gastric vessels, approaching the posterior wall of the gastric fundus. This variation allows making a total or partial fundoplication, of any length, without the risks of working close to the spleen and also minimising the risks of post-operative dysphagia.

**Results:** In this video we present a variation of the Nissen procedure.

With this technique, employed in near 1000 patients, we achieve the same results as a “classic” Nissen procedure, without the risks and materials involved in ligating short gastric vessels.

**Discussion:** Laparoscopic Nissen fundoplication is the gold standard surgical treatment of GERD.

We present a surgical technique to perform a fundoplication approaching the posterior wall of the gastric fundus from the right side, using this part of the fundus, along with the anterior wall from the left side, to perform a 360° fundoplication without dividing the short gastric vessels.

**Disclosure:** All authors have declared no conflicts of interest.

**V1.03 TECHNIQUES OF PRESERVATION OF VAGUS NERVES AT THE LOWER ESOPHAGUS AND CARDIA DURING MINIMALLY INVASIVE SURGERY FOR FUNCTIONAL ESOPHAGEAL DISEASES**

Sandro Mattioli, Alberto Ruffato, Vladimiro Pilotti, Luca Ferruzzi  
Division Of Thoracic Surgery, Gvm Care & Research, Maria Cecilia Hospital, Cotignola (Ravenna), Center For The Study And Therapy Of Diseases Of The Esophagus. Alma Mater Studiorum – University Of Bologna, Italy, Bologna/ITALY

**Background:** To show in a video the technical passages for the preservation of vagus nerves during benign esophageal surgery.

**Methods:** 76 consecutive minimally invasive procedures were reviewed.

**Results:** The position of the vagus nerves from the cardiac level where the left vagus becomes anterior to the lesser curvature at the level of the branch of the nerves for the gallbladder is not variable; 2) the left vagus becomes anterior and adherent to the esophagus between 6 and 9 cm above the apex of the hiatus; 3) vaguses can be visualized; their position is also assessed while passing over the cord with an endodissect device; 4) the safest way to manage the vaguses is to know exactly where they are during each step of the surgery; 5) the dangerous steps of the minimally invasive surgery are: a)

the isolation of the left nerve where it becomes anterior, b) at the lesser curvature especially when resecting the fat pad or the sac of a II-IV hiatus hernia, c) when dissecting posteriorly the esophagus, in case of panmural esophagitis. The following cases are presented: 1 case of normal ge-junction during GERD surgery, 2 cases of short esophagus, 2 cases of type III-IV hiatus hernias, 2 Heller-Dor operation for achalasia, 2 cases of redo surgery for recurrent hiatus hernia.

**Discussion:** The video demonstrates several examples of booby traps for the vagus nerves integrity. When it is essential to mobilize adequately the lower esophagus, the surgeon must know in every moment where the vagus nerves are, particularly in difficult situations.

**Disclosure:** All authors have declared no conflicts of interest.

#### V1.04 GIANT ESOPHAGEAL POLYPS – MANAGEMENT ISSUES

Servarayan Murugesan Chandramohan<sup>1</sup>, Manickavasagam Kanagavel<sup>2</sup>, Chandramohan Asmita<sup>1</sup>, Cornelius Jacinth<sup>1</sup>, R K Sasankh<sup>1</sup>, D Madhusudhanan<sup>1</sup>, Dr Mohammed Ali<sup>1</sup>

<sup>1</sup>Madras Medical College And Rajiv Gandhi Government General Hospital, ChennaiINDIA, <sup>2</sup>St Isabel Hospital, ChennaiINDIA

**Background:** Polyps of the esophagus and hypopharynx are rare benign tumours which can reach giant size. Even though they are benign they can sometimes cause lethal problems like Asphyxia if regurgitated and GI bleed. Less common symptoms include dysphagia and mass coming out of the mouth.

**Methods:** We present our experience in management of two complex giant polyps with different manifestations and innovative management. Case 1: Giant polyp 12 cm in size located at supra-carinal level with coexisting tuberculosis presenting with odynophagia and high grade fever. Endoscopic biopsy of polyp confirmed tuberculosis. Under ATT cover Trans-thoracic excision with a pedicle patch closure was done. The leak after surgery was successfully managed by endoscopic stenting. The final biopsy was lipoma with tuberculosis. Case 2: Giant polyp 26 cm with history of mass coming out of the mouth on and off. Evaluations revealed polyp from cryopharyngeal region up to GE junction. CT-Angio revealed the feeding vessel is ascending pharyngeal artery. Successfully excised using NOTES technique Trans orally. The biopsy was fibro vascular polyp.

**Results:** Both these giant polyps, one with coexisting tuberculosis were managed successfully and on regular follow-up.

**Discussion:** Giant esophageal polyps are an uncommon entity presenting with varying manifestations. We describe two cases the first one with an unusual combination, the second, one of the longest reported in literature, removed without any incision in the esophagus by NOTES approach.

**Disclosure:** All authors have declared no conflicts of interest.

#### V1.05 SINGLE INCISION LAPAROSCOPIC HELLERS CARDIOMYOTOMY WITH TOUPET FUNDOPLICATION: USING CONVENTIONAL TROCARS AND INSTRUMENTS

Rajan P.S., Vaithiswaran V, Palanivelu C  
Gem Hospital And Research Center, 641045INDIA

**Background:** Single Incision Laparoscopic Surgery is gaining popularity. Hellers Cardiomyotomy (with or without Fundoplication) is the procedure of choice for treatment of Achalasia Cardia. There are only few reports on Single Incision Hellers Cardiomyotomy. The port devices and specialized instrumentation required add to the cost of the procedure. Here in this video we will be demonstrating our technique of Single Incision Hellers Cardiomyotomy with Toupet Fundoplication using conventional trocars and regular straight instruments.

**Methods:** Video: In this high Definition video, we demonstrate our technique of Single Incision Hellers Cardiomyotomy with Toupet Fundoplication. The steps are as follows, – Creation of umbilical flaps by cutting into the umbilicus. – Creating pneumoperitoneum using a Veress needle – Placement of one 10 mm and two 5 mm trocars at some distance between each other. – Liver retraction using a novel liver suspension technique using straight needles and a corrugated drain. – Mobilization of the fundus and the lower end of esophagus after creating the retro esophageal window. – Myotomy at the level of the LES and proximal esophagus for 3 cms. – Closure of the hiatal defect with 1 Ethilon – Toupet Fundoplication is performed and fixed to the myotomy and wrap anchored to the right crus.

**Results:** Twelve patients have undergone Single incision laparoscopic Heller's Cardiomyotomy with Toupet fundoplication. All had complete relief of symptoms. There was no post operative morbidity. All of them had satisfactory scar almost hidden at the umbilicus.

**Discussion:** Single incision multiport Heller's Cardiomyotomy is feasible and can be performed with low morbidity. When the incision is planned carefully at the umbilicus it is virtually invisible in the post operative period.

**Disclosure:** All authors have declared no conflicts of interest.

#### V1.06 LAPAROSCOPIC TRANSGASTRIC RESECTION OF LEIOMIOMA OF THE ESOPHAGO-GASTRIC JUNCTION

Carlo Castoro<sup>1</sup>, Matteo Cagol<sup>1</sup>, Rita Alfieri<sup>1</sup>, Marco Scarpa<sup>1</sup>, Tiziana Morbin<sup>2</sup>, Paolo Bocus<sup>3</sup>, Giorgio Diamantis<sup>3</sup>, Gianpiero Zanchettin<sup>2</sup>, Giorgio Battaglia<sup>3</sup>, Ermanno Ancona<sup>2</sup>  
<sup>1</sup>Surgical Oncology, Veneto Oncological Institute, PadovaITALY, <sup>2</sup>University Of Padua, Department Of Surgical And Gastroenterological Sciences, Clinica Chirurgica I, PaduaITALY, <sup>3</sup>Veneto Oncological Institute, PadovaITALY

**Background:** Laparoscopic resection of submucosal tumors located on the posterior aspect of the esophago-gastric junction is in many cases a difficult procedure. We describe a case of laparoscopic transgastric resection of a 3.2 cm submucosal tumor of the esophago-gastric junction in a 22 years old woman.

**Methods:** The procedure starts with the introduction of a supraumbilical trocar for a 30° angled optic scope. Two 5 mm trocars are inserted in left and right ipocondrium. Opening of the anterior gastric wall at a suitable level is then performed and a 10 mm balloon trocar is introduced. This allows the introduction of the 10 mm angled scope and the suspension and sealing of the gastric wall to the abdominal wall. The two 5 mm operating trocars are introduced through the gastric wall.

Resection of the submucosal neoplasm is performed by means of ultrasonic scalpel which allows bloodless resection of full thickness gastric wall with 1 cm margins of healthy tissue. The closure of the posterior gastric wall at the cardia is performed with a single layer running absorbable 3/0 suture. Intraoperative endoscopic assistance allows better exposure of the region and facilitates both resection and suturing.

The specimen is retrieved trans-orally by an extraction bag introduced through the gastroscope.

The trocars are then retrieved under vision and the gastric wall sutured.

**Results:** This technique allowed the preservation of the gastroesophageal junction.

**Discussion:** Pre-operative differential diagnosis between benign submucosal tumors and gastrointestinal stromal tumors is not always possible. In case of uncertain diagnosis full thickness wide local excision with adequate margins is mandatory.

**Disclosure:** All authors have declared no conflicts of interest.

#### V1.07 THORACOSCOPIC MANAGEMENT OF BENIGN DISEASE OF THE THORACIC ESOPHAGUS WITH PATIENT IN PRONE POSITION

Massimo Vecchiato, Marco Brizzolari, Alessandro Rosignoli, Vittorio Durastante, Marco Zuccolo, Roberto Petri  
S. Maria Misericordia Hospital, UdineITALY

**Background:** Benign diseases of the thoracic esophagus are rare conditions. Leiomyomas and caustic injuries are the most common indications for surgical treatment. We present our experience of thoracoscopic enucleation and esophagectomy for benign disease of the thoracic esophagus with patient in prone position.

**Methods:** Between July 2010 and August 2011 we have managed 3 patients (2 males; 1 female; median age 61 years) for leiomyoma and 1 patient of 56 years for caustic injury of the esophagus. All procedures were performed through a right thoracoscopy with patient in prone position. A right posterior thoracoscopic access is performed and three trocars are placed: a 10 mm for 30° angled scope in the seventh intercostal space near the apex of the scapula, a 5 or 10 mm in the fifth space and a 12 mm in the ninth space on the posterior axillary line. A pneumothorax using carbon dioxide at a pressure of 7–8 mm Hg is performed. We used a coagulating hook to open the muscular layer and to perform the esophageal dissection. After leiomyoma enucleation the muscular layer was closed by interrupted stitches.

**Results:** Median operative time was 130 minutes (range 120–170 minutes); we didn't observe any major post-operative complications. Median post-operative stay was 10 days (range 9–11 days).

**Discussion:** Thoracoscopy with patient in prone position allows leiomyoma enucleation and esophagectomy with low morbidity and without selective lung desufflation. Thanks to this technique, improved surgeon ergonomics, increased operative field exposure and satisfactory respiratory results can be obtained.

**Disclosure:** All authors have declared no conflicts of interest.

**VI.08 MINIMALLY INVASIVE ENUCLEATION OF ESOPHAGEAL LEIOMYOMA**

Mario Costantini<sup>1</sup>, Renato Salvador<sup>1</sup>, Lisa Zanatta<sup>1</sup>, Cristina Longo<sup>1</sup>, Elena Finotti<sup>1</sup>, Gloria Dogá, Giovanni Capovilla<sup>1</sup>, Alberto Ruol<sup>1</sup>, Giovanni Zaninotto<sup>2</sup>

<sup>1</sup>University Of Padua, Department Of Surgical And Gastroenterological Sciences, Clinica Chirurgica 1, Padua/ITALY, <sup>2</sup>Department Of General Surgery, Ss Giovanni E Paolo Hospital, Ulss 12, Venezia/ITALY

**Background:** Albeit rare, esophageal leiomyomas are the most frequent benign esophageal tumors. Videoendoscopic techniques have changed the surgical approach to these lesions. In this video, the authors present the different surgical techniques for the enucleation of esophageal leiomyomas, depending on their location and size, and review their experience in the field.

**Methods:** From 1999, 24 patients (Median age: 48; 12 male) underwent surgical enucleation of esophageal leiomyoma. In 11 patients, with tumor located in the thoracic esophagus, a thoracoscopic approach was used (7 right lateral, 4 prone position). Thirteen additional patients, with the tumor within 5 cm from the cardia, were approached through laparoscopy. In these cases, a partial emifundoplication was also added. In all cases, the reapproximation of the muscle layers was performed to prevent the development of a pseudodiverticulum.

**Results:** The median operative time was 175 min. Two conversions were necessary (one in each group). In another laparoscopic case, the repair of a mucosal lesion was performed. Patients resumed oral feeding after a Gastrografin swallow. Median post-operative hospital stay was 5 days. No mortality or major morbidity (i.e.: leakages) were observed. All tumors were benign leiomyomas (median size: 4.5 cm). Median follow up was 25 months (2–88). Most patients are asymptomatic, with GERD symptoms and grade A esophagitis in one patient operated with the laparoscopic approach. One additional patient developed an asymptomatic pseudodiverticulum at the enucleation site.

**Discussion:** Video-assisted enucleation of esophageal leiomyomas is effective and safe. Different approaches can be used based on the position and size of the tumors.

**Disclosure:** All authors have declared no conflicts of interest.

**VI.09 LAP REOPERATION IN GASTROESOPHAGEAL REFLUX DISEASE - TACTICS AND SURGICAL APPROACH TO THE DYSPHAGIA AND RECURRENT REFLUX**

Sergio Szachnowicz<sup>1</sup>, Rubens Sallum<sup>2</sup>, Julio Rocha<sup>3</sup>, Francisco Seguro<sup>4</sup>, Marco Aurelio Santo<sup>5</sup>, Ivan Ceconello<sup>6</sup>

<sup>1</sup>Department Of Gastroenterology – Esophageal Surgical Division, University Of São Paulo School Of Medicine, São Paulo - Brazil, São Paulo/BRAZIL, <sup>2</sup>University Of Sao Paulo, Sao Paulo/BRAZIL,

<sup>3</sup>Esophageal Surgical Division Univ Of Sao Paulo, Sao Paulo, Brazil, Sao Paulo/BRAZIL, <sup>4</sup>Hospital Das Clinicas - Fmusp, São Paulo/BRAZIL,

<sup>5</sup>Department Of Gastroenterology – Esophageal Surgical Division, University Of São Paulo School Of Medicine, Sao Paulo/BRAZIL,

<sup>6</sup>Esophageal Surgical Division Univ Of Sao Paulo, Sao Paulo/BRAZIL

**Background:** The indication for surgical re-operation of gastroesophageal reflux disease (GERD) is often individualized Aim: show the most common causes of reoperation and steps of the surgical re treatment

**Methods:** The video shows various surgical procedures edited by addressing the main indications for lap reoperation in GERD, acquired in the treatment of 97 consecutive patients

**Results:** First, will be discussed reoperation for early and late dysphagia after antireflux procedure, due to constriction of the esophageal hiatus, twisting or displacement of the fundoplication.

In the second phase will be addressed reoperation for recurrent reflux with emphasis on the main tactics for success in reoperations.

**Discussion:** Reoperation in GERD in a referral service is safe by lap approach with low morbimortality with good results

**Disclosure:** All authors have declared no conflicts of interest.

**VI.10 FREQUENCY OF TRUE SHORT ESOPHAGUS IN TYPE II-IV HIATUS HERNIAS**

Sandro Mattioli, Alberto Ruffato, Vladimiro Pilotti, Luca Ferruzzi Division Of Thoracic Surgery, Gvm Care & Research, Maria Cecilia Hospital, Cotignola (Ravenna), Center For The Study And Therapy Of Diseases Of The Esophagus. Alma Mater Studiorum – University Of Bologna, Italy, Bologna/ITALY

**Background:** The length of the abdominal esophagus (AE) in patients undergoing surgery for type II-IV hiatus hernias is controversial. This lack of information may concur to the high rate of hernia's recurrence after repair. We measured intraoperatively the distance between the gastro-esophageal

junction (GEJ) and the hiatus in patients undergoing surgery for type II-IV hiatus hernias.

**Methods:** Thirty-four patients (26 females 76.4%, mean age 65.3 range 41–84 years) underwent a laparoscopic approach. After full isolation of the GEJ and complete resection of the sac, the position of the gastric folds was localized endoscopically and two clips were applied. The distance between the clips and the apex of the diaphragm was measured with a dedicated ruler after the esophageal dissection. In case of AE <1.5 cm a Collis-Nissen was performed.

**Results:** Mean duration of symptoms was 100 months (range 12–360), reflux symptoms were moderate in 21/34 (61.7%), severe in 13/34 (38.3%), esophagitis was present in 16/34 (47%). 4 (11.8%) were type II (para-esophageal), 24 (70.6%) were type III (mixed), 6 (17.6%) were type IV (organo-axial volvulus) hernias. After dissection AE was <1.5 cm in 17 (50%) in 0/4 of type II, in 13/24 of type III and in 4/6 of type IV. Seventeen patients (50%) underwent the Collis-Nissen.

**Discussion:** Short esophagus is present in 50% of type III-IV and in none of type II hiatus hernia. The intraoperative measurement of the length of the AE is an objective method for recognizing these cases.

**Disclosure:** All authors have declared no conflicts of interest.

**VI.11 THE ROUX EN Y DISTAL GASTRIC RESECTION WITH PRESERVATION OF THE GASTRIC REMNANT AND JEJUNAL INNERVATION: A VALID SURGICAL OPTION FOR THE TREATMENT OF DIFFICULT BENIGN SITUATIONS OF THE UPPER GASTRO-INTESTINAL TRACT**

Sandro Mattioli, Alberto Ruffato, Vladimiro Pilotti, Luca Ferruzzi Division Of Thoracic Surgery, Gvm Care & Research, Maria Cecilia Hospital, Cotignola (Ravenna), Center For The Study And Therapy Of Diseases Of The Esophagus. Alma Mater Studiorum – University Of Bologna, Italy, Bologna/ITALY

**Background:** The distal gastric resection with the Roux en y gastrojejunostomy has been proposed for the treatment of complex benign diseases involving the distal esophagus and gastro-esophageal junction, in alternative to esophageal resection, redo surgery and in case of concomitant esophageal and antrum functional or organic abnormalities. The rationale is to reduce gastric secretion, to divert bilio-pancreatic secretions, to preserve the motility of the gastric stump and the jejunal loop, in order to reduce the incidence and severity of the Roux stasis syndrome which may impair long term results in up to 50% of cases. In this video we show the technique and report the long term results.

**Methods:** We performed a 2/3 distal gastrectomy comprehensive of the whole gastrin secreting mucosa, maintaining the innervation of the gastric fundus. The stomach resection line formed a 145° angle with the lesser curvature to obtain a toboggan like end to side gastro-jejunostomy. We did not divide the jejunal mesentery underneath the jejunum resection line, to preserve the intrinsic innervation. It was otherwise easy, to perform the end to side jejunal-jejunostomy at least 70 cm below the gastro-jejunostomy.

**Results:** Clinical results were excellent in 11 out of 27 (40.8%), good in 10 (37%), fair in 1 (3.7%) and poor in 5 (18.5%) of whom 2 for Roux en Y Stasis Syndrome (global frequency 2/27 7.4%).

**Discussion:** The Roux en Y gastrojejunostomy may be a valid solution for difficult upper gastro-intestinal problems, if performed according to surgical physiology principles.

**Disclosure:** All authors have declared no conflicts of interest.

**VIDEO SESSION V2 – October 16, 2012 10:20–11:50****V2.01 SAFE USE OF POLYPROPYLENE MESH IN THE HIATUS IN TYPE III-IV HIATAL HERNIAS.**

Andre Brandalise, Nilton Aranha, Nelson Brandalise, Claudia Lorenzetti Fundacao Centro Medico Campinas, Campinas/BRAZIL

**Background:** The hiatal closure remains the Achilles Heel of the anti-reflux surgery. In large hernias (type III and IV) and re-operations it is even worse. In our group, we have been using in those patients a reinforcement of the hiatal closure with specially designed polypropylene mesh.

**Methods:** The mesh is cut in an U shaped pattern and the area in contact with the esophagus is protected with a Sylastic catheter. The fixation of the mesh over the sutured hiatus is done with endoscopic staples. To avoid contact with the gastric fundus the mesh is covered with the hernia sac and/or the great omentum.

**Results:** We used this technique in 70 patients, with good results, and no signs of mesh erosion to esophagus or stomach in an average follow of 60 months (6–140 months).

**Discussion:** The use of a polypropylene mesh in the hiatus is shown to prevent recurrence in large paraesophageal hernias. Unfortunately, many complications have been published, with polypropylene and other materials.

This video shows a technique we use since 1999 to try to avoid this complications. And with this technique, we have no cases of mesh erosion or strictures.

**Disclosure:** All authors have declared no conflicts of interest.

## V2.02 THORACOSCOPIC RESECTION OF GIANT ESOPHAGEAL LEIOMYOMA

Marnay Carvalho, Bruno Zilberstein  
*Gastromed Instituto Zilberstein, São Paulo/BRAZIL*

**Background:** This video shows the resection of a leiomyoma in the middle third of esophagus by thoracoscopy. It demonstrates the technical details from the positioning of the patient until the economic tumor resection executed without thoracotomy.

**Methods:** Female patient of 47 years old, who underwent bariatric surgery (RYGB) for 7 years, evolved with important dysphagia. The endoscopy demonstrates a submucosal tumor in the middle third of esophagus. The CT demonstrates a extensive tumor mass of 12 × 7 cm projected in the left hemithorax. The patient subjected to a right economic thoracoscopy for resection of the tumor without necessity of thoracotomy.

**Results:** The patient left the hospital on the tenth day of postoperative oral feeding and without drain. The material analysis revealed a leiomyoma.

**Discussion:** This video shows that it is enterly possible to approach giant submucosal tumors by thoracoscopy without open surgery.

**Disclosure:** All authors have declared no conflicts of interest.

## V2.03 LAPAROSCOPIC/THORACOSCOPIC SURGERY FOR COMPLEX TYPE II-IV HIATUS HERNIAS

Sandro Mattioli, Alberto Ruffato, Vladimiro Pilotti, Luca Ferruzzi  
*Division Of Thoracic Surgery, Gvm Care & Research, Maria Cecilia Hospital, Cotignola (Ravenna), Center For The Study And Therapy Of Diseases Of The Esophagus. Alma Mater Studiorum – University Of Bologna, Italy, Bologna/ITALY*

**Background:** In order to demonstrate the feasibility and the corner stones of the minimally invasive surgical technique for the treatment of type II-IV hiatus hernia we show the case of a 66-year-old woman with 20 years history of GERD symptoms, dyspnoea with orthopnea, erosive esophagitis and recurrent sideropenic anaemia. Barium swallow shows a paraesophageal hiatus hernia. We present a second case of a 56-year-old man complaining severe GERD symptoms since six years with painful dysphagia, erosive esophagitis. Barium swallow shows a non-reducible 10 cm diameter massive incarcerated hiatus hernia.

**Methods:** The steps of the surgical procedure are: 1) complete resection of the hernia sac and fat pad with preservation of the vagus nerves, 2) localization of the position of the gastro-esophageal junction with respect to the apex of the hiatus with a combined endoscopic-laparoscopic procedure, 3) measurement of the length of the submerged esophageal segment, 4) isolation of the mediastinal esophagus, 5) Collis gastroplasty in case of short esophagus, 6) hiatus alloplasty, 7) Nissen floppy fundusplication.

**Results:** After maximal esophageal mobilization, in the first patient the gastro-esophageal junction was placed 2.5 cm below the hiatus and a standard fundusplication was performed, in the second case the gastro-esophageal junction was placed across the hiatus and a combined laparoscopic-left thoracoscopic Collis gastroplasty was necessary.

**Discussion:** The minimally invasive approach for complex hiatus hernias appears feasible.

**Disclosure:** All authors have declared no conflicts of interest.

## V2.04 LAPAROSCOPIC RETROSTERNAL BYPASS FOR CORROSIVE STRICTURE OF THE ESOPHAGUS

Amit Javed, Anil Agarwal  
*Gb Pant Hospital & Mam College, New Delhi/INDIA*

**Background:** Surgical management of corrosive stricture of the esophagus entails replacement of the scarred esophagus with a gastric or colonic conduit. This has traditionally been done using the conventional open surgical approach. We herein in the video describe the first ever reported minimally invasive technique for performing retrosternal esophageal bypass using a stomach conduit.

**Methods:** Patients with corrosive stricture involving the esophagus alone with a normal stomach was selected. The surgery was performed with the patient in a supine position using 4 abdominal ports and a transverse skin

crease neck incision. Steps included mobilization of the stomach and division of the gastroesophageal junction, creation of a retrosternal space, transposition of stomach into the neck (via retrosternal space), and a cervical esophago-gastric anastomosis.

**Results:** The duration of surgery was 240 minutes. The patient was ambulated on the first postoperative day and was allowed oral liquids on the 5th day. At a follow up of 9 months, he is euphagic to solid diet and had an excellent cosmetic results.

**Discussion:** Laparoscopic bypass for corrosive stricture of the esophagus using a gastric conduit is technically feasible. It results in early post operative recovery, effective relief of dysphagia and excellent cosmesis in these young patients.

**Disclosure:** All authors have declared no conflicts of interest.

## V2.05 ESOPHAGEAL ACHALASIA ASSOCIATED TO A LARGE TYPE III HIATAL HERNIA: A CASE REPORT

Mario Costantini, Lisa Zanatta, Renato Salvador, Cristina Longo, Michela Di Giunta, Giulia Pozza, Nicola Passuello, Gloria Dogã, Giovanni Capovilla  
*University Of Padua, Department Of Surgical And Gastroenterological Sciences, Clinica Chirurgica 1, Padua/ITALY*

**Background:** The association between small, type I hiatal hernias and achalasia is not uncommon, and do not represent a surgical problem. On the contrary, the presence of large, type III hiatal hernia associated with achalasia is exceptional, and may constitute a diagnostic and therapeutic challenge. In this video, the authors present the laparoscopic surgical treatment of a patient with this association of diseases.

**Methods:** A 73-year-old lady, complaining of dysphagia, regurgitation and weight loss for a year, was diagnosed as having paraesophageal hiatal hernia and achalasia by endoscopy, barium swallow and manometry. At laparoscopy, a large hiatal defect was evident, with half of the stomach herniated into the mediastinum. The reduction of the hernia was performed, with partial excision of the sac. The esophagus was secured bilaterally to the crura, and a posterior partial fundoplication was performed. An 8-cm long myotomy was then performed. An anterior hiatoplasty with one stitch completed the operation. A mesh was considered not necessary.

**Results:** The operation lasted 150 min. After a Gastrografin swallow the patient resumed oral feeding and was discharged on 3<sup>rd</sup> POD. At a 18-month follow-up the patient is free of dysphagia. Endoscopy and barium swallow confirmed the good outcome of the operation.

**Discussion:** The laparoscopic surgical treatment of esophageal achalasia associated with large paraesophageal hernia have revealed to be feasible and have provided, in this patient, good long-term results. The use of prosthetic mesh should be avoided for the risk of complications, especially if complementary pneumatic dilations become necessary for the recurrence of achalasia symptoms.

**Disclosure:** All authors have declared no conflicts of interest.

## V2.06 LAPAROSCOPIC REVISIONAL MYOTOMY FOR RECURRENT ACHALASIA

John Preto<sup>1</sup>, Hugo Sousa<sup>1</sup>, António Gouveia<sup>1</sup>, Manuela Baptista<sup>1</sup>, José Barbosa<sup>1</sup>, José Costa-Maia<sup>2</sup>

<sup>1</sup>Unidade Esôfago-Gastro-Duodenal, Serviço De Cirurgia Geral, Centro Hospitalar De São João, Porto/PORTUGAL, <sup>2</sup>Serviço De Cirurgia Geral, Centro Hospitalar De São João, Porto/PORTUGAL

**Background:** Laparoscopic Heller myotomy for achalasia has been reported to have a 10–20 % failure rate. It may require re-do surgery in order to control persistent or recurrent symptoms. Revisional laparoscopic myotomy may pose a surgical challenge.

**Methods:** Present a video demonstrating the technical aspects of a laparoscopic revisional myotomy for recurrent achalasia.

**Results:** The authors present the case of a 36 year old female patient, previously diagnosed and treated for achalasia, with a laparoscopic Heller-Dor procedure. During follow-up, the patient began to refer persistent dysphagia. Studies performed confirmed recurrent achalasia. The patient was initially submitted to 3 sessions of dilation, with very little improvement of her symptoms. She was submitted to laparoscopic re-do myotomy with no complications and there were none observed during the post operative period. At 6 months follow up, the patient is with no complaints.

**Discussion:** Laparoscopic revisional myotomy for failed Heller-Dor procedure is feasible and results in symptom improvement.

**Disclosure:** All authors have declared no conflicts of interest.

**V2.07 ROBOTIC ACCESS FOR HIATAL HERNIA RECURRENCE WITH MESH**

Guilherme Tommasi Kappaz<sup>1</sup>, Ricardo Abdalla<sup>2</sup>, Rodrigo Garcia<sup>2</sup>, Rubens Sallum<sup>3</sup>

<sup>1</sup>Department Of Gastroenterology – Esophageal Surgical Division. University Of São Paulo School Of Medicine, São Paulo – Brazil, São Paulo/BRAZIL, <sup>2</sup>Hospital Sirio Libanes Teaching And Research Institute, Sao Paulo/BRAZIL, <sup>3</sup>University Of Sao Paulo, Sao Paulo/BRAZIL

**Background:** This video presentation is of a 61 year old woman with recurrent hiatal hernia with dysphagia and heartburn. Her first surgery was 8 years earlier and the symptoms begun since the first surgery. Her endoscopy showed a huge hiatal hernia and esophagogram with a kinked proximal gastric camera of about 8 cm in length. She also had esophageal reflux and slow gastric emptying

**Methods:** The procedure was performed with da Vinci® System, four robot arms and one 5 mm auxiliary trocar. Liver was retracted through sponge and suture presentation, without other incision. Dissection was made as one stationary arm to present any scar tissue around diaphragmatic crura or hernia sac and two arms working together, with bipolar dissector in one hand, plus harmonic scalpel on the other. Wrist movements and stability are important to perform a careful procedure. The surgery steps are right crura exposure, left branch and hernia sac dissection, distal esophageal isolation and recognition of the previous flap. Previous flap removal and suture of the hiatus were performed. A synthetic bioabsorbable non cellular matrix was laid over the closed hiatus as a tissue reinforcement. The mesh was sutured considering a muscular tissue margin between itself and the esophagus

**Results:** The patient was discharged within 24 h after taking clear liquids with no dysphagia and no reflux symptoms

**Discussion:** The robotic procedure was ideal for detailed dissection, even in scar tissue. Delicate movements, stability and precise vision facilitates the surgical procedure and brought confidence to the operation

**Disclosure:** All authors have declared no conflicts of interest.

**V2.08 TRANSHIATAL ROBOT-ASSISTED ESOPHAGECTOMY.**

Francesco Coratti, Stefano Bongiolatti, Michele Di Marino, Mario Annecchiario, Antonella Lombardi, Maurizio Di Bisceglie, Andrea Coratti  
*Ospedale Misericordia, Grosseto/ITALY*

**Background:** We describe a case of robotic transhiatal esophagectomy (RATE) for a stenosis after ingestion of caustics. The current study shows that RATE, with its decreased blood loss, minimal cardiopulmonary complications, and no hospital mortality, represents a safe and effective alternative for the treatment of esophageal pathology

**Methods:** We describe a case of robotic transhiatal esophagectomy (RATE) for a stenosis after ingestion of caustics not responsive at endoscopic treatment.

**Results:** We perform a transhiatal esophagectomy robot-assisted in a young woman with a stenosis of distal esophagus after ingestion of caustics. This video shows our positioning of trocars, robotic cart and technical pitfalls of this procedure.

**Discussion:** Traditional esophagectomy may be associated with mortality, considerable morbidity, and lengthy recovery.

Minimally invasive esophagectomy has the potential advantages of being a less traumatic procedure with an easier postoperative recovery.

**Disclosure:** All authors have declared no conflicts of interest.

**V2.09 INEXPENSIVE ALTERNATIVE FOR REPAIR OF GIANT HIATUS HERNIA – USE OF BOVINE PERICARDIUM.**

Beatriz Azevedo, Sergio Szachnowicz, Rubens Sallum, Ivan Ceconello  
*Department Of Gastroenterology – Esophageal Surgical Division. University Of São Paulo School Of Medicine, São Paulo – Brazil, São Paulo/BRAZIL*

**Background:** The giant hiatal hernias are difficult to treat diseases due to the high recurrence rate. In some cases it is necessary to use prostheses beyond hiatoplastia in an attempt to reduce the risk of recurrence. This video aims to show a cheap and widely available alternative, the prosthesis of bovine pericardium, showing their way of handling and fixation technique used in our service.

**Methods:** An edited video that shows step by step the dissection of giant hiatal hernia, hiatoplasty and posterior repair with bovine pericardium prosthesis, highlighting our way of handling, surgical technique, and final appearance.

**Results:** The placement of bovine pericardium prosthesis provided an enhancement to repair the esophageal hiatus in the intraoperative view. The

patient remains without complications related to the prosthesis, without evidence of recurrence of hiatal hernia or gastroesophageal reflux.

**Discussion:** The repair of giant hiatus hernias remains a challenge despite new technologies introduced. Various biological and synthetic materials has been studied for this purpose. The bovine pericardium prosthesis remains, in our experience, alternative low-cost, easy available, and handling beyond good results.

**Disclosure:** All authors have declared no conflicts of interest.

**VIDEO SESSION V3 – October 16, 2012 13:30–15:00****V3.01 ROBOT-ASSISTED DISTAL ESOPHAGECTOMY (LEWIS-SANTY PORCEDURE) FOR A CANCER OF ESOPHAGOGASTRIC JUNCTION WITH THE PATIENT IN PRONE POSITION.**

Stefano Bongiolatti, Mario Annecchiario, Antonella Lombardi, Michele Di Marino, Francesco Coratti, Andrea Coratti, Maurizio Di Bisceglie  
*Ospedale Misericordia, Grosseto/ITALY*

**Background:** Minimally invasive esophagectomy is rapidly emerging as a suitable surgical alternative to the open technique.

**Methods:** We describe a technique of distal esophagectomy (Lewis-Santy procedure) for a cancer of the esophagogastric junction by robot-assisted thoracoscopy with the patient in the prone position and with addominal time laparoscopy in the supine position.

**Results:** First the patient was placed in supine position for the abdominal time that consists in accurate lymphadenectomy (stations 8, 9, 11p, 19 and 20), gastric mobilization and creation of gastric tube. Subsequently the patient was placed in the prone position and we placed three trocars: on seventh intercostal space on posterior axillary line for camera and on fourth and ninth intercostal space on mid-scapular line for robotic arms. We perform the dissection of intrathoracic esophagus, the mediastinal lymphadenectomy (stations 110, 111, 112, 107 and 108) and finally we perform manual esophago-gastric anastomosis realized by robotic arms.

**Discussion:** This technique allows a better and more accurate mediastinal and abdominal lymphadenectomy, a precise totally manual anastomosis and reducing postoperative pain and morbidity.

**Disclosure:** All authors have declared no conflicts of interest.

**V3.02 THE LESSONS FROM MORE THAN 150 EXPERIENCES OF RADICAL VIDEO-ASSISTED ESOPHAGECTOMY**

Harushi Udagawa, Masaki Ueno, Hisashi Shinohara, Shusuke Haruta, Sachiko Kaida, Masatoshi Nakagawa  
*Dept. Of Gastroenterological Surgery, Toranomon Hospital, Tokyo/JAPAN*

**Background:** The advantage of radical video-assisted esophagectomy (R-VAE) is generally regarded as its minimally invasive nature. We would like to show that the essential points are different.

**Methods:** Review our experience of R-VAEs between Sept. 2006 and Dec. 2011 and discuss the technical clues and advantages of the procedure.

**Results:** One hundred and sixty-eight R-VAEs were attempted and 151 (90%) were completed. When the patients were divided into 3 groups chronologically, the rate of conversion to open surgery of group A (first 56 patients), B (mid 56) and C (last 56) was 13, 14, and 3.6%. The average number of dissected mediastinal nodes was 32.8, 34.6, and 36.1.

**Discussion:** The basic principle of R-VAE is the en bloc dissection. The key for success is the understanding of surgical anatomy. The technical clues include

to follow the steps of the open surgery,  
to identify layered structure,  
to utilize magnification and shift of the view point,  
to repeat tiny traction and dissection,  
to add gross traction adequately,  
to leave the esophagus uncut,  
to know where blunt dissection is effective.

With these clues, R-VAE can be more than equally meticulous and extended operation compared to open procedure.

Video-assisted surgery is very educational. R-VAE in left lateral position is the best simulation of radical esophagectomy via right thoracotomy. The current step of our educational program is Assistant of open esophagectomy >> Assistant of R-VAE >> Operator of R-VAE >> Operator of open esophagectomy.

**Disclosure:** All authors have declared no conflicts of interest.



### V3.03 ENDOSCOPIC SUBMUCOSAL DISSECTION (ESD) USING NEW DEVICE MUCOSECTOM2 FOR ESOPHAGEAL CANCERS

Yoshiro Kawahara<sup>1</sup>, Hiroyuki Okada<sup>1</sup>, Kazuhide Yamamoto<sup>2</sup>  
<sup>1</sup>Department Of Endoscopy, Okayama University Hospital, Okayama JAPAN, <sup>2</sup>Gastroenterology & Hepatology, Okayama University Graduate School Of Medicine Dentistry And Pharmaceutical Sciences, Okayama JAPAN

**Background:** We developed and reported a safe and easy technique of the ESD using Mucosectom (Pentax Japan) for gastric cancers. Because the wall of esophagus is very thin and its lumen is very narrow, en-bloc resection for esophageal tumors by ESD is thought to be a very difficult procedure in gastrointestinal tract. We have developed New-type Mucosectom (Mucosectom2) to carry out ESD safely. We display our ESD technique for early esophageal cancers using Mucosectom2.

**Methods:** Mucosectom is composed with flexible plastic shaft and cutting wire. Plastic shaft moves a muscular layer side; cutting wire moves a mucosal layer side of the submucosa during ESD, and then procedure itself becomes safe. To adjust the esophageal lesion, we improved the conventional Mucosectom. The blade length has been shortened 5 mm to 2.5 mm and the diameter has become thinner than that of the conventional type. We used and evaluated this Mucosectom2 in 54 esophageal ESD cases.

**Results:** We could complete the esophageal ESD by Mucosectom2 in all cases. By using this new device, we could dissect the submucosa very quickly. The mean (95% CI) procedure time was 58.49 (53.76–63.21) min in the conventional group and 27.12 (21.78– 32.45) min in the Mucosectom2 group. The procedure time of esophageal ESD with Mucosectom2 group is significantly shorter than that with conventional group. The mean of differences is 24.73(15.82–33.64) min (P < 0.0001).

**Discussion:** We present a novel method of ESD for early esophageal cancers using Mucosectom2, which can realize safer, easier, and less time-consuming ESD compared to previous methods using other devices.

**Disclosure:** All authors have declared no conflicts of interest.

### V3.04 NEAR TOTAL DISTAL PANCREATECTOMY AND GASTRIC CONDUIT RESECTION FOR PANCREATIC ADENOCARCINOMA AFTER IVOR-LEWIS ESOPHAGECTOMY

Carlo Staudacher, Elena Orsenigo, Carlo Socci, Luca Ghirardelli, Michele Carvello  
University Vita-Salute San Raffaele, Milan/ITALY

**Background:** Gastric conduit resection after Ivor-Lewis esophagectomy often results in high operative mortality and morbidity rates due to mediastinal surgery related complications.

**Methods:** This report describes the case of a 52 years old male patient who has undergone laparoscopic-thoracotomy Ivor-Lewis distal esophagectomy for a Siewert I adenocarcinoma pT3 pN2 G2 M0. Adjuvant chemotherapy was administered after surgery. Five years after surgery patient developed an adenocarcinoma of the pancreatic isthmus infiltrating the gastric conduit the gastroduodenal artery and focally the hepatic segment II. One year after chemotherapy regimen (PDFG) CT scan showed no distant metastasis and no disease progression. The patient was scheduled for surgery and underwent laparotomic-thoracotomy resection of the gastric conduit, near total distal pancreatectomy and splenectomy. Transverse colon marginal artery was ligated for oncologic purpose. An ileo-ascending colon graft pedicled on the right ileocolic artery was used to restore intestinal continuity. Esophago ileo anastomosis and transverse-jejunosomy were performed. On post operative day 7 after surgery the patient developed right massive chylothorax and underwent redo right thoracotomy. A lymphatic leak from the thoracic duct was found and sealed.

**Results:** Histological examination showed a pancreatic ductal adenocarcinoma pT3 pN1 G2 infiltrating the gastric conduit. The patient is disease free at short term follow up.

**Discussion:** Gastric conduit resection for metachronous pancreatic adenocarcinoma is feasible. Ileo-colic graft pedicled on right colic artery may be used to restore intestinal continuity in case other suitable intestinal segments have impaired perfusion after extended oncological resection.

**Disclosure:** All authors have declared no conflicts of interest.

### V3.05 PATIENT POSITION FOR A SYNCHRONOUS CERVICOTHORACOABDOMINAL TWO-TEAM ESOPHAGECTOMY

Sandro Mattioli, Vladimiro Pilotti, Luca Ferruzzi, Alberto Ruffato  
Division Of Thoracic Surgery, Gvm Care & Research, Maria Cecilia Hospital, Cotignola (Ravenna), Center For The Study And Therapy Of Diseases Of The Esophagus. Alma Mater Studiorum – University Of Bologna, Italy, Bologna/ITALY

**Background:** Cervicothoracoabdominal and cervicoabdominal approach are routinely adopted for total or subtotal esophagectomy. We propose a

modification of the Nanson's patient position to optimize sequential or simultaneous left cervicotomy, laparotomy, and eventual right thoracotomy with one or two surgical teams.

**Methods:** The main feature of this technique is the possibility, by rotating the table on each side, of obtaining a horizontal supine patient position or a right chest up patient position as for a normal laparotomic or thoracotomic procedure. We use a surgical table that permits a 25-degree rotation on each side and maintains stability when the patient is in the horizontal supine position in which the entire body weight is completely off center with respect to the base of the bed. A two-team operation may be carried out with one team working on the abdomen and one on the neck.

**Results:** Our variation of the Nanson's position permits the operation to be carried out as if each step of the procedure were performed singularly and yet without redraping or repositioning of the patient. It maintains the advantage of shortening the operating time by means of a synchronous combined two-team operation. Disadvantages are only the extra set-up time and extra equipment.

**Discussion:** This technique permits better control of the operative field for each phase of the procedure with coordinated operating of two surgical teams on the neck, abdomen, and chest.

**Disclosure:** All authors have declared no conflicts of interest.

### V3.06 GASTRIC PULL UP RECONSTRUCTION AFTER PHARYNGO-LARYNGO-ESOPHAGECTOMY FOR RECURRENT SQUAMOUS CELL CARCINOMA

Carlo Staudacher, Elena Orsenigo, Mario Bussi, Carlo Socci, Stefano Bondi, Michele Carvello  
University Vita-Salute San Raffaele, Milan/ITALY

**Background:** Pharyngolaryngo-Esophagectomy with esophago-gastric anastomosis is a reliable surgical technique to treat the neck tumors involving hypopharynx and cervical esophagus. Pectoralis major myocutaneous flap is commonly used in neck surgical reconstruction. The purpose of this video is to demonstrate the feasibility of this surgical technique in the treatment of tumor recurrence for squamous cell carcinoma of the neck.

**Methods:** A 60 years old patient has undergone radiation treatment and partial laryngectomy for a squamous cell carcinoma in 2003 and presented recurrence in the hypopharynx and cervical esophagus. Surgical plan was a Pharyngolaryngo-esophagectomy. A two team approach was used to shorten the time of surgery. Extended cervical Lymphnodes dissection was made on the neck operating field and myocutaneous flap anterior to the hypopharynx was removed together with the neoplasm for oncological radicality purpose. Gastric conduit was made up by laparotomy. Intestinal continuity was restored by pharyngo-gastric anastomosis. Pectoralis major myocutaneous flap was used for neck reconstruction. Jejunostomy was performed for early postoperative enteral feeding.

**Results:** Histological evaluation confirmed node negative recurrent squamous carcinoma. Resected specimen margins were free of neoplasm. The patient had no major complication after surgery. After an absence of leakage shown by Gastrographin swallow, oral intake was introduced. The patient is free of disease at short term follow-up.

**Discussion:** Pharyngolaryngo-esophagectomy and pectoralis major myocutaneous flap is safe and feasible in the treatment of recurrent squamous carcinoma of hypopharynx involving the cervical esophagus.

**Disclosure:** All authors have declared no conflicts of interest.

### V3.07 TWO OPTIONS FOR THE SURGICAL THERAPY OF ADENOCARCINOMA OF THE ESOPHAGUS AND CARDIA (ADEC): A MODULATED RESECTION + EXTENDED LYMPHADENECTOMY, THE GASTRIC PULL UP AT THE THORACIC DOME OR THE ROUX EN Y ESOPHAGO-JEJUNOSTOMY AT THE AZYGOS VEIN LEVEL

Sandro Mattioli, Alberto Ruffato, Vladimiro Pilotti, Luca Ferruzzi  
Division Of Thoracic Surgery, Gvm Care & Research, Maria Cecilia Hospital, Cotignola (Ravenna), Center For The Study And Therapy Of Diseases Of The Esophagus. Alma Mater Studiorum – University Of Bologna, Italy, Bologna/ITALY

**Background:** In spite of the recent simplification operated by the TNM 7<sup>th</sup> edition, pathogenesis of ADEC and consequently its surgical therapy are controversial. In 1988 our group decided to operate differently tumors prevalently located in the esophagus (Siewert type I sub total esophagectomy – gastric pull up at the dome) or cardia (Siewert type II, esophageal resection at the azygos vein total gastrectomy). The approach (right thoracotomy + laparotomy), complete lymphadenectomy of thoracic stations (#2,3,4r-l, 7, 8, 9) and abdominal (perigastric+emphatic, splenic artery, celiac trunk) are the same for both techniques except for greater curve nodes.

**Methods:** In this video we show the steps of sub total esophagectomy, esophageal resection + total gastrectomy, thoracic and abdominal lymphadenectomy, the gastric pull up and preparation of the jejunal loop to anastomose with the esophagus at the azygos vein.

**Results:** Results in terms of mortality, morbidity, survival, # of nodes resected, modalities of nodal metastatization recorded in two groups of patients consecutively operated upon in recent years (group 1, 54 patients in which Barret's epithelium was histologically diagnosed nearby the tumor gastric pull up) and, group 2, 140 patients in which it was not (total gastrectomy) are offered for discussion.

**Discussion:** Results are offered for discussion.

**Disclosure:** All authors have declared no conflicts of interest.

### V3.08 VIDEOTHORACOSCOPIC ESOPHAGECTOMY FOR SALVAGE SURGERY IN ESOPHAGEAL CANCER

Rubens Sallum<sup>1</sup>, Flavio Roberto Takeda<sup>2</sup>, Julio Rocha<sup>3</sup>, Ulysses Ribeiro<sup>4</sup>, Ivan Ceconello<sup>5</sup>

<sup>1</sup>University Of Sao Paulo, Sao Paulo/BRAZIL, <sup>2</sup>Esophageal Surgical Division – University Of Sao Paulo – São Paulo School Of Medicine – Icesp, São Paulo/BRAZIL, <sup>3</sup>Esophageal Surgical Division Univ Of Sao Paulo, Sao Paulo, Brazil, Sao Paulo/BRAZIL, <sup>4</sup>Department Of Gastroenterology – Esophageal Surgical Division – University Of São Paulo School Of Medicine, São Paulo/BRAZIL, <sup>5</sup>Esophageal Surgical Division Univ Of Sao Paulo, Sao Paulo/BRAZIL

**Background:** One of the most technically difficult procedures in surgery for esophageal cancer is the Salvage esophagectomy after definitive chemoradiation.

The indication of this procedure is very limited and with controversial benefit. Cases of locally advanced tumors with good response to initial treatment in patients within good clinical status performance are those best prospect for this indication.

The difficulties arise from local dissection especially due to late effects of radiotherapy and are usually higher than in situations of neoadjuvant therapy or without previous treatment.

**Methods:** After 80 consecutive cases of videothoracoscopic esophagectomy with lymphadenectomy in esophageal cancer (with or without neoadjuvant therapy), the authors present the experience in seven cases of this procedure in patients in the situation of salvage surgery.

**Results:** This video presents the technical steps of this procedure as well as limitations and difficulties in the dissection. Also, strategies in minimally invasive procedure to allow safe dissection into the fibrotic area are shown.

**Discussion:** From 7 procedures, conversion to open surgery was necessary in 1 case due to severe fibrosis. No deaths were observed in those cases. This procedure seems to be feasible and effective in selected cases.

**Disclosure:** All authors have declared no conflicts of interest.

### V3.09 AUSCULTATORY TRIANGLE THORACOTOMY AS LESS INVASIVE ESOPHAGECTOMY

Nobukazu Hokamura

National Cancer Center Hospital, Tokyo/JAPAN

**Background:** Less invasive surgery is thought to be useful to prevent fatal complications in esophagectomy. VATS is most less-invasive surgery, but it is very costly and needs special training. Auscultatory triangle thoracotomy (ATT) is a modification of ordinary thoracotomy and thought to decrease surgical stress through small incision and preserving osseous thorax. ATT makes it possible to perform same surgical procedure as ordinary thoracotomy. We evaluated this procedure through retrospective review of our surgical results.

**Methods:** The incision of 12 cm is placed on postero-lateral thorax. The latissimus dorsi muscle is split only for 5 cm. Thoracic cavity is gradually opened with preserving the anterior serratus muscle and ribs. Applied wound retractor (ML) is placed. Surgical loupe with a light produces provides good surgical view. Long type surgical instruments (more than 30 cm) are necessary. LigaSure<sup>®</sup> is very useful, if available.

**Results:** From 2009 to 2012, 22 patients underwent ATT esophagectomy, however, 4 patients were converted to ordinary thoracotomy. Residual 18 had advanced stage disease, and 8 had chemoradiotherapy and 10 had chemotherapy preoperatively. Two patients had reconstruction with colon. Pneumonia developed in 5 (28%), recurrent nerve paralysis developed also in 5 (28%). One operative death developed after salvage surgery.

**Discussion:** ATT esophagectomy is cheap and makes it possible for surgeons to perform same procedure without special training. It is easy to convert to ordinary thoracotomy. Postoperative complications are acceptable. This approach is useful as less invasive esophagectomy.

**Disclosure:** All authors have declared no conflicts of interest.

## VIDEO SESSION V4 – October 16, 2012 15:30–17:00

### V4.01 ENDOSCOPIC TREATMENT FOR SUPERFICIAL CARCINOMA OF BORDERLINE LESIONS BETWEEN THE CERVICAL ESOPHAGUS AND HYPOPHARYNX.

Hirofumi Kawakubo, Tai Omori, Rieko Nakamura,

Tsunehiro Takahashi, Norihito Wada, Hiroya Takeuchi,

Yoshiro Saikawa, Hirofumi Kawakubo

Department Of Surgery, School Of Medicine, Keio University, Tokyo/JAPAN

**Background:** Early diagnosis and early treatment are the best ways to improve cancer patient prognoses. We developed ELPS (endoscopic laryngo-pharyngeal surgery) as an endoscopic treatment for superficial pharyngeal carcinoma. ELPS is transoral endoscopic surgery for laryngeal cancer. After lifting the larynx using the laryngoscope, the scopist inserts endoscope and the operator inserts forceps and electric device transorally, and resects superficial pharyngeal carcinoma. However, ELPS has not been applied for cervical esophagus carcinoma because of the narrow working space. We developed a hybrid endoscopic surgery (ESD+ELPS) for borderline lesions between the cervical esophagus and hypopharynx. The purpose of this study was to examine the usefulness and effectiveness of endoscopic treatment for superficial carcinoma of the hypopharynx and cervical esophagus.

**Methods:** Hybrid endoscopic surgery (ESD and ELPS) was performed on 8 lesions, which involved both the hypopharynx and cervical esophagus.

**Results:** six of eight patients had esophageal cancer treatments in their past histories, two for ESD, two for esophagectomy and two for chemoradiation. All lesions were completely resected. The complications of this procedure were laryngeal edema for three patients, which required overnight intubation, and stenosis for two patients, which required endoscopic dilation more than 10 times. There were no long term complications in all patients.

**Discussion:** The results indicated the usefulness and effectiveness of hybrid endoscopic treatment (ELPS+ESD) for superficial carcinoma of borderline lesion between the cervical esophagus and hypopharynx.

**Disclosure:** All authors have declared no conflicts of interest.

### V4.02 CARCINOMA OF GASTRO-ESOPHAGEAL JUNCTION: LOW MORBIDITY OUTCOMES OF THE THE GARLOCK'S TYPE LEFT THORACOABDOMINAL APPROACH

Virendra Rajpurohit, Sanjay Sharma

S. L. Raheja Hospital, Mumbai/INDIA

**Background:** The surgical expertise has evolved over the last 2–3 decades for gastro-esophageal junction carcinomas. Garlock's technique that is well established provides a good access to mediastinum as well as abdomen. Radical en block abdominal and mediastinal lymphadenectomy can be achieved through this single incision approach. If required multi-organ resections are feasible through the same route.

**Methods:** We analysed prospective database of 107 patients of Gastro esophageal junction carcinomas operated over between 2004–2009 for treatment outcome and morbidity. All patients underwent radical surgery.

**Results:** Most of our patients were stage III (n = 63; 59%) followed by stage II (n = 34; 32%) and stage I (n = 10; 9%). All but one were Adenocarcinoma. Stage II and III patients also received adjuvant chemotherapy. After a median follow up of 56 months, local recurrence was seen in 18% and distant metastases in 35%. Overall Survival at 5 years was 44%. Incidence of anastomotic leak and pulmonary complications was 1% and 7% respectively. Operative mortality was nil in our cohort.

**Discussion:** This video presentation is the method describing the technical details of the procedure performed through the approach known as Garlock's approach. We highly recommend this for type II and type III gastro-esophageal junction carcinomas. This procedure permits extensive clearance of the primary and well as the draining areas leading to low local recurrence rates, reduces operative time, lesser pulmonary complications and shorter post-operative stay in the hospital.

**Disclosure:** All authors have declared no conflicts of interest.

### V4.03 LABORATORY TRAINING STEPS FOR ROBOT-ASSISTED ESOPHAGECTOMY WITH THORACIC LYMPHADENECTOMY

Rubens Sallum<sup>1</sup>, Ricardo Abdalla<sup>2</sup>, Rodrigo Garcia<sup>2</sup>,

Guilherme Tommasi Kappaz<sup>3</sup>, Ivan Ceconello<sup>4</sup>

<sup>1</sup>University Of Sao Paulo, Sao Paulo/BRAZIL, <sup>2</sup>Hospital Sirio Libanes Teaching And Research Institute, Sao Paulo/BRAZIL, <sup>3</sup>Department Of Gastroenterology – Esophageal Surgical Division. University Of São Paulo School Of Medicine, São Paulo – Brazil, São Paulo/BRAZIL, <sup>4</sup>Esophageal Surgical Division Univ Of Sao Paulo, Sao Paulo/BRAZIL

**Background:** This presentation regards a step by step standard protocol for training a new technique in robot esophagectomy with thoracic lymphadenectomy.

nectomy. Robot Training and standardization are important for doctors and residents. The robot technique, because of its new application, is an opportunity for laboratory access from the begging to make a step-by-step program schedule. The lab schedule brings confidence and safety skills for the surgeon and surgical team.

**Methods:** We used a da Vinci® System in an animal model. Thoracic approach is made with a model in a prone position. Three trocars are located on the right hemithorax under a semicircular formation pointing to the mid line.

**Results:** Dissection is made at distal esophagus, with recognition of para esophageal, infra carinal and R and L para tracheal lymph nodes. Because of the stability and quality of the image, it is possible to dissect those structures under safety, plus precision avoiding other noble tissues injuries. Isolation of recurrent laryngeal nerve is also feasible and worth to perform in this field. We made the model as a proposal for training and improvement.

**Discussion:** laboratory brought confidence and timing for a difficult procedure. Robot stability and visual quality were crucial for detail evidence at residents training.

**Disclosure:** All authors have declared no conflicts of interest.

#### V4.04 LAPAROSCOPIC-ASSISTED GASTRIC TUBE CREATION FOR THE RECONSTRUCTION ROUTE AFTER ESOPHAGECTOMY

Masaru Kawai, Masako Hiramatsu, Song-woong Lee, Takaya Tokuhara, Eiji Nomura, Kazuhisa Uchiyama  
*Osaka Medical College, Osaka/JAPAN*

**Background:** Gastric tube is most simple and useful organ for reconstruction after esophagectomy. We use laparoscopic approach for the creation of gastric tube. We present some technical point for laparoscopic-assisted gastric tube creation.

**Methods:** From January 2000 to January 2012, we have 302 consecutive patients of esophagectomy with gastric tube reconstruction in our department. In these cases of gastric tube creation, open laparotomy was used in 236 cases, hand assisted laparoscopic surgery (HALS) and was used in 37 cases and mostly using laparoscopic procedure was used in 29 cases. Laparoscopic-assisted gastric tube creation was used by 5 trocar technique. Liver retractor is important for the opening of esophageal hiatus in this method. We used special technique by silicon tube for liver retractor without other instrument. After mobilization of the stomach with preservation of right gastroepiploic vessels, stomach was pulled out from 3 cm extracted umbilical incision. Small diameter gastric tube was created using by linear stapler outside of the abdominal cavity.

**Results:** Operation time for abdominal procedure, complications and lymph node dissection were not significantly difference between three groups. Laparoscopic approach tends to have less bleeding, especially around the spleen because of good exposure by magnified effect. However laparoscopy to open laparotomy converted cases were included 3 cases in HALS and 1 case in laparoscopic approaches. All cases were troubled by uncontrolled bleeding.

**Discussion:** Esophagectomy is generally much excessive invasion by thoracotomy and laparotomy. Today, we use thoracoscopic and/or laparoscopic esophagectomy for improvement of surgical quality and minimally invasive for the patients.

**Disclosure:** All authors have declared no conflicts of interest.

#### V4.05 SENTINEL LYMPH NODE NAVIGATION IN ESOPHAGEAL SQUAMOUS CELL CARCINOMA

Elena Orsenigo, Carlo Staudacher, Carla Canevari, Edi Viale, Michele Carvello, Carlo Soggi  
*University Vita-Salute San Raffaele, Milan/ITALY*

**Background:** Sentinel lymph node concept describes the preferential lymphatic drainage of a primary tumor to a regional lymph node and is established in breast cancer and melanoma but its role is still controversial in esophageal cancer. The purpose of this video is to demonstrate feasibility of sentinel lymph node mapping for esophageal squamous carcinoma.

**Methods:** A 72 years old female was diagnosed with squamous carcinoma of esophagus. Preoperative work-up (CT scan, MRI and endoscopic ultrasound) showed a cT2 N0 lesion in the middle third of the esophagus. The day before surgery peritumoral radiomarker (Tc 99) was injected around the tumour in the sub-mucosal layer by upper endoscopy. A lymphoscintigraphy was performed and two hot spots were detected: mediastinum and lesser gastric curve. Patient was scheduled for Ivor-Lewis esophagectomy. Gastrolysis was performed by laparoscopy. Intraoperatively injection of blue patent was performed around the tumor by upper endoscopy. A right thoracotomy was performed to mobilize the middle third of the esophagus. By gamma probe sentinel lymph node was found in the lesser gastric curve and in Barety's space.

**Results:** Histological evaluation revealed a pT1b N0 squamous neoplasm and negative sentinel nodes. The patient had no complication after surgery and is disease-free at short-term follow-up.

**Discussion:** Sentinel lymph node navigation in esophageal is feasible and could provide improved staging for esophageal cancer. Further study is needed to address the impact on therapeutic algorithms.

**Disclosure:** All authors have declared no conflicts of interest.

#### V4.06 INTRATHORACIC LEAK AFTER MINIMALLY INVASIVE ESOPHAGECTOMY: THORACOSCOPIC REPAIR WITH REINFORCED PLEURAL FLAP

Eng Hong Pok, Kin Fah Chin, Chee Loong Yeap, Peng Choong Lau  
*University Malaya Medical Center, Kuala Lumpur/MALAYSIA*

**Background:** Intrathoracic leak after esophagectomy is a catastrophic event with significant morbidity and mortality. It remains a major therapeutic challenge. The dilemma of treatment is whether to extirpate the esophageal anastomosis with formation of esophagostomy or continue with primary repair with the risk of further leak. However, it is advocated that the primary repair provides good results if the leak is detected early with demonstrably healthy tissue. We would like to report our experiences together with video presentation of using thoracoscopic technique of primary repair of esophageal leak with pleural flap reinforcement

**Methods:** We had successfully repaired primarily the esophageal leak after thoracoscopic debridement and drainage. Regional viable pleural flap was used to reinforce the sites of primary repair.

**Results:** Two patients were treated as described. The mean interval from leak to surgery was 28 hours. One patient had an uneventful postoperative course with a mean hospital stay of 21days. The other case had contained leak which needed further endoscopic stenting. All 2 patients recovered without mortality.

**Discussion:** Optimal survival was achieved in those patients who were treated early and aggressively with surgery. Thoracoscopic primary repair with pleural flap is a safe and effective treatment for esophageal leak as it retains the native esophagus and avoids the need for later reconstructive operations.

**Disclosure:** All authors have declared no conflicts of interest.

#### V4.07 COMBINED EVAR AND IVOR-LEWIS

Simone Giacomuzzi<sup>1</sup>, Gian Franco Veraldi<sup>2</sup>, Andrea Zanoni<sup>3</sup>, Bruno Genco<sup>2</sup>, Giovanni Scudo<sup>1</sup>, Giovanni De Manzoni<sup>3</sup>  
<sup>1</sup>Upper G.I. Surgery Division, University Of Verona, Verona/ITALY,  
<sup>2</sup>Terapia Chirurgica Dei Piccoli E Grossi Vasi, Azienda Ospedaliera-Universitaria Itegrata Di Verona, Verona/ITALY, <sup>3</sup>Upper G.I. Surgery Division University Of Verona, Verona/ITALY

**Background:** The cancer rate in the elderly is gradually increasing with the increasing life expectancy; this rises problems of treatment strategies, especially when the tumor is very aggressive and requires a surgical procedure burdened by high morbi-mortality. Furthermore, in these patients, the presence of comorbidities is significantly more frequent than in younger patients.

**Methods:** We here report a case of a combined treatment of abdominal aortic aneurysm and adenocarcinoma of the distal thoracic esophagus in a 71-year old patient. At the preoperative workup, tumor was classified as cT1smN0M0 and the aneurysm was infrarenal, saccular, 4,1 cm in transverse diameter and 6,5 cm in length. The therapeutic approach adopted was an endovascular exclusion of the aneurysm by endoprothesis (Zenith-Flex Cook) as first step, followed by a transthoracic Ivor-Lewis subtotal esophagectomy with intrathoracic end-to-end esophago-gastro anastomosis according to a personal technique

**Results:** There were no postoperative complications related to the surgical procedure and the patient was discharged on the 14th postoperative day. At the one month follow-up, an endo-leak type 2a was noted and treated conservatively.

**Discussion:** A combined approach of Esophagectomy and endovascular aneurismectomy is feasible, but requires to be managed in dedicated centers.

**Disclosure:** All authors have declared no conflicts of interest.

**V4.08 TECHNIQUE OF TRANSORAL ORVIL EEA STAPLER FOR MINIMALLY INVASIVE TRANSTHORACIC ESOPHAGECTOMY**

Dawn Jaroszewski, Suzanne Carpenter, Chee-chee Stucky, Lee Mcghan, Helen Ross, Harshita Paripati, Kristi Harold  
*Mayo Clinic Arizona, Phoenix/UNITED STATES OF AMERICA*

**Background:** Minimally invasive esophagectomy (MIE) can be performed using a variety of techniques for creation of the gastro-esophageal anastomosis. We present our technique for transthoracic MIE using an end-to-side anastomosis (EEA) with a trans-orally directed circular stapler.

**Methods:** A retrospective review evaluated consecutive patients undergoing MIE for esophageal cancer or related disease with intrathoracic anastomoses using an EEA with a trans-orally directed circular stapler from December 2007–May 2010.

**Results:** Fifty-one patients underwent transthoracic MIE with neoadjuvant chemoradiotherapy performed in 62.7%. The operation involved laparoscopic formation of a gastric conduit and thoracoscopic resection of the esophagus with an esophago-gastric anastomosis utilizing the OrVil™ 25-mm Anvil and an EEA circular stapler (EEA XL 25-mm with 4.8-mm staples, Covidien, New Haven, CT) (our previously published technique). Mean operative time was 338 minutes including 4 cases also having intra-operative radiation therapy (range 211–565). In-hospital 90 day morbidity/mortality was 49.0% and 5.9%. Anastomotic leaks were observed in 5 patients (9.8%). Two patients diagnosed with leaks were clinically asymptomatic. Stricture was diagnosed and treated in 7 pts (13.7%).

**Discussion:** With the design of the OrVil™ 25-mm anvil in the form of a tilted head attached to an oropharyngeal tube, passage through the oropharynx and upper esophageal sphincter is easily performed. This facilitated the esophago-gastric anastomosis in our transthoracic MIE cases and achieved a comparable morbidity and mortality rate to experiences of open esophageal resections.

**Disclosure:** All authors have declared no conflicts of interest.

**V4.09 LAPAROSCOPIC TOTAL ADVENTITIAL RESECTION OF THE CARDIA WITH TRANSORALLY ASSISTED STAPLING OF THE INTRA-THORACIC ESOPHAGO-GASTRIC ANASTOMOSIS**

Abraham Botha, Gabriele Marangoni, Ahmed Hamouda, Kostas Tsigritis, Harriet Deere  
*St Thomas' Hospital, London/UNITED KINGDOM*

**Background:** We have previously shown that Total Adventitial Resection of the Cardia (TARC) for tumours of the gastro-esophageal junction can be done safely by open surgery. We have also shown that transorally assisted stapling of the intra-thoracic esophago-gastric anastomosis helps the conversion from open to laparoscopic surgery. It is crucial that laparoscopic surgery achieve oncological parity with open surgery. The purpose of this study was to assess whether TARC can be performed laparoscopically.

**Methods:** Between 2005 and 2001 all patients who had an esophago-gastrectomy with a fully laparoscopic abdominal phase, and either a video assisted thoracoscopy (VATS) or mini-thoracotomy were included. Data collected were patient demographics, preoperative chemoradiotherapy, intraoperative details, postoperative complications and final histology. The last operation in the series was recorded in high definition and assessed for completeness of the TARC, lymphadenectomy and intra-thoracic anastomosis.

**Results:** Some 155 laparoscopic esophago-gastrectomies were performed. The median length of stay was 14 days (range 10–210). Four patients died in hospital (2.58%). The video recording is of a patient with a large T3N0 Siewert type I adenocarcinoma of the esophago-gastric junction after neoadjuvant chemotherapy. The 4.5 hour laparoscopic/thoracoscopic resection was edited down to show the gastric mobilisation, gastric tube stapling, TARC, 2-field lymphadenectomy and transorally assisted stapling of the intra-thoracic anastomosis. The patient had an uncomplicated hospital stay.

**Discussion:** Laparoscopic/thoracoscopic resection of esophago-gastric junction tumours is made easier by transorally assisted stapling of the intra-thoracic esophago-gastric anastomosis. Total adventitial resection of the cardia is feasible laparoscopically which contributes to oncological parity between laparoscopic and open surgery.

**Disclosure:** All authors have declared no conflicts of interest.