

Freestyle Pedicled Perforator Flaps: Safety, Prevention of Complications, and Management Based on 85 Consecutive Cases

Salvatore D'Arpa, M.D., Ph.D.
Adriana Cordova, M.D.
Marco Pignatti, M.D.
Francesco Moschella, M.D.

Palermo and Modena, Italy



Background: Despite the widespread use of free perforator flaps, pedicled perforator flaps seem not to be as widely accepted, probably because of the fear of vascular complications caused by transfer of a flap attached only by its vascular pedicle, prone to shearing, kinking, and trauma. In this article, the authors report on their experience with 85 consecutive cases, focusing on incidence, prevention, and management of complications.

Methods: Eighty-five consecutive cases were treated over 6 years at the Plastic and Reconstructive Surgery Department of the University of Palermo for defects of different causes that were reconstructed with a freestyle pedicled perforator flap, in every region of the body, including the head and neck (41.2 percent), trunk (20 percent), upper limb (7.1 percent), and lower limb (31.8 percent). The majority of flaps (67.1 percent) were 180-degree propeller perforator flaps.

Results: Complete flap survival was observed in 93 percent of cases. Six flaps (7 percent) had vascular complications that were managed with venous supercharging (two cases), derotation (one case), conservative management (two cases), or secondary skin grafting (one case). The authors provide their approach to each situation to prevent or manage complications.

Conclusions: The 93 percent success rate in this series seems to be acceptable and demonstrates that these flaps might be safely included in the authors' routine. If the flaps are appropriately planned and executed, with the suggestions provided in this article, some mistakes can be avoided to make these flaps even safer. (*Plast. Reconstr. Surg.* 128: 892, 2011.)

CLINICAL QUESTION/LEVEL OF EVIDENCE: Therapeutic, IV.

Perforator flaps have revolutionized the practice of modern reconstructive plastic surgery, as free, anterolateral thigh, deep inferior epigastric artery perforator, and thoracodorsal artery perforator flaps are among the first options for head and neck, breast, and limb reconstruction when a cutaneous flap is needed. As pedicled flaps, only relatively small series¹⁻⁴ have been published, and pedicled perforator flaps seem not to be as popular as free perforator flaps. Among the reasons is the fact that perforator flap harvesting requires the dissection of vessels as small as 0.5 mm. These vessels are extremely sensitive to shearing, torsion, kinking, and

spasms. When a free flap is used (based on a known and reliable donor site), a longer pedicle can be harvested and a microsurgical anastomosis, performed on vessels of usually more than 1.5 mm, will comfortably position the flap in the recipient site, minimizing tension and risks related to shearing forces. When a pedicled perforator flap is harvested, the regional anatomy dictates the pedicle length and is frequently not completely predictable.

Both for advancement flaps and for propeller flaps, where the rotations necessary to reach the recipient site can be up to 180 degrees, the pedicle can be prone to kinking, spasm, or occlusion. This is especially true if, because of inappropriate planning or execution, excessive tension is exerted on the pedicle. For these reasons, pedicled perforator

From Chirurgia Plastica e Ricostruttiva, Dipartimento di Discipline Chirurgiche ed Oncologiche, Università degli Studi di Palermo, and Chirurgia Plastica e Ricostruttiva, Policlinico di Modena.

Received for publication December 29, 2010; accepted March 18, 2011.

Copyright ©2011 by the American Society of Plastic Surgeons

DOI: 10.1097/PRS.0b013e3182268c83

Disclosure: *The authors have no financial interest to declare in relation to the content of this article.*

flaps are probably still not considered as reliable as other options, and this is why they are not as widespread as free perforator flaps.

To the best of our knowledge, the largest series published of pedicled perforator flaps is that of Hamdi et al.,⁵ which included 100 flaps. However, those were thoracodorsal artery perforator flaps, all of which were based on the same donor site.

A particular way of harvesting perforator flaps is the freestyle technique. Asko Seljavaara⁴ in 1983⁶ introduced the term “freestyle free flaps” to describe the flap harvesting technique based on the identification of a perforator/cutaneous vessel and the design of a skin island over it. Wide clinical application of this technique followed.⁷⁻¹⁰

A perforator vessel is located perioperatively with a handheld Doppler device and then chosen during surgical exploration. Around this, the flap is custom-designed with the advantage of a flap skin island tailored to the shape of each defect. These flaps can be used everywhere in the body, provided that a suitable perforator and an adequate quantity of local tissue are present.

The largest series published to date on freestyle perforator flaps has beautifully shown how useful they can be for reconstruction of every region of the body.¹⁰ In this study, a series of 85 consecutive freestyle pedicled perforator flaps from a single institution, harvested in almost all areas of the body, is presented.

Complications are reviewed and analyzed to assess the safety of pedicled perforator flaps. Tricks and tips for preventing, managing, and solving complications are discussed.

PATIENTS AND METHODS

Between November of 2004 and November of 2010, 85 patients were treated at the Plastic and Reconstructive Surgery Unit of the University of Palermo School of Medicine for reconstruction of defects of different causes with a freestyle pedicled perforator flap. Sixty-five patients were men and 20 were women. The patients' ages ranged between 40 and 92 years (mean, 76 years). Fifty-one patients underwent reconstruction after cancer resection, seven underwent reconstruction after resection of benign lesions (i.e., hydradenitis suppurativa, fibroadenoma of the breast, sternotomy wound dehiscence, pressure sore), four patients had salvage reconstruction after Port-A-Cath (Smiths Medical, Dublin, Ohio) exposure, three patients had coverage of a radial forearm flap donor site, and the remaining 20 were posttrau-

matic, of which one had a burn scar contracture (Table 1).

Among comorbidities, 32 had atherosclerotic vessel disease, 28 were diabetic, and 37 were smokers. Flaps were harvested in every region of the body (Table 1 and Fig. 1): 35 in the head and neck (41.2 percent), 17 in the trunk (20 percent), six in the upper limb (7.1 percent), and 27 in the lower limb (31.8 percent). Eighty-one flaps (95.3 percent) were island perforator flaps. The remaining four flaps (4.7 percent) were transferred as perforator-based flaps, which means that even though the perforator had been identified and isolated, the flap was not islanded because it was not necessary for optimal transfer. Perforator identification was performed to have consistent vascularization and not a “random” flap.

Flap designs (Table 1 and Fig. 2) were classic V-Y in 12 cases (14.1 percent), extended V-Y in six cases (7.1 percent), perforator-based transposition in four cases (4.7 percent), perforator propellers with 90-degree rotation in six cases (7.1 percent), and 180-degree rotation in 57 cases (67.1 percent). All flaps were based on a single perforator (Table 1). All operations were performed by the same surgeon.

Surgical Technique

After having mapped all the perforators around the defect/planned resection, an exploratory incision is made. To minimize morbidity, this incision is placed in previously existing scars or natural folds or along minimal tension lines. The exploratory incision should not interfere with an alternative local flap that should also be planned and marked preoperatively according to the surgeon's preferences and the characteristics of that particular anatomical region. This flap will only be used as a “plan B,” in case a suitable perforator for the freestyle flap cannot be found or is injured during dissection. Plan B can also be a free flap. To have a plan B is a safe preventive measure. We never had to use a plan B alternative in this series.

When a free flap is the alternative, like in most distal lower limb defects, the exploratory incision should be positioned, if possible, to allow access to the recipient vessels. The incision is carried down to the fascia and the perforators are identified with suprafascial dissection. The exploratory incision should be wide enough to allow easy visualization of the perforators. Once all the perforators are identified, the best one is chosen based on pulsatility, caliber, number and caliber of accompanying veins, proximity to the defect, subcutaneous

Table 1. Patient Data

Patient	Region	Defect	Diagnosis	Source Artery	Flap Size (cm)	Flap Design	Outcome
1	Head and neck	Nose	Basal cell carcinoma	Facial artery	1.2 × 0.8	180-degree propeller	Complete survival
2	Head and neck	Nose	Basal cell carcinoma	Facial artery	0.5 × 0.7	180-degree propeller	Complete survival
3	Head and neck	Nose	Basal cell carcinoma	Facial artery	2.2 × 1.6	180-degree propeller	Complete survival
4	Head and neck	Nose	Basal cell carcinoma	Facial artery	0.9 × 0.8	180-degree propeller	Complete survival
5	Head and neck	Nose	Basal cell carcinoma	Facial artery	1 × 1.1	180-degree propeller	Complete survival
6	Head and neck	Nose	Basal cell carcinoma	Facial artery	2 × 1.5	180-degree propeller	Complete survival
7	Head and neck	Nose	Basal cell carcinoma	Facial artery	1.4 × 1	180-degree propeller	Complete survival
8	Head and neck	Nose	Basal cell carcinoma	Facial artery	1.2 × 0.8	180-degree propeller	Partial necrosis, secondary healing
9	Head and neck	Nose	Basal cell carcinoma	Facial artery	1.8 × 0.9	180-degree propeller	Complete survival
10	Head and neck	Nose	Basal cell carcinoma	Facial artery	1.4 × 0.8	180-degree propeller	Complete survival
11	Head and neck	Nose	Basal cell carcinoma	Facial artery	2 × 1	180-degree propeller	Complete survival
12	Head and neck	Nose	Basal cell carcinoma	Facial artery	1.3 × 0.7	180-degree propeller	Complete survival
13	Head and neck	Nose	Basal cell carcinoma	Supratrochlear artery	6 × 2	180-degree propeller	Complete survival
14	Head and neck	Nose	Basal cell carcinoma	Supratrochlear artery	12 × 1.5	180-degree propeller	Complete survival
15	Head and neck	Nose	Basal cell carcinoma	Supratrochlear artery	8 × 13.3	180-degree propeller	Arterial insufficiency, salvaged by derotation
16	Head and neck	Nose	Basal cell carcinoma	Supratrochlear artery	6 × 1.3	180-degree propeller	Complete survival
17	Head and neck	Nose	Basal cell carcinoma	Supratrochlear artery	5.6 × 1.4	180-degree propeller	Complete survival
18	Head and neck	Nose	Basal cell carcinoma	Supratrochlear artery	6.7 × 12.7	180-degree propeller	Complete survival
19	Head and neck	Nose	Basal cell carcinoma	Supratrochlear artery	7.2 × 1.5	180-degree propeller	Complete survival
20	Head and neck	Nose	Breast cancer	Supratrochlear artery	8.6 × 4.2	180-degree propeller	Complete survival
21	Head and neck	Nose	Breast cancer	Supratrochlear artery	4.8 × 1.3	180-degree propeller	Complete survival
22	Head and neck	Nose	Breast cancer	Supratrochlear artery	6 × 1.4	180-degree propeller	Complete survival
23	Head and neck	Nose	Breast cancer	Supratrochlear artery	6.3 × 1.8	180-degree propeller	Complete survival
24	Head and neck	Nose	Breast cancer	Supratrochlear artery	7.2 × 3.8	Extended V-Y	Complete survival
25	Head and neck	Nose	Burn scar contracture	Supratrochlear artery	6.8 × 1.6	V-Y	Complete survival
26	Head and neck	Retroauricular	Dermatofibrosarcoma protuberans	Posterior auricular artery	8 × 3	180-degree propeller	Complete survival
27	Head and neck	Neck	Fibroadenoma	Posterior auricular artery	9.5 × 4.5	180-degree propeller	Complete survival
28	Head and neck	Neck	Hydradenitis suppurativa	Transverse cervical artery	17 × 8	180-degree propeller	Complete survival
29	Head and neck	Upper lip	Hydradenitis suppurativa	Facial artery	4.2 × 2.8	V-Y	Complete survival
30	Head and neck	Upper lip	Hydradenitis suppurativa	Facial artery	4 × 2.5	180-degree propeller	Complete survival
31	Head and neck	Upper lip	Hydradenitis suppurativa	Facial artery	3.5 × 2.8	180-degree propeller	Complete survival
32	Head and neck	Upper lip	Melanoma	Facial artery	3.5 × 2.8	180-degree propeller	Complete survival
33	Head and neck	Cheek	Multifocal basal cell carcinoma	Facial artery	3 × 2	180-degree propeller	Complete survival
34	Head and neck	Lower lip, skin	Oral cancer	Facial artery	6 × 4	180-degree propeller	Complete survival
35	Head and neck	Lower lip, skin	Oral cancer	Facial artery	4 × 3.2	180-degree propeller	Complete survival
36	Breast	Central and lateral	Oral cancer	Lateral intercostal artery	24 × 12.5	180-degree propeller	Complete survival
37	Breast	Central and lateral	Port-A-Cath exposure	Thoracodorsal artery	20 × 11	180-degree propeller	Complete survival
38	Breast	Lateral	Port-A-Cath exposure	Thoracodorsal artery	18 × 11	180-degree propeller	Complete survival
39	Breast	Middle	Port-A-Cath exposure	Anterior intercostal artery	15 × 5	90-degree propeller	Complete survival

(Continued)

Table 1. (Continued)

Patient	Region	Defect	Diagnosis	Source Artery	Flap Size (cm)	Flap Design	Outcome
40	Breast	Middle	Port-A-Cath exposure	Superior epigastric artery	8 × 3	90-degree propeller	Complete survival
41	Breast	Medial	Pressure sore	Superior epigastric artery	12 × 4	90-degree propeller	Complete survival
42	Presternal	Lower two-thirds	Squamous cell carcinoma	Superior epigastric artery	22 × 7	180-degree propeller	Complete survival
43	Presternal	Lower two-thirds	Squamous cell carcinoma	Superior epigastric artery	14 × 5	180-degree propeller	Complete survival
44	Anterior chest	Subclavicular	Squamous cell carcinoma	Thoracoacromial artery	6 × 2	Perforator-based	Complete survival
45	Anterior chest	Subclavicular	Squamous cell carcinoma	Thoracoacromial artery	8 × 2.5	Perforator-based	Complete survival
46	Anterior chest	Subclavicular	Squamous cell carcinoma	Thoracoacromial artery	7 × 3	Perforator-based	Complete survival
47	Anterior chest	Subclavicular	Squamous cell carcinoma	Thoracoacromial artery	6 × 2.5	Perforator-based	Complete survival
48	Abdomen	Epigastrium	Squamous cell carcinoma	Deep inferior epigastric artery	12 × 8	Extended V-Y	Complete survival
49	Posterior chest	Scapular	Squamous cell carcinoma	Thoracodorsal artery	21 × 13	180-degree propeller	Complete survival
50	Chest	Axilla	Squamous cell carcinoma	Thoracodorsal artery	15 × 8	180-degree propeller	Complete survival
51	Chest	Axilla	Squamous cell carcinoma	Thoracodorsal artery	13 × 8	180-degree propeller	Complete survival
52	Lower back	Lumbar	Squamous cell carcinoma	Posterior intercostal artery	23 × 8	90-degree propeller	Complete survival
53	Volar forearm	Radial forearm flap donor site	Squamous cell carcinoma	Ulnar artery	8 × 4	180-degree propeller	Complete survival
54	Volar forearm	Radial forearm flap donor site	Squamous cell carcinoma	Ulnar artery	10 × 5	90-degree propeller	Complete survival
55	Volar forearm	Radial forearm flap donor site	Squamous cell carcinoma	Ulnar artery	7 × 4	180-degree propeller	Complete survival
56	Volar forearm	Distal third	Squamous cell carcinoma	Ulnar artery	13 × 6	180-degree propeller	Salvaged by venous supercharging Failed salvage, 90% necrosis
57	Volar forearm	Distal third	Squamous cell carcinoma	Radial artery	12 × 4	180-degree propeller	Complete survival
58	Dorsal fifth finger	Dorsal MCP to PIP	Squamous cell carcinoma	Dorsal metacarpal artery	4 × 1	180-degree propeller	Complete survival
59	Groin	Groin crease	Squamous cell carcinoma	Lateral circumflex femoral artery	14 × 6	180-degree propeller	Complete survival
60	Sacral	Intergluteal crease	Squamous cell carcinoma	Superior gluteal artery	18 × 6	180-degree propeller	Complete survival
61	Sacral	Intergluteal crease	Squamous cell carcinoma	Superior gluteal artery	30 × 16	V-Y	Complete survival
62	Lower leg	Pretibial middle third	Squamous cell carcinoma	Peroneal artery	4 × 12	Extended V-Y	Complete survival
63	Lower leg	Pretibial middle third	Squamous cell carcinoma	Peroneal artery	5 × 13	Extended V-Y	Complete survival
64	Lower leg	Pretibial proximal third	Squamous cell carcinoma	Medial sural artery	4 × 11	Extended V-Y	Complete survival

(Continued)

Table 1. (Continued)

Patient	Region	Defect	Diagnosis	Source Artery	Flap Size (cm)	Flap Design	Outcome
65	Lower leg	Pretibial proximal third	Squamous cell carcinoma	Tibialis posterior artery	3 × 7	Extended V-Y	Complete survival
66	Lower leg	Pretibial, distal third	Sternotomy wound dehiscence	Tibialis posterior artery	5 × 26	180-degree propeller	Partial necrosis, skin grafted
67	Lower leg	Pretibial, distal third	Trauma	Tibialis posterior artery	6 × 15	180-degree propeller	Complete survival
68	Lower leg	Pretibial, distal third	Trauma	Tibialis posterior artery	5 × 13	180-degree propeller	Complete survival
69	Lower leg	Pretibial, distal third	Trauma	Tibialis posterior artery	4 × 14	180-degree propeller	Complete survival
70	Lower leg	Pretibial, distal third	Trauma	Tibialis posterior artery	3 × 12	180-degree propeller	Complete survival
71	Lower leg	Pretibial, distal third	Trauma	Tibialis posterior artery	4 × 15	180-degree propeller	Complete survival
72	Lower leg	Lateral, middle third	Trauma	Peroneal artery	3 × 8	180-degree propeller	Complete survival
73	Lower leg	Lateral, middle third	Trauma	Peroneal artery	4 × 11	180-degree propeller	Partial necrosis, secondary healing
74	Lower leg	Lateral, distal third	Trauma	Peroneal artery	3 × 10	180-degree propeller	Complete survival
75	Lower leg	Pretibial, distal third	Trauma	Peroneal artery	4 × 10	180-degree propeller	Complete survival
76	Lower leg	Achilles tendon	Trauma	Tibialis posterior artery	3 × 10	V-Y	Complete survival
77	Lower leg	Pretibial middle third	Trauma	Peroneal artery	4 × 8	V-Y	Complete survival
78	Lower leg	Peroneal side, proximal third	Trauma	Peroneal artery	5 × 8	V-Y	Complete survival
79	Lower leg	Pretibial proximal third	Trauma	Peroneal artery	4 × 9	V-Y	Complete survival
80	Lower leg	Calf	Trauma	Tibialis posterior artery	5 × 11	V-Y	Complete survival
81	Lower leg	Medial, middle third	Trauma	Tibialis posterior artery	3 × 7	V-Y	Complete survival
82	Lower leg	Medial, distal third	Trauma	Tibialis posterior artery	3 × 8	V-Y	Complete survival
83	Lower leg	Achilles tendon	Trauma	Tibialis posterior artery	5 × 11	V-Y	Complete survival
84	Lower leg	Medial, distal third	Trauma	Tibialis posterior artery	4 × 9	V-Y	Complete survival
85	Lower leg	Pretibial distal third	Trauma	Tibialis posterior artery	6 × 15	90-degree propeller	Infection of the skin grafted donor site

MCP, metacarpophalangeal; PIP, proximal interphalangeal.

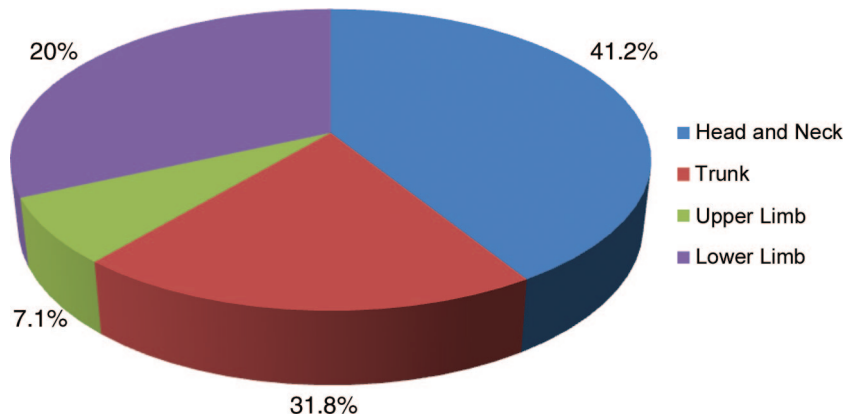


Fig. 1. Defect location.

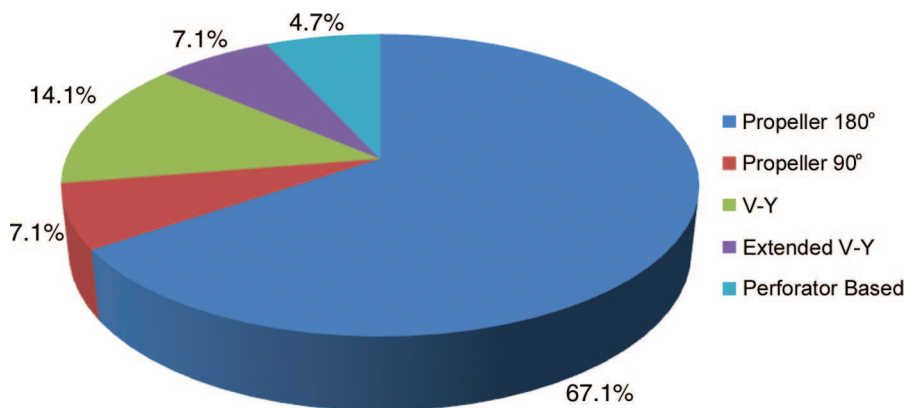


Fig. 2. Flap design.

course and orientation, and proximity to a sensory nerve. These general criteria need to be adapted to each specific case. Caliber of the perforating vessel, for example, is a relative value dependent on the size of the flap: intuitively, a larger flap will need a perforator of larger caliber and stronger pulsatility. In our experience, the real limit to a flap's size is the possibility of donor-site closure rather than concerns regarding the flap perfusion. When the flap needed is too large to obtain primary closure, we would choose a free flap to obtain better donor-site cosmesis.

This is especially true in the head and neck region, where only concealable donor sites amenable to primary closure are chosen. If a very large flap is needed, a local flap will cause extensive disfigurement and a distant option will be chosen. An exception to this general guideline is in the anatomical region of the leg where, even if donor-site primary closure can be achieved only in selected cases, the freestyle pedicled perforator flap can be a very useful reconstructive tool, sometimes worthy even if the price to pay is a skin-grafted

donor site. In the leg, tibialis posterior perforators are preferred when possible because they are usually larger, have better veins, and allow easier dissection compared with anterior tibial and peroneal artery perforators.

Once the perforator has been chosen, the flap is redrawn, correcting the preoperative markings when needed, based on the surgeon's preferences and recipient-site requirements. Centering the skin island over the perforator would maximize vascularization and reduce the risk of torsion, kinking, or tension on the pedicle when mobilizing the flap.

As a general rule, the flap should be oriented transversely in the trunk and longitudinally in the limbs,¹⁰ especially when large flaps have to be harvested. In the head and neck, these flaps are usually the evolution of more traditional pedicled skin flaps and should be harvested from the same well-described donor sites. For superior epigastric artery perforator flaps originating close to the xyphoid process, the caudal/oblique orientation should be preferred when a large flap is needed.

If an average size flap is needed, transverse orientation will allow the flap to be hidden in the submammary sulcus and is then preferable.

Conventional length-to-width ratios do not apply to freestyle pedicled perforator flaps, not only because these flaps are not random, but also because the pedicle is not placed at one end of the flap but normally is very close to the midpoint. For example, the flap in Figure 4, measuring 26 × 5 cm, should not be considered a skin island with a 5:1 ratio but rather a flap made of two smaller skin islands, one with a 3:1 (16 × 5 cm) ratio and the other with a 2:1 (10 × 5 cm) ratio.

Once the skin flap harvest has been completed, the perforating artery and vein should be prepared adequately. If a V-Y or 90-degree propeller is chosen, neither aggressive perforator dissection nor skeletonization is necessary. When higher rotations are needed, the perforators should be skeletonized for their entire length to free them from adhesions and distribute torsion evenly.

If additional pedicle length is needed, the source vessel can be dissected and ligated distal to the perforator. This has been done in six cases (five thoracodorsal artery perforator flap and one lateral circumflex femoral artery perforator flap in this series (patients 37, 38, 49 through 51, and 59; Table 1).

At this point, vascularization of the flap is checked. Usually, manipulation causes some

spasm; therefore, especially when flap rotations greater than 90 degrees are planned, we wait for this spasm to settle before rotating the flap.

RESULTS

Vascular insufficiency was observed in six cases (7 percent) (venous congestion in five and arterial insufficiency in one). Of these, three flaps were treated conservatively and three were reexplored. The decision of whether to reexplore the flaps or not was made on the basis of the clinical parameters (i.e., color, temperature, and turgor) and their evolution in the first hour (Fig. 3).

Three flaps suffering from venous congestion were not reexplored because they showed a stable, nonprogressive blue discoloration. Because in most of these cases the congestion resolves spontaneously, an attending policy can be considered acceptable, although sometimes partial flap necrosis will occur.

In one of these flaps (patient 66) (Figs. 4 through 6), we had to perform a secondary skin graft, whereas conservative treatment was sufficient in the other two (patients 8 and 73). Among the three flaps that required reexploration, arterial insufficiency occurred in a propeller flap rotated 180 degrees (because of spasm) and was solved by derotating the flap to its original position, delay, and rerotating it over the defect after

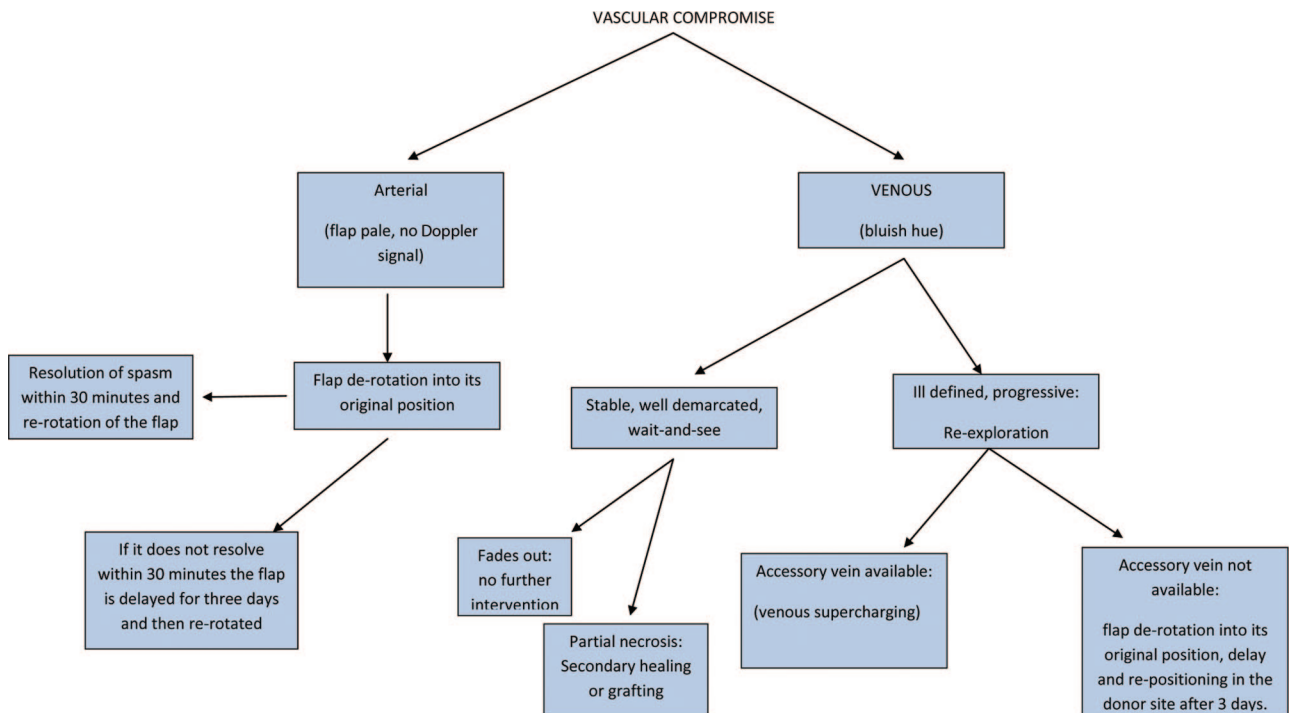


Fig. 3. Our algorithm in cases of vascular compromise. Flap monitoring is performed every second hour during the first 24 hours.

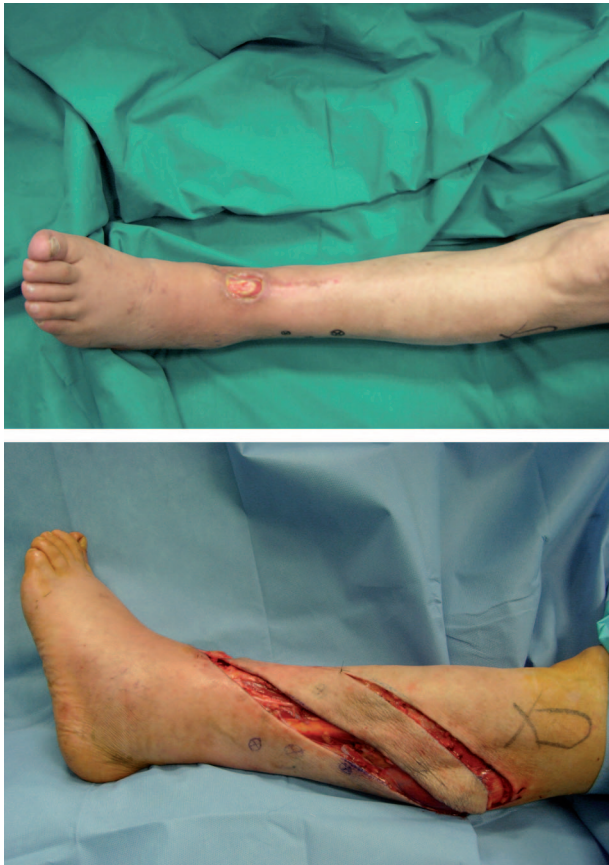

Fig. 4. (Above) A nonhealing ulcer with exposed tibialis anterior tendon in a 72-year-old man after trauma. (Below) A 26 × 5-cm propeller perforator flap is planned based on a single peroneal artery perforator with two venae comitantes.

3 days. The flap eventually survived completely (patient 15).

The two venous congestions occurred in two forearm perforator flaps and were treated with salvage venous supercharging. Although one survived completely (patient 56), the other failed, probably because of a delay in reexploration. This case was the only case of nearly complete (90 percent) flap failure (patient 57). Granulation of the residual defect after débridement of the necrotic skin of the flap allowed resurfacing with a skin graft at day 28 postoperatively. Overall, the vascular complication rate was 7 percent. Partial flap necrosis occurred in four cases (4.7 percent). Complications requiring reexploration occurred in four cases (4.7 percent).

Not surprisingly, all vascular complications were observed with 180-degree rotation propeller flaps and in the first part of the series. An extremely high venous insufficiency rate (40 percent) was noted in the forearm. Two of five cases required reoperation

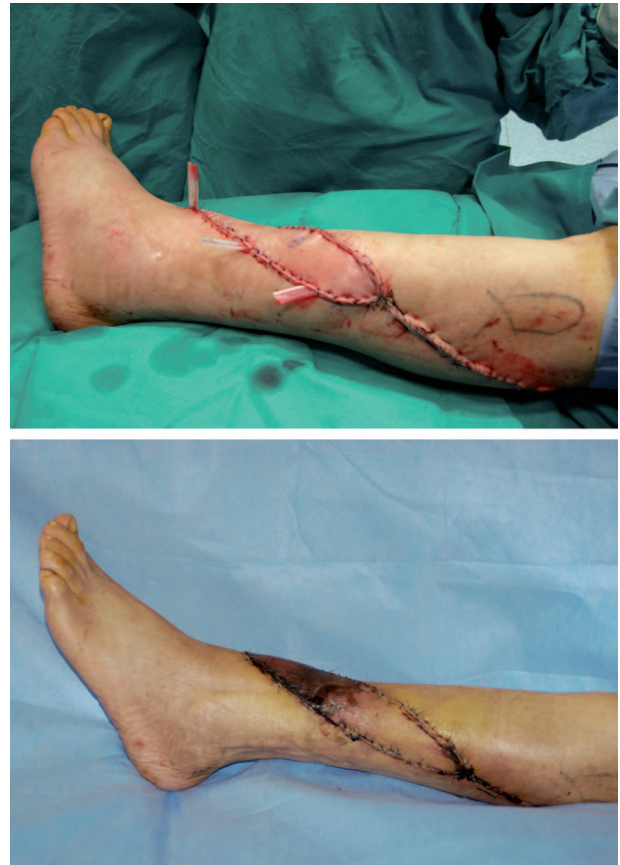

Fig. 5. (Above) After 180-degree rotation, at the end of the operation, the flap appears good. The donor site is closed primarily, allowing for the best result possible. However, the oblique orientation might have contributed to the distal flap's compromise, together with the choice of a peroneal artery perforator. (Below) The eschar on the distal part of the flap on postoperative day 10 is shown. From the beginning, the suffering part of the flap has been nonprogressing and has been left alone while waiting for necrosis to demarcate. No secondary pedicles were available for supercharging. The eschar was removed on postoperative day 14 and, after another 14 days of wound care, a split-thickness skin graft taken from the thigh was used.

and venous supercharging. If the forearm is excluded from the series, the complication rates drop to 6.25 percent (overall complication rate) and 3.75 percent (vascular complications and complications requiring reexploration).

One patient (1.2 percent) with a 90-degree propeller flap had delayed healing of the skin-grafted donor site because of a *Pseudomonas aeruginosa* infection that was managed with culture-guided systemic antibiotic therapy and local wound care. This complication is not strictly related to the freestyle perforator flaps technique and is mentioned for the purpose of completeness.

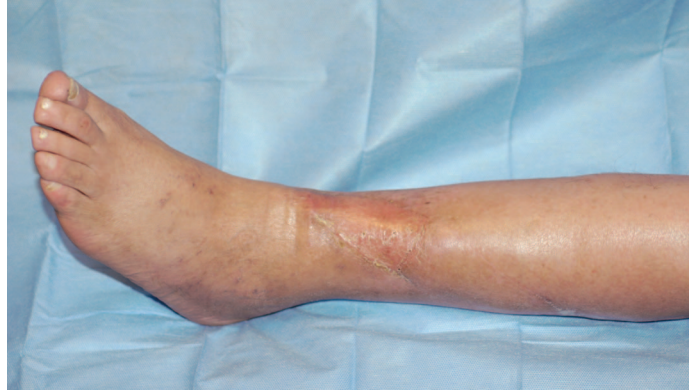


Fig. 6. One-year postoperative view. Because of a good wound bed over the tendon, the skin graft had 100 percent take, allowing achievement of satisfactory coverage and a satisfactory cosmetic result even though some mild color mismatch between the graft and the flap is still visible.

Overall, the complication rate was 8.2 percent, including infection. In 22 cases (25.6 percent), temporary pincushioning of the flap was observed and resolved within 3 months (range, 6 weeks to 3 months) in all cases without any treatment. Satisfactory coverage was eventually achieved in all cases. The cosmetic outcome was worse when partial flap necrosis occurred (three cases) and when partial skin grafting of the donor site was necessary (three cases).

DISCUSSION

Avoidance and Treatment of Complications

In this section, avoiding or eventually dealing with specific complications of freestyle pedicled perforator flap is discussed.

Perforator Is Not Found

Perforators exist in all areas of the body. When no suitable perforator is found, this can be attributable to either inadequate exploratory incision or inadvertent damage to perforators. Accurate preoperative mapping of all of the perforators is mandatory. The exploratory incision must be wide enough to warrant good exposure, but must never interfere with a second-choice flap (the plan B) that should be planned in advance in case a perforator flap cannot be performed. Sometimes, especially in the lower limb, it is not uncommon that a perforator vessel has a quite long suprafascial course after having pierced the deep fascia and before reaching the skin. In these cases, the skin mark of the Doppler signal heard preoperatively may be located over the subcutaneous course of the vessel and not over the exiting point of the perforator from the fascia. Therefore, during dissection, the perforator will be found past the pre-

viously marked point and the search for it should not be abandoned prematurely.

No Arterial Inflow, Spasm

This situation is commonly encountered intraoperatively after pedicle dissection and sometimes postoperatively if the flap is not checked accurately during the operation. It is attributable to spasm of the vessels caused by surgical manipulation. To let the spasm resolve, the flap should be left in place until the circulation has settled (this normally takes approximately 20 minutes) and then transferred (during this period, the pedicle can be rinsed with papaverine or lidocaine). In selected cases, harvesting the flap first and then performing wound débridement or cancer resection might be considered. We are aware that this behavior might be questionable, but it is not very different from simultaneous free flap harvesting by a second team that is routinely performed in most operations. If the resection has been planned accurately, no harm (but rather a safer flap) will be done to the patient. If spasm persists, the flap can be derotated and brought back to its original position,¹¹ left for a few days (3 days in our practice), and then rerotated to cover the defect (Fig. 3). As a preventive measure, flap rotation is always recorded in the surgical notes, as an arrow marked on the skin of the patient, and usually photographed. This routine avoids derotating in the wrong sense with worsening of pedicle torsion, which is especially a risk if a different surgeon is likely to perform the reoperation.

Pure arterial insufficiency is an extremely rare situation and will usually cause necrosis of only one part of larger flaps. Only judicious planning,

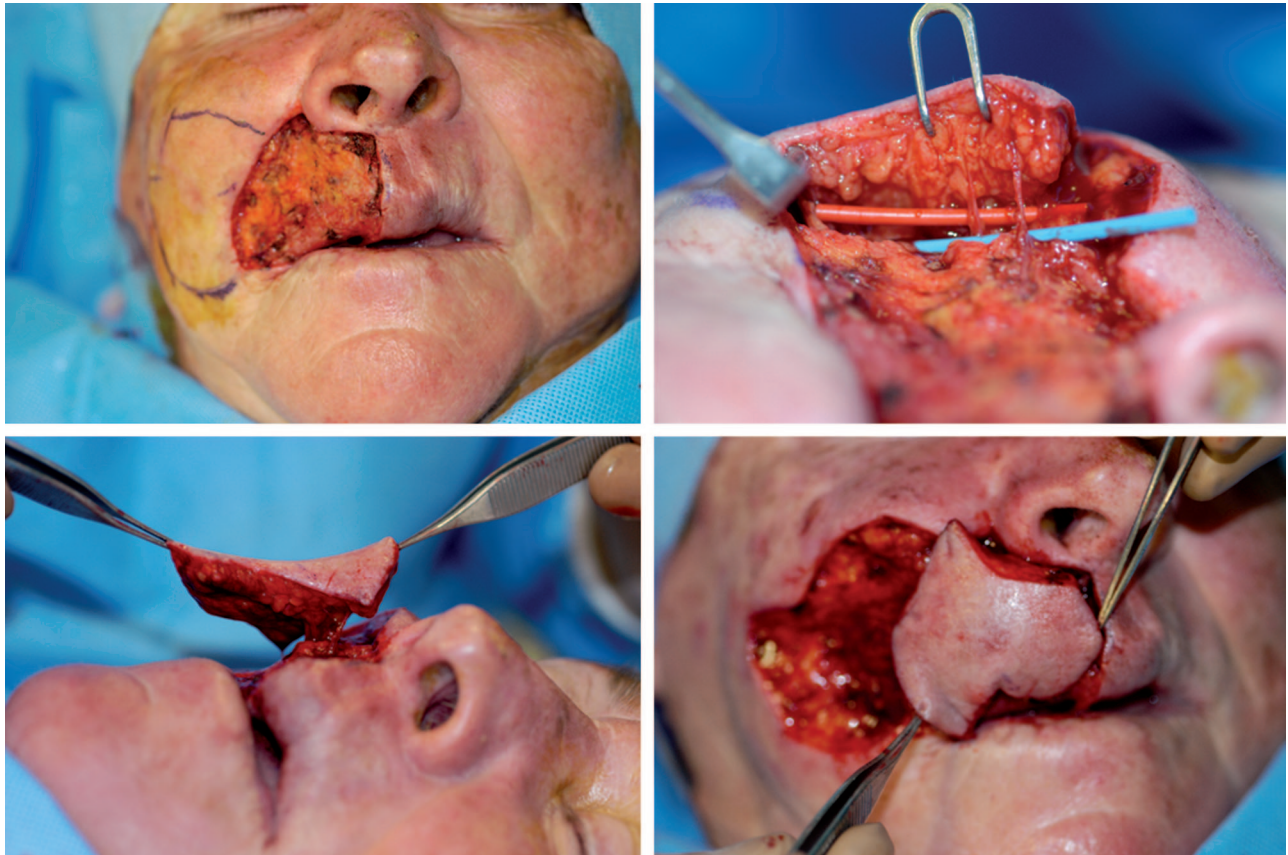


Fig. 7. (Above, left) Upper lip defect after squamous cell carcinoma resection. (Above, right) Through the same wound perforators coming from the facial artery (red loop) and vein (blue loop). Because the vein is not attached to the artery, generous dissection to free the vessels is mandatory to avoid kinking when the flap rotates. The flap is then isolated on the pedicle (below, left) and rotated 90 degrees (below, right).

flap orientation, flap design, and choice of the largest and best pulsating perforator can help prevent it. Correct flap orientation (as described earlier under Surgical Technique and Discussion and by Lecours et al.¹⁰) can also optimize circulation.

Venous Insufficiency

The key to preventing venous insufficiency is to always make sure that there is a good vein in the pedicle (Figs. 7 and 8). A temporary purplish hue is often observed in perforator flaps, either free or pedicled. This should not be interpreted as venous insufficiency but rather as a temporary congestion that fades out with stabilization of flow. This process usually takes a few minutes. True venous insufficiency is diagnosed when it worsens over time (Fig. 3). The smaller the flap, the harder the diagnosis because bruising caused by local anesthetic injection and/or manipulation can mimic venous congestion. Sometimes, venous insufficiency is limited to a small apical part of the flap. These cases are left alone. Most of them will fade

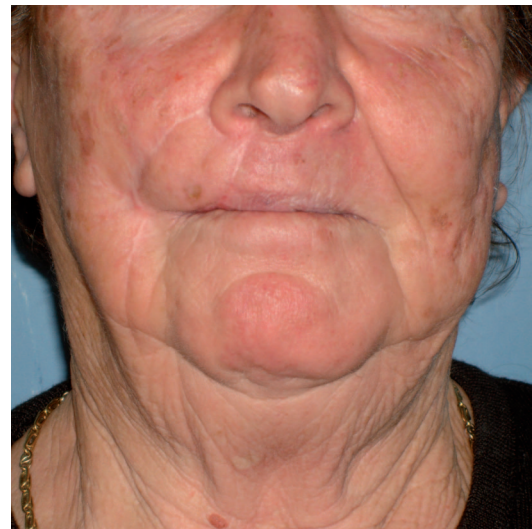

Fig. 8. Same patient as shown in Figure 7, 2 years after the operation.

out (Figs. 9 through 11). If necrosis ensues, an eschar will form and the remaining defect will heal spontaneously. The necrosis is only superficial in these cases and the deep part of the flap will cover the recipient site anyway (Fig. 6), as is sometimes observed with free perforator flaps also. If venous insufficiency is severe, two options remain. The best one is to perform venous supercharging by microsurgically anastomosing a superficial vein of the flap or a vein of a second perforator that is divided to let the flap rotate, to a recipient vein (usually a superficial one). These two alternative pedicles should always be prepared preventively during initial flap dissection. In consideration of the very high venous insufficiency rate (40 percent) in the forearm, where plenty of superficial veins are available as both recipients and donors, it is the authors' advice to routinely perform a supercharged propeller flap¹² (Figs. 12 and 13). Should venous supercharging be impossible to perform, derotation as described above can be a solution when pedicle torsion is the cause of venous insufficiency. A preventive measure to minimize venous insufficiency caused by torsion is to dissect the perforator as long as possible down to the source vessels. There is a geometric explanation to this, namely, that the longer the rotated segment, the better the torsion that will be distributed along it.^{13,14}

This can also be partly the explanation for the high venous insufficiency rate in the fore-

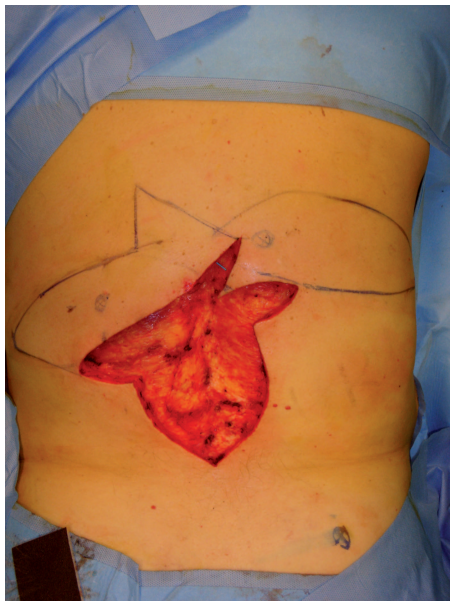


Fig. 9. Wide defect on the dorsum after resection of a multifocal basal cell carcinoma. Two potential flaps are drawn based on preoperative Doppler signals.

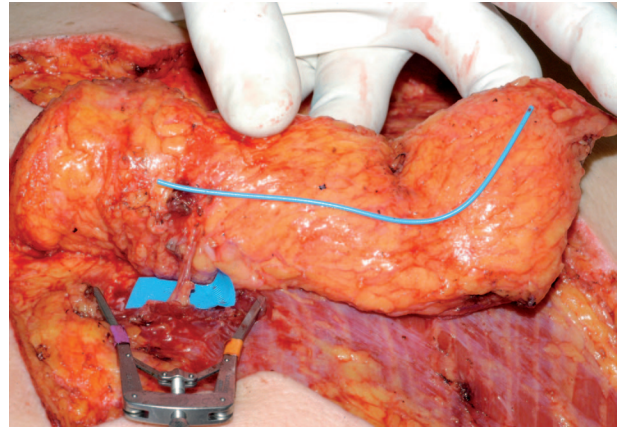


Fig. 10. After a posterior intercostal artery perforator is identified and dissected, the flap is cut circumferentially and oriented along the course of a sensory nerve (*blue loop*). Perforators running with nerves are usually the largest and follow the course of the nerve.

arm, where perforators are quite short and thus torsion is maximized. Another reason can be that in some cases the superficial system is dominant. It is our routine practice also with free radial forearm flaps to use both superficial and deep systems for drainage to prevent problems. Based on this experience, we will perform it with pedicled flaps as well.

Partial Necrosis

It is the authors' experience with perforator flaps, free or pedicled, that partial necrosis is often limited to the skin. In these cases, after eschar removal, there is enough surviving tissue to nourish a skin graft. Partial- or full-thickness skin grafting for larger defects and healing by secondary intention are the solutions in these cases. Excess tension on the pedicle is a technical mistake that can only be avoided by accurate intraoperative planning, complete dissection of the perforator as far as the source vessel, and appropriate tunneling of the flap and its pedicle. If additional length is needed, the source vessel can be included in the pedicle. When the pedicled perforator flap has to reach a very distant defect and the perforator is musculocutaneous, a cuff of muscle might be left on one side of the perforator to protect it from shearing. An excess of tension on the pedicle has to be recognized intraoperatively because it could cause an artery collapse, interrupting the blood flow to the flap. Once tension on the pedicle is recognized and there is no possibility of reducing it, for example, by further dissection of the vascular pedicle (even the source vessel of the perforator can be dissected until its origin when nec-

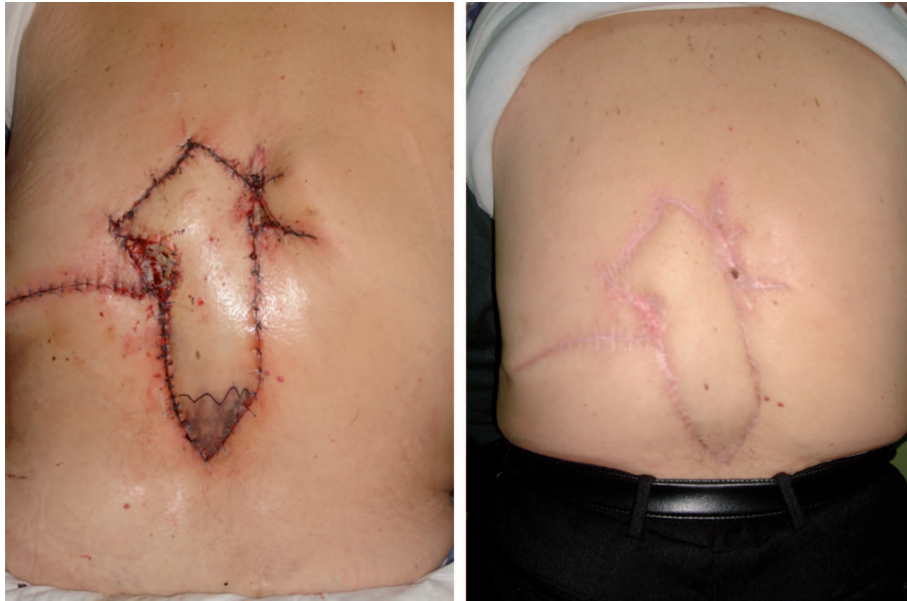

Fig. 11. (Left) On day 2, discoloration appeared at the tip of the flap that was marked and observed. When it is not progressive, nothing is done. A small full-thickness skin graft was used to partially cover the donor site, taken from a dog-ear in the donor flap. (Right) One-year post-operative view. No necrosis at all was observed at the tip of the flap.

essary), appropriate measures such as a second flap to cover the distal part of the defect, so that the arc of rotation required for the perforator flap is reduced and so is tension, must be used.

Safety and Reliability of Perforator Flaps

Similar to other recently introduced surgical techniques, pedicled perforator flaps are also frequently seen with skepticism. Alternative surgical solutions, such as skin grafting, traditional skin pedicled flaps, musculocutaneous flaps, and free flaps are always available, each with particular advantages and disadvantages. It is the surgeon's experience and judgment that guide the choice among them.

Pedicled perforator flaps have the advantage of minimizing morbidity by harvesting only the tissues that are necessary to the reconstruction and of minimizing uncertainties about vascularization seen with classic skin pedicle flaps harvested following the empiric width-to-length ratio.¹⁵ Freestyle flaps have another advantage: they free the surgeon from any restriction in the flap skin island design. As a result, a freestyle flap can be harvested anywhere in the body, provided that a valuable perforator is found and an adequate quantity of tissue is available.

When these two conditions are present, the surgeon can customize the flap design according to his or her own style and preferences, based on

donor- and recipient-site needs. This is the *freestyle* definition borrowed from the sports disciplines that have no rules, whereby the athletes are free to express their own style.

However, freestyle does not mean improvisation. As described above, and elsewhere, appropriate planning is crucial for the success of the procedure and, together with postoperative monitoring, that resembles that of a free flap, they require more effort than other alternative surgical techniques. They can be more rewarding as well.

The propeller flap with a 180-degree rotation was the pedicled perforator flap used most in this series. The reason is that this particular design, although most prone to complications because of extreme pedicle rotation, can achieve rewarding reconstructive results by limiting the donor-site morbidity and matching color and skin texture of the surrounding tissues. These flaps are particularly useful in lower limb and nose^{9,16,17} reconstruction (82 percent of lower limb defects were treated with these flaps in our study).

Propeller flaps with a 90-degree rotation require a skin graft to cover the donor site and give a less appealing outcome in the leg. In these cases, a free flap could be considered as a cosmetically pleasing alternative. In our series, a skin graft was necessary to cover the donor site in only three cases. These data are probably biased by our atti-

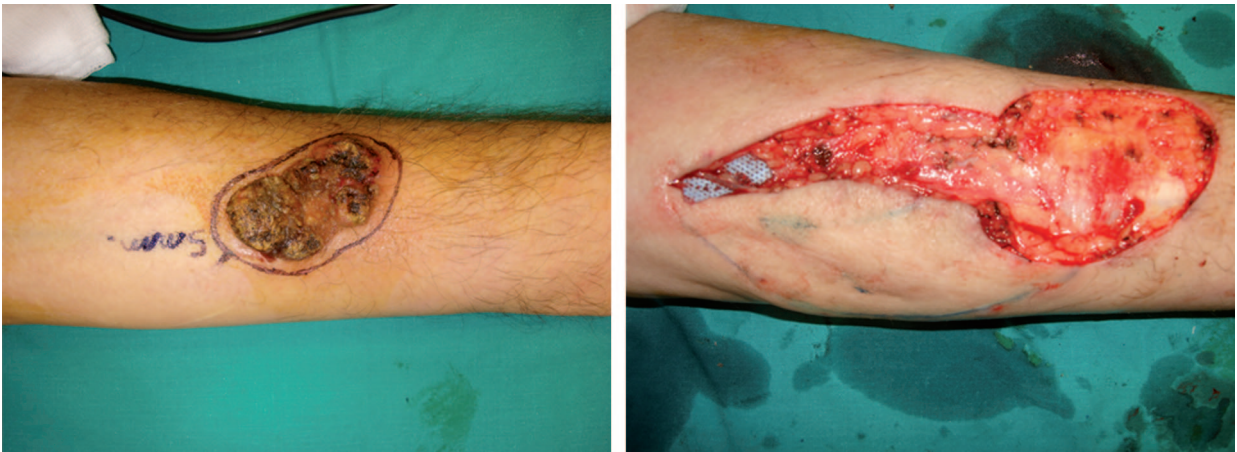

Fig. 12. (Left) Squamous cell carcinoma in the volar surface of the forearm. (Right) A wide exploratory incision allows searching for the perforators. Every superficial vein is identified and preserved.

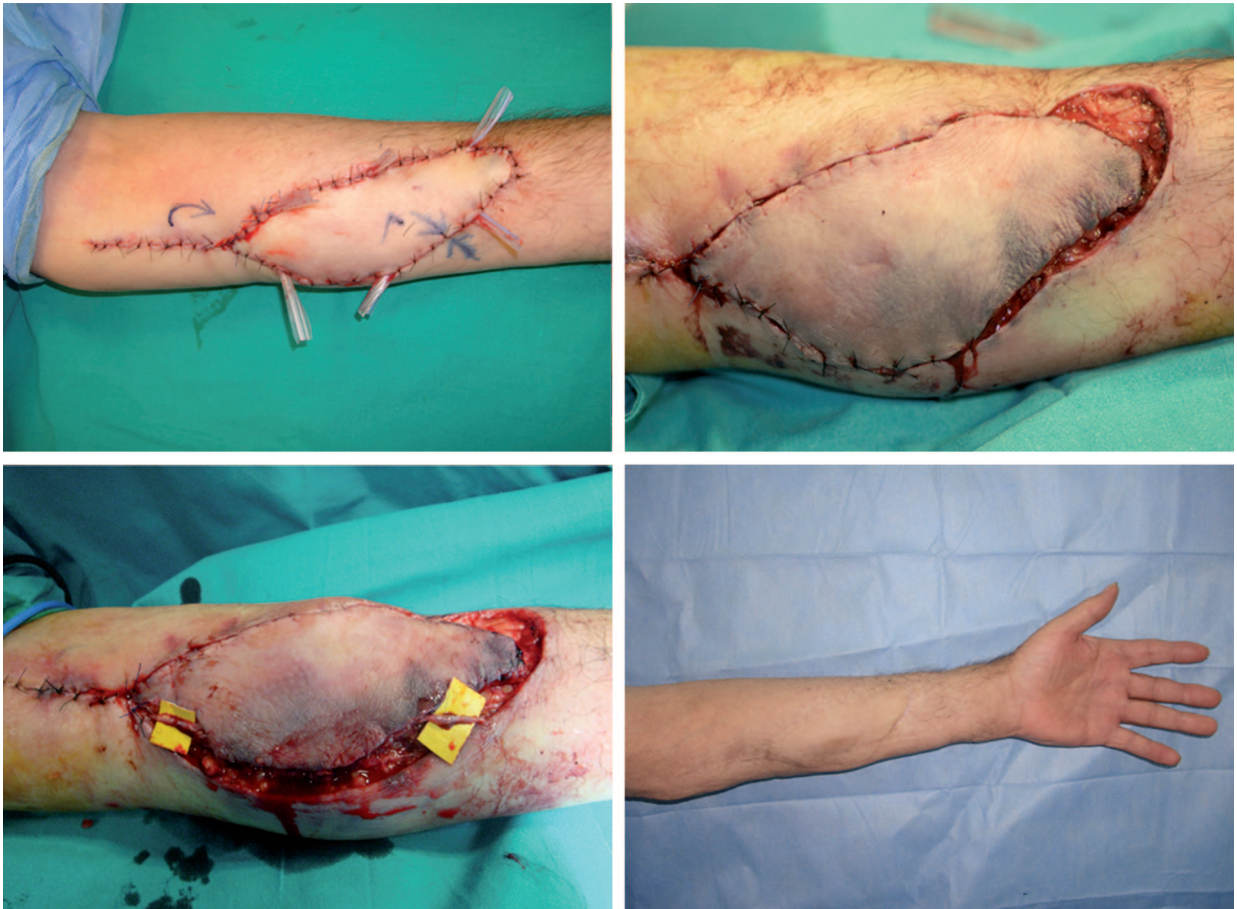


Fig. 13. (Above, left) Eventually, an ulnar artery perforator is chosen and dissected free from any attachment, and the flap is turned 180 degrees. The sense of rotation and the position of the superficial vein are marked on the skin should reexploration be necessary. (Above, right) On postoperative day 1, the flap was reexplored because of venous congestion. (Below, left) Two superficial veins were used for flap supercharging. (Below, right) Final result 2 years after the operation. The flap survived completely and only a linear scar is left at the donor site.

tude toward choosing a free flap when we are able to anticipate that the donor site will not close primarily and the patient's condition allows.

When possible or when local or general conditions suggest, once the perforator vessel is isolated, a skin pedicle can be maintained without islanding this perforator-based flap. Although aesthetically less elegant, this technical variation will improve flap safety by providing additional vascularity to the flap and protecting the perforator from shearing forces.

The overall vascular complication rate in this study was 7 percent, with a partial necrosis rate and a reexploration rate of 4.7 percent each. These rates are acceptable and comparable to or even lower than complication rates reported for other techniques, including even workhorse flaps such as the transverse rectus abdominis musculocutaneous^{18,19} and the distally based sural flap,²⁰ and comparable to the 9.5 percent rate reported by Lecours et al.¹⁰

Some of these complications could have been avoided with appropriate planning and flap harvesting or could have been salvageable with prompt intervention. Pedicled perforator flaps, like free flaps, must be monitored closely. Complications occurred within the first 24 hours. Reoperation was necessary in four cases (4.7 percent). Salvage was successful in three of these (75 percent). These percentages are comparable to those of free flaps that are unanimously considered safe.

If we consider 180-degree propeller flaps alone, and adjust the complication rates accordingly, this will rise to 10.5 percent (six of 57), which is still acceptable, especially if we consider that in most patients propeller flaps are used when the alternative is a more demanding free flap, a two-stage technique, or multiple local flaps.

One last comment is necessary regarding postoperative monitoring. According to our experience, these flaps are considered safe, and vascular complications that require salvage procedures such as venous supercharging or derotation occur within the first 24 hours after the operation. These flaps are used as an alternative to other local flaps that do not require monitoring or to a more demanding free flap. Monitoring will increase the workload required and may discourage surgeons from using them. Based on this series, if one takes care to avoid the spasm and to make a supercharged flap whenever possible (such as in forearm flaps), the need for postoperative monitoring can be reduced dramatically. Waiting for the spasm to settle or anastomosing an extra vein pro-

longs the operative time by approximately half an hour but allows the staff and the patient to have a good first night's sleep.

To the best of our knowledge, this is the first report on complications of freestyle pedicled perforator flaps based on a relatively large series and dealing with almost every body region. Based on this retrospective review, it seems that complication rates are reasonable and that this operation is safe to perform, provided that appropriate planning and technique are used.

We are not able to provide precise guidelines on how large the flap can be. Given the huge individual variability of perforators in both position and size, this is a very difficult task to achieve. Absolute measures are very difficult to provide and probably misleading because it is intuitive that a 20 × 10-cm anterolateral thigh flap in a 1.5-m, 50-kg person is absolutely not the same as a 20 × 10-cm anterolateral thigh flap in a 1.90-m person weighing 140 kg.

Having said that, some useful information about suitable flap sizes in different parts of the body can be deduced from Table 1. The readers will notice that very large flaps are not present in this series, except possibly for some lower limb cases.

Whenever the defect is too large, we would choose a free flap. We all know from experience that very large deep inferior epigastric artery perforator and anterolateral thigh flaps, among others, can be harvested on a single perforator. There is no reason why pedicled perforator flaps must be an exception to this rule if anatomical differences are taken into account, and this is why we consider donor-site closure, rather than concerns on vascularity, the real limitation to the flap's size.

There are some general rules that were provided by Taylor and Palmer²¹ first and then confirmed by Saint-Cyr et al.²² in their studies on the vascular anatomy of the body. Flaps should be based on perforators as close to the midline or a fixed point (i.e., an articulation in the limbs) as possible, oriented along the axis of the main source vessel or the line connecting two perforators, and with their main axis parallel to the axis of growth of the body area (transverse in the trunk and longitudinal in the limbs).

The described ways of overcoming complications may help to reduce their incidence and their effect on flap survival. A learning curve is definitely necessary. We hope that this report on our mistakes and how we solved them will allow others to avoid the same mistakes and achieve higher success rates.

Salvatore D'Arpa, M.D., Ph.D.

Chirurgia Plastica e Ricostruttiva
Dipartimento di Discipline Chirurgiche ed Oncologiche
Università degli Studi di Palermo
Via del Vespro 129
90127 Palermo, Italy
turidarpa@unipa.it

PATIENT CONSENT

The patient consented to the use of the patient image.

REFERENCES

- Pignatti M, Pasqualini M, Governa M, Bruti M, Rigotti G. Propeller flaps for leg reconstruction. *J Plast Reconstr Aesthet Surg*. 2008;61:777–783.
- Moscatiello F, Masià J, Carrera A, Clavero JA, Larrañaga JR, Pons G. The “propeller” distal anteromedial thigh perforator flap: Anatomic study and clinical applications. *J Plast Reconstr Aesthet Surg*. 2007;60:1323–1330.
- Hamdi M, Spano A, Van Landuyt K, D’Herde K, Blondeel P, Monstrey S. The lateral intercostal artery perforators: Anatomical study and clinical application in breast surgery. *Plast Reconstr Surg*. 2008;121:389–396.
- Hamdi M, Van Landuyt K, de Frene B, Roche N, Blondeel P, Monstrey S. The versatility of the inter-costal artery perforator (ICAP) flaps. *J Plast Reconstr Aesthet Surg*. 2006;59:644–652.
- Hamdi M, Van Landuyt K, Hijjawi JB, Roche N, Blondeel P, Monstrey S. Surgical technique in pedicled thoracodorsal artery perforator flaps: A clinical experience with 99 patients. *Plast Reconstr Surg*. 2008;121:1632–1641.
- Wei FC, Mardini S. Free-style free flaps. *Plast Reconstr Surg*. 2004;114:910–916.
- Asko Seljavaara S. In: *Abstracts of the Seventh Congress of the International Society of Reconstructive Microsurgery*; June 19–30, 1983; New York, NY.
- Yildirim S, Taylan G, Aköz T. Freestyle perforator-based V-Y advancement flap for reconstruction of soft tissue defects at various anatomic regions. *Ann Plast Surg*. 2007;58:501–506.
- D’Arpa S, Cordova A, Pirrello R, Moschella F. Free style facial artery perforator flap for one stage reconstruction of the nasal ala. *J Plast Reconstr Aesthet Surg*. 2009;62:36–42.
- Lecours C, Saint-Cyr M, Wong C, et al. Freestyle pedicle perforator flaps: Clinical results and vascular anatomy. *Plast Reconstr Surg*. 2010;126:1589–1603.
- Pignatti M, Ogawa R, Hallock GG, et al. The “Tokyo” consensus on propeller flaps. *Plast Reconstr Surg*. 2011;127:716–722.
- Pignatti M, D’Arpa S, Cubison TC. Novel fasciocutaneous flaps for reconstruction of complicated lower extremity wounds. *Tech Orthop*. 2009;24:88–95.
- Selvaggi G, Anicic S, Formaggia L. Mathematical explanation of the buckling of the vessels after twisting of the anastomosis. *Microsurgery* 2006;26:524–528.
- Demir A, Acar M, Yldz L, Karacalar A. The effect of twisting on perforator flap viability: An experimental study in rats. *Ann Plast Surg*. 2006;56:186–189.
- Milton SH. Pedicled skin flaps: The fallacy of the length: width ratio. *Br J Surg*. 1970;57:502–508.
- Cordova A, D’Arpa S, Tripoli M, Napoli P, Di Lorenzo S. The supra-trochlear artery perforator propeller (STAPP) flap: A one stage method for nose reconstruction. Paper presented at: 21st Annual Meeting of the European Association of Plastic Surgeons; May 27–29, 2010; Manchester, United Kingdom.
- Teo TC. Perforator local flaps in lower limb reconstruction. *Cir Plast Iberolatinoam*. 2006;32:15–16.
- Kim EK, Eom JS, Ahn SH, Son BH, Lee TJ. Evolution of the pedicled TRAM flap: A prospective study of 500 consecutive cases by a single surgeon in Asian patients. *Ann Plast Surg*. 2009;63:378–382.
- Aoki S, Tanuma K, Iwakiri I, et al. Clinical and vascular anatomical study of distally based sural flap. *Ann Plast Surg*. 2008;61:73–78.
- Chun YS, Sinha I, Turko A, Lipsitz S, Pribaz JJ. Outcomes and patient satisfaction following breast reconstruction with bilateral pedicled TRAM flaps in 105 consecutive patients. *Plast Reconstr Surg*. 2010;125:1–9.
- Taylor GI, Palmer JH. The vascular territories (angiosomes) of the body: Experimental study and clinical applications. *Br J Plast Surg*. 1987;40:113–141.
- Saint-Cyr M, Wong C, Schaverien M, Mojallal A, Rohrich RJ. The perforasome theory: Vascular anatomy and clinical implications. *Plast Reconstr Surg*. 2009;124:1529–1544.