

Bilateral Bennett's fracture: A case report

Salvatore Cassaro, Salvatore Ratano^{*}, Domenico Claudio Cobisi, Gabriele Salomone, Massimo Ferruzza, Lawrence Camarda

Department of Orthopaedics Surgery (DICHIRINOS), University of Palermo, Palermo, Italy

ARTICLE INFO

Keywords:

Hand fracture
Bilateral fracture
Bennet fracture
Surgical treatment
Percutaneous pinning

SUMMARY

Bennet's fracture represents one of the most common injuries of the hand district, involving the base of the thumb, and it affects children and elderly patients the most. The fracture is caused by direct axial trauma to a partially flexed first metacarpal and it is always intra-articular: the fracture line separates the palmar ulnar aspect of the first metacarpal base from the remaining first metacarpal. The fracture pattern is such that the first metacarpal shaft moves dorsally, proximally, and radially due to the pull of the abductor pollicis longus, extensor pollicis longus, extensor pollicis brevis, and the adductor pollicis brevis, which remain attached to the fracture fragment. The surgical treatment consists of closed reduction with percutaneous pinning or open reduction with either pins or interfragmentary screws. The decision to treat these fractures with either open reduction or closed reduction is still a matter of debate. To the best of our knowledge, there are no cases of bilateral Bennett's fracture reported in literature. The aim of this paper is to present a rare case of bilateral Bennett's fracture, the decision of two different treatments, and the good clinical outcomes.

Case presentation

A 40-year-old bilateral-hand male presented to the emergency department after a motor vehicle accident occurred on the same day. He complained of pain and functional limitation of both thumbs with edema and hematoma at the base of the fingers. Clinically, the patient presented an instability of the right trapeziometacarpal joint. There were no skin injuries, and the neurovascular status was normal. Standard anteroposterior and oblique radiographs of the hand revealed a bilateral Bennett fracture with a dislocated fragment on the right hand (Fig. 1). On the left side, conservative treatment was considered by placing a wrist cast including the thumb base (Fig. 2a). On the right side, surgical treatment was performed two days after the trauma. Under regional anesthesia, the fracture was reduced under fluoroscopy by longitudinal traction, pronation, and direct pressure over the base of the first metacarpal bone. Two 1.2 mm K-wires were placed under direct fluoroscopy evaluation and a wrist cast was placed including the base of the thumb (Fig. 2b). Post-operative AP and oblique x-ray showed a good fracture reduction on both sides. On the left side, the cast was removed at 4 weeks allowing immediate mobilization of the thumb. On the right hand, the K-wires were removed at five weeks, starting active and passive movement of the right thumb. The patient resumed all daily activities and sports without any functional limitation after twelve weeks postoperatively (Figs. 3a–3b).

^{*} Corresponding author at: Department of Orthopaedic Surgery (DICHIRINOS), University of Palermo, Via del Vespro, 127, 90100 Palermo, Italy. E-mail addresses: sratano.md@gmail.com (S. Ratano), lawrence.camarda@unipa.it (L. Camarda).

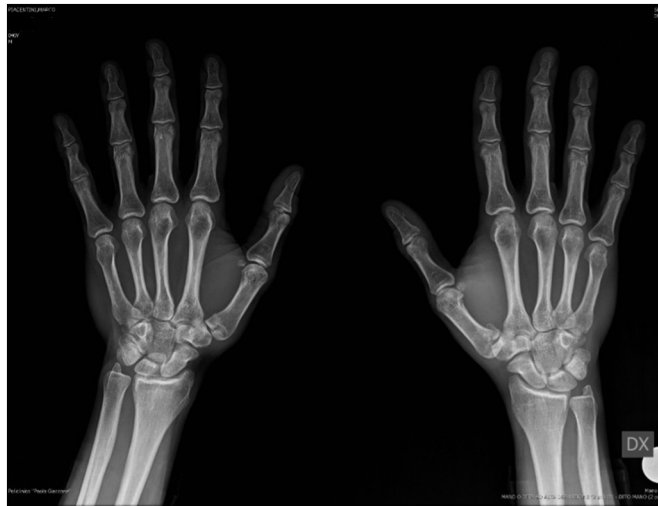

Fig. 1. Initial radiographic assessment of patient with bilateral Bennett's fracture.

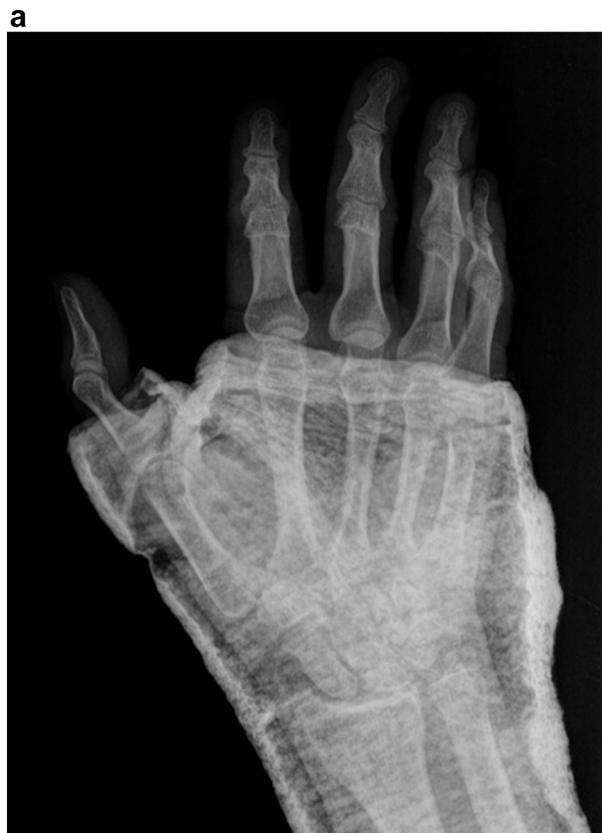

Fig. 2a. Radiographic control after immobilization of the right hand fracture with wrist cast.

Discussion

A Bennett fracture is an injury on the base of the first metacarpal with the avulsion of the attachment of the thick and strong volar oblique ligament and, for this, it is also defined partially articular. This is the substantial difference with the fracture of Rolando: a comminuted articular fracture of the base of the thumb metacarpal [4]. The diagnosis is classically carried out with a standard RX in double orthogonal projections of the first ray of the hand [1–3]. The projection of Robert and that of Bett, help to evaluate the articular

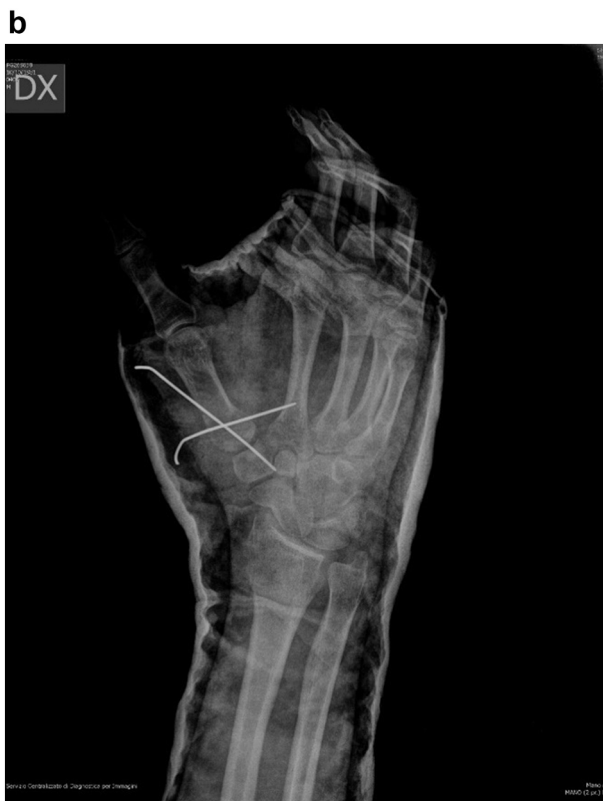

Fig. 2b. Post-operative x-ray.




Fig. 3a. Follow-up at twelve weeks: functional tests on both hands.

congruence and the degree of displacement of the fragments. In his article, Bennet described a treatment of the fracture with closed reduction and splinting. This remained the preferred method of treatment until the 1970s with good clinical results [5]. In case of unstable fracture, the surgical treatment consists of osteosynthesis with percutaneous pinning, or open reduction and osteosynthesis with interfragmentary screws. All methods of fixation have been shown to be effective in case reviews and series [3]. Regarding the quality of articular reduction, some authors have found no correlation with radiographic or subjective outcomes [6]. With a biomechanical study, Cullen et al. have demonstrated that 2 mm of persistent articular surface step-off does not alter the contact pressures at the location of the step off, but they concluded that bony apposition of the fragments within 2 mm and the correction of



Fig. 3b. Follow-up at twelve weeks: functional tests on both hands.

any joint subluxation will be tolerated without increasing the risk of post-traumatic arthritis [7]. Despite this, other clinical studies have recommended the anatomic reduction [5]. The peculiarity of this case lies in the fact that it is a bilateral fracture of Bennett in the patient, this was caused by a motorcycle accident with both hands on the handlebar. Given the different outcome of closed reduction on both hands, the two fractures were classified differently and, therefore, treated in two different ways: one through the osteosynthesis with two wires of Kirschner, while the other fracture was treated with closed reduction and splinting. The case assessment and the choice of treatments was favorable with very good clinical result and the patient very satisfied at follow-up of 3 months.

Conclusion

The combination of a bilateral Bennett's fracture is rare observation and requires an accurate clinical and radiographic assessment to decide on the most appropriate treatment. In the present case, the combination of two different treatments has led to a good clinical results.

Funding

None.

Other financial and personal relationships

None.

Declaration of competing interest

None.

References

- [1] J.O. Edmunds, Traumatic dislocations and instability of the trapeziometacarpal joint of the thumb, *Hand Clin.* 22 (3) (2006 Aug) 365–392.
- [2] - K Kjaer-Petersen O Langhoff K Andersen . Bennett's fracture. *J Hand Sur.*
- [3] K.R. Carter, S.V. Nallamothu, Bennett Fracture, StatPearls [Internet], StatPearls Publishing, Treasure Island (FL), 2022 Apr 30, 2022 Jan–. PMID: 29763211.
- [4] P.A. Liverneaux, S. Ichihara, S. Hendriks, S. Facca, F. Bodin, Fractures and dislocation of the base of the thumb metacarpal, *J. Hand Surg. Eur.* 40 (1) (2015 Jan) 42–50, <https://doi.org/10.1177/1753193414554357>. Epub 2014 Oct 13 PMID: 25311936.
- [5] C.J. Oosterbos, H.H. de Boer, Nonoperative treatment of Bennett's fracture: a 13-year follow-up, *J. Orthop. Trauma* 9 (1) (1995 Feb) 23–27.
- [6] E. Demir, F. Unglaub, M. Wittemann, G. Germann, M. Sauerbier, Surgically treated intraarticular fractures of the trapeziometacarpal joint – a clinical and radiological outcome study, *Unfallchirurg* 109 (1) (2006 Jan) 13–21.
- [7] J.P. Cullen, M.A. Parentis, V.M. Chinchilli, V.D. Pellegrini, Simulated Bennett fracture treated with closed reduction and percutaneous pinning. A biomechanical analysis of residual incongruity of the joint, *J. Bone Joint Surg. Am.* 79 (3) (1997 Mar) 413–420.