

## Aulogous fibrin sealant (Vivostat®) in the neurosurgical practice: Part II: Vertebro-spinal procedures

Francesca Graziano, Rosario Maugeri, Luigi Basile, Favia Meccio, Domenico Gerardo Iacopino

Department of Experimental Biomedicine and Clinical Neuroscience, Neurosurgical Unit, University Hospital, Paolo Giaccone, Palermo, Italy

E-mail: Francesca Graziano - [franeurosurgery@libero.it](mailto:franeurosurgery@libero.it); Rosario Maugeri - [rosario.maugeri1977@gmail.com](mailto:rosario.maugeri1977@gmail.com); Luigi Basile - [lbasile64@libero.it](mailto:lbasile64@libero.it); Favia Meccio - [flavia.meccio@virgilio.it](mailto:flavia.meccio@virgilio.it); \*Domenico Gerardo Iacopino - [gerardo.iacopino@unipa.it](mailto:gerardo.iacopino@unipa.it)

\*Corresponding author

Received: 25 July 15 Accepted: 17 October 15 Published: 25 January 16

### Abstract

**Background:** Epidural hematomas, cerebrospinal fluid fistula, and spinal infections are challenging postoperative complications following vertebro-spinal procedures. We report our preliminary results using autologous fibrin sealant as both fibrin glue and a hemostatic during these operations.

**Methods:** Prospectively, between January 2013 and March 2015, 68 patients received an autologous fibrin sealant prepared with the Vivostat® system applied epidurally to provide hemostasis and to seal the dura. The surgical technique, time to bleeding control, and associated complications were recorded.

**Results:** Spinal procedures were performed in 68 patients utilizing autologous fibrin glue/Vivostat® to provide rapid hemostasis and/or to seal the dura. Only 2 patients developed postoperative dural fistulas while none exhibited hemorrhages, allergic reactions, systemic complications, or infections.

**Conclusions:** In this preliminary study, the application of autologous fibrin sealant with Vivostat® resulted in rapid hemostasis and/or acted as an effective dural sealant. Although this product appears to be safe and effective, further investigations are warranted.

**Key Words:** Autologous fibrin glue, cerebrospinal fluid fistula, dural repair, dural sealant, hemorrhage, hemostasis

#### Access this article online

**Website:**

[www.surgicalneurologyint.com](http://www.surgicalneurologyint.com)

**DOI:**

10.4103/2152-7806.174894

**Quick Response Code:**



### INTRODUCTION

Cerebrospinal fluid (CSF) fistulas and postoperative hematomas constitute two of the major complications of spinal surgery.<sup>[2,13,21]</sup> Fibrin sealants supplement dural closure and promote hemostasis.<sup>[5,16,18]</sup> This study reports the preliminary results of utilizing a new fibrin sealant Vivostat® (Vivostat A/S, Alleroed, Denmark) to achieve both hemostasis and facilitate dural repair in spinal surgery.

### MATERIALS AND METHODS

From January 2013 to March 2015, 68 patients undergoing spinal surgery received autologous fibrin sealant prepared

with the Vivostat® system and applied epidurally, over the resection bed.

### Patients population

Upon approval of the local Institutional Review Board, between January 2013 and March 2015 we performed 68 neurosurgical spinal procedures utilizing autologous

This is an open access article distributed under the terms of the Creative Commons Attribution-NonCommercial-ShareAlike 3.0 License, which allows others to remix, tweak, and build upon the work non-commercially, as long as the author is credited and the new creations are licensed under the identical terms.

**For reprints contact:** [reprints@medknow.com](mailto:reprints@medknow.com)

**How to cite this article:** Graziano F, Maugeri R, Basile L, Meccio F, Iacopino DG.

Aulogous fibrin sealant (Vivostat®) in the neurosurgical practice: Part II:Vertebro-spinal procedures. *Surg Neurol Int* 2016;7:S77-82.

[http://surgicalneurologyint.com/Aulogous-fibrin-sealant-\(Vivostat®\)-in-the-neurosurgical-practice:-Part-II:-Vertebro-spinal-procedures/](http://surgicalneurologyint.com/Aulogous-fibrin-sealant-(Vivostat®)-in-the-neurosurgical-practice:-Part-II:-Vertebro-spinal-procedures/)

fibrin sealant/Vivostat® to achieve hemostasis and/or to seal the dura.

In 47% of cases (32 cases), the autologous fibrin glue was used only as an hemostatic agent; in 34% of cases it was used both as an hemostatic and dural sealant agent for strengthening atretic dura (without frank CSF fistula); in 19% of cases the autologous fibrin glue was used to achieve both hemostasis and CSF fistula repair; [Table 1]. In the majority of cases, autologous fibrin glue addressed degenerative disease (43%) or tumor (oncological cases: 32%) [Table 1, Figure 1]. For Vivostat preparation and administration see Graziano *et al.* and Giugno *et al.*<sup>[6-8]</sup> All patients were monitored postoperatively for an average of 18 months.

## RESULTS

### Technical and economic considerations

This system was effective in all three circumstances; as a hemostatic alone, as a hemostatic and to strengthen atretic dura, and for hemostasis and dural repair. The Notably, Vivostat® formed an extremely thin white coat and did not compress the neural structures; additionally, it was physiologically eliminated within 24–36 h [Figure 2]. Only in 2 cases postoperative CSF fistulas were encountered; 1 was successfully treated conservatively while the other required additional dural repair [Table 1]. Notably, no local medullar toxicity, allergic reactions, infection, or systemic complications

**Table 1: Patient data including the vertebro-spinal procedures performed**

Case number	Sex	Age	Pathology	Treatment	Dural opening	Vivostat® indication	Postoperative complications
1	Male	50	Cervical disc herniation	Microdiscectomy, arthroplasty	No	Hemostasis	None
2	Male	67	Dorsal spondylodiscitis	Decompression, arthrodesis	No	Hemostasis, dural sealing	None
3	Female	66	Dorsal meningioma	Laminectomy and microsurgical asportation	Yes (intentional)	Dural sealing	None
4	Male	75	Dorsal pathologic fracture	Arthrodesis	No	Hemostasis, dural sealing	None
5	Female	80	Lumbar canal stenosis	Decompression, arthrodesis	Yes (accidental)	CSF fistula repair	None
6	Female	60	Cervical myelopathy	Decompression, arthrodesis	Yes (accidental)	CSF fistula repair	None
7	Female	79	Cauda equina neurinoma	Decompression, microsurgical asportation	Yes (intentional - duroplasty)	Dural sealing	None
8	Female	76	Cervical myelopathy	Decompression, arthrodesis	No	Hemostasis	None
9	Female	69	Postoperative CSF fistula (lumbar canal stenosis)	CSF repair, duroplasty	Yes (intentional)	CSF fistula repair	None
10	Female	77	Lumbar pathological fracture	Decompression, arthrodesis	No	Hemostasis	None
11	Male	57	Dorsal vertebral metastasis	Decompression, arthrodesis	No	Hemostasis	None
12	Female	53	Cervical extra-assial neoplasm	Decompression, microsurgical asportation, arthrodesis	No	Hemostasis	None
13	Male	54	Lumbar spondylolisthesis	Decompression, arthrodesis	Yes (accidental)	CSF fistula repair	Postoperative CSF fistula; conservative treatment
14	Male	51	Lumbar canal stenosis	Arthrodesis system revision	Yes (accidental)	CSF fistula repair	None
15	Male	52	Dorsal neoplasm	Decompression, microsurgical asportation, arthrodesis	No	Hemostasis	None
16	Male	55	Dorsal extra-assial neoplasm	Decompression, microsurgical asportation, arthrodesis	Yes (intentional - duroplasty)	Dural sealing	None
17	Male	43	Lumbar CSF fistula	CSF fistula repair	Yes (intentional - duroplasty)	CSF fistula repair	Postoperative CSF fistula; reintervention with other sealants
18	Female	72	Dorsal extra-assial neoplasm	Decompression, microsurgical asportation	No	Hemostasis	None
19	Female	76	Dorsal epidural haematoma	Decompression, evacuation	Yes (accidental)	Hemostasis CSF fistula repair	None
20	Female	53	Dorsal vertebral metastasis	Decompression, arthrodesis	No	Hemostasis, dural sealing	None
21	Male	74	Lumbar canal stenosis	Decompression, microdiscectomy, arthrodesis	Yes (accidental)	Hemostasis CSF fistula repair	None

Contd...

**Table 1: Contd...**

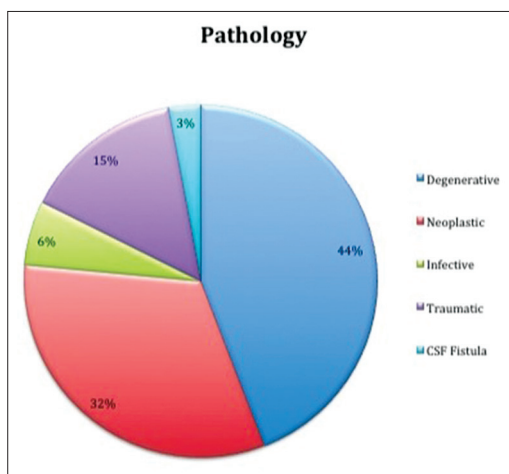
Case number	Sex	Age	Pathology	Treatment	Dural opening	Vivostat® indication	Postoperative complications
22	Male	68	Dorsal vertebral metastasis	Decompression, arthrodesis	No	Hemostasis	None
23	Male	74	Lumbar pathologic fracture	Decompression, arthrodesis	No	Hemostasis	None
24	Male	65	Cervical canal stenosis	Vertebral corpectomy	Yes (accidental)	Hemostasis, dural sealing	None
25	Male	55	Recidivant lumbar disc herniation	Decompression, microdiscectomy, arthrodesis	No	Hemostasis	None
26	Female	66	Lumbar spondylolisthesis	Decompression, arthrodesis	No	Hemostasis	None
27	Female	40	Dorsal vertebral metastasis	Decompression, corpectomy	No	Hemostasis	None
28	Male	39	Posttraumatic lumbar fracture	Decompression, arthrodesis	No	Hemostasis	None
29	Male	50	Recidivant lumbar disc herniation	Microsurgical discectomy, arthrodesis	No	Hemostasis	None
30	Male	50	Lumbar disc herniation	Microsurgical discectomy, decompression, arthrodesis	No	Hemostasis	None
31	Male	77	Lumbar canal stenosis and spondylolisthesis	Decompression, arthrodesis	No	Hemostasis, dural strengthening	None
32	Male	55	Dorsal vertebral metastasis	Decompression, arthrodesis	No	Hemostasis	None
33	Male	61	Posttraumatic lumbar vertebral fracture	Decompression, arthrodesis	Yes (accidental)	CSF fistula repair	None
34	Male	61	Posttraumatic lumbar vertebral fracture	Decompression, arthrodesis	Yes (accidental)	CSF fistula repair	None
35	Male	66	Lumbar canal stenosis, recidivant lumbar disc herniation	Microdiscectomy, decompression, arthrodesis	Yes (accidental)	Hemostasis CSF fistula repair	None
36	Male	67	Recidivant lumbar disc herniation	Microdiscectomy, decompression, arthrodesis	No	Hemostasis	None
37	Male	79	Cicatrizial adhesions in previous lumbar stenosis	Surgical decompression and adhesions resolution	No	Hemostasis	None
38	Female	57	Dorsal neurinoma	Decompression, microsurgical asportation, arthrodesis	Yes (intentional)	Hemostasis, dural sealing	None
39	Male	56	Lumbar canal stenosis	Decompression, arthrodesis	Yes (accidental)	Hemostasis, dural sealing	None
40	Female	59	Dorsal vertebral burst fracture	Laminectomy and arthrodesis	No	Hemostasis	None
41	Female	68	Lumbar canal stenosis	Decompression, arthrodesis	Yes (accidental)	Hemostasis, dural sealing, CSF fistula repair	None
42	Male	75	Epidural dorsal abscess	Laminectomy, abscess drainage	No	Hemostasis	None
43	Male	77	Cervical canal stenosis	Decompression, arthrodesis	No	Hemostasis	None
44	Male	55	Lumbar canal stenosis	Decompression, arthrodesis	No	Hemostasis	None
45	Female	57	Lumbar extra-axial neoplasm	Decompression, microsurgical asportation	Yes (intentional - duroplasty)	Hemostasis, dural sealing	None
46	Male	51	Cauda equina lipoma	Decompression, microsurgical asportation	Yes (intentional - duroplasty)	Hemostasis, dural sealing	None
47	Male	66	Lumbar canal stenosis	Decompression, arthrodesis	No	Hemostasis, dural strengthening	None
48	Female	56	Intramedullar dorsal metastasis	Decompression, microsurgical asportation	Yes (intentional - duroplasty)	Hemostasis, dural sealing	None
49	Female	87	Cervical tarumatic vertebral fracture	Arthrodesis	No	Hemostasis	None
50	Female	84	Mielopathy (cervical trauma)	Discectomy, corpectomy, arthrodesis	Yes (accidental)	Hemostasis CSF fistula repair	None
51	Male	67	Dorsal traumatic vertebral fracture	Decompression, arthrodesis	No	Hemostasis, dural strengthening	None

Contd...

**Table 1: Contd...**

Case number	Sex	Age	Pathology	Treatment	Dural opening	Vivostat® indication	Postoperative complications
52	Female	65	Lumbar tarumatic vertebral fracture	Arthrodesis	No	Hemostasis	None
53	Male	60	Lumbar pathological fracture	Decompression, thermo-ablation, arthrodesis	No	Hemostasis	None
54	Male	71	Lumbar vertebral micro-instability	Decompression, arthrodesis	No	Hemostasis	None
55	Female	61	Lumbar canal stenosis, lumbar disc herniation	Decompression, microdiscectomy, arthrodesis	No	Hemostasis, dural strengthening	None
56	Female	61	Lumbar canal stenosis, lumbar disc herniation	Decompression, microdiscectomy, arthrodesis	No	Hemostasis, dural strengthening	None
57	Male	41	Cicatrizial adhesions and recidivant lumbar disc herniation	Decompression, adhesions resolution, microdiscectomy, arthrodesis	No	Hemostasis	None
58	Male	53	Intra-extradural lumbar vertebral metastasis	Decompression, microsurgical asportation, thermo-ablation, arthrodesis	Yes (intentional)	Hemostasis, dural sealing	None
59	Female	54	Lumbar disc herniation, lumbar canal stenosis	Discectomy, arthrodesis	No	Hemostasis	None
60	Female	60	Cervical burst fracture	Corpectomy, arthrodesis	Yes (accidental)	Hemostasis, dural sealing	None
61	Male	54	Dorsal meningioma	Decompression, microsurgical asportation	Yes (intentional - dural patch)	Dural sealing	None
62	Male	67	Lumbar canal stenosis	Decompression, arthrodesis	No	Hemostasis, dural strengthening	None
63	Female	48	Lumbar spondylolisthesis	Arthrodesis	No	Hemostasis	None
64	Male	72	Lumbar canal stenosis and spondylolisthesis	Decompression and arthrodesis	No	Hemostasis, dural strengthening	None
65	Male	84	Cervical myelopathy and vertebral listhesis	Listhesis reduction and cervical arthrodesis	No	Hemostasis	None
66	Male	57	Dorsal vertebral metastasis	Decompression, arthrodesis	Yes (intentional)	Hemostasis, dural sealing	None
67	Female	54	Dorsal vertebral abscess	Decompression, biopsy	No	Hemostasis	None
68	Male	52	Lumbar spondylodiscitis	Decompression, microdiscectomy, arthrodesis	No	Hemostasis	None

CSF: Cerebrospinal fluid fistula



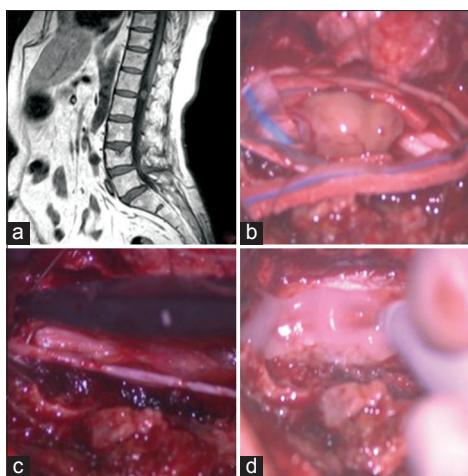
**Figure 1: Graph showing the percentage of the pathologies included in the study**

occurred. The cost per kit needed (e.g., automated preparation of 6.5 ml of fibrin glue) is around 700 USD. Each procedure typically requires only kit; only 5–10% of cases may require two kits.

## DISCUSSION

### Application for durotomies and hemostasis

In spinal surgery, the major intraoperative complications are typically due to accidental durotomies or postoperative hematomas. Cammisa *et al.* found 66 (3.1%) durotomies occurring during 2144 spinal operations; they were immediately treated with dural suturing and fibrin glue.<sup>[4]</sup> During minimally invasive spine surgery, the durotomy incidence has been estimated to be 9%, 4% among 563 patients in the case series of Ruban and O’Toole.<sup>[17]</sup>



**Figure 2: Cauda equina neurinoma. (a) Preoperative Magnetic resonance (MR), T1-weighted sagittal view: An hyperintense homogeneous enhancing circular lesion is visible posterior to the disc space L1-L2. (b) Intraoperative picture of the intradural lesion. (c) After the lesion removal, the dura mater is closed in watertight fashion with single stitches. (d) The autologous fibrin glue is applied on the reconstructed dural layer in order to achieve a satisfactory dural sealing**

### Do dural sealants inhibit fusion

Some are concerned whether these sealants on the vertebral fusion rate.<sup>[5]</sup> Turgut *et al.* assessed the impact of Tisseel on anterior cervical interbody allograft fusion at the C5–C6 level in cats (12 received Tisseel, 12 did not); it was not suitable for “fixation of bone fragments” for anterior cervical discectomy and fusion in this cat model.<sup>[22]</sup> Landi *et al.* determined the efficacy of utilizing a topical platelet gel to supplement posterolateral fusions rates in 14 instrumented fusions; fusion rates were comparable for both groups at 6 postoperative months.<sup>[12]</sup>

### Arguments favoring utilization of Vivostat system

The Vivostat<sup>®</sup> system is successfully used in several specialties.<sup>[1,3,10,11,14,15,19,20]</sup> The autologous nature of Vivostat<sup>®</sup> eliminates the risks of bovine or human-borne contaminants, protecting the patient against viral diseases. It provides rapid polymerization, set rapidly, and provides instant tissue-fibrin adhesion, enabling the surgeon to manipulate the treated area early.<sup>[9,23]</sup> In our clinical series, the Vivostat<sup>®</sup> provided immediate hemostasis without compression of neural tissues. Furthermore, there were 2 cases complicated by postoperative CSF fistula out of 68 patients treated, but only one required repeated surgical intervention.

### CONCLUSION

Vivostat<sup>®</sup> system appears to be a safe/effective fully autologous hemostatic and dural sealant agent. Its composition and mechanism of action makes it able to adhere immediately to tissues and its rapid degradation time avoids any potential long-term mass effect.

### Financial support and sponsorship

Nil.

### Conflicts of interest

There are no conflicts of interest.

### REFERENCES

1. Belboul A, Dernevik L, Aljassim O, Skrbic B, Rådberg G, Roberts D. The effect of autologous fibrin sealant (Vivostat) on morbidity after pulmonary lobectomy: A prospective randomised, blinded study. *Eur J Cardiothorac Surg* 2004;26:1187-91.
2. Black P. Cerebrospinal fluid leaks following spinal or posterior fossa surgery: Use of fat grafts for prevention and repair. *Neurosurg Focus* 2000;9:e4.
3. Buchta C, Hedrich HC, Macher M, Höcker P, Redl H. Biochemical characterization of autologous fibrin sealants produced by CryoSeal and Vivostat in comparison to the homologous fibrin sealant product Tisseel/Tisseel. *Biomaterials* 2005;26:6233-41.
4. Cammisia FP Jr, Girardi FP, Sangani PK, Parvataneni HK, Cadag S, Sandhu HS. Incidental durotomy in spine surgery. *Spine (Phila Pa 1976)* 2000;25:2663-7.
5. Epstein NE. Hemostasis and other benefits of fibrin sealants/glues in spine surgery beyond cerebrospinal fluid leak repairs. *Surg Neurol Int* 2014;5 Suppl 7:S304-14.
6. Giugno A, Maugeri R, D'Arpa S, Visocchi M, Iacopino DG. Complex reconstructive surgery following removal of extra-intracranial meningiomas, including the use of autologous fibrin glue and a pedicled muscle flap. *Interdiscip Neurosurg* 2014;1:84-7.
7. Giugno A, Maugeri R, Graziano F, Iacopino DG. Intraoperative reparation of superior sagittal sinus (SSS) rupture with autologous fibrin glue: Management of a complication. Our experience and technical note. *J Neurol Disord* 2015;3:2.
8. Graziano F, Certo F, Basile L, Maugeri R, Grasso G, Meccio F, *et al.* Autologous fibrin sealant (Vivostat<sup>®</sup>) in the neurosurgical practice: Part I: Intracranial surgical procedure. *Surg Neurol Int* 2015;6:77.
9. Hanks JB, Kjaergard HK, Hollingsbee DA. A comparison of the haemostatic effect of Vivostat patient-derived fibrin sealant with oxidised cellulose (Surgicel) in multiple surgical procedures. *Eur Surg Res* 2003;35:439-44.
10. Kjaergard HK, Trumbull HR. Bleeding from the sternal marrow can be stopped using Vivostat patient-derived fibrin sealant. *Ann Thorac Surg* 2000;69:1173-5.
11. Kjaergard HK, Trumbull HR. Vivostat system autologous fibrin sealant: Preliminary study in elective coronary bypass grafting. *Ann Thorac Surg* 1998;66:482-6.
12. Landi A, Tarantino R, Marotta N, Ruggeri AG, Domenicucci M, Giudice L, *et al.* The use of platelet gel in postero-lateral fusion: Preliminary results in a series of 14 cases. *Eur Spine J* 2011;20 Suppl 1:S61-7.
13. Landriel Ibañez FA, Hem S, Ajler P, Vecchi E, Ciruolo C, Baccanelli M, *et al.* A new classification of complications in neurosurgery. *World Neurosurg* 2011;75:709-15.
14. Lardinois D, Jung FJ, Opitz I, Rentsch K, Latkoczy C, Vuong V, *et al.* Intrapleural topical application of cisplatin with the surgical carrier Vivostat increases the local drug concentration in an immune-competent rat model with malignant pleuromesothelioma. *J Thorac Cardiovasc Surg* 2006;131:697-703.
15. Lassen MR, Solgaard S, Kjersgaard AG, Olsen C, Lind B, Mittet K, *et al.* A pilot study of the effects of Vivostat patient-derived fibrin sealant in reducing blood loss in primary hip arthroplasty. *Clin Appl Thromb Hemost* 2006;12:352-7.
16. Ochsner MG. Fibrin solutions to control hemorrhage in the trauma patient. *J Long Term Eff Med Implants* 1998;8:161-73.
17. Ruban D, O'Toole JE. Management of incidental durotomy in minimally invasive spine surgery. *Neurosurg Focus* 2011;31:E15.
18. Schexneider KI. Fibrin sealants in surgical or traumatic hemorrhage. *Curr Opin Hematol* 2004;11:323-6.
19. Schips L, Dalpiaz O, Cestari A, Lipsky K, Gidaro S, Zigeuner R, *et al.* Autologous fibrin glue using the Vivostat system for hemostasis in laparoscopic partial nephrectomy. *Eur Urol* 2006;50:801-5.

20. Schmidt SC, Langrehr JM. Autologous fibrin sealant (Vivostat) for mesh fixation in laparoscopic transabdominal preperitoneal hernia repair. *Endoscopy* 2006;38:841-4.
21. Theodosopoulos PV, Ringer AJ, McPherson CM, Warnick RE, Kuntz C 4<sup>th</sup>, Zuccarello M, et al. Measuring surgical outcomes in neurosurgery: Implementation, analysis, and auditing a prospective series of more than 5000 procedures. *J Neurosurg* 2012;117:947-54.
22. Turgut M, Erkus M, Tavus N. The effect of fibrin adhesive (Tisseel) on interbody allograft fusion: An experimental study with cats. *Acta Neurochir (Wien)* 1999;141:273-8.
23. Velada JL, Hollingsbee DA. Physical characteristics of Vivostat patient-derived sealant. Implications for clinical use. *Eur Surg Res* 2001;33:399-404.