

## THE IMMUNOHISTOCHEMICAL EXPRESSION OF LEPTIN IN LYMPH NODE METASTASIS FROM LARYNGEAL SQUAMOUS CELL CARCINOMA (SCC)

R. GARGANO<sup>1</sup>, B. VERRÒ<sup>1</sup>, S. D'ALESSI<sup>1</sup>, A. M. FLORENA<sup>2</sup>, F. GALLETTI<sup>3</sup>, B. GALLETTI<sup>3</sup>, G. GRECO<sup>1</sup>, S. FERRARA<sup>1</sup>

<sup>1</sup>Otorhinolaryngology Section, Department of Biomedicine, Neurosciences and Advanced Diagnostic, University of Palermo, Palermo, Italy - <sup>2</sup>Department of Sciences for Health Promotion and Mother and Child Care "G. D'Alessandro", University of Palermo, Palermo, Italy - <sup>3</sup>Otorhinolaryngology Section, University of Messina, Messina, Italy

### ABSTRACT

**Introduction:** Leptin is a proteohormone produced predominantly by white adipocytes and primarily known for its key role in the control of food intake and sense of satiety. From its discover leptin has been found in different body districts, involved in always new functions and processes. In the last years numerous relationships between leptin and cancer has been found. The aim of this study is to test the leptin positivity in human primitive laryngeal squamous cell carcinoma (SCC) and in its lymph node metastasis.

**Materials and methods:** Leptin positivity was detected by immunohistochemical analysis on pathological samples from 18 patients subjected to laryngectomy and neck dissection for SCC.

**Results:** During the study we pointed out a statistically significant relationship ( $p < 0.05$ ) between leptin positivity levels and tumor differentiation grade, in particular we observed that a decrease in tumor leptin production correlates with higher level of cancer histological dedifferentiation.

**Conclusion:** Our research on leptin expression in laryngeal squamous neoplastic pathology is aimed to the attempt of establishing a more precise patient risk stratification thanks to a new marker able to give a contribution to the identification of patient with poor prognosis and at risk of failure of actual standard therapy.

**Keywords:** Head and neck tumor, Adipokine, Leptin, Predictive factor.

DOI: 10.19193/0393-6384\_2020\_1\_8

Received November 30, 2018; Accepted February 20, 2019

### Introduction

Leptin (from the Greek λεπτός, "thin")<sup>(1,2)</sup> is a peptidic hormone of 167 amino-acid. It is known as "satiety hormone" due to the fact that it plays an important monitoring role in the energetic homeostasis, primarily inhibiting hunger and inducing the sense of satiety and consequently reducing the food intake to regulate the body weight<sup>(3)</sup>.

Leptin was first identified in adipose tissue and it was labeled as an adipokine. More recently a large number of observations proves that this hormone is secreted in many other different tissues - such as gastric fundic glands, skeletal muscle, liver, placenta<sup>(4)</sup> - and situations - as during inflammatory processes. Leptin secretion follows the circadian rhythm and it reaches its pick during the night<sup>(5,6)</sup>.

The regulation of leptin serum levels is not only related to the adipocyte number and to

variations in the body weight and nutritional status but also to many endocrinological factors, first of all the insulin level<sup>(4)</sup> that, if is too low, inhibits leptin production. Leptin secretion is stimulated by glucocorticoids, TNF- $\alpha$  (Tumor Necrosis Factor) and estrogens, while it is inhibited by  $\beta$ -adrenergic activity, androgens, FFA (Free Fatty Acid), GH (Growth Hormone) and thyroid hormones.

Leptin receptor belongs to type I cytokine receptors<sup>(7)</sup>, it is ubiquitously expressed in body in 3 alternatively spliced forms (long, short and soluble) and each one has a different location where plays different role<sup>(8)</sup>.

Leptin has an anorectic effect decreasing the food intake<sup>(3)</sup>; it acts also as an insulin-sensitizing hormone reducing lipids storage; moreover, leptin promotes catabolic pathways that lead to ATP (Adenosine Triphosphate) production and inhibits the anabolic processes that require ATP<sup>(3)</sup>.

Leptin has many other important and various effects involving the regulation of immune function, the interference with bone remodeling<sup>(9)</sup>, the promotion of hematopoietic cells proliferation and differentiation, the regulation of the reproductive system<sup>(10, 11)</sup> and, during the fetal period, the stimulation of the alveolar surfactant production<sup>(12)</sup>. But two remarkable and recently discovered leptin functions suggest that this hormone may play an important role in the risk of cancer development and recurrence: the power of leptin to stimulate angiogenesis, endothelial cells growth<sup>(13)</sup> and proangiogenic factors release and its ability to make cells avoid stress-induced apoptosis and proliferate<sup>(14)</sup>.

To date the relation between leptin expression and risk of recurrence in laryngeal squamous cell carcinoma (SCC) was demonstrated<sup>(15)</sup> and from this assumption, the aim of our study was to test leptin positivity in lymph node SCC metastasis to rate its relation with primitive laryngeal cancer samples.

## Materials and methods

### *Patients selection*

We selected a series of 18 consecutive patients, 13 males and 5 females, whose age, at the time of diagnosis, was between 43 and 78 years, with a mean age of 59 years (61,6 years males; 52,2 years females). All patients had been subjected to total/partial laryngectomy with unilateral/total neck dissection in our Operating Unit between 2010 and 2015. 12 patients had lymph node metastasis at the time of the diagnosis.

The characteristics and histopathological features of the sample are shown and summarized in Table 1.

### *Sample selection*

We picked up 19 samples out of our 18 patients; each patient sample included 2 specimens: the first one taken from a section of larynx primitive tumor without any sign of necrosis, the second one taken from one resected lymph node. 12 of the lymph nodes included in this study were involved by metastasis from laryngeal squamous cell carcinoma; the 7 lymph nodes negative for metastasis were used as negative controls.

The histological grade according to tumor differentiation was assessed histologically (Figure 1).

### *Tissue preparation and histopathologic analysis*

All samples were fixed in formalin and embedded in paraffin to obtain sections of approximately 4 $\mu$ m. Sample sections were stained with hematoxylin and eosin histochemical staining for histological evaluation.

### *Immunohistochemical analysis*

All sections were deparaffinated with xylol, rehydrated in a decreasing alcohol scale and subjected to antigenic exposure by 3 cycles of microwave treatment in Tris-HCL/EDTA buffer solution (Ph 6) for 5 minutes, led to ambient temperature and washed with PBS buffer. After endogenous peroxidase activity quenching with 3% hydrogen peroxide, all sections were incubated with a protein blocking buffer for 10 minutes to prevent antibodies nonspecific binding to tissue. Afterwards all samples were incubated with the primary antibody for one hour at ambient temperature. The primary antibody used for the immunohistochemical analysis is an anti-leptin rabbit polyclonal antibody. Primary antibody binding was detected using the Labeled StreptAvidin Biotin (LASB+) horseradish peroxidase (HRP) kit using acetyl-ethanol-carbazole as chromogenic substrate for immunohistochemical staining. All sections were contrasted with hematoxylin and afterwards were subjected to optical microscope evaluation.

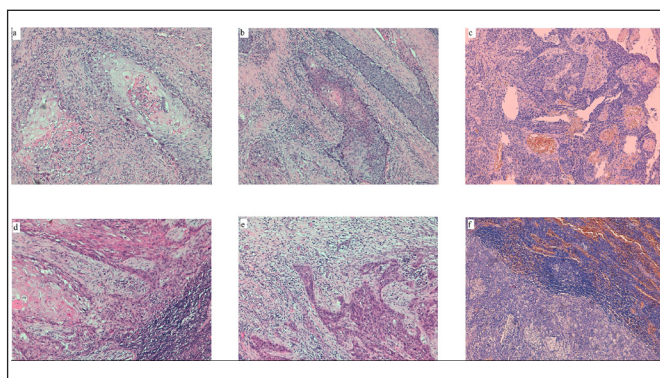
All samples included in the study were subsequently histologically reevaluated from two different pathologists to identify the tumor differentiation grade and to highlight eventual vascular and/or perineural infiltration.

### *Image analysis*

All sections were analyzed to evaluate staining positivity, intensity and distribution. To rate the staining reaction efficacy, adipose tissue, submucosal larynx glands and inflammatory cells (histiocytes, lymphocytes and plasma cells) were used as positive controls. The staining reaction was evaluated by a team of expert pathologists in a subjective semiquantitative way using an increasing intensity scale going from 0 to 3. The staining was scored 0 if there was no immunoreactivity, 1 if it was light, 2 if immunoreactivity was moderate and 3 if tissue response to immunohistochemical staining was high.

		Laryngeal Squamous Cell Carcinoma (SCC)				SCC Lymph Node Metastasis								
		N (%)	Mean age	Leptin		p value	N (%)	Mean age	Leptin		p value			
Patients				Low (0-1)	High (2-3)				Low (0-1)	High (2-3)				
Total		18	59	7 (2-5)	11 (9-2)		12	59.7	8 (3-5)	4 (3-1)				
Males		13 (72.2)	61.6	5 (1-4)	8 (7-1)	0.68	8 (66.6)	63.2	5 (3-2)	3 (3-0)	0.59			
Females		5 (27.7)	51.2	2 (1-1)	3 (2-1)		4 (33.3)	52.7	3 (0-3)	1 (0-1)				
Age														
≤59		10 (55.6)	51.6	4 (1-3)	6 (5-1)	0.64	6 (50)	52	3 (1-2)	3 (2-1)	0.27			
>59		8 (44.4)	68.3	3 (1-2)	5 (4-1)		6 (50)	67.5	5 (2-3)	1 (1-0)				
Differentiation														
G1	High	2 (11.1)	59.5	-	2	2 (0-2)	0.013 5 (41.7)	1 (8.3)	43	-	2	1 (0-1)	4	0.03
G2		10 (55.6)	58.8	2 (0-2)	8 (8-0)	3 (3-0)		57.6	2 (0-2)					
G3	Low	6 (33.3)	59.1	5 (2-3)	1 (1-0)	6 (50)		64.3	6 (3-3)	-				

**Table 1:** Characteristics and histopathological features of 18 patients and correlation with leptin expression.



**Fig. 1:** Hematoxylin and eosin staining; MO x10.  
**a:** Well-differentiated (G1) squamous cell carcinoma primitive of larynx: note the mild pleomorphism and keratinization; **b:** moderately differentiated (G2) squamous cell carcinoma primitive of larynx: there is more pleomorphism but the nature of the tumor is still readily apparent; **c:** poorly differentiated (G3) squamous cell carcinoma primitive of larynx: there is marked pleomorphism but no keratinization; **d:** nodal metastasis by well-differentiated (G1) squamous cell carcinoma: note the nodal rim at lower right corner; **e:** nodal metastasis by moderately differentiated (G2) squamous cell carcinoma; **f:** nodal metastasis by poorly differentiated (G3) squamous cell carcinoma: note the nodal tissue at upper right corner.

**Statistical analysis**

All statistical analysis were performed using VassarStats (©Richard Lowry). Fisher’s exact test was used to compare categorical variables. We considered a  $p \leq 0.05$  to be significant.

**Results**

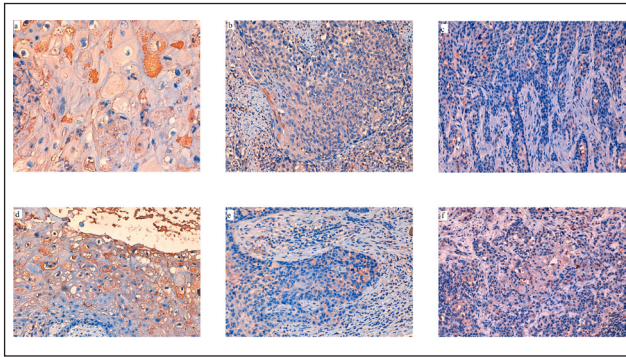
Neoplastic cells showed a variable but statistically significant cytoplasmic positivity to leptin (88.9%).

Comparing immunohistochemical characteristics in each case was found a different rate of leptin positivity related to clinicopathological characteristic of tumor and especially related to histological grade ( $p < 0.05$ ) (Table 1).

There seems to be no statistically significant relationship between the intensity of leptin positivity and sex ( $p = 0.68$ ) or age ( $p = 0.64$ ).

In all samples a significant association between positivity to leptin and tumor histological grade was found. Indeed, leptin positivity sharply raised with the increase of tumor differentiation in both laryngeal primitive tumor ( $p = 0.013$ ) and lymph node metastasis specimens ( $p = 0.03$ ). We found the highest staining positivity - grade 3 - in all tumor samples (100%) graded as G1 (Figure 2 a-d) while a negative or minimal positivity – grade 0/1 - in most (90.9%) G3 labeled samples (Figure 2 c-f). Moderate leptin expression levels - grade 2 - were found in most (73.3%) G2 tumor samples (Figure 2 b-e).

Furthermore, we observed that the leptin immunohistochemical staining positivity level showed by lymph node tissue samples was comparable to the primitive laryngeal tumor level only in those cases showing the same histological grade.



**Fig. 2:** Immunohistochemical level of leptin expression in squamous cell carcinoma primitive of larynx (**a-b-c**) and nodal metastasis (**d-e-f**); MO x20.

The staining is intense for primitive and metastatic well-differentiated (G1) forms (**a-d**); the neoplastic tissue shows a moderate intensity in primitive and metastatic moderately differentiated (G2) forms (**b-e**); the staining results mild or absent in primitive and metastatic poorly differentiated (G3) forms (**c-f**).

An interesting finding was the detection of a higher degree of leptin expression in the more superficial and mature layers of laryngeal squamous stratified nonkeratinized epithelium in the areas not involved by the tumor as well as in the enclosed healthy submucosal glands.

## Discussion

The positivity to leptin expression in primitive tumor tissue we found is in agreement with other observations reported in the literature regarding other neoplastic diseases of head and neck district. In particular it was reported in lacrimal glands tumors and salivary glands tumors<sup>(16)</sup> where different hormonal production levels were related to differences in tumor histological type.

To date there are many studies about leptin expression in breast, bladder, lung, pancreatic, cancers and large B cell lymphoma. Specifically high leptin levels represent a poor prognostic marker in breast, thyroid<sup>(17)</sup>, ovarian, colon and gastric<sup>(18)</sup> cancer, while they may predict a good outcome in soft tissue cancer<sup>(19)</sup>. Moreover in their study, for the first time, Gallina et al.<sup>(15)</sup> demonstrated the immunohistochemical expression of leptin in laryngeal SCC. In particular they observed its higher expression in cases of advanced grade tumor (G2-G3) and its possible role to predict malignant recurrence. In addition, our study revealed leptin positivity in lymph node SCC metastasis and that its immunohistochemical staining positivity level in lymph node tissue samples was comparable to the primitive laryngeal tumor level only in those cas-

es showing the same histological grade. Though, contrary to what observed by Gallina et al.<sup>(15)</sup>, leptin positivity raised with the increase of tumor differentiation in both laryngeal primitive tumor and lymph node metastasis specimens.

To the best of our knowledge, no paper has been so far published about pathologic tissue samples coming from lymph node metastasis of epidermoid squamous cell carcinoma. This study can therefore be configured as the first in this direction. Indeed, up to now, several studies demonstrated the correlation between leptin expression and metastasis in different types and sites of tumor such as bone metastasis in lung adenocarcinoma (20), sentinel lymph node metastasis in cutaneous melanoma<sup>(21)</sup> or even lymph node metastasis in endometrial cancer<sup>(22)</sup>. Moreover, these studies didn't evaluate the link between leptin expression levels and tumor differentiation as we have done. Therefore no one studied the association of leptin expression and lymph node metastasis of laryngeal SCC.

The target of our research on leptin expression in laryngeal squamous neoplastic pathology, besides a better prognostic patient stratification, is also aimed to the attempt of establishing a more precise patient risk stratification possibly identifying a new marker able to give a contribution to the identification of patient with poor prognosis and at risk of failure of actual standard therapy.

## References

- 1) Halaas JL, Gajiwala KS, Maffei M, Cohen SL, Chait BT, Rabinowitz D, Lallone RL, Burley SK, Friedman JM: Weight-reducing effects of the plasma protein encoded by the obese gene. *Science*, July 1995; 269 (5223): 543-546
- 2) Neill US: Leaping for leptin: the 2010 Albert Lasker Basic Medical Research Award goes to Douglas Coleman and Jeffrey M. Friedman. *Journal of Clinical Investigation*, October 2010; 120 (10): 3413-3418
- 3) Mantzoros CS: The role of leptin in human obesity and disease: a review of current evidence. *Annals of Internal Medicine*, 1999; 130 (8): 671-680
- 4) Margetic S, Gazzola C, Pegg GG, Hill RA: Leptin: a review of its peripheral actions and interactions. *International Journal of Obesity and Related Metabolic Disorders*, 2002; 26 (11): 1407-1433
- 5) Schoeller DA, Cella LK, Sinha MK, Caro JF: Entrainment of the diurnal rhythm of plasma leptin to meal timing. *Journal of Clinical Investigation*, October 1997; 100 (7): 1882-1887
- 6) Sinha MK, Ohannesian JP, Heiman ML, Kriauciunas A, Stephens TW, Magosin S, Marco C, Caro JF: Nocturnal

- rise of leptin in lean, obese, and non-insulin- dependent diabetes mellitus subjects. *Journal of Clinical Investigation*, March 1996; 97 (5): 1344-1347
- 7) Tartaglia LA: The leptin receptor. *Journal of Biological Chemistry*, 1997; 272: 6093-6096
  - 8) Bjorbaek C, Uotani S, da Silva B, Flier JS: Divergent signaling capacities of the long and short isoforms of the leptin receptor. *Journal of Biological Chemistry*, 1997; 272: 32686-32695
  - 9) Ducy P, Amling M, Takeda S, Priemel M, Schilling AF, Beil FT, Shen J, Vinson C, Rueger JM, Karsenty G: Leptin inhibits bone formation through a hypothalamic relay: a central control of bone mass. *Cell*, January 2000; 100 (2): 197-207
  - 10) Comminos AN, Jayasena CN, Dhillon WS: The relationship between gut and adipose hormones, and reproduction. *Human Reproduction Update*, 2014; 20 (2): 153-174
  - 11) Köpp W, Blum WF, von Prittwitz S, Ziegler A, Lübbert H, Emons G, Herzog W, Herpertz S, Deter HC, Remschmidt H, Hebebrand J: Low leptin levels predict amenorrhea in underweight and eating disordered females. *Molecular Psychiatry*, 1997; 2: 335-340
  - 12) Torday JS, Rehan VK: Up-regulation of fetal rat lung parathyroid hormone- related protein gene regulatory network down-regulates the Sonic Hedgehog/Wnt /beta-catenin gene regulatory network. *Pediatric Research*, October 2006; 60 (4): 382-388
  - 13) Park HY, Kwon HM, Lim HJ, Hong BK, Lee JY, Park BE, Jang Y, Cho SY, Kim HS: Potential role of leptin in angiogenesis: leptin induces endothelial cell proliferation and expression of matrix metalloproteinases in vivo and in vitro. *Experimental & Molecular Medicine*, June 2001; 33(2): 95-102
  - 14) Housa D, Housova J, Vernerova Z, Haluzik M: Adipocytokines and cancer. *Physiological Research*, 2006; 55: 233-244
  - 15) S. Gallina, F. Sireci, F. Lorusso, D.V. Di Benedetto, R. Speciale, D. Marchese, C. Costantino, G. Napoli, V. Tessitore, D. Cucco, A. Leone, G. Bonaventura, M.L. Uzzo, G.F. Spatola: The immunohistochemical peptidergic expression of leptin is associated with recurrence of malignancy in laryngeal squamous cell carcinoma. *ACTA otorhinolaryngologica italica*, 2015; 35: 15-22
  - 16) Schapher M, Wendler O, Groschi M, Schafer R, Heinrich I, Zenk J. Salivary leptin as a candidate diagnostic marker in salivary gland tumors. *Clinical Chemistry* 2009; 55: 914-922
  - 17) Fan YL, Li XQ. Expression of leptin and its receptor in thyroid carcinoma: distinctive prognostic significance in different subtypes. *Clinical Endocrinology*, 2015; 83(2): 261-267
  - 18) Bain GH, Collie-Duguid E, Murray GI, Gilbert FJ, Denison A, McKiddie F, Ahearn T, Fleming I, Leeds J, Phull P, et al. Tumour expression of leptin is associated with chemotherapy resistance and therapy-independent prognosis in gastro-oesophageal adenocarcinomas. *British Journal of Cancer*, 2014; 110(6): 1525-1534
  - 19) Lin TC, Huang KW, Liu CW, Chang YC, Lin WM, Yang TY, Hsiao M. Leptin signaling axis specifically associates with clinical prognosis and is multifunctional in regulating cancer progression. *Oncotarget*, 2018; 9 (24): 17210-17219
  - 20) Feng HL, Guo P, Wang J, Liu QY, Xu JF, Yang HC, Zhang JM. Association of the expression of leptin and leptin receptor with bone metastasis in pulmonary adenocarcinoma. *Zhonghua Zhong Liu Za Zhi*, 2016; 38: 840-844
  - 21) Oba J, Wei W, Gershenwald JE, Johnson MM, Wyatt CM, Ellerhorst JA, Grimm EA. Elevated serum leptin levels are associated with an increased risk of sentinel lymph node metastasis in cutaneous melanoma. *Medicine*, 2016; 95 (11): 3073
  - 22) Zhang Y, Liu L, Li C, Ai H. Correlation analysis between the expressions of leptin and its receptor (ObR) and clinicopathology in endometrial cancer. *Cancer Biomark*, 2014; 14: 353-359

#### Acknowledgements

The authors wish to thank Professor Domenica Matranga for her statistical analysis assistance.

#### Corresponding Author:

BARBARA VERRO  
Email: verrobarbara@gmail.com  
(Italy)