

## SEPTIC SKIN LESIONS: AN UNCOMMON MANIFESTATION OF PERIPHERAL PROSTHETIC VASCULAR GRAFT INFECTION

MAFALDA MASSARA<sup>1</sup>, ANTONIO CASCIO<sup>2</sup>, FILIPPO BENEDETTO<sup>1</sup>, GIOVANNI DE CARIDI<sup>1</sup>, SALVATORE LENTINI<sup>3</sup>, FRANCESCO SPINELLI<sup>1</sup>

<sup>1</sup>Cardiovascular and Thoracic Department, University of Messina, Messina - <sup>2</sup>Department of Human Pathology, University of Messina, Messina - <sup>3</sup>Cardiovascular Department, Città di Lecce Hospital, Lecce, Italy

### ABSTRACT

*Peripheral prosthetic vascular graft infection following lower limb surgical revascularization is a relatively rare but serious condition. A case of early infection and occlusion of a above-knee femoro-popliteal artery prosthetic bypass is here reported. It was accompanied by acute lower limb ischemia, fever and distally by embolic septic skin lesions.*

**Key words:** Embolism; infection; skin; vascular graft.

*Received February 18, 2014; Accepted March 24, 2014*

### Introduction

Infection of a prosthesis following a lower limb surgical revascularization is a relatively rare condition (1-6%)<sup>(1)</sup>. Serious complications can occur, such as pseudoaneurysm formation at the level of anastomotic site, bleeding, graft occlusion and organ failure, resulting in leg amputation (10-70%) or even death (10-20%)<sup>(2-5)</sup>. Among the complications, septic skin lesions are very rare and only a few cases are reported in literature<sup>(6,7)</sup>.

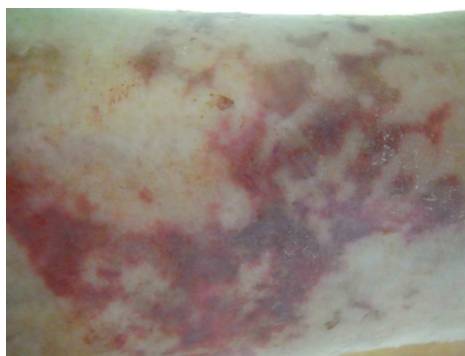
Here we describe a case of early infection and occlusion of a femoro-popliteal above the knee prosthetic bypass, that was accompanied by acute lower limb ischemia, fever and distally by embolic septic skin lesions. Current literature on this subject is reviewed.

### Case presentation

A 71 years old woman affected by systemic hypertension and type II diabetes with a history of peripheral artery disease previously treated by percutaneous transluminal angioplasty (PTA) came under our observation complaining of right lower limb rest pain (stage 4 of Rutherford classification).

Ultrasound (US) Doppler scan showed sub-occlusive re-stenosis of the right superficial femoral artery (SFA) previously treated with PTA, patency of the popliteal artery and patency of two tibial vessels (peroneal and posterior tibial artery). A femoro-popliteal above the knee bypass was performed using a vascular graft in polytetrafluoroethylene (PTFE). During hospitalization the patient received perioperative antibiotic prophylaxis with cefazolin and low molecular weight heparin therapy (LMWH). She was discharged home on the 8th postoperative day on LMWH and antiplatelet therapy.

The patient returned to our observation twenty days later appearing seriously ill. On admission she had right lower limb acute pain, fever (38.5 °C), pulse rate 110 beats/min, respiratory rate 22 breaths/min, blood pressure 90/60 mmHg and oxygen saturation 88%. The right lower limb was painful with foot cyanosis and dehiscence of the distal surgical wound, with necrosis of skin margins. On the right leg there were also peculiar skin lesions suggestive of peripheral embolism. In particular, several erythematous plaques with a purpuric center and poorly defined borders were present (Figure 1).



**Figure 1:** Erythematous plaques with a purpuric center and poorly defined borders on the distal part of the right lower limb.

They were mostly present on the distal portion of the limb where they tended to be present in clusters. US scan confirmed prosthetic bypass occlusion as the cause of acute limb ischemia. Neither arterial aneurysms with ulcerated atherosclerotic plaques nor pseudo-aneurysm sources of emboli were identified through physical examination or US scan. Electrocardiography excluded ischemic myocardial abnormalities or arrhythmias; echocardiography revealed normal ventricular function with no cardiac valves vegetations or other sources of cardiac emboli.

Laboratory investigations revealed a white blood cell count (WBC) of 15.500/mm<sup>3</sup> (76% neutrophils); C-reactive protein (CRP) 30 mg/dL (normal values < 0.5 mg/dL), increased serum potassium, lactate dehydrogenase and creatine kinase; the remainder of blood results including clotting screening were within normal ranges.

Two samples for blood cultures were drawn. Broad spectrum antibiotic therapy with teicoplanin and levofloxacin was started and the patient was brought to the surgical room. A femoro-tibial peroneal trunk bypass using the great saphenous vein in situ was performed. Surgical decompression of the anterior leg compartment was also completed to avoid compartment syndrome after revascularization. In the suspicion of a prosthetic infection, based on the fact that the prosthesis appeared not well adherent to the surrounding tissues, the PTFE previously implanted prosthesis was removed and sent for microbiological analysis; a drainage was positioned in correspondence of the previous distal surgical wound.

Histopathology of the skin lesions showed a normal epidermis and multifocal, dense neutrophilic inflammatory infiltrates in the mid and deep dermis with extravasated red blood cells. The vessels presented a prominent endothelium, intralu-

minal thrombi, and intraluminal, intraparietal, and interstitial neutrophils.

The microbiological cultures from the removed thrombus and prosthesis returned positive for *Staphylococcus warneri*; the strain was resistant to methicillin, erythromycin, clindamycin, and sensitive to teicoplanin (MIC≤0.5μg/ml), linezolid (MIC≤1μg/ml) and tetracycline (MIC≤4μg/ml). Levofloxacin was stopped and teicoplanin continued for a total of 10 days. General conditions slowly improved with normalization of the WBC count and CRP value. The right lower limb conditions improved with disappearance of the distal cyanosis, resumption of normal local temperature and normalization of both motility and sensitivity. The patient was discharged home on the 15<sup>th</sup> postoperative day without signs or symptoms of infection. At 1, 3, 6, and 12 month follow-up visits, US scan showed the patency of the femoro-distal bypass and absence of local and systemic signs and symptoms of infection.

## Discussion

Infection of a prosthesis following a lower limb surgical revascularization is a relatively rare but serious complication. The appearance of peripheral septic skin lesions is an uncommon and very rare manifestation of this condition. To the best of our knowledge, only two cases of peripheral septic skin lesions originating from an infected peripheral vascular prosthesis have been previously reported in literature. Zumelzu et al. described a case of fever, purpura of the left lower limb with cyanotic left toes in a 43 year-old-HIV-positive man presenting a voluminous right iliac abscess, following a crossover iliofemoral arterial bypass. The patient was submitted to skin biopsy, blood culture, echocardiography to exclude a cardiac source of peripheral septic embolism, bypass eco-color-duplex, ankle radiograph and abdominal and pelvic CT scan, demonstrating a periprosthetic abscess. Treatment was based on surgical debridement of the abscess without prosthesis removal and specific antibiotic therapy (oxacillin for 6 months), resulting in complete healing<sup>(6)</sup>.

Boureau et al. reported a case of late infection of an iliofemoral prosthetic vascular graft in a 52 year-old man, accompanied by purpura localized on the right leg and fever. Also in this case the diagnosis was achieved through skin biopsy, echocardiography and blood culture. A specific antibiotic thera-

py was started (penicillin and gentamycin), the infected prosthesis was removed and an extra-anatomic bypass was performed, to avoid the lower limb ischemia. Also in this patient a complete healing was observed<sup>(7)</sup>.

In both cases the infection was caused by *Staphylococcus aureus*, while in our patient the germ involved was *Staphylococcus warneri*. Our patient presented an early infection with consequently occlusion of a femoro-popliteal above the knee prosthetic bypass. Unlike the other two cases, our patient was a 71 year-old woman that presented also an acute ischemia of the lower limb, in addition to fever and peripheral septic skin lesions.

The diagnosis was obtained through skin biopsy, blood culture and echocardiography, to exclude a cardiac source of emboli. The treatment was based on antibiotic therapy (teicoplanin), removal of the infected prosthesis as reported by Boureau and co-workers and, unlike the two cases mentioned, a femoro-tibial peroneal trunk bypass using the great saphenous vein was performed. In addition, our patient required surgical decompression of the anterior leg compartment to avoid compartment syndrome after revascularization. As in the other cases, the healing of the patient was obtained.

Staphylococci (*S. aureus* and coagulase-negative staphylococci) account for 80% of prosthetic vascular graft infections<sup>(8)</sup>, but infections caused by fungi (mainly *Candida*), other Gram-positive cocci (enterococci, streptococci), or Gram-negative rods (mainly *Escherichia coli*, *Pseudomonas aeruginosa* and *Klebsiella* spp.) are also reported<sup>(9)</sup>.

Possible causes of PVGI are represented by local bleeding and haematoma formation around the prosthesis that could be responsible also of bypass compression and occlusion; cutaneous necrosis caused by prolonged skin margin retraction or subcutaneous tangential inappropriate dissection during surgery and lymphorrhea.

The clinical presentation of PVGI is very variable. Early infections that develop less than 3 months after surgery, generally occur with acute onset of fever, bacteraemia, pain, erythema, swelling, warmth, local bleeding, graft occlusion or the appearance of a pulsatile mass, sign of pseudoaneurysm formation. Late infections develop more than 3 months after surgery: systemic manifestations of infection are often absent and blood cultures are often negative.

Clinically, they may present with more subtle symptoms and signs such as back pain, fistula, graft

occlusion and asymptomatic pseudoaneurysm formation<sup>(10)</sup>.

The presence of peripheral septic skin lesions represents a very uncommon clinical manifestation of this condition, therefore the differential diagnosis with other sources of septic embolism is always required. In particular, peripheral septic cutaneous manifestations generally have a cardiac source such as endocarditis and echocardiography is required to achieve a correct diagnosis. Non-cardiac sources of septic skin lesions are more rarely observed and actually, the most frequent cause of these could be represented by arterial pseudoaneurysm formation and/or septic endarteritis following percutaneous transluminal angioplasty; this is due to the increasing use of invasive diagnostic and therapeutic vascular procedures<sup>(11-15)</sup>.

The diagnosis is essentially based on clinical examination of the patient, skin biopsy of the lesions, microbiological exam of the removed prosthesis and blood culture. Echocardiography is useful to exclude a cardiac source of septic emboli.

In conclusion, our case provides clinical evidence to add septic skin embolism among the complications of peripheral prosthetic revascularization. Physicians should be aware that patients presenting with fever and purpuric lesions on the skin distally to a prosthetic bypass may have septic embolism and include this in their differential diagnosis. Apart the intervention of revascularization and surgical debridement of the infected tissues, it is essential to perform blood cultures, cultures of the thrombus and of the removed prosthesis. Antibiotic therapy should not be delayed, broad spectrum empiric antibiotics should be used initially, and on the basis of culture results should be subsequently tailored.

## References

- 1) Darouiche RO *Treatment of infections associated with surgical implants*. N Engl J Med 2004; 350: 1422-1429.
- 2) Edwards WH, Jr., Martin RS, 3rd, Jenkins JM, Edwards WH, Sr., Mulherin JL, Jr. *Primary graft infections*. J Vasc Surg 1987; 6: 235-239.
- 3) Calligaro KD, Veith FJ, Schwartz ML, et al. *Selective preservation of infected prosthetic arterial grafts. Analysis of a 20-year experience with 120 extracavitary-infected grafts*. Ann Surg 1994; 220: 461-469; discussion 469-471.
- 4) Liekweg WG, Jr., Greenfield LJ *Vascular prosthetic infections: collected experience and results of treat-*

- ment. *Surgery* 1977; 81: 335-342.
- 5) Newington DP, Houghton PW, Baird RN, Horrocks M *Groin wound infection after arterial surgery*. *Br J Surg* 1991; 78: 617-619.
  - 6) Zumelzu C, Alexandre M, Blom A, et al. *Unilateral purpura of a limb revealing a periprosthetic abscess in an HIV-infected patient*. *Ann Dermatol Venereol* 2011; 138: 748-752.
  - 7) Boureau AS, Lescalie F, Cassagnau E, Clairand R, Connault J *Localized purpura revealing vascular prosthetic graft infection*. *J Mal Vasc* 2013; 38: 276-279.
  - 8) Stone PA, Back MR, Armstrong PA, et al. *Evolving microbiology and treatment of extracavitary prosthetic graft infections*. *Vasc Endovascular Surg* 2008; 42: 537-544.
  - 9) Mayer D, Hasse B, Koelliker J, et al. *Long-term results of vascular graft and artery preserving treatment with negative pressure wound therapy in Szilagy grade III infections justify a paradigm shift*. *Ann Surg* 2011; 254: 754-759; discussion 760.
  - 10) Hasse B, Husmann L, Zinkernagel A, et al. *Vascular graft infections*. *Swiss Med Wkly* 2013; 143: w13754.
  - 11) Sanz-Canalejas L, Floristan-Muruzabal U, Feito-Rodriguez M, et al. [Septic emboli to the skin following angioplasty]. *Actas Dermosifiliogr* 2011; 102: 142-145.
  - 12) Izumi AK, Samlaska CP, Hew DW, Bruno PP *Septic embolization arising from infected pseudoaneurysms following percutaneous transluminal coronary angioplasty: a report of 2 cases and review of the literature*. *Cutis* 2000; 66: 447-452.
  - 13) Evans BH, Goldstein EJ *Increased risk of infection after repeat percutaneous transluminal coronary angioplasty*. *Am J Infect Control* 1987; 15: 125-126.
  - 14) McCready RA, Siderys H, Pittman JN, et al. *Septic complications after cardiac catheterization and percutaneous transluminal coronary angioplasty*. *J Vasc Surg* 1991; 14: 170-174.
  - 15) Krupski WC, Pogany A, Effeney DJ *Septic endarteritis after percutaneous transluminal angioplasty*. *Surgery* 1985; 98: 359-362.

*Funding acknowledgment statement*

*This research received no specific grant from any funding agency in the public, commercial, or not-for-profit sectors.*

*Request reprints from:*

PROF. ANTONIO CASCIO  
UOC Malattie Infettive, AOU Policlinico "G. Martino"  
Via Consolare Valeria n. 1  
98125 Messina  
(Italy)