

# Treatment of femoral pseudoaneurysm after vascular procedure

E. Dinoto, F. Pecoraro, D. Pakeliani, G. Bajardi  
Vascular Surgery Unit, University of Palermo, Palermo, Italy

Femoral artery pseudoaneurysms (FAP) incidence has increased, in last years, in line with the number of percutaneous interventions. FAP may complicate up to 8% of percutaneous vascular accesses after interventional procedures. FAP incidence can be even higher if are employed large-diameter sheaths, fibrinolytic therapy and anticoagulant regimens.<sup>1, 2</sup> A spontaneous sealing can occur in small diameter FAP, but an intervention is often required especially for larger diameter. Surgery has been considered the “gold standard” treatment, although its related perioperative morbidity in these high-risk patients with severe cardiovascular disease. Less invasive treatment options such as Duplex ultrasound-guided compression (DUGC) and percutaneous thrombin injection are available with satisfactory results.<sup>2</sup> Endovascular solutions, as FAP exclusion with stent-graft deployment, have also been reported.<sup>3</sup> Herein we report our experience in FAP treatment after percutaneous interventions.

## Material and methods

From June 2009 to June 2014 patients presenting FAP after percutaneous interventions were retrospective analysed. All the inclusion patients presented FAP after a percutaneous intervention. FAP after femoral surgical treatments were excluded. FAPs were diagnosis included clinical examination (pain and tender pulsatile mass in correspondence of the femoral percutaneous access site) and duplex ultrasound (DUS) in all cases. In selected cases, with large FAP diameter, a Computed Tomography Angiography (CTA) was performed to as-

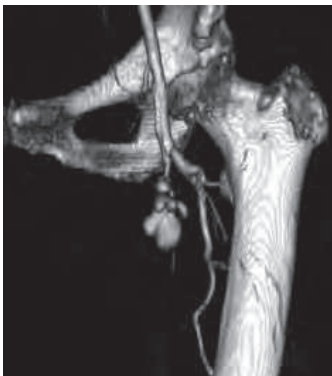

Figure 1. – 3D reconstruction: femoral bifurcation pseudoaneurysm.

sess anatomic relation with adjacent structures (Figure 1). FAP treatment protocol included duplex ultrasound guided-compression (DUGC) for diameter inferior to 2 cm and percutaneous thrombin injection (PTI) for diameter superior to 2 cm. Surgery was employed in large (>7 cm) FAP, DUGC or PTI failure, FAP presenting with cutaneous necrosis, associated FAP compressive symptoms into adjacent structures or the finding of large (>0.5 cm) FAP neck diameter. Follow-up included clinical examination and DUS at 1, 3, 6 and 12 months. Early outcomes measured were procedural technical success, perioperative mortality and morbidity. Perioperative outcomes were defined as event occurred within 30-days. Technical success was defined as procedure completed as intended with FAP exclusion. Late outcomes included FAP related complications during follow-up. In these patients mean follow-up was 12,4 months (range: 6 - 24; SD: 6,4).

## Technique

DUGC repair was performed positioning the transducer to visualize the FAP neck. Subsequently 5 minutes compression was applied in correspondence of the FAP neck. After this period FAP patency was checked. If flow obliteration was obtained a 10 minutes manual compression was performed and FAP obliteration confirmed. If no flow obliteration was no achieved DUGC was repeated for other 5 minutes.

PTI was performed in operation room under local anaesthesia and sterile setting. Before thrombin injection, the FAP was visualised with DUS. The centre of FAP sac was accessed with a 20-gauge spinal needle. Correct placement of the needle was confirmed by the DUS appearance in both longitudinal and transverse projection. Human thrombin was injected (maximum 500 IU) into the FAP until thrombosis was confirmed by cessation of Doppler flow. After the procedure, the patient underwent to a compressive dressing in correspondence of the FAP and bed rest for at least 24 hours.

Surgical FAP repair was performed after appropriate anaesthesia with the patient placed in supine position. The common, deep, and superficial femoral arteries were explored through a vertical incision in the femoral region and encircled with elastic loops. After systemic heparinization (5,000 IU) the femoral arteries were

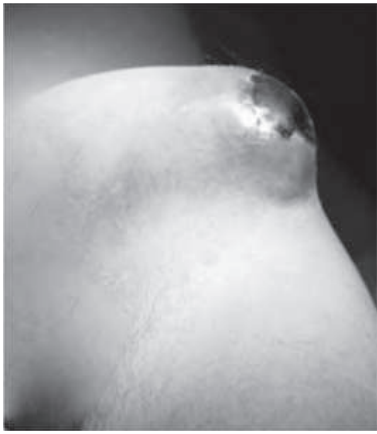

Figure 2. – Clinical presentation: large femoral pseudoaneurysm with skin ulcer.

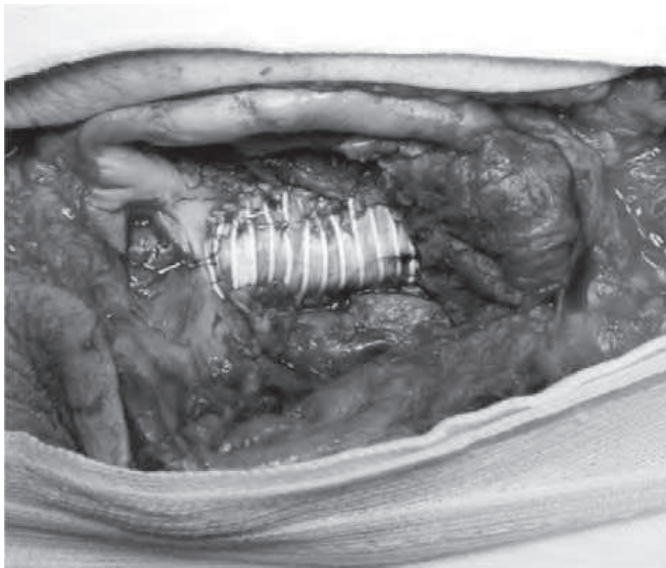


Figure 3. – Intraoperative findings: femoral artery pseudoaneurysm repair with synthetic patch.

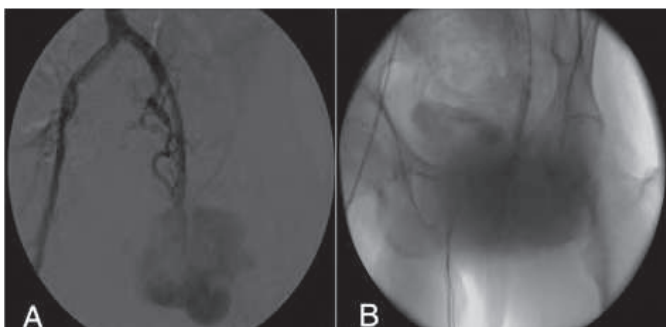


Figure 4. – A) Intraoperative angiography: large femoral pseudoaneurysm; B) Intraoperative angiography: endovascular balloon occlusion in external iliac artery.

clamped and the arterial defect repaired. When possible arterial defects were repaired by direct suture or synthetic patch. In some cases a short femoral bypass was employed due to high-grade femoral atherosclerotic disease (Figures 2, 3). In one case of large FAP, an occlusive balloon in external iliac artery was placed before femoral artery repair to reduce the risk of operative bleeding (Figures 4, 5).

## Results

A total of 50 patients presenting a FAP were included in the study period. The mean patient age was 76,4 years (range: 46 - 84; SD: 9,3) and 26 (52%) were male. Comorbidities included coronary artery disease 43 (86%), hypertension 33 (66%), 11 diabetes (22%), 33 dyslipidemia (66%). In 39 (78%) patients FAP developed after coronary intervention, in 10 (20%) after peripheral artery interventions and 1 (2%) after percutaneous foramen ovale closure. In these procedures were employed catheters from 6F to 8F. In all cases an antiplatelet or anticoagulants regime was reported and it was not interrupted for FAP repair. DUCG was used to treat 10 (20%) FAP, PTI in 30 (60%) and open surgery in 10 (20%). The mean maximum FAP diameter was 42,9 (range: 10-63; SD: 46) mm. Two (4%) large FAPs presented in association skin and femoral bifurcation disease (Table 1).

Technical success was achieved in 90% (45) of cases. In 10% (5) of patients at 24 hour from the initial DUCG treatment a patent FAP was observed. These cases were subsequently managed successfully with PTI. No mortality was registered perioperatively. Overall perioperative complications were registered in the surgical group in 3 (6%) cases. These complications consisted of wound bleeding requiring a secondary intervention, one lymphatic fistula managed conservatively with compressive dressing and a wound infection managed with systemic antibiotic therapy. During follow-up no additional complications were registered.

## Discussion

A pseudoaneurysm occurs when blood escapes from the lumen of an artery through a defect in one or more layers of the arterial wall and generates a localized pocket of flow either beneath the adventitia (outer wall of the artery) or in the surrounding tissues. Causes of iatrogenic FAP are poor haemostasis (failure to control blood flow) at the time of the initial in correspondence of the percutaneous access site or the failure of closure devices. Moreover femoral atherosclerosis is a determinant risk factor for FAP. In our experiences no closure were used. Also the use of antiplatelet or anticoagulant regime represents an issue. These patients have a higher risk of bleeding but the discontinuation of the medical treatment expose these patients to a risk of thrombosis. FAP occur in 8% of therapeutic endovascular interventions.<sup>4</sup> Typical FAP symptoms include pain, swelling, and bruising in the groin area. Moreover FAP are exposed to a rupture risk<sup>2</sup>.

Several studies indicate different risk factors for FAP such as advanced age, diabetes mellitus, obesity, chronic obstructive pulmonary disease, peripheral artery disease, hypertension and inadequate compression. Also the level of puncture in correspondence of the super-

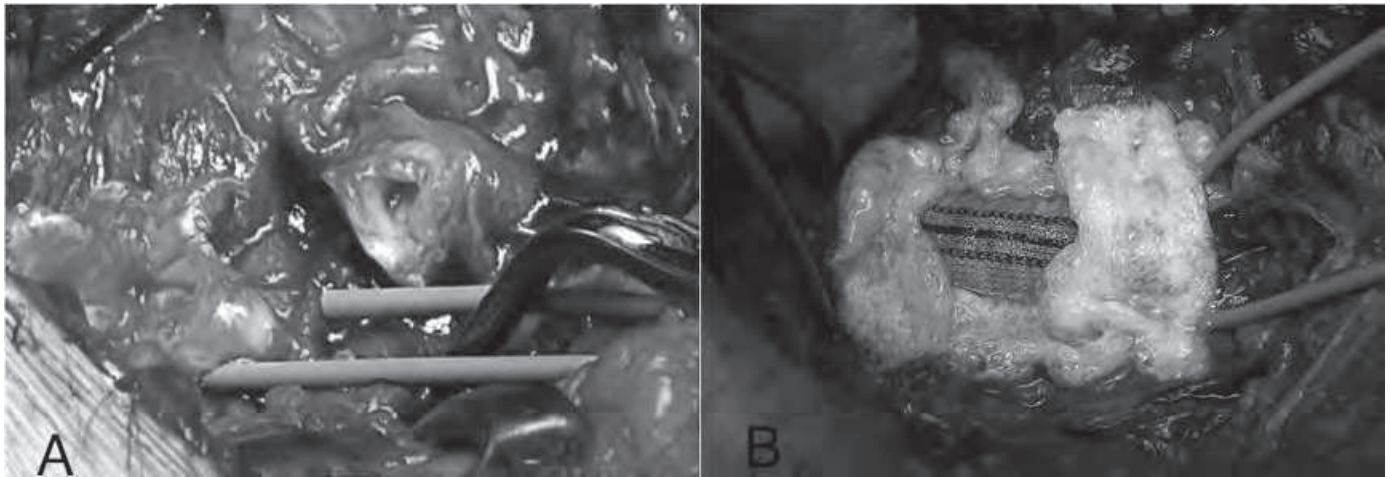


Figure 5. – A) Intraoperative findings: femoral bifurcation rupture after percutaneous procedure; B) Intraoperative findings: femoral artery pseudoaneurysm repair with synthetic patch and haemostatic sponge application.

Table I. – Case characteristics.

	Number of patients (%)
Total patients	50
Comorbidities	
– Hypertension	33 (66%)
– Coronary Artery disease	43 (86%)
– Diabetes	11 (22%)
– Dislipidemia	33 (66%)
Procedure associated with pseudoaneurysm formation	
Coronary Procedure	39 (78%)
Peripheral Revascularization	10 (20%)
Others	1 (2%)
Age	76,4 (46-84)
Pseudoaneurysm Location	
Common Femoral Artery	30 (60%)
Superficial Femoral Artery	15 (30%)
Profunda Femoral Artery	5 (10%)
Size	
Mean maximum diameter	42,9 mm (10 – 163 mm)
Treatment	
Ultrasound guide-compression	10 (20%)
Thrombolytic injection	30 (60%)
– Mean dose	350 UI
Surgery	10(20%)
– Direct Suture	8 (80%)
– Short Bypass	1 (10%)
– Patch	1 (10%)

femoral artery, deep femoral artery and external iliac artery instead of common femoral artery is clearly related to FAP formation.<sup>5,6</sup> External iliac artery punctures are also at risk of retroperitoneal hematoma.<sup>6</sup> In all these puncture sites the arterial wall is thinner rather than common femoral artery and the post-procedure compression is not effective.<sup>7</sup>

In the present study different solutions to treat FAP are reported to treat an increasingly frequent vascular iatrogenic complication.<sup>8</sup> In our experience indicates the employed technique was depending on the FAP diameter. In fact a spontaneous sealing can rarely occur but only in small FAP, thus an intervention is almost always required.

Most FAP are relatively stable, with a tendency to a slow increase during time, however in our experience an early diagnosis led to a less invasive approach such as DUGC or PTI. Moreover a non-interventional clinical observation for spontaneous thrombosis requires prolonged hospitalization and serial follow-up DUS, which is not cost-effective especially when compared to DUGC or even PTI.<sup>1</sup> Surgery has been considered the “gold standard” treatment, although its related perioperative morbidity in these high-risk patients with cardiovascular disease. To reduce the complication rate and invasiveness, treatment options such as DUGC and PTI are available, however also these options are no complications-free.<sup>2</sup> After PTI, artery thrombosis/embolism, vein thrombosis, infections within aneurysm sack, allergic reactions including anaphylactic shock have been reported. Main DUGC drawback is related to patient intolerance to compression and the need to use sedation.<sup>9</sup> Stent-graft placement has been rarely due to the need of adequate proximal and distal landing zones and the concerns regarding the coverage of common femoral artery.<sup>10</sup>

## Conclusion

In our experience the use of different tools to treat FAP according to maximal diameter was safe. Less invasive options such as DUGC and PTI were effective in 80% of cases. FAP conventional surgery should be deserved in case of less invasive procedure failure, presence of cutaneous necrosis, *ab extrinseco* compressive syndrome and large diameters (>7 cm).

## References

1. Eisemberg L, Paulson EK, Kliewer MA *et al.* Sonographically guided compression repair of pseudoaneurysms: further experience from a single institution. *AJR Am J Roentgenol* 1999;173:1567-73.
2. Tisi PV, Callam MJ. Treatment for femoral pseudoaneurysms. *Cochrane Database Syst Rev* 2013;11:CD004981.
3. Orimoto Y, Van Keulen JW, Waasdorp EJ *et al.* Treatment of a recurrent false aneurysm of the femoral artery by stent-graft placement from brachial artery *Ann Vasc Surg* 2011;25:841.
4. Eternad-Rezai R, Peck DJ. Ultrasound-guided thrombin injection of femoral artery pseudoaneurysms. *Can Assoc Radiol J* 2003;54:118-20.
5. Messina LM, Brothers TE, Wakefield TW *et al.* Clinical characteristics and surgical management of vascular complications in patients undergoing cardiac catheterization: interventional versus diagnostic procedures. *J Vasc Surg* 1991;13:593-600.
6. Schwartz LB, Clarck ET, Gewertz BL. Anastomic and other pseudoaneurysms. Rutherford RB (ed). *Vascular Surgery*. Philadelphia: W.B. Saunders; 2000. p. 752-60.
7. Huseyin S, Yuksel V, Sivri N *et al.* Surgical management of iatrogenic femoral artery pseudoaneurysms: A 10-year experience. *Hippokratia* 2013;17:332-6.
8. Chatterjee T, Do DD, Kaufmann U *et al.* Ultrasound-guided compression repair for treatment of femoral artery pseudoaneurysm: acute and follow-up results. *Cathet Cardiovasc Diagn* 1996;38:335-40.
9. Batyraliev T, Ayalp MR, Sercelik A *et al.* Complications of cardiac catheterization: a single-center study. *Angiology* 2005;56:75-80.
10. Thalhammer C, Kirchherr AS, Uhlich F *et al.* Postcatheterization pseudoaneurysms and arteriovenous fistulas: repair with percutaneous implantation of endovascular covered stents. *Radiology* 2000;214:127-31.