

# Hernia

 Springer

The World Journal of Hernia  
and Abdominal Wall Surgery

## Abstract Book

INTERNATIONAL  
CONGRESS  
OF EUROPEAN  
HERNIA SOCIETY

ISTANBUL, TURKEY  
October 6-9, 2010

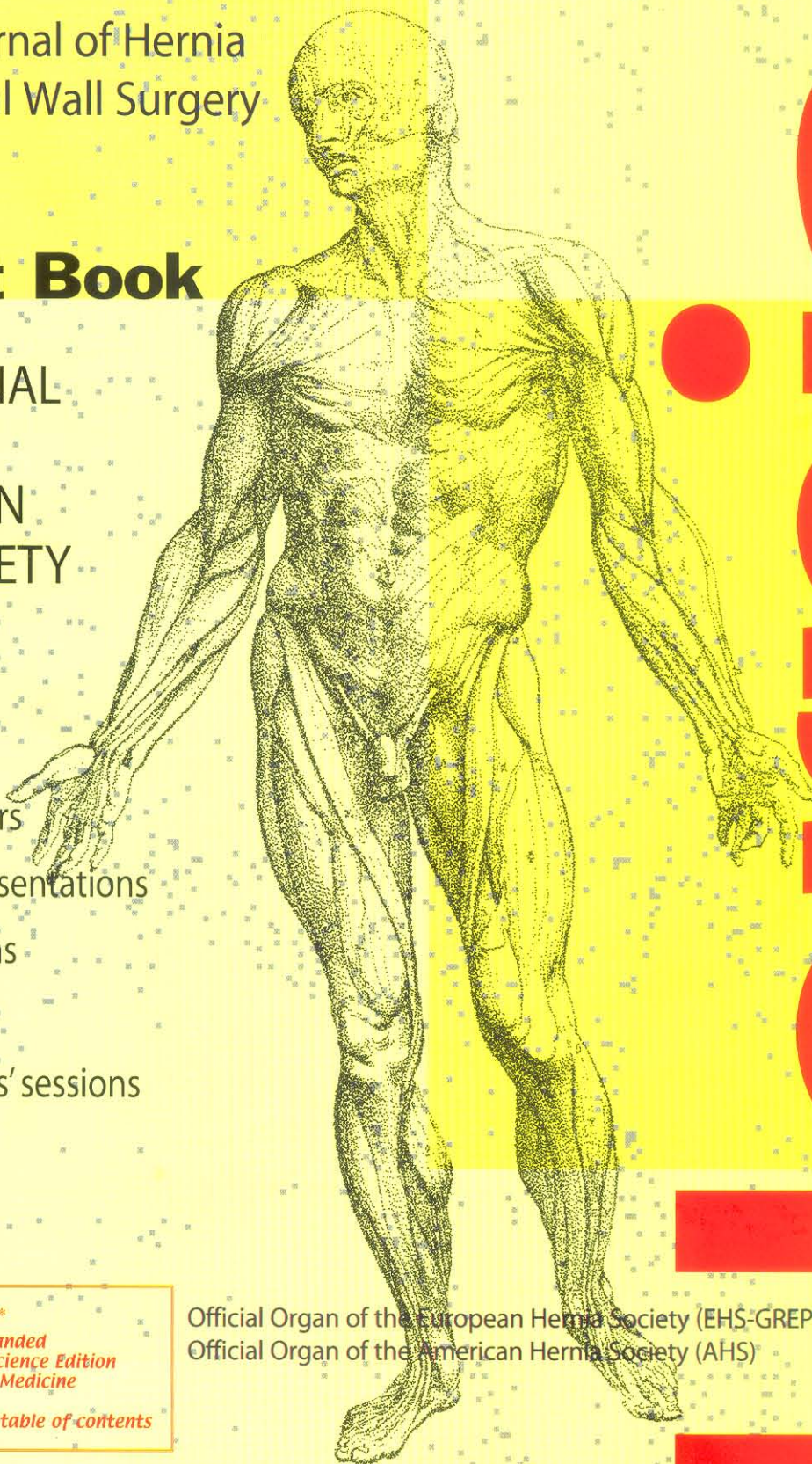
Selected free papers  
Selected video presentations  
Video presentations  
Oral presentations  
Emerging surgeons' sessions  
presentations  
Posters

*Now indexed and included in\**

- ♦ Science Citation Index Expanded
- ♦ Journal Citation Reports/Science Edition
- ♦ Current Contents®/Clinical Medicine

*\*See complete list below the table of contents*

Official Organ of the European Hernia Society (EHS-GREPA)  
Official Organ of the American Hernia Society (AHS)



operated using open suture repair; the second group patients using open mesh repair (onlay technique). The satisfaction of the patients was assessed by telephone. Postoperative evaluation included pain and discomfort in the abdomen, physical activity, and recurrence rate after operation.

**Findings:** A total of 88 patients (35 males, 53 females) with incisional hernia were operated during 2005-2010. Fifty patients were in the open technique groups, and 38 patients in the onlay mesh group. There were no significant difference in age and sex between these groups. The hospitalization time was significantly longer in the open mesh repair group. The postoperative complication (wound seroma and suppuration) rate was significantly higher in the onlay mesh group. The patients return to physical activity after surgery was significantly longer in the open technique group. Eleven patients (22%) and 4 patients (10%) in the onlay mesh groups ( $P < 0.05$ ).

**Results:** Although the postoperative complications are significantly higher after open mesh repair surgery, the hernia recurrence are lower than non-mesh repair surgery of incisional hernia. Return to normal physical activity after surgery is significantly longer after non-mesh repair surgery.

### P-111

#### Spigelian hernias: the treatment and diagnosis of our experience

Citgez B, Yetkin G, Uludag M, Akgün I, Karakoc S

*Sisli Etfal Training and Research Hospital II, General Surgery*

Spigelian hernia occur through defects in the anterior abdominal wall adjacent to the semilunar line. It is generally considered rare but is probably underdiagnosed.

This study was undertaken to characterize the history, presenting features and efficacy of surgical correction of Spigelian hernia.

**Method and Material:** Medical and surgical charts of 17 patients treated for spigelian hernia over 10 years were studied retrospectively. Patients were invited for an outpatient interview and physical examination. We retrospectively reviewed our experience of 17 patients with spigelian hernia between 2000 and 2010.

**Findings:** Dominant symptoms were an intermittent palpable mass 15 patients and postural pain 12. Two of the patients reported a history of other hernias. Computed Tomography were available that show the defect in the abdominal wall. All hernia repair was performed by underlay propylene mesh. There was no recurrence with a mean follow up of 5.7 years.

**Results:** Spigelian hernia is rare encountered and requires surgical treatment because of the risk of strangulation. The diagnosis of the spigelian hernia is an indication for surgical treatment because of the high rate of strangulation. Surgical treatment is simple and effective in the long term.

### P-112

#### Dynamic autostatic implant for inguinal hernia repair. Early results in an explorative cohort of patients

Amato G, Salamone G, Agrusa A, Romano G, Saladino V, Morfino G, Gulotta G

*Department of General Surgery, Urgency, and Organ Transplantation, University of Palermo, Italy*

Acknowledging the need to further improve outcomes and reduce complications in inguinal hernia repair, our group has been developing new surgical implants for this condition. Our primary considerations are to reduce complications associated with invasive fixation, and improve the quality of the tissue ingrowth within the implant. We have developed a new type of 3D dynamic, self retaining implant to achieve these effects. This newly designed implant was previously

experimentally tested in porcine model, showing excellent outcomes. Above all, the results concerning the quality of tissue ingrowth and the nearby absence of shrinkage in the long term were excellent. In this report we describe the preliminary results after implantation of this new implant in patients with inguinal hernia.

**Method and Material:** An explorative cohort of patients having direct and indirect inguinal hernia, was scheduled to undergo an open inguinal hernia repair with local/general anesthesia depending upon the patient's condition. After dissection and returning the hernia sack into the abdomen, the new 3D autostatic dynamic implant (Freedom I, Inshtra Medical Inc, CA, USA) was delivered into the hernia defect. A proprietary device was utilized to deliver and deploy the implant the hernia defect with no fixation. Assessments were made for: operation length, intraoperative complications, late complications such as seroma, infection, chronic pain. Patient follow up was made at 0,5, 1, 3 and 6 months. Ultrasound scans were performed for the detection of implant dislodgment and shrinkage

**Findings:** All procedures were carried out with no intraoperative complications. All patients were discharged within 12-24 hours after the operation. In the early, as well as in the late postoperative period, the patients satisfaction was subjectively reported to be high. The scheduled follow up, integrated with ultrasound scans, demonstrated a progressive tissue incorporation within the implant. In fact, we saw full obliteration of the defect and incorporation of the 3D implant starting from 15 days post implantation. No clinically relevant seroma, no infection were reported. None of the implants delivered in the groin were seen to migrate. Shrinkage was measured and deemed to be irrelevant. No signs of spermatic cord compression or testicle atrophy was seen. To date no recurrence is to be reported.

**Results:** Our results indicate that by using a purposefully designed geometric implant, expulsion forces can be diverted into gripping forces, and traumatic implant fixation can be eliminated. Thus avoiding the typical complications related to mesh fixation; such as bleeding, hematoma, chronic pain and tissue tearing, often resulting in mesh dislodgement. Placement of the dynamic implant into the hernia opening was very simple and could be performed in a very short time. Total procedure time was on average less than 30 minutes. The patients showed an excellent and speedy recovery. The dynamic compliant movement of the 3D implant structure within the groin's natural tissues allows for cyclical physiologic loading. This is well known to induce better tissue restructuring. The ultrasound examinations validated this improved tissue restructuring in the form of a thick barrier. We believe our low recurrence rate is the direct result of this definitive obliteration. The lack of shrinkage could result in less patient discomfort. The elimination of point fixation combined with the excellent tissue ingrowth, might potentially improve outcomes in hernia surgery as well as reduce the complications.

### P-113

#### Early and late results of incisional hernia repair

Kaya B, Uçtum Y, Kutanis R

*Fatih Sultan Mehmet Training and Research Hospital General Surgery; Vakıf Gureba Training and Research Hospital General Surgery*

Incisional hernia is still an important problem in general surgery practice due to reducing life quality and causing high socioeconomic costs. Its incidence is varying between 10 and 20% after laparotomy. Incisional hernia repair has changed during the last decades. While primary repair of incisional hernia has high recurrence rate, tension free repair with prosthetic material is recommended to almost every patient with incisional hernia today.

**Method and Material:** We were studied 139 patients retrospectively, operated due to incisional hernia in between January 2001 to November 2009 in Vakıf Gureba Training and Research Hospital General Surgery Department. All hernias were repaired with prolene