

## Short Report

# Misdiagnosis of familial Mediterranean fever in patients with Anderson–Fabry disease

Zizzo C, Colomba P, Albeggiani G, Gallizzi R, Iemolo F, Nuzzo D, Vasto S, Caruso C, Duro G. Misdiagnosis of familial Mediterranean fever in patients with Anderson–Fabry disease. *Clin Genet* 2013; 83: 576–581. © John Wiley & Sons A/S. Published by Blackwell Publishing Ltd, 2012

Fabry disease (FD) is an underdiagnosed pathology due to its symptomatology that overlaps with various systemic and rheumatic disorders, including familial Mediterranean fever (FMF). We examined the Mediterranean fever (MEFV) and  $\alpha$ -galactosidase A (*GLA*) genes, whose mutations are responsible for FMF and FD, respectively, in 42 unrelated patients diagnosed with FMF, which revealed significant ambiguity regarding some of the symptoms which are also present in FD. The objective of this study was to determine the spectrum of mutations present in these genes, in order to identify cases of mistaken diagnosis of FMF and/or missed diagnosis of FD. Ten out of 42 patients had one mutation in homozygosis or two different mutations in heterozygosis in the *MEFV* gene; 20/42 had a single heterozygous mutation, and 12/42 did not have genetic alterations in *MEFV*. The analysis of the *GLA* gene conducted on all the samples revealed that three subjects, and some members of their families, had two different exonic mutations associated with FD. Family studies allowed us to identify eight other cases of FD, bringing the total undiagnosed subjects to 11/53. Analyzing the *MEFV* and *GLA* genes in patients with clinical diagnoses of FMF proved to be fundamentally important for the reduction of diagnostic errors.

### Conflict of interest

The authors declare that they have no competing interests.

**C Zizzo<sup>a</sup>, P Colomba<sup>a</sup>,  
G Albeggiani<sup>a</sup>, R Gallizzi<sup>b</sup>,  
F Iemolo<sup>a,c</sup>, D Nuzzo<sup>a</sup>,  
S Vasto<sup>d</sup>, C Caruso<sup>d</sup> and G  
Duro<sup>a</sup>**

<sup>a</sup>National Research Council, Institute of Biomedicine and Molecular Immunology “A. Monroy”, IBIM-CNR, Palermo, Sicily, Italy, <sup>b</sup>Department of Pediatric Sciences, University of Messina, Messina, Sicily, Italy, <sup>c</sup>Department of Neurology, Guzzardi Hospital, Vittoria, Sicily, Italy, and <sup>d</sup>Dipartimento di Biopatologia e Biotecnologie Mediche e Forensi, University of Palermo, Palermo, Sicily, Italy

Key words: Fabry disease – familial Mediterranean fever – misdiagnosis –  $\alpha$ -galactosidase A

Corresponding author: Giovanni Duro, National Research Council, Institute of Biomedicine and Molecular Immunology “A. Monroy”, IBIM-CNR, Via Ugo La Malfa 153, 90146, Palermo, Italy.  
Tel.: +39 091 6809507;  
fax: +39 091 6809603;  
e-mail: duro@ibim.cnr.it

Received 23 May 2012, revised and accepted for publication 13 July 2012

Fabry disease (FD) is a lysosomal enzymopathy, caused by the mutations in the  $\alpha$ -galactosidase A (*GLA*) gene, with extremely heterogeneous clinical manifestations (1). As FD is an X-linked disease, affected women are mostly heterozygotes with random X-chromosome inactivation, and they generally have less-evident symptoms, making diagnosis more difficult (2).

FD is considered a rare pathology, having an estimated incidence for its classical form of 1:40,000 live male births. However FD is still underdiagnosed, the average delay from the onset of symptoms to diagnosis is more than a decade (3). The underestimation of the disease is mainly because of its clinical expression, as FD can be confused with other systemic disorders which present similar symptoms and is often treated as an organ pathology.

Literature reports cases in which the overlapping of clinical indicators of FD with certain rheumatic disorders, such as familial Mediterranean fever (FMF), made the diagnosis of FD difficult and time consuming (4, 5). Both diseases are hereditary disorders with similarities in their onset of symptoms and clinical manifestations: the first problems arise during childhood, with clinical features such as recurrent febrile episodes, abdominal and joint pain, gastrointestinal disorders and renal damage.

FMF is considered a genetic autosomal recessive disease occurring in Mediterranean and Middle Eastern populations (6). The onset of the disease is characterized by recurrent acute febrile episodes of brief duration, associated with painful manifestations. The standard treatment for FMF is daily administration

## Misdiagnosis of familial Mediterranean fever in patients with Anderson–Fabry disease

of colchicine, which aids in the control of symptoms and prevents the occurrence of renal amyloidosis. Mediterranean fever (*MEFV*) is the gene responsible for the disease and the genetic diagnosis of FMF is positive when one mutation in homozygosis or two different mutations in heterozygosis (combined heterozygotes) are present in the *MEFV* gene (7). However, it has been observed that up to 30% of patients with FMF-compatible symptomatology and optimal response to colchicine had only one mutation in the *MEFV* gene (8).

In order to identify possible cases of mistaken diagnosis of FMF and/or missed diagnosis of FD, we analyzed mutations in the *MEFV* and *GLA* genes of 42 unrelated patients with clinical diagnoses of FMF, which revealed significant ambiguity regarding some of the symptoms which are also present in FD.

### Materials and methods

#### Patient specimens

We studied 42 patients, along with family members of some of these patients, from Southern Italy, the part of the country with the highest frequency of FMF. Signed informed consent was obtained from all participants for genetic analysis and publication of data.

Peripheral blood was collected, using ethylenediaminetetraacetic acid as an anticoagulant. DNA samples were isolated from whole blood by column extraction.

#### HRM analysis and DNA sequencing

A pre-sequencing screening was performed on DNA samples by high resolution melting (HRM) analysis for the study of the exons of the *MEFV* and *GLA* genes. The Light Cycler 480 system (Roche Applied Science, Penzberg, Germany) was used, as previously described (9).

Purified polymerase chain reaction products were sequenced using the automated DNA sequencer at BMR Genomics.

#### $\alpha$ -Galactosidase activity assay

The activity of GLA was determined by the ‘dried blood filter paper’ test described by Chamoles et al., with minor modifications (10).

### Results

We performed the genetic study of the *MEFV* and *GLA* genes by HRM analysis, and sequencing of DNA extracted from blood samples of 42 patients with clinical diagnoses of FMF. The results of the genetic analysis and clinical data are reported in Table 1.

In the cases that we studied, we found several mutations in the *MEFV* gene that have been previously described in the literature (<http://fmf.igh.cnrs.fr>): 7/42 subjects (16.7%) had a homozygous mutation; 3/42 subjects (7.1%) were combined heterozygotes; in 20/42

subjects (47.6%) a single mutation in the *MEFV* gene was found. Twelve of 42 subjects (28.6%) did not have any mutations in *MEFV*.

We also conducted analysis of the *GLA* gene on all the samples, and for the patients found to have mutations in the gene, the analysis was extended to their relatives. Two different mutations were found in three unrelated subjects, as well as in some members of their families. Two patients (23 and 38) were found to have the *S126G* mutation, also known as c.376A>G (Fig. 1a–c), on exon 3, which is responsible for the classical form of FD (11), another (patient 27) was found to have the *M51I* mutation, also known as c.153G>A (Fig. 1d–f), on exon 1, which according to literature is responsible for a late-onset form of FD (12).

Patient 23 is a 20-year-old female affected by acute bilateral arthritis of the phalanges, and fevers  $\leq 38^{\circ}\text{C}$  which is not related to other pathologies. The fever lasted for several months as night fever and did not respond to paracetamol, cortisone and/or antibiotics and was accompanied by persistent arthralgia. In her medical history, the patient also reported mild acroparesthesias and other paroxysmal pains, in addition to renal symptoms and mild left ventricular hypertrophy. The genetic analysis of *MEFV* gene in the patient reported one mutation in heterozygosis, P369S (Table 2A). The same genetic alteration was found in the patient’s father, who had also the mutation E148Q, making him a combined heterozygote. The patient’s sister had the mutation E148Q in heterozygosis whereas her mother did not have any mutations in *MEFV*. The analysis of the *GLA* gene in patient 23 revealed the *S126G* mutation on exon 3 (Table 2A); her mother and sister also turned out to be carriers of the same mutation. They presented many systemic symptoms whose mild nature is a characteristic of female subjects affected by FD, due to the phenomenon of random X-chromosome inactivation. Analysis of GLA activity in members of this family showed that the female carriers of the *S126G* mutation had residual enzymatic activity slightly lower than the norm (Table 2A).

Patient 27 is an 18-year-old female with recurrent bouts of abdominal and distal extremity pain, accompanied by fever for approximately 6 months. During these episodes, she was treated with non-steroidal anti-inflammatory drugs, antibiotics and antipyretics, without any effect on the fever. The patient also presented mild cardiac and neurological symptoms. The intermittent nature of the clinical manifestations and the presence of fever during the painful attacks have led her physician to consider FMF as the presumptive diagnosis. The presence of proteinuria, which may be attributable to the development of amyloidosis, was also taken to be evidence of FMF. The analysis of her *MEFV* gene reported one mutation in heterozygosis, A744S, which is also present in her father (Table 2B). The analysis of the *GLA* gene in the patient revealed the *M51I* mutation on exon 1 (Table 2B). The same genetic alteration was also found in the patient’s mother, aunt (her mother’s sister), uncle (her

Table 1. Genetic diagram of GLA and MEFV and clinical data of patients with presumptive diagnosis of FMF

No	Sex/age	MEFV mutations	GLA mutations	Fever attacks	Abdominal pains	Arthritis	Gastrointestinal manifestations	Recurrent headaches	Other signs	Family study
1	M/21	M694V/M694V	-	+	+	+	+	+	-	ND
2	F/24	M694V/M694V	-	+	+	+	+	+	-	ND
3	M/20	M694V/M694V	-	+	+	-	+	-	-	ND
4	M/8	M694V/M694V	-	+	-	+	-	+	-	ND
5	M/20	M680I/M680I	-	+	+	-	+	-	-	ND
6	M/47	M680I/M680I	-	+	+	-	+	-	-	ND
7	M/26	R761H/R761H	-	+	+	-	+	-	-	ND
8	F/56	M694V/E148Q	-	+	+	+	+	+	Angiokeratomas, renal, neurologic	ND
9	M/37	M694V/ M694I	-	+	+	+	+	-	Cardiac	ND
10	M/38	M680I/V726A	-	+	+	-	-	+	-	ND
11	F/36	M680I	-	+	+	+	+	+	Angiokeratomas, cardiac	ND
12	F/37	M680I	-	-	-	+	-	+	-	ND
13	M/25	M680I	-	-	-	+	-	+	-	ND
14	M/57	M680I	-	-	-	-	-	+	-	ND
15	F/21	M680I	-	-	-	-	-	-	Renal	ND
16	F/41	E148Q	-	+	-	+	+	+	Cardiac, neurologic	ND
17	M/18	E148Q	-	+	+	+	+	+	-	ND
18	F/61	E148Q	-	-	-	+	-	+	Angiokeratomas	ND
19	M/8	E148Q	-	-	+	+	-	+	-	ND
20	M/10	E148Q	-	+	+	-	-	+	-	ND
21	F/7	E148Q	-	+	-	-	-	-	-	ND
22	M/3	P369S	-	+	+	-	-	-	-	ND
23	F/20	P369S	S126G	+	-	+	-	-	Cardiac, renal	+
24	M/7	-	-	+	+	+	-	-	-	ND
25	F/42	-	-	+	+	-	+	+	-	ND
26	F/40	-	-	+	+	+	-	-	Angiokeratomas, cardiac, neurologic	ND
27	F/18	A744S	M51I	+	+	+	-	-	Cardiac, neurologic, renal	+
28	F/30	-	-	+	+	-	+	-	-	ND
29	F/8	-	-	+	-	+	-	+	Neurologic	ND
30	M/17	-	-	-	-	+	-	+	-	ND
31	M/11	-	-	+	+	+	-	-	-	ND
32	M/53	M694V	-	-	-	+	-	+	-	ND
33	F/57	M694V	-	-	-	+	-	-	Cardiac	ND
34	M/23	M694V	-	+	+	-	+	+	-	ND
35	M/6	K695R	-	+	+	-	-	-	-	ND
36	F/18	R761H	-	+	+	+	+	+	Renal	ND
37	F/33	V726A	-	+	-	+	+	+	Renal, cardiac	ND
38	F/30	-	S126G	+	+	-	+	-	-	+
39	F/35	-	-	+	-	-	+	+	-	ND
40	F/45	-	-	+	-	+	+	+	Cardiac, neurologic	ND
41	F/64	-	-	+	+	+	+	+	Cardiac, neurologic	ND
42	F/20	-	-	+	-	-	+	+	-	ND

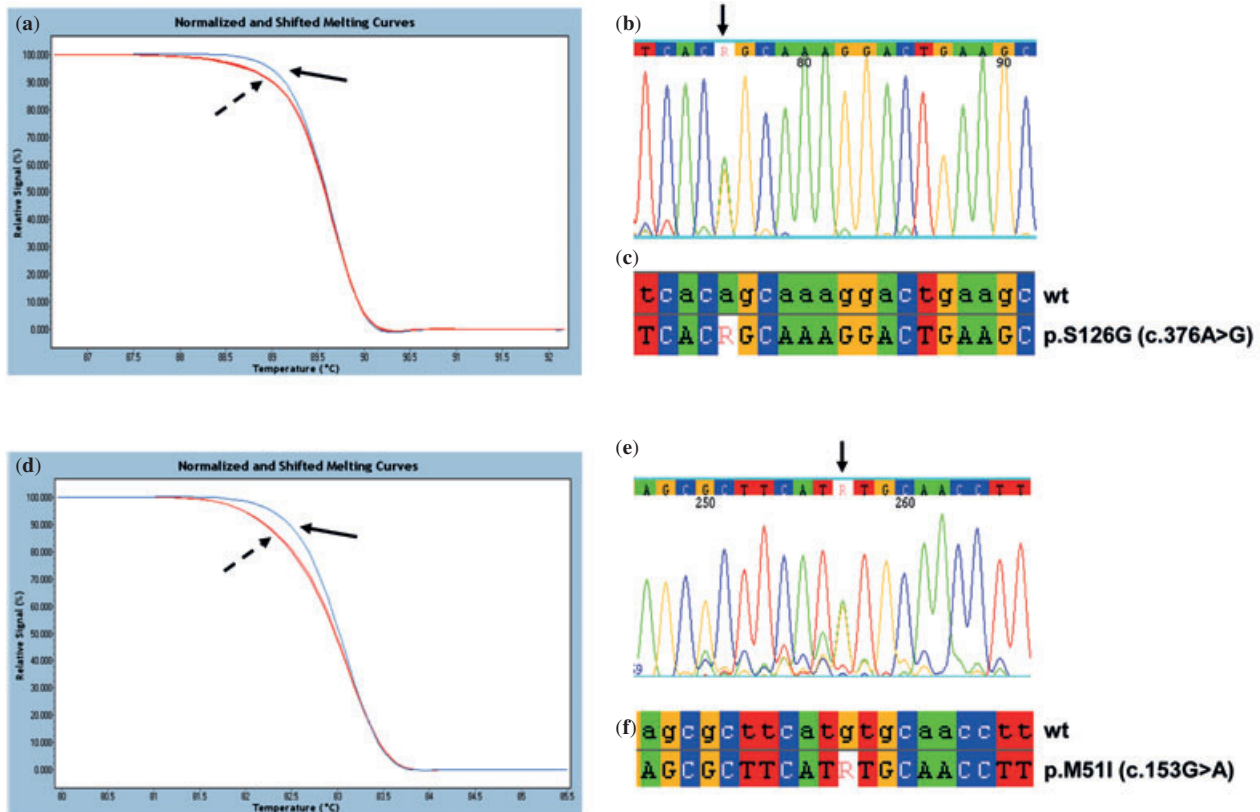
+, yes; -, no; F, female; FMF, familial Mediterranean fever; GLA,  $\alpha$ -galactosidase A; M, male; MEFV, Mediterranean fever; ND, not determined.

mother's brother) and cousin (son of the aunt). The patient's mother suffered from left ventricular hypertrophy, recurrent headaches and intolerance to heat and/or cold; a careful medical history revealed in the other family members carrying the same mutation several systemic symptoms with renal, cardiac and neurological manifestations. The GLA activity in patient 27, her mother and aunt were slightly below the norm, while

that of the uncle and cousin were completely absent (Table 2B).

Patient 38 is a 30-year-old woman who presented with recurrent fever and significant gastrointestinal involvement with repeated attacks of abdominal pain. The inflammatory background, together with her medical history, suggested a diagnosis of FMF. The genetic analysis of *MEFV* in the patient did not report

## Misdiagnosis of familial Mediterranean fever in patients with Anderson–Fabry disease



**Fig. 1.** (a) High resolution melting (HRM) analysis of exon 3 of the  $\alpha$ -galactosidase A (GLA) gene in patients 23 and 38 (curves indicated by dashed arrow) and in healthy control (curve indicated by solid arrow). (b) Portion of the electropherogram of exon 3 of the GLA gene in patient 23, showing c.376A>G mutation in heterozygosis (corresponding to S126G) indicated by the arrow. (c) Portion of the sequence of exon 3 of the GLA gene in patient 23 aligned with the corresponding sequence of a wt control. (d) HRM analysis of exon 1 of the GLA gene in patient 27 and her mother (curves indicated by dashed arrow) and in a wt control (curve indicated by solid arrow). (e) Portion of the electropherogram of exon 1 of the GLA gene in patient 27, in which c.153G>A mutation in heterozygosis (corresponding to M51I) is indicated by the arrow. (f) Portion of the sequence of exon 1 of the GLA gene in patient 27 aligned with the corresponding sequence of a wt control. The mutations A>G and G>A are indicated by the letter R [International Union of Pure and Applied Chemistry (IUPAC) nomenclature].

any mutations; the analysis of *GLA* however, revealed the S126G mutation on the exon 3 (Table 2C). Her mother and sister also had the same mutation. Clinical analyses in these two subjects showed mild systemic symptoms, such as recurrent headaches, abdominal pains and cardiac involvement with signs of left ventricular hypertrophy. The residual enzymatic activity of GLA in the patient 38 and her relatives carrying this mutation (Table 2C) is explained by the fact that they are all female.

### Discussion

FD is a genetic disease that is currently underdiagnosed because of its clinical manifestations that can suggest other pathologies. In fact, some features of FD, in the absence of a severe clinical picture, can easily be confused with those of other systemic disorders leading to its misdiagnoses.

In cases in which the patient presents recurrent attacks of fever, abdominal and joint pains, gastrointestinal problems and renal damage, in the absence of other findings indicative of a specific systemic disorder

and in the presence of a specific ethnic background, clinicians are often led to diagnose FMF. Although it is a rare disease it becomes the primary diagnostic hypothesis.

In this article, we present the results of a study conducted on 42 patients whose clinical manifestations and geographic origins led to clinical diagnoses of FMF. For these subjects, we have determined the spectrum of mutations present in the *MEFV* and *GLA* genes to identify cases of possibly mistaken FMF diagnoses and/or missed diagnoses of FD.

Our results have shown that in 23.8% of the subjects studied who had two mutations in the *MEFV* gene, the symptomatology was strongly attributable to FMF. Another 47.6% of the studied subjects had a single mutation in heterozygosis in the *MEFV* gene; a detailed clinical analysis of these patients revealed that they showed a mild FMF phenotype, and some of them also had other signs and symptoms not related to the disease (Table 1). Several hypotheses have been proposed to explain the development of clinical symptoms in subjects carrying a single mutation in a disease such as FMF, which is considered to be recessive.



Table 2. GLA and MEFV genetic diagram of the 3 families studied

		Kinship	Sex/age	Enzyme activity (nmol/ml/h)	GLA mutation	MEFV mutation
A	Family 1	Patient 23	F/20	3.2	S126G	P369S
		Father	M/54	5.6	—	E148Q/P369S
		Mother	F/53	2.3	S126G	—
		Sister	F/23	3.2	S126G	E148Q
B	Family 2	Patient 27	F/18	2.6	M51I	A744S
		Father	M/49	5.3	—	A744S
		Mother	F/52	3.5	M51I	—
		Uncle	M/54	0.0	M51I	—
		Aunt	F/51	3.3	M51I	—
		Cousin	M/24	0.0	M51I	—
C	Family 3	Patient 38	F/30	3.9	S126G	—
		Father	M/61	5.5	—	—
		Mother	F/57	2.6	S126G	—
		Sister	F/33	3.3	S126G	—

—, no mutation; F, female; GLA,  $\alpha$ -galactosidase A; M, male; MEFV, Mediterranean fever.

Normal values of GLA activity assayed in whole blood are  $>3.5$  nmol/ml/h; however, in females, this assay give no clear indication, as is discussed in the text.

These include the pseudo-dominant inheritance of some mutations and the possible involvement of other genes (modifier genes) that contribute to the clinical variability of heterozygous patients. Furthermore, due to the overlapping of clinical features of FMF with other disorders characterized by systemic involvement, the symptomatology may be determined by another disease caused by mutations in other genes. In our study, 28.6% of the patients studied did not have genetic alterations in MEFV, so in these subjects, the presence of symptoms may be due to other diseases with similar clinical manifestations (4).

The results of the study of the *GLA* gene in subjects harboring a single genetic alteration in MEFV, or without mutations in this gene, were quite interesting; indeed, in 9.4% of the cases, the S126G and M51I exonic mutations were found which, according to literature, are responsible for FD. This percentage is very significant, and confirms that the presence of the disease is underestimated. The S126G and M51I amino acid substitutions present in three unrelated subjects of the study were also detected in other members of their families who, upon careful analysis, showed some symptoms of FD. In fact, the diagnoses of FD suggested the need to conduct a family study, which allowed the disease to be identified in another eight members of their families, bringing the total number of undiagnosed subjects to 11/53.

The clinical symptoms presented by subjects carrying mutations in the *GLA* gene can thus be explained by the diagnosis of FD, which was not considered at the beginning. The correct diagnosis of FD is important not only for etiological reasons but, above all, for the initiation of the correct therapy so that the patients do not undergo useless doses of colchicine because of the diagnosis of FMF. Instead, they can undergo enzyme replacement therapy which is available for the treatment of FD. Furthermore, the diagnosis of FD, as it suggests the need for the analysis of other family members, can facilitate

the identification of the disease in other relatives who may be asymptomatic because of their age or sex.

In conclusion, we are convinced that the analysis of the *MEFV* and *GLA* genes, as well as a careful analysis of family medical history and other diagnostic tools which can help identify the clinical features of FD, should be performed for all patients presenting ambiguous symptomatological patterns of FMF.

#### Acknowledgements

This work was supported by a financial contribution of Shire Italia—Human Genetic Therapies. The authors confirm their independence from the sponsors. The content of the article has not been influenced by the sponsors.

C.Z. conducted the experiments and drafted the manuscript; P.C. participated in the experiments and the drafting of the manuscript; G.A. carried out the enzymatic analysis; R.G. participated in the acquisition and interpretation of data; D.N. participated in the experiments; F.I. participated in the acquisition and interpretation of data; S.V. performed the statistical analysis; C.C. participated in the interpretation of data; G.D. designed and coordinated the study, including obtaining the informed consent and ethics approval to conduct the study.

#### Ethics approval

The study was approved by the University Hospital Ethics Committee.

#### References

- Desnick RJ, Ioannou YA, Eng CM. Alpha-galactosidase A deficiency: Fabry disease. In: Scriver CR, Beaudet AL, Sly WS, Valle D, Childs B, Kinzler KE, Vogelstein B, eds. The metabolic and molecular bases of inherited disease, 8th edn. New York, NY: McGraw-Hill, 2001: 3733–3774.
- Dobrovolny R, Dvorakova L, Ledvinova J et al. Relationship between X-inactivation and clinical involvement in Fabry heterozygotes. Eleven novel mutations in the alpha-galactosidase A gene in the Czech and Slovak population. *J Mol Med* 2005; 83 (8): 647–654.

## Misdiagnosis of familial Mediterranean fever in patients with Anderson–Fabry disease

- Hoffmann B, Mayatepek E. Fabry disease-often seen, rarely diagnosed. *Dtsch Arztebl Int* 2009; 106 (26): 440–447.
- Dinc A, Simsek I, Pay S, Caglar K, Can C. Fabry's disease mimicking familial Mediterranean fever. *Clin Exp Rheumatol* 2000; 18 (6): 787–788.
- Lidove O, Kaminsky P, Hachulla E et al. Fabry disease 'The New Great Imposter': results of the French Observatoire in Internal Medicine Departments (FIMeD). *Clin Genet* 2012; 81 (6): 571–577.
- Ben-Chetrit E, Touitou I. Familial mediterranean Fever in the world. *Arthritis Rheum* 2009; 61 (10): 1447–1453.
- Padeh S, Livneh A, Pras E et al. Familial Mediterranean Fever in the first two years of life: a unique phenotype of disease in evolution. *J Pediatr* 2010; 156 (6): 985–989.
- Booth DR, Gillmore JD, Lachmann HJ et al. The genetic basis of autosomal dominant familial Mediterranean fever. *QJM* 2000; 93 (4): 217–221.
- Bono C, Nuzzo D, Albegiani G et al. Genetic screening of Fabry patients with EcoTILLING and HRM technology. *BMC Res Notes* 2011; 4: 323.
- Chamoles NA, Blanco M, Gaggioli D. Fabry disease: enzymatic diagnosis in dried blood spots on filter paper. *Clin Chim Acta* 2001; 308 (1–2): 195–196.
- Altarescu GM, Goldfarb LG, Park KY et al. Identification of fifteen novel mutations and genotype-phenotype relationship in Fabry disease. *Clin Genet* 2001; 60 (1): 46–51.
- Spada M, Pagliardini S, Yasuda M et al. High incidence of later-onset Fabry disease revealed by newborn screening. *Am J Hum Genet* 2006; 79 (1): 31–40.